

研究要旨:慢性活動性 EB ウイルス病とその類縁疾患の診療ガイドライン、また、CAEBV ガイドライン英文訳に併せて種痘様水疱症リンパ増殖異常症および重症蚊アレルギーに対する診断基準と重症度判定基準を作成した。タイトル名 ; “Diagnostic and disease severity determination criteria for hydroa vacciniforme lymphoproliferative disorders and severe mosquito bite allergy” 雑誌名 : The Journal of Dermatology で 2023 年 3 月に受理された。この成果は、今後の患者登録、統計分析、および治療効果評価等の研究において貢献できると考えている。本研究成果を用いて、引き続き、患者登録・疫学調査を行っている。

A. 研究目的

慢性活動性 EB ウイルス病 (CAEBV) とその類縁疾患の診療ガイドライン、また、CAEBV ガイドライン英文訳に併せて種痘様水疱症リンパ増殖異常症 (HV-LPD) および重症蚊刺アレルギー (SMBA) に対する診断基準と重症度判定基準の作成を目的とした。

B. 研究方法

CAEBV とその類縁疾患の診療ガイドライン、また、CAEBV ガイドライン英文訳に併せて種痘様水疱症および重症蚊アレルギーに対する診断基準と重症度判定基準を作成した。診断基準および重症度判定基準あたり、種痘様水疱症リンパ増殖異常症 (HV-LPD) と重症蚊刺アレルギー (SMBA)、CAEBV、EBV 関連血球貪食性リンパ組織球症 (EBV-HLH)、EBV 関連リンパ腫・白血病など、病因的に関連する疾患について文献調査を実施した。WHO 分類第 5 版および CAEBV とその関連疾患について新たに発表された用語と定義と一致するように改訂した。また、本研究は個人情報や人体から採取された試料等を用いず、倫理面の問題がないと判断した。

C. 研究結果

研究班で協議の上、HV-LPD および SMBA の診断アルゴリズム (図 2)、HV-LPD の診断基準及び重症度分類 (図 3)、SMBA の診断基準及び重症度分類 (図 4) について作成した。

D. 考察

HV-LPD および SMBA は EB ウイルス陽性の T/NK 細胞リンパ増殖異常症の皮膚型に相当する (図 1)。両疾患は時に重複し、CAEBV に匹敵する重篤な状態に進行することから、CAEBV の皮膚型にも分類されて

いる。HV-LPD と SMBA には、CAEBV と明確に区別できるコンセンサス診断基準や重症度分類がまだ存在しておらず、これらの基準を診断アルゴリズムと共に作成した。今後の患者登録、統計分析、および治療効果評価等の研究において貢献できると考えている。

E. 結論

HV-LPD と SMBA について、診断アルゴリズムを用いた疾患スペクトラムの定義と診断基準、また重症度判定基準を作成し国際発信した。本研究成果を用いて、引き続き、患者登録・疫学調査を行っている。

G. 研究発表

1. 論文発表

タイトル名 ; “Diagnostic and disease severity determination criteria for hydroa vacciniforme lymphoproliferative disorders and severe mosquito bite allergy” 雑誌名 : The Journal of Dermatology で 2023 年 3 月に受理された。

(J Dermatol. 2023 Jul;50(7):e198-e205.)

2. 学会発表

該当なし

3. 一般向け講演会

該当なし

H. 知的財産権の出現・登録状況

1. 特許取得 該当なし

2. 実用新案登録 該当なし

3. その他 該当なし

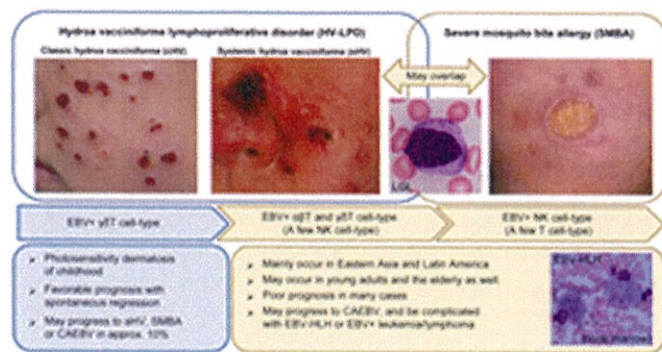


図 1 HV-LPD および SMBA の疾患スペクトラム (J Dermatol. 2023 Jul;50(7):e198-e205.)

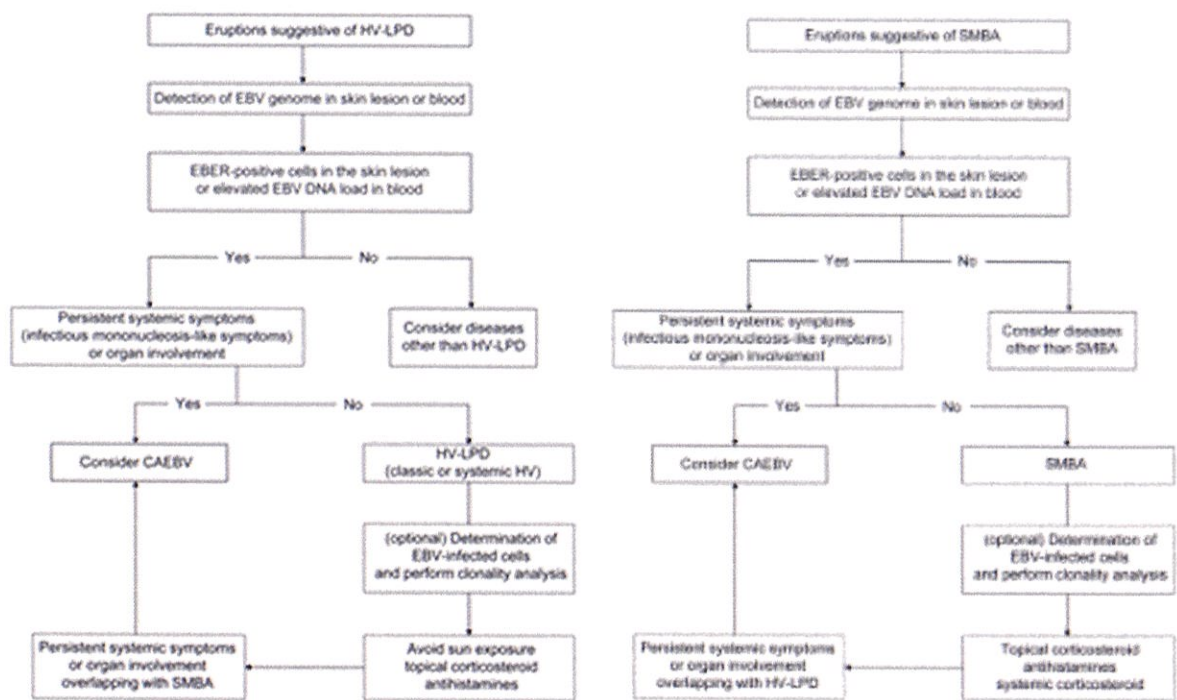


図 2 HV-LPD および SMBA の診断アルゴリズム (J Dermatol. 2023 Jul;50(7):e198-e205.)

| | |
|---|---|
| <p>I. Classic hydroa vacciniforme (cHV)</p> <p>1) Herpetic vesicles and papules/crusts on sun-exposed areas including face, auricles, and dorsal surfaces of the hands.</p> <p>2) EBV-infected cells or the virus-gene products can be detected in the skin lesions</p> <p>3) The number of EBV-positive T cells is increased in peripheral blood.</p> <p>4) The level of EBV DNA load in the blood is high.</p> <p>5) The following diseases are excluded: other known skin diseases, CAEBV, and SMBA.</p> <p>The definite case fulfills all of the above Nos. 1)–5).</p> <p>The probable case fulfills No. 1) and has at least one of Nos. 2) and 3).</p> <p>The possible case fulfills Nos. 1) and 4).</p> | |
| <p>II. Systemic hydroa vacciniforme (sHV)</p> <p>In addition to Nos. 1)–4),</p> <p>6) Swollen edematous face and lips, transient fever, liver damage, and lymphadenopathy are present.</p> <p>7) The following diseases are excluded: other known skin diseases and EBV-associated lymphoma/leukemia</p> <p>The definite case fulfills all of the above Nos. 1)–7).</p> <p>The probable case fulfills Nos. 1) and 6), and has at least one of Nos. 2) and 3)*.</p> <p>The possible case fulfills Nos. 1), 4), and 6).</p> <p>*NK-cell-dominant cases can be included in systemic hydroa vacciniforme.</p> | |
| <p>Supplementary explanation</p> <p>Classic hydroa vacciniforme (cHV)</p> <p>1) In addition to herpetic vesicles, cHV may be accompanied with conjunctival hyperemia and aphthous stomatitis of the lips and gingiva.</p> <p>2) Detection of EBV-encoded small nuclear RNA (EBER)-positive cells in the skin biopsy samples is a standard method, but when biopsy is difficult, the blister roof or crusts can be used instead for EBER detection by RT-PCR (at a research level).</p> <p>3) The cHV usually occurs in childhood, associated with an increased number of EBV-infected $\gamma\delta$T cells (>5% of all lymphocytes). The sHV may occur even in young and old adults as well as in children, and include either EBV-infected $\alpha\beta$T-cell-dominant or $\gamma\delta$T-cell-dominant type. Flow cytometry–fluorescent in-situ hybridization or immunomagnetic bead-aided quantitative PCR is performed at a research level to confirm EBV infection in the T cell fraction.</p> <p>4) The standardized value of elevated EBV DNA load in whole blood is $>1 \times 10^4$ IU/mL.</p> <p>5) The following diseases should be excluded: herpes simplex, varicella-zoster virus infection, Kaposi's varicelliform eruption, porphyria, polymorphic light eruption, impetigo contagiosum, acne, and lymphomatoid papulosis. The overlapping of CAEBV should be considered according to the diagnostic algorithm if patients have the following symptoms: infectious mononucleosis-like symptoms for >3 months, persistent fever, and organ involvement (see the CAEBV algorithm).</p> <p>Systemic HV (sHV)</p> <p>6) Swelling of the face, eyelids, and lips can occur in extranodal NK/T-cell lymphoma, nasal type (ENKTL-NT) and aggressive NK-cell leukemia, but both diseases usually lack herpetic vesicles.</p> <p>7) HV-LPD, especially the sHV, may overlap severe mosquito bite allergy (SMBA) associated with systemic symptoms, thereby often being included in the category of cutaneous CAEBV. The cutaneous form, however, is not the same as CAEBV defined in the present diagnostic criteria. HV-LPD may progress to ENKTL-NT and aggressive NK-cell leukemia.</p> <p>HV-LPD, hydroa vacciniforme lymphoproliferative disorder; cHV, classic hydroa vacciniforme; sHV, systemic hydroa vacciniforme; EBV, Epstein–Barr virus; CAEBV, chronic active Epstein–Barr virus disease; SMBA, severe mosquito bite allergy; EBER, EBV-encoded small nuclear RNA; RT-PCR, reverse</p> | |
| Mild | No systemic symptoms* or organ involvement, except for the characteristic mucocutaneous lesions |
| Moderate | Characteristic mucocutaneous lesions associated with edema of the face, eyelids, or lips Characteristic mucocutaneous lesions associated with transient systemic symptoms* |
| Severe | Overlapping with SMBA Fulfilled diagnostic criteria for CAEBV Complicated with EBV-HLH or progression to EBV-related T/NK lymphoma/leukemia |
| <p>*Systemic symptoms include fever $>37.5^{\circ}\text{C}$, liver damage, and lymphadenopathy, excluding specific organ involvement.</p> <p>The disease severity is classified into the mild (exclusively cHV), moderate or severe disease by the most severe item.</p> | |
| <p>HV-LPD, hydroa vacciniforme lymphoproliferative disorder; SMBA, severe mosquito bite allergy; EBV, Epstein–Barr virus; CAEBV, chronic active Epstein–Barr virus disease; EBV-HLH, EBV-associated hemophagocytic lymphohistiocytosis; T/NK, T cell, or natural killer cell.</p> | |

図 3 HV-LPD の診断基準及び重症度分類 (J Dermatol. 2023 Jul;50(7):e198–e205.)

| | |
|---|---|
| <p>1) Skin redness, swelling, and ulcers occur in the sites of mosquito bites and vaccine injection accompanied with fever, followed by scar formation, but the patients are asymptomatic without such provocative factors.</p> <p>2) EBV-infected cells or the virus-gene products can be detected in the skin lesions.</p> <p>3) The level of EBV DNA load is elevated in the blood.</p> <p>4) The number of LGLs or EBV-infected NK cells is increased in the peripheral blood.</p> <p>5) Skin reactions caused by a known allergic mechanism or underlying diseases are excluded.</p> <p>The definite case fulfills all of the above Nos. 1)–5).</p> <p>The probable case fulfills No. 1) and has at least one of Nos. 2) and 4).</p> <p>The possible case fulfills Nos. 1) and 3).</p> | |
| <p>Supplementary explanation</p> <p>1) SMBA is mostly induced by mosquito bites, but it can also be caused by other insect bites and vaccine injection. Patients may present with transient systemic symptoms including fever, lymphadenopathy, and liver dysfunctions. Scar formation resulting from the previous episodes of SMBA can be present.</p> <p>2) Detection of EBV-encoded small nuclear RNA (EBER)-positive cells using skin biopsy samples is a standard method, but when biopsy is difficult, EBER can be detected in the crusts and lesional skin tissue by RT-PCR at a research level.</p> <p>3) The standardized value of elevated EBV DNA load in whole blood is $>1 \times 10^4$ IU/mL.</p> <p>4) Flow cytometric analysis reveals that most patients with SMBA have an increased total number of NK cells ($\geq 30\%$ of the total lymphocytes). Flow cytometry–fluorescent in-situ hybridization or immunomagnetic bead-aided quantitative PCR is performed at a research level to confirm EBV infection in the NK cell fraction. Some patients may have an EBV-infected T-cell-dominant type of SMBA.</p> <p>5) Diseases to be excluded: blisters, redness, swelling, and generalized rash related to common insect bite allergy, and pathergy reactions associated with neutrophilic dermatoses including Behçet's disease, Sweet disease, and pyoderma gangrenosum.</p> <p>The overlapping of CAEBV should be considered in line with the diagnostic algorithm if patients have the following symptoms: infectious mononucleosis-like symptoms for >3 months, persistent fever, and organ involvement (see the CAEBV algorithm).</p> <p>SMBA may overlap HV-LPD associated with systemic symptoms, thereby being included in the category of cutaneous CAEBV. The cutaneous form, however, is not the same as CAEBV defined in the present diagnostic criteria.</p> <p>SMBA may progress to extranodal NK/T-cell lymphoma, nasal type (ENKTL-NT) and aggressive NK-cell leukemia.</p> <p>SMBA, severe mosquito bite allergy; EBV, Epstein–Barr virus; LGL, large granular lymphocyte; NK, natural killer; EBER, EBV-encoded small nuclear RNA; RT-PCR, reverse transcription PCR; CAEBV, chronic active Epstein–Barr virus disease; HV-LPD, hydroa vacciniforme lymphoproliferative disorder; NK/T, natural killer cell, or T cell; ENKTL-NT, extranodal NK/T-cell lymphoma, nasal type.</p> | |
| Mild | Definite case of SMBA showing clinical improvement, without extracutaneous organ involvement for over 1 year. |
| Moderate | Recurrent SMBA associated with transient systemic symptoms*, but no persistent extracutaneous organ involvement |
| Severe | Overlapping with HV-LPD Fulfilled diagnostic criteria for CAEBV Complicated with EBV-HLH or progression to EBV-related T/NK lymphoma/leukemia |
| <p>*Systemic symptoms include fever $>37.5^{\circ}\text{C}$, liver damage, and lymphadenopathy, excluding specific organ involvement.</p> <p>The disease severity is classified into the mild (exclusively a stable disease of SMBA), moderate or severe disease by the most severe item.</p> | |
| <p>SMBA, severe mosquito bite allergy; HV-LPD, hydroa vacciniforme lymphoproliferative disorder; EBV, Epstein–Barr virus; CAEBV, chronic active Epstein–Barr virus disease; EBV-HLH, EBV-associated hemophagocytic lymphohistiocytosis; T/NK, T cell, or natural killer cell.</p> | |

図 4 SMBA の診断基準及び重症度分類 (J Dermatol. 2023 Jul;50(7):e198–e205.)