

GUIDELINES

Japanese guidelines for the management of palmoplantar keratoderma

Kozo Yoneda¹  | Akiharu Kubo²  | Toshifumi Nomura³  | Akemi Ishida-Yamamoto⁴  | Yasushi Suga⁵ | Masashi Akiyama⁶  | Nobuo Kanazawa⁷  | Takashi Hashimoto⁸  | Committee on Guidelines for the Management of PPKs

¹Department of Clinical Pharmacology, Faculty of Pharmacy, Osaka Ohtani University, Tondabayashi, Japan

²Department of Dermatology, Keio University Graduate School of Medicine, Tokyo, Japan

³Department of Dermatology, Tsukuba University, Tsukuba, Japan

⁴Department of Dermatology, Asahikawa Medical University, Asahikawa, Japan

⁵Department of Dermatology, Juntendo University Urayasu Hospital, Urayasu, Japan

⁶Department of Dermatology, Nagoya University Graduate School of Medicine, Nagoya, Japan

⁷Department of Dermatology, Hyogo College of Medicine, Nishinomiya, Japan

⁸Department of Dermatology, Osaka City University Graduate School of Medicine, Osaka, Japan

Correspondence

Kozo Yoneda, M.D., Ph.D., Department of Clinical Pharmacology, Faculty of Pharmaceutical Sciences, Osaka Ohtani University, 3-1-1 Nishikiori-kita, Tondabayashi, Osaka 584-8540, Japan. Email: yonedakou@osaka-ohtani.ac.jp

Abstract

Palmoplantar keratoderma (PPK) is a collective term for keratinizing disorders in which the main clinical symptom is hyperkeratosis on the palms and soles. To establish the first Japanese guidelines approved by the Japanese Dermatological Association for the management of PPKs, the Committee for the Management of PPKs was founded as part of the Study Group for Rare Intractable Diseases. These guidelines aim to provide current information for the management of PPKs in Japan. Based on evidence, they summarize the clinical manifestations, pathophysiologies, diagnostic criteria, disease severity determination criteria, treatment, and treatment recommendations. Because of the rarity of PPKs, there are only few clinical studies with a high degree of evidence. Therefore, several parts of these guidelines were established based on the opinions of the committee. To further optimize the guidelines, periodic revision in line with new evidence is necessary.

KEYWORDS

diagnostic algorithm, palmoplantar keratoderma, treatment

1 | POSITION OF GUIDELINES FOR THE MANAGEMENT OF PALMOPLANTAR KERATODERMAS (PPKS)

As part of the Ministry of Health, Labour and Welfare's research project for overcoming intractable skin diseases, a committee was founded to establish guidelines for the treatment of palmoplantar

keratoderma (PPK).¹ PPKs are primarily genetic diseases whose main clinical symptom is hyperkeratosis on the palms and soles. PPKs are sometimes associated with carcinoma or abnormalities of other organs. These diseases are fatal, when complications, such as skin cancer, esophageal cancer, dilated cardiomyopathy, right ventricular hypoplasia, limb osteolysis, and eosinophilic esophagitis become serious. In addition, if sensorineural hearing loss or intellectual disability occurs, the quality of life (QOL) will be significantly reduced. This group of diseases, which manifest with other organ abnormalities in addition to PPKs, should be called

This is the secondary English version of the original Japanese manuscript for Palmoplantar Keratoderma (PPK) Treatment Guide, published in the Japanese Journal of Dermatology. 130; 2017-2029, 2020¹

Hereditary and nonsyndromic PPK diagnostic algorithm

Transgrediens: The lesion spreads beyond the palmoplantar region to the dorsum of the toes, wrists, ankles, and up to the Achilles tendons.

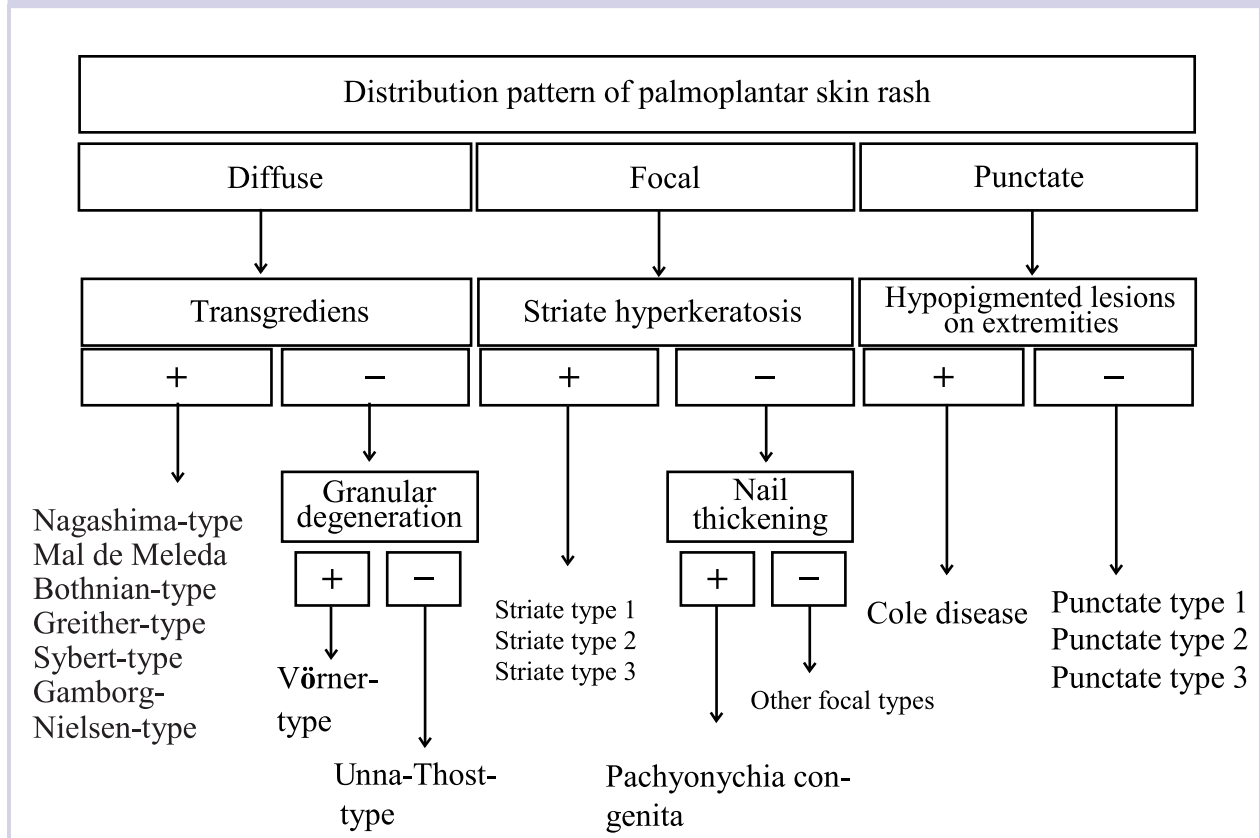


FIGURE 1 Hereditary and nonsyndromic palmoplantar keratoderma (PPK) diagnostic algorithm. Transgrediens: The lesion spreads beyond the palmoplantar region to the dorsum of the toes, wrists, ankles, and up to the Achilles tendons.

syndromic PPK. The present guidelines (Japanese guidelines for the management of PPK) cover isolated PPKs in which the lesions are mainly localized to the skin and several diseases belonging to syndromic PPKs.

We used the criteria proposed by the Ministry of Health, Labour, and Welfare Study Group for the diagnosis of the disease (name/type) and determination of the disease severity. Moreover, to answer questions and guide decisions that are likely to occur in routine clinical practice, we have provided graded recommendations determined via evidence-based medicine (EBM).

Ultimately, we believe that we have successfully created a PPK treatment guide for clinicians based on the most recent, up-to-date findings. However, because PPKs are rare intractable diseases, very few clinical studies with a high evidence level exist. Thus, in many instances, we had to rely on the members' opinions of Committee on Guidelines for the Management of PPKs to develop this treatment guide. This treatment guide presents the current, standard clinical practices for PPKs in Japan. Nevertheless, in clinical care, diagnosis and treatment need to be performed while keeping in mind the diverse backgrounds of individual patients. Therefore,

these guidelines do not aim to restrict treatment choices for PPKs. In clinical settings, the judgment of individual doctors should be given priority. These guidelines will be updated as necessary, following the progress in PPK diagnosis, treatment, and the medical demands of the time.

2 | OVERVIEW OF PPKS

2.1 | Definitions/characteristics

Keratinization disorders can be broadly divided into hereditary and non-hereditary types. PPKs are hereditary diseases that cause extensive hyperkeratosis of the palms and soles. Traditionally, they have been classified by their clinical features, pathological findings, and inheritance patterns. Causative genes have now been identified for the vast majority of PPKs. It is sometimes challenging to determine the disease type by examining clinical and histopathological findings alone; a detailed examination of patients' genetic history is often required. Ultimately, it is

TABLE 1 Palmoplantar keratoderma (PPK) showing diffuse hyperkeratosis

	Inheritance pattern	Causative gene	Pathological findings	Trans-grediens	Hyperhidrosis	Whitish change upon water exposure	Involvement of non-palmoplantar skin	Mutilation
Vörner-type (Unna-Thost-type)	Autosomal dominant	KRT1, KRT9	Granular degeneration (+) Unna-Thost-type does not show granular degeneration	No	No	No	No	No
Diffuse PPK caused by <i>DSG1</i> mutations	Autosomal dominant	<i>DSG1</i>	Granular degeneration (-)	No	Not described	Not described	Onycholysis, yellow nail.	No
Nagashima-type	Autosomal recessive	<i>SERPINB7</i>	Granular degeneration (-)	Yes	Yes	Yes	Hyperkeratotic lesions of knees, elbows, and Achilles tendons.	No
Bothnian-type	Autosomal dominant	<i>AQP5</i>	Granular degeneration (-)	Yes	Yes	Yes	No	No
Greither-type	Autosomal dominant	<i>KRT1</i>	Granular degeneration (-)	Yes	Yes	No	Hyperkeratotic lesions of knees, elbows, Achilles tendons, and skin flexures.	Yes
Sybert-type	Autosomal dominant	Unknown	Granular degeneration (-)	Yes	Not described	No	Hyperkeratotic lesions of knee, elbow, dorsum of forearm, and the lower extremities.	Yes
Mal de Meleda	Autosomal recessive	<i>SLURP1</i>	Granular degeneration (-)	Yes	Yes	No	Hyperkeratotic lesions of the knee and elbow skin and erythema of the mouth and eye circumference.	Yes
Gamborg-Nielsen-type	Autosomal recessive	<i>SLURP1</i>	Granular degeneration (-)	Yes	Not described	Yes	Knuckle pads on dorsal sides of fingers.	Yes

often necessary to identify the genetic mutation(s) present for the diagnosis (Figure 1; Tables 1, 2, and 3).²⁻⁴ There is still no fundamental treatment for PPKs, and symptomatic treatment remains the mainstay of most protocols.

The clinical features and histopathological findings of the major disease types are briefly described below (also see Tables 1, 2, and 3).

2.2 | Vörner-type PPK (including Unna-Thost-type)⁵⁻⁷

2.2.1 | Overview

Vörner-type PPK is caused by mutations in *KRT1* or *KRT9*, showing an autosomal dominant inheritance pattern. Diffuse hyperkeratosis is confined to the palms and soles. Granular degeneration is seen from the spinous layer to granular layer in hematoxylin and eosin (HE)-stained pathological samples. It cannot be distinguished from the Unna-Thost-type PPK based on clinical symptoms alone. Presently, Unna-Thost-type PPK is considered to be the same disease as Vörner-type PPK; the disease is diagnosed as Vörner-type PPK when there is granular degeneration in pathological findings and as Unna-Thost-type PPK when there is no granular degeneration.

2.2.2 | Symptoms

Symptoms appear from birth. These include hyperkeratosis with erythema of the palms and soles. In some cases, skin erythema is noticeable around hyperkeratotic lesions. Contraction of the fingers and toes, nail plate changes, and excessive sweating on the palmoplantar region may be present. These may be combined with tinea pedis. There are also cases of offensive odor.

2.2.3 | Pathological findings

Hyperkeratosis with or without parakeratosis may be observed. Granular degeneration is typically seen from the stratum spinosum to stratum granulosum, but it may not be apparent depending on the biopsy site. The hyperproliferation of sweat gland tissue may also be seen.

2.3 | Nagashima-type PPK⁸⁻¹¹

2.3.1 | Overview

This type exhibits an autosomal recessive inheritance. It was established as an independent disease concept by Nagashima

TABLE 2 Focal • Pachyonychia congenita • Striate • Punctate palmoplantar keratoderma (PPK)

		Inheritance pattern	Causative gene	Clinical features
Focal		Autosomal dominant	<i>KRT6C</i> , <i>KRT16</i> , <i>DSG1</i> , <i>TRPV3</i>	Focal skin hyperkeratosis of palms and soles. These hyperkeratotic lesions are accompanied by pain and triggered by mechanical stimulation.
Pachyonychia congenita		Autosomal dominant	<i>KRT6A</i> , <i>KRT6B</i> <i>KRT6C</i> , <i>KRT16</i> , <i>KRT17</i>	Thickening of the nail plate, blisters of the plantar region, steatocystoma, and oral leukokeratosis.
Striate	Striate PPK type 1	Autosomal dominant	<i>DSG1</i>	Striate hyperkeratotic lesions on the flexion side of the fingers. Hyperkeratotic lesions on the weight-bearing portions of the footpad.
	Striate PPK type 2	Autosomal dominant	<i>DSP</i>	
	Striate PPK type 3	Autosomal dominant	<i>KRT1</i>	
Punctate	Punctate PPK type 1A (Buschke-Fischer-Brauer type)	Autosomal dominant	<i>AAGAB</i>	Numerous tiny punctate keratotic papules appear on the palmoplantar region from childhood to adolescence. The numbers of these tiny hyperkeratotic papules increase gradually and they become larger hyperkeratotic lesions by the fusion of several these papules. Tiny punctate keratotic lesions appear when patients are in their puberty. Histopathologically, the coronoid lamella-like column of parakeratotic cells is characteristic.
	Punctate PPK type 1B	Autosomal dominant	<i>COL14A1</i>	
	Punctate PPK type 2 (Porokeratosis type, spiny keratoderma)	Autosomal dominant	Unknown	
	Punctate PPK type 3 (Acrokeratoelastoidosis)	Autosomal dominant	Unknown	

TABLE 3 Syndromic palmoplantar keratoderma (PPK)

Features	Disease name	Inheritance pattern	Causative gene	Clinicopathological features
PPK with deafness	Vohwinkel syndrome	Autosomal dominant	<i>GJB2</i>	Mutilating, honeycomb-like keratinization of the palmoplantar region, constriction ring, starfish-shaped keratoses.
	PPK with hearing loss	Autosomal dominant	<i>GJB2</i>	Diffuse or focal PPK.
	KID (keratitis-ichthyosis-deafness) syndrome	Autosomal dominant	<i>GJB2</i>	Keratitis with angiogenesis, ichthyosiform erythroderma, squamous cell carcinoma.
	Ichthyosis hystrix with deafness	Autosomal dominant	<i>GJB2</i>	Verrucous or spinous hyperkeratosis.
	Bart-Pumphrey syndrome	Autosomal dominant	<i>GJB2</i>	Leukonychia, nodules of fingers.
	Mitochondrial PPK with deafness	Maternal inheritance	Mitochondrial genome (m.7445A>G)	Granular degeneration (-).
Mutilating PPK with ichthyosis	Vohwinkel syndrome with ichthyosis (loricrin keratoderma)	Autosomal dominant	<i>LOR</i>	Ichthyosis, mutilating, honeycomb-like keratinization of the palmoplantar region, constriction ring.
Keratosis linearis with ichthyosis and sclerosing keratoderma	KLICK syndrome	Autosomal recessive	<i>POMP</i>	Constriction rings of fingers, diffuse PPK, transgrediens (+).
PPK with periodontitis	Papillon-Lefèvre syndrome	Autosomal recessive	<i>CTSC</i>	Periodontitis, increased susceptibility to infections, hyperkeratosis with redness of the distal portion of the extremities including the palmoplantar region, diffuse PPK, transgrediens (+).
	Haim-Munk syndrome	Autosomal recessive	<i>CTSC</i>	Severe periodontitis, arachnodactyly, acroosteolysis, diffuse PPK, transgrediens (+).
PPK with cardiomyopathy and woolly hair	Carvajal syndrome	Autosomal recessive	<i>DSP</i>	Dilated cardiomyopathy, striate PPK.
	Naxos disease	Autosomal recessive	<i>JUP</i>	Dilated cardiomyopathy, striate PPK.
	PPK with arrhythmogenic right ventricular cardiomyopathy	Autosomal dominant, Autosomal recessive	<i>DSC2</i>	Right ventricular myocardial degeneration, mild striate PPK.
PPK with ectodermal dysplasia	Clouston syndrome	Autosomal dominant	<i>GJB6</i>	Diffuse PPK, nail dystrophy, hair abnormalities.
	Naegeli-Franceschetti-Jadassohn syndrome	Autosomal dominant	<i>KRT14</i>	Diffuse PPK, nail dystrophy, anhidrosis, dental defects, reticular hyperpigmentation.
	Odontoonychodermal dysplasia	Autosomal recessive	<i>WNT10A</i>	Diffuse PPK, hyperhidrosis, hypodontia, smooth tongue, hypotrichosis, nail dystrophy.
	Schöpf-Schultz-Passarge syndrome	Autosomal recessive	<i>WNT10A</i>	In addition to the above symptoms of odontoonychodermal dysplasia, cystic eyelids and skin cancer exist.
	Skin fragility syndrome	Autosomal recessive	<i>PKP1</i>	Systemic skin fragility, diffuse PPK with painful fissures, hypotrichosis or woolly hair, growth retardation.
PPK with a predisposition to carcinogenicity	Howel-Evans (Tylosis with esophageal cancer)	Autosomal dominant	<i>RHBDF2</i>	Focal PPK, esophageal cancer, leukoplakia.
	Huriez syndrome	Autosomal dominant	<i>SMARCAD1</i>	Diffuse PPK, transgrediens (+), scleroatrophy of distal extremities, squamous cell carcinoma.

(Continues)

TABLE 3 (Continued)

Features	Disease name	Inheritance pattern	Causative gene	Clinicopathological features
	Cowden disease (Cowden syndrome type 1)	Autosomal dominant	<i>PTEN</i>	Punctate PPK, intraoral mucosal papillomatosis, facial trichilemmoma, benign hamartomatous lesion in the gastrointestinal tract, mammary gland, thyroid gland, central nerve, urogenital organs, etc., liver cancer, breast cancer, thyroid cancer, uterine cancer.
	Olmsted Syndrome	Autosomal dominant	<i>TRPV3, MBTPS2</i>	Mutilating PPK, transgrediens (+), periorificial hyperkeratotic plaques with pruritus, skin cancer.

and Mitsuhashi and is caused by mutations in *SERPINB7*.⁸⁻¹⁰ This is the most common form of PPK in Asians, and there are an estimated ten thousand patients in Japan alone.³ PPK which exhibits milder hyperkeratosis than Mal de Meleda and an appearance of autosomal dominant inheritance pattern has been called as “autosomal dominant Mal de Meleda-like PPK” in Japan. Mizuno et al. revealed *SERPINB7* mutation in 1 family of “autosomal dominant Mal de Meleda-like PPK”.¹¹ Thus, “autosomal dominant Mal de Meleda-like PPK” is now considered to be Nagashima-type PPK. It is highly likely that most of the cases reported as “autosomal dominant Mal de Meleda-like PPK” in the Japanese literature are pseudodominant Nagashima-type PPK.

2.3.2 | Symptoms

Shortly after birth, until about 1 to 2 years of age, skin erythema and mild hyperkeratosis of the palms and soles often appear. Erythema and hyperkeratosis often show transgrediens extending to the dorsal regions of the fingers, toes, hands, and feet, inside of the wrist, and the Achilles tendons. They may also show progrediens with non-continuous erythema and hyperkeratosis of the elbows and knees. Constriction rings do not form on the fingers or feet. There is often excessive sweating on the palmoplantar region, often accompanied by a foul odor. There are many cases of recurrent tinea pedis. The worsening of scaling or development of pruritus suggest a complication of tinea pedis. Unlike in Mal de Meleda, the extent of symptoms does not increase after adulthood, but hyperkeratosis progresses mildly with aging. One characteristic feature is the maceration of affected areas to a white color after a short immersion in water.

2.3.3 | Pathological findings

Hyperkeratosis and epidermal thickening are observed without granular degeneration. There is mild parakeratosis limited to the lowermost layer of the stratum corneum (immediately above the granular layer).

2.4 | Bothnian-type PPK^{12,13}

2.4.1 | Overview

This disease shows an autosomal dominant inheritance. It occurs due to mutations in *AQP5*.

2.4.2 | Symptoms

From early childhood, hyperkeratotic lesions with erythema appear in the palmoplantar region. Diffuse cornification is observed. This hyperkeratosis spreads to dorsal regions of the fingers, toes, hands, and feet. There is hyperhidrosis on the palmoplantar region. After a short period of water exposure, the palmoplantar region is macerated, and the skin becomes white and spongy. Fungal infections are common.

2.4.3 | Pathological findings

Hyperkeratosis and acanthosis are observed. There is no granular degeneration. The sweat ducts in the stratum corneum dilate. The eccrine sweat glands change as they do in miliaria rubra, and lymphocytes infiltrate around the sweat glands.

2.5 | Greither-type PPK^{14,15}

2.5.1 | Overview

This disease occurs due to mutations in *KRT1* and shows autosomal dominant inheritance.

2.5.2 | Symptoms

Diffuse hyperkeratotic lesions with erythema appear on the palmoplantar region from an early age. The diffuse hyperkeratosis extends to the dorsal regions of the fingers and hands, and the back of the toes and

feet (transgrediens). Hyperkeratotic lesions may appear on the axilla discontinuously. Hyperhidrosis on the palmoplantar region is seen.

2.5.3 | Pathological findings

Hyperkeratosis and acanthosis are observed. Granular degeneration is not typically observed.

2.6 | Mal de Meleda^{16,17}

2.6.1 | Overview

This disease is caused by biallelic mutations in *SLURP1*. A founder effect has led to many patients on the Island of Mljet in the Adriatic Sea. The Croatian name "Mljet" is "Meleda" in Italian. This disease has been reported throughout the world.

2.6.2 | Symptoms

Shortly after birth, hyperkeratotic lesions with erythema appear on the palms and soles. Over time, hyperkeratotic lesions extend not only to the palms and soles but also to the back of the hands and feet. Hyperkeratotic lesions extend to the elbows and knees. When the degree of keratinization is high, the lesions become yellowish. Diffuse hyperkeratosis is usually observed. There is a clear boundary between the hyperkeratotic lesions and healthy areas.

2.6.3 | Pathological findings

Hyperkeratosis and acanthosis are seen. There are cases with or without parakeratosis. There are many cases with the proliferation of sweat gland tissue.

2.7 | Striate or focal PPK¹⁸⁻²⁵

2.7.1 | Overview

This disease shows an autosomal dominant inheritance. It occurs due to mutations in *DSG1*, *DSP*, *KRT1*, *KRT6C*, *KRT16*, or *TRPV3*. Striate, zonal, or focal (circular) hyperkeratosis is seen on the palmoplantar region. Striate PPK is classified into type 1, type 2, and type 3, depending on the causative gene (Table 2).

2.7.2 | Symptoms

Erythema is seen on the palms and soles. Striate, zonal, or circular keratotic lesions appear at the center of irritated and

weight-bearing sites. Symptoms often continue to progress until adulthood. While one patient from a given family may present mainly with striate hyperkeratotic lesions, another may present mainly with circular hyperkeratotic lesions. Even in the same patient, hyperkeratotic lesions on the palms and soles may have different morphologies.

2.7.3 | Pathological findings

Hyperkeratosis with or without parakeratosis is observed. In striate PPK type 1 and type 2, dilation of the intercellular space is observed.

2.8 | Pachyonychia congenita²⁶⁻³⁰

2.8.1 | Overview

This disease is caused by heterozygous mutations in *KRT6A*, *KRT6B*, *KRT6C*, *KRT16*, or *KRT17*. Two subtypes exist. In the Jadassohn-Lewandowsky type (pachyonychia congenita-1), thickening of the nail plate, focal hyperkeratotic lesions on the palms and soles, keratosis follicularis, and leukoplakia on the oral mucosa are observed. In the Jackson-Lawler type (pachyonychia congenita-2), neonatal teeth, steatocystoma multiplex, and focal hyperkeratotic lesions on the palms and soles are seen. The Jadassohn-Lewandowsky type is caused by mutations in *KRT6A* or *KRT16*, while mutations in *KRT6A*, *KRT6B*, *KRT16* or *KRT17* cause the Jackson-Lawler-type PPK.

2.8.2 | Symptoms

Shortly after birth or 1 to 2 years after birth at the latest, erythema becomes visible on the nail bed and palmoplantar region. After that, focal hyperkeratotic lesions appear on irritated and weight-bearing palmoplantar areas. Keratinized plantar lesions are painful, and there is a significant thickening of the nail plates.

2.8.3 | Pathological findings

Hyperkeratosis with or without parakeratosis is observed.

2.9 | Cole disease^{31,32}

2.9.1 | Overview

This disease shows an autosomal dominant inheritance. It occurs due to mutations in *ENPP1*. Punctate hyperkeratotic lesions occur in the palms and soles. Hypopigmented lesions are found on the extremities.

2.9.2 | Symptoms

Punctate hyperkeratotic papules and hypopigmented lesions appear from childhood. Hypopigmented lesions vary in shape. This disease usually affects the extremities. In hypopigmented lesions, the density of melanocytes is normal, and the number of melanosomes in melanocytes is also normal. However, in the depigmented patch, melanin granules in keratinocytes are decreased, and the transport of melanin is considered to be impaired.

2.9.3 | Pathological findings

Hyperkeratosis is observed. It is not accompanied by parakeratosis. There are acanthosis and thickened granular layer.

2.10 | Punctate PPK³³⁻³⁹

2.10.1 | Overview

This disease shows an autosomal dominant inheritance. The punctate 1A type is due to mutations in *AAGAB*, whereas the punctate 1B type is caused by mutations in *COL14A1*. Punctate hyperkeratotic lesions occur on the palmoplantar region. It may appear as a symptom of Cowden disease (Cowden syndrome type 1).

2.10.2 | Symptoms

Symptoms most often occur after adolescence. Translucent punctate hyperkeratotic papules occur on the palms and soles. The keratinized papules gradually grow and increase in diameter. They may become clavus-like or callus-like, and the patients may complain of pain. This condition must therefore be differentiated from clavus, callus, and viral warts.

2.10.3 | Pathological findings

Hyperkeratosis is observed. The stratum corneum in the central part of the lesion is markedly thickened so that the epidermis is extruded downward and looks like a cup. There are cases with or without parakeratosis. Acanthosis and granular layer thickening vary from case to case.

2.11 | Mutilating PPK (Vohwinkel)⁴⁰⁻⁴²

2.11.1 | Overview

This disease shows an autosomal dominant inheritance. This disease is caused by mutations in *LOR* or *GJB2*.

2.11.2 | Symptoms

Hyperkeratotic lesions appear from infancy. The hyperkeratotic lesions on the palms and soles are the honeycomb type with fine granular surfaces. A constriction ring is formed around the joints of the fingers and toes, and the tips of toes fall off as it progresses. Cases with ichthyosis over the entire body due to *LOR* gene mutations are diagnosed as lorincrin keratoderma (Table 3). When mutations are in *GJB2*, hyperkeratotic lesions on the fingers and dorsa of the toes, hands, and feet may manifest as irregular starfish-shaped hyperkeratosis. This type is accompanied by sensorineural deafness.

2.11.3 | Pathological findings

Significant hyperkeratosis and parakeratosis are seen. Inflammatory cell infiltration is present in the upper dermis.

2.12 | Papillon-Lefèvre syndrome⁴³

2.12.1 | Overview

This disease shows an autosomal dominant inheritance. This disease is caused by mutations in *CTSC*. The three major signs are erythema and hyperkeratosis on the distal extremities, periodontal disease, and infection susceptibility.

2.12.2 | Symptoms

Erythema appears on the palms and soles during infancy. Erythema extends to the dorsa of the hands and feet. Furthermore, this erythema extends beyond the Achilles tendons to the lower legs. Hyperkeratotic lesions are psoriasis-like.

2.12.3 | Pathological findings

Hyperkeratosis accompanied by parakeratosis is observed. Vasodilation of the upper dermis and perivascular lymphocyte infiltration are seen.

2.13 | Epidemiology

The frequency of Nagashima-type PPK in Japan and China is estimated to be 1.2 and 3.1 per 10,000 persons, respectively.² The frequency of Bothnian-type PPK in the north of Sweden (in the coastal region of the Gulf of Bothnia) is reported to be 0.30–0.55% (30–55 per 100,000 persons) in the general population.² We conducted a national epidemiological survey on PPK by sending questionnaires to dermatologists and pediatricians at the hospitals which have more

than 500 beds. They were sent by late June, and the responses were received by fax by late July. For families of the known type, we asked them to enter the number of family members with each disease type. We also provided a “free description” field and asked for comments and requests regarding the questionnaire survey. Questionnaires were sent to dermatologists and pediatricians at 690 facilities nationwide. Responses were received from 325 facilities. There were 113 pedigrees and 147 patients (1.2 per population of 1 million) with known PPKs types. About 90% of PPKs had been diagnosed at University Hospitals. Regarding the number of patients per population of 1 million, Aomori Prefecture had the largest number, with 30.6 per 1 million people.

2.14 | Treatment

The frequency of PPK cases is low; therefore, large-scale clinical trials are not possible. Consequently, treatment methods with a high level of evidence have not been established. Currently, the treatments which are usually done in routine clinical works depend on ones reported in case reports.

2.14.1 | Topical treatment

A keratolytic agent such as salicylate vaseline, urea ointment, or an ointment containing calcipotriol is applied.

2.14.2 | Dermabrasion

Cone cutters, long razors, biopsy punches, ophthalmic scissors, and others, are used to remove the thickened cornified layer.

2.14.3 | Oral therapy

Oral retinoids are administered. However, since this drug is teratogenic, it must not be given to pregnant women or those who may be pregnant. It is also contraindicated in patients with a history of hypersensitivity to etretinate, liver damage, renal damage, receiving vitamin A preparations, and hypervitaminosis A. Each time etretinate is prescribed, written informed consent should be obtained.

2.14.4 | Treatment for complications

For complications such as constriction rings and skin cancer, caution is required for early detection and surgical intervention. For complications such as hearing loss, esophageal cancer, periodontal disease, cardiomyopathy, and others, a specialist must be consulted for medical treatment. For fungal and bacterial infections, appropriate antifungal agents and antibiotics should be administered.

2.14.5 | Patient self-care

If fissures develop and cause pain, the stratum corneum is scraped off using a long razor, and ODT is performed using vaseline at bedtime, which aids in preventing fissures on the palmoplantar region and alleviating pain.

2.15 | Prognosis

Due to the small number of cases, there is little evidence of the effects of treatment. For mild cases, keratolytic agents such as salicylate vaseline and urea ointment or ointment containing active forms of vitamin D3 are applied, and for severe cases, retinoids are administered orally; however, the course is often chronic.

REFERENCES

1. Yoneda K, Kubo A, Nomura T, et al. Palmoplantar Keratoderma (PPK) Treatment Guide. *Jpn J Dermatol*. 2020;130:2017–29. (in Japanese).
2. Sakiyama T, Kubo A. Hereditary palmoplantar keratoderma “clinical and genetic differential diagnosis”. *J Dermatol*. 2016;43:264–74.
3. Kubo A. Hereditary palmoplantar keratodermas. In *UpToDate*(Wolters Kluwer, MA, USA), 2019 <https://www.uptodate.com/contents/hereditary-palmoplantar-keratodermas>.
4. Nomura T. (hereditary and asymptomatic) Palmoplantar keratoderma. In: Hide M, Aoyama Y, Kato N, (Eds.), *Power-up of the diagnosis of skin disease learning from experts*. Tokyo: Nakayama Shoten, 2018; 305–9 (in Japanese).
5. Vörner H. Zur Kenntniss des Keratoma hereditarium palmare et plantare. *Arch Derm Syph*. 1901;56:3–31.
6. Thost A. Ueber erbliche Ichthyosis palmaris et plantaris cornea, *Dissertation*, 1880; Heidelberg (pub).
7. Unna PG. Ueber das Keratoma palmare et plantare hereditarium. *Vierteljahresschr Derm Syph*. 1883;15:231–70.
8. Nagashima M. Palmoplantar keratoderma. In: Miura O, Ochiai K (Eds.), *Handbook of Human Genetics*, Volume 9, Tokyo: Igaku Shoin, 1977;23–7.
9. Mitsuhashi Y, Hashimoto I. Keratosis palmoplantaris Nagashima. *Dermatologica*. 1989;179:231.
10. Kubo A, Shiohama A, Sasaki T, Nakabayashi K, Kawasaki H, Atsugi T, et al. Mutations in SERPINB7, encoding a member of the serine protease inhibitor superfamily, cause Nagashima-type palmoplantar keratosis. *Am J Hum Genet*. 2013;93:945–56.
11. Mizuno O, Nomura T, Suzuki S, et al. Highly prevalent SERPINB7 founder mutation causes pseudodominant inheritance pattern in Nagashima-type palmoplantar keratosis. *Br J Dermatol*. 2014;171:847–53.
12. Lind L, Lundström A, Hofer PA, Holmgren G. The gene for diffuse palmoplantar keratoderma of the type found in northern Sweden is localized to chromosome 12q11-q13. *Hum Mol Genet*. 1994;3:1789–93.
13. Blaydon DC, Lind LK, Plagnol V, Linton KJ, Smith FJD, Wilson NJ, et al. Mutations in AQP5, encoding a water-channel protein, cause autosomal-dominant diffuse nonepidermolytic palmoplantar keratoderma. *Am J Hum Genet*. 2013;93:330–5.
14. Greither A. Keratosis extremitatum hereditaria progrediens mit dominantem Erbgang. *Hautarzt*. 1952;3:198–203.
15. Gach JE, Munro CS, Lane EB, Wilson NJ, Moss C. Two families with Greither's syndrome caused by a keratin 1 mutation. *J Am Acad Dermatol*. 2005;53:S225–S230.

16. Hovorka O, Ehlers E. Mal de Meleda. *Arch Dermatol Res.* 1897;40:251–6.
17. Fisher J, Bouadjar B, Hellig R, et al. Mutations in the gene encoding SLURP-1 in Mal de Meleda. *Hum Mol Genet.* 2001;10:875–80.
18. Milingou M, Wood P, Masouye I, McLean W, Borradori L. Focal palmoplantar keratoderma caused by an autosomal dominant inherited mutation in the desmoglein 1 gene. *Dermatology.* 2006;212:117–22.
19. Armstrong DK, McKenna KE, Purkis PE, et al. Haploinsufficiency of desmoplakin causes a striate subtype of palmoplantar keratoderma. *Hum Mol Genet.* 1999;8:143–8.
20. Whittock NV, Smith FJ, Wan H, Wan H, Mallipeddi R, Griffiths W, et al. Frameshift mutation in the V2 domain of human keratin 1 results in striate palmoplantar keratoderma. *J Invest Dermatol.* 2002;118:838–44.
21. Wilson NJ, Messenger AG, Leachman SA, O'Toole EA, Lane EB, Irwin McLean W, et al. Keratin K6c mutations cause focal palmoplantar keratoderma. *J Invest Dermatol.* 2010;130:425–9.
22. Shamsheer MK, Navsaria HA, Steven HP, Ratnavel RC, Purkis PE, Keisell DP, et al. Novel mutations in keratin 16 gene underly focal non-epidermolytic palmoplantar keratoderma (NEPPK) in two families. *Hum Mol Genet.* 1995;4:1875–81.
23. Smith FJ, Fisher MP, Healy E, Rees JL, Bonifas JM, Epstein Jr EH, et al. Novel keratin 16 mutations and protein expression studies in pachyonychia congenita type 1 and focal palmoplantar keratoderma. *Exp Dermatol.* 2000;9:170–7.
24. Rickman L, Simrak D, Stevens HP, et al. N-terminal deletion in a desmosomal cadherin causes the autosomal dominant skin disease striate palmoplantar keratoderma. *Hum Mol Genet.* 1999;8:971–6.
25. He Y, Zeng K, Zhang X, et al. A gain-of-function mutation in TRPV3 causes focal palmoplantar keratoderma in a Chinese family. *J Invest Dermatol.* 2010;130:425–9.
26. Bowden PE, Haley JL, Kansky A, Rothnagel JA, Jones DO, Turner RJ. Mutation of a type II keratin gene (K6a) in pachyonychia congenita. *Nat Genet.* 1995;10:363–5.
27. Smith FJ, Jonkman MF, van Goor H, Coleman CM, Covello SP, Uitto J, et al. A mutation in human keratin K6b produces a phenocopy of the K17 disorder pachyonychia congenita type 2. *Hum Mol Genet.* 1998;7:1143–8.
28. McLean WH, Rugg EL, Lunny DP, Morley SM, Lane EB, Swensson O, et al. Keratin 16 and keratin 17 mutations cause pachyonychia congenita. *Nat Genet.* 1995;9:273–8.
29. McLean WH, Hansen CD, Eliason MJ, Smith FJD. The phenotypic and molecular genetic features of pachyonychia congenita. *J Invest Dermatol.* 2011;131:1015–7.
30. Sybert VP. Pachyonychia congenita. In: *Genetic skin disorders.* New York: Oxford University Press, 2017;143–6.
31. Cole LA. Hypopigmentation with punctate keratosis of the palms and soles. *Arch Dermatol.* 1976;112:998–1000.
32. Eytan O, Morice-Picard F, Sarig O, Ezzedine K, Isakov O, Li Q, et al. Cole disease results from mutations in ENPP1. *Am J Hum Genet.* 2013;93:752–7.
33. Buschke A, Fischer W. Keratoderma mauculosa disseminate symmetrica palmaris and plantaris. *Ikongraphia Dermatol.* 1910;51:183–92.
34. Brauer A. Über eine besondere Form des hereditären Keratoms (keratoderma disseminatum hereditarium palmare et plantare). *Arch Dermatol Syph.* 1913;114:211–36.
35. Brown FC. Punctate keratoderma. *Arch Dermatol.* 1971;104:682–3.
36. Costa O. Akrokerato-elastoidosis (a hitherto underscribed skin disease). *Dermatologica.* 1953;107:164–8.
37. Giehl KA, Eckstein GN, Pasternack SM, Praetzel-Wunder S, Ruzicka T, Lichtner P, et al. Nonsense mutations in AAGAB cause punctate palmoplantar keratoderma type Buschke-Fischer-Brauer. *Am J Hum Genet.* 2012;91:754–9.
38. Pohler E, Mamai O, Hirst J, Zamiri M, Horn H, Nomura T, et al. Haploinsufficiency for AAGAB causes clinically heterogeneous forms of punctate palmoplantar keratoderma. *Nat Genet.* 2012;44:1272–6.
39. Guo BR, Zhang X, Chen G, et al. Exome sequencing identifies a COL14A1 mutation in a large Chinese pedigree with punctate palmoplantar keratoderma. *J Med Genet.* 2012;49:563–8.
40. Maestrini E, Monaco AP, McGrath JA, Ishida-Yamamoto A, Camisa C, Hovnanian A, et al. A molecular defect in lorincrin, the major component of the cornified cell envelope, underlies Vohwinkel's syndrome. *Nat Genet.* 1996;13:70–7.
41. Ishida-Yamamoto A, McGrath JA, Lam H, Iizuka H, Friedman RA, Christiano AM. The molecular pathology of progressive symmetric erythrokeratoderma: a frameshift mutation in the lorincrin gene and perturbations in the cornified cell envelope. *Am J Hum Genet.* 1997;61:581–9.
42. Maestrini E, Korge BP, Ocana-Sierra J, et al. A missense mutation in connexin 26, D66H, causes mutilating keratoderma with sensorineural deafness (Vohwinkel's syndrome) in three unrelated families. *Hum Mol Genet.* 1999;8:1237–43.
43. Hart TC, Hart PS, Bowden DW, et al. Mutations of the cathepsin C gene are responsible for Papillon-Lefèvre syndrome. *J Med Genet.* 1999;36:881–7.

3 | DIAGNOSTIC AND SEVERITY CRITERIA

3.1 | Diagnostic criteria for PPK

3.1.1 | Main points

(1) Clinical matters

(a) Hyperkeratotic lesions on the palms and/or soles.

There are cases which exhibit diffuse or focal hyperkeratosis.

Clavus, callus, and viral warts are excluded.

(b) In general, onset occurs in early childhood, and the symptoms persist for a long time.

(2) Pathological matters

Histopathological findings are usually hyperkeratosis and acanthosis. These may or may not be accompanied by parakeratosis or granular degeneration.

3.1.2 | Judgment

If (1) (a) (b) and (2) are all satisfied, the disease is diagnosed as PPK.

3.2 | Diagnosis of disease type

3.2.1 | Prediction of disease type

According to the distribution pattern of eruptions, it is classified into three types: (1) diffuse, (2) focal, and (3) punctate (Figure. PPK diagnostic algorithm).

1. Diffuse cases

If the eruption is localized on the palmoplantar region, consider Vörner-type, Unna-Thost-type, or diffuse PPK caused by *DSG1* mutations. If the lesion shows transgrediens*, consider Nagashima-type, Mal de Meleda, Gamborg-Nielsen-type, Greither-type, Sybert-type, or Bothnian-type PPK.

*Transgrediens: The lesion spreads beyond the palmoplantar region to the dorsum of the toes, wrists, ankles, and up to the Achilles tendons.

†Nagashima-type PPK is a very common PPK in Japan.

2. Focal cases

Consider striate PPK, pachyonychia congenita, and other focal PPKs. When linear hyperkeratosis is observed on the flexion side of the fingers, consider striate PPK. Consider pachyonychia congenita if accompanied by thickening of the nail plate, blisters, and intense pain on the plantar region, edema, and oral keratinizing lesions. If neither striate PPK nor pachyonychia congenita is applicable, diagnose as other focal PPKs. The skin lesion may also be circular.

3. Punctate cases

Consider punctate PPK types 1A, 1B, type 2, and type 3 and Cole disease. Cole disease is accompanied by depigmentation of the extremities.

3.3 | Definite diagnosis and others

3.3.1 | Interview

Accurately record the age at onset and family history in medical records. Most PPKs are monogenic diseases; therefore, the disease has a characteristic mode of transmission within the family. Construct the family tree if possible.

3.3.2 | Skin histopathology

3.3.3 | Genetic testing

Under the Institutional Ethics Committee's approval, the procedure must be performed with the written consent of the patient (or guardian of the minor).

3.3.4 | Genetic counseling

We recommend that patients and their families undergo genetic counseling when they are diagnosed as having hereditary PPK. If the

patient and family agree, refer the patient to a doctor and genetic counselor specializing in clinical genetics.

3.4 | Severity criteria

Severity is calculated based on the score calculation table in the Appendix. It is classified into mild, moderate, and severe (3 grades).

4 | CLINICAL QUESTIONS (CQ)

CQ list

CQ1: Are oral retinoids useful?

CQ2: Is the topical use of active vitamin D3 ointment useful?

CQ3: Is topical salicylate vaseline useful?

CQ4: Is topical urea ointment useful?

CQ5: Is the topical application of adapalene ointment useful?

CQ6: Is dermabrasion useful?

CQ7: Is nucleic acid drug small interfering RNA (siRNA) treatment useful?

CQ8: Is treatment with readthrough drugs useful?

CQ9: Is genetic counseling useful?

4.1 | Oral retinoids

CQ1: Are oral retinoids useful?

Statement on recommendation: Oral retinoids are useful for treating PPK.

Consent level: 4.73

Recommendation level: B

Commentary: There are case reports and case series studies that have described oral retinoids as useful in PPK patients.⁴⁴⁻⁵¹ There is no evidence-based severity regarding the retinoid dose, and the dose is determined based on experience. Acitretin was administered to 12 cases of PPK (3 'not classified' cases, 1 case of striate PPK, 4 of Unna-Thost-type, 1 with Mal de Meleda, and 3 cases of Papillon-Lefèvre syndrome).⁵⁰ No effect was seen in 2 cases, and therapeutic effects were noted in the remaining 10 cases.⁵⁰ Six patients with PPK (2 males and 4 females) were administered isotretinoin.⁵¹ These PPKs were as follows: 3 had Mal de Meleda, 1 had punctate PPK, and 2 were undiagnosed. The initial dose of isotretinoin was 0.5 mg/kg/day. After 16 weeks, the average dose increased to 1.95 mg/kg/day. Of the 6 cases, one was almost completely cured, 3 were relieved, and one was unresponsive. One patient discontinued treatment due to side effects.⁵¹

REFERENCES

- Wang B, Zhang Z, Huang X, Lin X, Qu W, Zhou Y. Successful treatment of mutilating palmoplantar keratoderma with acitretin capsule and adapalene gel: a case report with review of the literature. *J Eur Acad Dermatol Venereol* 2016; 30: 169-72. (Level V).

45. Lundgren T, Crossner CG, Twetman S, Ullbro C. Systemic retinoid medication and periodontal health in patients with Papillon-Lefèvre syndrome. *J Clin Periodontol* 1996; 23:176–9. (Level V).
46. Wereide K. Mutilating palmoplantar keratoderma successfully treated with etretinate. *Acta Derm Venereol*, 1984; 64: 566–9. (Level V).
47. Nazzaro V, Blanket-Bardon C, Mimoz C, Revuz J, Puisant A. Papillon-Lefèvre Syndrome. Ultrastructural study and successful treatment with acitretin. *Arch Dermatol* 1988; 124: 533–9. (Level V).
48. Camisa C, Rossana C. Variant of keratoderma hereditaria mutilans (Vohwinkel's syndrome). Treatment with orally administered isotretinoin. *Arch Dermatol* 1984; 120: 1323–8. (Level V).
49. Raone B, Raboni R, Patrizi A. Alitretinoin: a new treatment option for hereditary punctate palmoplantar keratoderma (Brauer-Buschke-Fischer syndrome). *J Am Acad Dermatol* 2014; 71: e48–49. (Level V).
50. Blanchet-Bardon C, Nazzaro V, Rognin C, Geiger JM, Puisant A. Acitretin in the treatment of severe disorders of keratinization. Results of an open study. *J Am Acad Dermatol* 1991; 24: 982–6. (Level V).
51. Bergfeld WF, Derbes VJ, Elias PM, Frost P, Greer KE, Shupack JL. The treatment of keratosis palmaris et plantaris with isotretinoin. A multicenter study. *J Am Acad Dermatol* 1982; 6: 727–31. (Level V).

4.2 | Active vitamin D3 ointment for topical use

CQ2: Is the topical use of active vitamin D3 ointment useful?

Statement on recommendation: The use of topical active vitamin D3 ointment may be considered.

Consent level: 4.68

Recommendation level: B

Commentary: There is a case series study which revealed that the application of an ointment containing calcipotriol was useful in about half of the 20 patients with PPK.⁵² In a case report in which one patient with punctate PPK was treated with oral low-dose retinoid and a topical ointment containing calcipotriol, the lesion almost disappeared.⁵³ There is also a report of one patient with striate PPK being treated with a topical ointment containing maxacalcitol.⁵⁴

REFERENCES

52. Kragballe K, Stijlen PM, Ibsen HH, et al. Efficacy, tolerability, and safety of calcipotriol ointment in disorders of keratinization. Results of a randomized, double-blind, vehicle-controlled, right/left comparative study. *Arch Dermatol*, 1995; 131: 556–60. (Level V).
53. Horikoshi M, Kuroda K, Tajima S. Punctate palmoplantar keratoderma with pigmentary lesions on the dorsa of feet and ankles: successful treatment with a combination of low-dose oral etretinate and topical calcipotriol. *J Dermatol*, 2004; 31: 469–72. (Level V).
54. Kawai K, Fukushige T, Sakanoue M, Kanekura T. Striate palmoplantar keratoderma. *J Dermatol*, 2010; 37: 854–6. (Level V).

4.3 | Salicylate vaseline ointment for topical use

CQ3: Is topical salicylate vaseline ointment useful?

Statement on recommendation: The use of topical salicylate vaseline for patients with PPK may be considered.

Consent level: 4.47

Recommendation level: B

Commentary: There is a case report of one family with Unna-Thost-type PPK treated with a combination of high-dose vitamin A (100,000 IU) and 12% salicylate vaseline applied topically. There is no consensus on the efficacy. However, it is commonly applied topically to patients to prevent dryness and fissures.⁵⁵

REFERENCES

55. Sehgal VN, Kumar S, Narayan S. Hereditary palmoplantar keratoderma (four cases in three generations). *Int J Dermatol*, 2001; 40:130–2. (Level V).

4.4 | Topical urea ointment

CQ4: Is topical urea ointment useful?

Statement on recommendation: The use of topical urea ointment for patients with PPK may be considered.

Consent level: 4.31

Recommendation level: B

Commentary: There is one case report in which the topical application of urea ointment was not effective during the treatment for patients with punctate PPK type 1A. No conclusion has been made regarding its efficacy. Nonetheless, in order to prevent dryness and fissures, topical application is performed in many patients.⁵⁶

REFERENCES

56. Bukhari R, Alhawsawi W, Radin AA, et al. Punctate palmoplantar keratoderma: A case report of type I (Buschke-Fischer-Brauer disease). *Case Rep Dermatol*, 2019; 11: 292–6. (Level V).

4.5 | Topical adapalene gel

CQ5: Is the topical application of adapalene gel useful?

Statement on recommendation: Effectiveness may be expected when used in combination with oral retinoids.

Consent: 4

Recommendation level: C1

Commentary: There is one case report of the topical use of adapalene gel in combination with an oral retinoid in a patient with mutilating PPK. No conclusion can be drawn about its efficacy.⁴⁴

4.6 | Dermabrasion

CQ6: Is dermabrasion useful?

Statement on recommendation: It can be considered for patients with PPK.

Consent level: 4.26

Recommendation level: B

Commentary: There is a report of a punctate PPK type 2 patient who underwent dermabrasion during treatment. Its efficacy has not

yet been established bibliographically. However, most PPK patients undergo treatment to remove hyperkeratosis that causes gait disorders and prevents pain.⁵⁷

REFERENCES

57. Torres G, Behshad R, Han A, Castrovinci AJ, Gilliam AC. "I forgot to shave my hands": A case of spiny keratoderma. *J Am Acad Dermatol*, 2008; 58: 344–8. (Level V).

4.7 | Treatment using nucleic acid drug small interfering RNA (siRNA)

CQ7: Is treatment using nucleic acid drug small interfering RNA (siRNA) useful?

Statement on recommendation: For the treatment of PPK, the administration of a nucleic acid drug siRNA would be a viable method in the future, but there are still some unclear points.

Consent Level: 4.1

Recommendation level: C1

Commentary: It was reported that siRNA was used against *KRT6A* to suppress keratin 6a protein expression in cultured human epidermal keratinocytes and mouse skin.^{58,59} It is also used in patients with pachyonychia congenita.⁶⁰

REFERENCES

58. Hickerson RP, Smith FJ, Reeves RE, Contag CH, Leake D, Leachman SA et al. Single-nucleotide-specific siRNA targeting in a dominant-negative skin model. *J Invest Dermatol*, 2008; 128: 594–605. (Level V).
59. Smith FJ, Hickerson RP, Sayers JM, Reeves RE, Contag CH, Leake D, et al. Development of therapeutic siRNAs for pachyonychia congenita. *J Invest Dermatol*, 2008; 128: 50–8. (Level V).
60. Leachman SA, Hickerson RP, Schwartz ME, Bullough EE, Hutcherson SL, Boucher KM et al. First-in-human mutation-targeted siRNA phase Ib trial of an inherited skin disorder. *Mol Ther*, 2010; 18: 442–6. (Level V).

4.8 | Treatment with readthrough drugs

CQ8: Is treatment with readthrough drugs useful?

Statement on recommendation: It is a promising therapeutic agent for patients with PPK.

Consent level: 4.16

Recommendation level: C1

Commentary: It has been reported that topical gentamicin was useful as a readthrough drug in 5 patients with Nagashima-type PPK.⁶¹ No conclusion has been made regarding its efficacy.

REFERENCES

61. Ohguchi Y, Nomura T, Suzuki S, Takeda M, Miyauchi T, Mizuno O, et al. Gentamicin-induced readthrough and nonsense-mediated mRNA decay of *SERPINB7* nonsense mutant transcripts. *J Invest Dermatol*, 2018; 138: 836–43. (Level V).

4.9 | Genetic counseling

CQ9: Is genetic counseling useful?

Statement on recommendation: Patients and their families should undergo genetic counseling if the disease's causative gene is known.

Consent level: 4.74

Recommendation level: B

Commentary: There are reports stating that genetic counseling is as important as the diagnosis and treatment for patients and their families when diagnosing patients with hereditary PPK.⁶²⁻⁶⁴

REFERENCES

62. Dev T, Mahajan VK, Sethuraman G. Hereditary plantar keratoderma: a practical approach to the diagnosis. *Indian Dermatol Online J*, 2019; 10: 365–79. (Level V).
63. Patch C, Middleton A. Genetic counseling in the era of genomic medicine. *Br Med Bull*, 2018; 126: 27–36. (Level IV).
64. Yang M, Kim JW. Principle of genetic counseling in the era of next-generation sequencing. *Ann Lab Med*, 2018; 38: 291–5. (Level IV).

CRITERIA TO DECIDE EVIDENCE LEVEL AND DEGREE OF RECOMMENDATION

As described below, the evidence level classification and degree of recommendation criteria adopted by the Guidelines for Skin Malignancy in Clinical Practice published by the Japanese Dermatology Association were used.

Criteria used to classify the level of evidence and degree of recommendation

A: Classification of the level of evidence

I: Systematic review/meta-analysis

II: One or more randomized controlled trials

III: Non-randomized controlled trial

IV: Analytical epidemiological studies (cohort studies and case-control studies)

V: Descriptive studies (case reports and case series studies)

VI: Opinions of expert committees or individual specialists¹

B: Degree of recommendation²

A: Highly recommended

(There must be at least level I or good quality level II evidence)

B: Recommended

(There is at least level I evidence showing efficacy or level II high-quality evidence. There is evidence of classification criteria for evidence level and degree of recommendation).

C1: Can be considered, but there is not enough supporting evidence³ (Poor quality III–IV, multiple good quality Vs or VIs approved by the committee).

C2: Lack of evidence 3, not actively recommended

(There is no evidence of effectiveness, or there is evidence available of ineffectiveness).

D: Recommended against

(There is good evidence that it is ineffective or harmful).

Notes:

¹ Data from basic experiments and theories derived from them are placed at this level.

² The degrees of recommendations in the text are not necessarily consistent with the above recommendations. This difference is due to the situation that there is insufficient evidence regarding the management of PPKs internationally, and the fact that foreign evidence cannot be applied to Japan without modification, and furthermore, considering the practicality, and evidence presented, etc. This is because there are places where the grade of recommendation level was decided based on the consensus reached at a committee meeting.

³ Evidence refers to findings from clinical trials and epidemiological studies.

ACKNOWLEDGMENT

The preparation of these guidelines was supported in part by the Ministry of Health, Labour and Welfare's Grant-in-Aid for Scientific

Research issued to the Ministry of Health, Labour and Welfare Research Project, entitled: "Comprehensive research on rare and intractable diseases associated with skin genetics."

ORCID

Kozo Yoneda  <https://orcid.org/0000-0001-6677-0866>

Akiharu Kubo  <https://orcid.org/0000-0003-0902-3586>

Toshifumi Nomura  <https://orcid.org/0000-0002-9954-6446>

Akemi Ishida-Yamamoto  <https://orcid.org/0000-0002-3104-102X>

Masashi Akiyama  <https://orcid.org/0000-0001-5863-9315>

Nobuo Kanazawa  <https://orcid.org/0000-0003-3000-9711>

Takashi Hashimoto  <https://orcid.org/0000-0002-0144-3255>

How to cite this article: Yoneda K, Kubo A, Nomura T, et al. Japanese guidelines for the management of palmoplantar keratoderma. *J Dermatol.* 2021;48:e353–e367. <https://doi.org/10.1111/1346-8138.15850>

APPENDIX

Parameter	Area of the hyperkeratotic lesion	Palmar erythema and hyperhidrosis	Finger/toe contracture and a constriction ring	Degree of nail deformation (anomaly of the nail plate)	Pain (spontaneous pain, tenderness, fissures, etc.)	Skin cancer, esophageal cancer	Cardiomyopathy	Periodontitis	Secondary bacterial infection such as cellulitis
Score 0	None	None	None	None	None	None	None	None	None
Score 1	<20%	Mild erythema		Mild (≤ 2 sites)			Abnormal test values only	Do not need any treatment	Treatment required
Score 2	<30%	Moderate erythema		Moderate (≥ 3 sites and ≤ 5 sites)			There are subjective symptoms (requires treatment/ can be reversed)	Treatment required	Hospitalization required
Score 3	$\geq 30\%$, or with impairment due to hyperkeratosis	Impaired QOL due to marked erythema or hyperhidrosis	Yes	Severe (≥ 6 sites)	Yes	Yes	Ablation (non-reversible)	Denture	Finger/limb amputation
Corresponding score									
									Total/27

Calculated from the total score of 9 items.

Mild disease: less than 2 points.

Moderate disease: 3 to 5 points.

Severe disease: 6 points or more.

Area of hyperkeratotic lesion: calculated as a ratio of the palmar and plantar surface area, including the area of transgrediens.

*transgrediens: The lesion spreads beyond the palmoplantar region to the dorsum of the toes, wrists, ankles, and up to the Achilles tendons.