

## PREFACE

# Management guideline for Werner syndrome 2020

## Establishing an evidence-based approach for the treatment of Werner syndrome

Werner syndrome (WS) is an autosomal recessive disorder sometimes referred to as “premature aging syndrome” because, beginning in puberty, it presents with symptoms such as cataracts, and loss and graying of hair, which makes individuals look relatively old for their age. Of the world’s reported cases to date, 60–80% are from Japan, where the incidence of WS in the population is unusually high. The life expectancy for people with WS is shorter because of its frequent comorbidities, which include diabetes, arteriosclerosis and malignant tumors. Although individuals with this disease “age prematurely,” simply referring to it as “accelerated aging” ignores the fact that the incidence of some common aspects of aging, such as dementia, are rare. Moreover, its comorbid malignant tumors are more frequently non-epithelial “sarcomas” than the more common epithelial “cancers”. In addition, the disease has a high incidence of intractable ulcers in the legs and feet, which result in pain and infections that can have a major negative impact in the person’s quality of life and vital prognosis.

In Japan, in 1984, the Ministry of Health and Welfare Specific Disease Research Group created a guide for the diagnosis of WS, which greatly contributed to the understanding of the disease. Since then, remarkable progress has been made in cellular research at the molecular level. In 1996, a mutation in the DNA helicase Werner syndrome protein (WRN) encoded by the RecQ genes on chromosome 8 was identified as the cause of the disease. Although no fundamental treatment has been developed for the disease, many studies have been published on its clinical features and the treatment of its specific morbidities. Findings of these studies are beginning to suggest that patient life expectancy could potentially be extended with appropriate treatment interventions.

It should be noted that numerous Japanese researchers have played a central role in advancing this research. On the other hand, no systematic survey of the number of patients, their symptoms and outcomes had been conducted in Japan for more than a quarter century. Furthermore, it can be presumed that a considerable number of Japanese individuals suffering from WS are never correctly diagnosed.

With this background, supported by a Health and Labour Sciences Research Grant for Research Projects on Overcoming Intractable Diseases, our research team set out to advance research on this disease with the following goals: (i) conduct a national assessment of the prevalence and treatment of patients with WS, (ii) create highly objective diagnostic standards that could be easily used as part of daily medical care, and (iii) standardize treatments of the syndrome and raise public awareness about the disease and its treatment. For the 2009–2013 Research Projects on Overcoming Intractable Diseases, the diagnostic criteria for WS were revised for the first time in 25 years, treatments were standardized, and the world’s first guidelines for its diagnosis and treatment were developed. A WS severity classification system was created by the 2014 Intractable Disease Policy Research Project, and in May 2014, WS was designated as an intractable disease (i.e., eligible for public medical expense subsidy). Regarding international forums, we sponsored a symposium in February 2012 for WS researchers from Japan and overseas in Tokyo, and in February 2018, we sponsored the International Meeting on RecQ Helicases and Related Diseases 2018, held in Chiba Prefecture.

For the 2020 version of the guidelines, we asked the leading WS researchers in all domains (including basic research, clinical research and medical care) for contributions beyond their fields of expertise. In principle, diagnostic and treatment guidelines consist of procedures that can be recommended scientifically and

This publication has been supported by The Japan Geriatrics Society

Contents

Preface

Takemoto M and Yokote K

Management guideline for Werner syndrome 2020

Chapter 1 Dyslipidemia and fatty liver associated with Werner syndrome

*Tsukamoto K, Takemoto M, Kubota Y, Taniguchi T, Motegi S, Taniguchi A, Nakagami H, Maezawa Y, Koshizaka M, Kato H, Mori S, Kuzuya M and Yokote K*

Chapter 2 Sarcopenia associated with Werner syndrome

*Kuzuya M, Takemoto M, Kubota Y, Taniguchi T, Motegi S, Taniguchi A, Nakagami H, Maezawa Y, Koshizaka M, Kato H, Mori S, Tsukamoto K and Yokote K*

Chapter 3 Diabetes associated with Werner syndrome

*Takemoto M, Kubota Y, Taniguchi T, Motegi S, Taniguchi A, Nakagami H, Maezawa Y, Koshizaka M, Kato H, Tsukamoto K, Mori S, Kuzuya M and Yokote K*

Chapter 4 Osteoporosis associated with Werner syndrome

*Mori S, Takemoto M, Kubota Y, Taniguchi T, Motegi S, Taniguchi A, Nakagami H, Maezawa Y, Koshizaka M, Kato H, Tsukamoto K, Kuzuya M and Yokote K*

Chapter 5 Infection associated with Werner syndrome

*Taniguchi T, Takemoto M, Kubota Y, Motegi S, Taniguchi A, Nakagami H, Maezawa Y, Koshizaka M, Kato H, Tsukamoto K, Mori S, Kuzuya M and Yokote K*

Chapter 6 Skin ulcers associated with Werner syndrome: Prevention and non-surgical and surgical treatment

*Kubota Y, Takemoto M, Taniguchi T, Motegi S, Taniguchi A, Nakagami H, Maezawa Y, Koshizaka M, Kato H, Mori S, Tsukamoto K, Kuzuya M and Yokote K*

Chapter 7 Skin ulcer associated with Werner syndrome

*Motegi S, Takemoto M, Kubota Y, Taniguchi T, Taniguchi A, Nakagami H, Maezawa Y, Koshizaka M, Kato H, Mori S, Tsukamoto K, Kuzuya M and Yokote K*

Chapter 8 Calcification in tendons associated with Werner syndrome

*Taniguchi A, Tanaka Y, Takemoto M, Kubota Y, Taniguchi T, Motegi S, Nakagami H, Maezawa Y, Koshizaka M, Kato H, Tsukamoto K, Mori S, Kuzuya M and Yokote K*

objectively based on collections of findings from clinical research backed by a large amount of evidence. However, for a rare disease such as WS, no large-scale treatment intervention studies can be conducted; therefore, the “evidence” available is limited. Thus, rather than being true “guidelines,” this management guideline is more of a “consensus guide” to clinical practice. However, we will be flattered if this attempt garners a certain amount of appreciation as “the first guide for the standardized treatment of WS that can be performed anywhere in the world.” Furthermore, using this guide as a foundation, it is our responsibility as researchers to make periodic revisions as we work toward the completion of “true guidelines,” by trying to increase the amount of evidence available and establish the fundamentals of treatment.

In 2010, our research team started the world’s first WS peer support group, the Werner Syndrome Patient and Family Association, building a foundation for patients and their families nationwide to make the most of treatment by sharing their concerns and information with peers. In addition, we were happy that both of the aforementioned symposia were jointly held with association, which enabled researchers to hear patients and their families “live” and provided researchers with the latest research results for their benefit.

Finally, we would like to express our sincere gratitude to everyone who made this management guideline possible, including the doctors and medical facilities nationwide that kindly cooperated with our research team, all the co-researchers and collaborators on this project who worked so hard on the guidelines, all members of

the Werner Syndrome Patient and Family Association who really motivated us, everyone at the Japan Patients Association, and everyone involved with the Health and Labour Sciences Research Grant for the Intractable Disease Policy Research Project.

## Disclosure statement

The authors declare no conflict of interest.

Dr. Minoru Takemoto<sup>1</sup>  and Dr. Koutaro Yokote<sup>2</sup>

<sup>1</sup>Department of Diabetes, Metabolism and Endocrinology,  
School of Medicine, International University of Health and  
Welfare, Chiba, Japan

<sup>2</sup>Department of Endocrinology, Hematology and Gerontology,  
Chiba University Graduate School of Medicine, Chiba, Japan




**How to cite this article:** Takemoto M, Yokote K. Management guideline for Werner syndrome 2020. *Geriatr. Gerontol. Int.* 2020;1–2. <https://doi.org/10.1111/ggi.14074>

## ORIGINAL ARTICLE

## SOCIAL RESEARCH, PLANNING AND PRACTICE

# Management guideline for Werner syndrome 2020

## 1. Dyslipidemia and fatty liver associated with Werner syndrome

Kazuhisa Tsukamoto,<sup>1</sup> Minoru Takemoto,<sup>2</sup> Yoshitaka Kubota,<sup>3</sup> Toshibumi Taniguchi,<sup>4</sup> Sei-ichiro Motegi,<sup>5</sup> Akira Taniguchi,<sup>6</sup> Hironori Nakagami,<sup>7</sup>  Yoshiro Maezawa,<sup>8</sup> Masaya Koshizaka,<sup>8</sup>  Hisaya Kato,<sup>8</sup> Seijiro Mori,<sup>9</sup> Masafumi Kuzuya<sup>10</sup>  and Koutaro Yokote<sup>8</sup>

<sup>1</sup>Department of Internal Medicine, Teikyo University School of Medicine, Tokyo, Japan

<sup>2</sup>Department of Diabetes, Metabolism and Endocrinology, School of Medicine, International University of Health and Welfare, Chiba, Japan

<sup>3</sup>Department of Plastic, Reconstructive and Aesthetic Surgery, Chiba University Graduate School of Medicine, Chiba, Japan

<sup>4</sup>Department of Infectious Diseases, Chiba University Hospital, Chiba, Japan

<sup>5</sup>Department of Dermatology, Gunma University Graduate School of Medicine, Gunma, Japan

<sup>6</sup>Department of Orthopedic surgery, Nara Medical University, Nara, Japan

<sup>7</sup>Department of Health Development and Medicine, Osaka University Graduate School of Medicine, Osaka, Japan

<sup>8</sup>Department of Endocrinology, Hematology and Gerontology, Chiba University Graduate School of Medicine, Chiba, Japan

<sup>9</sup>Center for the Promotion of Clinical Investigation, Tokyo Metropolitan Geriatric Hospital, Tokyo, Japan

<sup>10</sup>Department of Community Healthcare & Geriatrics, Nagoya University Graduate School of Medicine, Institutes of Innovation for Future Society, Nagoya University, Nagoya, Japan

For the purpose of examining the characteristics of dyslipidemia and fatty liver in patients with Werner syndrome in Japan in recent years, we searched all case reports of Japanese Werner syndrome reported on Medical Online and PubMed since 1996, and collected and examined the data and clinical features described in these reports. In addition, as there are few descriptions of treatment methods in these reports from Medical Online and PubMed, we analyzed 12 cases for which detailed data on treatment methods are available at Chiba University. *Geriatr Gerontol Int* 2020; ••: ••–••.

**Keywords:** clinical medicine, geriatric medicine, management guideline, Werner syndrome.

### Correspondence

Professor Minoru Takemoto MD  
PhD, Department of Diabetes,

Metabolism and Endocrinology,  
School of Medicine, International  
University of Health and Welfare,  
4-3, Kozunomori, Narita, Chiba  
286-8686, Japan. Email: minoru.  
takemoto@iuhw.ac.jp  
Professor Koutaro Yokote MD  
PhD, Department of  
Endocrinology, Hematology and  
Gerontology, Chiba University  
Graduate School of Medicine, 1-8-1  
Inohana, Chuo-ku, Chiba  
260-8670, Japan.  
Email: kyokote@faculty.chiba-u.jp

Received: 5 October 2020

Revised: 28 October 2020

Accepted: 4 November 2020

## Introduction

Arteriosclerosis is one of the two leading causes of death in Werner syndrome patients, along with malignancy.<sup>1</sup> Among the various forms of arteriosclerosis Werner syndrome patients develop, coronary artery diseases and peripheral arterial disease have a high incidence, and the latter plays a role in making skin ulcers in Werner syndrome patients refractory.<sup>2</sup> Arteriosclerosis in Werner syndrome patients is considered to be one of the features of disease-specific premature aging, whereas disorders of carbohydrate metabolism and lipid metabolism associated with Werner syndrome also act as promoting factors. Insulin resistance associated with a fatty liver (non-alcoholic fatty liver disease [NAFLD]) and accumulation of visceral fat has been considered to be greatly involved in these metabolic abnormalities.<sup>3–5</sup> Recently, the ratio of hepatocellular cancer caused by NAFLD or non-alcoholic steatohepatitis (NASH) in all hepatocellular cancers has reportedly risen in the general population, thus the management of these diseases in Werner syndrome patients is also important.<sup>6,7</sup>

It has been said that Werner syndrome patients develop dyslipidemia/fatty liver at a high rate. The previous guidelines showed that hypercholesterolemia occurred in 53% of 15 Werner syndrome patients.<sup>2</sup> However, there have been no data obtained by an extensive literature screening on the incidence of dyslipidemia and characteristics of dyslipidemia/fatty liver in Werner syndrome patients. To address this issue in the current edition of the guidelines, we screened cases reported on PubMed and Medical Online from 1996 to 2016 (98 articles, 119 cases), from which 44 cases (26 men with a mean age of 45.6 years) including some descriptions or data relating to either lipid or fatty liver in the articles were selected for analysis (reports before 2005: 26 cases).<sup>8–43</sup> The detailed literature search method and process were as follows.

Medical Online: We searched Medical Online with the search term “Werner Syndrome” and publication year “since 1996”. A total of 186 papers were hit, and 49 case reports were confirmed to be appropriate and picked up.

PubMed: We searched PubMed by search formula “Werner syndrome” [All Fields] AND (Case Reports [ptyp] AND [“1996/01/01”

(PDAT): “3000/12/31” (PDAT))). With this screening, 151 case reports were hit, and 49 Japanese documents were picked up from them.

Considering that Werner syndrome is likely to be associated with malignant diseases, and that an onset of a malignant disease would possibly affect the lipid metabolism or fatty liver, the participants were divided into 13 Werner syndrome patients with a malignant disease (6 men; mean age 50.4 years) and the remaining 31 Werner syndrome patients with either no malignant diseases or no descriptions of malignant diseases (20 men; mean age 43.6 years) for analysis. As to these data, the Werner syndrome patients with a malignant disease and the other Werner syndrome patients are represented as a group with M and a group without M, respectively, in the guidelines.

Meanwhile, the case reports obtained through the aforementioned literature search included neither adequate description on the treatment nor records on any treatment effect/rates of achieving control target values. Additionally, an antihyperlipidemic drug has shown remarkable progress in recent years. Under such circumstances, we researched treatments for dyslipidemia/fatty liver and their effects in 11 patients with no malignant diseases at the time of data acquisition (4 men and 7 women; mean age 50.7 years [range 39–60 years]) among 12 patients (5 men and 7 women; mean age 50.1 [range 39–60 years]) under follow up at Chiba University whose detailed data on their lipid levels and fatty livers from 2010 were available. We also examined patients with data of a liver-to-spleen attenuation ratio (L/S ratio), which was considered to reflect the degree of fatty liver.

The results obtained through literature search are represented as SR, and the results of case examination at Chiba University are represented as CS in these guidelines.

## Dyslipidemia

**Q1. How frequently does dyslipidemia occur in Werner syndrome? What type of dyslipidemia appears in these patients?**

**A1. The incidence of dyslipidemia in Werner syndrome patients is high, at 85%. The most common type of dyslipidemia is hypertriglyceridemia, occurring in 76% of**

patients, followed by hyper-low-density lipoprotein (LDL) cholesterolemia/non-high-density lipoprotein (HDL) cholesterolemia in 68% of patients and hypo-HDL cholesterolemia in 32% of patients (SR; Table 1).

Descriptions on the presence or the absence of dyslipidemia were found in 41 (the group with M: 13 patients, the group without M: 28 patients) of 44 patients, and 35 of whom (85.4%) developed dyslipidemia (the group with M: 84.6%, the group without M: 85.7%). Data on lipid were confirmed in 25 patients (the group with M: 7 patients, the group without M: 18 patients); hypertriglyceridemia (TG) accounted for 76.0% (the group with M: 57.1%, the group without M: 83.3%), hyper-LDL cholesterolemia/non-HDL cholesterolemia accounted for 68.0% (the group with M: 42.9%, the group without M: 77.8%) and hypo-HDL cholesterolemia accounted for 32.0% (the group with M: 14.2%, the group without M: 38.9%).

**Q2. What are the characteristics of Werner syndrome with dyslipidemia?**

**A2. Werner syndrome patients with dyslipidemia develop diabetes at a high rate (≥90%). The mean body mass index (BMI) of Werner syndrome patients with TG was 18.2, showing a lack of association with obesity (SR; Tables 1,2)**

Records on the presence or the absence of diabetes were found in 33 out of 35 Werner syndrome patients with dyslipidemia, and 31 patients (93.9%) of whom developed diabetes (the group with M: 88.9%, the group without M: 95.8%), showing an extremely high incidence of diabetes. Complications of arteriosclerosis were found in four Werner syndrome patients with dyslipidemia; they developed atherosclerosis at a mean age of 41 years, indicating premature arteriosclerosis in Werner syndrome.

A total of 19 Werner syndrome patients with hypertriglyceridemia had a mean BMI of 18.2 (the group with M: 17.6, the group without M: 18.4), a maximum BMI of 22.8 and a minimum BMI of 12.49. There were nine underweight patients who had a BMI <18.5 (47.3%; the group with M: 7 patients, 46.7%; the group without M: 2 patients, 50%). The mean BMI of nine patients with normal triglyceridemia was 16.5, and eight of whom (88.9%) had a BMI not >18.5; there was no significant difference in BMI among normo- and hypertriglyceridemic patients, but was a tendency to be more "underweight" in normotriglyceridemic patients than those with hypertriglyceridemia. Thus, Werner syndrome patients with hypertriglyceridemia tended to have a higher BMI than patients with normal triglyceridemia in Werner syndrome; however, its characteristics were different from those in hypertriglyceridemic patients in the general population, who are strongly complicated with obesity.

**Q3. What are the rates of achieving the lipid control target values in patients with Werner syndrome? Which drugs are effective?**

**A3. The rates of achieving the lipid control target values are high, at 91% for LDL cholesterol, 91% for HDL cholesterol and 82% for TG. Strong statin is mainly used as an antidyplipidemic drug, and contributes to achieving the control target values (CS).**

Of 12 Werner syndrome patients with CS, diabetes was documented in six, glucose intolerance in one, lower leg ulcer in nine and peripheral arterial disease in three (all developed diabetes and lower leg ulcer), but none had a history of myocardial infarction. Thus, there were six patients who were classified as the high-risk group according to the categorization in the Japan Atherosclerosis Society (JAS) Guidelines for Prevention of Atherosclerotic Cardiovascular diseases 2017.<sup>44</sup>

Among 11 Werner syndrome patients who did not have malignant disease, five were taking antidyplipidemic drugs, one was neither taking a statin nor achieved the LDL cholesterol control target value based on risk factors, one had HDL cholesterol <40 mg/dL and two had TG levels of ≥150 mg/dL; thus, taken all together, eight were diagnosed with dyslipidemia (a patient who met either criterion; 73%). All patients who were taking statin achieved the LDL cholesterol control target value, and the achievement rates for LDL cholesterol, TG and HDL cholesterol reached markedly high levels of 91%, 82% and 91%, respectively. Antidyplipidemic drugs administered to the patients were all strong statins (atorvastatin, rosuvastatin and pitavastatin).

The LDL cholesterol level of Werner syndrome patients complicated with diabetes, which is classified as a high-risk condition in the JAS guidelines, was 84.5 ± 21.4 mg/dL (minimum 51.0 mg/dL, maximum 105.4 mg/dL), showing successful control compared with the mean LDL cholesterol level of diabetes patients in the general population who received special health checkups (men 114.0 mg/dL, women 122.9 mg/dL).<sup>45</sup> Similarly, the LDL cholesterol level of Werner syndrome patients with peripheral arterial disease, also a high-risk condition in the JAS Guidelines, was 75.1 ± 23.2 mg/dL (minimum 51.0 mg/dL, maximum 97.4 mg/dL), which was a better outcome compared with special health checkup results of patients with a history of cerebral vascular disorder, a high-risk condition, as with peripheral arterial disease (men 115.7 mg/dL, women 123.2 mg/dL).<sup>45</sup> As such, the rates of Werner syndrome patients achieving the lipid control target values reached 100% in high-risk conditions, suggesting that the lipid was quite successfully controlled in high-risk Werner syndrome patients, compared with the approximately 60% achievement rate of

**Table 1** Characteristics of dyslipidemia among Werner Syndrome

Malignant disease	No. cases	No. cases (%)	Dyslipidemia		DM among dyslipidemic patients		Cases reported with precise lipid data				
			present	Absent	Present	Absent	Not reported	Reported	High LDL-C/ non-HDL-C	High TG	Low HDL-C
Asent or not reported	No. cases (%)	28	24 (85.7)	4 (14.3)	23 (95.8)	1 (4.2)	0	18	14 (77.8)	15 (83.3)	7 (38.9)
Present	No. cases (%)	13	11 (84.6)	2 (15.4)	8 (88.9)	1 (1.1)	2	7	3 (42.9)	4 (57.1)	1 (14.3)
Total	No. cases (%)	41	35 (85.3)	6 (14.7)	31 (75.6)	2 (4.9)	2	25	17 (68.0)	19 (76.0)	8 (32.0)

DM, diabetes mellitus; HDL-C, high density lipoprotein-cholesterol; LDL-C, low density lipoprotein-cholesterol; TG, triglyceride.

**Table 2** Characteristics of Werner syndrome patients with hypertriglyceridemia

Malignant disease		No. cases	Mean BMI	BMI <18.5	
				No. cases	%
Absent or not reported	High TG	15	18.4	7	46.7
	Normal TG	6	16.4	5	83.3
Present	High TG	4	17.6	2	50.0
	Normal TG	3	16.7	3	100
Total	High TG	19	18.2	9	47.3
	Normal TG	9	16.5	8	88.8

BMI, body mass index; TG, triglyceride.

**Table 3** Characteristics of Werner syndrome patients documented with fatty liver

Malignant Disease	No. cases (n)	Mean BMI	Max BMI	BMI >22		BMI <18.5		No. cases with lipid data	Complicated with dyslipidemia		No. cases with GI data	Complicated with GI
				No. cases	%	No. cases	%		No. cases	%		
Absent or not reported	10	19.3	22.6	2	20.0	4	40.0	10	9	90.0	10	9
Present	2	18.7	19.3	0	0.0	0	0.0	2	2	100.0	1	1
Total	12	18.8	22.6	2	16.7	4	33.3	12	11	91.6	11	10

BMI, body mass index; GI, glucose intolerance.

LDL cholesterol control target value in the general population with high-risk conditions (with a history of diabetes or cerebrovascular disorder) based on special health checkup data.<sup>45</sup>

### Fatty liver

#### Q4. What are the characteristics of fatty liver in patients with Werner syndrome?

**A4. Werner syndrome with fatty liver had a mean BMI of 18.8 and a maximum BMI of 22.6, and 83% of these patients are underweight (SR; Table 3.)**

Descriptions of fatty liver were found in 12 (the group with M: 10 patients, the group without M: 2 patients) of 44 Werner syndrome patients, with a mean BMI of 18.8 (the group with M: 18.7, the group without M: 19.3). Among them, just two patients had a BMI of  $\geq 22$  (in the group without M), and the maximum BMI was 22.6. In contrast, the prevalence of fatty liver (NAFLD) in the general population is approximately 30% and increases with the degree of obesity. The reported incidences of NAFLD in individuals with a BMI of  $\geq 28$ , 25–<28, 23–<25 and <23 are approximately 85%, 60%, 40% and 10%, respectively. Accordingly, the main characteristic of fatty liver in Werner syndrome patients would be that even “underweight” patients develop fatty liver at a high rate. Additionally, 91.6% of these 12 Werner syndrome patients with fatty liver had concomitant dyslipidemia (the group with M: 90.0%, the group without M: 100%), and 90.9% had disorders of carbohydrate metabolism (the group with M: 90.0%, the group without M: 100%), showing that they also developed other metabolic disorders at a high rate.

**Q5. Are there any differences in biochemical data between Werner syndrome patients with fatty liver and those without fatty liver?**

**A5. The L/S ratio showed a positive correlation with HDL cholesterol levels and a negative correlation with TG levels. It does not correlate with the liver enzyme levels (CS).**

The following are analytical results of nine patients with data on L/S ratios and without malignancy in CS. Four patients (44%) had concomitant fatty liver (L/S ratio not >1.0). The mean BMI of these patients was 16.7 (maximum BMI 17.8, minimum BMI 15.5), consisting only of “underweight” patients (the mean BMI of non-fatty liver patients 17.1). When individual laboratory test values (LDL-C, HDL-C non-HDL-C, TG, aspartate transaminase, alanine transaminase,  $\gamma$ -glutamyl transpeptidase, cholinesterase and aspartate transaminase/alanine transaminase ratio) of the fatty liver group were compared with those of the non-fatty liver group (*t*-test), the HDL cholesterol levels stood at  $46.0 \pm 8.1$  mg/dL in the fatty liver group and  $64.6 \pm 13.3$  mg/dL in the non-fatty liver group, showing a significantly low value in the fatty liver group ( $P < 0.05$ ). As to the correlation of the L/S ratio with each laboratory value, it showed a positive correlation with the HDL cholesterol levels ( $R^2 = 0.609$ ,  $P = 0.013$ ) and a negative correlation with the TG levels ( $R^2 = 0.509$ ,  $P = 0.031$ ).

**Q6. Have there been any Werner syndrome patients with hepatocellular cancer?**

**A6. One of the 44 Werner syndrome patients reportedly developed hepatocellular cancer, although no specific description of a relationship with fatty liver was found (SR).**

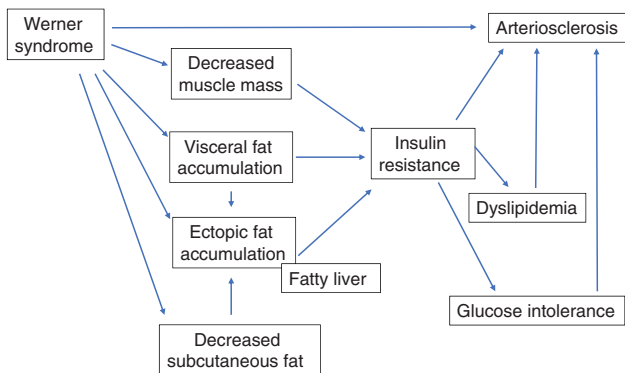
One report out of 44 showed that hepatocellular cancer occurred in a 40-year-old male patient.<sup>30</sup> Although we cannot say for certain due to a lack of description on a non-cancerous hepatic tissue, he tested negative for hepatitis B and C viruses and autoimmune hepatic disease, and thus it cannot be denied that hepatocellular cancer might have been originally caused by NAFLD or NASH in this case.



## Discussion

As described in the review article by Epstein *et al.* in 1966<sup>46</sup> and in the report by Yokote *et al.* in 1989,<sup>47</sup> Werner syndrome is likely to be accompanied with dyslipidemia. We comprehensively collected recent relevant case reports (from 1996) and examined them according to the diagnostic criteria specified in the JAS Guidelines for Prevention of Atherosclerotic Cardiovascular diseases 2017.<sup>44</sup> The results showed that: (i) dyslipidemia occurred in 85% of Werner syndrome patients,  $\geq 90\%$  of whom developed diabetes; (ii) all types of dyslipidemia (i.e. hyper-LDL cholesterolemia/non-HDL cholesterolemia, hypertriglyceridemia and hypo-HDL cholesterolemia) were observed in Werner syndrome, although hypertriglyceridemia was relatively common; and (iii) Werner syndrome patients developed hypertriglyceridemia without obesity; the mean BMI of affected patients was 18.2. Mori *et al.* examined abdominal computed tomography images of three male patients and one female patient, which showed that two male patients had a visceral fat area of  $>100 \text{ cm}^2$  and the other two patients showed a high visceral fat area/subcutaneous fat area ratio.<sup>21</sup> There remain many unclear points about the molecular mechanism of accumulated visceral fat in Werner syndrome, but the accumulation of visceral fat is considered to increase insulin resistance, leading to dyslipidemia or disorder of carbohydrate metabolism. From another point of view, Werner syndrome is a condition that has not only visceral fat accumulation observed in metabolic syndrome, but also an imbalance between visceral fat mass and subcutaneous fat mass and subcutaneous fat reduction, which are observed in lipodystrophic patients<sup>48</sup> and metabolically unhealthy normal-weight individuals.<sup>49</sup> In any of these pathological conditions, the cardiometabolic phenotype, such as dyslipidemia, diabetes, insulin resistance and ectopic fat accumulation, such as fatty liver, is observed. In particular, in recent years, great attention has been paid to the contribution of a decrease in subcutaneous fat to fatty liver and cardiometabolic phenotype, and this contribution is thought to be compatible with Werner syndrome.<sup>50</sup> The assumed mechanism for cardiometabolic phenotype in Werner syndrome is summarized in Figure 1.

As to hyper-LDL cholesterolemia, Yokote and Mori *et al.* reported that thickened Achilles tendon and hypercholesterolemia occurred in six out of 10 Werner syndrome patients in their facilities,<sup>47</sup> and five of them showed a decrease in the LDL receptor activity;<sup>51</sup> thus, it might be plausible that Werner syndrome itself possesses some sort of mechanism to decrease the LDL receptor activity. Given that an increased LDL cholesterol level is a disease-specific postnatal feature in Werner syndrome, it might be possible to assume that hypercholesterolemia in Werner syndrome patients has a risk equivalent to familial hypercholesterolemia considering the notion of cumulative LDL cholesterol, which has recently been proposed.



**Figure 1** Schematic flow of metabolic disorder that causes arteriosclerosis in Werner syndrome.

Of course, it remains unclear whether dyslipidemia occurs before the diagnosis of Werner syndrome. However, considering that macrophages are likely to become foamy in Werner syndrome, and that Werner syndrome is characterized by overlapping risk factors including disorders of carbohydrate metabolism and accumulated visceral fat, it is necessary to proactively and adequately control dyslipidemia.<sup>52</sup> The analyses of 12 Werner syndrome patients in CS showed that an intensive treatment using strong statin might possibly achieve the lipid control target values. The rate of achieving the LDL cholesterol control target value of high-risk patients in the special health checkup was approximately 60%, whereas that in Werner syndrome patients was  $\geq 90\%$ , which might be because both healthcare professionals and patients have recognized the association between Werner syndrome and arteriosclerosis, and proactively treated dyslipidemia in Werner syndrome.

According to the questionnaire investigation of 102 Werner syndrome patients carried out by Imura *et al.* in Japan in 1985, 35.4% of these patients had mild hepatic dysfunction, and fatty liver was suggested as its cause.<sup>53</sup> The analysis on 12 Werner syndrome patients in CS confirmed that approximately 40% of them developed fatty liver. Unlike common fatty liver disease, both the SR and CS analyses showed that fatty liver occurred in normal-weight and underweight Werner syndrome patients, and that the rates of developing dyslipidemia and glucose intolerance were extremely high in them. A similar mechanism for the onset of fatty liver in the general population; that is, excessive free fatty acids inflow into the liver from the accumulated visceral fat, would underlie the onset of fatty liver in Werner syndrome, although a Werner syndrome-specific mechanism might be involved in the onset of fatty liver.<sup>54</sup>

Recently, an onset of hepatocellular cancer caused by NAFLD or NASH has become the focus of interest. Hepatocellular cancer observed in a 40-year-old Werner syndrome patient of SR might have occurred in association with Werner syndrome, but the possibility of its occurrence in association with fatty liver or NASH cannot be excluded. Therefore, a treatment to ameliorate fatty liver also needs to be established. There is evidence about treatments with pioglitazone,<sup>55,56</sup> vitamin E<sup>57</sup> and ursodeoxycholic acid<sup>58</sup> in the general population, whereas Takemoto *et al.* reported that astaxanthin, a kind of carotenoid, improved fatty liver in Werner syndrome patients.<sup>43</sup> Another study also showed an effect of resveratrol to improve fatty liver in a Werner syndrome-model animal.<sup>59</sup> Further therapeutic drug development is expected.

## Disclosure statement

The authors declare no conflict of interest.

## References

- Goto M. Hierarchical deterioration of body systems in Werner's syndrome: implications for normal ageing. *Med Ageing Dev* 1997; **98**: 239–254.
- The Guideline of Werner Syndrome for Diagnosis and Clinical Practice 2012. <http://www.m.chiba-u.jp/dept/clin-cellbiol/files/5215/0752/8288/guideline.pdf#search=%E3%82%A6%E3%82%A7%E3%83%AB%E3%83%8A%E3%83%BC%E7%97%87%E5%80%99%E7%BE%A4+%E3%82%AC%E3%82%A4%E3%83%89%E3%83%A9%E3%82%A4%E3%83%B3>
- Kitade H, Chen G, Ni Y, Ota T. Nonalcoholic fatty liver disease and insulin resistance: new insights and potential new treatments. *Nutrients* 2017; **9**: 387.
- Kahn BB, Flier JS. Obesity and insulin resistance. *J Clin Invest* 2000; **106**: 473–481.
- Hardy OT, Czech MP, Corvera S. What causes the insulin resistance underlying obesity? *Curr Opin Endocrinol Diabetes Obes* 2012; **19**: 81–87.
- Evidence-based clinical practice guidelines for nonalcoholic fatty liver disease/nonalcoholic steatohepatitis. *J Gastroenterol* 2015; **50**: 364–377.
- Anstee QM, Reeves HL, Kotsiliti E *et al.* From NASH to HCC: current concepts and future challenges. *Nat Rev Gastroenterol Hepatol* 2019; **16**: 411–428.

- 8 Mita M, Ishibashi T, Shichishima T, Maruyama Y. Myelodysplastic syndrome with multiple chromosomes aberrations in a patient with Werner's syndrome. *Rinsho Ketsueki* 1996; **37**: 725–730.
- 9 Cho KB, Tanabe Y *et al.* Siblings of Werner syndrome who died of cardiovascular diseases: a case report. *Niigata mMed Soc J* 1996; **110**: 186 (in Japanese).
- 10 Morita K, Nishigori C, Sasaki MS *et al.* Werner's syndrome: chromosome analyses of cultured fibroblasts and mitogen-stimulated lymphocytes. *Br J Dermatol* 1997; **136**: 620–623.
- 11 Yamanaka A, Hirai T, Ohtake Y, Kitagawa M. Lung cancer associated with Werner's syndrome: a case report and review of the literature. *Jpn J Clin Oncol* 1997; **27**: 415–418.
- 12 Igarashi M, Shiina Y, Morimoto K *et al.* A case of Werner syndrome that could be saved by inserting a stent into the lesion at the origin of the right coronary artery. *Heart* 1997; **29**: 764–769 (in Japanese).
- 13 Takano S, Kato K, Waguri N *et al.* A case of Werner syndrome with a 5-year progression of aortic stenosis. *Heart* 1997; **29**: 150–154 (in Japanese).
- 14 Okazaki M, Ueda K, Kuriki K. Lateral supramalleolar flap for heel coverage in a patient with Werner's syndrome. *Ann Plast Surg* 1998; **41**: 307–310.
- 15 Kubokawa M, Ikuyama S, Sakai H *et al.* A case of Werner syndrome who were associated with malignant melanoma. *Jpn J Clin Exp Med* 1998; **75**: 2641–2644 (in Japanese).
- 16 Murata K, Hatamochi A, Shinkai H, Ishikawa Y, Kawaguchi N, Goto M. A case of Werner's syndrome associated with osteosarcoma. *J Dermatol* 1999; **26**: 682–686.
- 17 Akiyama K, Takazawa A, Taniyasu N, Sato H. Revascularization of femoropopliteal artery occlusion in Werner's syndrome. Report of a case and review of surgical literature in cardiovascular lesions. *J Cardiovasc Surg (Torino)* 2000; **41**: 303–306.
- 18 Kobayashi J, Murano S, Yokote K *et al.* Marked decrease in plasma apolipoprotein A-I and high density lipoprotein-cholesterol in a case with Werner syndrome. *Clin Chim Acta* 2000; **293**: 63–73.
- 19 Shimura K, Shimazaki C, Okamoto A *et al.* Werner's syndrome associated with acute myelofibrosis. *Rinsho Ketsueki* 2000; **41**: 123–128.
- 20 Tsuji Y, Kusuzaki K, Kanemitsu K, Matsumoto T, Ishikawa Y, Hirasawa Y. Calcaneal osteosarcoma associated with Werner syndrome. A case report with mutation analysis. *J Bone Joint Surg Am* 2000; **82**: 1308–1313.
- 21 Mori S, Murano S, Yokote K *et al.* Enhanced intra-abdominal visceral fat accumulation in patients with Werner's syndrome. *Int J Obes Relat Metab Disord* 2001; **25**: 292–295.
- 22 Sato O, Nakabayashi K, Ichinose H, Namiki A. A case of Werner syndrome in which lumbar sympathetic ganglion block was effective. *J Jpn Soc Pain Clin* 2001; **8**: 44–46 (in Japanese).
- 23 Nakayama T, Ochiai T, Takahashi Y, Ohkubo K, Hironaga T, Kokubun S. A novel mutation in a patient with Werner's syndrome. *Gerontology* 2002; **48**: 215–219.
- 24 Mori H, Tomiyama T, Maeda N, Ozawa K, Wakasa KI. Lack of amyloid plaque formation in the central nervous system of a patient with Werner syndrome. *Neuropathology* 2003; **23**: 51–56.
- 25 Murakami M, Tsutsumi S, Tezuka N, Kurachi H. Pregnancy complicated with Werner's syndrome. *BJOG* 2003; **110**: 635–636.
- 26 Kawamura H, Tsuchida H, Maczawa Y *et al.* A case of Werner syndrome in which hemodialysis was introduced due to chronic renal failure. *Jpn J Geriatr* 2003; **40**: 282–286 (in Japanese).
- 27 Sogabe Y, Yasuda M, Yokoyama Y *et al.* Genetic analyses of two cases of Werner's syndrome. *Eur J Dermatol* 2004; **14**: 379–382.
- 28 Matsutani R, Watanabe Y, Kato T, Kubo T. A case of Werner syndrome who was associated with a vocal cord polyp. *Larynx Jpn* 2005; **17**: 39–42 (in Japanese).
- 29 Ochi M, Igase M, Nagai A *et al.* A case of Werner syndrome with chromosomal abnormality. *Nihon Ronen Igakkai Zasshi* 2006; **43**: 639–642.
- 30 Shimono J, Haratake J. A case of Werner syndrome who was associated with a hepatocellular carcinoma. *Jpn J Clin Exp Med* 2006; **83**: 1863–1864 (in Japanese).
- 31 Hashimoto N, Hatanaka S, Yokote K *et al.* A patient with Werner syndrome and adiponectin gene mutation. *Diabetes Res Clin Pract* 2007; **75**: 27–29.
- 32 Yamamoto H, Kurebayashi S, Kouhara H *et al.* Impacts of long-term treatments with testosterone replacement and pioglitazone on glucose and lipid metabolism in male patients with Werner's syndrome. *Clin Chim Acta* 2007; **379**: 167–170.
- 33 Sakura M, Tsujii T, Yamauchi A *et al.* A case of Werner syndrome with triple cancers of bladder cancer, malignant fibrous histiocytoma, and basal cell carcinoma. *Jpn J Urol Surg* 2007; **20**: 190 (in Japanese).
- 34 Taniguchi Y, Asai Y, Shimoe T *et al.* A experience in treating knee joint skin soft tissue defects by free latissimus dorsi flap transplantation. *J Wakayama Med Soc* 2008; **59**: 134–138 (in Japanese).
- 35 Izumi H, Natori K, Ishihara S *et al.* A case of Werner syndrome with breast cancer and myelodysplastic syndrome. *Jpn J Clin Exp Med* 2008; **85**: 1187–1189 (in Japanese).
- 36 Hashizume H, Sato K, Takagi H *et al.* Werner syndrome as a possible cause of non-alcoholic steatohepatitis. *J Clin Pathol* 2009; **62**: 1043–1045.
- 37 Ohnishi S, Fujimoto M, Oide T *et al.* Primary lung cancer associated with Werner syndrome. *Geriatr Gerontol Int* 2010; **10**: 319–323.
- 38 Furuya M *et al.* A case of Werner syndrome who was diagnosed during treatment for juvenile-onset diabetes. *Folia Endocrinol Jpn* 2011; **87**: 351 (in Japanese).
- 39 Takada-Watanabe A, Yokote K, Takemoto M *et al.* A case of Werner syndrome without metabolic abnormality: implications for the early pathophysiology. *Geriatr Gerontol Int* 2012; **12**: 140–146.
- 40 Sasoh M, Tsukitome H, Matsui Y, Furuta M, Kondo M. Bilateral retinal detachment in Werner syndrome. *Retin Cases Brief Rep* 2014; **8**: 92–94.
- 41 Toda N, Ihara K, Takemoto M, Yokote K, Hara T. Endocrine and metabolic abnormalities in a girl with childhood Werner syndrome: case report. *J Am Geriatr Soc* 2014; **62**: 1404–1405.
- 42 Saito T *et al.* A case of Werner syndrome with type 1 diabetes showing insulin resistance. *Folia Endocrinol Jpn* 2014; **90**: 345.
- 43 Takemoto M, Yamaga M, Furuichi Y *et al.* Astaxanthin improves non-alcoholic fatty liver disease in Werner syndrome with diabetes mellitus. *J Am Geriatr Soc* 2015; **63**: 1271–1273 (in Japanese).
- 44 Japan atherosclerosis society (JAS) guidelines for prevention of atherosclerotic cardiovascular diseases 2017. *J Atheroscler Thromb* 2018; **25**: 864–984.
- 45 Hasegawa K, Tsukamoto K, Kunimi M *et al.* Control status of atherosclerotic cardiovascular risk factors among Japanese high-risk subjects: analyses of a Japanese health check database from 2008 to 2011. *J Atheroscler Thromb* 2016; **23**: 991–1003.
- 46 Epstein CJ, Martin GM, Schultz AL *et al.* Werner's syndrome: a review of its symptomatology, natural history, pathologic features, genetics and relationship to the natural aging process. *Medicine (Baltimore)* 1966; **45**: 177–221.
- 47 Yokote K, Mori S, Morosaki N *et al.* Dyslipidemia: a complication of Werner syndrome. *Jpn J Geriatr* 1989; **26**: 455–461 (in Japanese).
- 48 Fiorenza C, Chou S, Mantzoros C. Lipodystrophy: pathophysiology and advances in treatment. *Nat Rev Endocrinol* 2011; **7**: 137–150.
- 49 Stefan N, Schick F, Häring HU. Causes, characteristics, and consequences of metabolically unhealthy Normal weight in humans. *Cell Metab* 2017; **26**: 292–300.
- 50 Stefan N. Causes, consequences, and treatment of metabolically unhealthy fat distribution. *Lancet Diabetes Endocrinol* 2020; **8**: 616–627.
- 51 Mori S, Yokote K, Morisaki N *et al.* Inheritable abnormal lipoprotein metabolism in Werner's syndrome similar to familial hypercholesterolaemia. *Eur J Clin Invest* 1990; **20**: 137–142.
- 52 Mori S, Morisaki N, Saito Y, Yoshida S. Metabolism of acetylated low density lipoproteins by monocyte-derived macrophages from patients with Werner's syndrome. *Arteriosclerosis* 1989; **9**: 644–649.
- 53 Imura H, Nakao Y, Kuzuya H *et al.* Clinical, endocrine and metabolic aspects of the Werner syndrome compared with those of normal aging. *Adv Exp Med Biol* 1985; **190**: 171–185.
- 54 Murata K, Nakashima H. Clinical and metabolic studies on Werner's syndrome: with special reference to disorders of lipid and liver function. *Adv Exp Med Biol* 1985; **190**: 285–304.
- 55 Belfort R, Harrison SA, Brown K *et al.* A placebo-controlled trial of pioglitazone in subjects with nonalcoholic steatohepatitis. *N Engl J Med* 2006; **355**: 2297–2307.
- 56 Aithal GP, Thomas JA, Kaye PV *et al.* Randomized, placebo-controlled trial of pioglitazone in nondiabetic subjects with nonalcoholic steatohepatitis. *Gastroenterology* 2008; **135**: 1176–1184.
- 57 Sanyal AJ, Chalasani N, Kowdley KV *et al.* Pioglitazone, vitamin E, or placebo for nonalcoholic steatohepatitis. *N Engl J Med* 2010; **362**: 1675–1685.
- 58 Leuschner UF, Lindenthal B, Herrmann G *et al.* High-dose ursodeoxycholic acid therapy for nonalcoholic steatohepatitis: a double-blind, randomized, placebo-controlled trial. *Hepatology* 2010; **52**: 472–479.
- 59 Labbé A, Garand C, Cogger VC *et al.* Resveratrol improves insulin resistance hyperglycemia and hepatosteatosis but not hypertriglyceridemia, inflammation, and life span in a mouse model for Werner syndrome. *J Gerontol A Biol Sci Med Sci* 2011; **66**: 264–278.

**How to cite this article:** Tsukamoto K, Takemoto M, Kubota Y, *et al.* Management guideline for Werner syndrome 2020 1. Dyslipidemia and fatty liver associated with Werner syndrome. *Geriatr. Gerontol. Int.* 2020;1–6. <https://doi.org/10.1111/ggi.14095>







## ORIGINAL ARTICLE

## SOCIAL RESEARCH, PLANNING AND PRACTICE

# Management guideline for Werner syndrome 2020.

## 2. Sarcopenia associated with Werner syndrome

Masafumi Kuzuya,<sup>1</sup>  Minoru Takemoto,<sup>2</sup>  Yoshitaka Kubota,<sup>3</sup> Toshibumi Taniguchi,<sup>4</sup> Sei-Ichiro Motegi,<sup>5</sup> Akira Taniguchi,<sup>6</sup> Hironori Nakagami,<sup>7</sup>  Yoshiro Maezawa,<sup>8</sup> Masaya Koshizaka,<sup>8</sup>  Hisaya Kato,<sup>8</sup> Seijiro Mori,<sup>9</sup> Kazuhisa Tsukamoto<sup>10</sup> and Koutaro Yokote<sup>8</sup>

<sup>1</sup>Department of Community Healthcare & Geriatrics, Nagoya University Graduate School of Medicine, Institutes of Innovation for Future Society, Nagoya University, Nagoya, Japan

<sup>2</sup>Department of Diabetes, Metabolism and Endocrinology, School of Medicine, International University of Health and Welfare, Chiba, Japan

<sup>3</sup>Department of Plastic, Reconstructive, and Aesthetic Surgery, Chiba University Graduate School of Medicine, Chiba, Japan

<sup>4</sup>Department of Infectious Diseases, Chiba University Hospital, Chiba, Japan

<sup>5</sup>Department of Dermatology, Gunma University Graduate School of Medicine, Gunma, Japan

<sup>6</sup>Department of Orthopaedic surgery, Nara Medical University, Nara, Japan

<sup>7</sup>Department of Health Development and Medicine, Osaka University Graduate School of Medicine, Osaka, Japan

<sup>8</sup>Department of Endocrinology, Hematology and Gerontology, Chiba University Graduate School of Medicine, Chiba, Japan

<sup>9</sup>Center for the Promotion of Clinical Investigation, Tokyo Metropolitan Geriatric Hospital, Tokyo, Japan

<sup>10</sup>Department of Internal Medicine, Teikyo University School of Medicine, Tokyo, Japan

### Correspondence

Minoru Takemoto, MD, PhD, Department of Diabetes, Metabolism, and Endocrinology, University: School of Medicine, International University of Health and Welfare, 4-3, Kozunomori, Narita, Chiba 286-8686, Japan.

Email: minoru.takemoto@iuhw.ac.jp

Koutaro Yokote, MD, PhD, Department of Endocrinology, Hematology and Gerontology, Chiba University Graduate School of Medicine, 1-8-1 Inohana, Chuo-ku, Chiba 260-8670, Japan.

Email: kyokote@faculty.chiba-u.jp

*Received: 5 October 2020*

*Revised: 14 October 2020*

*Accepted: 19 October 2020*

**Aim:** Sarcopenia is defined as a condition that combines decreased skeletal muscle mass with weakness or decreased physical function. It is well known that in older adults, the presence of sarcopenia is a risk of frailty, falls and physical dysfunction. Patients with Werner syndrome are characterized by visceral fat accumulation and thin limbs, but the prevalence of sarcopenia in patients with Werner syndrome has not been investigated.

**Methods:** A literature search was conducted using Werner syndrome and skeletal muscle as keywords. We also analyzed data from our 7 Werner syndrome patients.

**Results:** A literature search on the relationship between Werner syndrome and skeletal muscle yielded only one article reported from Japan. According to this paper, a decrease in skeletal muscle mass (appendicular skeletal muscle index) was observed in all 9 Werner syndromes investigated. On the other hand, in our 7 Werner syndrome patients, their appendicular skeletal muscle indexes were below the standard value except for one male patient who had continued resistance exercise.

**Conclusion:** The decrease in skeletal muscle mass frequently occurs in patients with Werner syndrome. However, resistance exercise may prevent the appearance of sarcopenia and requires early intervention in patients with Werner syndrome. **Geriatr Gerontol Int 2020;**

••: •••••.

**Keywords:** clinical medicine, Werner syndrome, geriatric medicine, management guideline, others.

## Introduction

Werner syndrome is frequently associated with a decrease in extremity skeletal muscle mass in adults (below the age of 40 years).

Although its contributing factors are still unclear, there are some cases where habitual resistance exercise has prevented a decrease in skeletal muscle mass. Therefore, appropriate intervention with habitual resistance exercise may be a useful preventive measure.

## Sarcopenia

Sarcopenia is characterized by a significant decrease in skeletal muscle mass and muscle weakness or a decline in the physical function with age.<sup>1</sup> It is generally known that the skeletal muscle area decreases by 25–30% and muscle strength by 30–40% by the age of 70 compared with those in the 20s, and muscle mass decreases by about 1–2% every year after the age of 50.<sup>2</sup> The age-related decrease in skeletal muscle mass is caused by a reduction in skeletal muscle fibers and atrophy of each muscle fiber. A decrease in skeletal muscle fibers has been known mainly to represent a reduction in type IIa muscle fibers (fast-twitch fibers, white muscle).<sup>2</sup> Sarcopenia is a term coined from “sarco” denoting “flesh” and “penia” representing “poverty” in Greek.<sup>1,2</sup> Sarcopenia is classified into primary (age-related) sarcopenia caused only by advancing age and secondary sarcopenia marked by decreases in skeletal muscle mass, muscle strength, and physical function associated with inactivity (disuse), diseases (progressive malignancy and organ failure), or malnutrition.<sup>1</sup>

Sarcopenia is known to be associated with risks of falling, physical function impairment, needing nursing care and frailty in the elderly, and this condition has recently been taken seriously in light of care prevention in Japan.<sup>3</sup>

## Sarcopenia in patients with Werner syndrome

A literature search on the relationship between Werner syndrome and skeletal muscle yielded only one article reported from Japan in 2017.<sup>4</sup> According to that report, nine patients with Werner syndrome (four men and five women) with the mean age of  $48 \pm 8.8$  years (range: 39–60 years) underwent a diagnostic test for sarcopenia based on indexes including decreases in the appendicular skeletal muscle mass index and the grip strength using the diagnostic criteria for sarcopenia (appendicular skeletal muscle index obtained by dual-energy X-ray absorptiometry [appendicular skeletal muscle mass, kg/body height,  $m^2$ :  $<7.0$  kg/ $m^2$  [male],  $<5.4$  kg/ $m^2$  [female] and grip strength:  $<26$  kg [male],  $<18$  kg [female])<sup>5</sup> suggested by Asian Working Group for Sarcopenia.

As to the grip strength, two of four male patients did not meet the diagnostic criteria for sarcopenia, whereas none exceeded the cutoff value of appendicular skeletal muscle indexes. The researchers also assessed the accumulation of visceral fat (evaluated by abdominal computed tomography) in the nine patients. An age-adjusted evaluation revealed that the decrease in skeletal muscle mass had been observed before the accumulation of

visceral fats. All had decreased motor functions. The analysis based on the presence or absence of diabetes indicated that patients with Werner syndrome with diabetes had higher body mass indexes and more visceral fat than those without diabetes, while there was no difference in the skeletal muscle index between the two groups.

In our study, the appendicular skeletal muscle index was examined by the bioimpedance method in seven patients with Werner syndrome (four men and three women) with the mean age of  $49.1 \pm 6.8$  years (range, 39–70 years). The results revealed that their appendicular skeletal muscle indexes were below the standard value (the cutoff values of the skeletal muscle indexes obtained by the bioimpedance method suggested by the Asian Working Group for Sarcopenia are  $<7.0$  kg/ $m^2$  for males and  $<5.7$  kg/ $m^2$  for females)<sup>5</sup> except for one male patient. He was 43 years old and had continued resistance exercise with dumbbells and bodyweight squats from his school days.<sup>6</sup>

As described above, age-related sarcopenia is generally associated with a decrease in skeletal muscle fibers (particularly, fast-twitch fibers) and atrophy of each muscle fiber, whereas it is still unclear whether similar changes appear in patients with Werner syndrome, because of the lack of detailed muscle biopsy findings in this patient population. Additionally, sarcopenia is diagnosed by low extremity skeletal muscle mass, as mentioned above, as an obligatory symptom and accompanied by a decline in muscle strength or physical function (e.g., walking speed).<sup>1–3,5</sup> Patients with Werner syndrome are likely to develop refractory plantar ulcers, which makes it impossible to measure their walking speed in some cases. Hand deformity also occurs in some cases, making it difficult to measure grip strength, and thus it is not always easy to make a diagnosis of sarcopenia.

## Discussion

The decrease in skeletal muscle mass, as discussed above, frequently occurs in patients with Werner syndrome before the age of 40. Although the mechanism is still unclear, various potential factors including aged skeletal muscle, metabolic abnormality, and inflammation, or a decreased amount of activity due to low physical function are considered, which are expected in the future progress of the research. On the other hand, a patient with Werner syndrome who was not diagnosed with sarcopenia, as in the above example, has also been observed, suggesting possible prevention of sarcopenia by appropriate intervention (e.g., resistance exercise).

## Disclosure statement

The authors declare no conflict of interest.

## References

- 1 Cruz-Jentoft AJ, Baeyens JP, Bauer JM *et al.* Sarcopenia: European consensus on definition and diagnosis: report of the European Working Group on Sarcopenia in Older People. *Age Ageing* 2010; **39**: 412–423.
- 2 Kuzuya M. Importance of sarcopenia & frailty in geriatrics. *Jpn J Geriatr* 2009; **46**: 279–285. (in Japanese).





- 3 Shimokata H, Shimada H, Satake S, *et al.* Chapter 2 Epidemiology of sarcopenia. *Geriatr Gerontol Int* 2018;**18**:13-22.
- 4 Yamaga M, Takemoto M, Shoji M *et al.* Werner syndrome: a model for sarcopenia due to accelerated aging. *Aging (Albany NY)* 2017; **9**: 1738-1744.
- 5 Chen LK, Liu LK, Woo J *et al.* Sarcopenia in Asia: consensus report of the Asian working group for sarcopenia. *J Am Med Dir Assoc* 2014; **15**: 95-101.
- 6 Kuzuya M, Kuzuya M, Tanaka F. Evaluation of appendicular skeletal muscle mass in 8 Werner syndrome patients. manuscript in preparation.

**How to cite this article:** Kuzuya M, Takemoto M, Kubota Y, *et al.* Management guideline for Werner syndrome 2020. 2. Sarcopenia associated with Werner syndrome. *Geriatr. Gerontol. Int.* 2020;1-3. <https://doi.org/10.1111/ggi.14076>

## ORIGINAL ARTICLE

## SOCIAL RESEARCH, PLANNING AND PRACTICE

# Management guideline for Werner syndrome 2020. 3. Diabetes associated with Werner syndrome

Minoru Takemoto,<sup>1</sup>  Yoshitaka Kubota,<sup>2</sup> Toshibumi Taniguchi,<sup>3</sup> Sei-ichiro Motegi,<sup>4</sup> Akira Taniguchi,<sup>5</sup> Hironori Nakagami,<sup>6</sup>  Yoshiro Maezawa,<sup>7</sup> Masaya Koshizaka,<sup>7</sup>  Hisaya Kato,<sup>7</sup> Kazuhisa Tsukamoto,<sup>8</sup> Seijiro Mori,<sup>9</sup> Masafumi Kuzuya<sup>10</sup>  and Koutaro Yokote<sup>7</sup>

<sup>1</sup>Department of Diabetes, Metabolism and Endocrinology, School of Medicine, International University of Health and Welfare, Chiba, Japan

<sup>2</sup>Department of Plastic, Reconstructive, and Aesthetic Surgery, Chiba University Graduate School of Medicine, Chiba, Japan

<sup>3</sup>Department of Infectious Diseases, Chiba University Hospital, Chiba, Japan

<sup>4</sup>Department of Dermatology, Gunma University Graduate School of Medicine, Gunma, Japan

<sup>5</sup>Department of Orthopaedic Surgery, Nara Medical University, Nara, Japan

<sup>6</sup>Department of Health Development and Medicine, Osaka University Graduate School of Medicine, Osaka, Japan

<sup>7</sup>Department of Endocrinology, Hematology and Gerontology, Chiba University Graduate School of Medicine, Chiba, Japan

<sup>8</sup>Department of Internal Medicine, School of Medicine, Teikyo University, Tokyo, Japan

<sup>9</sup>Center for the Promotion of Clinical Investigation, Tokyo Metropolitan Geriatric Hospital, Tokyo, Japan

<sup>10</sup>Department of Community Healthcare & Geriatrics, Nagoya University Graduate School of Medicine, Institutes of Innovation for Future Society, Nagoya University, Nagoya, Japan

## Correspondence

Dr Minoru Takemoto MD PhD,  
Department of Diabetes, Metabolism,  
and Endocrinology, School of  
Medicine, International University of  
Health and Welfare, 4-3, Kozunomori,  
Narita, Chiba 286-8686, Japan.  
Email: minoru.takemoto@iuhw.ac.jp

Received: 5 October 2020

Revised: 19 October 2020

Accepted: 22 October 2020

**Aims:** To evaluate the characteristics of diabetes associated with Werner syndrome.

**Methods:** A literature search was done with search term “Werner syndrome” and “Diabetes”.

**Results and Conclusions:** Prevalence of diabetes is extremely high in Werner syndrome. Diabetes associated with Werner syndrome is classified as “accompanied with other diseases and conditions and the one occurring mainly in association with other genetic syndromes.” This type of diabetes is marked by accumulated visceral fat and high insulin resistance, despite low body mass index. Thiazolidine derivatives and metformin are effective for glycaemic control. New antidiabetic drugs, such as dipeptidyl peptidase-4 inhibitors and glucagon-like peptide-1 receptor agonists, could be potentially beneficial for patients with Werner syndrome. Furthermore, the establishment of diet therapy as well as exercise therapy is warranted. *Geriatr Gerontol Int* 2020; ••: ••-••.

**Keywords:** clinical medicine, geriatric medicine, others.

## Introduction

Werner syndrome is a disease representing progeria. The clinical finding that is first observed, is loss of the pubertal growth spurt, followed by geriatric symptoms including atrophy and hardening of the skin, partial loss of the subcutaneous fat, changes in hair such as graying and balding, and cataract. Glucose metabolism disorders are also seen at a high rate, making this a typical metabolic disorder in patients with Werner syndrome.<sup>1,2</sup>

Q1. How frequently do patients with Werner syndrome develop diabetes?

A1. Approximately 55% of them develop diabetes.

The review article published by Epstein *et al.* in 1966 indicates that diabetes was observed in 55 (28 males and 27 females) of 125 patients diagnosed with Werner syndrome.<sup>1</sup> In Japan, the results of the research on domestic patients with Werner syndrome were reported by Imura *et al.*, of the Health and Welfare Ministry's specific disease hormone receptor mechanism research group (Etsuro Ogata Group) in 1984. These researchers conducted a questionnaire survey consisting of 1930 questions to domestic hospitals equipped with at least 200 beds, and 181 patients participated in this survey. Furthermore, a glucose tolerance test was conducted in 90 patients, 50 of whom (55.6%) developed diabetes.<sup>3</sup>

Goto reported that about 70% of patients with Werner syndrome developed type 2 diabetes or borderline diabetes based on the results of the literature review from 1966 to 2004.<sup>4</sup> Goto *et al.* further extended the target year of review to 2008 to review the articles by year and reported that the incidence of diabetes in patients with Werner syndrome remained unchanged regardless of year and that the mean age of onset of diabetes was 33.7, 39.7 and 39.3 years in 1966, 2004 and 2008, respectively, which revealed a delay in onset over time.<sup>5</sup>

As a nationwide epidemiological survey in 2011, a questionnaire survey consisting of 6921 questions was conducted in medical institutions with at least 200 beds, through which 396 patients with Werner syndrome were newly confirmed, and clinical

findings of 196 patients were obtained. The results revealed that 55.7% of these patients developed diabetes and 6.5% had borderline diabetes.<sup>6</sup> As described by Goto *et al.*, the incidence of diabetes in patients with Werner syndrome in Japan was comparable with that reported by Imura *et al.* in 1984.

Q2. What type of diabetes do the patients with Werner syndrome develop?

A2. Diabetes associated with Werner syndrome are classified into "one accompanied with other diseases and conditions and one occurring mainly in association with other genetic syndromes." Such diabetes is marked by accumulated visceral fat and high insulin resistance despite low body mass index (BMI).

Epstein *et al.* reported that diabetes occurring in association with Werner syndrome is characterized by a gradual rise in blood sugar levels leading to prolonged hyperglycemia after the glucose tolerance test and less effective insulin therapy for such hyperglycemia despite normal blood sugar levels in many patients with Werner syndrome. His study also indicated that although dead branch-like extremities and fat atrophy are observed in Werner syndrome, fat atrophy is not involved in an onset of diabetes.<sup>1</sup>

According to the report from Imura *et al.*, the researchers measured the serum insulin levels of 53 patients with Werner syndrome in the glucose tolerance test, observing hyperinsulinemia in 33% with basal insulin levels at 20  $\mu\text{U}/\text{mL}$  and overreaction to insulin in 67% with the peak level at the glucose tolerance test showing 200  $\mu\text{U}/\text{mL}$ . They suggested that a decrease in endogenous insulin secretion have been rarely seen and insulin secretion from the pancreatic  $\beta$  cells has been relatively maintained even though insulin resistance is higher in patients with Werner syndrome. The report also indicates pathogenesis of high insulin resistance in which expression of insulin receptors on the erythrocyte surface is not decreased and malfunction of the insulin receptors expressed is associated with higher insulin resistance in the examination using cultivated dermal fibroblasts.<sup>3</sup>

An onset of diabetes generally correlates with obesity (an increase in BMI), whereas BMIs of most patients with Werner

**Table 1** Differences in clinical findings affected by the presence or absence of diabetes

	Non-diabetic	<i>n</i>	Diabetic	<i>n</i>	<i>P</i> value
Age (years)	44 $\pm$ 6.9	5	53 $\pm$ 9.1	4	0.16
25-question GLFS score	40 $\pm$ 31.7	4	43 $\pm$ 18.8	4	0.88
Two-step test value	0.73 $\pm$ 0.49	5	0.60 $\pm$ 0.51	4	0.71
Grip strength (kg)	20.1 $\pm$ 7.1	5	12.5 $\pm$ 5.1	4	0.11
VFA ( $\text{cm}^2$ )	56.1 $\pm$ 43.6	4	142.6 $\pm$ 40.1	3	0.04*
SMI ( $\text{kg}/\text{m}^2$ )	4.2 $\pm$ 0.7	5	3.8 $\pm$ 0.4	3	0.4
BMD (L) (%YAM)	89.4 $\pm$ 13.8	5	83.3 $\pm$ 8.4	3	0.47
BMD (F) (%YAM)	75.3 $\pm$ 4.6	4	61.7 $\pm$ 5.7	3	0.03*
BW (kg)	40.4 $\pm$ 7.5	5	42.9 $\pm$ 6.6	4	0.61
BMI ( $\text{kg}/\text{m}^2$ )	16.2 $\pm$ 1.2	5	18.7 $\pm$ 1.3	4	0.02*
Adiponectin (ng/mL)	6.4 $\pm$ 2.8	4	6.6 $\pm$ 4.1	4	0.95
TNF- $\alpha$ (pg/mL)	1.4 $\pm$ 0.6	4	3.0 $\pm$ 4.3	4	0.51
Leptin (ng/nL)	7.2 $\pm$ 3.6	4	30.0 $\pm$ 16.9	4	0.07

\**P* < 0.05, quoted from Yamaga *et al.*<sup>10</sup>

Data are expressed as mean  $\pm$  standard deviation. Comparisons between the two groups were made using Welch's *t*-test. *P* < 0.05 was considered statistically significant. All statistical analyses were performed using JMP Pro 12 (SAS Institute Japan, Tokyo, Japan).

BMD (F), bone mineral density (femoral neck); BMD (L), bone mineral density (lumbar spine); BMI, body mass index; BW, body weight; GLFS, geriatric locomotive function scale; SMI, skeletal muscle index; TNF, tumor necrosis factor; VFA, visceral fat area; YAM, young adult mean.



syndrome are <22. Yokote *et al.* reported that accumulated visceral fat, low serum adiponectin levels and increases in tumor necrosis factor  $\alpha$  and interleukin-6 were observed in patients with Werner syndrome with diabetes.<sup>7,8</sup> A recent case report has suggested that although it was confirmed in one patient, abnormal glucagon secretion after a food load might be associated with carbohydrate metabolism disorders in patients with Werner syndrome.<sup>9</sup> Recently, the body compositions of Japanese patients with Werner syndrome were examined in detail, and the results revealed that there were no differences in age, sex and skeletal muscle mass between the diabetic ( $n = 4$ ) non-diabetic ( $n = 5$ ) groups, whereas they had a predominantly higher BMI and amount of visceral fat (Table 1).<sup>10</sup> Accordingly, not fats in extremities or atrophy of skeletal muscle but insulin resistance accompanied by accumulated visceral fat is associated with an onset of diabetes in patients with Werner syndrome. Diabetes is generally determined by not only genetic background but also changes in environmental factors. Considering that the rate of diabetes occurring in patients with Werner syndrome remains constant, the development of diabetes in patients with Werner syndrome may be greatly influenced by genetic factors rather than environmental factors.

Q3. What is an effective treatment for diabetes in patients with Werner syndrome?

A3. Thiazolidine derivatives and metformin are effective for glycemic control.

As reported by Epstein *et al.*, insulin treatment for diabetes associated with Werner syndrome lacks efficacy. There have been many reports on the effectiveness of a thiazolidine derivative, an agonist, of peroxisome proliferator-activated receptor  $\gamma$ , an insulin sensitizer.<sup>7,8,11–18</sup> On the other hand, although concerns about the effect of thiazolidine derivatives on the bone and the onset of malignancy have been generally reported, no reports have suggested relationships between thiazolidine derivatives and the bone or the development of malignancy in Werner syndrome, which requires further examination. Other than those described above, use of metformin,<sup>19</sup> dipeptidyl peptidase 4 inhibitors<sup>9,20</sup> and glucagon-like peptide-1 receptor agonists<sup>21</sup> have been reported, although are few in number. In patients with Werner syndrome, not only short stature and low body weight but also a reduction in the skeletal muscle mass early in life has been observed.<sup>10</sup> Although dietary instructions to prevent an increase in visceral fat and a decrease in the skeletal muscle mass may be required, no dietary therapy for diabetes occurring in Werner syndrome has been established, which is one of the important subjects to be examined.

## Discussion

Diabetes is highly prevalent among patients with Werner syndrome. Reportedly, thiazolidine derivatives increase the risks for weight gain and bone fracture, necessitating clinicians to be wary of the prolonged usage of thiazolidine derivatives. In Japan, thiazolidine derivatives had been widely used in the treatment of patients with Werner syndrome because of the reduced prevalence of biguanide owing to its side effects, such as lactic acidemia. With the growing usage of metformin in Japan and the fact that it reportedly exerts favorable effects on metabolism and acts as an anticancer agent, re-evaluation of the efficacy of metformin in the treatment of patients with Werner syndrome is warranted. In our opinion, new antidiabetic drugs, such as dipeptidyl peptidase

4 inhibitor and/or glucagon-like peptide-1 receptor analog, could be potentially beneficial for patients with Werner syndrome. Furthermore, the establishment of not only diet therapy<sup>22</sup> but also exercise therapy for patients with Werner syndrome is warranted in the future.

## Disclosure statement

The authors declare no conflict of interest.

## References

- Epstein CJ, Martin GM, Schultz AL *et al.* Werner's syndrome a review of its symptomatology, natural history, pathologic features, genetics and relationship to the natural aging process. *Medicine* 1966; **45**: 177–221.
- Takemoto M, Mori S, Kuzuya M *et al.* Diagnostic criteria for Werner syndrome based on Japanese nationwide epidemiological survey. *Geriatr Gerontol Int* 2013; **3**: 475–481.
- Ogata E, Hormone Receptor Mechanism of Specific Diseases Research Group, the Ministry of Health, Labor and Welfare. 1984. (In Japanese.)
- Goto M. Hierarchical deterioration of body systems in Werner's syndrome: implications for normal ageing. *Mech Ageing Dev* 1997; **98**: 239–254.
- Goto M, Ishikawa Y, Sugimoto M, Furuichi Y. Werner syndrome: a changing pattern of clinical manifestations in Japan (1917–2008). *Biosci Trends* 2013; **7**: 13–22.
- Okabe E, Takemoto M, Onishi S *et al.* Incidence and characteristics of metabolic disorders and vascular complications in individuals with Werner syndrome in Japan. *J Am Geriatr Soc* 2012; **60**: 997–998.
- Yokote K, Hara K, Mori S, Kadowaki T, Saito Y, Goto M. Dysadipocytokinaemia in Werner syndrome and its recovery by treatment with pioglitazone. *Diabetes care* 2004; **27**: 2562–2563.
- Honjo S, Yokote K, Fujishiro T *et al.* Early amelioration of insulin resistance and reduction of interleukin-6 in Werner syndrome using pioglitazone. *J Am Geriatr Soc* 2008; **56**: 173–174.
- Watanabe K, Kobayashi K, Takemoto M *et al.* Sitagliptin improves postprandial hyperglycemia by inhibiting glucagon secretion in Werner syndrome with diabetes. *Diabetes care* 2013; **36**: e119.
- Yamaga M, Takemoto M, Shoji M *et al.* Werner syndrome: a model for sarcopenia due to accelerated aging. *Aging* 2017; **9**: 1738–1744.
- Takino H, Okuno S, Uotani S *et al.* Increased insulin responsiveness after CS-045 treatment in diabetes associated with Werner's syndrome. *Diabetes Res Clin Pract* 1994; **24**: 167–172.
- Izumino K, Sakamaki H, Ishibashi M *et al.* Troglitazone ameliorates insulin resistance in patients with Werner's syndrome. *J Clin Endocrinol Metab* 1997; **82**: 2391–2395.
- Imano E, Kanda T, Kawamori R, Kajimoto Y, Yamasaki Y. Pioglitazone-reduced insulin resistance in patient with Werner syndrome. *Lancet* 1997; **350**: 1365.
- Yokote K, Honjo S, Kobayashi K *et al.* Metabolic improvement and abdominal fat redistribution in Werner syndrome by pioglitazone. *J Am Geriatr Soc* 2004; **20**: 1582–1583.
- Hattori S, Kasai M, Namatame T, Hattori Y, Kasai K. Pioglitazone treatment of insulin resistance in a patient with Werner's syndrome. *Diabetes care* 2004; **27**: 3021–3022.
- Yamamoto H, Kurebayashi S, Kouhara H *et al.* Impacts of long-term treatments with testosterone replacement and pioglitazone on glucose and lipid metabolism in male patients with Werner's syndrome. *Clin Chim Acta* 2007; **379**: 167–170.
- Furuya M, Kurokawa R, Fujita N *et al.* A case of Werner syndrome diagnosed during treatment of juvenile diabetes. *Folia Endocrinol Jpn* 2011; **87**: 351–351. (In Japanese.)
- Saito T, Shimoda Y, Tagaya Y *et al.* A case of Werner syndrome with type 1 diabetes showing insulin resistance. *Folia Endocrinol Jpn* 2014; **90**: 345–345. (In Japanese.)
- Yasuda H, Nagata M, Hara K, Moriyama H, Yokono K. Biguanide, but not thiazolidinedione, improved insulin resistance in Werner syndrome. *J Am Geriatr Soc* 2010; **58**: 181–182.

- 20 Kitamoto T, Takemoto M, Fujimoto M *et al.* Sitagliptin successfully ameliorates glycemic control in Werner syndrome with diabetes. *Diabetes care* 2012; **35**: e83.
- 21 Ide S, Yamamoto M, Takemoto M *et al.* Improved glycemic control and vascular function and reduction of abdominal fat accumulation with liraglutide in a case of Werner syndrome with diabetes mellitus. *J Am Geriatr Soc* 2016; **64**: 687–688.
- 22 Yamamoto R, Akasaki K, Horita M *et al.* Evaluation of glucose tolerance and effect of dietary management on increased visceral fat in a patient with Werner syndrome. *Endocr J* 2020. <https://doi.org/10.1507/endocrj.EJ20-0304>.




**How to cite this article:** Takemoto M, Kubota Y, Taniguchi T, et al. Management guideline for Werner syndrome 2020. 3. Diabetes associated with Werner syndrome. *Geriatr. Gerontol. Int.* 2020;1–4. <https://doi.org/10.1111/ggi.14083>

## ORIGINAL ARTICLE

## EPIDEMIOLOGY, CLINICAL PRACTICE AND HEALTH

# Management guideline for Werner syndrome 2020.

## 4. Osteoporosis associated with Werner syndrome

Seijiro Mori,<sup>1</sup> Minoru Takemoto,<sup>2</sup>  Yoshitaka Kubota,<sup>3</sup> Toshibumi Taniguchi,<sup>4</sup> Sei-ichiro Motegi,<sup>5</sup> Akira Taniguchi,<sup>6</sup> Hironori Nakagami,<sup>7</sup>  Yoshiro Maezawa,<sup>8</sup> Masaya Koshizaka,<sup>8</sup>  Hisaya Kato,<sup>8</sup> Kazuhisa Tsukamoto,<sup>9</sup> Masafumi Kuzuya<sup>10</sup> and Koutaro Yokote<sup>8</sup>

<sup>1</sup>Center for the Promotion of Clinical Investigation, Tokyo Metropolitan Geriatric Hospital, Tokyo, Japan

<sup>2</sup>Department of Diabetes, Metabolism and Endocrinology, School of Medicine, International University of Health and Welfare, Chiba, Japan

<sup>3</sup>Department of Plastic, Reconstructive, and Aesthetic Surgery, Chiba University Graduate School of Medicine, Chiba, Japan

<sup>4</sup>Department of Infectious Diseases, Chiba University Hospital, Chiba, Japan

<sup>5</sup>Department of Dermatology, Gunma University Graduate School of Medicine, Maebashi, Japan

<sup>6</sup>Department of Orthopaedic Surgery, Nara Medical University, Nara, Japan

<sup>7</sup>Department of Health Development and Medicine, Osaka University Graduate School of Medicine, Osaka, Japan

<sup>8</sup>Department of Endocrinology, Hematology and Gerontology, Chiba University Graduate School of Medicine, Chiba, Japan

<sup>9</sup>Department of Internal Medicine, School of Medicine, Teikyo University, Tokyo, Japan

<sup>10</sup>Department of Community Healthcare & Geriatrics, Nagoya University Graduate School of Medicine, Institutes of Innovation for Future Society, Nagoya University, Nagoya, Japan

### Correspondence

Minoru Takemoto, MD, PhD, Department of Diabetes, Metabolism, and Endocrinology, University School of Medicine, International University of Health and Welfare, 4-3, Kozunomori, Narita, Chiba 286-8686, Japan.

Email: minoru.takemoto@iuhw.ac.jp

Koutaro Yokote, MD, PhD, Department of Endocrinology, Hematology and Gerontology, Chiba University Graduate School of Medicine, 1-8-1 Inohana, Chuo-ku, Chiba 260-8670, Japan.

Email: kyokote@faculty.chiba-u.jp

Received: 5 October 2020

Revised: 14 October 2020

Accepted: 19 October 2020

**Keywords:** osteoporosis, Werner syndrome.

CQ1. What percentage of patients with Werner syndrome develops osteoporosis and which site does osteoporosis appear more commonly?

A1. Osteoporosis has been observed in approximately 41% of these patients. It is likely to be more severe in the femur than in the lumbar spine.

Werner syndrome is a typical genetic progeroid syndrome characterized by pathological conditions similar to age-related various changes that present early in life. Among them, osteoporosis is a characteristic sign of premature aging observed in patients with Werner syndrome.

According to a report summarizing clinical characteristics of 24 patients with Werner syndrome by Murata and Nakashima,<sup>1</sup> the radiographs showed osteoporosis in nine of 24 patients. Although osteoporosis was relatively rare in younger patients, almost all patients at least 40 years of age developed osteoporosis,

with its degree being more severe in the lower extremities. Their review of the Japanese medical literature revealed that osteoporosis occurred in 41% of 153 patients with Werner syndrome reported in Japan.

As the above report by Murata and Nakashima was made before bone densitometry (using dual energy X-ray absorptiometry) had become generalized, it was unclear whether the incidence of osteoporosis in patients with Werner syndrome using the current diagnostic criteria for primary osteoporosis<sup>2</sup> was as high as that reported in previous studies. Therefore, a more detailed assessment of osteoporosis was made in 10 patients with Werner syndrome visiting Chiba University Hospital.<sup>3</sup> As shown in Table 1, the patients consisted of five men and five women. Werner syndrome was diagnosed by genetic testing using DNAs extracted from peripheral blood leukocyte as well as the characteristic clinical signs (Table 1). Bone density was measured by dual

**Table 1** Bone density in 10 patients with Werner syndrome

Case	Sex	Age	WRN mutation	Bone density in the lumbar spine (L <sub>2-4</sub> )			Bone density in the femoral neck		
				g/cm <sup>2</sup>	T-score SD	%YAM	g/cm <sup>2</sup>	T-score SD	%YAM
1	M	57	6/6	0.730	-2.7 <sup>†</sup>	70 <sup>‡</sup>	0.601	-2.1	70 <sup>‡</sup>
2	F	60	6/6	0.804	-2.1	78	0.452	-3.1 <sup>†</sup>	57 <sup>‡</sup>
3	F	57	4/6	0.790	-1.9	78	0.351	-4.0 <sup>†</sup>	45 <sup>‡</sup>
4	M	40	4/11	1.116	0.6	107	—	—	—
5	F	60	4/4	0.803	-1.8	79	0.533	-2.3	68 <sup>‡</sup>
6	F	40	11/11	0.983	-0.2	97	0.582	-1.9	74
7	M	51	4/7	0.971	-0.6	93	0.508	-2.8 <sup>†</sup>	59 <sup>‡</sup>
8	F	42	4/4	0.892	-1.0	88	0.598	-1.7	76
9	M	43	4/4	0.890	-1.3	85	0.697	-1.3	81
10	M	53	4/-	0.901	-1.1	85	0.606	-2.0	70 <sup>‡</sup>

<sup>†</sup>T-score  $\leq$  -2.5.

<sup>‡</sup>YAM  $\leq$  70%.

YAM, young adult mean value.

**Table 2** Association between the WRN gene polymorphism (rs2230009, 340G>A) and femur fractures

Factor	Odds ratio (95% CI)	P
Genotype: AA/AG vs. GG	2.528 (1.194–5.350)	0.0154
Sex: women vs. men	2.983 (1.988–4.776)	<0.0001
Age at autopsy (every 10-year increase in age)	1.746 (1.396–2.185)	<0.0001

CI, confidence interval.

energy X-ray absorptiometry, and  $\leq$ 70% of the young adult mean value or T-score of  $\leq$ -2.5 SD was defined as osteoporosis. Osteoporosis was diagnosed by evaluation of the lumbar spine bone density in only case 1. Spine radiographs had positive findings in six patients but with no specific osteoporosis-related fragility fractures. In contrast, osteoporosis was identified in six patients (cases 1, 2, 3, 5, 7 and 10) when assessed by the bone density of the femoral neck. The above results suggested that osteoporosis accompanied by Werner syndrome is more severe in the femur than in the lumbar spine.

CQ.2 Has the pathogenesis of osteoporosis been elucidated?

A2. It is considered that osteoporosis occurs because bone formation is inhibited while bone resorption is normal in Werner syndrome.

Osteoporosis has long been considered to be caused by the imbalance between osteogenesis by osteoblasts and bone resorption by osteoclasts. For example, hyperfunction of osteoclasts mainly due to a decrease in estrogen levels has been known to be involved in the development of typical postmenopausal osteoporosis. From this perspective, Rubin *et al.*, have reported examination results related to the pathogenesis of osteoporosis in patients with Werner syndrome.<sup>4</sup>

The researchers examined osteoporosis in a 43-year-old white female patient. The spine radiograph showed fragility compression fractures in almost all thoracolumbar spines. Her bone density stood at 0.776 g/cm<sup>2</sup> in the lumbar spine and 0.441 g/cm<sup>2</sup> in the femoral neck, which was equivalent to -2.38 and -3.93 SD, respectively, compared with the mean values in women of the same age. Hematological parameters were unremarkable, except for insulin-like growth factor-1 (IGF-1), which showed a low level

of 86 ng/mL (normal range for age: 142–389 ng/mL). However, the basal serum growth hormone level was within the normal range, and the load tests using arginine and L-dopa showed a normal somatotropin secretory response pattern. The iliac bone of the patient was also biopsied, which showed low cortical bone mass and thinning of the cortical bone. More important findings included a significant decrease in the osteoid mass and absence of osteoblasts in sampled tissues. To sum up these findings, it was considered that while bone resorption was normal, osteogenesis was inhibited in patients with Werner syndrome.

Furthermore, Rubin *et al.*, reported results obtained when Werner syndrome was treated with IGF-1.<sup>5</sup> They measured changes in bone density and the bone metabolism marker of patients with Werner syndrome with osteoporosis before and after daily subcutaneous injection of recombinant human IGF-1 for 6 months. Serum type I procollagen C-peptide and serum osteocalcin, the osteogenesis markers, had increased, while urinary pyridinoline crosslinked products and urinary hydroxyproline, the bone resorption markers, had also risen during the treatment. The post-treatment bone density of the lumbar spine increased by 3%, showing an increment exceeding a variation coefficient in the testing. Given these results, they concluded that supplementation of IGF-1 might possibly relieve inhibition of osteogenesis in patients with Werner syndrome with osteoporosis displaying low IGF-1 levels.

Generally, age-related osteoporosis occurs more commonly in the bony skeleton, including proximal sites of the vertebra and the femur, whereas osteoporosis in Werner syndrome tends to be more severe in the distal extremities, particularly in the lower extremities. As arthrogyposis associated with dermal sclerosis in the lower extremities or ulcerative lesions in the foot region often occur in Werner syndrome, the bones of the lower limbs are susceptible to disuse and inflammatory changes. This is considered one reason why osteoporosis in Werner syndrome tends to be more severe in the lower extremities.

CQ3. Is osteoporosis related with WRN gene polymorphism?

A3. Research results showing the relation between the WRN gene polymorphism and osteoporosis suggested that genetic factors might also be involved in osteoporosis associated with Werner syndrome.

Osteoporosis is included as one of the premature aging signs in Werner syndrome, which, however, does not immediately indicate a direct relationship between a genetic abnormality causing Werner syndrome and the bone metabolism. Werner helicase, a

**Table 3** Association between the *WRN* gene polymorphism (rs2230009, 340G>A) and each clinical indicator

	GG (n = 236)		AG (n = 15)		Difference (95% CI)	P
	Mean	SD	Mean	SD		
Age (years)	70.9	8.09	71.7	6.83	0.76 (-3.43-4.94)	0.724
Body weight (kg)	48.0	6.81	44.7	5.00	-3.33 (-6.97-0.32)	0.074
Body height (m)	150	11.4	140	38.5	-11.2 (-32.6-10.1)	0.279
Body mass index (kg/m <sup>2</sup> )	21.0	2.88	20.1	2.51	-0.92 (-2.46-0.61)	0.240
Muscle mass in extremities (kg)	12.7	1.52	12.4	1.48	-0.24 (-1.18-0.71)	0.620
Skeletal muscle mass index (kg/m <sup>2</sup> )	5.51	0.54	5.55	0.52	0.03 (-0.31-0.37)	0.850
Bone density in the lumbar spine (g/cm <sup>2</sup> )	0.79	0.14	0.73	0.17	-0.07 (-0.14-0.00)	0.068
Bone density in the femoral neck (g/cm <sup>2</sup> )	0.63	0.08	0.59	0.08	-0.04 (-0.08 - -0.00)	0.041*
Serum calcium (mg/dL)	9.65	0.41	9.53	0.31	-0.12 (-0.33-0.09)	0.270
Serum 25-OH vitamin D (ng/mL)	21.5	6.45	19.4	5.15	-2.02 (-5.35-1.30)	0.230

\**P* < 0.05.

CI, confidence interval; SD, standard deviation.

product of the gene responsible for Werner syndrome, has been considered to play a role mainly in the DNA repair process. It has been observed that the *WRN* gene is expressed in human dermal fibroblasts,<sup>6</sup> whereas it has not been confirmed whether it is expressed in osteoblasts or osteoclasts, leading to difficulty in inferring a functional relationship between the *WRN* gene and bone metabolism. Lately, research providing a new insight concerning this topic has been reported.

It has been known that there are single nucleotide polymorphisms at eight positions in the *WRN* gene: four of them involve amino acid substitution, while the other four do not.<sup>7</sup> Some researchers have already reported examination results of a relationship particularly with rs1346044 (T>C, Cys1367Arg), i.e., a polymorphism with the 1367th cysteine residue being replaced with an arginine residue, and osteoporosis.<sup>8</sup> They examined 377 healthy postmenopausal women with a mean age of 65.6 years. The genotype frequencies were 87.5% for T/T, 12.2% for T/C and 0.3% for C/C. The subjects were classified into two groups of non-carriers of C (T/T) and carriers of C (T/C and C/C) for comparison, which resulted in the carriers of C having significantly low bone density in the lumbar spine (*P* = 0.037).

We also conducted genotyping of rs2230009 (340G>A, V114I) of the *WRN* gene to examine the association with the prevalence of femoral fracture using DNAs obtained from 1632 consecutive autopsy cases (mean age: 81; 924 men and 708 women) in Tokyo Metropolitan Geriatric Hospital.<sup>9</sup> Table 2 shows the results of multiple logistic regression analysis adjusted for sex and age. The odds ratio of femoral fracture in rs2230009 with the AA or AG genotype was significantly high, standing at 2.528 times as frequently as that with the GG genotype. In addition, the study found that the above odds ratio in women was 2.983 times as high as that in men, and a risk of femoral fracture increased by 1.746 times for every 10-year increase in age. Furthermore, we performed validation of rs2230009 that was found to have a significant association with the femoral fracture by analyzing its relationship with the bone density using DNAs taken from 251 patients with postmenopausal osteoporosis (mean age: 71 years) in Tokyo Metropolitan Geriatric Hospital.<sup>9</sup> Table 3 shows the relationship between the genotype of rs2230009 and each clinical indicator in these patients. A Student's *t*-test was employed for age, body weight and body height, and a linear regression analysis (adjusted for age) for the others to conduct a significance test. Therefore, it revealed that the AG genotype had a significantly lower bone density in the femoral neck than did the GG genotype.

The results obtained from a series of studies on the association between the *WRN* gene polymorphism and osteoporosis suggests

genetic factors are potentially involved in the onset of osteoporosis associated with Werner syndrome.

CQ4. How should osteoporosis in patients with Werner syndrome be treated?

A4. No clear evidence to date regarding treatment for osteoporosis associated with Werner syndrome has been found at present, and thus it is considered appropriate to treat osteoporosis according to the guidelines for the treatment of osteoporosis.<sup>10</sup>

As a typical drug to decrease the risk of osteoporosis-related fractures, bisphosphonates have been widely used. A report indicated that etidronate, one of the bisphosphonates, has ameliorated painful soft tissue calcification,<sup>11</sup> which provides a helpful perspective to select drugs. On the other hand, there has been a report suggesting that osteoporosis in Werner syndrome is caused mainly by inhibition of osteogenesis, for which parathyroid hormone (teriparatide) is considered effective. As sarcoma frequently develops in patients with Werner syndrome, the use of parathyroid hormone requires special attention to the development of osteosarcoma.

## Discussion

Werner syndrome is often accompanied by osteoporosis. Age-related osteoporosis generally occurs more commonly in the bony skeleton including proximal sites of the vertebra and the femur, whereas osteoporosis is more severe in the distal extremities, particularly in the lower extremities in patients with Werner syndrome. As arthrogyrosis is associated with dermal sclerosis in the lower extremities or ulcerative lesions in the foot region occur in patients with Werner syndrome, the bones of the lower limbs are easily influenced by disuse and inflammatory changes. These are considered one of the reasons that osteoporosis associated with Werner syndrome may become more severe in the lower extremities. On the other hand, the research results indicating the association between *WRN* gene polymorphism and osteoporosis have also been reported, suggesting that an onset of osteoporosis might be genetically promoted in Werner syndrome.

As no specific evidence has been found to date regarding treatment for osteoporosis associated with Werner syndrome, it is considered appropriate to follow conventional treatment for this bone disease. Given that disuse may possibly be involved in the pathogenesis of osteoporosis, prevention against disuse through active rehabilitation is also important.



## Disclosure statement

The authors declare no conflict of interest.

## References




- 1 Murata K, Nakashima H. Werner's syndrome: twenty-four cases with a review of the Japanese medical literature. *J Am Geriatr Soc* 1982; **30**: 303–308.
- 2 Soen S, Fukunaga M, Sugimoto T *et al.* Diagnostic criteria for primary osteoporosis: year 2012 revision. *J Bone Miner Metab* 2013; **31**: 247–257.
- 3 Mori S, Zhou H, Yamaga M, Takemoto M, Yokote K. Femoral osteoporosis is more common than lumbar osteoporosis in patients with Werner syndrome. *Geriatr Gerontol Int* 2017; **17**: 854–856.
- 4 Rubin CD, Zerwekh JE, Reed-Gitomer BY *et al.* Characterization of osteoporosis in a patient with Werner's syndrome. *J Am Geriatr Soc* 1992; **40**: 1161–1163.
- 5 Rubin CD, Reed B, Sakhaee K, Pak CY. Treating a patient with the Werner syndrome and osteoporosis using recombinant human insulin-like growth factor. *Ann Intern Med* 1994; **121**: 665–668.
- 6 Hatamochi A, Arakawa M, Takeda K, Ueki H. Activation of fibroblast proliferation by Werner's syndrome fibroblast-conditioned medium. *J Dermatol Sci* 1994; **7**: 210–216.
- 7 Castro E, Ogburn CE, Hunt KE *et al.* Polymorphisms at the Werner locus: I. Newly identified polymorphisms, ethnic variability of 1367Cys/Arg, and its stability in a population of Finnish centenarians. *Am J Med Genet* 1999; **82**: 399–403.
- 8 Ogata N, Shiraki M, Hosoi T, Koshizuka Y, Nakamura K, Kawaguchi H. A polymorphic variant at the Werner helicase (WRN) gene is associated with bone density, but not spondylosis, in postmenopausal women. *J Bone Miner Metab* 2001; **19**: 296–301.
- 9 Zhou H, Mori S, Tanaka M *et al.* A missense single nucleotide polymorphism, V114I of the Werner syndrome gene, is associated with risk of osteoporosis and femoral fracture in the Japanese population. *J Bone Miner Metab* 2015; **33**: 694–700.
- 10 Orimo H, Osteoporosis Prevention and Treatment Guideline 2015 Edition (in Japanese)., Committee for making Osteoporosis Prevention and Treatment Guidelines (edit), Life Science Publishing Co., Ltd, pp. 53–123. 2015.
- 11 Honjo S, Yokote K, Takada A *et al.* Etidronate ameliorates painful soft-tissue calcification in Werner syndrome. *J Am Geriatr Soc* 2005; **53**: 2038–2039.

**How to cite this article:** Mori S, Takemoto M, Kubota Y, *et al.* Management guideline for Werner syndrome 2020. 4. Osteoporosis associated with Werner syndrome. *Geriatr. Gerontol. Int.* 2020;1–4. <https://doi.org/10.1111/ggi.14078>

## ORIGINAL ARTICLE

## SOCIAL RESEARCH, PLANNING AND PRACTICE

# Management guideline for Werner syndrome 2020. 5. Infection associated with Werner syndrome

Toshibumi Taniguchi,<sup>1</sup> Minoru Takemoto,<sup>2</sup>  Yoshitaka Kubota,<sup>3</sup> Sei-ichiro Motegi,<sup>4</sup> Akira Taniguchi,<sup>5</sup> Hironori Nakagami,<sup>6</sup>  Yoshiro Maezawa,<sup>7</sup> Masaya Koshizaka,<sup>7</sup>  Hisaya Kato,<sup>7</sup> Seiji Mori,<sup>8</sup> Kazuhisa Tsukamoto,<sup>9</sup> Masafumi Kuzuya<sup>10</sup> and Koutaro Yokote<sup>7</sup>

<sup>1</sup>Department of Infectious Diseases, Chiba University Hospital, Chiba, Japan

<sup>2</sup>Department of Diabetes, Metabolism and Endocrinology, School of Medicine, International University of Health and Welfare, Chiba, Japan

<sup>3</sup>Department of Plastic, Reconstructive, and Aesthetic Surgery, Chiba University Graduate School of Medicine, Chiba, Japan

<sup>4</sup>Department of Dermatology, Gunma University Graduate School of Medicine, Maebashi, Japan

<sup>5</sup>Department of Orthopaedic Surgery, Nara Medical University, Nara, Japan

<sup>6</sup>Department of Health Development and Medicine, Osaka University Graduate School of Medicine, Osaka, Japan

<sup>7</sup>Department of Endocrinology, Hematology and Gerontology, Chiba University Graduate School of Medicine, Chiba, Japan

<sup>8</sup>Center for the Promotion of Clinical Investigation, Tokyo Metropolitan Geriatric Hospital, Tokyo, Japan

<sup>9</sup>Department of Internal Medicine, School of Medicine, Teikyo University, Tokyo, Japan

<sup>10</sup>Department of Community Healthcare & Geriatrics, Nagoya University Graduate School of Medicine, Institutes of Innovation for Future Society, Nagoya University, Nagoya, Japan

## Correspondence

Dr. Minoru Takemoto, MD, PhD, Department of Diabetes, Metabolism, and Endocrinology, School of Medicine, International University of Health and Welfare, 4-3, Kozunomori, Narita, Chiba 286-8686, Japan.

Email: minoru.takemoto@iuhw.ac.jp

Koutaro Yokote, MD, PhD, Department of Endocrinology, Hematology and Gerontology, Chiba University Graduate School of Medicine, 1-8-1 Inohana, Chuo-ku, Chiba 260-8670, Japan.

Email: kyokote@faculty.chiba-u.jp

Received: 5 October 2020

Accepted: 8 October 2020

**Keywords:** Infection, Werner syndrome.

## Introduction

Werner syndrome is characterized by symptoms such as atrophy of subcutaneous tissues, decreased blood flow<sup>1</sup> and lower activity of fibroblast cells<sup>2</sup> due to metabolic disorders in connective tissues,<sup>3</sup> which may easily cause refractory skin ulcers.<sup>4</sup> Furthermore, it may occur with type 2 diabetes,<sup>5</sup> which is likely to cause skin and soft tissue infections and osteomyelitis at an ulcer site. Generally, such symptoms may often become more severe than in patients with diabetes, leading to failure of conservative treatment and necessitating surgical excision of the infected site. It is considered that the goal to treat an infection caused by refractory skin ulcers in patients with Werner syndrome is to minimize exacerbation of the ulcerated skin lesion by detecting signs of infection early and treating it.

## Treatment guidelines for infections in dermal ulcers

The bacterial etiology of skin ulcers in Werner syndrome is nearly identical to that observed in a diabetic foot infection. However,

skin ulcers are poorly healed in patients with Werner syndrome compared with those of patients with diabetes, thereby raising a risk of long-term and chronic infection. Prolonged infection could cause the emergence of a drug-resistant strain, resulting in a limited choice of antimicrobials capable of treating the lesion. Therefore, it is important to identify the bacterial etiology causing an infection in the skin ulcer and treat with an effective antimicrobial. For poorly controlled infection, debridement and surgical excision are needed at an appropriate time. Thus it is essential to work with plastic surgeons and orthopedists.

## Laboratory examination and diagnosis

When treating diabetic foot infections, we recommend a microbiological diagnostic method. To assess the severity of a diabetic foot infection, it is recommended by the Infectious Diseases Society of America (IDSA) to collect samples in the following way.<sup>6</sup>

1. Clean area of the wound, perform debridement and biopsy a deep tissue or take samples by curettage.

**Table 1** Examples of antimicrobials for mild or long-term/chronic cases

Antimicrobial drug <sup>†</sup>	Comments
Oral administration of cephalexin (500 mg) every 6 h	Covers Gram-positive bacteria
Oral administration of amoxicillin (250 mg)/clavulanate (125 mg) + amoxicillin (250 mg) every 8 h	Cover anaerobic bacteria
Oral administration of two sulfamethoxazole (400 mg)/trimethoprim (80 mg) Tablets every 12 h	Cover MRSA
Oral administration of minocycline (100 mg) every 12 h	Covers MRSA
Oral administration of clindamycin (300 mg) every 8 h	Covers anaerobic bacteria and some MRSA
Oral administration of levofloxacin (500 mg) every 24 h	Covers <i>Pseudomonas aeruginosa</i> . Often used in combination with clindamycin

MRSA, methicillin-resistant *Staphylococcus aureus*.

<sup>†</sup>Dosage and dose regimen need to be adjusted according to renal function.

**Table 2** Examples of antimicrobials for moderate to severe cases

Antimicrobial drug <sup>†</sup>	Comments
Intravenous injection of 3 g of ampicillin/sulbactam every 6 h	Covers Gram-positive bacteria and anaerobic bacteria First-line drug in cases of no drug-resistant strains
Intravenous injection of 4.5 g of piperacillin/tazobactam every 6 h	Covers Gram-positive bacteria, anaerobic bacteria and <i>Pseudomonas aeruginosa</i>
Intravenous injection of 2 g of cefepime every 12 h and 500 mg of metronidazole every 8 h	Covers drug-resistant Gram-negative bacteria except <i>Pseudomonas aeruginosa</i> as well
Intravenous injection of 1 g of meropenem every 8 h	Covers ESBL-producing Gram-negative bacteria and anaerobic bacteria as well
Vancomycin <sup>‡</sup>	Covers Gram-positive bacteria and MRSA
Daptomycin <sup>§</sup>	Covers Gram-positive bacteria and MRSA In cases where vancomycin cannot be used

ESBL, extended spectrum beta lactamase; MRSA, methicillin-resistant *Staphylococcus aureus*.

<sup>†</sup>Dosage and dose regimen need to be adjusted according to renal function.

<sup>‡</sup>Dosage and frequency based on body weight and drug blood level.

<sup>§</sup>Dosage and frequency based on body weight.

2. Puncture fluid of purulent discharge.
3. Obtain bone biopsy tissue in cases of suspected osteomyelitis.

When a sample is obtained from a wound without clinical symptoms of infection (obtained from an area of the wound without debridement, or obtained simply by swabbing an area of the wound), normal bacterial flora, which may not be the cause of infection can be detected, which poses the risk of administering unnecessary broad-spectrum antimicrobials. In cases of a deep ulcerated lesion with a symptom of infection, a Probe to Bone test (to check whether a probe inserted into the lesion reaches the bone) is performed.<sup>7</sup> If the bone is exposed, osteomyelitis is suspected, which necessitates a culture from biopsied bone tissue.<sup>8</sup>

## Selection of therapeutic drugs

As with treatment for diabetic foot infection, a skin and soft tissue infection occurring with an ulcerated lesion in Werner syndrome is treated by targeting Gram-positive bacteria, which includes *Streptococcus* spp. and *Staphylococcus aureus*.<sup>9</sup> To determine if any other bacteria should be covered, the following four items should be checked.

1. Risk of methicillin-resistant *S. aureus*.
2. History of antimicrobial use within a month; if present, Gram-negative bacteria need to be covered.
3. Risk of *Pseudomonas* infection.
4. Determination of the severity.

Example of antimicrobials for (i) mild or long-term/chronic, and (ii) moderate to severe cases are shown in Tables 1 and 2 respectively.

## Treatment duration

The goal of treatment is to ameliorate symptoms of infection (red flare, pain and swelling). Treatment duration corresponds to that for diabetes foot infection,<sup>6</sup> but if the infected skin tissue is poorly healed, it should be determined on a case-by-case basis.

## Disclosure statement

The authors declare no conflict of interest.

## References

- 1 Okabe E, Takemoto M, Onishi S *et al.* Incidence and characteristics of metabolic disorders and vascular complications in individuals with Werner syndrome in Japan. *J Am Geriatr Soc* 2012; **60**: 997–998.
- 2 Hatamochi A, Arakawa M, Takeda K, Ueki H. Activation of fibroblast proliferation by Werner's syndrome fibroblast-conditioned medium. *J Dermatol Sci* 1994; **7**: 210–216.
- 3 Muftuoglu M, Oshima J, von Kobbe C, Cheng WH, Leistriz DF, Bohr VA. The clinical characteristics of Werner syndrome: molecular and biochemical diagnosis. *Hum Genet* 2008; **124**: 369–377.
- 4 Yeong EK, Yang CC. Chronic leg ulcers in Werner's syndrome. *Br J Plast Surg* 2004; **57**: 86–88.
- 5 Goto M, Matsuura M. Secular trends towards delayed onsets of pathologies and prolonged longevities in Japanese patients with Werner syndrome. *Biosci Trends* 2008; **2**: 81–87.
- 6 Lipsky BA, Berendt AR, Cornia PB *et al.* 2012 Infectious Diseases Society of America clinical practice guideline for the diagnosis and




- treatment of diabetic foot infections. *Clin Infect Dis* 2012; **54**: e132–e173.
- 7 Grayson ML, Gibbons GW, Balogh K, Levin E, Karchmer AW. Probing to bone in infected pedal ulcers. A clinical sign of underlying osteomyelitis in diabetic patients. *JAMA* 1995; **273**: 721–723.
  - 8 Elamurugan TP, Jagdish S, Kate V, Chandra Parija S. Role of bone biopsy specimen culture in the management of diabetic foot osteomyelitis. *Int J Surg* 2011; **9**: 214–216.
  - 9 Lipsky BA, Pecoraro RE, Larson SA, Hanley ME, Ahroni JH. Outpatient management of uncomplicated lower-extremity infections in diabetic patients. *Arch Intern Med* 1990; **150**: 790–797.

**How to cite this article:** Taniguchi T, Takemoto M, Kubota Y, et al. Management guideline for Werner syndrome 2020. 5. Infection associated with Werner syndrome. *Geriatr. Gerontol. Int.* 2020;1–3. <https://doi.org/10.1111/ggi.14073>

## ORIGINAL ARTICLE

## EPIDEMIOLOGY, CLINICAL PRACTICE AND HEALTH

# Management guideline for Werner syndrome 2020. 6. Skin ulcers associated with Werner syndrome: Prevention and non-surgical and surgical treatment

Yoshitaka Kubota,<sup>1</sup> Minoru Takemoto,<sup>2</sup>  Toshibumi Taniguchi,<sup>3</sup> Sei-ichiro Motegi,<sup>4</sup> Akira Taniguchi,<sup>5</sup> Hironori Nakagami,<sup>6</sup>  Yoshiro Maezawa,<sup>7</sup> Masaya Koshizaka,<sup>7</sup>  Hisaya Kato,<sup>7</sup> Seiji Mori,<sup>8</sup> Kazuhisa Tsukamoto,<sup>9</sup> Masafumi Kuzuya<sup>10</sup> and Koutaro Yokote<sup>7</sup>

<sup>1</sup>Department of Plastic, Reconstructive, and Aesthetic Surgery, Chiba University Graduate School of Medicine, Chiba, Japan

<sup>2</sup>Department of Diabetes, Metabolism and Endocrinology, School of Medicine, International University of Health and Welfare, Chiba, Japan

<sup>3</sup>Department of Infectious Diseases, Chiba University Hospital, Chiba, Japan

<sup>4</sup>Department of Dermatology, Gunma University Graduate School of Medicine, Maebashi, Japan

<sup>5</sup>Department of Orthopaedic Surgery, Nara Medical University, Nara, Japan

<sup>6</sup>Department of Health Development and Medicine, Osaka University Graduate School of Medicine, Osaka, Japan

<sup>7</sup>Department of Endocrinology, Hematology and Gerontology, Chiba University Graduate School of Medicine, Chiba, Japan

<sup>8</sup>Center for the Promotion of Clinical Investigation, Tokyo Metropolitan Geriatric Hospital, Tokyo, Japan

<sup>9</sup>Department of Internal Medicine, Teikyo University School of Medicine, Tokyo, Japan

<sup>10</sup>Department of Community Healthcare & Geriatrics, Nagoya University Graduate School of Medicine, Institutes of Innovation for Future Society, Nagoya University, Nagoya, Japan

**Aim:** To provide guidelines on the diagnosis, treatment, and prevention of skin ulcers in Werner syndrome.

**Methods:** This article was based on literature from 1996, when WRN was identified as a gene responsible for Werner syndrome, and we evaluated several authentic clinical cases of genetically diagnosed patients. There were 63 patients with Werner syndrome in the Japanese reports retrieved from Medical Online between January 1996 and December 2017. There were 56 patients with Werner syndrome in English reports written by Japanese authors and retrieved from PubMed during the same period.

**Results:** Records on skin ulcers were found in 27 (43%) out of 63 patients and 22 (40%) out of 56 patients from the Japanese and English reports, respectively. The reported ulcers were often located at the distal one-third of the lower legs. There were 8 patients with callosities in the foot in the Japanese reports and 9 patients in the English reports. A skin ulcer in Werner syndrome is generally intractable. Weight-bearing ulcers or callosity should be critically assessed in surgical procedures because they have effects on patient pain and gait. By adopting a recently advanced technique to facilitate wound healing, the cases of ulcers that were difficult to treat and those requiring major operations can be closed with minimally invasive surgery.

**Conclusions:** Skin ulcers in Werner syndrome are refractory, and they lead to reduced quality of life of patients. A callosity in Werner syndrome is an important therapeutic target for the prevention of ulcers. *Geriatr Gerontol Int* 2020; ●●: ●●–●●.

**Keywords:** callosities, foot ulcer, osteomyelitis, shoes, werner syndrome.

**Correspondence**

Minoru Takemoto, MD, PhD,



Department of Diabetes,  
Metabolism, and Endocrinology,  
School of Medicine, International  
University of Health and Welfare,  
4-3, Kozunomori, Narita, Chiba  
286-8686, Japan.  
Email: minoru.takemoto@iuhw.  
ac.jp

Received: 5 October 2020

Revised: 2 November 2020

Accepted: 4 November 2020

## Introduction

Skin ulcers are commonly observed in Werner syndrome (WS). This article explores the epidemiology, diagnosis, treatment and prevention of ulcers in WS from a surgical perspective.

Skin ulcers in WS are refractory, and they lead to a reduced quality of life for patients. Foot ulcers in WS require special care because its clinical presentation is similar but not identical to that of ischemic limb ulcers or diabetic ulcers, both of which have recently increased in prevalence. As WS is an extremely rare disease, it is difficult to gain adequate experience in treating it. It is also difficult to create evidence-based guidelines based on clinical trials involving several patients. Nonetheless, it is necessary to make an appropriate diagnosis and provide treatment tailored to the skin ulcer in each patient with WS. In addition, ulcers in these patients are refractory, which necessitates prevention. Based on these observations, guidelines on the diagnosis, treatment and prevention of skin ulcers in WS based on case reports, including ours, are important. This article also explores elbow ulcers, as well as other lower-limb ulcers, which occur commonly in WS.

## Literature

Most studies on WS are case reports; there are only a few case series. This article was based on literature from 1996, when *WRN* was identified as a gene responsible for WS, and we evaluated several authentic clinical cases of genetically diagnosed patients.

There were 63 patients with WS in the Japanese reports retrieved from Medical Online between January 1996 and December 2017. There were 56 patients with WS in English reports written by Japanese authors and retrieved from PubMed during the same period. Both reports were used in this study. However, these Japanese reports included abstracts of conference presentations; thus, some cases overlapped. Similarly, cases reported in Japanese could overlap with those in English.

## Overview of skin ulcers

Q1. What is the complication rate of skin ulcers in patients with Werner syndrome?

A1. Approximately 40% of patients with Werner syndrome have skin ulcers.

WS is a very rare disease, and it is difficult to determine accurately the morbidity and prevalence of complications of skin ulcers. Records on skin ulcers were found in 27 (43%) of 63 patients and 22 (40%) of 56 patients from the Japanese and

English reports, respectively (Table 1). The reported ulcers were often located at the olecranon of the elbow joint in the upper limbs; ulcers were observed at sites below the distal one-third of the lower legs in several cases. There have also been reports of ulcers in the extensor surfaces of the knee joints.

Q2. Which part of the lower limb is typically affected in patients with Werner syndrome?

A2. The distal one-third of the lower leg and the foot are typically affected.

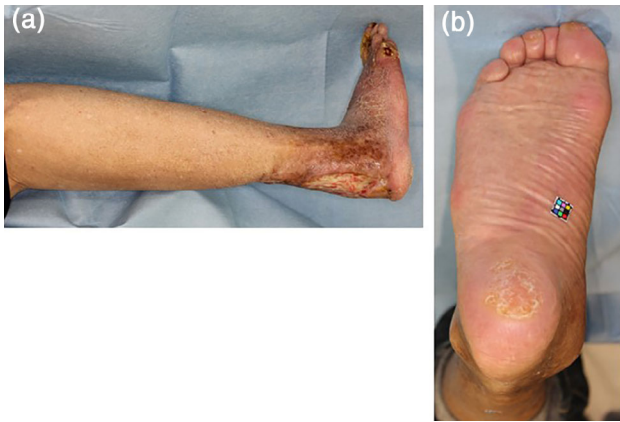Patients with WS often have thin lower limbs and dry skin. Poikiloderma and scleroderma-like changes occur on the foot, particularly on the distal one-third of the lower legs (Fig. 1). The distal one-third of the lower legs and foot will be discussed subsequently. The skin is often poorly extensible and shiny. The contraction of the ankle often limits the range of motion with the pes equinus position. Flat foot is a typical symptom of WS. Flame-like calcification in the Achilles tendon shown on radiographs is a typical symptom in WS, and skin ulcers are sometimes observed. In addition, WS may be associated with lateral and medial malleoli on the ankle and multiple leg ulcers. Callosities are also frequently observed. Even on an ulcer-free foot in relatively good condition, a callosity is often observed when critically assessed. Toe deformities frequently occur and sometimes progress rapidly.

Q3. What are the underlying diseases that can cause lower-limb ulcers?

A3. Glucose metabolism disorders are present in many cases.

**Table 1** Number of reported skin ulcers by body part in Werner syndrome

Body part	No. of cases in the Japanese reports ( <i>n</i> = 63)	No. of cases in the English reports ( <i>n</i> = 56)
Elbow	11 (17%)	1 (2%)
Knee	1 (2%)	2 (4%)
Lower leg	2 (3%)	4 (7%)
Achilles tendon	4 (6%)	5 (9%)
Medial and lateral malleoli in the ankle	2 (3%)	6 (11%)
Sole	4 (4%)	3 (5%)
Heel	6 (10%)	4 (7%)
Toe	4 (6%)	3 (5%)
Foot	1 (2%)	1 (2%)



**Figure 1** (a) Typical images of lower limbs in Werner syndrome. Significant hardening and atrophy of the skin and soft tissue are observed below the distal one-third of the lower extremities. (b) Foot is in relatively good condition without ulcers yet with a callosity on the heel region.

The incidence of carbohydrate metabolism disorders in patients with WS was high at 43% and 39% in the Japanese and English reports, respectively (Table 2). The clinical presentation of a foot ulcer in WS is partly similar to, but not necessarily identical to, that in diabetes or hypertension, which has been increasing in prevalence recently. This requires attention. Hypertension was not necessarily found in several cases. Lower limb ischemia was also not observed in several WS cases. In WS, a decrease in sensation is not common unless there is diabetes. It should be noted that the ulcers in WS are caused by multiple factors; among them, scleroderma-like changes and foot deformities are the most common. Furthermore, defective wound healing may also contribute to the development of foot ulcers in WS.

**Q4. Are there ulcers associated with malignancy?**

**A4. Yes, such ulcers are occasionally seen.**

Malignancy is prevalent in WS. The incidence of a non-epithelial tumor in patients with WS has also been reported to be higher than that in the healthy population. Regarding the association with skin ulcers, a study reported that calcaneal osteosarcoma was observed in a patient with a heel ulcer.<sup>1</sup> Malignancies should be considered as differential diagnoses for skin ulcers in patients with WS.

**Q5. Are callosities frequently observed?**

**A5. Yes, they are frequently observed.**

Callosities occur frequently on the feet of patients with WS. There were eight patients with callosities in Japanese reports and nine patients in English reports. Callosities cause pain and decrease quality of life, and an ulcer may occur at a site of callosity. Moreover, pain caused by a callosity worsens gait, which contributes to an increased load on the other sites, and subsequent

development of new callosities or ulcers. Accordingly, a callosity in WS is an important therapeutic target for the prevention of ulcers.

WS is characterized by hardened and poorly extensible skin. In addition, symptoms, including flat foot, toe deformity and ankle contracture, may progress. These conditions cause high callosities in WS.

As mentioned above, a callosity may become the origin of a skin ulcer. Thus, for patients with WS who have a callosity without a skin ulcer, prevention is necessary, considering the risk of developing an ulcer. Such cases have been reported in two patients from Japanese reports and five from English reports. The importance of interventions for preventing or treating callosities in ulcer-free patients with WS is underscored by the following among others: (i) several patients do not take preventive measures, including the use of a foot orthosis and shoe orthosis because they have never developed an ulcer or experienced refractory ulcers; and (ii) patients with mild symptoms are quite active, and therefore high pressure is applied to the callosities over a long period. In our patient, a load on a callosity on the heel ruptured the calcaneal bony cortex, leading to calcaneal bone osteomyelitis (Fig. 2). Although this patient presented with changes typical of WS, including poikiloderma, scleroderma-like skin changes, and ankle contracture of the distal one-third of the lower legs to the foot, the skin on the lower legs and feet were in relatively good condition. The causes of a heel ulcer were considered to include failure to treat a callosity on the heel, use of commercial shoes, and repeated and continuous pressure applied to a callosity on the heel due to the patient’s activities.

These observations demonstrate that a callosity is a prodrome of skin ulcers in WS. The interventions for callosities may prevent severe and difficult-to-treat conditions such as skin ulcers and osteomyelitis.

**Diagnosis**

**Q6. Are macroscopic evaluations of ulcers important?**

**A6. Yes, they are important.**

As macroscopic findings, the records of sites and characteristics of ulcers are important. It is useful to keep records, with the items included in DESIGN-R®(edited by the Japanese Society of Pressure Ulcers)<sup>2</sup> in mind, to reduce the number of omissions. DESIGN-R® provides criteria for evaluating pressure ulcers, yet it can also be used to assess ulcers other than pressure ulcers. The evaluation items are depth, amount of exudate, size, inflammation/infection, granulation tissue, necrotic tissue and pocket.

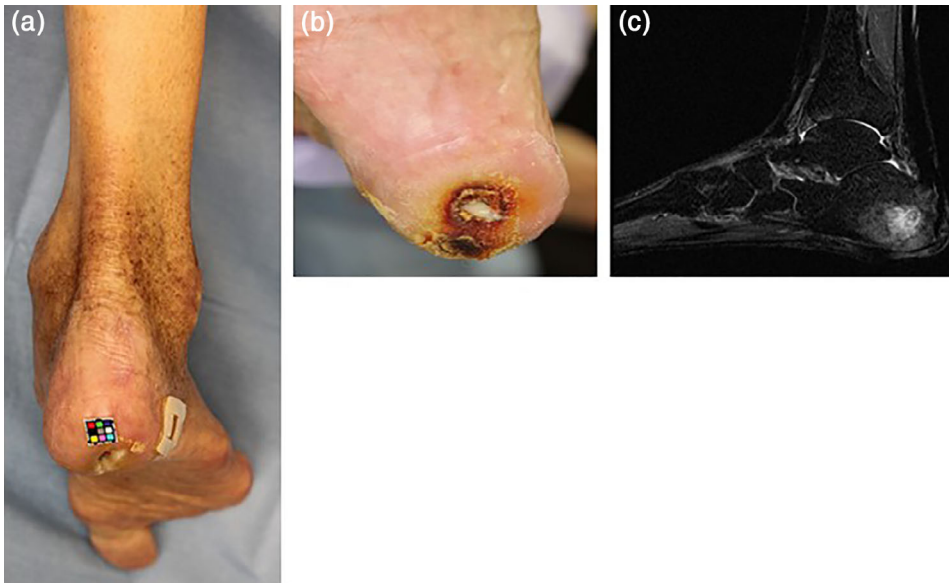
DESIGN-R is a detailed evaluation method that can be utilized for therapeutic effect determination and assessment of time-dependent changes. Its limitations include slightly cumbersome records.

The following are points that are considered important in the assessment of ulcers in WS.

1. Depth of an ulcer: an ulcer in WS easily reaches the bone or the articular cavity. It is necessary to consider the possibility of osteomyelitis in case of the rupture of the ulcer and extension to the bone marrow, osteomyelitis and purulent arthritis in case of an ulcer reaching the articular cavity.
2. Amount of exudate: in cases of purulent exudates, the possibility of osteomyelitis or purulent arthritis should be considered.
3. Size: it is important to determine the condition of an ulcer and the therapeutic effects.

**Table 2** Underlying diseases that can cause a lower extremity ulcer

	Japanese reports (n = 63)	English reports (n = 56)
Carbohydrate metabolism disorders	27 (43%)	22 (39%)
Hypertension	3 (5%)	1 (2%)
Lower limb ischemia	1 (2%)	2 (4%)



**Figure 2** A case of a calcaneal callosity developing into possible calcaneal bone osteomyelitis. (a) Skin is generally in good condition from the distal one-third of the lower extremities to the foot region. (b) Pus from the ulcer on the heel region. (c) Magnetic resonance imaging: sagittal section of the foot. Fat-suppressed T2-weighted image shows high signal intensity in the calcaneal bone marrow, which reflects osteomyelitis.

4. Inflammation/infection: it is important to identify the focus of the infection, which may be the skin and soft tissue, bone marrow, or articular cavity.
5. Granulation tissue: generally, granulation is poor at the site of an ulcer in WS. In cases with poorly formed granulation tissue, it is necessary to investigate the cause, which may include poor blood flow, infection and necrotic tissue, and provide treatments to eliminate these conditions.
6. Necrotic tissue: the following should be determined, i.e., nature, depth and range of necrotic tissue.
7. Pocket: in several patients with WS, the formation of a pocket in a foot ulcer may become a problem.

Q7. Are plain radiography and computed tomography of the foot region useful?

A7. Plain radiography and computed tomography are helpful for examining the shape of the entire foot and the conditions of individual bones of the foot.

It is important to understand the time-dependent changes because the shape of the foot and the state of each bone may change rapidly in WS.

Q8. Is magnetic resonance imaging examination useful?

A8. Magnetic resonance imaging examination is useful for a suspected case of osteomyelitis (Fig. 2).

Q9. Is vascular evaluation necessary?

A9. Yes, it is necessary.

In cases of lower-limb ischemia, it is necessary to assess the possibility of revascularization. Lower-limb ischemia should be considered in patients with a history of hypertension or diabetes, cold feet, or non-palpable dorsalis pedis and posterior tibial pulses. There were suspected cases of lower-limb ischemia in one patient from the Japanese and two from the English reports. One of these patients reportedly showed revascularization after a femoropopliteal artery bypass surgery using a saphenous vein.<sup>3</sup>

## Treatment

Q10. Is the combination of surgical treatment and wound bed preparation important in treating skin ulcers?

A10. Yes, it is important to combine these treatments.

A skin ulcer in WS is generally intractable. Weight-bearing ulcers or callosity should be critically assessed in surgical procedures because they have effects on patient pain, gait and quality of life. Even if a wound is finally closed surgically, using procedures such as skin grafting and flap surgery, preparation before wound closure can influence the outcomes. By adopting a recently advanced technique to facilitate wound healing, the cases of ulcers that were difficult to treat and those requiring major operations can be closed with minimally invasive surgery. The attempt to improve the condition of an ulcer preoperatively is called wound bed preparation, and its importance cannot be overemphasized. In addition, progress in regenerative medicine may introduce other treatment options in the future, which may include cultured tissue grafting. This section discusses the progression from wound bed preparation to surgery in patients with WS, incorporating our experience.

### *Debridement and curettage*

In the management of skin ulcers, the removal of necrotic tissue and cleaning of the wound surface are important. Thus, daily cleaning of wound surfaces by patients is necessary. At the same time, curettage and surgical debridement are desirable every time they visit medical institutions. In addition, chemical debridement, which involves the enzymatic removal of necrotic tissue, is one of the options for daily debridement.

For obviously infected wounds, incisional drainage or debridement should be performed immediately. Lately, ulcers with no obvious symptoms of infection but increased bacterial volume, called critical colonization, has attracted attention. The critically colonized bacterial mass forms a biofilm of glycocalyx and other components, disrupts host immunity and affects the effectiveness of external medicine, and inhibits wound healing. A soft yellow-to white-colored tissue attached to the surface of an ulcer (sometimes called a slough) may include a biofilm, which is suggestive of critical colonization. In addition, NERDS has also been reported as a clinical finding suggestive of critical colonization<sup>4</sup> (Table 3). It is considered effective, as a countermeasure against critical colonization, to remove soft yellow- to white-colored tissue attached to the bottom of an ulcer using a sharp spoon or other



**Table 3** Signs suggestive of critical colonization

English terms	Meaning
N: Non-healing wounds	Treatment-resistant ulcers
E: Exudative wounds	Heavy effusion
R: Red and bleeding wound surface and granulation tissue	Red granulation tissue with bleeding
D: Debris	Existence of necrotic tissue, etc.
S: Smell or unpleasant odor	Odious smell

Signs suggestive of critical colonization are termed NERDS; an acronym using the terms shown above (quoted from Woo and Sibbald<sup>4</sup>).

instrument when the ulcer in WS is examined; this procedure removes the biofilm and reduces bacterial volume.

Debridement is useful for the diagnosis because it facilitates the determination of the range and depth of an ulcer. During the procedure, it is also important to collect samples for bacterial cultivation from wounded surfaces, necrotic tissue or pus. Some ulcers extend to the bone marrow, and osteomyelitis may be found during debridement. In such cases, pus should be obtained from the bone marrow for bacterial cultivation.

Pain is the most common hindrance in performing debridement for patients with WS. They frequently develop carbohydrate metabolism, yet have less perceptual decline than patients with diabetic ulcers and stronger pain than healthy people during the procedure. This often makes debridement without anesthesia difficult. In the case of local infiltration anesthetic injection, the hardening of tissue worsens the pain caused by the injection and prevents the injected anesthetic agent from penetrating the tissue, which increases the dose requirement and decreases the effectiveness of analgesia. One of the measures is block injection to sites with soft skin away from an ulcer such as the center of the lower thigh (Fig. 3). In any case, the significance and necessity of

debridement in WS should be explained to patients, followed by adequate preparations before applying this procedure.

### Topical medication

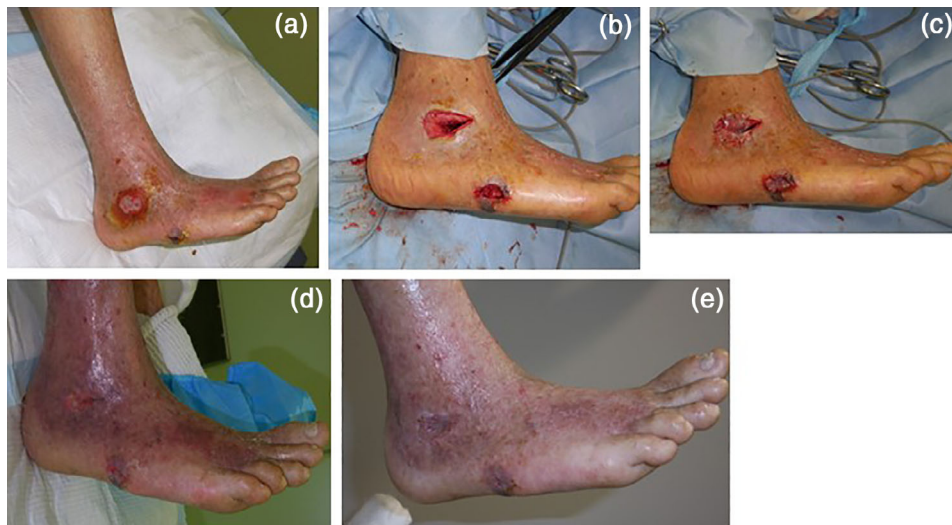It is important to use an appropriate topical medication for an ulcer. The basic idea of moist wound healing in ulcer treatment is to maintain an adequately moist environment and facilitate wound healing. However, ulcers in WS rarely heal with drugs that directly promote a moist environment and wound healing (Vaseline ointment, prostaglandin-containing ointment and basic fibroblast growth factor [bFGF] spray) alone. The critical colonization of bacteria is often addressed with iodine preparation or silver preparation. Heavy exudation exceeding the range of moist wound healing inhibits this process, and thus preparations with a water-absorbing base (cadexomer iodine and iodine-sucrose preparations) are often used to absorb exudates.

### Washing

Washing a wound surface is considered effective. There is little evidence on the effectiveness of washing, but a clinical consensus on efficacy is considered to have been reached. Wound irrigation with a shower by a patient acts as self-care and is one of the desirable personal hygiene measures. Accordingly, washing the foot in the shower just because an ulcer should be avoided, despite the lack of reason, to control a wound.

On the other hand, the following risks caused by washing should be considered, i.e., (i) multidrug-resistant bacteria in the environment are attached to a wound surface, and (ii) multidrug-resistant bacteria on a wound surface may spread to the environment.

Water-related equipment (e.g., water faucets, showerheads, bathtubs, perineal irrigation bottles) may be contaminated by various bacteria in medical institutions. Wound irrigation is likely to cause contamination of the environment by splatter. In light of the



**Figure 3** (a) Ulcers are observed on the lateral malleolus in the ankle and the lateral aspect of the foot. (b) Post-debridement. Anesthesia is administered at a site with the soft skin slightly distal from the center of the lower limb for a sural nerve block. Ulcer on the lateral malleolus reaches into the bone marrow, and the ulcer on the lateral aspect of the foot to the fifth metatarsal bone. (c) After artificial dermis was attached on to the ulcers, negative pressure wound therapy (NPWT) started. (d) Post-NPWT: granulated and reduced-size ulcers are observed. They were determined applicable to skin grafting, and split-thickness skin grafts for meshing was performed. (e) Post-skin grafting: successful engraftment and ulcer closure are confirmed.

above risks in (i) and (ii), a wound should be irrigated following standard preventive measures.

### **Negative pressure wound therapy**

Negative pressure wound therapy (NPWT) has been widely used to treat refractory ulcers in recent years. It promotes neovascularization and granulation by continuous negative pressure and facilitates ulcer healing by controlling exudates. It was effective to an extent in our cases (Fig. 3), and it should be proactively employed in the future. General precautions for NPWT include (i) not using infected wounds, and (ii) paying attention to skin diseases around ulcers, which should also be followed accordingly in WS. Skin ulcers associated with purulent arthritis frequently occur in WS. Infected ulcers are not an indication for NPWT monotherapy, but a combination with continuous irrigation may be effective.

Caution should be exercised when administering NPWT for the foot in WS because the tissue is severely indurated and the skin and soft tissue are thin and close to the bone, leading to the likelihood of developing skin and soft tissue disorders following pressure from a foaming agent. A foaming agent should be cut into an appropriate width and thickness for effective use.

### **Surgical procedure**

#### *Attachment of artificial dermis*

The skin and soft tissues in WS become thin and indurated, which likely causes loss of all layers of the bone and tendon. The artificial dermis is essential for treating foot ulcers in WS (Fig. 3). In WS, the bony cortex is often ruptured, leading to exposure of the bone marrow, but an artificial dermis can also be attached to the exposed bone marrow. Dermis-like tissue is constructed on the surface of the exposed bone marrow to prevent osteomyelitis and enable epidermization.

#### *Skin grafting*

Several skin ulcers in WS had previously been accompanied by bone exposure at the regions of loss of periosteum and aponeurosis, and it is difficult to perform skin grafting. However, the advent of the artificial dermis, bFGF preparation and NPWT has increased the number of cases that can have a base bed for skin grafting for ulcers in WS; patients undergoing skin grafting may also be on the increase. Descriptions of skin grafting were found in one case from the Japanese report and two cases from the English reports. Figure 3 shows the cases of skin grafting on the lateral malleolus in the ankle.

#### *Flap surgery*

With or without WS, the percentage of comparatively major surgeries, such as flap surgery, has decreased for the treatment of intractable ulcers, and their roles have been relatively declining. This is attributable to drug advances, including topical medication and bFGF preparations, advent of the artificial dermis, which has made skin grafting possible even in previously contraindicated situations, and a powerful granulating effect and reduction of ulcers by NPWT. On the other hand, flap surgery can close ulcers that could not be closed by other therapeutic procedures; ulcers can be closed using thick skin and soft tissue, and the duration of treatment shortens.

#### *Elbow ulcers*

The olecranon bone is curved, and highly flexible soft tissue is required because of the elbow flexion–extension movements. Furthermore, the articular cavity is often exposed in elbow ulcers of patients with WS. For these reasons, flap surgery may be appropriate in several cases instead of skin grafting. Regarding flap surgery for elbow ulcers, there have been reports on the use of radial recurrent flaps,<sup>5</sup> flexor carpi ulnaris muscle flaps,<sup>6</sup> and radial forearm flaps.<sup>7</sup> Other than those above, skin grafting<sup>8</sup> and partial osteotomy<sup>9</sup> have been reported.

#### *Knee ulcers*

Flap surgery is highly applicable to ulcers with an exposed knee-joint cavity. There are reports on cases of anterior tibial artery flap, sartorius muscle flap and free latissimus dorsi myocutaneous flap.<sup>10,11</sup>

#### *Heel ulcers*

A free serratus anterior muscle flap has been reported for a heel ulcer associated with osteomyelitis.<sup>12</sup>

#### *Ulcers in the Achilles tendon*

Calcification with a flame-like shape in the Achilles tendon observed on radiographs is a characteristic finding of WS. The infection of calcification often causes ulcers in the Achilles tendon. It has been reported to be treated with a lateral supramalleolar flap.<sup>13</sup>

#### *Amputation*

Amputation of the affected parts cannot be avoided in some refractory ulcers. Records on amputation were found for one case each of the foot and toe from Japanese reports and one case below the knee and another case of the toe from English reports. A case of below-the-knee amputation caused by calcaneal osteosarcoma has also been reported.<sup>1</sup>

#### **Others**

#### *Hyperbaric oxygen therapy*

Hyperbaric oxygen therapy for calcaneal ulcers accompanied by calcaneal osteomyelitis has been reported.<sup>14</sup>

#### *Lumbar sympathetic ganglion block*

There are reports on the lumbar sympathetic ganglion block for foot ulcers and pain.<sup>15,16</sup>

#### **Skin care**

#### *Moisture retention*

In WS, skin dryness is frequently observed, particularly in the lower leg and foot. It may become a predisposing factor for callosities and the exacerbation of skin ulcers. Desquamation or rash caused by cutaneous dryness is considered to induce contamination in surgical wounds and inhibit wound healing. The application of a moisturizer may be effective.

## **Management**

Q11. Is the management for a callosity necessary?

A11. Yes, it is necessary.

Callosities frequently occur in the foot in WS (Fig. 1b), and they may induce skin ulcers, rupture of the bony cortex in the calcaneal bone, and osteomyelitis (Fig. 2). Special attention should be paid to the callosity in the weight-bearing portion of the foot. Once an ulcer or osteomyelitis occurs in WS, it may become



**Figure 4** Samples of shoe-shaped orthoses: (a) outdoor type shoes; (b) indoor type shoes.

intractable, and preventive measures against these symptoms are implemented when a callosity is observed. Therefore, proactive intervention for callosities is important.

### Prevention against callosities

A callosity occurs when excessive pressure is prolonged. It is important to avoid excess pressure on the feet to prevent callosity formation.

Use of an appropriate foot orthosis or shoe-shaped orthosis, which is tailored to each patient's foot, may prevent a callosity and an ulcer. An article reported the use of foot orthosis and a shoe-shaped orthosis for two patients with WS.<sup>17</sup> According to the report, it was challenging to make orthoses for both cases, yet one patient was satisfied with it. In our cases, shoe-shaped orthoses were proactively made (Fig. 4). There are outdoor shoe types and indoor shoe types, which are tailored to the lifestyle of each patient by a prosthetist. These shoes are more comfortable than commercial shoes made for healthy people, and they relieve pain. We are currently examining the effects of these orthoses on callosities and ulcers. A toe deformity may progress rapidly in WS, which often renders a prepared orthosis unsuitable after a brief period.

Orthoses can be applied to the lower and upper extremities, such as the elbow joint.

### Treatment of callosity

Proactive treatment of a callosity is desirable in WS., Treatment should be continued, given that a callosity recurs unless continuous excessive pressure, the cause, is eliminated. The specific methods include the following.

#### Shaving of a callosity

The thickness of a callosity may be reduced with a razor, and the shape of a callosity may be smoothed. This makes it possible to prevent extremely heavy pressure from being applied to the narrow range of the skin.

#### Attachment of salicylic acid preparation

By attaching a salicylic preparation, keratin can be macerated and manually exfoliated.

#### Use of an appropriate foot orthosis or shoe-shaped orthosis

A foot orthosis or shoe-shaped orthosis tailored to each patient's foot may be effective not only for the prevention of callosity and ulcer but also for their treatment.

## Disclosure statement

The authors declare no conflict of interest.

## References

- 1 Nakamura Y, Shimizu T, Ishikawa Y *et al.* Triple primary sarcoma in Werner syndrome with a novel mutation. *Rheumatology* 2003; **42**: 798–800.
- 2 Japanese Society of Pressure Ulcers. *DESIGN-R*. <http://www.jspu.org/jpn/info/design.html>. (in Japanese).
- 3 Akiyama K, Takazawa A, Taniyasu N, Sato H. Revascularization of femoropopliteal artery occlusion in Werner's syndrome. Report of a case and review of surgical literature in cardiovascular lesions. *J Cardiovasc Surg* 2000; **41**: 303–306.
- 4 Woo KY, Sibbald RG. A cross-sectional validation study of using NERDS and STONEES to assess bacterial burden. *Ostomy Wound Manage* 2009; **55**: 40–48.
- 5 Hayashi T, Motomura H. Experience of radial recurrent flap for intractable ulcers in patients with Werner syndrome. *J Jpn Soc Plast Reconstr Surg* 2009; **52**: 291 (in Japanese).
- 6 Abe Y, Doi K, Hattori Y, Ikeda K. Experience in treating Werner syndrome with bilateral intractable olecranon ulcers. *Yamaguchi Med J* 2003; **52**: 1–2 (in Japanese).
- 7 Ooshima S, Katou H, Minami A, Suenaga N, Iwasaki M, Tazaki Y. A case of radial forearm flap for intractable skin ulcer of the elbow due to Werner syndrome. *Hokkaido J Orthop Traumatol* 2001; **43**: 24–27 (in Japanese).
- 8 Tamori Y, Takahashi T, Nakajima S *et al.* A case of Werner syndrome identifying a complex heterozygotes mutation in the WRN gene. *J Japanese Soc Intern Med* 2011; **100**: 642–1644 (in Japanese).
- 9 Akimoto H, Sasaki T. A sibling with Werner syndrome with congenital elbow dislocation. *Tohoku Arch Orthop Surg Dent Traumatol* 1999; **43**: 175 (in Japanese).
- 10 Taniguchi Y, Asai Y, Shimoe T *et al.* Experience in treating knee joint skin soft tissue defects by free latissimus dorsi flap transplantation. *J Wakayama Med Soc* 2008; **59**: 134–138 (in Japanese).
- 11 Taniguchi Y, Tamaki T. Reconstruction of intractable ulcer of the knee joint in Werner's syndrome with free latissimus dorsi myocutaneous flap. *J Reconstr Microsurg* 1998; **14**: 555–558.
- 12 Suzuki S, Fukui T, Imagawa K, Fujibayashi M, Kohno T, Miyasaka M. A case of heel ulcer suspected of WS. *Skin Surg* 2015; **24**: 45 (in Japanese).
- 13 Okazaki M, Ueda K, Kuriki K. Lateral supramalleolar flap for heel coverage in a patient with Werner's syndrome. *Ann Plast Surg* 1998; **41**: 307–310.
- 14 Yamamoto K, Imakiire A, Miyagawa N, Kasahara T. A report of two cases of Werner's syndrome and review of the literature. *J Orthop Surg* 2003; **11**: 224–233.
- 15 Shinokawa M, Kamijima K, Kiyonaga N *et al.* A case in which lumbar sympathetic ganglion block was effective for intractable leg ulcer of WS. *J Jpn Soc Pain Clin* 2014; **2**: 164–165 (in Japanese).
- 16 Satoh O, Nakabayashi K, Ichinose H, Namiki A. A case of WS in which lumbar sympathetic ganglion block was effective. *J Jpn Soc Pain Clin* 2001; **2**: 96–98 (in Japanese).
- 17 Suzuki Y, Ohshima Y. Two cases of Werner syndrome with a chief complaint of gait disturbance. *Jpn J Rehabil Med* 2000; **37**: 180 (in Japanese).





**How to cite this article:** Kubota Y, Takemoto M, Taniguchi T, *et al.* Management guideline for Werner syndrome 2020. 6. Skin ulcers associated with Werner syndrome: Prevention and non-surgical and surgical treatment. *Geriatr. Gerontol. Int.* 2020;1–7. <https://doi.org/10.1111/ggi.14096>



## ORIGINAL ARTICLE

## EPIDEMIOLOGY, CLINICAL PRACTICE AND HEALTH

# Management guideline for Werner syndrome 2020. 7. Skin ulcer associated with Werner syndrome dermatological treatment

Sei-ichiro Motegi,<sup>1</sup>  Minoru Takemoto,<sup>2</sup>  Toshibumi Taniguchi,<sup>3</sup> Yoshitaka Kubota,<sup>4</sup> Akira Taniguchi,<sup>5</sup> Hironori Nakagami,<sup>6</sup>  Yoshiro Maezawa,<sup>7</sup> Masaya Koshizaka,<sup>7</sup>  Hisaya Kato,<sup>7</sup> Seijiro Mori,<sup>8</sup> Kazuhisa Tsukamoto,<sup>9</sup> Masafumi Kuzuya<sup>10</sup> and Koutaro Yokote<sup>7</sup>

<sup>1</sup>Department of Dermatology, Gunma University Graduate School of Medicine, Gunma, Japan

<sup>2</sup>Department of Diabetes, Metabolism and Endocrinology, School of Medicine, International University of Health and Welfare, Chiba, Japan

<sup>3</sup>Department of Infectious Diseases, Chiba University Hospital, Chiba, Japan

<sup>4</sup>Department of Plastic, Reconstructive, and Aesthetic Surgery, Chiba University Graduate School of Medicine, Chiba, Japan

<sup>5</sup>Department of Orthopaedic surgery, Nara Medical University, Nara, Japan

<sup>6</sup>Department of Health Development and Medicine, Osaka University Graduate School of Medicine, Osaka, Japan

<sup>7</sup>Department of Endocrinology, Hematology and Gerontology, Chiba University Graduate School of Medicine, Chiba, Japan

<sup>8</sup>Center for the Promotion of Clinical Investigation, Tokyo Metropolitan Geriatric Hospital, Tokyo, Japan

<sup>9</sup>Department of Internal Medicine, Teikyo University School of Medicine, Tokyo, Japan

<sup>10</sup>Department of Community Healthcare & Geriatrics, Nagoya University Graduate School of Medicine, Institutes of Innovation for Future Society, Nagoya University, Nagoya, Japan

Skin ulcers in Werner's syndrome often arise from hyperkeratotic lesions and trauma to pressure points such as the plantar region, and are more difficult to treat than wound healing in healthy individuals. Multiple factors contribute to the intractable skin ulcers in Werner's syndrome, including skin thinning, sclerosis, fatty tissue loss, impaired blood flow, calcification, and excessive pressure due to osteoarticular deformity. Treatment includes topical application of a keratolytic agent for keratosis around the ulcer. Treatment of ulcers is the same as for normal ulcers, and if the ulcer is associated with infection and necrotic tissue, surgical debridement with a scalpel or scissors should be performed as much as possible after washing with saline or mildly warm water or with an antibacterial agent. Topical medications that promote softening and debridement of the necrotic tissue are used with careful control of moisture in the wound. Topical agents that promote granulation should be used in wounds where necrotic tissue has been removed without infection. Dressings to maintain a moist environment in the wound may also be useful. If the wound does not improve with conservative treatment, surgical treatment should be considered. **Geriatr Gerontol Int** ••; ••: ••–•• **Geriatr Gerontol Int** 2020; ••: ••–••.

**Keywords:** clinical medicine, geriatric medicine, management guideline, Werner syndrome.

## Correspondence

Minoru Takemoto MD PhD,  
Department of Diabetes,

Metabolism, and Endocrinology,  
University: School of Medicine,  
International University of Health  
and Welfare, 4-3, Kozunomori,  
Narita, Chiba 286-8686, Japan.  
Email: minoru.takemoto@iuhw.ac.jp  
Koutaro Yokote MD PhD,  
Department of Endocrinology,  
Hematology and Gerontology, Chiba  
University Graduate School of  
Medicine, 1-8-1 Inohana, Chuo-ku,  
Chiba 260-8670, Japan.  
Email: kyokote@faculty.chiba-u.jp

Received: 5 October 2020

Revised: 14 October 2020

Accepted: 18 October 2020

## Introduction

A skin ulcer in Werner syndrome is caused by various factors. It has been said that impaired metabolism of the connective tissue component is involved.<sup>1</sup> In addition, the following factors are considered concurrently associated with ulcer development: greater weight bearing on the distal extremities due to thin limbs for the body trunk, a deformed bone and joint such as hallux valgus and a flat foot, localized hyperkeratosis on the sole of the foot, physical pressure on dermal connective tissue due to subcutaneous calcification, thinning or hardening of the skin, decreased adipose tissue, delayed wound healing due to decreased fibroblast proliferation capacity, occurrence of diabetes and hematogenous disorder accompanied by an arteriosclerotic lesion.<sup>2</sup>

A skin ulcer occurs more commonly at sites on which pressure is exerted, including the Achilles tendon, ankle, elbow and plantar region.<sup>3</sup> It sometimes presents with prodromal symptoms of a corn, callus and trauma. Owing to the atrophied skin and decreased subcutaneous adipose tissue at sites of predilection for skin ulcers, formation of an ulcer causes a tendon or bone to be projected easily.<sup>2</sup> Patients with Werner syndrome often develop tumors, and thus, it is desirable to consult a dermatologist when in doubt to consider the possibility of a refractory skin ulcer attributed to squamous cell carcinoma or a malignant melanoma. In particular, careful attention is needed, as patients with Werner syndrome can develop acral lentiginous malignant melanoma, occurring commonly on the sole of the foot, at a high rate.<sup>4</sup>

## Treatment guidelines

A skin ulcer in Werner syndrome is attributed to the above factors, which makes it intractable. It is conservatively treated with topical medications and wound dressings first, while systemic treatment including diabetic control needs to be performed concurrently. For hyperkeratosis around a skin ulcer, keratin softeners such as salicylic acid Vaseline and urea ointment are used topically. Treating a corn and callus with keratin softeners is important to prevent the occurrence of a skin ulcer as well. In cases where a skin ulcer is not improved with conservative medical treatment, surgical treatment should be considered.

## Local treatment

A skin ulcer in Werner syndrome is a chronic cutaneous wound. Prolonged inflammation caused by various cytokines and increased activity of protease that plays a role in breaking down necrotic tissue protein cause an extracellular matrix acting as a scaffold of tissue to be breaks down, leading to failure to reconstruct tissues in the chronic cutaneous wound.<sup>5</sup> In addition, impaired molecular composition in the effusion lowers the division potential of the cell that is involved in tissue reconstruction.<sup>5</sup> To facilitate the healing process of a chronic wound, topical medications to eliminate causes that interfere with healing, and topical medications or wound dressings that accelerate the repairing process need to be appropriately selected before use.<sup>6</sup>

### *In cases where a skin ulcer is associated with infection or necrotic tissue*

The skin ulcer is washed with saline or lukewarm water, followed by surgical debridement of the necrotic tissue using a scalpel and a scissor as much as possible. If it is in the process of being infected or already infected, the ulcer is disinfected with povidone iodine, chlorhexidine gluconate or benzalkonium chloride to control infection.<sup>6</sup> In case of failure to perform debridement, chemical debridement is conducted using necrotic tissue removers including CADEX OINTMENT<sup>®</sup>, Isodine gel<sup>®</sup> and Bromelain ointment<sup>®</sup>. GEBEN cream<sup>®</sup> containing more water facilitates softening and dissolving of necrotic tissue, which is effective treatment for a wound site with a small effusion. In cases with heavy exudate from a wound site due to infection or intense inflammation, CADEX OINTMENT<sup>®</sup> and U-Pasta<sup>®</sup> KOWA are effective in absorbing the exudate. As to an ulcer associated with infection or necrotic tissue, closure of an ulcer can worsen infection, and thus it should not be treated with wound dressings (closed dressings) but mainly using antibacterial therapy available in topical preparations.<sup>6</sup>

### *Granulation/epithelium formation stage*

At an infection-free wound site after necrotic tissue has been removed, granulation is generally formed, whereas it is not easily

formed in most skin ulcers occurring in patients with Werner syndrome. Therefore, a wound site should be washed with saline or lukewarm water, followed by application of granulation promoting drugs, including Olcenon Ointment<sup>®</sup>, Prostandin Ointment<sup>®</sup> and Reflap Ointment<sup>®</sup>. A basic fibroblast growth factor (Fibrast spray<sup>®</sup>) is also effective, but attention is required because skin ulcers in a patient with Werner syndrome are often associated with malignancy.

Granulation tissue can then fill the ulcer, leading to epithelization. At this stage, epithelization promoters including Prostandin Ointment<sup>®</sup> and Actosin Ointment<sup>®</sup> are used. Wound dressings are also effective to maintain a moist environment at the wound site. Hydrocolloid is recommended for wounds with a small amount of exudate, while alginate (Sorbsan<sup>®</sup>), chitin (Beschitin<sup>®</sup>), hydrofiber (AQUACEL<sup>®</sup>), hydropolymer (TIELLE<sup>®</sup>) and polyurethane foam (HYDROSITE<sup>®</sup>) are effective with heavy exudate.<sup>6</sup>

Recently, a case has been reported where endothelin receptor antagonist successfully treated a refractory ulcer.<sup>7</sup>

## Surgical treatment

In many cases, there are difficulties in healing skin ulcers using skin grafting, while the attachment of artificial dermis<sup>8</sup> and flap reconstruction<sup>9,10</sup> are often more effective. It is also necessary to consider the possibility that debridement may enlarge an ulcer due to decreased fibroblast division capacity.<sup>8</sup>

## Discussion

Skin ulcers associated with Werner syndrome are often caused by a corn, callus or trauma occurring at sites on which pressure is exerted, including the Achilles tendon, ankle, elbow and plantar region, and are more refractory than wounds in healthy individuals. This may be attributable to thinning or hardening of the skin, a decrease in adipose tissue, inadequate blood flow, calcification and excess pressure due to a deformed bone and joint. To treat skin ulcers, a keratin softener is used topically for the hyperkeratosis around an ulcer. Treatment for an ulcer associated with Werner syndrome is the same as that for a common ulcer. However, if it is accompanied by infection or necrotic tissue, the ulcer is washed with saline or lukewarm water or disinfected with antiseptic, followed by surgical debridement for necrotic tissue using a scalpel and a scissor as much as possible. Topical medications that

promote softening and dissolving of necrotic tissue are used concurrently, with careful attention paid to moisture control at the surgical wound site. For infection-free wound sites after the necrotic tissue has been removed, topical medications for a granulation promoting effect are used. Wound dressings are also effective to maintain a moist environment at the wound site. In cases where a skin ulcer is not ameliorated with conservative medical treatment, surgical treatment should be considered.

## Disclosure statement

The authors declare no conflict of interest.

## References




- 1 Hatamochi A. Werner syndrome and connective tissue. *Rinsyo Derma* 1996; **38**: 1529–1536 (in Japanese).
- 2 Banno T. Werner syndrome. *Rinsyo Derma* 2000; **42**: 1512–1513 (in Japanese).
- 3 Goto M. Werner syndrome. *Rinsyo Derma* 1997; **39**: 1095–1102 (in Japanese).
- 4 Lauper JM, Krause A, Vaughan TL, Monnat RJ Jr. Spectrum and risk of neoplasia in Werner syndrome: a systematic review. *PLoS One* 2013; **8**: e59709.
- 5 Ohura N, Harii K. Chronic wound. *J Therapy* 2009; **91**: 237–242 (in Japanese).
- 6 Inoue Y, Kaneko S, Kano H *et al.* Wound/pressure ulcer/burn guidelines: general guidelines for wounds. *Jpn J Dermatol* 2017; **127**: 1659–1687 (in Japanese).
- 7 Noda S, Asano Y, Masuda S *et al.* Bosentan: a novel therapy for leg ulcers in Werner syndrome. *J Am Acad Dermatol* 2011; **65**: e54–e55.
- 8 Numata T, Funasaka Y, Nagai H *et al.* A case of Werner syndrome treated with artificial dermis. *Rinsyo Derma* 1998; **40**: 1703–1705 in Japanese.
- 9 Terashi H, Ishii Y, Murakami I *et al.* Experience in treating intractable ulcers of the Achilles tendon of Werner syndrome. *Rinsyo Derma* 1994; **36**: 749–751 (in Japanese).
- 10 Taino H, Yajima H, Tatsumi H *et al.* Treatment experience for Achilles tendon skin ulcer caused by Werner syndrome. *Cent Jpn J Orthop Surg Traumatol* 2002; **45**: 1005–1006 (in Japanese).

**How to cite this article:** Motegi S, Takemoto M, Taniguchi T, et al. Management guideline for Werner syndrome 2020. 7. Skin ulcer associated with Werner syndrome dermatological treatment. *Geriatr. Gerontol. Int.* 2020;1–3. <https://doi.org/10.1111/ggi.14077>

## ORIGINAL ARTICLE

## SOCIAL RESEARCH, PLANNING AND PRACTICE

# Management guideline for Werner syndrome 2020 8. Calcification in tendons associated with Werner syndrome

Akira Taniguchi,<sup>1</sup> Yasuhito Tanaka,<sup>1</sup> Minoru Takemoto,<sup>2</sup>  Yoshitaka Kubota,<sup>3</sup> Toshibumi Taniguchi,<sup>4</sup> Sei-ichiro Motegi,<sup>5</sup> Hironori Nakagami,<sup>6</sup>  Yoshiro Maezawa,<sup>7</sup> Masaya Koshizaka,<sup>7</sup>  Hisaya Kato,<sup>7</sup> Kazuhisa Tsukamoto,<sup>8</sup> Seiji Mori,<sup>9</sup> Masafumi Kuzuya<sup>10</sup> and Koutaro Yokote<sup>7</sup>

<sup>1</sup>Department of Orthopaedic Surgery, Nara Medical University, Nara, Japan

<sup>2</sup>Department of Diabetes, Metabolism and Endocrinology, School of Medicine, International University of Health and Welfare, Chiba, Japan

<sup>3</sup>Department of Plastic, Reconstructive and Aesthetic Surgery, Chiba University Graduate School of Medicine, Chiba, Japan

<sup>4</sup>Department of Infectious Diseases, Chiba University Hospital, Chiba, Japan

<sup>5</sup>Department of Dermatology, Gunma University Graduate School of Medicine, Maebashi, Japan

<sup>6</sup>Department of Health Development and Medicine, Osaka University Graduate School of Medicine, Osaka, Japan

<sup>7</sup>Department of Endocrinology, Hematology and Gerontology, Chiba University Graduate School of Medicine, Chiba, Japan

<sup>8</sup>Department of Internal Medicine, School of Medicine, Teikyo University, Tokyo, Japan

<sup>9</sup>Center for the Promotion of Clinical Investigation, Tokyo Metropolitan Geriatric Hospital, Tokyo, Japan

<sup>10</sup>Department of Community Healthcare & Geriatrics, Nagoya University Graduate School of Medicine, Institutes of Innovation for Future Society, Nagoya University, Nagoya, Japan

## Correspondence

Professor Koutaro Yokote MD PhD, Department of Endocrinology, Hematology and Gerontology, Chiba University Graduate School of Medicine,

**Aim:** To clarify the diagnostic value of the calcification in the Achilles tendon for Werner syndrome.

**Methods:** Calcification of the Achilles tendon in the plain radiograph was investigated in 92 patients with Werner syndrome provided from the nationwide secondary survey in 2010. And the same investigation was performed for 2151 feet in 1853 patients without Werner syndrome, who underwent foot and ankle surgeries at the department of orthopaedic surgery in Nara Medical University from 2004 to 2015.

**Result and Conclusion:** Achilles tendon calcification was observed in 70 (76.1%) out of 92 patients with Werner syndrome, whereas that was observed only in 19 feet (0.88%) without Werner syndrome, accompanied by 1 to 4 calcified masses with a maximum diameter ranging from 9.7mm to 63.2mm. The frequency of Achilles tendon calcification in patients with Werner syndrome is far higher than that of patients without Werner syndrome. Achilles tendon calcification could be included in the diagnostic criteria for Werner syndrome. **Geriatr Gerontol Int 2020; ●●: ●●–●●.**

**Keywords:** Achilles tendon, calcification, flame-like.

1-8-1 Inohana, Chuo-ku, Chiba  
260-8670, Japan.  
Email: kyokote@faculty.chiba-u.jp

Received: 6 October 2020

Revised: 20 October 2020

Accepted: 22 October 2020

## Calcification in tendons is observed in patients with Werner syndrome

Asymmetrical calcification in ligaments and tendons has been reported in patients with Werner syndrome, the mechanism of which remains unclear.<sup>1</sup> Multiple calcifications of articular capsules and tendinous insertions might be observed in the hand, wrist, foot, knee and elbow.<sup>2</sup> The Achilles tendon might also be calcified,<sup>3</sup> and characteristically shaped calcified substances might be widely observed in some cases.<sup>4</sup> Ectopic calcification has also been previously reported in one-third of Werner syndrome patients,<sup>5</sup> and it has recently been reported in 85.3% of patients.<sup>6</sup> The Na-Pi cotransporter (Pit-1), which plays a vital role in phosphoric acid uptake, has been observed to increase in the fibroblast cells of the skin tissue in patients with Werner syndrome.<sup>6</sup>

### *Achilles tendon calcification in patients with Werner syndrome differs from that in patients without Werner syndrome*

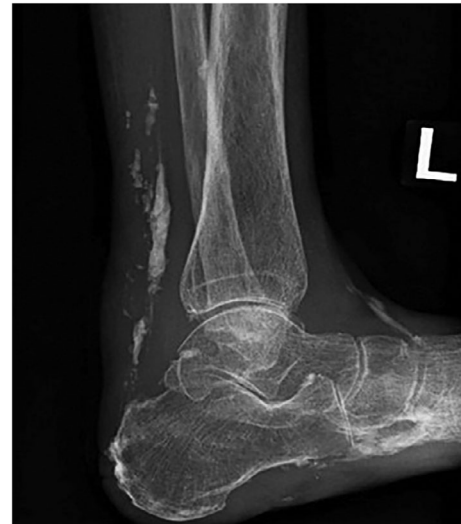The results of a recent investigation showed that a bone spur on the calcaneus at the insertion of the Achilles tendon, which might be confused with calcified Achilles tendon, is caused by the apoptosis of fibrocartilaginous components on the surface of the Achilles tendon insertion, and subsequent enchondral ossification. This mechanism proves that bony spurs differ from calcified Achilles tendons.<sup>7</sup>

Some studies reported calcification in the Achilles tendon to be found in patients with Achilles tendinitis and Achilles enthesitis,<sup>8,9</sup> whereas another study reported it to be observed after the operative treatment of Achilles tendon rupture.<sup>10</sup> Patients with Werner syndrome develop multiple blocky calcifications in a wide area of the Achilles tendon with a flame-shaped calcification pattern, which clearly differs from Achilles tendon calcification in patients without Werner syndrome.

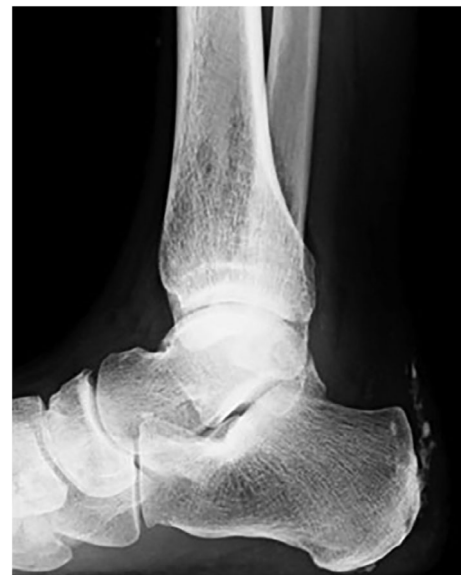### *Calcification of the Achilles tendon found in a plain radiograph is useful for the diagnosis of Werner syndrome*

There are clear differences between Achilles tendon calcification in patients with Werner syndrome and those without Werner syndrome in terms of frequency, area and pattern of occurrence. In 2010, a nationwide secondary survey was carried out as part of the Nationwide Study for the Understanding of the Clinical Conditions, Creation of Practice Guidelines and Development of a New Treatment for Werner Syndrome. This survey showed that Achilles tendon calcification was observed in 70 (76.1%) out of 92 patients with Werner syndrome who participated in the survey and submitted their responses regarding calcification of the Achilles tendon. Plain radiographs of 2151 feet belonging to 1853 patients without Werner syndrome, who underwent foot and ankle surgeries at the Department of Orthopedic Surgery in Nara Medical University between 2004 and 2015, showed that Achilles

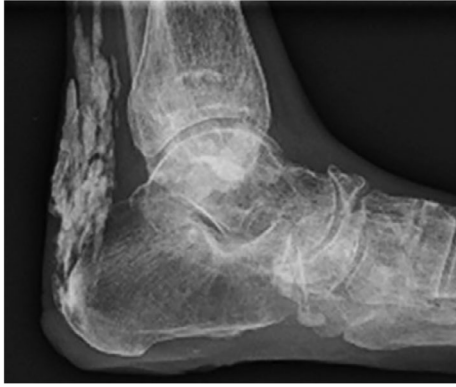tendon calcification was observed in just 19 feet (0.88%). The finding of calcification in the Achilles tendon was also accompanied by one to four calcified masses with a maximum diameter ranging from 9.7 to 63.2 mm.



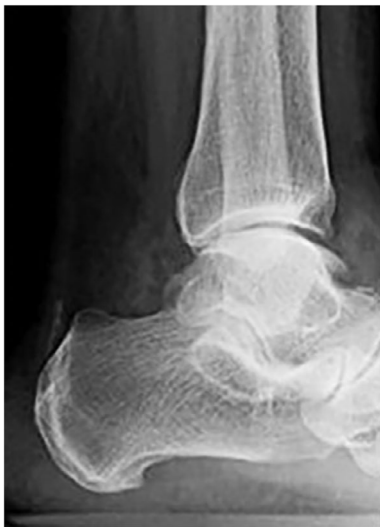**Figure 1** Calcification exceeding 2 cm is observed in the Achilles tendon (a single large segmental calcification).



**Figure 2** Several calcifications not exceeding 2 cm in length are observed (several small segmental calcifications).



**Figure 3** Flame-like calcifications are observed widely in Achilles tendon insertion (flame-like calcifications).



**Figure 4** Isolated lesion with 14-mm length in a patient without Werner.

The frequency of Achilles tendon calcification in patients with Werner syndrome is far higher than that in patients without Werner syndrome; thus, it is beneficial to incorporate Achilles tendon calcification into the diagnostic criteria for Werner syndrome.

### Achilles tendon calcification includes

1. A calcification seen on a plain radiograph with a length of at least 2 cm that is not contiguous with the calcaneus (a single large segmental calcification; Fig. 1).

2. At least two calcific masses with a length not exceeding 2 cm and not contiguous with the calcaneus (several small segmental calcific masses; Fig. 2).
3. Clearly abnormal flame-like calcification in a large area of the Achilles tendon (Fig. 3).
4. A typical pattern of Achilles tendon calcification in patients without Werner is shown in Figure 4.

In cases where any one of the above items applies, a diagnosis should be made, keeping in mind that a patient might develop Werner syndrome-specific Achilles tendon calcification.

### Disclosure statement

The authors declare no conflict of interest.

### References

- 1 Laroche M, Ricq G, Cantagrel A, Amigues JM, Mazieres B. Bone and joint involvement in adults with Werner's syndrome. *Rev Rhum Engl Ed* 1997; **64**: 843–846.
- 2 Gaetani SA, Ferraris AM, D'Agosta A. Case report 485: Werner syndrome. *Skeletal Radiol* 1988; **17**: 298–301.
- 3 Walton NP, Brammar TJ, Coleman NP. The musculoskeletal manifestations of Werner's syndrome. *J Bone Joint Surg Br* 2000; **82**: 885–888.
- 4 Leone A, Costantini AM, Brigida R, Antoniol OM, Antonelli-Incalzi R, Bonomo L. Soft-tissue mineralization in Werner syndrome. *Skeletal Radiol* 2005; **34**: 47–51.
- 5 Epstein CJ, Martin GM, Schultz AL *et al*. Werner's syndrome a review of its symptomatology, natural history, pathologic features, genetics and relationship to the natural aging process. *Medicine* 1966; **45**: 177–221.
- 6 Honjo S, Yokote K, Fujimoto M *et al*. Clinical outcome and mechanism of soft tissue calcification in Werner syndrome. *Rejuvenation Res* 2008; **11**: 809–819.
- 7 Benjamin M, Rufai A, Ralphs JR. The mechanism of formation of bony spurs (enthesophytes) in the achilles tendon. *Arthritis Rheum* 2000; **43**: 576–583.
- 8 Courville XF, Coe MP, Hecht PJ. Current concepts review: non-insertional Achilles tendinopathy. *Foot Ankle Int* 2009; **30**: 1132–1142.
- 9 Irwin TA. Current concepts review: insertional achilles tendinopathy. *Foot Ankle Int* 2010; **31**: 933–939.
- 10 Kraus R, Stahl JP, Meyer C *et al*. Frequency and effects of intratendinous and peritendinous calcifications after open Achilles tendon repair. *Foot Ankle Int* 2004; **25**: 827–832.

**How to cite this article:** Taniguchi A, Tanaka Y, Takemoto M, et al. Management guideline for Werner syndrome 2020 8. Calcification in tendons associated with Werner syndrome. *Geriatr. Gerontol. Int.* 2020;1–3. <https://doi.org/10.1111/ggi.14084>