

## Detection of somatic activating *GNAS* mutations in girls with isolated autonomous ovarian cyst by next generation sequencing

---

Hironori Shibata<sup>1</sup>, Satoshi Narumi<sup>1,2</sup>, Tomohiro Ishii<sup>1</sup>, Koji Muroya<sup>3</sup>, Yumi Asakura<sup>3</sup>, Masanori Adachi<sup>3</sup>, Goro Sasaki<sup>4</sup>, Takumi Shibazaki<sup>5</sup>, Yosuke Hara<sup>5</sup>, Tomonobu Hasegawa<sup>1</sup>

(1) Department of Pediatrics, Keio University School of Medicine, Tokyo, Japan

(2) Department of Molecular Endocrinology, National Research Institute for Child Health and Development, Tokyo, Japan

(3) Department of Endocrinology and Metabolism, Kanagawa Children's Medical Center, Yokohama, Japan

(4) Department of Pediatrics, Tokyo Dental College Ichikawa General Hospital, Ichikawa, Chiba, Japan

(5) Department of Pediatrics, Shinshu University School of Medicine, Matsumoto, Japan

---

## Take Home Message

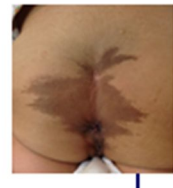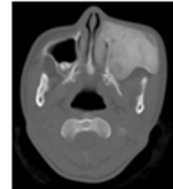
Somatic activating *GNAS* mutations  
is the major cause of  
isolated autonomous ovarian cyst

|

---

## McCune-Albright syndrome (MAS)

- Caused by a somatic activating mutation of *GNAS*
- Characterized clinically by the classic triad
  - Fibrous dysplasia (FD)
  - Café-au-lait skin spots
  - GnRH-independent precocious puberty (PP) due to autonomous ovarian cyst



---

## Somatic activating *GNAS* mutations in isolated autonomous ovarian cyst

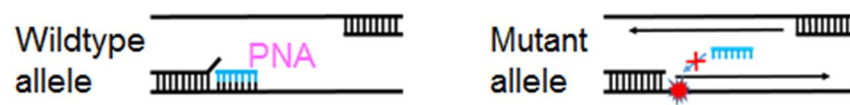
- Ovarian samples
  - direct sequencing
  - detected in 13 (33.3%) of 39
- Peripheral blood leucocytes (PBL) samples
  - nested PCR and restriction enzyme digestion
  - detected in only 3 (7.7%) in 39

J Clin Endocrinol Metab 2004; 89: 2107 |

---

## Detection of somatic activating *GNAS* mutations by next generation sequencing (NGS)

- PBL samples in MAS  
NGS with peptide nucleic acids (PNA) probe  
detected in 12 (75.0%) of 16



PLoS One 2013; 8: e60525 |

---

## Objective

To determine if we could detect somatic activating *GNAS* mutations in girls with isolated autonomous ovarian cyst by NGS using PBL samples

|

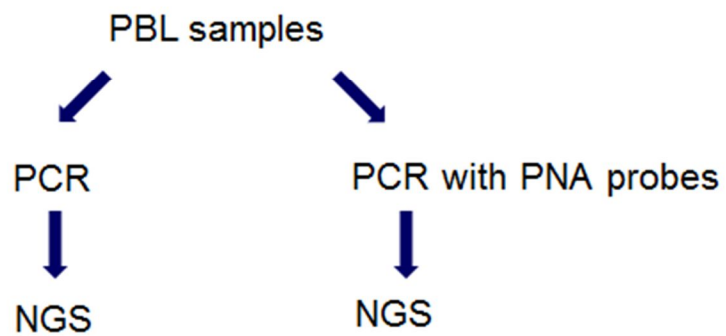
---

## Participants

- Inclusion criteria
  - GnRH-independent PP due to isolated autonomous ovarian cyst
- Exclusion criteria
  - Fibrous dysplasia (FD)
  - Café-au-lait skin spots

---

## Methods Mutation detection



## Results

### Characteristics of 8 participants

Case	First symptom		First evaluation			MAS feature			Last evaluation
	Age (years)	Type	Age (years)	Bone age (years)	Tanner stage	FD	Skin lesion	Ovarian cyst	Age (years)
1	4.8	B	5.3	5.4	B2P1	Absent*	Absent	Present	12.0
2	0.3	B, V	1.9	1.9	B3P1	Absent*	Absent	Present	4.8
3	3.0	B, V	7.5	10.5	B2P1	Absent*	Absent	Present	10.2
4	1.5	B	4.6	4.6	B2P1	Absent*	Absent	Present	7.3
5	1.0	B	2.7	3.0	B3P1	No history**	Absent	Present	5.3
6	3.3	B	3.3	3.1	B2P1	No history**	Absent	Present	5.5
7	1.4	B, V	1.5	1.5	B2P1	No history**	Absent	Present	4.3
8	5.3	V	5.5	4.6	B1P1	No history**	Absent	Present	6.4

Abbreviations: B breast, P pubic hair, V vaginal bleeding.

\*No lesion on skeletal radiographic examination.

\*\*No history of fracture nor skeletal deformity.

## Results

### Detection of somatic activating *GNAS* mutations

Case	Mutation detection method	
	NGS	NGS with PNA
1	Negative	Negative
2	Negative	Negative
3	Negative	R201C
4	Negative	R201H
5	Negative	R201H
6	Negative	R201C
7	R201H	R201H
8	Negative	Negative

< Detection probabilities >

- NGS  
one (12.5%) in 8
- PNA-NGS  
5 (62.5%) in 8

---


## Discussion

- This is the first report of somatic activating *GNAS* mutations analyses using NGS in isolated autonomous ovarian cyst
  - We detected somatic activating *GNAS* mutations sensitively from PBL samples by PNA-NGS
- ⇒ Somatic activating *GNAS* mutations is the major cause of isolated autonomous ovarian cyst

---

## Discussion

- Somatic activating *GNAS* mutations analysis by PNA-NGS using PBL sample is less invasive than biopsy
- ⇒ PNA-NGS using PBL sample may be useful for differentiation of GnRH-independent PP



## Take Home Message

Somatic activating *GNAS* mutations  
is the major cause of  
isolated autonomous ovarian cyst

|