

Original Article

Simeprevir or telaprevir with peginterferon and ribavirin for recurrent hepatitis C after living-donor liver transplantation: A Japanese multicenter experience

Yoshihide Ueda,¹ Toru Ikegami,² Akihiko Soyama,³ Nobuhisa Akamatsu,⁴ Masahiro Shinoda,⁵ Kohei Ishiyama,⁶ Masaki Honda,⁷ Shigeru Marubashi,⁸ Hideaki Okajima,⁹ Tomoharu Yoshizumi,² Susumu Eguchi,³ Norihiro Kokudo,⁴ Yuko Kitagawa,⁵ Hideki Ohdan,⁶ Yukihiko Inomata,⁷ Hiroaki Nagano,⁸ Ken Shirabe,² Shinji Uemoto⁹ and Yoshihiko Maehara²

¹Department of Gastroenterology and Hepatology, Graduate School of Medicine, Kyoto University, ²Department of Surgery and Science, Graduate School of Medical Sciences, Kyushu University, Fukuoka, ³Department of Surgery, Nagasaki University Graduate School of Biomedical Sciences, Nagasaki, ⁴Division of Artificial Organ and Transplantation, Department of Surgery, University of Tokyo, ⁵Department of Surgery, Keio University School of Medicine, Tokyo, ⁶Gastroenterological and Transplant Surgery, Applied Life Sciences, Institute of Biomedical and Health Sciences, Hiroshima University, Hiroshima, Japan, ⁷Department of Transplantation and Pediatric Surgery, Kumamoto University, Kumamoto, ⁸Department of Surgery, Osaka University Graduate School of Medicine, Osaka, and ⁹Department of Surgery, Graduate School of Medicine, Kyoto University, Kyoto, Japan

Aim: This study aimed to clarify the efficacy and safety of simeprevir, a second-generation NS5A inhibitor, with peginterferon and ribavirin for recurrent hepatitis C after liver transplantation.

Methods: A retrospective cohort study of living-donor liver transplant recipients with recurrent hepatitis C with the hepatitis C virus genotype 1 treated with either simeprevir- or telaprevir-based triple therapy was carried out at eight Japanese liver transplant centers.

Results: Simeprevir- and telaprevir-based triple therapies were given to 79 and 36 patients, respectively. Of the 79 patients treated with simeprevir-based triple therapy, 44 (56%) achieved sustained virological response 12 weeks (SVR12) after treatment ended, and there was no significant difference in the SVR12 between the simeprevir- and telaprevir-based triple therapy groups (69%). The rates of adverse events were not significantly different between the

simeprevir- and telaprevir-based triple therapy groups, although the rate of patients who received blood cell transfusion and erythropoietin due to anemia and had renal insufficiency were significantly higher in the telaprevir group than in the simeprevir group. Three baseline factors, the presence of prior dual therapy with peginterferon and ribavirin ($P = 0.001$), a non-responder to the prior dual therapy ($P < 0.001$), and male sex ($P = 0.040$), were identified as significant predictive factors for non-SVR with simeprevir-based triple therapy.

Conclusion: Simeprevir-based triple therapy for recurrent hepatitis C after living-donor liver transplantation resulted in a high SVR rate and good tolerability, especially in treatment-naïve patients.

Key words: hepatitis C, liver transplantation, living donor, simeprevir, telaprevir

INTRODUCTION

LIVER CIRRHOSIS AND hepatocellular carcinoma caused by hepatitis C virus (HCV) infection are the

leading indications for liver transplantation in many countries, including Japan. However, almost all HCV-positive recipients develop recurrent hepatitis C.^{1–3} After hepatitis C recurrence, the progression of fibrosis in the transplanted liver is often accelerated, and 10–30% of transplant recipients with an HCV infection develop cirrhosis within 5 years,^{4–8} resulting in a poorer prognosis for HCV-positive recipients than HCV-negative recipients.^{2,9}

To prevent the progression of hepatitis C after liver transplantation, dual therapy with peginterferon and ribavirin

Correspondence: Dr Yoshihide Ueda, Department of Gastroenterology and Hepatology, Graduate School of Medicine, Kyoto University, 54 Kawahara-cho, Shogoin, Sakyo-ku, Kyoto 606-8507, Japan. Email: yueda@kuhp.kyoto-u.ac.jp
Received 24 December 2015; revision 10 February 2016; accepted 12 February 2016.

has been administered as standard therapy for a long time.^{10,11} However, the efficacy of dual therapy for liver transplant recipients is limited, with a mean sustained virological response (SVR) rate of only 30% (range, 8–50%).¹² In addition, many adverse events due to dual therapy, including immune-mediated graft dysfunction (IGD), have been reported.¹³

The first direct acting antivirals (DAA), telaprevir and boceprevir in combination with peginterferon and ribavirin, became available for clinical use in 2011. However, using these first-generation NS3/4A inhibitors in liver transplant recipients is challenging because of the drug–drug interaction with calcineurin inhibitors, tacrolimus, and cyclosporine.¹⁴ Triple therapy with telaprevir or boceprevir in addition to peginterferon and ribavirin reportedly increases the SVR rate to 50–63%, according to findings from large multicenter studies.^{15–18} Severe anemia, renal dysfunction, and infection, in addition to the adverse events observed with dual therapy, were frequently observed during triple therapy, and patients died while receiving triple therapy.

Since 2013, the second-generation NS3/4A inhibitor simeprevir along with peginterferon and ribavirin has been used in patients with recurrent hepatitis C after liver transplantation. Simeprevir has two major benefits for use in liver transplant recipients compared with the first-generation NS3/4A inhibitors telaprevir and boceprevir. First, no clinically significant interactions were observed between simeprevir and calcineurin inhibitors in transplant recipients.^{19–21} Second, there are fewer adverse events associated with simeprevir-based triple therapy. In non-transplant settings, the incidence of severe adverse events and treatment discontinuation due to adverse events did not increase with simeprevir-based triple therapy compared to dual therapy with peginterferon and ribavirin.^{22–25} However, telaprevir-based triple therapy showed more frequent adverse events, including anemia and skin rash, compared to dual therapy.^{26–28} Therefore, simeprevir-based triple therapy may be safe and effective therapy for liver transplant recipients, although the efficacy and safety of this therapy is largely unknown.

More recently, the high efficacy and safety of interferon-free therapy for recurrent hepatitis C after liver transplantation have been reported.^{29–32} Sofosbuvir-based regimens, in particular, have shown no clinically significant drug–drug interactions with immunosuppressive agents, and they achieve a high SVR rate in transplant recipients.^{29,30,32} Therefore, first-line therapy for recurrent hepatitis C after liver transplantation has been changed to interferon-free therapy.³³ However, several obstacles must be overcome

to use interferon-free therapy in liver transplant recipients, including DAA-resistant HCV, the high cost, and treatment for decompensated cirrhosis. For these reasons, interferon-containing therapy would be one of the treatment options, even in this interferon-free therapy era. Interferon-containing therapy will need to be used for some populations of patients, for example, those with multiple DAA-resistant HCV, and patients who cannot afford to use interferon-free therapy. Therefore, the efficacy and safety of DAA-containing triple therapy, especially second-generation NS3/4A inhibitors with peginterferon and ribavirin, should be clarified.

We evaluated the efficacy and safety of the second-generation NS3/4A inhibitor simeprevir-based triple therapy by comparing it with the first-generation NS3/4A inhibitor telaprevir-based triple therapy in patients with recurrent hepatitis C after living-donor liver transplantation (LDLT) in a Japanese multicenter study.

METHODS

Study design and patients

THIS WAS A retrospective cohort study of LDLT recipients with recurrent hepatitis C and the HCV genotype 1 treated with either simeprevir- or telaprevir-based triple therapy at eight Japanese liver transplant centers. Data were collected until July 2015.

The study protocol was approved by the ethics committee of each liver transplant center, and written informed consent was obtained from patients for participation.

Treatment protocol

Triple therapy with simeprevir or telaprevir, peginterferon, and ribavirin was administered for the first 12 weeks, followed by dual therapy with peginterferon and ribavirin for at least another 12 weeks. Telaprevir- and simeprevir-based triple therapies were administered when patients were diagnosed with recurrent hepatitis C between November 2011 and November 2013, and between December 2013 and August 2014, respectively. Telaprevir was administered at a dose of 1500 mg/day (750 mg twice daily) or 2250 mg/day (750 mg three times daily). Simeprevir was administered at a dose of 100 mg once daily. The standard dose of peginterferon was 180 µg for peginterferon α -2a or 1.5 µg/kg of peginterferon α -2b per week. The standard ribavirin dose was determined based on the patient's body weight (BW): 600 mg/day for BW <60 kg, 800 mg/day for BW of 60–80 kg, and 1000 mg/day for BW >80 kg. These doses were reduced according to renal function, the baseline hemoglobin level, and anemia during the previous treatment, at the investigator's discretion. The management of anemia, including the

use of erythropoietin and blood transfusion, was not standardized across centers and was determined at the investigator's discretion. The selection of immunosuppressive drugs and conversion from tacrolimus to cyclosporine before treatment was decided by the investigators at each center. The blood concentration of cyclosporine or tacrolimus was adjusted using therapeutic drug monitoring. The reduction and discontinuation of treatment were also left to the investigator's discretion.

Study definitions

The HCV genotype was determined using a genotyping system based on polymerase chain reaction (PCR) of the core region using genotype-specific primers.³⁴ The serum HCV RNA load was evaluated using a real-time PCR-based quantification method for HCV (COBAS AmpliPrep/COBAS TaqMan HCV Test; Roche Molecular Systems, Pleasanton, CA, USA). The host interleukin (IL)-28B genotype for single nucleotide polymorphism at rs8099917 and inosine

triphosphatase genotype for single nucleotide polymorphism at rs1127354 were analyzed with the InvaderPlus assay, which combines PCR and the invader reaction using methods previously reported.³⁵

The rapid virological response (RVR), complete early virological response (cEVR), and end-of-treatment response (ETR) were defined as HCV RNA undetectable at 4 weeks, 12 weeks, and end of treatment, respectively. The absence of HCV RNA in the serum for >12 weeks after completing treatment was defined as SVR12. Breakthrough and relapse were defined as the reappearance of HCV RNA in the serum after being undetectable during treatment and after discontinuing therapy, respectively.

Safety assessments

Patients were hospitalized before the initiation of treatment and received strict clinical monitoring until they were stabilized. Clinical and biological data were collected during treatment. All adverse events were recorded during the

Table 1 Characteristics of patients treated with protease inhibitor with peginterferon and ribavirin after living-donor liver transplantation (LDLT)

	Simeprevir <i>n</i> = 79	Telaprevir <i>n</i> = 36	<i>P</i> -value
Age, years	62 (42–73)	60 (42–70)	0.049†
Males / females	35/44	24/12	0.026‡
Weight, kg	56.5 (35.4–84.9)	62.0 (36.0–120.2)	0.052†
Body mass index	21.8(13.8–33.1)	22.0 (16.2–41.4)	0.816†
Graft type left / right / dual	40/39/0	15/20/1	0.443‡
Splenectomy	66	33	0.243‡
Months from LDLT to therapy	29 (2–147)	26 (2–92)	0.524†
Recipient IL28B genotype (rs8099917)			
TT / TG / GG / not examined	48/19/3/9	23/13/0/0	0.079‡
Donor IL28B genotype (rs8099917)			
TT / TG / GG / not examined	28/8/1/42	22/6/0/8	0.015‡
Recipient ITPA genotype (rs1127354)			
CC / CA / AA / not examined	38/1/1/39	20/3/0/13	0.155‡
HCV RNA, log copies/mL	6.8 (4.9–7.8)	6.45 (2.7–7.8)	0.004†
HCV genotype 1a / 1b / unspecified	2/71/6	1/35/0	0.236‡
Hemoglobin, g/dL	11.6 (8.1–16.0)	12.35 (6.8–16.0)	0.372†
eGFR, mL/min/1.73 m ²	61.0 (29.9–138.8)	64.5 (32.1–114.0)	0.171†
Calcineurin inhibitor tacrolimus / cyclosporine / none	48/28/3	5/31/0	<0.001‡
MMF	36	19	0.473‡
Peginterferon α -2a/ α -2b	20/59	0/36	0.001‡
Prior dual therapy post-transplant			
NR / relapse / withdrawal / none / uncertain	41/19/3/16/0	19/6/3/7/1	0.658‡

Qualitative variables are shown in number; quantitative variables are expressed as median (range) for non-normally distributed variables.

†Wilcoxon test.

‡ χ^2 -test.

eGFR, estimated glomerular filtration rate; HCV, hepatitis C virus; IL28B, interleukin-28B; ITPA, inosine triphosphatase; MMF, mycophenolate mofetil; NR, no response.

treatment period and until 12 weeks after the last dose was given. Blood transfusion, the use of growth factors, and reductions and discontinuations of simeprevir, telaprevir, peginterferon, and ribavirin were also recorded.

Statistical analysis

The characteristics of patients, adverse events, and virological response to treatment were described and compared between simeprevir-based triple therapy and telaprevir-based triple therapy (Tables 1, 2; Figs. 1, 2). Predictive factors associated with SVR were described and compared between the SVR and non-SVR groups (Table 3, Fig. 3). For continuous variables that were nearly symmetrically distributed, means and standard deviations are given, and these data were analyzed by the *t*-test. For non-normally distributed variables, medians and ranges are presented, and the data were analyzed by Wilcoxon tests. For categorical variables, counts are given, and the data were analyzed by the χ^2 -test. $P < 0.05$ was considered significant.

RESULTS

Patients' characteristics

BETWEEN SEPTEMBER 2012 and July 2015, 115 patients with recurrent hepatitis C with the HCV genotype 1 after LDLT completed treatment with NS3/4A

inhibitor-based triple therapy and were followed for at least 12 weeks at eight transplant centers in Japan after treatment was terminated. In the 115 patients, simeprevir was used in 79 (69%, simeprevir group) and telaprevir was used in 36 (31%, telaprevir group) (Fig. 1).

A comparison of the patients' baseline characteristics in the simeprevir group and telaprevir group is presented in Table 1. Six characteristics were significantly different between the two groups, including age, sex, the donor IL28B genotype, the HCV RNA load, type of calcineurin inhibitors, and type of peginterferon. Patients in the telaprevir group were significantly younger than those in the simeprevir group. More women were treated with simeprevir. The donor IL28B genotype was not examined in 42 patients (53%) in the simeprevir group compared to 8 patients (22%) in the telaprevir group because a Japanese phase III trial for patients in non-transplant settings showed that there are no clinically relevant differences in the efficacy of simeprevir-based triple therapy according to the IL28B genotype.^{23,36} The serum HCV RNA levels before treatment were significantly lower in the telaprevir group than in the simeprevir group. Cyclosporine was preferentially used with telaprevir because the drug–drug interaction of cyclosporine with telaprevir has been reported to be much less than that of tacrolimus.¹⁴ Peginterferon α -2b was

Table 2 Adverse events during triple therapy after living-donor liver transplantation

Adverse events	Simeprevir (n = 79) n (%)	Telaprevir (n = 36) n (%)	P-value
Any adverse event	49 (62)	26 (72)	0.287
Any adverse event leading to discontinuation of treatment	10 (13)	7 (19)	0.342
Serious adverse event	9 (11)	9 (25)	0.063
Death	2 (3)	1 (3)	0.939
Anemia			
Lowest hemoglobin <10 g/dL	61 (77)	31 (86)	0.269
Lowest hemoglobin <8 g/dL	35 (44)	17 (47)	0.771
Lowest hemoglobin <6 g/dL	4 (5)	5 (14)	0.102
Received blood cell transfusion	14 (18)	16 (44)	0.002
Use of erythropoietin	4 (5)	6 (17)	0.041
Renal insufficiency			
eGFR >30 decrease from baseline	8 (10)	14 (39)	<0.001
Symptomatic skin rash	5 (6)	2 (6)	0.872
Immune-mediated graft dysfunction	6 (8)	4 (11)	0.535
Acute cellular rejection	3	0	
Chronic rejection	1	0	
Plasma cell hepatitis	0	4	
Veno-occlusive disease	2	0	
Infection	1 (1)	3 (8)	0.055

eGFR, estimated glomerular filtration rate; n, number of patients.

Table 3 Predictive factors associated with sustained virological response 12 weeks after treatment ended (SVR12) in patients with simeprevir triple therapy

		SVR <i>n</i> = 44	Non-SVR <i>n</i> = 35	<i>P</i> -value
Age, years		62.9 (5.2)	59.7 (8.4)	0.052†
Gender	Male	15 (43%)	20 (57%)	0.040‡
	Female	29 (66%)	15 (34%)	
Weight, kg		56.2 (10.5)	58.8 (11.1)	0.280†
Body mass index		22.7 (4.0)	22.5 (3.9)	0.860†
Graft type	Left	25 (62.5%)	15 (37.5%)	0.218‡
	Right	19 (49%)	20 (51%)	
Splenectomy	Yes	36 (55%)	30 (45%)	0.643‡
	No	8 (62%)	5 (38%)	
Months from LDLT to therapy		28 (2–118)	41 (5–147)	0.194§
Recipient IL28B genotype (rs8099917)	TT	30 (62.5%)	18 (37.5%)	0.181‡
	TG or GG	10 (45%)	12 (55%)	
	Not examined	4	5	
HCV RNA, log copies/mL		6.7 (0.6)	6.9 (0.5)	0.087†
Hemoglobin, g/dL		11.25 (8.1–15.8)	12.5 (8.5–16.0)	0.636§
eGFR, mL/min/1.73 m ²		57.5 (32.9–138.8)	62.8 (29.9–101.0)	0.459§
Calcineurin inhibitor	Tacrolimus	25 (52%)	23 (48%)	0.179‡
	Cyclosporine	19 (68%)	9 (32%)	
	None	0	3	
MMF	Yes	19 (53%)	17 (47%)	0.633‡
	No	25 (58%)	18 (42%)	
Prior dual therapy	Yes	29 (46%)	34 (54%)	0.001‡
	No	15 (94%)	1 (6%)	
Prior dual therapy	No response	14 (34%)	27 (66%)	<0.001‡
	Relapse or withdrawal or none	30 (79%)	8 (21%)	
Peginterferon	α-2a	12 (60%)	8 (40%)	0.654‡
	α-2b	32 (54%)	27 (46%)	

Qualitative variables are shown in number (%); quantitative variables are expressed as mean (standard deviation) for continuous variables that were nearly symmetrically distributed, or as median (range) for non-normally distributed variables.

†*t*-test.

‡ χ^2 -test.

§Wilcoxon test.

eGFR, estimated glomerular filtration rate; HCV, hepatitis C virus; IL28B, interleukin-28B; LDLT, living donor liver transplantation; MMF, mycophenolate mofetil.

given to all patients treated with telaprevir, whereas 20 patients (25%) in the simeprevir group received peginterferon α-2a.

Efficacy

Of the 79 patients treated with simeprevir-based triple therapy, 58 completed the treatment protocol, whereas 21 discontinued treatment due to adverse events (*n* = 10), no virological response (*n* = 7), or viral breakthrough during treatment (*n* = 4) (Fig. 1). Forty-four (56%) of 79 patients achieved SVR12. Of the 36 patients who received telaprevir-based triple therapy, 28 completed the treatment protocol, whereas 8 discontinued treatment because of adverse events (*n* = 7) or no virological response to the

treatment (*n* = 1). SVR12 was achieved in 25 patients (69%) who received telaprevir-based triple therapy.

Figure 2 shows the virological outcomes of simeprevir-based triple therapy and telaprevir-based triple therapy. The serum level of HCV RNA became undetectable within 4 weeks (i.e., RVR) in 48% and 53% of patients in the simeprevir and telaprevir groups, respectively, and >80% of the patients achieved cEVR in both groups. End-of-treatment response was achieved in 78% and 83% of the patients in the simeprevir and telaprevir groups, respectively. Finally, the SVR12 rates were 56% and 69% for simeprevir-based triple therapy and telaprevir-based triple therapy, respectively. Simeprevir-based triple therapy tended to have lower rates of RVR, cEVR, ETR, and SVR12

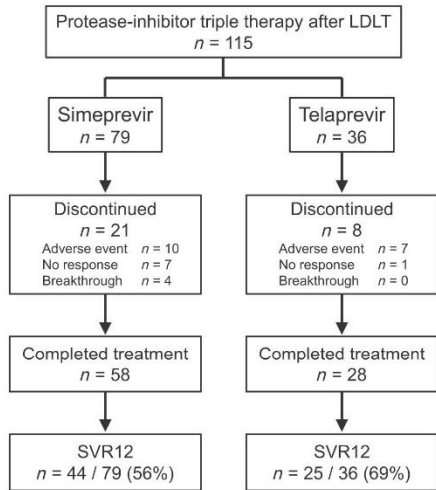


Figure 1 Flow diagram showing the outcomes of 115 patients treated with simeprevir or telaprevir with peginterferon and ribavirin after living-donor liver transplantation (LDLT). The numbers of patients who discontinued the treatment protocol (and their reasons for discontinuation), completed the treatment protocol, and achieved sustained virological response at week 12 (SVR12) after the termination of treatment are shown.

than telaprevir-based triple therapy, but the differences were not statistically significant.

Safety and tolerability

Adverse events that occurred during the triple therapies are summarized in Table 2. Adverse events occurred in 62% and 72% of patients, including serious adverse events in 11% and 25%, and death in 3% and 3% in the simeprevir- and telaprevir-based triple therapy groups, respectively. Treatment was discontinued due to adverse events in 13% and 19% of patients in the simeprevir and telaprevir groups, respectively. Dose modification of the DAAs, peginterferon, or ribavirin was required in 78 of 79 patients (99%) in the simeprevir group and in all patients (100%) in the telaprevir group. All patients, except for 10 patients (13%) who discontinued the treatment protocol, started receiving simeprevir triple therapy at the standard dose (100 mg/day) and continued the same dose until 12 weeks. Telaprevir was started at a reduced dose (1500 mg/day) in 34 (94%) of 36 patients and was discontinued in 8 patients (22%) until

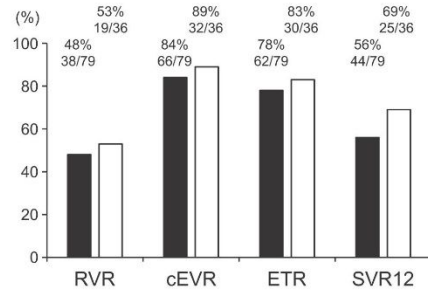


Figure 2 Virological responses in 115 patients treated with simeprevir- or telaprevir-based triple therapy (black and white bars, respectively) after living-donor liver transplantation. Rapid virological response (RVR), complete early virological response (cEVR), and end-of-treatment response (ETR) are defined as undetectable hepatitis C virus RNA in serum at 4 weeks, 12 weeks, and end of treatment, respectively. Sustained virological response at 12 weeks (SVR12) is defined as the absence of hepatitis C virus RNA in the serum for >12 weeks after the termination of treatment.

12 weeks of treatment. The reduced dose of peginterferon at treatment initiation was used in 6 (8%) and 4 (11%) patients, and a reduction from the initial dose during the treatment was required in 22 (28%) and 13 (36%) patients in the simeprevir and telaprevir groups, respectively. A reduced dose of ribavirin compared to the standard dose at treatment initiation was given in 63 (80%) and 35 (97%) patients, and a reduction in the ribavirin dose from the initial dose during treatment was required in 59 (75%) and 30 (83%) patients, including discontinuation in 31 (39%) and 13 (36%) patients, in the simeprevir and telaprevir groups, respectively.

There was no statistically significant difference in the rate of adverse events between the simeprevir and telaprevir groups, although serious adverse events tended to be more frequent in the telaprevir group than in the simeprevir group. The rate of patients who received blood cell transfusion and erythropoietin due to anemia were significantly higher in the telaprevir group than in the simeprevir group. Renal insufficiency, defined when the estimated glomerular filtration rate decreased >30 mL/min/1.73 m² from the baseline estimated glomerular filtration rate, was significantly less common in the simeprevir group than in the telaprevir group. Immune-mediated graft dysfunction occurred in 6 patients during simeprevir-based triple therapy, including 3 with acute cellular rejection, 2 with veno-occlusive disease, and 1 with chronic rejection. In

the telaprevir group, IGD occurred in 4 patients, and all had plasma cell hepatitis. Infection was observed in 3 patients in the simeprevir group (2 with a cytomegalovirus infection and 1 with pneumonia), whereas 1 patient had cholangitis in the telaprevir group. In the simeprevir group, 2 patients died of graft failure caused by chronic rejection 5 weeks after the termination of 31 weeks of treatment, and graft failure by infection at 2 weeks of treatment. One patient died of brain hemorrhage at 25 weeks of telaprevir-based triple therapy.

Factors predictive of SVR12 with simeprevir-based triple therapy

Baseline factors that could predict SVR12 with simeprevir-based triple therapy were analyzed by comparing patients in the SVR group ($n = 44$) with those in the non-SVR group ($n = 35$) (Table 3). Three factors, male sex ($P = 0.040$), the presence of prior dual therapy with peginterferon and ribavirin ($P = 0.001$), and non-responders to the prior dual therapy ($P < 0.001$), were identified as significant predictive factors for non-SVR. Associations of prior dual therapy with the efficacy of simeprevir- and telaprevir-based triple therapy are shown in Figure 3. In patients who received simeprevir-based triple therapy, the SVR12 rates were 94% in treatment-naïve patients, and 68%, 67%, and 34% in patients with relapse, withdrawal, and no response to the prior dual therapy, respectively. Differences between treatment-naïve patients and non-responders of prior dual therapy ($P < 0.001$), and between relapsers and non-responders ($P = 0.013$) were statistically significant. The impact of prior dual therapy on the treatment response of triple therapy was observed in both the telaprevir and simeprevir groups, although the difference was not significant in the telaprevir group.

DISCUSSION

IN THE CURRENT study, we showed the efficacy and safety of second-generation NS3/4A inhibitor simeprevir with peginterferon and ribavirin in patients with recurrent hepatitis C after LDLT. The SVR12 rate of simeprevir-based triple therapy was 56% overall, but it was 94% in treatment-naïve patients, indicating that simeprevir-based triple therapy is very effective when patients are selected according to their experience with prior therapy.

The efficacy and safety of first-generation NS3/4A inhibitors telaprevir and boceprevir in liver transplant recipients have been reported mainly in patients after deceased-donor liver transplantation (DDLT).^{15–18} Most studies have shown that triple therapy with telaprevir or boceprevir with peginterferon and ribavirin increased the SVR rate, but this resulted in many

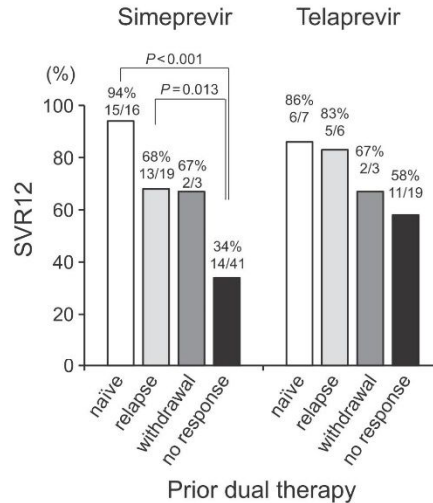


Figure 3 Rate of sustained virological response at 12 weeks (SVR12) after the termination of treatment with simeprevir- or telaprevir-based triple therapy following living-donor liver transplantation in treatment-naïve patients and relapsers, patients who withdrew, and non-responders to the prior dual therapy. P -values are shown if the differences are statistically significant ($P < 0.05$).

adverse events. In the present study, the SVR rate of telaprevir-based triple therapy was 69% in patients after LDLT, which is similar to the reported SVR rate of 50–63% in patients after DDLT.^{15–18} Severe adverse events, including anemia and renal insufficiency, which have been reported in a previous study on patients after DDLT, also occurred in the present study. These results indicate that the efficacy and safety of telaprevir-based triple therapy in patients after LDLT are similar to those in patients after DDLT.

Compared to telaprevir-based triple therapy, simeprevir-based triple therapy can be more easily administered to transplant recipients because no clinically significant interactions between simeprevir and calcineurin inhibitors have been observed.^{20,21} Although the overall incidence of adverse events was not significantly different between telaprevir and simeprevir, simeprevir tended to be associated with fewer serious adverse events than telaprevir. Blood cell transfusion and erythropoietin were less frequently used in the simeprevir group than in the telaprevir group, suggesting that less intensive management for anemia was needed

during simeprevir-based therapy. Moreover, the rate of renal insufficiency was significantly less in the simeprevir group than in the telaprevir group. Furthermore, IGD, including acute cellular rejection, chronic rejection, and plasma cell hepatitis, is one of the major adverse events of interferon-containing therapy in patients after liver transplantation.¹³ In this study, there was no difference in the incidence of IGD between the simeprevir and telaprevir groups. Therefore, in terms of safety, simeprevir-based triple therapy is superior to telaprevir-based triple therapy.

The efficacy of simeprevir-based triple therapy was not satisfactory; the SVR rate was 56%. The virological responses, including the RVR, cEVR, ETR, and SVR12, of simeprevir-based triple therapy tended to be lower than those of telaprevir-based triple therapy. To achieve a higher efficacy of simeprevir-based triple therapy in liver transplant recipients, it is necessary to select patients before treatment. An analysis of the predictive factors associated with SVR showed that the presence and efficacy of prior dual therapy are important for predicting the efficacy of simeprevir-based triple therapy. Notably, 94% of treatment-naïve patients achieved SVR12 with simeprevir-based triple therapy, whereas the SVR12 rate in non-responders to prior dual therapy was only 34%. Similar results have been shown in Japanese phase III trials on patients in non-transplant settings; the SVR12 rates of simeprevir-based triple therapy were 88.6%, 95.9%, and 52.8% in treatment-naïve patients, relapsers, and non-responders to prior interferon-based therapy, respectively.^{23,36} As the efficacy of dual therapy is determined by multiple factors, including host IL28B genotypes and HCV genomic mutations, these factors may also affect the efficacy of simeprevir-based triple therapy, resulting in the low efficacy of simeprevir-based triple therapy in non-responders to dual therapy. In our study, female patients had a significantly higher SVR12 rate with simeprevir-based triple therapy compared to male patients, although the reason for this difference is unknown. These predictive factors may help in selecting patients before administering simeprevir-based triple therapy, and the efficacy may be higher by selecting patients according to the status of prior dual therapy and sex.

Recent reports have indicated a higher efficacy and safety of interferon-free therapy in liver transplant recipients compared to second-generation NS3/4A inhibitor-based triple therapy clarified in the present study.^{29–32} Therefore, interferon-free therapy should be used as first-line therapy for recurrent hepatitis C after liver transplantation, according to the recent recommendation for hepatitis C treatment.³³ The SVR rate of interferon-free therapy in liver transplant recipients is reportedly 70–97%,^{29–32} and resistance-associated variants to DAAs were detected in

most of the remaining non-SVR patients.^{29,31} Second-line therapy with interferon-free therapy for non-SVR patients has not yet been established. As interferon's broad antiviral activity will help clear DAA-resistant IICV, interferon-containing therapy would be one of the choices as second-line therapy for hepatitis C after liver transplantation. Therefore, the efficacy and safety of simeprevir-based therapy clarified in the present study will provide useful information even in the interferon-free therapy era.

In conclusion, simeprevir-based triple therapy for recurrent hepatitis C after LDLT resulted in an SVR rate of 56% and good tolerability. Although this therapy is not recommended for non-responders to prior dual therapy because of low efficacy, simeprevir-based triple therapy may be one of the options for treatment-naïve patients. An individualized treatment strategy that predicts the efficacy and safety of treatment will result in more effective and safer treatment for liver transplant recipients in the DAA era.

ACKNOWLEDGMENTS

THIS RESEARCH WAS supported by the Research Program on Hepatitis from Japan Agency for Medical Research and Development, AMED

REFERENCES

- 1 Feray C, Caccamo L, Alexander GJ *et al.* European collaborative study on factors influencing outcome after liver transplantation for hepatitis C. European Concerted Action on Viral Hepatitis (EUROHEP) Group. *Gastroenterology* 1999; **117**: 619–25.
- 2 Forman LM, Lewis JD, Berlin JA, Feldman HI, Lucey MR. The association between hepatitis C infection and survival after orthotopic liver transplantation. *Gastroenterology* 2002; **122**: 889–96.
- 3 Prieto M, Berenguer M, Rayon JM *et al.* High incidence of allograft cirrhosis in hepatitis C virus genotype 1b infection following transplantation: relationship with rejection episodes. *Hepatology* 1999; **29**: 250–6.
- 4 Belli LS, Burroughs AK, Burra P *et al.* Liver transplantation for HCV cirrhosis: improved survival in recent years and increased severity of recurrent disease in female recipients: results of a long term retrospective study. *Liver Transpl* 2007; **13**: 733–40.
- 5 Berenguer M, Ferrell L, Watson J *et al.* HCV-related fibrosis progression following liver transplantation: increase in recent years. *J Hepatol* 2000; **32**: 673–84.
- 6 Neumann UP, Berg T, Bahra M *et al.* Fibrosis progression after liver transplantation in patients with recurrent hepatitis C. *J Hepatol* 2004; **41**: 830–6.
- 7 Walter T, Dumortier J, Guillaud O, Hervieu V, Scoazec JY, Boillot O. Factors influencing the progression of fibrosis in patients with recurrent hepatitis C after liver transplantation

- under antiviral therapy: a retrospective analysis of 939 liver biopsies in a single center. *Liver Transpl* 2007; 13: 294–301.
- 8 Yilmaz N, Shiffman ML, Stravitz RT *et al*. A prospective evaluation of fibrosis progression in patients with recurrent hepatitis C virus following liver transplantation. *Liver Transpl* 2007; 13: 975–83.
 - 9 Thuluvath PJ, Guidinger MK, Fung JJ, Johnson LB, Rayhill SC, Pelletier SJ. Liver transplantation in the United States, 1999–2008. *Am J Transplant* 2010; 10: 1003–19.
 - 10 Gordon FD, Kwo P, Vargas HE. Treatment of hepatitis C in liver transplant recipients. *Liver Transpl* 2009; 15: 126–35.
 - 11 Terrault NA. Hepatitis C therapy before and after liver transplantation. *Liver Transpl* 2008; 14(Suppl 2): S58–66.
 - 12 Berenguer M. Systematic review of the treatment of established recurrent hepatitis C with pegylated interferon in combination with ribavirin. *J Hepatol* 2008; 49: 274–87.
 - 13 Levitsky J, Fiel MI, Norvell JP *et al*. Risk for immune-mediated graft dysfunction in liver transplant recipients with recurrent HCV infection treated with pegylated interferon. *Gastroenterology* 2012; 142: 1132–9 e1.
 - 14 Garg V, van Heeswijk R, Lee JE, Alves K, Nadkarni P, Luo X. Effect of telaprevir on the pharmacokinetics of cyclosporine and tacrolimus. *Hepatology* 2011; 54: 20–7.
 - 15 Burton JR Jr, O’Leary JG, Verna EC *et al*. A US multicenter study of hepatitis C treatment of liver transplant recipients with protease-inhibitor triple therapy. *J Hepatol* 2014; 61: 508–14.
 - 16 Coilly A, Roche B, Dumortier J *et al*. Safety and efficacy of protease inhibitors to treat hepatitis C after liver transplantation: a multicenter experience. *J Hepatol* 2014; 60: 78–86.
 - 17 Faisal N, Yoshida EM, Bilodeau M *et al*. Protease inhibitor-based triple therapy is highly effective for hepatitis C recurrence after liver transplant: a multicenter experience. *Ann Hepatol* 2014; 13: 525–32.
 - 18 Pungpapong S, Aql BA, Koning L *et al*. Multicenter experience using telaprevir or boceprevir with peginterferon and ribavirin to treat hepatitis C genotype 1 after liver transplantation. *Liver Transpl* 2013; 19: 690–700.
 - 19 Fontana RJ, Hughes EA, Bifano M *et al*. Sofosbuvir and daclatasvir combination therapy in a liver transplant recipient with severe recurrent cholestatic hepatitis C. *Am J Transplant* 2013; 13: 1601–5.
 - 20 Tanaka T, Sugawara Y, Akamatsu N *et al*. Use of simeprevir following pre-emptive pegylated interferon/ribavirin treatment for recurrent hepatitis C in living donor liver transplant recipients: a 12-week pilot study. *J Hepatobiliary Pancreat Sci* 2015; 22: 144–50.
 - 21 Ueda Y, Kaido T, Uemoto S. Fluctuations in the concentration/dose ratio of calcineurin inhibitors after simeprevir administration in patients with recurrent hepatitis C after liver transplantation. *Transpl Int* 2015; 28: 251–2.
 - 22 Forns X, Lawitz E, Zeuzem S *et al*. Simeprevir with peginterferon and ribavirin leads to high rates of SVR in patients with HCV genotype 1 who relapsed after previous therapy: a phase 3 trial. *Gastroenterology* 2014; 146: 1669–79 e3.
 - 23 Hayashi N, Izumi N, Kumada H *et al*. Simeprevir with peginterferon/ribavirin for treatment-naïve hepatitis C genotype 1 patients in Japan: CONCERTO-1, a phase III trial. *J Hepatol* 2014; 61: 219–27.
 - 24 Jacobson IM, Dore GJ, Foster GR *et al*. Simeprevir with pegylated interferon alfa 2a plus ribavirin in treatment-naïve patients with chronic hepatitis C virus genotype 1 infection (QUEST-1): a phase 3, randomised, double-blind, placebo-controlled trial. *Lancet* 2014; 384: 403–13.
 - 25 Manns M, Marcellin P, Poordad F *et al*. Simeprevir with pegylated interferon alfa 2a or 2b plus ribavirin in treatment-naïve patients with chronic hepatitis C virus genotype 1 infection (QUEST-2): a randomised, double-blind, placebo-controlled phase 3 trial. *Lancet* 2014; 384: 414–26.
 - 26 Jacobson IM, McHutchison JG, Dusheiko G *et al*. Telaprevir for previously untreated chronic hepatitis C virus infection. *N Engl J Med* 2011; 364: 2405–16.
 - 27 Kumada H, Toyota J, Okanou T, Chayama K, Tsubouchi H, Hayashi N. Telaprevir with peginterferon and ribavirin for treatment-naïve patients chronically infected with HCV of genotype 1 in Japan. *J Hepatol* 2012; 56: 78–84.
 - 28 Zeuzem S, Andreone P, Pol S *et al*. Telaprevir for retreatment of HCV infection. *N Engl J Med* 2011; 364: 2417–28.
 - 29 Charlton M, Everson GT, Flamm SL *et al*. Ledipasvir and sofosbuvir plus ribavirin for treatment of HCV infection in patients with advanced liver disease. *Gastroenterology* 2015; 149: 649–59.
 - 30 Charlton M, Gane E, Manns MP *et al*. Sofosbuvir and ribavirin for treatment of compensated recurrent hepatitis C virus infection after liver transplantation. *Gastroenterology* 2015; 148: 108–17.
 - 31 Kwo PY, Mantry PS, Coakley E *et al*. An interferon-free antiviral regimen for HCV after liver transplantation. *N Engl J Med* 2014; 371: 2375–82.
 - 32 Pungpapong S, Aql B, Leise M *et al*. Multicenter experience using simeprevir and sofosbuvir with or without ribavirin to treat hepatitis C genotype 1 after liver transplant. *Hepatology* 2015; 61: 1880–6.
 - 33 Panel AHG. Hepatitis C guidance: AASLD-IDS recommendations for testing, managing, and treating adults infected with hepatitis C virus. *Hepatology* 2015; 62: 932–54.
 - 34 Ohno O, Mizokami M, Wu RR *et al*. New hepatitis C virus (HCV) genotyping system that allows for identification of HCV genotypes 1a, 1b, 2a, 2b, 3a, 3b, 4, 5a, and 6a. *J Clin Microbiol* 1997; 35: 201–7.
 - 35 Ito K, Higami K, Masaki N *et al*. The rs8099917 polymorphism, when determined by a suitable genotyping method, is a better predictor for response to pegylated alpha interferon/ribavirin therapy in Japanese patients than other single nucleotide polymorphisms associated with interleukin-28B. *J Clin Microbiol* 2011; 49: 1853–60.
 - 36 Izumi N, Hayashi N, Kumada H *et al*. Once-daily simeprevir with peginterferon and ribavirin for treatment-experienced HCV genotype 1-infected patients in Japan: the CONCERTO-2 and CONCERTO-3 studies. *J Gastroenterol* 2014; 49: 941–53.

CASE REPORT

Open Access

Neuroendocrine tumor of the ampulla of Vater with distant cystic lymph node metastasis: a case report



Mariko Tsukagoshi^{1,2}, Yasuo Hosouchi², Kenichiro Araki^{1*}, Yasushi Mochida¹, Ryusuke Aihara^{1,2}, Ken Shirabe³ and Hiroyuki Kuwano¹

Abstract

Background: Neuroendocrine tumors (NETs) of the ampulla of Vater are rare and difficult to diagnose. We report a rare case of a small NET of the ampulla of Vater with metastasis to distant lymph nodes.

Case presentation: The patient was a 54-year-old man complaining of epigastric pain and melena. Upper gastrointestinal endoscopy revealed a bulging papilla with active bleeding, which was diagnosed as a well-differentiated NET of the ampulla of Vater. An approximately 10-mm hypervascular tumor at the ampulla of Vater and a 41-mm cyst adjacent to the wall of the jejunum were revealed by abdominal computed tomography. We performed pylorus-preserving pancreaticoduodenectomy with lymph node dissection. Macroscopic examination revealed a 9-mm tumor of the ampulla of Vater and a 52-mm cyst adjacent to the wall of the jejunum. Histological examination revealed that the cyst was a lymph node metastasis. The final diagnosis was non-functional NET G1 of the ampulla of Vater, designated T1N1M0 stage IIIB. Postoperatively, the patient underwent no treatment and has had no recurrence for 4 years.

Conclusions: This case demonstrates that sporadic NETs of Vater's papilla have aggressive metastatic potential even with a small primary lesion, and radical resection with lymphadenectomy is recommended for all cases.

Keywords: Neuroendocrine tumor, Lymph node metastases, Ampulla of Vater, Surgical resection

Background

Neuroendocrine tumors (NETs) of the ampulla of Vater are rare [1, 2]. A total of 139 patients with NETs of the ampulla were identified from the Surveillance, Epidemiology, and End Results Program of the National Cancer Institute between 1973 and 2006 [3]. The incidence of NETs has been rising due to an improvement in diagnostic techniques, and the mortality rate has also been increasing in recent years [4, 5]. There are still many issues regarding diagnosis and treatment.

There is no curative treatment for NETs, except surgical resection. In general, a tumor size greater than 2 cm in diameter, invasion of the muscularis propria, and presence of mitotic figures are correlated with metastasis

of NETs [6]. Therefore, surgery has been recommended for tumors larger than 2 cm.

In the cases of duodenal NETs, tumors smaller than 2 cm have limited metastatic potential [7, 8]. However, unlike NETs in other areas, it has been demonstrated that tumor size has no correlation with metastatic potential in NETs of the ampulla of Vater [1, 9]. Thus, the best therapeutic approach for ampullary NETs remains controversial.

Herein, we report our experience with a rare case of 9-mm ampullary NET with lymph node metastasis and review the current literatures on the topic.

Case presentation

A 54-year-old man presented with a history of epigastric pain and melena over the last few days. The patient did not have hormone-related symptoms. He had received treatment for a myocardial infarction at the age of 51

* Correspondence: karaki@gunma-u.ac.jp

¹Department of General Surgical Science, Gunma University Graduate School of Medicine, 3-39-22 Showa-machi, Maebashi, Gunma 371-8511, Japan

Full list of author information is available at the end of the article



© 2016 The Author(s). **Open Access** This article is distributed under the terms of the Creative Commons Attribution 4.0 International License (<http://creativecommons.org/licenses/by/4.0/>), which permits unrestricted use, distribution, and reproduction in any medium, provided you give appropriate credit to the original author(s) and the source, provide a link to the Creative Commons license, and indicate if changes were made.

with an antiplatelet therapy; therefore, we considered that there was a possibility of tumor bleeding by antiplatelet therapy. Blood biochemical examinations indicated slight anemia. Serum carbohydrate antigen 19-9 and carcinoembryonic antigen (CEA) levels were not elevated. The 24-h urinary 5-hydroxyindoleacetic acid (5-HIAA) level was 3.2 mg. Upper gastrointestinal endoscopy showed a bulging papilla with bleeding (Fig. 1a). A biopsy was not performed at that time because of the active bleeding. Endoscopic examination on day 7 revealed an approximately 10-mm mass of the ampulla of Vater with a superficial ulcer (Fig. 1b). Pathological findings of the endoscopic biopsy of the ampulla revealed a well-differentiated NET. Immunohistochemically, the tumor stained positive for CD56, chromogranin A, and synaptophysin. An upper gastrointestinal series showed an ampullary mass without any obvious lesions of the jejunum (Fig. 1c). An enhanced abdominal computed tomography (CT) scan revealed a 10-mm hypervascular tumor at the ampulla of Vater and a 41-mm multilocular cyst adjacent to the wall of the jejunum near the ligament of Treitz (Fig. 2). The wall of the multilocular cyst showed the same enhancement patterns with the tumor.

The patient underwent magnetic resonance imaging that was negative for visceral metastasis. About the cyst, the preoperative definitive diagnosis was not provided.

The patient was referred to our hospital for treatment of the NET. We performed a pylorus-preserving pancreaticoduodenectomy with regional lymph node dissection. The operative time was 497 min, and the volume of blood loss during the surgery was 1220 ml. The resected specimen was macroscopically a 9-mm white solid tumor (Fig. 3). Tumor cells confined to duodenal mucosal layer. There was a 52-mm cyst in the superior mesentery adjacent to the wall of the jejunum (Fig. 3). Microscopically, the tumor consisted of small-sized round cell proliferations with a solid nest pattern (Fig. 4a). The cyst preserved the structure of the lymph node and was the superior mesenteric lymph node metastasis of the tumor (Fig. 4b). We performed D2 lymph node dissection, and there was no metastatic lymph node except for the superior mesenteric lymph node. Immunohistochemically, the resected specimen revealed that the tumor and the lymph node metastasis were positive for chromogranin A (Fig. 4c) and CD56 and negative for synaptophysin. The Ki-67-labeling index of

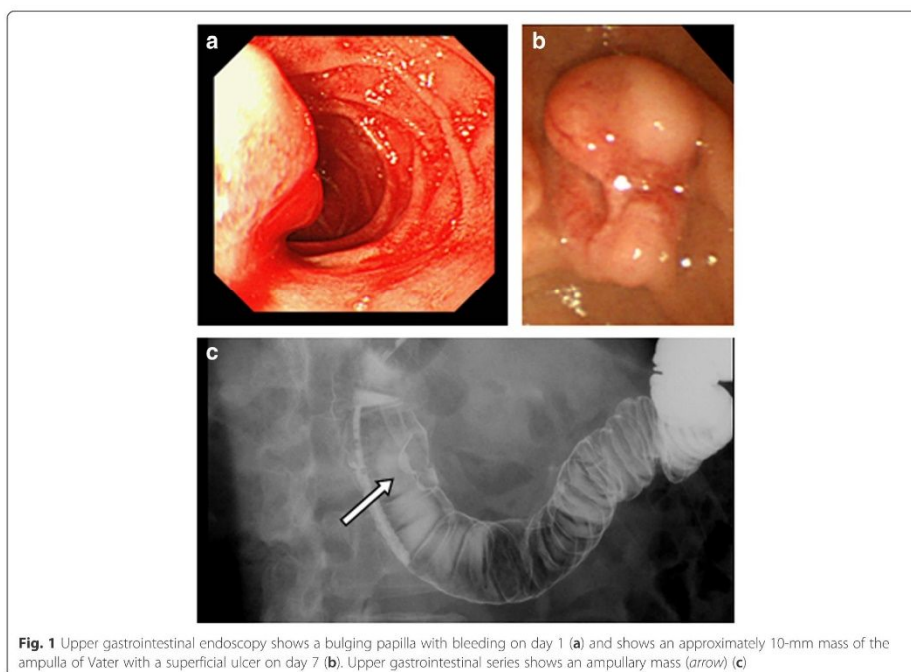


Fig. 1 Upper gastrointestinal endoscopy shows a bulging papilla with bleeding on day 1 (a) and shows an approximately 10-mm mass of the ampulla of Vater with a superficial ulcer on day 7 (b). Upper gastrointestinal series shows an ampullary mass (arrow) (c)

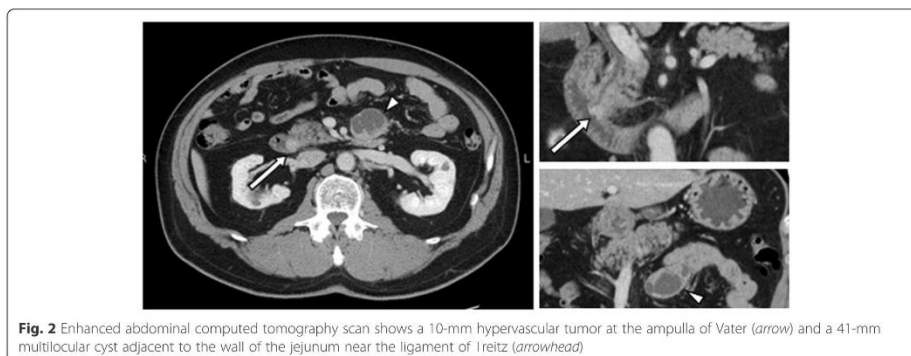


Fig. 2 Enhanced abdominal computed tomography scan shows a 10-mm hypervascular tumor at the ampulla of Vater (arrow) and a 41-mm multilocular cyst adjacent to the wall of the jejunum near the ligament of Treitz (arrowhead)

the tumor cells determined with MIB-1 was 2.0 %. The final diagnosis was sporadic non-functional NET G1 of the ampulla of Vater (pT1N1M0 stage IIIB). The patient was discharged 36 days after the operation. He has had no recurrence for 4 years after surgery. No further treatment was administered.

Discussion

NETs of the ampulla of Vater are rare and difficult to diagnose [1, 2]. Jaundice (60 %) and abdominal pain (40 %) are the most frequent symptoms. Upper gastrointestinal bleeding is a rare presentation (<3 %) [1, 10]. In our case, the patient presented with abdominal pain and melena. On admission, upper gastrointestinal endoscopy revealed a bulging papilla with active bleeding. When we performed gastric endoscopy again 7 days later, we found a 10-mm mass of the ampulla of Vater with a superficial ulcer.

Diagnosis of NETs is established by histological and immunohistochemical analysis of endoscopic biopsy

specimens [11]. NETs of the ampulla of Vater usually appear as submucosal masses that are small and spherical with a smooth surface and an intact duodenal mucosa. Consequently, superficial biopsies are negative and deeper biopsies are required for a diagnosis [12, 13]. In our present case, we could get the biopsy specimen from the mass because it had an ulcerated surface. Thus, the correct diagnosis of a NET was established preoperatively. However, we could not diagnose the cyst adjacent to the wall of the jejunum as a lymph node metastasis at the time of resection.

Previous reports have suggested that the biological behavior of ampullary NETs is distinct from that of duodenal NETs and they are more aggressive [14]. Randle and colleagues reported that ampullary NETs were larger, higher grade, and higher stage and had a higher rate of lymph node metastasis than duodenal NETs [15]. The incidence of lymph node metastases in patients with resected ampullary NETs and duodenal NETs was 72.9 and 48.4 %, respectively.

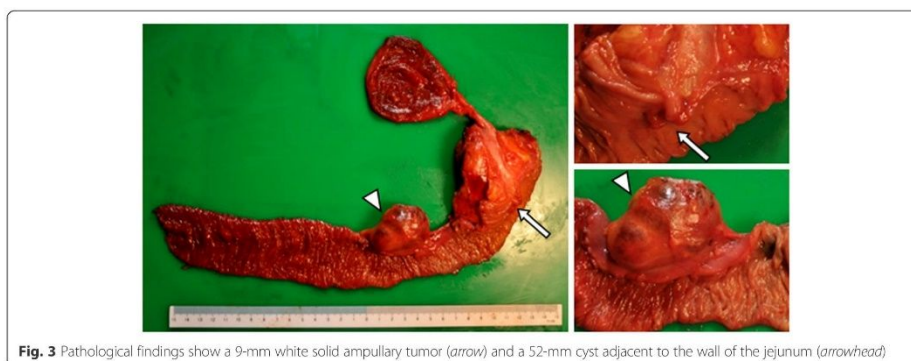


Fig. 3 Pathological findings show a 9-mm white solid ampullary tumor (arrow) and a 52-mm cyst adjacent to the wall of the jejunum (arrowhead)

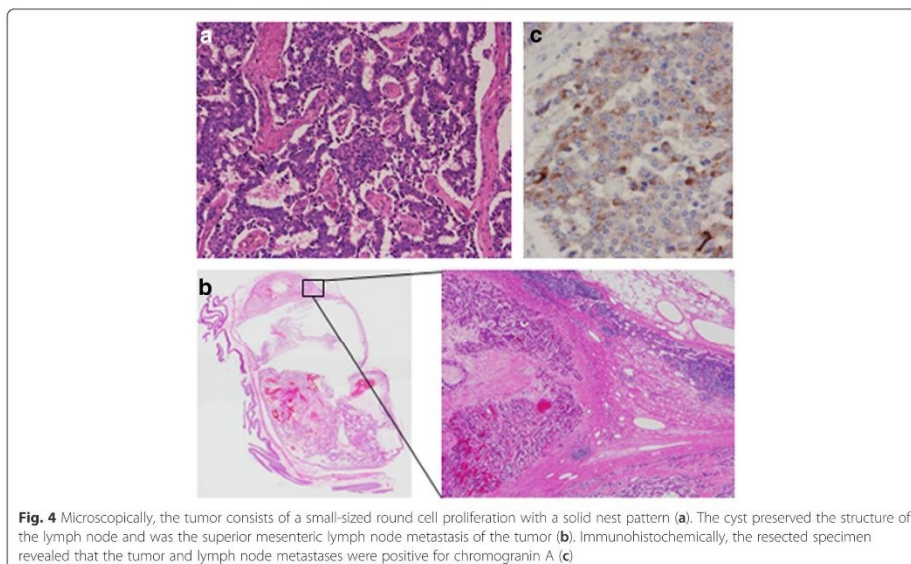


Fig. 4 Microscopically, the tumor consists of a small-sized round cell proliferation with a solid nest pattern (a). The cyst preserved the structure of the lymph node and was the superior mesenteric lymph node metastasis of the tumor (b). Immunohistochemically, the resected specimen revealed that the tumor and lymph node metastases were positive for chromogranin A (c)

In the case of ampullary NETs, even in tumors smaller than 2 cm, a high percentage have lymph node metastases [14, 16–18]. Nikou et al. reported that lymph node metastases were found in two cases of ampullary NET with tumor sizes of 1.0 and 1.2 cm, respectively [19]. In the present case, the histologic examination revealed metastasis to distant lymph nodes despite the tumor only being 9 mm in diameter and within duodenal mucosal layer. These findings suggest that there is no correlation between tumor size and metastatic potential in ampullary NETs. We consider that an anatomical reason is one of the reasons why NETs at the ampulla of Vater have high incidence of metastasis. Ampullary carcinoma with perisphincteric or duodenal submucosal invasion showed more frequent lymph node metastasis and a greater tumor recurrence rate than tumor limited within the sphincter of Oddi muscle [20]. Moreover, the perisphincteric and duodenal submucosal space is relatively small and closer to the next layering of duodenal proper muscle and the pancreas. Thus, the malignant potential of perisphincteric and/or duodenal submucosal invasion may be greater than that of other gastrointestinal tract tumors. Moreover, previous studies have reported that lymph node metastasis is difficult to detect on preoperative imaging [18, 21]. Although some authors report the existence of lymph node metastasis of NETs is not correlated with patient prognosis, this could be due to

metastasis to the liver or some other organ, which is an important prognostic factor for NETs. Therefore, radical resection with lymph node dissection is recommended as a treatment of ampullary NETs regardless of tumor size [1, 14, 18, 22, 23].

We performed a pylorus-preserving pancreaticoduodenectomy with regional lymph node resection and also resected a 52-mm lymphatic metastasis adjacent to the wall of the jejunum. Despite the lymph node involvement, the Ki-67-labeling index was low (2 %) and the patient has had no evidence of recurrence for 4 years after surgery.

Randle et al. indicated that tumor size was correlated with poor prognosis, but the presence of positive lymph nodes was not a predictive outcome in resected ampullary NETs [15]. Untch et al. reported that only tumor size and tumor grade were associated with recurrence [24]. Thus, we can perform radical resection and completely remove the tumor with good clinical outcomes.

Conclusions

In conclusion, NETs of the ampulla of Vater, even very small tumors (<1 cm), may have aggressive metastatic potential. A radical resection with lymphadenectomy might be the appropriate treatment strategy for sporadic NETs of the ampulla of Vater.

Consent

Written informed consent was obtained from the patient for publication of this case report and any accompanying images.

Abbreviations

5-HIAA, 5-hydroxyindoleacetic acid; CEA, carcinoembryonic antigen; CT, computed tomography; NET, neuroendocrine tumor

Acknowledgements

None.

Funding

The authors declare that they have no financial support in association with this case report.

Authors' contributions

MT reported the case and wrote the manuscript. MT, YH, YM, and RA performed the surgery and perioperative management of the patient and helped draft the manuscript. KA, KS, and HK participated in revising the manuscript critically. All authors declare that they contributed to this article and that they read and approved the final manuscript.

Competing interests

The authors declare that they have no competing interests.

Author details

¹Department of General Surgical Science, Gunma University Graduate School of Medicine, 3-39-22 Showa-machi, Maebashi, Gunma 371-8511, Japan.

²Department of Surgery and Laparoscopic Surgery, Gunma Prefecture Saiseikai-Maebashi Hospital, 564-1 Kamishinden-machi, Maebashi, Gunma 371-0821, Japan. ³Department of Hepatobiliary and Pancreatic Surgery, Gunma University Graduate School of Medicine, 3-39-22 Showa-machi, Maebashi, Gunma 371-8511, Japan.

Received: 18 March 2016 Accepted: 13 July 2016

Published online: 25 July 2016

References

- Hatzitheoklitos E, Buchler MW, Friess H, Poch B, Ebert M, Mohr W, et al. Carcinoid of the ampulla of Vater. Clinical characteristics and morphologic features. *Cancer*. 1994;73:1580–8.
- Makhlouf HR, Burke AP, Sobin LH. Carcinoid tumors of the ampulla of Vater: a comparison with duodenal carcinoid tumors. *Cancer*. 1999;85:1241–9.
- Albores-Saavedra J, Hart A, Chable-Montero F, Henson DE. Carcinoids and high-grade neuroendocrine carcinomas of the ampulla of Vater: a comparative analysis of 139 cases from the surveillance, epidemiology, and end results program—a population based study. *Arch Pathol Lab Med*. 2010;134:1692–6.
- Hemminki K, Li X. Incidence trends and risk factors of carcinoid tumors: a nationwide epidemiologic study from Sweden. *Cancer*. 2001;92:2204–10.
- Mocellin S, Nitti D. Gastrointestinal carcinoid: epidemiological and survival evidence from a large population-based study (n = 25 531). *Ann Oncol*. 2013;24:3040–4.
- Burke AP, Federspiel BH, Sobin LH, Shekitka KM, Helwig EB. Carcinoids of the duodenum. A histologic and immunohistochemical study of 65 tumors. *Am J Surg Pathol*. 1989;13:828–37.
- Burke AP, Sobin LH, Federspiel BH, Shekitka KM, Helwig EB. Carcinoid tumors of the duodenum. A clinicopathologic study of 99 cases. *Arch Pathol Lab Med*. 1990;114:700–4.
- Zyromski NJ, Kendrick ML, Nagorney DM, Grant CS, Donohue JH, Farnell MB, et al. Duodenal carcinoid tumors: how aggressive should we be? *J Gastrointest Surg*. 2001;5:588–93.
- Rohan VS, Narendra H, Patel JJ, Tankshali RA. Carcinoid of ampulla of Vater. *Indian J Cancer*. 2007;44:90–2.
- De Palma GD, Masone S, Siciliano S, Maione F, Falletti J, Mansueti G, et al. Endocrine carcinoma of the major papilla: report of two cases and review of the literature. *Surg Oncol*. 2010;19:235–42.
- Hartel M, Wente MN, Sido B, Friess H, Buchler MW. Carcinoid of the ampulla of Vater. *J Gastroenterol Hepatol*. 2005;20:676–81.

- Mullen JT, Wang H, Yao JC, Lee JH, Perrier ND, Fisters PW, et al. Carcinoid tumors of the duodenum. *Surgery*. 2005;138:971–7. discussion 977–978.
- Waisberg J, Joppert-Netto G, Vasconcellos C, Sartini GH, Miranda LS, Franco M. Carcinoid tumor of the duodenum: a rare tumor at an unusual site. Case series from a single institution. *Arq Gastroenterol*. 2013;50:3–9.
- Clements WM, Martin SP, Stemmerman G, Lowy AM. Ampullary carcinoid tumors: rationale for an aggressive surgical approach. *J Gastrointest Surg*. 2003;7:773–6.
- Randle RW, Ahmed S, Newman NA, Clark CJ. Clinical outcomes for neuroendocrine tumors of the duodenum and ampulla of Vater: a population-based study. *J Gastrointest Surg*. 2013.
- Ricci JL. Carcinoid of the ampulla of Vater. Local resection or pancreaticoduodenectomy. *Cancer*. 1993;71:686–90.
- Hubalewska-Dydejczyk A, Trofimiuk M, Sowa-Staszczak A, Gills-Januszewska A, Baczyńska E, Szybinski P, et al. Neuroendocrine tumours of rare location. *Endokrynol Pol*. 2010;61:322–7.
- Carter JT, Grenert JP, Rubenstein L, Stewart L, Way LW. Neuroendocrine tumors of the ampulla of Vater: biological behavior and surgical management. *Arch Surg*. 2009;144:527–31.
- Nikou GC, Toubanakis C, Moulakakis KG, Pavlatos S, Kosmidis C, Mallas E, et al. Carcinoid tumors of the duodenum and the ampulla of Vater: current diagnostic and therapeutic approach in a series of 8 patients. *Case Series Int J Surg*. 2011;9:248–53.
- You D, Heo J, Choi S, Choi D, Jang KT. Pathologic T1 subclassification of ampullary carcinoma with perisphincteric or duodenal submucosal invasion: is it T1b? *Arch Pathol Lab Med*. 2014;138:1072–6.
- Dumitrascu T, Dima S, Herlea V, Tomulescu V, Ionescu M, Popescu I. Neuroendocrine tumours of the ampulla of Vater: clinico-pathological features, surgical approach and assessment of prognosis. *Langenbecks Arch Surg*. 2012;397:933–43.
- Modlin IM, Lye KD, Kidd M. A 5-decade analysis of 13,715 carcinoid tumors. *Cancer*. 2003;97:934–59.
- Hwang S, Lee SG, Lee YJ, Han DJ, Kim SC, Kwon SH, et al. Radical surgical resection for carcinoid tumors of the ampulla. *J Gastrointest Surg*. 2008;12:713–7.
- Untch BR, Bonner KP, Roggin KK, Reidy-Lagunes D, Klimstra DS, Schattner MA, et al. Pathologic grade and tumor size are associated with recurrence-free survival in patients with duodenal neuroendocrine tumors. *J Gastrointest Surg*. 2014;18:457–62. discussion 462–53.

Submit your manuscript to a SpringerOpen® journal and benefit from:

- Convenient online submission
- Rigorous peer review
- Immediate publication on acceptance
- Open access: articles freely available online
- High visibility within the field
- Retaining the copyright to your article

Submit your next manuscript at ► springeropen.com