

## Original Article

## Functional remnant liver assessment predicts liver-related morbidity after hepatic resection in patients with hepatocellular carcinoma

Shinji Itoh,<sup>1</sup> Tomoharu Yoshizumi,<sup>1</sup> Ken Shirabe,<sup>1</sup> Koichi Kimura,<sup>1</sup> Hirohisa Okabe,<sup>1</sup> Norifumi Harimoto,<sup>1</sup> Toru Ikegami,<sup>1</sup> Hideaki Uchiyama,<sup>1</sup> Akihiro Nishie<sup>2</sup> and Yoshihiko Maehara<sup>1</sup>

Departments of <sup>1</sup>Surgery and Science, and <sup>2</sup>Clinical Radiology, Graduate School of Medical Sciences, Kyushu University, Fukuoka, Japan

**Aim:** We aimed to evaluate whether functional assessment of the future remnant liver is a predictor of postoperative morbidity after hepatic resection in patients with hepatocellular carcinoma (HCC).

**Methods:** One hundred forty-six patients who underwent hepatic resection for HCC were enrolled in this study. Gadolinium-ethoxybenzyl-diethylenetriamine pentaacetic acid enhanced MRI (EOB-MRI) analysis for functional liver assessment was carried out before hepatic resection. The signal intensity in the remnant liver was measured and divided by the signal intensity of the major psoas muscle (the liver to major psoas muscle ratio, LMR) for standardization. The remnant liver function was calculated using the formula (LMR on the hepatobiliary phase/LMR on the precontrast image). Computed tomography liver volumetry was also carried out. The remnant functional liver was calculated as the remnant liver volume or volumetric rate  $\times$  remnant liver function by EOB-MRI.

**Results:** Morbidities developed in 19 (13.0%) patients. Morbidities associated with the liver occurred in 7 patients (4.7%). There was no mortality during surgery. Median remnant liver function scores using EOB-MRI and remnant functional liver using volumetric rate or volumetry were 1.82 (range, 1.25–2.96), 155.9 (range, 64.7–285.3), and 1027 (range, 369–2148), respectively. Logistic regression analysis identified the remnant functional liver volume as the only independent predictor for liver-related morbidity.

**Conclusion:** Remnant functional liver volume using computed tomography liver volumetry and EOB-MRI was a significantly useful predictor for liver-related morbidity after hepatic resection in patients with HCC.

**Key words:** EOB-MRI, functional remnant liver, hepatic resection, morbidity

### INTRODUCTION

HEPATOCELLULAR CARCINOMA (HCC) is the most prevalent epithelial cancer of the liver and one of the most common causes of death in many countries, especially in Japan.<sup>1,2</sup> Hepatic resection has been established as a safe and effective treatment for HCC.<sup>3,4</sup> Although surgical techniques and postoperative management have recently improved,<sup>5,6</sup> postoperative morbidity in patients with HCC remains elevated.<sup>7,8</sup> Liver dysfunction is the major cause of postoperative morbidity and mortality after hepatic resection. Therefore, accurate estimation of the

remnant functional liver volume is one of the most important issues for reducing postoperative morbidity after hepatic resection for patients with HCC.

Gadolinium-ethoxybenzyl-diethylenetriamine pentaacetic acid (Gd-EOB-DTPA) is a magnetic resonance imaging (MRI) contrast medium used to examine the hepatobiliary system.<sup>9</sup> Because of uptake of Gd-EOB-DTPA in the hepatocytes specifically, Gd-EOB-DTPA enhanced MRI (EOB-MRI) can reflect the function of the liver.<sup>10</sup> Several studies have reported that EOB-MRI correlates with biochemical liver function tests including indocyanine green (ICG) retention rate and prothrombin time, and hepatobiliary scintigraphy with technetium-99m (Tc-99m) iminodiacetic acid or Tc-99m galactosyl human serum albumin (GSA).<sup>10,11</sup> This suggests that EOB-MRI could be used for the quantitative analysis of regional liver function. The present study investigated

Correspondence: Dr Shinji Itoh, Department of Surgery and Science, Graduate School of Medical Sciences, Kyushu University, 3-1-1 Maidashi, Higashi-ku, Fukuoka 812-8582, Japan. Email: itoshin@surg2.med.kyushu-u.ac.jp

Conflict of interest: The authors have no conflict of interest.

Received 1 January 2016; revision 20 May 2016; accepted 7 June 2016.

whether functional assessment of the future remnant liver is the prediction of postoperative morbidity after hepatic resection in patients with HCC.

## METHODS

### Patients

ONE HUNDRED FORTY-SEVEN patients underwent hepatic resection for HCC at the Department of Surgery and Science, Kyushu University Hospital (Fukuoka, Japan) from July 2009 to June 2015. The study protocol was carried out in accordance with the Code of Ethics of the World Medical Association (Declaration of Helsinki) and the institutional review board (26–300).

### Imaging studies for remnant functional liver volume

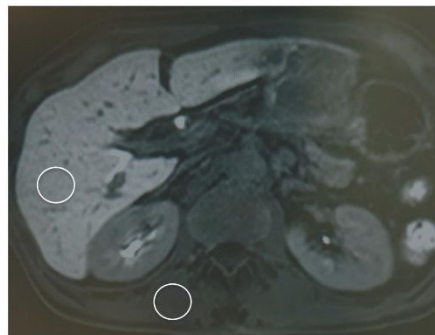
All patients underwent multidetector computed tomography (CT) and EOB-MRI before the operation. Preoperative CT images were reconstructed into 3D images using a Synapse Vincent 3D-image analyzer (Fujifilm, Tokyo, Japan), and used for vascular mapping and prediction of total and remnant liver volume. The remnant liver was then normalized for body surface area (BSA). The equation for determining BSA was:<sup>12</sup>  $BSA = (\text{body weight [kg]}^{0.725} \times (\text{height [cm]})^{0.425} \times 0.007184 \text{ (m}^2\text{)})$ .

The EOB-MRI procedure was carried out on a whole-body 1.5 T scanner (Intera Achieva Nova Dual; Philips Medical Systems, Best, Netherlands). A multiphase dynamic study including arterial, portal, and late phases was carried out using axial 3D eTHRIVE (3D T1 high-resolution isotropic volume excitation). The MR images scanned before and 20 min after i.v. injection of 0.1 mL/kg (total amount, 4.5–8 mL) Primovist (Bayer, Osaka,

Japan) were evaluated in this study.<sup>11,13</sup> The signal intensity (SI) of 3D eTHRIVE on EOB-MRI was measured on a DICOM viewer (TWS-5000; Toshiba, Tokyo, Japan). The SI was measured by placing the largest possible region of interest (ROI) on the future remnant liver parenchyma as avoiding vessels and artifacts in a consensus fashion (Fig. 1). The SI of the major psoas muscle was also measured for standardization. The averages of the three signal intensities of the future remnant liver parenchyma and the three signal intensities of the major psoas muscle were calculated. Based on these average values, the liver to major psoas muscle ratio (LMR) before and after administration of Gd-EOB-DTPA was recorded for each patient. The same size and shape of ROI was placed at the same position for the images before and after administration of Gd-EOB-DTPA. The remnant liver function was calculated using this formula (LMR on the hepatobiliary phase / LMR on the precontrast image). The remnant functional liver was calculated as the remnant liver volume or volumetric rate by 3D-CT  $\times$  the remnant liver function by EOB-MRI.

### Surgical procedures

Patients were carefully selected for major hepatic resection based on volumetric analysis of the remnant liver to prevent postoperative liver failure.<sup>7,14</sup> The type of hepatic resection was determined according to the preoperative ICG retention rate at 15 min (ICGR15).<sup>15</sup> Liver function criteria "liver damage (A,B and C)" as proposed by the Liver Cancer Study Group of Japan were used in this study (Table 1).<sup>16</sup> Parenchymal transection was carried out using the Cavitron Ultrasonic Surgical Aspirator (CUSA system; Valleylab, Boulder, CO, USA) and the monopolar



**Figure 1** Hepatobiliary phase of gadolinium-ethoxybenzyl-diethylenetriamine pentaacetic acid-enhanced magnetic resonance imaging of the liver. Signal intensities were measured by placing as large a region of interest (ROI) as possible on the future remnant liver parenchyma and major psoas muscle, avoiding vessels, tumors, and artifacts. For each slice, two circular ROIs were placed: one in the remnant liver and the other in the major posts muscle. [Color figure can be viewed at [wileyonlinelibrary.com](http://wileyonlinelibrary.com)]

**Table 1** Liver Damage Presented by Liver Cancer Study Group of Japan

Variables	Liver Damage		
	A	B	C
Ascites	None	Controllable	Uncontrollable
Total bilirubin, mg/dL	< 2.0	2.0 -3.0	> 3.0
Albumin, g/L	> 3.5	3.0 -3.5	< 3.0
ICGR15, %	< 15	15 -40	> 40
Prothrombin activity, %	> 80	50 -80	< 50

Liver damage A, B, or C is determined by which ones fit more than two categories. If there are two liver damage types in which more than two categories fit, the higher liver damage should be applied. For example, if three categories fit liver damage A and two categories fit liver damage B, liver damage B is applied. ICGR15, indocyanine green dye retention at 15 min.

dissecting sealer (TissueLink; Salient Surgical Technologies, Portsmouth, NH, USA) powered by a VIO system (VIO 300D; Erbe Elektromedizin, Tübingen, Germany). Inflow vascular control was carried out with intermittent hemi- or total Glisson's sheath occlusion (Pringle maneuver) and, if required, with a selective hepatic vein-clamping method. Inflow occlusion was applied intermittently with 15 min of occlusion alternating with 5 min of reperfusion. A bile leakage test was undertaken using an ICG injection through a cannula placed inside the common bile duct through the cystic duct after transection. If bile leakage was detected, the leakage point was repaired by Z-sutures using 6-0 polydioxanone (PDS II; Johnson & Johnson, Tokyo, Japan). An absorbable polyglactin acid sheet mesh (Neoveil; Gunze, Tokyo, Japan) and fibrin glue (Bolheal; Kaketsuken, Kumamoto, Japan or Beriplast; Nycomed, Zurich, Switzerland) was routinely applied to the cut surface of the liver.

### Postoperative outcomes

Postoperative complications were categorized by use of the Clavien-Dindo classification.<sup>17</sup> In this study, morbidity was classified as grade III or greater. Liver-related morbidity included refractory ascites, pleural effusion that required invasive treatment, hepatic encephalopathy, or liver failure, as defined by the International Study Group of Liver Surgery, as total serum bilirubin concentration >2.9 mg/dL and a prothrombin time index <50% of normal value at postoperative day 5.<sup>18</sup>

### Statistical analysis

Continuous variables are presented as the median (range) and compared using the Mann-Whitney *U*-test. A logistic

regression analysis was carried out to identify variables for liver-related morbidity. Estimation of the cut-off values for predicting liver-related morbidity was undertaken by calculating the areas under the receiver-operating characteristic (ROC) curves. The ROC curve is a plot of sensitivity versus 1 - specificity for all possible cut-off values. The most commonly used index of accuracy is the area under the ROC curve, where values close to 1.0 indicate high diagnostic accuracy, and 0.5 indicates a test of no diagnostic value. The optimal cut-off values used were selected based on the sensitivity and specificity.

A value of  $P < 0.05$  was considered statistically significant. Data are expressed as median and range. All statistical analyses were carried out using JMP software (SAS Institute, Cary, NC, USA).

**Table 2** Preoperative characteristics of 146 patients who underwent hepatic resection for hepatocellular carcinoma

Variable	Value
Age, years, median (range)	69 (34–87)
Men / women	105/41
Body mass index, kg/m <sup>2</sup> , median (range)	23.2 (17.0–32.6)
Background liver disease	
HBV	24
HCV	74
HBV + HCV	1
Non B, non C	47
Child-Pugh classification, A / B	143/3
Liver damage, A / B	119/27
MELD score, median (range)	7 (6–11)
Albumin, g/L, median (range)	4.0 (2.6–5.1)
Total bilirubin, mg/dL, median (range)	0.75 (0.2–2.4)
Prothrombin activity, %, median (range)	89.5 (64–123)
ICGR15, %, median (range)	12.8 (2.0–71)
Platelet count, 10 <sup>3</sup> /μL, median (range)	15.4 (5.1–43.7)
Preoperative portal vein embolization, n (%)	9 (6.1)
Histological liver cirrhosis, n (%)	25 (17.1)
Solitary / multinodular tumor	119/27
Main tumor size, cm, median (range)	3.0 (1.0–18)
Remnant liver function score, median (range)	1.82 (1.25–2.96)
Remnant liver volumetric rate, %, median (range)	90.1 (43.9–99.3)
Remnant liver volume, mL/m <sup>2</sup> , median (range)	571 (266–1100)
Remnant functional liver using volumetric rate, median (range)	155.9 (64.7–285.3)
Remnant functional liver using volume, median (range)	1027 (369–2148)

HBV, hepatitis B virus; HCV, hepatitis C virus; ICGR15, indocyanine green dye retention at 15 min; MELD, Model for End-stage Liver Disease.

## RESULTS

**P**REOPERATIVE CHARACTERISTICS FOR patients with HCC are described in Table 2. The maximal diameter of HCC for all patients ranged from 1.0 to 18 cm (median, 3.0 cm). Median remnant liver function score using EOB-MRI, median remnant liver volume and volumetric rate, and remnant functional liver using volumetric

rate or volumetry were 1.82 (range, 1.25–2.96), 90.1% (range, 43.9–99.3%), 571 mL/m<sup>2</sup> (range, 266–1100 mL/m<sup>2</sup>), 155.9 (range, 64.7–285.3), and 1027 (369–2148), respectively.

Table 3 shows the surgical outcomes after hepatic resection. Limited hepatic resection was carried out in 65 patients (44.5%), subsegmentectomy of the liver in 26 patients (17.8%), segmentectomy in 32 patients (21.9%), and two or more segmentectomies in 23 patients (15.8%). Nineteen patients (13.0%) suffered morbidity classified as grade III or greater. Liver-related morbidity occurred in 7 patients (4.7%). There was no mortality during surgery, within 30 days of surgery, or during the same hospital admission.

Patients with liver-related morbidity had significantly lower levels of remnant liver function, remnant functional liver using volumetric rate and volume, and higher duration of operation and blood loss compared to those without liver-related morbidity (Table 4). However, there were no significant differences in liver function scores except with liver damage. Logistic regression analysis of factors including liver damage, duration of operation, blood loss, remnant liver function, and remnant functional liver using volumetric rate and volume revealed that only remnant functional liver volume was an independent predictor for liver-related morbidity. The area under the ROC curves for liver-related morbidity using remnant functional liver volume was 0.973. The optimal cut-off value was 731 (sensitivity, 1.00; specificity, 0.91). The characteristics and surgical outcomes of the patients with liver-related morbidity are shown in Table 5.

**Table 3** Surgical outcomes of 146 patients who underwent hepatic resection for hepatocellular carcinoma

Variable	Value
Hepatic resection	
Open / laparoscopic	100/46
Limited resection, <i>n</i> (%)	65 (44.5)
Subsegmentectomy, <i>n</i> (%)	26 (17.8)
Segmentectomy, <i>n</i> (%)	32 (21.9)
Two or more segmentectomies, <i>n</i> (%)	23 (15.8)
Duration of operation, min, median (range)	295 (65–845)
Blood loss, mL, median (range)	389 (0–5391)
Blood transfusion, <i>n</i> (%)	20 (13.6)
Morbidity, <i>n</i> (%)	19 (13.0)
Wound infection	7
Intra-abdominal infection	7
Bile leakage	6
Ascites	2
Pleural effusion	4
Liver dysfunction	3
Liver related morbidity, <i>n</i> (%)	7 (4.7)
Mortality, <i>n</i> (%)	0 (0.0)

**Table 4** Predictors of liver-related morbidity after hepatic resection in patients with hepatocellular carcinoma

Variable	Without liver-related morbidity ( <i>n</i> = 139)	With liver-related morbidity ( <i>n</i> = 7)	<i>P</i> -value (univariate analysis)	<i>P</i> -value (multivariate analysis)
Child–Pugh classification, A / B	136/3	7/0	0.585	
Liver damage, A / B	116/23	3/4	0.018	0.086
MELD score	7 (6–11)	7.5 (7–11)	0.524	
Albumin, g/L	4.0 (2.6–5.1)	3.6 (3.5–4.3)	0.130	
Total bilirubin, mg/dL	0.8 (0.2–2.4)	0.6 (0.4–0.8)	0.090	
Prothrombin activity, %	90 (64–123)	81 (70–97)	0.058	
ICGR15, %	12.6 (2.0–71.6)	12.9 (5.4–20.0)	0.869	
Platelet counts, 10 <sup>4</sup> /μL	15.5 (5.1–43.7)	15.3 (12.0–28.2)	0.670	
Duration of operation, min	292 (65–845)	484 (186–659)	0.012	0.061
Blood loss, mL	370 (0–4051)	1000 (150–5391)	0.036	0.189
Histological liver cirrhosis, yes / no	25/112	0/7	0.255	
Remnant liver function score	1.84 (1.25–2.96)	1.48 (1.27–1.94)	0.015	0.548
Remnant functional liver using volumetric rate	156.8 (77.5–285.3)	89.8 (64.7–127.5)	<0.001	0.290
Remnant functional liver using volume	1039 (566–2148)	582 (369–731)	<0.001	<0.001

Values are numbers with median (range).

ICGR15, indocyanine green dye retention at 15 min; MELD, Model for End-stage Liver Disease.



Table 5 Characteristics and surgical outcomes of patients with hepatocellular carcinoma with liver-related morbidity following hepatic resection

Patient no.	Age, years	Sex	Procedure	Tumor size, cm	Liver damage	Duration of operation, min	Blood loss, mL	Liver cirrhosis	Remnant functional liver	Liver-related morbidity	Postoperative hospital stay, days
1	77	F	Right lobectomy	3.5	B	186	150	No	430	Ascites	18
2	68	M	Anterior segmentectomy	6.2	A	519	1266	No	582	Liver dysfunction, ascites, pleural effusion	77
3	68	M	Left lateral segmentectomy	3.5	B	659	1000	No	532	Pleural effusion	30
4	64	M	Posterior segmentectomy and gastrectomy	2.5	B	377	600	No	731	Liver dysfunction, ascites	137
5	75	M	Posterior segmentectomy	4.0	B	484	2000	No	585	Liver dysfunction	42
6	84	M	Central bisegmentectomy	10	A	358	490	No	725	Pleural effusion	19
7	73	M	Right lobectomy	15	A	522	5391	No	369	Pleural effusion	18

F, female; M, male.

The median scores of remnant liver function, remnant functional liver using volumetric rate, and volume in patients with morbidity classified as grade III or greater were significantly lower than those of patients with morbidity. However, there was no independent risk factor for morbidity in logistic regression analysis (data not shown).

## DISCUSSION

**I**N THIS STUDY, we found that remnant functional liver volume measured by CT volumetry and EOB-MRI was a useful predictor of liver-related morbidity after hepatic resection in patients with HCC. This is the first clinical study that evaluates whether functional assessment of the future remnant liver using EOB-MRI and CT volumetry is a predictor of postoperative morbidity after hepatic resection in patients with HCC.

Postoperative liver-related morbidity remains problematic. Shirabe *et al.* reported that a remnant liver volume  $>250$  mL/m<sup>2</sup> following major hepatic resection was recommended to prevent the occurrence of postoperative liver failure.<sup>14</sup> With regard to living related liver transplantation, we have strict criteria for performing donor right hepatectomy, and preoperative volumetric analyses confirmed the estimated remnant liver volume as no less than 35% of the total liver volume.<sup>19</sup> In our study, all cases were within the limits of this criteria and no mortality was reported. Nevertheless, postoperative liver-related morbidity occurred in 7 of 147 patients (4.7%) with HCC. Therefore, we thought that we had to plan on the possibility of using new criteria to predict liver-related morbidity.

Several studies have suggested that EOB-MRI can be used to estimate liver function.<sup>10,11,13</sup> The LMR was one of the quantitative indicators of liver function per unit liver volume.<sup>10</sup> Galactosyl human serum albumin is known as another method for quantitative liver function tests.<sup>20</sup> Recently, the newly developed Tc-99m-GSA scintigraphy single-photon emission CT fusion system allows for the simultaneous evaluation of any part of the liver volume and the corresponding liver function.<sup>21</sup> It has been reported that EOB-MRI is better at evaluating the regional liver function reserve than GSA because the spatial resolution of EOB-MRI is superior to that of GSA.<sup>11</sup> Furthermore, the use of radioactive isotopes is necessary in order to obtain these images. In contrast, EOB-MRI can be applied without any additional equipment or the need to use any radioactive agents. The advantages of EOB-MRI include high spatial resolution that enables detailed assessment of regional liver function concomitantly with the diagnostic information for HCC.

In our study, the functional with volumetric assessment was a significant predictor of liver-related morbidity following hepatic resection based on multivariate analysis. The remnant liver function using EOB-MRI correlated with ICGR15 and prothrombin activity (data not shown). According to these data, our assessment for remnant functional liver volume using CT volumetry and EOB-MRI is valid. However, the precise reason for the superiority of remnant functional liver determination using volume (mL/BSA) compared to volumetric rate (%) with regard to liver-related morbidity is not currently known. Further studies with a greater number of cases are required to confirm the results of the present study.

As Gd-EOB-DTPA is secreted into the biliary system based on its physical characteristics, hyperbilirubinemia may affect the values of the LMR of the EOB-MRI.<sup>22</sup> The total bilirubin level in only one patient was more than 2.0 mg/mL, so the influence of hyperbilirubinemia on the relative LMR values could not be determined in the present study. However, a recent study has shown that the uptake of Gd-EOB-DTPA in HCC is determined by the expression of the organic anion transporter 1B3, rather than bile production.<sup>23</sup> Therefore, an evaluation of organic anion transporter 1B3 expression in non-tumorous liver tissue specimens in patients with hyperbilirubinemia may help us understand the status of the relative SI of EOB-MRI in these patients.

The current study has several limitations including the retrospective nature and the use of prospectively collected perioperative data, and the inclusion of a relatively small number of patients, especially those who underwent two or more segmentectomies of the liver. Further multi-institutional studies with a greater number of patients are required to confirm the results of the current study.

In conclusion, remnant functional liver volume using CT volumetry and EOB-MRI is a useful predictor for liver-related morbidity after hepatic resection in patients with HCC. Assessments of remnant functional liver volume would help hepatic surgeons more accurately estimate the remnant liver functional reserve after hepatic resection.

## REFERENCES

- 1 Forner A, Llovet JM, Bruix J. Hepatocellular carcinoma. *Lancet* 2012; 379: 1245–55.
- 2 Bosch FX, Ribes J, Díaz M, Cléries R. Primary liver cancer: worldwide incidence and trends. *Gastroenterology* 2004; 127: S5–16. review
- 3 Shirabe K, Takeishi K, Taketomi A, Uchiyama H, Kayashima H, Maehara Y. Improvement of long-term outcomes in hepatitis C virus antibody-positive patients with hepatocellular carcinoma after hepatectomy in the modern era. *World J Surg* 2011; 35: 1072–84.
- 4 Itoh S, Morita K, Ueda S *et al.* Long-term results of hepatic resection combined with intraoperative local ablation therapy for patients with multinodular hepatocellular carcinomas. *Ann Surg Oncol* 2009; 16: 3299–307.
- 5 Itoh S, Fukuzawa K, Shitomi Y *et al.* Impact of the VIO system in hepatic resection for patients with hepatocellular carcinoma. *Surg Today* 2012; 42: 1176–82.
- 6 Bekki Y, Yamashita Y, Itoh S, Harimoto N, Shirabe K, Maehara Y. Predictors of the effectiveness of prophylactic drains after hepatic resection. *World J Surg* 2015; 39: 2543–9.
- 7 Itoh S, Shirabe K, Taketomi A *et al.* Zero mortality in more than 300 hepatic resections: validity of preoperative volumetric analysis. *Surg Today* 2012; 42: 435–40.
- 8 Itoh S, Uchiyama H, Kawanaka H *et al.* Characteristic risk factors in cirrhotic patients for posthepatectomy complications: comparison with noncirrhotic patients. *Am Surg* 2014; 80: 166–70.
- 9 Van Beers BE, Pastor CM, Hussain HK. Primovist, Eovist: what to expect? *J Hepatol* 2012; 57: 421–9.
- 10 Nishie A, Ushijima Y, Tajima T *et al.* Quantitative analysis of liver function using superparamagnetic iron oxide- and Gd-EOB-DTPA-enhanced MRI: comparison with technetium-99 m galactosyl serum albumin scintigraphy. *Eur J Radiol* 2012; 81: 1100–4.
- 11 Utsunomiya T, Shimada M, Hanaoka J *et al.* Possible utility of MRI using Gd-EOB-DTPA for estimating liver functional reserve. *J Gastroenterol* 2012; 47: 470–6.
- 12 Du Bois D, Du Bois EF. A formula to estimate the approximate surface area if height and weight be known. 1916. *Nutrition* 1989; 5: 303–11.
- 13 Nishie A, Asayama Y, Ishigami K *et al.* MR prediction of liver fibrosis using a liver-specific contrast agent: Superparamagnetic iron oxide versus Gd-EOB-DTPA. *J Magn Reson Imaging* 2012; 36: 664–71.
- 14 Shirabe K, Shimada M, Gion T *et al.* Postoperative liver failure after major hepatic resection for hepatocellular carcinoma in the modern era with special reference to remnant liver volume. *J Am Coll Surg* 1999; 188: 304–9.
- 15 Taketomi A, Kitagawa D, Itoh S *et al.* Trends in morbidity and mortality after hepatic resection for hepatocellular carcinoma: an institute's experience with 625 patients. *J Am Coll Surg* 2007; 204: 580–7.
- 16 Ikai I, Arai S, Kojiro M *et al.* Reevaluation of prognostic factors for survival after liver resection in patients with hepatocellular carcinoma in a Japanese nationwide survey. *Cancer* 2004; 101: 796–802.
- 17 Clavien PA, Barkun J, de Oliveira ML *et al.* The Clavien–Dindo classification of surgical complications: five-year experience. *Ann Surg* 2009; 250: 187–96.
- 18 Rahbari NN, Garden OJ, Padbury R *et al.* Posthepatectomy liver failure: a definition and grading by the International

- Study Group of Liver Surgery (ISGLS). *Surgery* 2011; 149: 713–24.
- 19 Uchiyama H, Shirabe K, Nakagawara H *et al.* Revisiting the safety of living liver donors by reassessing 441 donor hepatectomies: is a larger hepatectomy complication-prone? *Am J Transplant* 2014; 14: 367–74.
- 20 Kwon AH, Ha-Kawa SK, Uetsuji S, Inoue T, Matsui Y, Kamiyama Y. Preoperative determination of the surgical procedure for hepatectomy using technetium-99m-galactosyl human serum albumin (99mTc-GSA) liver scintigraphy. *Hepatology* 1997; 25: 426–9.
- 21 Hayashi H, Beppu T, Okabe H *et al.* Functional assessment versus conventional volumetric assessment in the prediction of operative outcomes after major hepatectomy. *Surgery* 2015; 157: 20–6.
- 22 Schuhmann-Giampieri G, Schmitt-Willich H, Press WR, Negishi C, Weinmann HJ, Speck U. Preclinical evaluation of Gd-EOB-MRI as a contrast agent in MR imaging of the hepatobiliary system. *Radiology* 1992; 183: 59–64.
- 23 Narita M, Hatano E, Arizono S *et al.* Expression of OATP1B3 determines uptake of Gd-EOB-DTPA in hepatocellular carcinoma. *J Gastroenterol* 2009; 44: 793–8.