

Initial Results of Hypofractionated Carbon Ion Radiotherapy for Cholangiocarcinoma

TAKANORI ABE¹, KEI SHIBUYA¹, YOSHINORI KOYAMA², MASAHIKO OKAMOTO³,
HIROKI KIYOHARA³, HIROYUKI KATOH³, HIROHUMI SHIMADA³,
HIROYUKI KUWANO⁴, TATSUYA OHNO⁴ and TAKASHI NAKANO¹

*Departments of ¹Radiation Oncology, ²Diagnostic and Interventional Radiology, and
⁴General Surgical Science, Gunma University, Graduate School of Medicine, Maebashi, Japan;
³Gunma University Heavy Ion Medical Center, Maebashi, Japan*

Abstract. *Aim: To report initial results of hypofractionated carbon ion radiotherapy (C-ion RT) for cholangiocarcinoma. Patients and Methods: Data regarding seven patients with cholangiocarcinoma treated by C-ion RT were analyzed. Prescribed doses were 52.8 Gy [relative biological effectiveness (RBE)] or 60.0 Gy (RBE) in four fractions for intrahepatic cases and 12 fractions for hilar hepatic/close to gastro-intestinal tract cases. Local control and overall survival were evaluated and toxicity was graded using Common Terminology Criteria for Adverse Events, version 4.0. Results: The median follow-up period was 16 months. There were two patients with stage I cancer, one with stage II, one with stage III, and three with stage IVA. Local control was achieved in five out of seven patients (71%) and survival was maintained in six out of seven patients (86%). There were no occurrences of acute or late toxicity of grade 3 or higher. Conclusion: Initial results show that hypofractionated C-ion RT appears to be tolerated and effective for cholangiocarcinoma.*

Cholangiocarcinoma is a relatively rare neoplasm that arises from the bile duct epithelium and generally carries a poor prognosis (1). Surgical resection is the only established curative therapy, but due to rapid disease progression without symptoms, most patients are diagnosed with disease at unresectable advanced stages (2, 3). Radiofrequency ablation (RFA) with or without photodynamic therapy, trans-arterial

chemoembolization (TACE), yttrium-90 radioembolization, brachytherapy with external-beam radiotherapy (EBRT) and EBRT with or without chemotherapy have been used to treat patients with unresectable disease (4-11). The 1-year overall survival rate ranges from 36% to 53% for patients treated with TACE, yttrium-90 radioembolization, and EBRT with or without chemotherapy (5-10). The 1-year overall survival rate for those treated with RFA is 80% and is 65% for brachytherapy with EBRT for selected patients, such as those with intrahepatic small tumors (4, 11). In general, application of RFA and brachytherapy to cholangiocarcinoma is limited and results of other therapies are insufficient.

To improve the efficacy of RT, a higher dose may be necessary because cholangiocarcinoma is resistant to conventionally fractionated X-ray RT (9). However, it is difficult to deliver an adequate dose to the tumor and spare surrounding normal tissue using conventional methods (12), hence stereotactic body radiotherapy (SBRT) with X-ray and proton beam therapy (PBT) have been attempted to overcome this obstacle (12-17). However, such high doses per fraction may be associated with toxicity due to limited dose localization in X-ray SBRT (14), and PBT requires a long overall treatment period due to the dose fractionation schedule (15-17). On the other hand, carbon-ion radiotherapy (C-ion RT) has been used to treat liver and pancreatic cancer since 1995 at the National Institute of Radiological Sciences in Japan, and has shown favorable results within a relatively short overall treatment period by taking advantage of its superior dose localization and higher relative biological effectiveness (RBE) compared with X-rays and protons (18, 19). With C-ion RT, it might be possible to deliver an adequate dose to the tumor while minimizing the dose to surrounding normal tissues when treating cholangiocarcinoma by application with method of C-ion RT for hepatocellular carcinoma (20). Based on this, we have applied hypofractionated C-ion RT to treat cholangiocarcinoma cases since 2013. Here we report the initial results of using hypofractionated C-ion RT for cholangiocarcinoma.

This article is freely accessible online.

Correspondence to: Takanori Abe, Department of Radiation Oncology, Gunma University, Graduate School of Medicine, 3-39-22, Showa-machi, Maebashi, 371-8511, Japan. Tel: +81 272208378, Fax: +81 272208379, e-mail: mrtaka100@yahoo.co.jp

Key Words: Carbon ion radiotherapy, cholangiocarcinoma, local control.

Table I. Patients' and tumor characteristics.

Case	Gender	Age (years)	T	N	M	Stage	Tumor location	Pathological diagnosis	Maximum tumor diameter (cm)	PTV (cm ³)	Dose Gy(RBE)/no. of fractions
1	Male	79	3	0	0	III	S1	Clinically diagnosed	7.6	304	52.8/4
2	Male	62	2a	1	0	IVA	S4	CCC	4.6	148	60.0/4
3	Male	68	4	0	0	IVA	S1	Clinically diagnosed	4.8	76	60.0/12
4	Male	71	2a	0	0	II	S8	Clinically diagnosed	3.3	110	60.0/4
5	Male	76	1	0	0	I	S4	CCC	3.9	84	60.0/4
6	Male	71	1	0	0	I	S6	CCC	3.7	107	60.0/4
7	Male	50	4	1	0	IVA	Hilar	Clinically diagnosed	6.3	107	52.8/12

PTV: Planning target volume; CCC: cholangiocellular carcinoma.

Table II. Clinical outcomes.

Case	Follow-up	Outcome (months)	Local recurrence	Out-of-field intrahepatic recurrence	Distant metastasis
1	29	Alive	NER	NER	NED
2	21	Alive	NER	Intrahepatic recurrence	NED
3	12	Alive	NER	NER	NED
4	13	Alive	Local recurrence	Intrahepatic recurrence	NED
5	17	Died of disease	Local recurrence	NER	Lung metastasis
6	16	Alive	NER	NER	Para-aortic LN metastasis
7	7	Alive	NER	NER	NED

NER: No evidence of recurrence; NED: no evidence of disease; LN: lymph node.

Patients and Methods

Patients. This study retrospectively analyzed patients with cholangiocarcinoma who were treated by hypofractionated C-ion RT at Gunma University Heavy Ion Medical Center (GHMC) from 2013 to 2015. All patients were treated and monitored according to the protocol approved by the Gunma University Hospital Institutional Review Board. Eligibility criteria were: i) cholangiocarcinoma confirmed by histology or clinical examination; ii) locally advanced cholangiocarcinoma without intrahepatic metastasis or distant metastasis; iii) medical inoperability due to comorbidity, or inoperability due of wide tumor extension; iv) no findings suggesting direct infiltration of the gastro-intestinal (GI) tract; v) good general condition with performance status ≤ 2 in the Eastern Cooperative Oncology Group classification; and vi) Child-Pugh classification A or B. Adjuvant and neoadjuvant chemotherapy were allowed in this study. Written informed consent was acquired from all patients prior to C-ion RT.

Treatment. C-ion RT dose is described herein in Gy (RBE), which is calculated by multiplying the carbon absorbed dose by an RBE of three. Prescribed doses were 52.8 Gy (RBE) or 60.0 Gy (RBE) in four fractions for intrahepatic cases and 12 fractions for hilar hepatic/close to GI-tract cases. Doses per fraction ranged from 4.4 to 15 Gy (RBE). Carbon ion beams were accelerated using the synchrotron at GHMC. Beam energies were 290 MeV/u, 380 MeV/u, and 400 MeV/u, determined individually for each patient based on

tumor depth. Patients were immobilized using fixation cushions and thermoplastic shells of 3-mm thickness. Treatment planning computed tomography (CT) under free respiration and respiratory-gated CT images were taken after immobilization. Contrast-enhanced CT images were taken concurrently and merged with the treatment planning CT to define gross tumor volume (GTV). The clinical target volume (CTV) margin, including subclinical tumor invasion, was added to the GTV, with an additional 10 mm in all directions. The internal margin was added as the extent of tumor motion shown in four-dimensional CT images. The planning target volume (PTV) was defined as a summation of the CTV, internal margin, and setup margin. Dose constraints were: i) D1 cm³ <40 Gy (RBE) to the GI tract; ii) D_{max} <52.8 Gy (RBE) to the secondary branch of the portal vein and common bile duct; iii) V20 <35% to the liver; and iv) D_{max} <45 Gy (RBE) to the skin. When tumors were located near the GI tract, priority was given to sparing the GI tract rather than covering the PTV with the prescribed dose. For daily patient position matching, fiducial gold marker was inserted in the liver. Matching of the position of the fiducial marker was confirmed every day with two-directional X-ray images taken immediately before treatment.

Evaluation. All patients were admitted to the Gunma University Hospital and acute toxicity was assessed daily during treatment. After treatment, blood tests and abdominal diagnostic imaging such as CT, magnetic resonance imaging, or fluoro-deoxyglucose position-emission tomography/CT were performed every 3 months for the first year and every 6 months thereafter. Acute and late toxicity were classified using the National Cancer Institute's

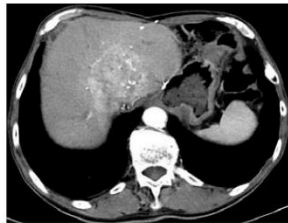


Figure 1. Computed tomographic image shows a bulky tumor (76 mm) with enhancement effect in the S1 region of the liver.

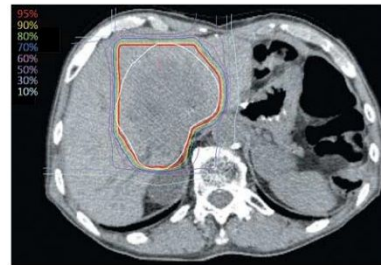

Figure 2. Treatment plan of carbon ion radiotherapy. The white line indicates the planning target volume and the red line indicates the 95% isodose line of the prescribed dose.

Table III. Toxicity.

	Grade 0	Grade 1	Grade 2	Grade ≥3
Acute toxicity, n				
Radiation dermatitis	0	7	0	0
Nausea	5	2	0	0
Anorexia	7	0	0	0
Hepatobiliary disorder (cholangitis)				
Transaminase elevation	6	1	0	0
Late toxicity, n	6	1	0	0
Hepatobiliary disorder (cholangitis)				
Bile duct stenosis	7	0	0	0
Gastric/duodenal ulcer	6	0	1	0
Gastric/duodenal stenosis	7	0	0	0

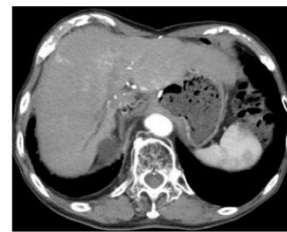

Figure 3. Computed tomographic image taken 29 months after treatment shows no evidence of recurrence.

Common Terminology Criteria for Adverse Events, version 4.0 (21). Local recurrence was defined as tumor regrowth in the irradiated field confirmed by diagnostic imaging, and overall survival was defined as the time interval between initiation of C-ion RT and the last follow-up when the patient was alive.

Results

Patients. Data regarding six patients with intrahepatic cholangiocarcinoma and one with hilar cholangiocarcinoma treated with hypofractionated C-ion RT were retrospectively analyzed. Patient and tumor characteristics are summarized in Table I. The median patient age was 71 years (range=47-83 years) and all patients were male. Tumor classification was T1 in two patients, T2a in two, T3 in one and T4 in two based on the Union for International Cancer Control classification (Edition 7) (22). There were two patients with stage I cancer, one with stage II, two with stage III, and three with stage IVA. The mean tumor diameter and PTV were 4.9 cm and 105 cm³, respectively (range=3.3-7.6 cm

and 76-304 cm³, respectively). The Child-Pugh category was class 5-A in six patients and 6-A in one. Three patients were histologically confirmed to have cholangiocellular carcinoma, and four were clinically diagnosed with cholangiocarcinoma by a multi-disciplinary discussion of the institution's Cancer Board.

Treatment outcomes. A representative case is shown in Figures 1-3. The median patient follow-up was 16 months (range=7-29 months). Local control was achieved in five out of seven patients (71%) and survival was maintained in six out of seven patients (86%). The median progression-free survival period and median overall survival periods after C-ion RT were 9 months and 16 months, respectively. Of two patients with poor local control, one developed intrahepatic metastasis and the other developed distant metastasis and died from their disease. Of five patients with good local control, one developed intrahepatic metastasis and one developed distant metastasis, but all were alive at the last follow-up. These results are summarized in Table II.

Table IV. Review of literature.

Author	Modality	No. of patients	Follow-up (months)	Total dose (dose per fraction)	Outcome
Makita <i>et al.</i> (15)	Protons	28	12	50.6-80 GyE (2.0-3.2 GyE)	OS, PFS, and LC rates at 1 year were 49%, 29%, and 67%
Ohkawa <i>et al.</i> (16)	Protons	20	20	56.1-72.6 GyE (3.3 GyE)	OS and LC rates at 1 year were 82 % and 88%
Mahadevan <i>et al.</i> (12)	SBRT	34	38	30 Gy (10 Gy)	Actual OS and LC rates at 1 year were 58% and 88%
Barney <i>et al.</i> (13)	SBRT	10	14	45-60 Gy (12-15 Gy)	OS and LC rates at 1 year were 73% and 100%
Present study	C-ion RT	7	16	52.8-60 Gy (RBE) [4.4-15 Gy (RBE)]	Actual OS and LC rates were 85% and 71%

SBRT: Stereotactic body radiotherapy; C-ion RT: carbon ion radiotherapy; RBE: relative biological effectiveness; OS: overall survival; PFS: progression-free survival; LC: local control.

Toxicity. All patients developed grade 1 acute radiation dermatitis that resolved in a few weeks without medication. Two patients experienced nausea during treatment that did not require medication. One patient developed grade 1 hepatobiliary disorder (cholangitis) and elevation of transaminase 1 month after treatment, and recovered without medication. Monitoring for late toxicity showed no grade 3 or higher toxicity. Grade 2 bile duct stenosis was observed in one patient; this patient developed jaundice 13 months after treatment due to stenosis and required hospitalization, but the condition resolved with supportive care. Cytology of ascites fluid of this patient did not reveal malignant cells and also resolved with supportive care. These toxicities are summarized in Table III.

Discussion

Conventional radiotherapy with or without chemotherapy is one of the treatment options for unresectable cholangiocarcinoma, but the outcome is still dissatisfactory, with a median survival of 10 months (7-10). Crane *et al.* conducted a retrospective analysis of definitive concurrent chemoradiotherapy (CCRT) for unresectable cholangiocarcinoma and concluded that the primary limitation of CCRT was local disease control, thus dose escalation is needed (9). However, intensive local therapy can result in significant complications, leading to deterioration of treatment outcomes.

Currently available studies of X-ray SBRT and PBT show an 8-20% incidence of grade 3 or higher late toxicity (12-17). Results of studies on X-ray SBRT and PBT are summarized in Table IV. Kopek *et al.* reported favorable local control with a total dose of 45 Gy given in three X-ray SBRT fractions, but six patients (22%) developed severe GI tract complications such as ulceration and stenosis (13). On

the other hand, Mahadevan *et al.* reported a 12% incidence of grade 3 or higher toxicity using X-ray SBRT for unresectable intra-hepatic cholangiocarcinoma using the CyberKnife, which enables accurate dose delivery with respiratory motion tracking of irradiation (12). Ohkawa *et al.* reported a 10% incidence of grade 3 or higher late toxicity with a total dose of 56.1 Gy to 72.6 Gy of PBT using respiratory-gated irradiation (16). These results suggest that improved techniques and new modalities that minimize the dose to normal tissue are warranted for delivering higher doses to the target tumor safely. In the present study, there was no grade 3 or higher acute or late toxicity observed with hypofractionated C-ion RT using dose constraints for the liver and GI tract for treatment of hepatocellular carcinoma, although further follow-up is necessary.

Total dose and fraction size vary in SBRT and PBT studies, ranging from 50.6-80 GyE with 2.0-3.9 GyE per fraction in PBT and 30-60 Gy with 10-15 Gy per fraction in X-ray SBRT. In our study, the median total dose and dose per fraction were 60.0 Gy (RBE) and 13.2 Gy (RBE), respectively. Tumor characteristics also vary between studies. The mean PTV ranged from 64 cm³ to 80 cm³ in X-ray SBRT studies and maximum tumor diameter ranged from 50 mm to 60 mm in PBT studies (12-17). In the present study, the mean PTV was 105 cm³, which is larger than in X-ray SBRT studies, while the mean tumor diameter was 49 mm, which is comparable to that of PBT studies. Considering these conditions, C-ion RT can deliver higher doses with less toxicity, resulting from superior dose localization by C-ion beams.

Our study achieved local control in five out of seven (71%) patients with a median follow-up of 16 months. One-year local control rates in X-ray SBRT and PBT studies range from 67% to 100% (12-17). To date, the local control

rate of C-ion RT is comparable to those of X-ray SBRT and PBT, but with less toxicity. The survival benefit from C-ion RT is unclear due to the insufficient follow-up period; however, there are potential benefits due to the lower incidence of toxicity, as well as favorable local control. Systemic therapy is also important for improving overall survival for this disease (23). In particular, a lower incidence of acute and late toxicity with use of hypofractionated C-ion RT may lead to safe initiation of adjuvant systemic chemotherapy with appropriate timing.

The present study has some limitations worth noting, such as its design as a single institutional retrospective study with a small number of patients, dose heterogeneity, and uncertainty regarding optimal hypofractionated C-ion RT doses. Prospective multi-institutional evaluation is necessary with a larger patient cohort in order to clarify the effectiveness and toxicity profile of hypofractionated C-ion RT. In conclusion, our initial results show that hypofractionated C-ion RT appears to be well tolerated and effective for cholangiocarcinoma.

Conflicts of Interests

The Authors declare that they have no competing interests in regard to this study.

Acknowledgements

The Authors thank Kyouhei Fukata, Motohiro Kawashima and Yoshiaki Kubota of the Department of Radiation Oncology, Gunma University, for making substantial contributions to study conception and interpretation of data.

References

- 1 Park J, Kim MH, Kim KP, Park do H, Moon SH, Song TJ, Eum J, Lee SS, Seo DW and Lee SK: Natural history and prognostic factors of advanced cholangiocarcinoma without surgery, chemotherapy, or radiotherapy: a large-scale observational study. *Gut Liver* 3: 298-305, 2009.
- 2 Burke EC, Jarnagin WR, Hochwald SN, Pisters PW, Fong Y and Blumgart LH: Hilar cholangiocarcinoma: patterns of spread, the importance of hepatic resection for curative operation, and a pre-surgical clinical staging system. *Ann Surg* 228: 385-394, 1998.
- 3 Jarnagin WR, Fong Y, DeMatteo RP, Gonen M, Burke EC, Bodniewicz BS J, Youssef BA M, Klimstra D and Blumgart LH: Staging, resectability, and outcome in 225 patients with hilar cholangiocarcinoma. *Ann Surg* 234: 507-517, 2001.
- 4 Han K, Ko HK, Kim KW, Won HJ, Shin YM and Kim PN: Radiofrequency ablation in the treatment of unresectable intrahepatic cholangiocarcinoma: systematic review and meta-analysis. *J Vasc Interv Radiol* 26: 943-948, 2015.
- 5 Yang L, Shan J, Shan L, Saxena A, Bester L and Morris DL: Trans-arterial embolization therapies for unresectable intrahepatic cholangiocarcinoma: a systematic review. *J Gastrointest Oncol* 6: 570-588, 2015.
- 6 Ibrahim SM, Mulcahy MF, Lewandowski RJ, Sato KT, Ryu RK, Masterson EJ, Newman SB, Benson A 3rd, Omary RA and Salem R: Treatment of unresectable cholangiocarcinoma using yttrium-90 microspheres: results from a pilot study. *Cancer* 113: 2119-2128, 2008.
- 7 Zeng ZC, Tang ZY, Fan J, Zhou J, Qin LX, Ye SL, Sun HC, Wang BL, Li D, Wang JH, Zeng MS, Guo W and Tan YS: Consideration of the role of radiotherapy for unresectable intrahepatic cholangiocarcinoma: a retrospective analysis of 75 patients. *Cancer J* 12: 113-122, 2006.
- 8 Chen SC, Chen MH, Li CP, Chen MH, Chang PM, Liu CY, Tzeng CH, Liu YM, Yen SH, Chao Y and Huang PI: External beam radiation therapy with or without concurrent chemotherapy for patients with unresectable locally advanced hilar cholangiocarcinoma. *Hepatogastroenterology* 62: 102-107, 2015.
- 9 Crane CH, Macdonald KO, Vauthey JN, Yehuda P, Brown T, Curley S, Wong A, Delclos M, Charnsangavej C and Janjan NA: Limitations of conventional doses of chemoradiation for unresectable biliary cancer. *Int J Radiat Oncol Biol Phys* 53: 969-974, 2002.
- 10 Ghafoori AP, Nelson JW, Willett CG, Chino J, Tyler DS, Hurwitz HI, Uronis HE, Morse MA, Clough RW and Czito BG: Radiotherapy in the treatment of patients with unresectable extrahepatic cholangiocarcinoma. *Int J Radiat Oncol Biol Phys* 87: 654-659, 2011.
- 11 Morganti AG, Trodella L, Valentini V, Montemaggi P, Costamagna G, Smaniotto D, Luzi S, Ziccarelli P, Macchia G, Perri V, Mutignani M and Cellini N: Combined modality treatment in unresectable extrahepatic biliary carcinoma. *Int J Radiat Oncol Biol Phys* 46: 913-919, 2000.
- 12 Mahadevan A, Dagoglu N, Mancias J, Raven K, Khwaja K, Tseng JF, Ng K, Enzinger P, Miksad R, Bullock A and Evenson A: Stereotactic body radiotherapy (SBRT) for intrahepatic and hilar cholangiocarcinoma. *J Cancer* 6: 1099-1104, 2015.
- 13 Barney BM, Olivier KR, Miller RC and Haddock MG: Clinical outcomes and toxicity using stereotactic body radiotherapy (SBRT) for advanced cholangiocarcinoma. *Radiat Oncol* 7: 67, 2012.
- 14 Kopeck N, Holt MI, Hansen AT and Høyer M: Stereotactic body radiotherapy for unresectable cholangiocarcinoma. *Radiother Oncol* 94: 47-52, 2010.
- 15 Makita C, Nakamura T, Takada A, Takayama K, Suzuki M, Ishikawa Y, Azami Y, Kato T, Tsukiyama I, Kikuchi Y, Hareyama M, Murakami M, Fuwa N, Hata M and Inoue T: Clinical outcomes and toxicity of proton beam therapy for advanced cholangiocarcinoma. *Radiat Oncol* 9: 26, 2014.
- 16 Ohkawa A, Mizumoto M, Ishikawa H, Abei M, Fukuda K, Hashimoto T, Sakae T, Tsuboi K, Okumura T and Sakurai H: Proton beam therapy for unresectable intrahepatic cholangiocarcinoma. *J Gastroenterol Hepatol* 30: 957-963, 2015.
- 17 Hong TS, Wo JY, Yeap BY, Ben-Josef E, McDonnell EI, Blaszkowsky LS, Kwak EL, Allen JN, Clark JW, Goyal L, Murphy JE, Javle MM, Wolfgang JA, Drapek LC, Arellano RS, Mamon HJ, Mullen JT, Yoon SS, Tanabe KK, Ferrone CR, Ryan DP, DeLaney TF, Crane CH and Zhu AX: Multi-institutional phase II study of high-dose hypofractionated proton beam therapy in patients with localized, unresectable hepatocellular carcinoma and intrahepatic cholangiocarcinoma. *J Clin Oncol* 34: 460-468, 2016.

- 18 Ohno T. Particle radiotherapy with carbon ion beams. *EPMA J* 4: 9, 2013.
- 19 Tsujii H and Kamada T: A review of update clinical results of carbon ion radiotherapy. *Jpn J Clin Oncol* 42: 670-685, 2012.
- 20 Abe T, Saitoh J, Kobayashi D, Shibuya K, Koyama Y, Shimada H, Shirai K, Ohno T and Nakano T: Dosimetric comparison of carbon ion radiotherapy and stereotactic body radiotherapy with photon beams for the treatment of hepatocellular carcinoma. *Radiat Oncol* 10: 187, 2015.
- 21 US. Department of health and human services, National Institutes of Health, National Cancer Institute: Common Terminology Criteria for Adverse Events v4.0. http://evs.nci.nih.gov/ftp1/CTCAE/CTCAE_4.03_2010-06-14_QuickReference_5x7.pdf#search=NIH+NCI+CTCAE+4, 2013.
- 22 Sobin L, Gospodarowicz MK and Wittekind C (eds.): *TNM Classification of Malignant Tumours*. Seventh Edition. Hoboken: Wiley-Blackwell, 2009.
- 23 Park JO, Oh DY, Hsu C, Chen JS, Chen LT, Orlando M, Kim JS and Lim HY: Gemcitabine plus cisplatin for advanced biliary tract cancer: A systematic review. *Cancer Res Treat* 47: 343-361, 2015.

Received April 7, 2016

Revised May 10, 2016

Accepted May 11, 2016

Ten-Year Survival of a Patient Treated with Stereotactic Gamma Knife Radiosurgery for Brain Metastases from Colon Cancer with Ovarian and Lymph Node Metastases: A Case Report

Nobuhiro Morinaga^a Naritaka Tanaka^a Yoshinori Shitara^a
Masatoshi Ishizaki^a Takatomo Yoshida^b Hideaki Kouga^c
Kazuki Wakabayashi^c Minoru Fukuchi^d Yoshiyuki Tsunoda^e
Hiroyuki Kuwano^f

^aDepartment of Surgery, Fujioka General Hospital, Fujioka, Japan; ^bDepartment of Pathology, Fujioka General Hospital, Fujioka, Japan; ^cDepartment of Neurosurgery, Fujioka General Hospital, Fujioka, Japan; ^dDepartment of Digestive Tract and General Surgery, Saitama Medical Center, Saitama Medical University, Moroyama, Japan; ^eTsunoda Hospital, Tamamura, Japan; ^fDepartment of General Surgical Science, Graduate School of Medicine, Gunma University, Maebashi, Japan

Keywords

Colorectal cancer · Brain metastasis · Stereotactic Gamma Knife radiosurgery · Multidisciplinary therapy

Abstract

Brain metastasis from colorectal cancer is infrequent and carries a poor prognosis. Herein, we present a patient alive 10 years after the identification of a first brain metastasis from sigmoid colon cancer. A 39-year-old woman underwent sigmoidectomy for sigmoid colon cancer during an emergency operation for pelvic peritonitis. The pathological finding was moderately differentiated adenocarcinoma. Eleven months after the sigmoidectomy, a metastatic lesion was identified in the left ovary. Despite local radiotherapy followed by chemotherapy,

KARGER

Nobuhiro Morinaga
Department of Surgery, Fujioka General Hospital
942-1, Fujioka, Fujioka, Gunma 375-8503 (Japan)
E-Mail no-morinaga@fujioka-hosp.or.jp

the left ovarian lesion grew, so resection of the uterus and bilateral ovaries was performed. Adjuvant chemotherapy with tegafur-uracil (UFT)/calcium folinate (leucovorin, LV) was initiated. Seven months after resection of the ovarian lesion, brain metastases appeared in the bilateral frontal lobes and were treated with stereotactic Gamma Knife radiosurgery. Cervical and mediastinal lymph node metastases were also diagnosed, and irradiation of these lesions was performed. After radiotherapy, 10 courses of oxaliplatin and infused fluorouracil plus leucovorin (FOLFOX) were administered. During FOLFOX administration, recurrent left frontal lobe brain metastasis was diagnosed and treated with stereotactic Gamma Knife radiosurgery. In this case, the brain metastases were well treated with stereotactic Gamma Knife radiosurgery, and the systemic disease arising from sigmoid colon cancer has been kept under control with chemotherapies, surgical resection, and radiotherapy.

© 2016 The Author(s)
Published by S. Karger AG, Basel

Introduction

In general, patients with brain metastasis from colorectal cancer show a poor prognosis, with an overall median survival of 2.8–5.4 months [1–4]. Several reports have mentioned that neurosurgical resection has a favorable impact on prognosis. In previous reports from Japan, only 5 patients with solitary brain metastasis survived more than 5 years [5, 6]. Of these 5 patients, 4 had undergone surgery with chemo- and/or radiotherapy. Whereas surgical resection seemed to be a favorable prognostic factor, it was not statistically significant [7]. So control of systemic disease from colorectal cancer is also important for long-term survival in patients with brain metastasis.

In this report, we present a case of multiple brain metastases, lymph node metastasis, and ovarian metastasis from sigmoid colon cancer treated with chemotherapies, surgical resection, and radiotherapy. The first brain metastatic lesions were treated with stereotactic Gamma Knife radiosurgery (GKS). Because of the less invasive nature of GKS, recurrent brain metastatic lesions could repeatedly be treated with GKS and systemic chemotherapy could be administered. At the time of writing, in March 2016, the patient is alive, with neither neurological nor systemic symptoms. The multidisciplinary therapy, including GKS, resulted in the patient's survival for 10 years after the identification of the first brain metastases and survival for 13 years and 7 months after the sigmoidectomy.

Case Report

A 39-year-old woman underwent an emergency drainage operation for pelvic peritonitis in August 2002. The left ovary was swollen, and paraovarian inflammation was apparent. A stenotic lesion existed at the sigmoid colon, and intraoperative colonoscopy revealed the stenosis to be due to sigmoid colon cancer. Sigmoidectomy with D1 lymph node dissection and stoma construction was therefore performed on the sigmoid colon. The pathological finding was moderately differentiated adenocarcinoma (fig. 1a), and the UICC TNM classification was T2, Nx, M0. Adjuvant chemotherapy was provided using capecitabine.

In July 2003, left ovarian metastasis and para-aortic lymph node metastasis were diagnosed and treated using fluorouracil and folinic acid (leucovorin) (5-FU/LV). After 4 months, the para-aortic lymph node metastasis was considered to have shown complete response, but the ovarian metastasis was classified as stable disease. Although chemotherapy was

changed to irinotecan for 5 months and tegafur/gimeracil/oteracil potassium (TS-1) for 12 months, the ovarian metastasis grew. We applied radiotherapy to the left ovarian lesion. All these therapies proved ineffective in controlling the ovarian metastasis, so resection of the uterus and bilateral ovaries was performed in July 2005. The pathological finding was adenocarcinoma, similar to the sigmoid colon cancer (fig. 1b). Both the sigmoid colon cancer and the left ovarian tumor were stained immunohistochemically with cytokeratin (CK) 7 and CK20. The sigmoid colon cancer showed negative staining for CK7 and positive staining for CK20, as is usually seen in the majority of colorectal cancers (fig. 1c, e). The left ovarian tumor also showed negative staining for CK7 and positive staining for CK20, compatible with its colon cancer origin (fig. 1d, f).

Adjuvant chemotherapy with tegafur-uracil (UFT)/calcium folinate (leucovorin, LV) was initiated. In November 2005, the right cervical subcutaneous lymph nodes became palpable. Computed tomography revealed swelling of the right cervical and mediastinal lymph nodes, so these lesions were diagnosed as lymph node metastases. In March 2006, convulsions of the left arm and leg were noted, followed by weakness of the left leg as well as gait disturbance. Magnetic resonance imaging (MRI) showed metastases in the bilateral frontal lobes (fig. 2a). We selected GKS for the treatment of brain metastases. After GKS, the patient was able to walk and the tumors were reduced in size (fig. 2b). In April 2006, radiotherapy for cervical and mediastinal lymph nodes was performed. In June 2006, administration of oxaliplatin and infused fluorouracil plus leucovorin (FOLFOX) was started as adjuvant chemotherapy. During the administration of FOLFOX, recurrence of a brain metastasis in the left frontal lobe was noted (fig. 3a). In November 2006, GKS for the recurrent brain metastasis was performed and was effective in controlling the lesion (fig. 3b). After 10 courses of FOLFOX, chemotherapy was not administered. At the time of writing, in March 2016, 10 years after the identification of the first brain metastasis, the patient has neither neurological nor systemic symptoms.

Discussion

Brain metastasis is infrequent in colorectal cancer. Patients with brain metastasis from colorectal cancer show a poor prognosis, with an overall median survival of 2.8–5.4 months [1–4]. As stated in case reports from Japan of colorectal cancer patients with solitary brain metastasis, only 5 patients survived more than 5 years [5, 6]. Reports of long-term survival with multiple brain metastases from colorectal cancer are not found in the literature.

In a retrospective review of patients treated for brain metastases from colorectal cancer, Suzuki et al. [4] reported that absence of extracranial metastatic lesions, 1 or 2 brain metastatic lesions, and treatment with neurosurgical resection represent favorable prognostic factors. In addition, several reports have mentioned that patients treated with surgery survived longer than those who did not undergo surgery [1–3]. Whereas resection of brain metastasis seemed to be a favorable prognostic factor, it was not identified as statistically significant in the multivariate analysis by Bartelt et al. [7]. In a study by Mongan et al. [8], the survival curve according to treatments suggests longer survival with stereotactic radiosurgery group than resection plus external beam radiation therapy, WBXRT (whole-brain external-beam radiation therapy), or WBXRT plus chemotherapy group. All of these reports involved retrospective studies, so selection biases may not have been excluded. In the analysis of 12 cases of brain metastasis from colorectal cancer reported by Tajima et al. [9], 9 patients showed multiple lesions. The longest survivor was a patient who had multiple lesions

and survived 505 days (median overall survival: 107 days). This patient was treated with chemotherapy and radiotherapy without surgery.

In patients with a solitary brain metastasis from colorectal cancer who underwent surgery with or without postoperative radiotherapy, death occurred in 82% of cases, according to the evolution of the systemic disease [10]. Thus, control of the systemic disease is important for long-term survival in patients with brain metastasis. Complete resection of brain metastases does not seem necessary for the long-term survival of patients with brain metastasis from colorectal cancer.

Petrovich et al. [11] demonstrated the efficacy and safety of GKS in selected patients with brain metastasis from melanoma, lung cancer, breast cancer, renal cell carcinoma, colon cancer, and others. In their study, depending on the intracranial tumor volume, disease control rates of 80–90% were obtained. Rades et al. [12] compared whole-brain radiotherapy (WBRT) plus stereotactic radiosurgery (SRS) to surgical resection (OP) plus WBRT for 1–3 brain metastases from breast cancer, lung cancer, and other tumors. They concluded that WBRT plus SRS appeared to be at least as effective as OP plus WBRT in terms of treatment outcomes.

In the present case, the primary sigmoid colon cancer was resected. The ovarian metastasis was treated with chemotherapy and radiotherapy and finally resected. The lymph node metastases were controlled with radiotherapy and chemotherapy. The brain metastases were well treated twice with GKS. This multidisciplinary therapy enabled the long-term survival of this patient. The clinical course of this case suggests the effectiveness of GKS for treatment of brain metastasis from colon cancer.

Recently, the median survival of patients with metastatic colorectal cancer has been prolonged by the sequential use of combination regimens. Controlling brain metastasis with GKS and using the combination regimens for systemic disease from colorectal cancer can be effective treatment options for certain patients with brain metastasis from colorectal cancer.

Statement of Ethics

All procedures followed were in accordance with the Helsinki Declaration of 1964 and later revision. Informed consent was obtained from the present patient for being included in this study.

Disclosure Statement

The authors declare that they have no conflict of interest.

References

- 1 Alden TD, Gianino JW, Saclarides TJ: Brain metastases from colorectal cancer. *Dis Colon Rectum* 1996;39:541–545.
- 2 Kye BH, Kim HJ, Kang WK, Cho HM, Hong YK, Oh ST: Brain metastases from colorectal cancer: the role of surgical resection in selected patients. *Colorectal Dis* 2012;14:e378–e385.
- 3 Hammoud MA, McCutcheon IE, Elsouki R, Schoppa D, Patt YZ: Colorectal carcinoma and brain metastasis: distribution, treatment, and survival. *Ann Surg Oncol* 1996;3:453–463.
- 4 Suzuki Y, Yamaguchi T, Matsumoto H, Nakano D, Honda G, Shinoura N, Karasawa K, Takahashi K: Prognostic factors and treatment effects in patients with curatively resected brain metastasis from colorectal cancer. *Dis Colon Rectum* 2014;57:56–63.

- 5 Yamamoto M, Yoshimitsu M, Mukaida H, Hirabayashi N, Takiyama W, Kaneko M: A long-term survived case of solitary brain metastasis from sigmoid colon carcinoma. *J Jpn Surg Assoc* 2013;74:1436–1442.
- 6 Nishimura M, Akamoto S, Yamamoto N, Fujiwara M, Okano K, Suzuki Y: A long-term surviving case of transverse colon cancer presented with solitary brain metastasis. *J Jpn Surg Assoc* 2014;75:1355–1359.
- 7 Bartelt S, Momm F, Weissenberger C, Lutterbach J: Patients with brain metastases from gastrointestinal tract cancer treated with whole brain radiation therapy: prognostic factors and survival. *World J Gastroenterol* 2004;10:3345–3348.
- 8 Mongan JP, Fadul CE, Cole BF, Zaki BI, Suriawinata AA, Ripple GH, Tosteson TD, Pipas JM: Brain metastases from colorectal cancer: risk factors, incidence, and the possible role of chemokines. *Clin Colorectal Cancer* 2009;8:100–105.
- 9 Tajima Y, Ishibashi K, Ishiguro T, Osawa T, Sakimoto T, Okada N, Miyazaki T, Yokoyama M, Yamano T, Nishimura K, Hondo M, Takahashi T, Ishida H: Analysis of 12 cases of brain metastasis from colorectal cancer (in Japanese). *Gan To Kagaku Ryoho* 2009;36:2245–2247.
- 10 D'Andrea G, Isidori A, Caroli E, Orlando ER, Salvati M: Single cerebral metastasis from colorectal adenocarcinoma. *Neurosurg Rev* 2004;27:55–57.
- 11 Petrovich Z, Yu C, Giannotta SL, O'Day S, Apuzzo ML: Survival and pattern of failure in brain metastasis treated with stereotactic gamma knife radiosurgery. *J Neurosurg* 2002;97(suppl):499–506.
- 12 Rades D, Kueter JD, Veninga T, Gliemroth J, Schild SE: Whole brain radiotherapy plus stereotactic radiosurgery (WBRT+SRS) versus surgery plus whole brain radiotherapy (OP+WBRT) for 1–3 brain metastases: results of a matched pair analysis. *Eur J Cancer* 2008;45:400–404.

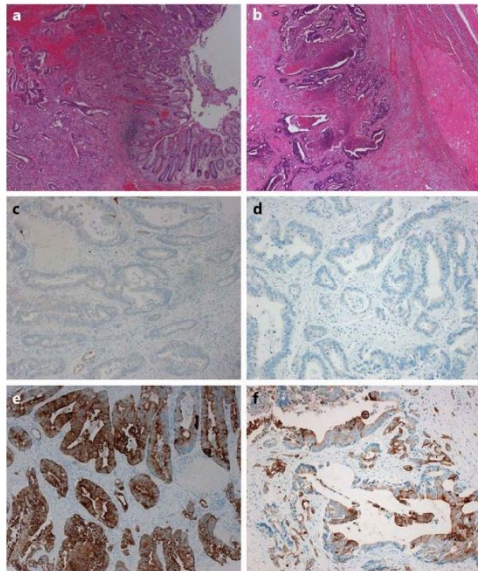


Fig. 1. Pathological findings of primary sigmoid colon cancer and metastatic ovarian tumor. The primary sigmoid colon cancer (a) represents a moderately differentiated adenocarcinoma, and the metastatic ovarian tumor (b) is also identified as an adenocarcinoma. Both the sigmoid colon cancer and ovarian tumor show negative staining for CK7 (c: sigmoid colon cancer; d: ovarian tumor) and positive results for CK20 (e: sigmoid colon cancer; f: ovarian tumor).

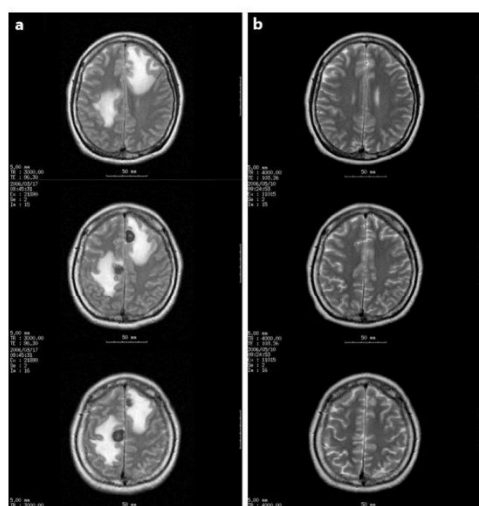


Fig. 2. MRI in March 2006 showed multiple metastatic tumors approximately 18 mm in diameter as well as surrounding brain edema in the bilateral frontal lobes (a). After GKS, the tumors had reduced in size by May 2006 (b).

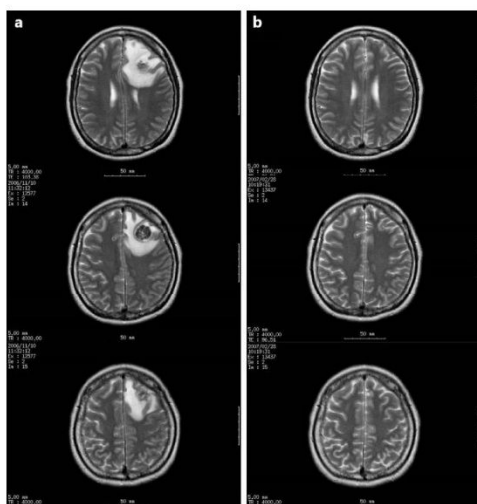


Fig. 3. MRI in November 2006 showed recurrent brain metastasis approximately 20 mm in diameter in the left frontal lobe (a). MRI in February 2007 showed that GKS was effective in controlling the lesion (b).