

## Perioperative management of hepatectomy in patients with interstitial pneumonia: a report of three cases and a literature review

Norio Kubo<sup>1,2</sup> · Kenichiro Araki<sup>1,2</sup> · Takahiro Yamanaka<sup>1,2</sup> · Kouki Hoshino<sup>1</sup> · Norihiro Ishii<sup>1,2</sup> · Mariko Tsukagoshi<sup>1,2</sup> · Takamichi Igarashi<sup>1</sup> · Akira Watanabe<sup>1,2</sup> · Keitaro Hirai<sup>1</sup> · Fumiyoshi Saitoh<sup>1,2</sup> · Hiroyuki Kuwano<sup>2</sup> · Ken Shirabe<sup>1</sup>

Received: 25 August 2016 / Accepted: 24 January 2017  
© Springer Japan 2017

### Abstract

**Purpose** Interstitial pneumonia (IP) is a progressive and irreversible fibrosis and can be fatal if acute exacerbation (AE) occurs. While a useful risk-scoring system has been established for lung surgery, no risk evaluation exists for AE of IP related to non-pulmonary surgery. The objective of this review is to describe the management for patients with IP.

**Methods** We experienced three hepatectomy cases with IP. The first was a 72-year-old male patient diagnosed with hepatocellular carcinoma. Preoperative computed tomography (CT) revealed IP with reticular shadow at the base of both lungs. After hepatectomy, his IP became acutely exacerbated and did not improve with steroid or sivelestat treatment. The second was a 74-year-old male patient diagnosed with hepatocellular carcinoma, and the third was a 75-year-old male patient with liver metastasis. In both these cases, CT revealed a reticular shadow in the lung fields, with increased serum KL-6 levels. We administered pirfenidone for perioperative management, during which time no respiratory complications occurred.

**Results** Perioperative management with pirfenidone for hepatectomy accompanied by IP was successful in our cases.

**Conclusion** We reviewed reports on the perioperative prevention, intraoperative risk factors, and treatment of

postoperative AE of IP and summarized the perioperative management techniques for IP patients undergoing non-pulmonary surgery.

**Keywords** Pirfenidone · Interstitial pneumonia · Acute exacerbation · Abdominal surgery · Hepatectomy

### Introduction

Although hepatectomy can be performed safely with various devices and maneuvers [1, 2], it still carries potential risk, especially in patients with preoperative complications. Interstitial pneumonia (IP) is a chronic and diffuse lung disease with progressive and irreversible fibrosis. When acute exacerbation (AE) of IP occurs, the mortality rate is in the range of 33.3–100% despite aggressive intensive-care management, mechanical ventilation, antibiotics, and steroid therapy [3, 4]. It is difficult to predict preoperatively whether or not AE of IP will occur, although a risk-scoring system for predicting AE of IP after pulmonary resection has been reported [5, 6].

In cases of lung cancer associated with IP, the frequency of AE of IP after surgery has been reported to range from 7.4 to 25% [3, 7, 8]. Postoperative pulmonary complications are frequent and represent a major source of perioperative morbidity and mortality [9, 10]. However, as yet, there have been no reports on the risk evaluation of postoperative AE of IP with regard to abdominal surgery. The literature is limited to case reports of AE of IP after non-pulmonary surgery and the perioperative management of AE of IP patients receiving non-pulmonary resection [11, 12].

We herein report the successful perioperative management of hepatectomy using pirfenidone to prevent AE of IP.

✉ Kenichiro Araki  
karaki@gunma-u.ac.jp

<sup>1</sup> Department of Hepatobiliary and Pancreatic Surgery, Graduate School of Medicine, Gunma University, 3-39-22 Showa-machi, Maebashi, Gunma 371-8511, Japan

<sup>2</sup> Department of General Surgical Science, Graduate School of Medicine, Gunma University, Maebashi, Japan

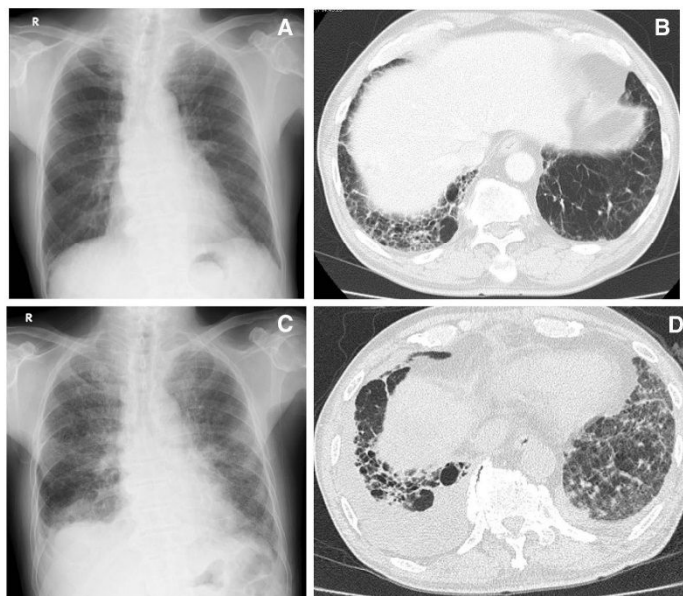
### Case reports

We encountered three cases of hepatectomy complicated with IP. The first case was a 72-year-old male patient diagnosed with a liver tumor who had a history of esophageal carcinoma treated by chemotherapy and radiation therapy 3 years previously. Preoperative chest X-ray did not reveal anything remarkable (Fig. 1a). Preoperative computed tomography (CT) revealed IP with reticular shadow at the base of both lungs (Fig. 1b). Under the risk-scoring system for pulmonary resection developed by Sato et al. [5], the risk score for AE of IP in this patient was 7, and the predicted incidence of AE was 3.3%. We performed subsegmentectomy for hepatocellular carcinoma (HCC) in segment 8 of the liver. The operation time was 348 min, and the ventilation time was 387 min. Blood loss was 1183 g, and the intraoperative fluid balance was +1647 mL. Six days after surgery, he developed dyspnea, and his SpO<sub>2</sub> decreased. Chest X-ray revealed loss of permeability in both lung fields with reticular shadow (Fig. 1c). CT revealed retention of the hydrothorax on both sides and an enhanced IP image (Fig. 1d). We initiated treatment with methylprednisolone and sivelestat sodium. The patient's breathing gradually worsened, and he was intubated. Despite percutaneous

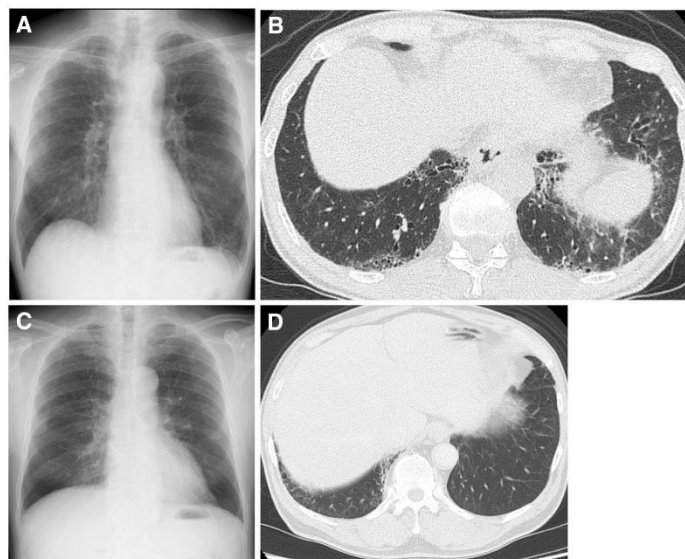
cardiopulmonary support and enforced breathing management, he succumbed 29 days after surgery.

Our second case was a 74-year-old male patient with hepatitis C virus infection who was admitted to our hospital with elevated levels of tumor markers. The tumor, which was enhanced on CT, was 40 mm in diameter in the posterior segment of the right hepatic lobe and was diagnosed as HCC. Chest X-ray showed a diffuse reticular shadow in both lower lung fields (Fig. 2a). CT detected a diffuse reticular shadow, tractional bronchus expansion, and pleural thickening in the inferior lobe of both lungs (Fig. 2b). Ground-glass opacity was apparent in the inferior lobe of the left lung. He had no respiratory symptoms but was considered to be at risk for IP or respiratory complications after hepatectomy. The risk score for AE of IP was 7. We consulted a respiratory physician regarding the perioperative management of IP. Before the operation, pirfenidone was administered at a daily dose of 600 mg for the prevention of AE of IP. After 2 week pirfenidone therapy, the serum KL-6 levels decreased from 954 to 835 U/mL. CT revealed no change in the usual IP pattern after 2 weeks of therapy, suggesting that the IP was stable and without inflammatory reaction. The results of pulmonary function testing and an arterial blood gas analysis were within the normal range. We diagnosed the patient with HCC with IP and performed posterior segment hepatectomy and cholecystectomy under

**Fig. 1** Case 1. **a** Preoperative chest X-ray revealed nothing remarkable. **b** Preoperative computed tomography (CT) revealed IP with reticular shadow at the base of both lungs. **c** Chest X-ray revealed loss of permeability in both lung fields with reticular shadow. **d** CT revealed retention of hydrothorax on both sides and enhanced IP images



**Fig. 2** **a** Case 2. Chest X-ray showed ground-glass opacity in both lower lung fields. **b** Chest CT before surgery revealed diffuse ground-glass opacities and interstitial changes in both lower lung fields. **c** Case 3. Preoperative chest X-ray revealed nothing remarkable. **d** CT detected diffuse reticular shadows in the inferior lobe of both lungs



general anesthesia combined with spinal-epidural anesthesia. During the operation, the fraction of inspired oxygen, tidal volume during surgery, and intraoperative fluid balance was minimized by the anesthesiologist. The operation time was 368 min, and the ventilation time was 441 min. Blood loss was 357 g, and the intraoperative fluid balance was +3093 mL. After surgery, the patient was extubated immediately and transferred to the intensive-care unit. Pirfenidone was administered as soon as oral intake was possible. Seven days after surgery, CT revealed no development of IP, and the KL-6 had decreased further to 528 U/mL. The perioperative respiratory function was unremarkable, without any pulmonary complications. The patient was discharged 13 days after surgery with continuing administration of pirfenidone.

The third case was a 75-year-old male patient who had undergone sigmoidectomy 2 years previously. Liver metastasis was detected on follow-up CT. Preoperative chest X-ray did not reveal any particular findings (Fig. 2c). CT detected a diffuse reticular shadow in the inferior lobe of both lungs (Fig. 2d). The KL-6 levels were elevated to 1059 U/mL and increased to 1559 U/mL after a single administration of pirfenidone. The AE of IP risk score was 9. After 3 months of pirfenidone therapy, the serum KL-6 levels had decreased to 784 U/mL. We then performed laparoscopic partial hepatectomy. The operation time was 313 min, and the ventilation time was 418 min. Blood loss was 15 g, and the intraoperative fluid balance was

+1860 mL. Perioperative management with pirfenidone was continued as described for the second case. The patient was discharged 8 days after surgery with continuing administration of pirfenidone.

We explained the risk of AE of IP after surgery with the risk score and obtained informed consent from all three patients before surgery. Informed consent included explaining alternative therapies with curative effects, such as radiofrequency ablation or transcatheter arterial chemoembolization, and the risk of these therapies.

## Discussion

In this study, the presented cases were classified in possible UIP with CT images based on the criteria of the American Thoracic Society/European Respiratory Society/Japanese Respiratory Society/Latin American Thoracic Association statement for IPF [13]. The diagnosis of IPF required a surgical lung biopsy when identified in possible UIP pattern cases. We believed that we could reduce the risk of AE of IP by preoperative treatment with pirfenidone, as in respiratory surgery [14]. The risk factors of AE of IP after abdominal surgery have not yet been sufficiently studied. The first patient we encountered had received radiation therapy for esophageal cancer in the past. Radiation pneumonitis had not been noted on CT, and 3 years had passed since the radiation therapy when we treated the patient. We,



therefore, believe that the radiation therapy was unlikely to have been involved in the onset of AE of IP in this patient. When the first case underwent surgery, the risk of AE of IP in this patient was still unclear, and anesthesia management was carried out as usual. AE of IP is an infrequent complication after abdominal surgery but can be fatal in some cases. The indications for surgery need to be assessed in detail with focus on the pulmonary function and the risk of AE of IP after surgery.

The risk factors for AE of IP that have been reported include surgical procedures at pulmonary resection, male sex, history of exacerbation, preoperative steroid use, high levels of serum sialylated carbohydrate antigen KL-6, a typical IP appearance on CT, reduced percent predicted vital capacity, low body mass index, emergency surgery, lung surgery, and long anesthesia time [9, 15]. A risk-scoring system for predicting AE of IP after pulmonary surgery has also been suggested, which includes a history of AE, surgical procedures, UIP appearance, male sex, preoperative steroid use, high KL-6 levels, and a low vital capacity [5]. Our predicted risk of AE of IP after hepatectomy was 3.3% for cases 1 and 2 and 6.0% for case 3, primarily based on the patients being male and having the usual IP appearance on CT with or without a high level of KL-6. Table 1 describes several cases of AE of IP after non-pulmonary surgery [9, 11, 12], but the frequency is unknown. The occurrence of AE in non-pulmonary surgery raises the possibility that perioperative lung dynamics may be responsible for the high oxygen concentration, mechanical insult due to higher airway pressures, or higher tidal volumes [12]. AE of IP after non-pulmonary surgery can occur in any patient undergoing surgery with general anesthesia, as in case 1. We determined the indication of hepatectomy with due consideration of the risk of AE of IP based on the risk-score system; we then explained the risk to all three patients and obtained their informed consent before surgery. No method of assessing the risk of AE of IP in abdominal surgery patients has yet been developed. Nationwide surveillance and a system for evaluating the risk of AE of IP after non-pulmonary resection, especially abdominal surgery, are clearly needed.

KL-6, surfactant protein (SP)-A, SP-D, and monocyte chemoattractant protein-1 (MCP-1) are reported to be sensitive markers for interstitial lung disease (ILD). The half-life of SP-A was reported to be 4.5 min, and the half-life of KL-6 is longer than that of SP-A [16]. Ohnishi suggested that KL-6 is the best serum marker for IP with respect to its sensitivity, specificity, and diagnostic accuracy [17]. A preventive effect of perioperative pirfenidone treatment for postoperative AE of IP in patients with lung cancer was reported [14]. The KL-6 levels in the patients who received perioperative pirfenidone treatment decreased significantly during the preoperative period and further after surgery

**Table 1** Acute exacerbation of interstitial pneumonia after non-pulmonary surgery

Author	Age (years)	Sex	VC (% pred)	DLCO (% pred)	FEV1.0 (% pred)	KL-6 (U/mL)	Predicted scoring	Diagnosis	Surgery	Time to AE (POD)	Treatment
Choi SM	69	M	90	74	-	-	>7	Prostate cancer	Robot-assisted laparoscopic radical prostatectomy	-	-
Kubota T	66	F	-	-	-	-	>4	Hemo peritoneum	Intestinal anastomosis appendectomy	-	-
	76	F	57	-	90	353	>1	Nuchal lipoma	Remove a lipoma	4	Sivelestat sodium methylprednisolone
Ghatal A	58	M	77	68.8	82.3	-	>8	Orthopedic disorder	Total knee replacement	7	-
	61	M	46.2	35.8	52.1	-	>13	Coronary disease	Coronary artery bypass graft surgery	2	-

VC vital capacity, DLCO diffusion capacity for carbon monoxide, FEV1.0 forced expiratory volume, AE acute exacerbation, POD postoperative day

**Table 2** Studies related to the acute exacerbation of interstitial pneumonia

Classification by contents	Number of patients	Number of patients with AE (%)	Notable features
<b>Predicted scoring system</b>			
Simple risk-scoring system [10]	1022	100 (9.8)	Predict with seven preoperative factors
High-resolution computed tomography score system [4]	28	9 (32.1)	Predict with computed tomography images
<b>Preservation of AE of IP</b>			
Pirfenidone [14]	28	6 (21.4)	Pirfenidone prevented postoperative AE of IP in clinical study
Nintedanib [15]	–	–	Nintedanib prevented postoperative AE of IP in clinical study
Macrolides [16, 17]	–	–	Preventing effect of erythromycin in vivo
<i>N</i> -Acetylcysteine [18, 19]	–	–	<i>N</i> -Acetylcysteine had an inhibitory effect on IL-8 and MMP-9 release and progress of IP
Neutrophil elastase inhibitor [20]	–	–	Neutrophil elastase inhibitor decreased fibrosis in vivo
Sivelestat sodium hydrate with low-dose methylprednisolone [21]	31	0	Perioperative administration may be useful as prophylaxis for AE of IP
<b>Perioperative management</b>			
Mechanical ventilation during operation [22]	68	3 (4.4)	High oxygen concentration, airway pressures and tidal volume increase the risk
Intraoperative excessive fluid infusion [23]	52	7 (13.5)	The amount of intraoperative fluid was a risk factor for AE of IP
<b>Treatment for AE of IP</b>			
High-dose corticosteroids [24]	–	–	Corticosteroid therapy demonstrated clinical improvement
Cyclosporine A [25, 26]	–	–	The prognosis of the cyclosporine-treated patients was better
Cyclophosphamide [27]	–	–	Improved AE of IP with cyclophosphamide
Recombinant human soluble thrombomodulin [29]	22	–	The mortality rate was significantly lower in the thrombomodulin group
Nintedanib [31]	–	–	Improved AE of IP with nintedanib
Polymixin B-immobilized fiber column	–	–	Neutrophils and MMP-9 levels were significantly decreased
Hemoperfusion [32–34]	–	–	The PaO <sub>2</sub> /fraction of the inspired oxygen ratio increased

[18]. KL-6 >1000 U/mL was included in the risk-score system, and the baseline serum KL-6 was an independent predictive factor for AE of IP in a multivariate analysis [19]. We believe that a reduction in the KL-6 levels reduces the risk of postoperative AE of IP. In this study, we used KL-6 as a marker of indication for surgery.

Only a few drugs have been established as successful in reducing the incidence of AE of IP. Pirfenidone was used as an oral antifibrotic therapy and reduced disease progression, as measured by the decline in the vital capacity or forced vital capacity, in patients with pulmonary fibrosis [20]. A significant difference was reported in the incidence of AE of IP between patients treated with pirfenidone and a placebo group [21], while in another study, there were no severe drug-related complications or IP-related events in the pirfenidone-treated

group [22]. AE of IP was significantly less frequent in the pirfenidone-treated group than in the control group in a pulmonary resection study [18]. In the present study, pirfenidone was used perioperatively, and the authors propose that the absence of pulmonary complications was due to pirfenidone therapy. Other drugs have also been reported as useful for the prevention of AE of IP. Nintedanib is a potent tyrosine kinase inhibitor with distinct specificity, targeting growth factors involved in fibrotic changes in the lungs of patients with IP [23]. For perioperative administration to prevent AE, macrolides [24, 25], *N*-acetylcysteine [26, 27], and proteinase inhibitors [28] have been reported to be useful. Combination administration with sivelestat sodium hydrate and low-dose methylprednisolone may also be beneficial as prophylaxis for AE of IP [29].

The intraoperative administration of supplemental oxygen at a high concentration and mechanical ventilation-related lung injury has been suggested as likely major causes of AE of IP in pulmonary resection [30]. Intraoperative excessive fluid infusion has also been reported to be a risk factor for AE of IP [31]. Cooperation between surgeons and anesthesiologists to perform less-invasive surgery is of great importance in preventing AE of IP, and intraoperative management that minimizes the concentration of oxygen, tidal volume, and intravenous fluid administration is warranted.

There is little evidence that the currently accepted treatments are effective for AE of IP. Some studies have reported that immunosuppressive agents, such as high-dose corticosteroids [32], cyclosporine A [33, 34], and cyclophosphamide [35], were efficacious. By contrast, however, patients receiving methylprednisolone pulse therapy in combination with cyclophosphamide or cyclosporine A did not achieve significantly improved outcomes for AE of IP [36]. Recombinant human soluble thrombomodulin is associated with reductions in the mortality rate in patients with AE of IP [37]. Disorders of coagulation and fibrinolysis are major components of AE of IP, and anticoagulant therapy is reported to be beneficial [38]. It was reported that the administration of nintedanib in patients who developed AE of IP was effective [39]. Furthermore, recent reports have suggested that the use of polymyxin B-immobilized fiber-column hemoperfusion (PMX-DHP) may be effective in patients with AE of idiopathic pulmonary fibrosis [40–42]. One study reported that the serum levels of cytokines, including interleukin (IL)-9, IL-12, IL-17, and vascular endothelial growth factor, were significantly decreased immediately after PMX-DHP and contributed to the rapid improvement in oxygenation by suppressing vascular permeability in the lung [43].

For major surgery, such as hepatectomy with severe IP, the selection of appropriate therapy based on an accurate evaluation of the IP activity and the careful management of the perioperative respiratory state are required. Table 2 summarizes the reports on IP that all non-respiratory surgeons should review. When there is inflammation or progression of IP, we should avoid surgery and prioritize antifibrotic therapy. Pirfenidone may be useful for the management of abdominal surgery with IP, but further well-designed, prospective, multicenter studies are required to help us better understand the risks for AE of IP in relation to non-pulmonary surgery.

#### Compliance with ethical standards

**Conflict of interest** All authors have nothing to disclose.

 Springer

## References

- Nanashima A, Nagayasu T. Development and clinical usefulness of the liver hanging maneuver in various anatomical hepatectomy procedures. *Surg Today*. 2016;46:398–404.
- Kawaguchi Y, Otsuka Y, Kaneko H, et al. Comparisons of financial and short-term outcomes between laparoscopic and open hepatectomy: benefits for patients and hospitals. *Surg Today*. 2016;46:535–42.
- Chiyo M, Sekine Y, Iwata T, et al. Impact of interstitial lung disease on surgical morbidity and mortality for lung cancer: analyses of short-term and long-term outcomes. *J Thorac Cardiovasc Surg*. 2003;126:1141–6.
- Kushibe K, Kawaguchi T, Takahama M, et al. Operative indications for lung cancer with idiopathic pulmonary fibrosis. *Thorac Cardiovasc Surg*. 2007;55:505–8.
- Sato T, Kondo H, Watanabe A, et al. A simple risk scoring system for predicting acute exacerbation of interstitial pneumonia after pulmonary resection in lung cancer patients. *Gen Thorac Cardiovasc Surg*. 2015;63:164–72.
- Suzuki H, Sekine Y, Yoshida S, et al. Risk of acute exacerbation of interstitial pneumonia after pulmonary resection for lung cancer in patients with idiopathic pulmonary fibrosis based on preoperative high-resolution computed tomography. *Surg Today*. 2011;41:914–21.
- Watanabe A, Higami T, Ohori S, et al. Is lung cancer resection indicated in patients with idiopathic pulmonary fibrosis? *J Thorac Cardiovasc Surg*. 2008;136:1357–63 (1363 e1351–1352).
- Fujita J, Yamadori I, Namihira H, et al. Increased intensity of lung infiltrates at the side of lung cancer in patients with lung cancer associated with pulmonary fibrosis. *Lung Cancer*. 1999;26:169–74.
- Choi SM, Lee J, Park YS, et al. Postoperative pulmonary complications after surgery in patients with interstitial lung disease. *Respiration*. 2014;87:287–93.
- Katayama H, Kurokawa Y, Nakamura K, et al. Extended Clavien–Dindo classification of surgical complications: Japan Clinical Oncology Group postoperative complications criteria. *Surg Today*. 2016;46:668–85.
- Kubota T, Miyata A. Postoperative respiratory failure caused by acute exacerbation of idiopathic interstitial pneumonia. *J Anesth*. 2011;25:422–5.
- Ghatol A, Ruhl AP, Danoff SK. Exacerbations in idiopathic pulmonary fibrosis triggered by pulmonary and nonpulmonary surgery: a case series and comprehensive review of the literature. *Lung*. 2012;190:373–80.
- Raghu G, Collard HR, Egan JJ, et al. An official ATS/ERS/IRIS/ALAT statement: idiopathic pulmonary fibrosis: evidence-based guidelines for diagnosis and management. *Am J Respir Crit Care Med*. 2011;183:788–824.
- Iwata T, Yoshida S, Fujiwara T, et al. Effect of perioperative pirfenidone treatment in lung cancer patients with idiopathic pulmonary fibrosis. *Ann Thorac Surg*. 2016;102:1905–10.
- Sato T, Teramukai S, Kondo H, et al. Impact and predictors of acute exacerbation of interstitial lung diseases after pulmonary resection for lung cancer. *J Thorac Cardiovasc Surg* 2014;147:1604–11 (e1603).
- Doyle IR, Nicholas TE, Bersten AD. Serum surfactant protein-A levels in patients with acute cardiogenic pulmonary edema and adult respiratory distress syndrome. *Am J Respir Crit Care Med*. 1995;152:307–17.
- Ohnishi H, Yokoyama A, Kondo K, et al. Comparative study of KL-6, surfactant protein-A, surfactant protein-D, and monocyte chemoattractant protein-1 as serum markers for interstitial lung diseases. *Am J Respir Crit Care Med*. 2002;165:378–81.

18. Iwata T, Yoshida S, Nagato K, et al. Experience with perioperative pirfenidone for lung cancer surgery in patients with idiopathic pulmonary fibrosis. *Surg Today*. 2015;45:1263–70.
19. Ohshimo S, Ishikawa N, Horimasu Y, et al. Baseline KL-6 predicts increased risk for acute exacerbation of idiopathic pulmonary fibrosis. *Respir Med*. 2014;108:1031–9.
20. King TE Jr, Bradford WZ, Castro-Bernardini S, et al. A phase 3 trial of pirfenidone in patients with idiopathic pulmonary fibrosis. *N Engl J Med*. 2014;370:2083–92.
21. Taniguchi H, Ebina M, Kondoh Y, et al. Pirfenidone in idiopathic pulmonary fibrosis. *Eur Respir J*. 2010;35:821–9.
22. Lancaster L, Albera C, Bradford WZ, et al. Safety of pirfenidone in patients with idiopathic pulmonary fibrosis: integrated analysis of cumulative data from 5 clinical trials. *BMJ Open Respir Res*. 2016;3:e000105.
23. Bonella F, Stowasser S, Wollin L. Idiopathic pulmonary fibrosis: current treatment options and critical appraisal of nintedanib. *Drug Des Devel Ther*. 2015;9:6407–19.
24. Azuma A, Furuta T, Enomoto T, et al. Preventive effect of erythromycin on experimental bleomycin-induced acute lung injury in rats. *Thorax*. 1998;53:186–9.
25. Li Y, Azuma A, Takahashi S, et al. Fourteen-membered ring macrolides inhibit vascular cell adhesion molecule 1 messenger RNA induction and leukocyte migration: role in preventing lung injury and fibrosis in bleomycin-challenged mice. *Chest*. 2002;122:2137–45.
26. Radomska-Lesniewska DM, Skopinska-Rozewska E, Jankowska-Steifer E, et al. *N*-Acetylcysteine inhibits IL-8 and MMP-9 release and ICAM-1 expression by bronchoalveolar cells from interstitial lung disease patients. *Pharmacol Rep*. 2010;62:131–8.
27. Demedts M, Behr J, Buhl R, et al. High-dose acetylcysteine in idiopathic pulmonary fibrosis. *N Engl J Med*. 2005;353:2229–42.
28. Taoka Y, Maeda A, Hiyama K, et al. Effects of neutrophil elastase inhibitor on bleomycin-induced pulmonary fibrosis in mice. *Am J Respir Crit Care Med*. 1997;156:260–5.
29. Ito H, Nakayama H, Yokose T, Yamada K. Prophylaxis for acute exacerbation of interstitial pneumonia after lung resection. *Asian Cardiovasc Thorac Ann*. 2014;22:948–54.
30. Sakamoto S, Homma S, Mun M, et al. Acute exacerbation of idiopathic interstitial pneumonia following lung surgery in 3 of 68 consecutive patients: a retrospective study. *Intern Med*. 2011;50:77–85.
31. Mizuno Y, Iwata H, Shirahashi K, et al. The importance of intraoperative fluid balance for the prevention of postoperative acute exacerbation of idiopathic pulmonary fibrosis after pulmonary resection for primary lung cancer. *Eur J Cardiothorac Surg*. 2012;41:e161–5.
32. Panos RJ, Mortenson RL, Niccoli SA, King TE Jr. Clinical deterioration in patients with idiopathic pulmonary fibrosis: causes and assessment. *Am J Med*. 1990;88:396–404.
33. Sakamoto S, Homma S, Miyamoto A, et al. Cyclosporin A in the treatment of acute exacerbation of idiopathic pulmonary fibrosis. *Intern Med*. 2010;49:109–15.
34. Inase N, Sawada M, Ohtani Y, et al. Cyclosporin A followed by the treatment of acute exacerbation of idiopathic pulmonary fibrosis with corticosteroid. *Intern Med*. 2003;42:565–70.
35. Ambrosini V, Cancellieri A, Chilosi M, et al. Acute exacerbation of idiopathic pulmonary fibrosis: report of a series. *Eur Respir J*. 2003;22:821–6.
36. Okamoto T, Gotoh M, Masuya D, et al. Clinical analysis of interstitial pneumonia after surgery for lung cancer. *Jpn J Thorac Cardiovasc Surg*. 2004;52:323–9.
37. Abe M, Tsushima K, Matsumura T, et al. Efficacy of thrombomodulin for acute exacerbation of idiopathic pulmonary fibrosis and nonspecific interstitial pneumonia: a nonrandomized prospective study. *Drug Des Devel Ther*. 2015;9:5755–62.
38. Kubo H, Nakayama K, Yanai M, et al. Anticoagulant therapy for idiopathic pulmonary fibrosis. *Chest*. 2005;128:1475–82.
39. Ikeda S, Sekine A, Baba T, et al. Administration of nintedanib after discontinuation for acute exacerbation of idiopathic pulmonary fibrosis: a case report. *BMC Pulm Med*. 2016;16:38.
40. Seo Y, Abe S, Kurahara M, et al. Beneficial effect of polymyxin B-immobilized fiber column (PMX) hemoperfusion treatment on acute exacerbation of idiopathic pulmonary fibrosis. *Intern Med*. 2006;45:1033–8.
41. Abe S, Seo Y, Hayashi H, et al. Neutrophil adsorption by polymyxin B-immobilized fiber column for acute exacerbation in patients with interstitial pneumonia: a pilot study. *Blood Purif*. 2010;29:321–6.
42. Enomoto N, Suda T, Uto T, et al. Possible therapeutic effect of direct haemoperfusion with a polymyxin B immobilized fibre column (PMX-DHP) on pulmonary oxygenation in acute exacerbations of interstitial pneumonia. *Respirology*. 2008;13:452–60.
43. Oishi K, Mimura-Kimura Y, Miyasho T, et al. Association between cytokine removal by polymyxin B hemoperfusion and improved pulmonary oxygenation in patients with acute exacerbation of idiopathic pulmonary fibrosis. *Cytokine*. 2013;61:84–9.