

CASE REPORT

Successful outcome following detection and removal of a very small ovarian teratoma associated with anti-NMDA receptor encephalitis during pregnancy

Etsuko Mizutamari¹, Yuji Matsuo¹, Tomohiro Namimoto², Takashi Ohba¹, Yasuyuki Yamashita² & Hidetaka Katabuchi¹

¹Department of Obstetrics and Gynecology, Faculty of Life Science, Kumamoto University, 1-1-1 Honjo, Chuo-ku, Kumamoto-city, Kumamoto 860-8556, Japan

²Department of Diagnostic Radiology, Faculty of Life Science, Kumamoto University, 1-1-1 Honjo, Chuo-ku, Kumamoto-city, Kumamoto 860-8556, Japan

Correspondence

Etsuko Mizutamari, Department of Obstetrics and Gynecology, Faculty of Life Science, Kumamoto University, 1-1-1 Honjo, Chuo-ku, Kumamoto-city, Kumamoto 860-8556, Japan. Tel: +81 96 373 5269; Fax: +81 96 363 5164; E-mail: mizutamarietsuko@gmail.com

Funding Information

No sources of funding were declared for this study.

Received: 9 September 2015; Revised: 16 November 2015; Accepted: 18 November 2015

Clinical Case Reports 2016; 4(3): 223–225

doi: 10.1002/ccr3.475

Introduction

Anti-N-methyl-D-aspartate (NMDA) receptor encephalitis was identified in 2007 by Dalmau and colleagues [1]. It is caused by an autoimmune reaction against the NMDA receptor, which is characterized by psychiatric and neurologic symptoms mimicking herpetic encephalitis. The onset of anti-NMDA receptor encephalitis in females is associated with ovarian teratomas [1, 2]. Herein we report a case of anti-NMDA receptor encephalitis without neurological sequelae after prompt detection and treatment of a small ovarian teratoma in a pregnant woman at 16 weeks of gestation.

Case Report

A healthy 30-year-old gravida 1 para 1 woman conceived naturally and began receiving prenatal care at a local

Key Clinical Message

An important part of anti-N-methyl-D-aspartate (NMDA) receptor encephalitis treatment is prompt detection and removal of any associated ovarian teratoma, regardless of size. High-resolution transvaginal ultrasonography followed by targeted CT with adaptive iterative dose reduction (AIDR) is a useful strategy for distinguishing small ovarian teratomas from luteal cysts during pregnancy.

Keywords

Adaptive iterative dose reduction, anti-NMDA receptor encephalitis, ovarian teratoma, pregnancy, ultrasonography.

general hospital. She had a history of left ovarian teratoma, which was resected at 24 years of age. During week 15 of gestation, she initially developed a high fever with headaches, and was admitted to the local general hospital. Viral encephalitis was initially suspected but ruled out. Despite symptomatic treatment, her condition worsened. She was referred to Kumamoto University Hospital because of an altered state of consciousness and aspiration pneumonia at 16 weeks +1 day of gestation.

On admission, she had nuchal rigidity and was in respiratory failure requiring mechanical ventilation in the intensive care unit. On hospital day 3, anti-NMDA receptor antibodies were found in her cerebrospinal fluid, prompting us to explore for an ovarian teratoma. Non-contrast magnetic resonance imaging (MRI, MAGNETOM Trio A Tim System 3T, SIEMENS, Erlangen, Germany) detected a cystic mass in the right ovary (Fig. 1A); however, since it was difficult to distinguish

© 2015 The Authors. *Clinical Case Reports* published by John Wiley & Sons Ltd.

This is an open access article under the terms of the Creative Commons Attribution-NonCommercial-NoDerivs License, which permits use and distribution in any medium, provided the original work is properly cited, the use is non-commercial and no modifications or adaptations are made.

223

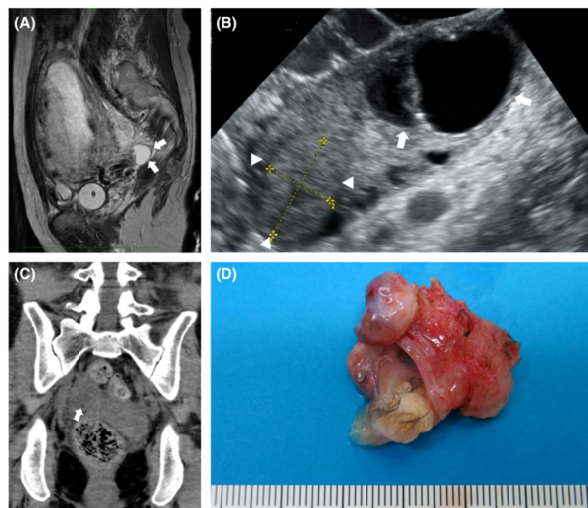


Figure 1. (A) T2-weighted magnetic resonance images of the pelvis in the sagittal plane at 16 weeks of gestation. A cystic mass (arrows) was found in the right adnexa. A lipid component could not be detected. (B) High-resolution transvaginal ultrasonography of the right ovary. A cystic mass (arrows) was detected next to the corpus luteum (arrowheads). (C) Noncontrast computed tomography with adaptive iterative dose reduction of the adnexal area was performed at 16 weeks of gestation. A tiny lipid component (arrow) was detected in the adnexal mass. (D) Macroscopic findings of the right ovarian tumor. The tumor measured $10 \times 25 \times 30 \text{ mm}^3$ and contained adipose tissue and hair.

this mass from a luteal cyst, we could not confirm the diagnosis of ovarian teratoma. High-resolution transvaginal ultrasonography (RIC6-12-D convex probe, 5.0–13.0 MHz; Voluson E8, GE Healthcare UK, Buckinghamshire, England) detected a cystic mass next to the corpus luteum of the right ovary (Fig. 1B). Noncontrast computed tomography (CT, 120 kV, 150 mA; Aquilion ONE, Toshiba Medical, Tochigi, Japan) with adaptive iterative dose reduction (AIDR) targeting the right adnexa showed that the mass had a very small lipid component (Fig. 1C). The volume CT dose index was 12 mGy, and the dose-length product was 432 mGy/cm. These findings were consistent with ovarian teratoma, and she was scheduled for laparotomy. Right oophorectomy was performed at 16 weeks + 4 days of gestation. The tumor measured $10 \times 25 \times 30 \text{ mm}^3$ (Fig. 1D). Pathological examination revealed mature cystic teratoma of the right ovary. After 4 weeks of postoperative therapy including five courses of plasma exchange, intravenous immunoglobulin therapy, and methylprednisolone pulse therapy, she recovered steadily. She was discharged at 25 weeks of gestation. Subsequently, her pregnancy was uneventful and she delivered a healthy baby at 40 weeks. Anti-NMDA receptor antibody titers were negative in the

umbilical vein blood sample. The mother and the infant were healthy with no obvious symptoms.

Discussion

Approximately 90% of patients with anti-NMDA receptor encephalitis are female, and more than 50% of them have ovarian teratoma [3]. Detection and subsequent removal of the teratoma in patients with anti-NMDA receptor encephalitis results in greater clinical improvement than in patients with no detected tumor [4].

It has been suggested that the severity of encephalitis is not related to tumor size [5]. Since anti-NMDA receptor encephalitis often occurs with very small ovarian teratomas and results in serious, irreversible symptoms, evaluation for an ovarian teratoma followed by prompt surgical resection is crucial.

While assessing an ovarian mass during pregnancy, adverse effects on the fetus and differentiating the mass from a luteal cyst are important considerations. Various imaging modalities such as ultrasonography, MRI, and CT are used to evaluate ovarian masses during pregnancy. Although ultrasonography and MRI can be used safely to evaluate adnexal masses during pregnancy, it is difficult

to differentiate ovarian tumors from luteal cysts during early pregnancy. Hoover *et al.* reported that 17% of ovarian masses that were surgically removed during pregnancy were functional cysts, including corpus luteal cysts [6]. Although CT is a powerful tool for detecting a lipid component, which is characteristic of teratomas, pelvic CT in the first trimester is relatively contraindicated due to possible adverse effects on the developing fetus.

The fetal exposure doses from a single pelvic CT examination remains below the consensus level or levels associated with negligible risk (50–150 mGy), well below the actionable level of 150 mGy [7]. Moreover, AIDR technology has been developed to eliminate noise and artifacts from reduced-dose CT examinations. Image quality and resolution are similar to standard CT, but with significantly lower (38.2%) radiation doses [8]. Compared to standard CT, the radiation dose in our patient was reduced in half by the use of AIDR and targeting the adnexal area. Our case suggests that high-resolution transvaginal ultrasonography followed by targeted reduced-dose CT with AIDR is a useful strategy for distinguishing very small ovarian teratomas from luteal cysts during pregnancy.

In conclusion, appropriate treatment, including prompt detection with transvaginal ultrasonography followed by reduced-dose CT with AIDR and surgical resection of an ovarian teratoma, can result in a good prognosis for both mother and child.

Conflict of Interest

None declared.

References

- Dalmau, J., E. Tüzün, H. Wu, J. Masjuan, J. E. Rossi, A. Voloschin, *et al.* 2007. Paraneoplastic anti-N-methyl-D-aspartate receptor encephalitis associated with ovarian teratoma. *Ann. Neurol.* 61:25–36.
- Tüzün, E., L. Zhou, J. M. Baehring, S. Bannykh, M. Rosenfeld, and J. Dalmau. 2009. Evidence for antibody-mediated pathogenesis in anti-NMDAR encephalitis associated with ovarian teratoma. *Acta Neuropathol.* 118:737–743.
- Dalmau, J., A. J. Gleichman, E. G. Hughes, J. Rossi, X. Peng, M. Lai, *et al.* 2008. Anti-NMDA receptor encephalitis: case series and analysis of the effects of antibodies. *Lancet Neurol.* 7:1091–1098.
- Dalmau, J., E. Lancaster, E. Martinez-Hernandez, M. R. Rosenfeld, and R. Balice-Gordon. 2011. Clinical experience and laboratory investigations in patients with anti-NMDAR encephalitis. *Lancet Neurol.* 10: 63–74.
- Motohara, T., S. Tayama, D. Narantuya, H. Tashiro, and H. Katabuchi. 2013. Anti-N-methyl D-aspartate receptor encephalitis associated with ovarian teratoma: clinical presentation, diagnosis, treatment, and surgical management. *Int. Cancer Conf. J.* 2: 121–130.
- Hoover, K., and T. R. Jenkins. 2011. Evaluation and management of adnexal mass in pregnancy. *Am. J. Obstet. Gynecol.* 205:97–102.
- McCullough, C. H., B. A. Schueler, T. D. Atwell, N. N. Braun, D. M. Regner, D. L. Brown, *et al.* 2007. Radiation exposure and pregnancy: when should we be concerned? *Radiographics* 27:909–918.
- Gonzalez-Guindalini, F. D., M. P. F. Botelho, H. G. Töre, R. W. Ahn, L. I. Gordon, and V. Yaghmai. 2013. MDCT of chest, abdomen, and pelvis using attenuation-based automated tube voltage selection in combination with iterative reconstruction: an inpatient study of radiation dose and image quality. *Am. J. Roentgenol.* 201: 1075–1082.