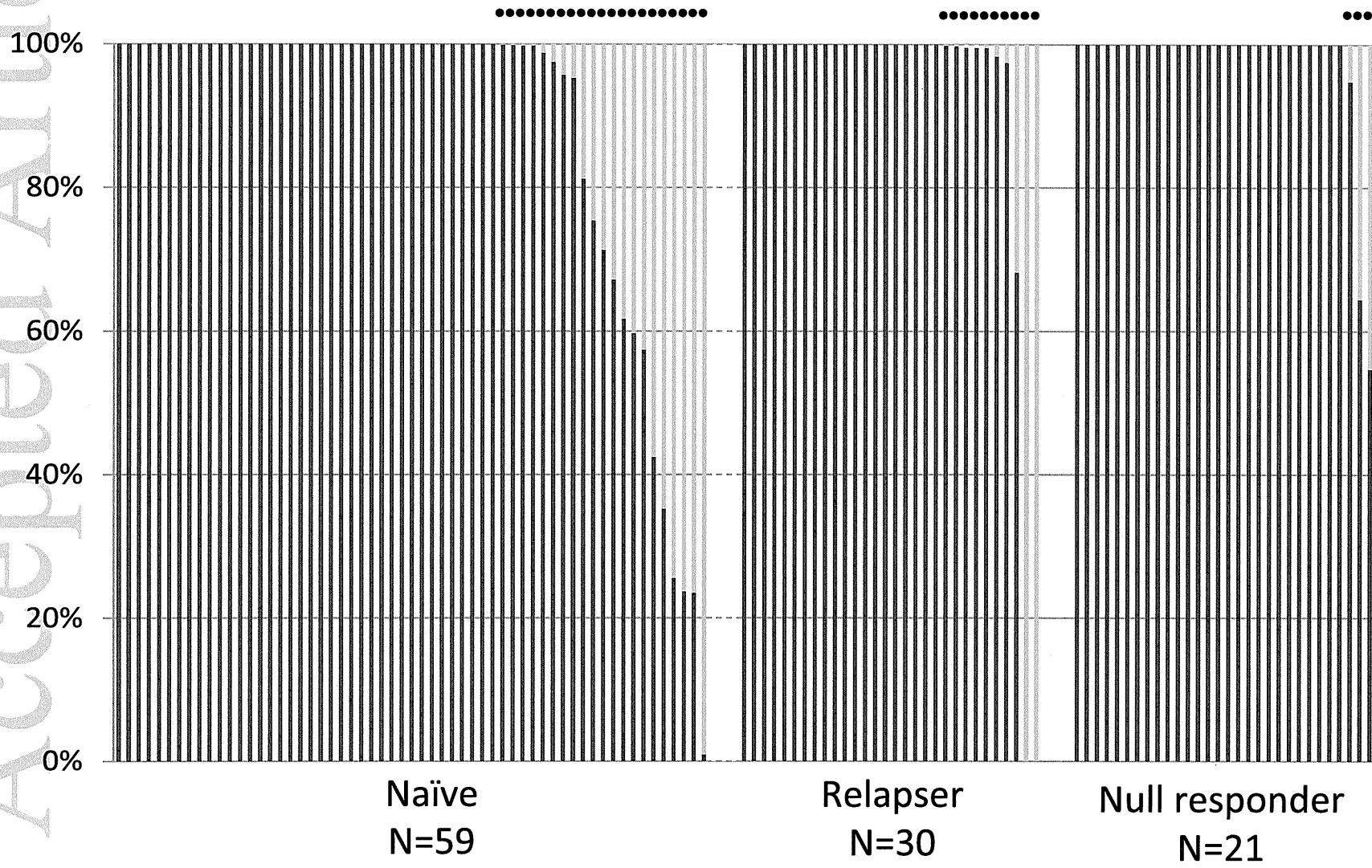


Figure 1B

NS5A aa 93  
■ Y ■ H



Accepted Article

Figure 2A

NS5A aa 31  
■ L ■ M/V/F

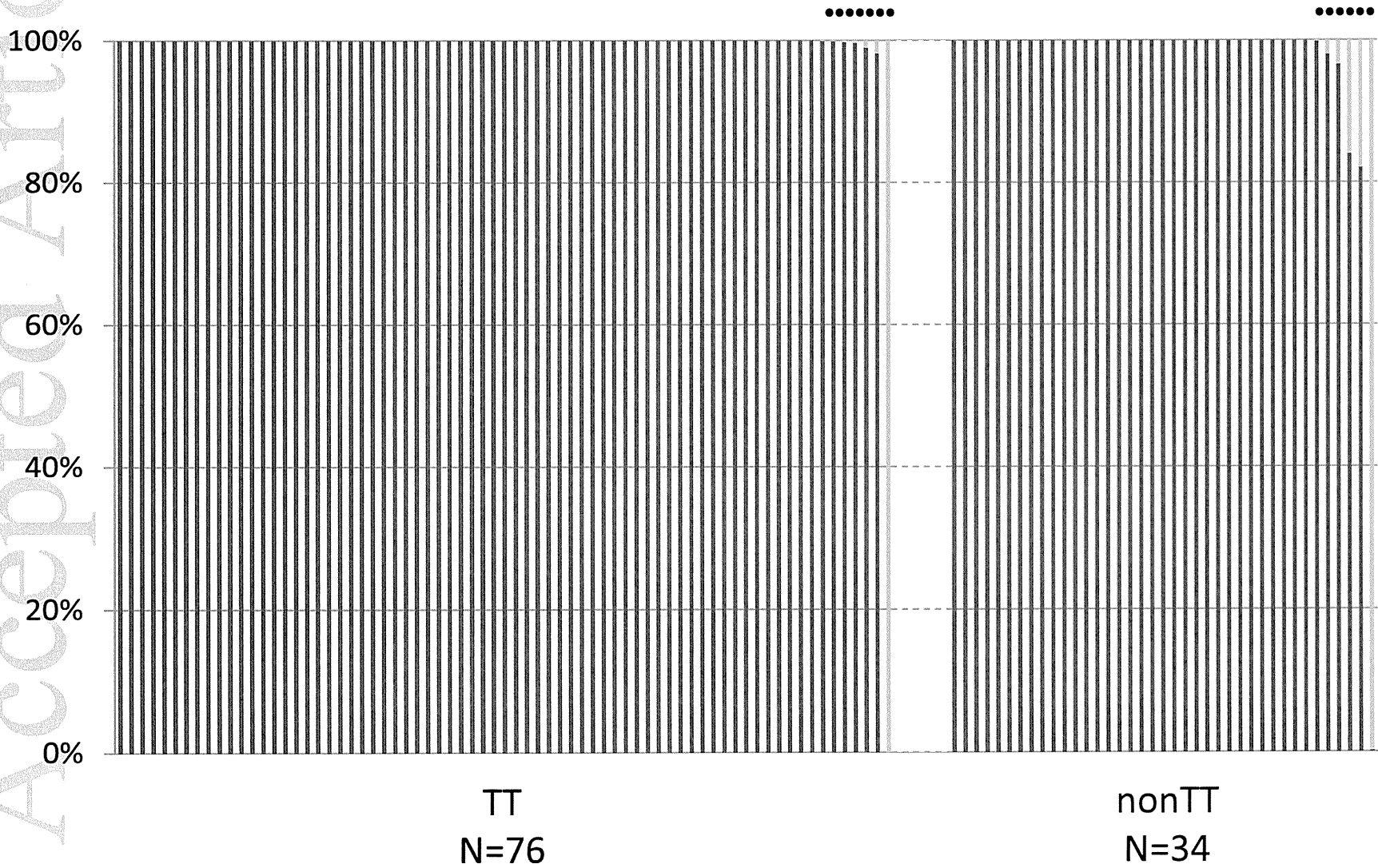
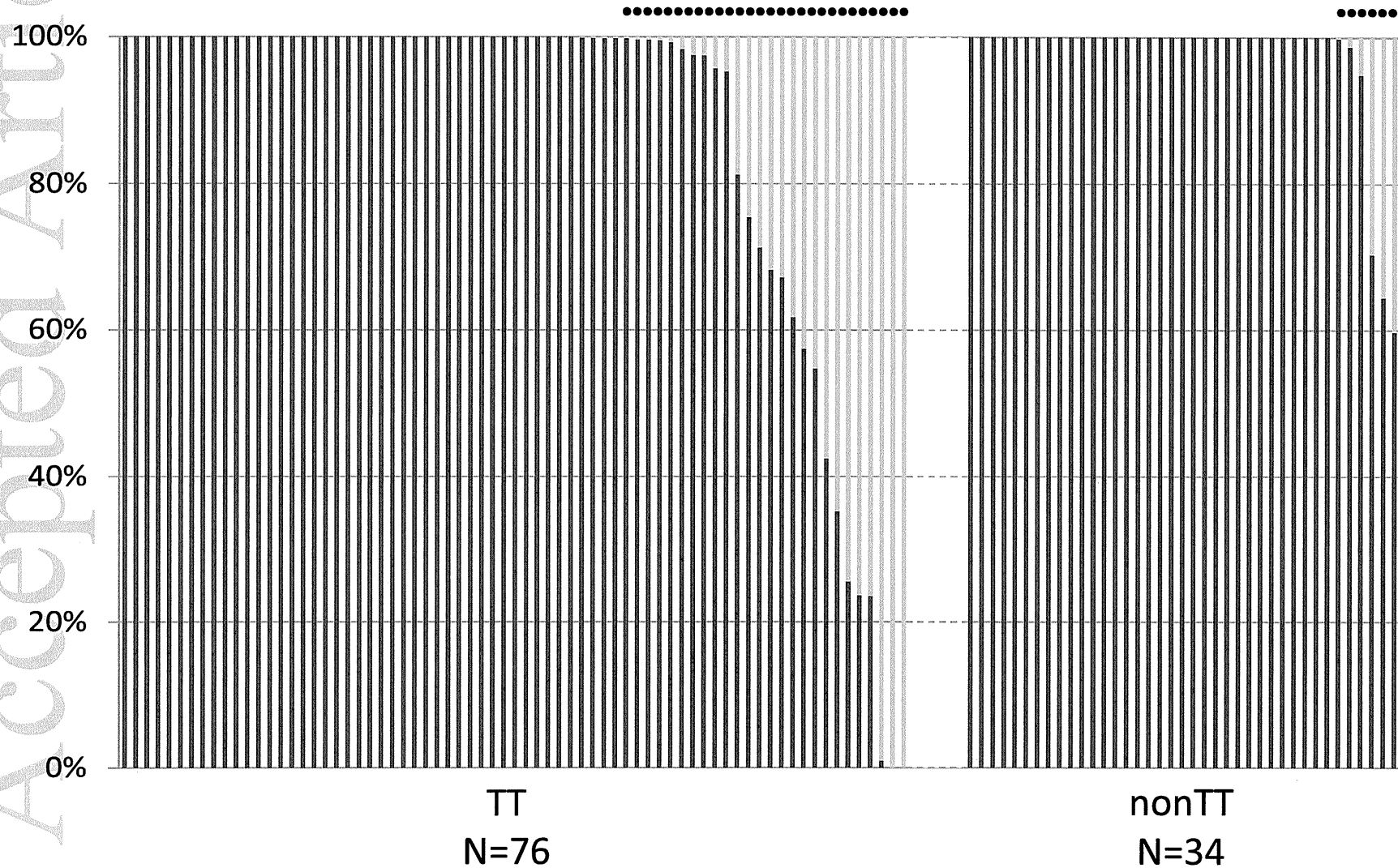


Figure 2B

NS5A aa 93  
■ Y ■ H

Accepted Article



1 **Hepatocellular carcinoma risk assessment using gadoxetic acid-enhanced**

2 **hepatocyte phase magnetic resonance imaging**

3

4 Nobutoshi Komatsu<sup>1)</sup>, Utaroh Motosugi<sup>2)</sup>, Shinya Maekawa<sup>1)</sup>, Kuniaki Shindo<sup>1)</sup>, Minoru

5 Sakamoto<sup>1)</sup>, Mitsuaki Sato<sup>1)</sup>, Akihisa Tatsumi<sup>1)</sup>, Mika Miura<sup>1)</sup>, Fumitake Amemiya<sup>1)</sup>,

6 Yasuhiro Nakayama<sup>1)</sup>, Taisuke Inoue<sup>1)</sup>, Mitsuharu Fukasawa<sup>1)</sup>, Tomoyoshi Uetake<sup>1)</sup>,

7 Masahiko Ohtaka<sup>1)</sup>, Tadashi Sato<sup>1)</sup>, Yasuhiro Asahina<sup>3)</sup>, Masayuki Kurosaki<sup>4)</sup>, Namiki

8 Izumi<sup>4)</sup>, Tomoaki Ichikawa<sup>2)</sup>, Tsutomu Araki<sup>2)</sup> and Nobuyuki Enomoto<sup>1)</sup>

9

10 1) First Department of Internal Medicine, University of Yamanashi

11 1110, Shimokato, Chuo-shi, Yamanashi, Japan 409-3898

12 2) Department of Radiology, University of Yamanashi

13 1110, Shimokato, Chuo-shi, Yamanashi, Japan 409-3898

14 3) Department of Gastroenterology and Hepatology, Tokyo Medical and Dental

15 University

16 1-5-45 Yushima, Bunkyo-ku, Tokyo, Japan 113-8510

17 4) Department of Gastroenterology and Hepatology, Musashino Red Cross Hospital,

18 1-26-1 Kyonan-cho, Musashino-shi, Tokyo, Japan 180-8610

19

20 **Short running title:** HCC risk assessment using EOB-enhanced MRI

21

---

This article has been accepted for publication and undergone full peer review but has not been through the copyediting, typesetting, pagination and proofreading process, which may lead to differences between this version and the Version of Record. Please cite this article as doi: 10.1111/hepr.12309

This article is protected by copyright. All rights reserved.

1 **Keywords:** hepatocellular carcinoma, magnetic resonance imaging, gadoxetic acid,  
2 hepatocyte phase, risk assessment

3

4

## FOOTNOTES

### 5 **Competing interests**

6 All authors have no conflict of interest related to this manuscript.

7

### 8 **Funding**

9 This study was supported in part by a grant-in-aid from the Ministry of Education,  
10 Science, Sports and Culture of Japan (23390195, 23791404, 24590964 and 24590965),  
11 and in part by a grant-in-aid from the Ministry of Health, Labour, and Welfare of Japan  
12 (H23-kanen-001, H23-kanen-004, H23-kanen-006, H24-kanen-002, H24-kanen-004 and  
13 H25-kanen-006).

14

### 15 **Correspondence:**

16 Nobuyuki Enomoto, M.D. / Ph.D.

17 First Department of Internal Medicine, University of Yamanashi,

18 1110, Shimokato, Chuo, Yamanashi, 409-3898, Japan.

19 Tel: +81-55-273-9584

20 Fax: +81-55-273-6748

21 E-mail: enomoto@yamanashi.ac.jp

22

1

2 **List of Abbreviations**

3 HCC: Hepatocellular Carcinoma

4 MRI: Magnetic Resonance Imaging

5 US: Ultrasonography

6 CT: Computed Tomography

7 HBV: Hepatitis B Virus

8 HCV: Hepatitis C Virus

9 AASLD: American Association for the Study of Liver Diseases

10 T1WIs: T1-Weighted Images

11 T2WIs: T2-Weighted Images

12 ALT: Alanine Aminotransferase

13  $\gamma$ -GTP:  $\gamma$  - Glutamyl Transpeptidase

14 AFP: Alpha-fetoprotein

15 HR: Hazard Ratio

16 CI: Confidence Interval

17 DWIs: Diffusion-Weighted Images

1

2

**ABSTRACT**

3 **Aim:** To investigate whether the patients with hypovascular liver nodules determined on  
4 the arterial phase and hypointensity on the hepatocyte phase gadoxetic acid-enhanced  
5 magnetic resonance imaging (hypovascular hypointense nodules) are at increased risk  
6 of hepatocarcinogenesis, we assessed subsequent typical hepatocellular carcinoma  
7 (HCC) development at any sites of the liver with and without such nodules.

8 **Methods:** One hundred and twenty-seven patients with chronic hepatitis B or C and  
9 without a history of HCC, including 68 with liver cirrhosis, were divided into those with  
10 (non-clean liver group, n = 18) and without (clean liver group, n =109) hypovascular  
11 hypointense nodules. All the patients were followed-up for 3 years, and HCC  
12 development rates and risk factors were analyzed with the Kaplan-Meier method and  
13 the Cox proportional hazard model, respectively.

14 **Results:** A total of 17 patients (10 in the non-clean liver group and 7 in the clean liver  
15 group) developed typical HCCs. Cumulative 3-year rates of HCC development were  
16 55.5% in the non-clean liver group and 6.4% in the clean liver group ( $p < 0.001$ ), and  
17 those at the different sites from the initial nodules was also higher in the non-clean liver  
18 group (22.2%) than the clean liver group (6.4%) ( $p = 0.003$ ). Multivariate analysis  
19 identified older age ( $p = 0.024$ ), low platelet counts ( $p = 0.017$ ) and a non-clean liver ( $p$   
20  $< 0.001$ ) as independent risk factors for subsequent HCC development.

21 **Conclusions:** Patients with hypovascular hypointense liver nodules are at a higher risk  
22 for HCC development at any sites of the liver than those without such nodules.

23

1  
2

## INTRODUCTION

3 Hepatocellular carcinoma (HCC) is one of the most common cancers worldwide  
4 and is a major cause of death in patients with chronic viral liver disease. Despite many  
5 advances in multidisciplinary treatment, complete curative treatment of early-stage  
6 HCC remains the only possible therapeutic choice for long-term survival. Therefore,  
7 surveillance programs for patients at a high-risk for HCC that include imaging-based  
8 evaluations are crucial for the detection and treatment of early-stage HCC.

9 The newly introduced magnetic resonance imaging (MRI) contrast agent,  
10 gadolinium ethoxybenzyl diethylenetriaminepentaacetic acid (gadoteric acid), has  
11 enabled concurrent assessment of tumor vascularity and unique hepatocyte-specific  
12 contrast (hepatocyte phase) (1-3). This has led to the frequent identification of  
13 hypovascular nodules determined on the arterial phase with hypointensity on the  
14 hepatocyte phase (hypovascular hypointense nodules) (4-8), while many of these  
15 nodules are difficult to be detected by ultrasonography (US) or computed tomography  
16 (CT). Recently, the natural history of hypovascular hypointense nodules themselves  
17 were reported in several studies (9-12), revealing the high risk of subsequent progress to  
18 typical HCCs from these nodules. However, it is not well known whether patients with  
19 such nodules has a higher risk of developing typical HCCs at any sites of the liver,  
20 including at the different sites from initial nodules, compared to those without such  
21 nodules.

22 If patients with these nodules may have a high risk of developing typical HCCs not  
23 only at the same sites but also at the different sites from initial nodules, significant  
24 proportion of these nodules are precancerous lesions or early-stage HCC as reported



1 (13-15), and more importantly, the liver with these nodules might reflect a higher  
2 potential for hepato-carcinogenesis or the presence of undetectable precursor lesions in  
3 other sites of the liver. Conversely, the absence of these nodules potentially identifies  
4 the patients at a low risk for subsequent typical HCC development at any sites. The  
5 purpose of this study was to assess the risk of subsequent typical HCC development at  
6 any sites of the liver with and without hypovascular hypointense nodules on gadoxetic  
7 acid-enhanced MRI.

8

1

2

## METHODS

### 3 *Ethical review*

4 The protocol of this retrospective study was approved by the ethics committee of  
5 Yamanashi University Hospital, which waived the requirement for written informed  
6 consent because the study was a retrospective data analysis, with appropriate  
7 consideration given to patient risk, privacy, welfare, and rights.

8

### 9 *Patients*

10 We recruited 559 consecutive outpatients with chronic hepatitis B virus (HBV) or  
11 hepatitis C virus (HCV) infection who underwent gadoxetic acid-enhanced MRI at  
12 Yamanashi University Hospital between January 2008 and December 2010. The  
13 exclusion criteria were as follows: 1) presence or history of typical HCC (n = 420),  
14 because intrahepatic metastasis does not always develop through the usual multistep  
15 hepatocarcinogenesis process, skipping the early pathological stage with  
16 hypovascularity to an advanced pathological stage even when the size is small (16, 17);  
17 2) Child-Pugh class C disease (n = 9), because the hepatocyte phase findings are not  
18 reliable in patients with this condition because of reduced gadoxetic acid uptake in the  
19 liver (18); and 3) patients who dropped out during the 3-year follow-up period (n = 3).  
20 After excluding 432 patients, 127 patients were included in this retrospective  
21 cohort study. They were divided into groups with hypovascular nodules determined on  
22 the arterial phase and hypointensity on the hepatocyte phase (non-clean liver group; n =  
23 18 patients) and without such nodules (clean liver group; n = 109 patients) as shown in  
24 Figure 1. In this study, we divided cases into two groups according to the presence or

1 absence of these nodules at the baseline, even when such nodules were initially detected  
2 during the follow-up period; we assigned these patients to the clean liver group.

3

#### 4 ***Follow-up and diagnosis of HCC***

5 All 127 patients were followed-up at the liver disease outpatient clinic of our  
6 institution with blood tests, including those for tumor markers, and diagnostic imaging  
7 modality (US, CT or MRI). The development of typical HCC that required treatment as  
8 proposed by the American Association for the Study of Liver Diseases (AASLD)  
9 guidelines (19) and that was diagnosed according to imaging criteria, showing arterial  
10 hypervascularity and venous phase washout, or based on histological examination of  
11 liver biopsies from hypovascular nodules that grew to >10 mm during follow-up.

12 Biopsies were obtained using a 21-gauge core needle. Two patients each had a liver  
13 nodule >10 mm in diameter on initial MRI (12mm and 13mm), was diagnosed on the  
14 basis of the biopsy as a dysplastic nodule.

15 The endpoint of this study was the development of typical HCC not only from the  
16 hypovascular hypointense nodules observed initially but also from other areas without  
17 these nodules (“*de novo* HCC”). Dynamic CT and/or MRI were also performed in cases  
18 with hepatic nodules detected by US, liver cirrhosis, a tendency of tumor marker  
19 elevation, and difficult evaluation of the liver parenchyma by US. All the 127 patients  
20 were followed-up for 3 years after the initial gadoxetic acid-enhanced MRI  
21 examination. When imaging modalities led to diagnosis of HCC, recognizing  
22 hypervascularization by more than one experienced radiologist and other imaging  
23 modalities was regarded as the time of diagnosis of HCC. When needle biopsy was  
24 performed to investigate nodules, the time of diagnosis of HCC was when the

1 pathologists and physicians examined pathological tissue and diagnosed as HCC.

2

### 3 ***MRI***

4 MRI was performed using a superconducting magnet that operated at 1.5 Tesla

5 (Sigma EXCITE HD; GE Medical Systems, Milwaukee, WI) and an 8-channel

6 phased-array coil. First, we obtained fast spoiled gradient-echo T1-weighted images

7 (T1WIs) with dual echo acquisition and respiratory-triggered fat-saturated fast

8 spin-echo T2-weighted images (T2WIs). Dynamic fat-suppressed gradient-echo T1WIs

9 were obtained using a three-dimensional (3D) acquisition sequence before (precontrast)

10 and 20-30 s, 60 s, 2 min, 5 min, 10 min, and 20 min after the administration of

11 gadoxetic acid (Primovist; Bayer Schering Pharma, Berlin, Germany). This contrast

12 agent (0.025 mmol/kg body weight) was administered intravenously as a bolus at a rate

13 of 1 mL/s through an intravenous cubital line (20–22 gauge) that was flushed with 20

14 mL saline from a power injector. The delay time for the arterial phase scan was adjusted

15 according to a fluoroscopic triggering method (20). All images were acquired in the

16 transverse plane. Sagittal plane T1WIs were also obtained during the hepatocyte phase

17 at 20 min after the injection of the contrast agent.

18

### 19 ***Statistical analysis***

20 All continuous values are expressed as median (range). Fischer's exact probability

21 test was used for comparisons between categorical variable and the non-parametric

22 Mann-Whitney test was used to compare differences between continuous variables.

23 Baseline clinical characteristics, including blood test results, were evaluated within 1

24 month of the initial MRI. We investigated whether or not HCC development was

1 associated with age, gender, fibrosis, etiology (HBV or HCV), platelet count, serum  
2 alanine aminotransferase (ALT),  $\gamma$ -glutamyl transpeptidase ( $\gamma$ -GTP), alpha-fetoprotein  
3 (AFP), and the presence or absence of hypovascular hypointense nodules.  
4 Cumulative HCC development was estimated according to the Kaplan-Meier  
5 method and differences in the curves were tested using the log-rank test. Risk factors for  
6 HCC development were determined according to the Cox proportional hazard model.  
7 Subgroup analyses with a Cox proportional hazard model were applied to estimation of  
8 the hazard ratio (HR) of the non-clean liver group versus clean liver group in the  
9 dichotomized subgroups. All statistical analyses were performed using JMP software,  
10 version 10 (SAS Institute Japan, Tokyo, Japan). A two-sided p value  $<0.05$  was  
11 considered statistically significant.

12

1  
2

## RESULTS

### 3 *Characteristics of the patients and nodules*

4 A total of 127 patients were enrolled, of whom 26 had chronic HBV infections and  
5 101 had HCV infections, and 68 had virus-associated cirrhosis. No statistically  
6 significant differences in the initial clinical characteristics were found between the  
7 non-clean liver and clean liver groups (Table 1). Thirty five hypovascular hypointense  
8 nodules were found in 18 patients in the non-clean liver group (1–5 nodules per patient)  
9 at baseline (data not shown). Twenty-four of these 35 nodules were detectable only on  
10 the hepatocyte phase MRI and were undetectable by US, CT and non-hepatocyte phase  
11 MRI. None of the 35 nodules showed high intensity on T2WIs. The median nodule  
12 diameter was 8 mm (range: 4–13 mm, 33 nodules with 10mm or less, 2 nodules with 12  
13 mm and 13 mm).

14

### 15 *HCC incidence according to initial MRI findings*

16 HCC was diagnosed in 17 patients, 10 in the non-clean liver group and 7 in the  
17 clean liver group; 14 of these patients had HCV infection. Thirteen patients were  
18 diagnosed according to the AASLD imaging criteria (19). Four patients were diagnosed  
19 pathologically by liver biopsies that were performed, based on enlargement of the  
20 nodules of >10 mm in diameter during the observation period.

21 The cumulative 1-, 2-, and 3-year HCC incidence rates were 1.5%, 10.2%, and  
22 13.4%. As determined by the Kaplan-Meier method, these rates were 11.1% (95%  
23 confidence interval [CI], 0.0-25.6%), 38.8% (95% CI, 16.3-61.4%), and 55.5% (95%  
24 CI, 32.6-78.5%) in the non-clean liver group and 0.0% (95% CI, 0.0-2.3%), 5.5% (95%

1 CI, 0.0-9.8%), and 6.4% (95% CI, 1.8-11.0%) in the clean liver group; the former group  
2 showed significantly higher rates of development of typical HCC than the latter ( $p$   
3  $<0.001$ ) as shown in Figure 2. The median imaging intervals were 3 months (3-6  
4 months) in the non-clean liver group and 4 months (2-12 months) in the clean liver  
5 group. The imaging interval of the non-clean liver group was shorter than clean liver  
6 group (3 vs. 4 months:  $p = 0.015$ ). The median intervals between the initial MRI and  
7 HCC diagnosis was 16 months (9-32 months) in the non-clean liver group and 21  
8 months (16-35 months) in the clean liver group.

9 In 11 of 17 patients with HCC development, HCCs developed at sites in which no  
10 nodules had been seen on the initial gadoxetic acid-enhanced MRI, *i.e.* "de novo HCC".  
11 These HCCs were found 4 in 18 patients in the non-clean liver group (3-year HCC  
12 incidence rates: 22.2%, 95% CI, 4.3-51.0%) and 7 in 109 patients in the clean liver  
13 group (3-year HCC incidence rates: 6.4%, 95% CI, 1.8-11.0%). The incidence rates of  
14 "de novo HCC" was significantly higher in the non-clean liver group than the clean liver  
15 group ( $p = 0.003$ , Figure 3). In the remaining 6 patients, HCCs developed at the same  
16 site of the initial nodules exclusively in 18 patients of a non-clean liver group by  
17 definition, and those HCCs arose among the nodules  $\geq 8$  mm in the initial MRI study.

18

### 19 ***Risk factors for HCC development***

20 Univariate analyses showed that the significant risk factors for HCC development  
21 included older age ( $p = 0.039$ ), cirrhosis ( $p = 0.009$ ), a low platelet count ( $p = 0.003$ ), a  
22 high AFP concentration ( $p = 0.006$ ), and a non-clean liver ( $p < 0.001$ ). Multivariate  
23 analysis with these variables revealed that older age (HR: 1.08; 95% CI, 1.01–1.16:  $p =$   
24 0.024), a low platelet count (HR 1.17; 95% CI, 1.03–1.35:  $p = 0.017$ ), and a non-clean

1 liver (HR 9.41; 95% CI, 3.47–25.46;  $p < 0.001$ ) were the only independent risk factors  
2 for HCC development (Table 2).

3 We further assessed the effect of a non-clean liver on the risk of HCC  
4 development in subgroups of these patients (Fig. 4). We found that belonging to the  
5 non-clean liver group was a significant risk factor in patients without HBV. Notably,  
6 this designation was particularly valuable for patients who are generally regarded as at  
7 low risk for HCC development: those without cirrhosis (HR 37.23; 95% CI,  
8 3.30–419.71;  $p = 0.003$ ) and those with high platelet counts (HR 33.42; 95% CI,  
9 6.69–166.94;  $p < 0.001$ ).

10



1

2

## DISCUSSION

3 This study revealed presence of hypovascular hypointense liver nodules ( non-clean  
4 liver) on gadoxetic acid-enhanced MRI, is a significant risk factor for subsequent  
5 development of typical HCC not only at the same sites but also at the different sites  
6 from the initial nodules. The incidence of development of typical HCC in the non-clean  
7 liver patients was >50% during a 3-year follow-up period, indicating these higher-risk  
8 patients should be rigorously investigated for the early detection of HCC during  
9 follow-up.

10 In the present study, 6 of the 18 patients in the non-clean liver group developed  
11 typical HCCs at the same site of the initial nodules during the subsequent 3 years  
12 (11.1%/year). Most of the hypovascular hypointense nodules on gadoxetic  
13 acid-enhanced MRI are considered precursor lesions of typical HCCs, such as early  
14 HCCs or high-grade dysplastic nodules, on histological examination (13-15), while it  
15 has been reported that most hypovascular nodules exhibiting high- to iso-intensity  
16 signals in the hepatocyte phase are benign hepatic nodules (14, 15). Recent studies have  
17 suggested that a reduction of OATP 1B3 (OATP 8) transporter expression begins at the  
18 earliest stage of hepatocarcinogenesis (21, 22), before changes in vascularity such as  
19 decreased portal flow or increased arterial flow. The progression rate of the small  
20 hypovascular hypointense nodules to typical HCC was reported as 10-17% / year (9,  
21 10), which is comparable to the present study. Typical HCCs arose exclusively among  
22 the nodules  $\geq 8$  mm, as in previous studies that the larger size of the hypovascular  
23 hypointense nodules is the risk factor for progression to typical HCCs in the initial MRI  
24 study (9, 10).

1 Hyperintensity on T2WIs (12) or diffusion-weighted images (DWIs) (11) also was  
2 reported to be useful for prediction of typical HCC progress in hypovascular  
3 hypointense nodules. In our patients, none of the nodules in the non-clean liver group  
4 showed hyperintensity on T2WIs, suggesting that the hepatocyte phase is more sensitive  
5 for detecting the early-stage of hepatocarcinogenesis (15). DWIs were not evaluated in  
6 this study because this usually detects pathologically advanced HCCs of larger size or  
7 with hypervascularity (23). Thus, it is reasonable that the hepatocyte phase can  
8 effectively recognize the earliest stage of HCC development without T2WIs or DWIs.

9 In 11 of 17 patients, typical HCCs developed at sites other than the initially  
10 detected hypovascular hypointense nodules. As shown in Figure 3, the incidence rates  
11 of such HCCs in the non-clean liver group was significantly higher than in the clean  
12 liver group ( $p = 0.003$ ), indicating a non-clean liver itself is a risk factor for HCC  
13 development, apart from the detectable hypovascular hypointense nodules. In addition,  
14 4 patients with nodules even below 8mm, 2 patients developed HCC at different sites  
15 from the initial nodules during follow up (data not shown). Taken together, a liver with  
16 non-clean liver has the higher potential for hepatocarcinogenesis or for undetectable  
17 precursor lesions. The non-clean liver might reflect more advanced genetic or epigenetic  
18 changes in the background hepatocytes, however, the detailed biological mechanism is  
19 not clear in this study.

20 Non-clean liver was an independent risk factor for the development of typical HCC,  
21 apart from well-documented risk factors (Table 2), such as cirrhosis (24), ALT (25),  
22  $\gamma$ -GTP (26), age and AFP (27). A non-clean liver is a significant risk for HCC  
23 development also for those without cirrhosis or with high platelet counts (Figure 4).  
24 This means patients at more increased risk of HCC development can be discerned as a

1 non-clean liver even among low-risk subgroups.

2 Conversely, patients without such nodules (clean liver group ) showed a  
3 significantly lower risk of developing typical HCC than those with non-clean livers  
4 (0.0% vs. 11.1% in 1-year, 6.8% vs. 55.5% at 3-years follow-up;  $p < 0.001$ ), suggesting  
5 that gadoteric acid-enhanced MRI could detect precursor lesions sensitively enough to  
6 rule out immediate (within 1 year) development of typical HCC. Although 7 patients in  
7 the clean liver group developed typical HCCs only after 1 year, these patients had other  
8 risk factors for HCC development, including lower platelet counts, implying more  
9 advanced liver cirrhosis, or high AFP (data not shown). Such HCCs might arise from  
10 precursor lesions that cannot be visualized by current imaging techniques.

11 This study is a retrospective study and has some limitations. We included patients  
12 with HBV and HCV together, because gadoteric acid-enhanced MRI findings or HCC  
13 development do not differ between these two groups and HBV or HCV infection is not  
14 an independent risk factor for typical HCC development. However, the number of HBV  
15 patients was too small ( $n = 26$ ) to statistically confirm the current result when limited to  
16 HBV patients only. Prospective studies with larger numbers of patients who have  
17 uniform liver disease etiologies and imaging intervals are needed to verify our findings  
18 in different settings. Although the imaging interval of the non-clean liver group was  
19 shorter than the clean liver group (3 vs. 4 months:  $p = 0.015$ ), the median intervals  
20 between the initial MRI and HCC diagnosis was 16 months in the non-clean liver group  
21 and 21 months in the clean liver group. They are short enough for cumulative detection  
22 of HCC development for three years and it is assumed that there was little influence on  
23 the conclusions.

24 In conclusion, patients with chronic viral liver disease are at high risk for

1 developing typical HCCs at any sites of the liver if they have hypovascular hypointense  
2 nodules on gadoxetic acid-enhanced MRI. These patients should be closely followed up  
3 for developing typical HCC not only at the same site but also at the different sites from  
4 the initial nodule.

5