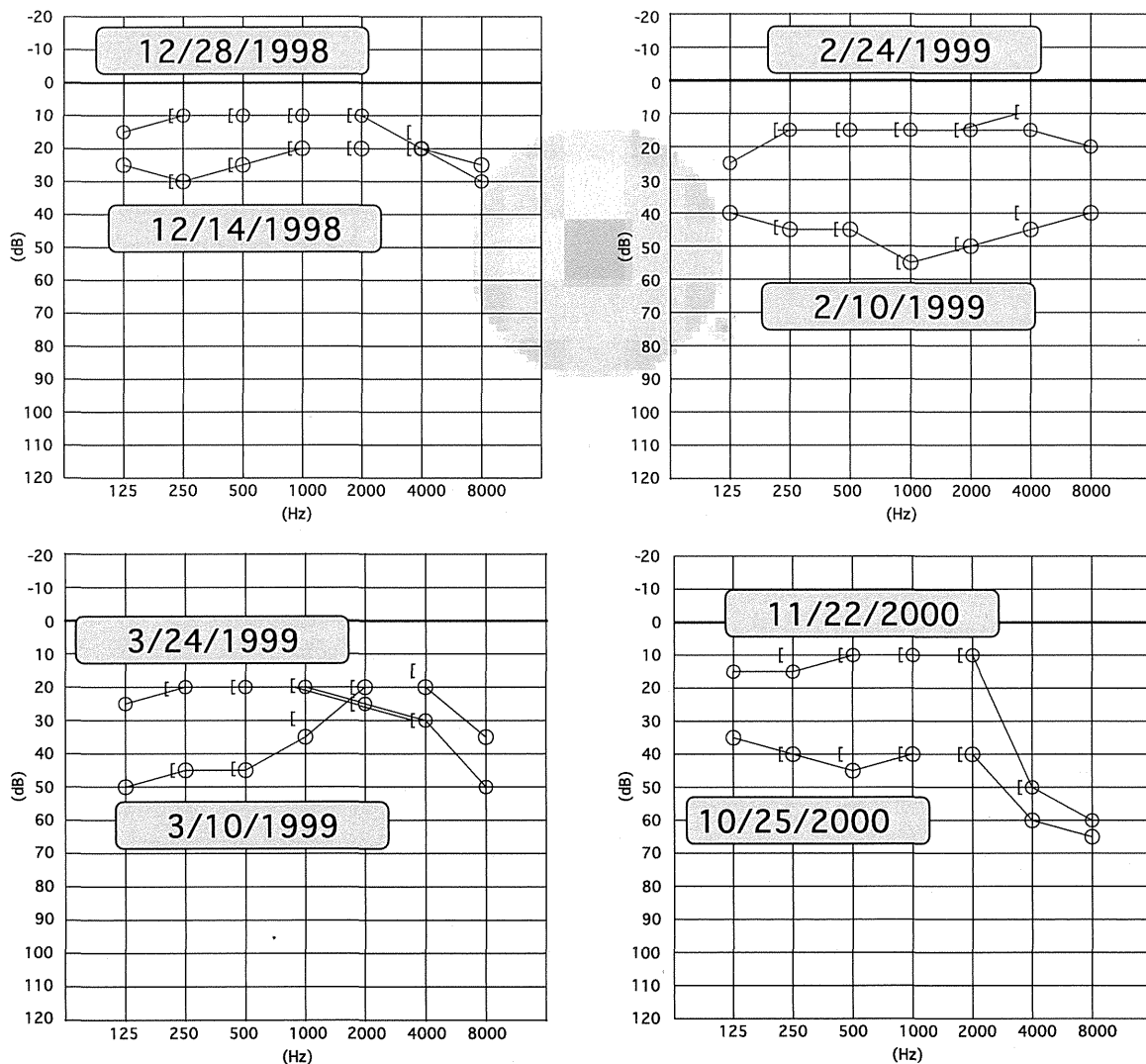


The symptoms however were recrudescence and he visited our outpatient clinic again in January 1999. He was prescribed ATP and vitamins, and his symptoms did not disappear. When he was prescribed prednisolone (10 mg/day), his symptoms were ameliorated for 1 week and his hearing improved to almost normal levels (Fig. 1b). Prednisolone dosage was therefore decreased gradually and discontinued on 24 February 1999. Two weeks later, however, he suffered a repeat of hearing loss and another attack of vertigo. The administration of prednisolone was restarted and the patient's hearing improved on 24 March 1999 (Fig. 1c). At this time, an AIED was suspected on the basis of his steroid-responsive symptoms and the presence of AS. Since this diagnosis, he has continued to take prednisolone up to the present time, the dosage being adjusted at different times depending on the

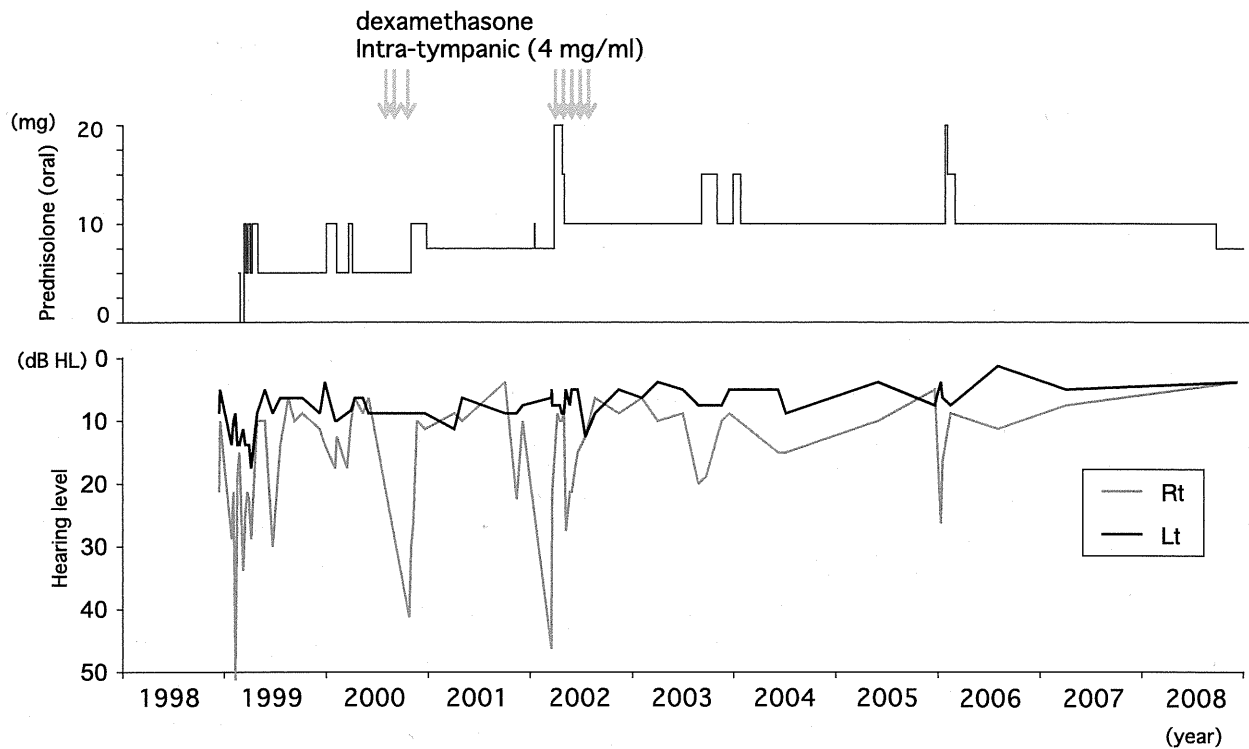
severity of his symptoms. The patient presented again with hearing loss in October 2000, and his prescribed dose of prednisolone was increased to 15 mg/day, but hearing level did not improve. Therefore, the intratympanic infusions of dexamethasone were performed, resulting in improved hearing for a period of 2 weeks (Fig. 1d). Since then, the dosage of prednisolone ranged from 5 to 15 mg/day, while the auditory function of the patient was monitored carefully. When the control of hearing was difficult only with the increasing dosage of prednisolone, the intratympanic administrations of dexamethasone were used in 2002. His symptoms have subsided with a continuing internal dosage of prednisolone (7.5 mg/day) up to the present time (August 2012) and the CRP level stays under 1.0 mg/dl (Fig. 2).

Figure 1



Pure tone audiogram of the right ear air conduction at the time of admission, 14 December 1998, and at discharge, 17 December 1998; at the maximum hearing deterioration, 10 February 1999, and at the recovery 2 weeks after steroid treatment commenced, 24 February 1999.

Figure 2



Pure tone audiogram of the right ear air conduction following cessation of steroid administration, 10 March 1999, and 2 weeks following the commencement of steroid treatment, 24 March 1999; before increased steroid dosage, 25 October 2000, and 4 weeks after increased steroid dosage, 22 November 2000.

Discussion

Patients with autoimmune SNHL often suffer from other autoimmune diseases [5]. There were few reports on patients with AS presenting autoimmune SNHL, although many cases of autoimmune SNHL were reported previously. Djupesland *et al.* [9] reported the cases of SNHL associated with AS. However, they could not confirm that the hearing loss was related to the mechanisms of autoimmunity. Only three patients with AS who were diagnosed as autoimmune SNHL were reported previously [10–12]. In these three patients, the fact that hearing improved after the treatment with steroids suggested that their hearing losses were concerned with immunological mechanism. In our case study presented here, the patient developed not only hearing loss, but also vertigo, and we diagnosed the patient as having AIED [4]. This present case is therefore the first report of AIED in AS. Previous reports showed that autoimmune SNHL often accompanied autoimmune diseases such as Cogan's syndrome and rheumatoid arthritis [5–7]. On the basis of our findings in this report, we propose that there should be careful monitoring of both hearing and vestibular functions when treating patients with other autoimmune diseases.

A few patients suffering from AS also suffer from conductive hearing loss, and the mobility of ear ossicles of these patients was assumed to be limited with the arthritis of the ear ossicles [13,14]. The reason why the arthritis of the ear ossicles appeared in some patients was unclear. In addition, it was reported that the middle ear involvement in patients with AS is very uncommon (<1% of ears in patient with AS) [15]. In our case, the hearing examinations of the patient have never shown conductive hearing loss, although he underwent the frequent hearing examinations.

AS is an autoimmune disease that affects the articulations and the ambient tissues near the trunk. Almost all patients present with consistent symptoms such as pain and stiffness of the sacroiliac joints at the back of the pelvis in their 30s, and these symptoms gradually become more severe. Nonsteroidal anti-inflammatory drugs were often administered as a first-line drug to patients with AS to reduce inflammation and relieve pain, whereas steroids were rarely used because weight gain, a common side effect of steroid use, may exacerbate the symptoms. In contrast, patients with an AIED should be treated immediately with a high dose of steroids, once a diagnosis of AIED is considered likely [4]. In three patients who were reported as autoimmune SNHL with AS, the maximum doses of

prednisolone were 50 and 60 mg/day, respectively [10,11]. When we treated the patient in this case study, we tried to prescribe a low dose of prednisolone (15 mg/day) so as not to promote weight gain. Although we had to increase the dose of prednisolone temporarily because of further deterioration in his hearing, we tried to ensure that the lowest dose possible was administered. Because his symptoms had not yet advanced, we believe that our choice of treatment was appropriate and successful in this case.

It is often difficult to reduce the maintenance dose of prednisolone. In the previous three cases of autoimmune SNHL in patients with AS, the physicians had trouble in reducing the dosage of prednisolone because of the relapse of symptoms [10–12]. Their final maintenance doses were 12.5 and 20 mg/day. In one of the cases, the hearing was impaired after a few deteriorations of symptoms [10]. Therefore, we cannot reduce the dosage furthermore while we monitor his auditory function.

Cytotoxic drugs [15–17] were used with prednisolone for autoimmune diseases. Some otolaryngologists reported the effect of azathioprine on the hearing function of the patients suffering from autoimmune SNHL [18,19]. In addition, azathioprine was often used as a steroid-sparing agent, and many cases of steroid-sparing effects were reported in autoimmune diseases [20,21]. Therefore, we should ponder whether we administer cytotoxic drugs in combination with steroids, when the maintenance dose of prednisolone is getting more.

Recently, intratympanic steroids have been used for the treatment of inner ear diseases. Intratympanic dexamethasone application results in significantly higher perilymph steroid concentrations than those achieved by means of a systemic route [22]. Dodson *et al.* [23] reported that the topical application of steroids could control the vertigo attack in patients suffering from Ménière's disease. Gouveris *et al.* [24] reported that intratympanic administration of steroids could be the therapeutic option for the treatment of patients with idiopathic sudden SNHL who do not respond to intravenous steroid and vasoactive therapy. In addition, the topical administration of steroids was used to protect the auditory function of the patients with AIEDs [25,26]. In our case, we should reduce the dose of systemic administration of prednisolone to prevent the weight gain of the patient. Therefore, the combination of the treatment, topical and systemic administration of steroids, was useful therapy.

Acknowledgements

Conflicts of interest

None declared.

References

- McCabe BF. Autoimmune sensorineural hearing loss. *Ann Otol Rhinol Laryngol* 1979; 88:585–589.
- Hughes GB, Kinney SE, Barna BP, Tomsak RL, Calabrese LH. Autoimmune reactivity in Cogan's syndrome: a preliminary report. *Otolaryngol Head Neck Surg* 1983; 91:24–32.
- O-Uchi T, Kanzaki J, Tsuchihashi N. Clinical analysis of steroid-responsive sensorineural hearing loss. *Auris Nasus Larynx* 1993; 20:79–93.
- Ryan AF, Keithley EM, Harris JP. Autoimmune inner ear disorders. *Curr Opin Neurol* 2001; 14:35–40.
- McCabe BF. Autoimmune inner ear disease: results of therapy. *Adv Otorhinolaryngol* 1991; 46:78–81.
- Kanzaki J, O-uchi T, Tsuchihashi N. Steroid-responsive sensorineural hearing loss: combination therapy with prednisolone and Sairei-to. *ORL J Otorhinolaryngol Relat Spec* 1993; 55:24–29.
- Kanzaki J. Immune-mediated sensorineural hearing loss. *Acta Otolaryngol Suppl* 1994; 514:70–72.
- Schlosstein L, Terasaki PI, Bluestone R, Pearson CM. High association of an HL-A antigen, W27, with ankylosing spondylitis. *N Engl J Med* 1973; 288:704–706.
- Djupesland G, Gronas HE, Saxegaard EF. Hearing and middle ear function in patients with inflammatory rheumatoid joint diseases. *Scand J Rheumatol* 1973; 2:53–56.
- Raza K, Karokis D, Wilson F, Delamere JP. Sensorineural hearing loss, iritis and ankylosing spondylitis. *Br J Rheumatol* 1998; 37:1363.
- Yeo SW, Park S-N. Immune-mediated sensorineural hearing loss in a patient with ankylosing spondylitis: a case report. *Otolaryngol Head Neck Surg* 2001; 125:113–114.
- Corapci I, Armagan O, Tascioglu F, Öner C. Sensorineural hearing loss in a patient with ankylosing spondylitis. *Rheumatol Int* 2004; 24:252–253.
- Magaro M, Ceresia G, Frustaci A. Arthritis of the middle ear in ankylosing spondylitis. *Ann Rheum Dis* 1984; 43:658–659.
- Pascual-Gomez E, Lopez-Rico JJ. Arthritis of the middle ear in ankylosing spondylitis. *Ann Rheum Dis* 1985; 44:141.
- De Miguel E, Tomás M, Benito S, Gavián J, Gijón J. Ankylosing spondylitis and middle ear impairment. *Ann Rheum Dis* 1987; 46:174.
- Sismanis A, Thompson T, Willis HE. Methotrexate therapy for autoimmune hearing loss: a preliminary report. *Laryngoscope* 1994; 104:932–934.
- Rahman MU, Poe DS, Choi HK. Autoimmune vestibulo-cochlear disorders. *Curr Opin Rheumatol* 2001; 13:184–189.
- Lasak JM, Sataloff RT, Hawkshaw M, Carey TE, Lyons KM, Spiegel JR. Autoimmune inner ear disease: steroid and cytotoxic drug therapy. *Ear Nose Throat J* 2001; 80:808–811+815.
- Saracaydin A, Katircioglu S, Katircioglu S, Karatay MC. Azathioprine in combination with steroids in the treatment of autoimmune inner-ear disease. *J Int Med Res* 1993; 21:192–196.
- Hahn BH, Kantor OS, Osterland CK. Azathioprine plus prednisone compared with prednisone alone in the treatment of systemic lupus erythematosus: report of a prospective controlled trial in 24 patients. *Ann Intern Med* 1975; 83:597–605.
- Sood A, Kaushal V, Midha V, Bhatia KL, Sood N, Malhotra V. The beneficial effect of azathioprine on maintenance of remission in severe ulcerative colitis. *J Gastroenterol* 2002; 37:270–274.
- Chandrasekhar SS, Rubinstein RY, Kwartler JA, Gatz M, Connelly PE, Huang E, Baredes S. Dexamethasone pharmacokinetics in the inner ear: Comparison of route of administration and use of facilitating agents. *Otolaryngol Head Neck Surg* 2000; 122:521–528.
- Dodson KM, Woodson E, Sismanis A. Intratympanic steroid perfusion for the treatment of Ménière's disease: a retrospective study. *Ear, Nose Throat J* 2004; 83:394–398.
- Gouveris H, Selivanova O, Mann W. Intratympanic dexamethasone with hyaluronic acid in the treatment of idiopathic sudden sensorineural hearing loss after failure of intravenous steroid and vasoactive therapy. *Eur Arch Otorhinolaryngol* 2005; 262:131–134.
- Parnes LS, Sun A-H, Freeman DJ. Corticosteroid pharmacokinetics in the inner ear fluids: An animal study followed by clinical application. *Laryngoscope* 1999; 109:1–17.
- Chandrasekhar SS. Intratympanic dexamethasone for sudden sensorineural hearing loss: Clinical and laboratory evaluation. *Otol Neurotol* 2001; 22:18–23.

