

primary tumor site during the treatment course may be necessary for metastatic RMS, as the patients who received local therapies showed significantly longer survival than those who did not. Although our findings suggest that patients with metastatic RMS should be treated at an early stage with local radiotherapy to improve OS, this aspect of our results requires more research; thus, the timing of local therapy should be individually determined depending on patient conditions.

Several studies have reported that age is associated with poor survival in patients with RMS. Sultan et al. reported on the prognosis of pediatric (age ≤ 19 years) and adult (age > 19 years) RMS patients, and their findings suggested that the 5-year survival rate was significantly poorer in adults compared to that in children (5-year OS, 27 and 61 %, respectively; $p < 0.0001$) (Sultan et al. 2009). Another study clarified that the outcomes of patients with intermediate-risk RMS varied depending on age (Meza et al. 2006). Oberlin et al. (2008) also reported on the prognosis of metastatic RMS, and their data suggested that the 3-year event-free survival rate was significantly poorer in RMS patients < 1 year and > 9 years of age compared to that in RMS patients aged 1–9 years ($p < 0.001$). In our study, age was a negative prognostic factor of PFS in RMS with localized disease, but outcomes for metastatic disease were not different between adults and children. Previous studies have mostly focused on age in children, but our study reported different prognoses for adults and children in both localized and metastatic disease. Therefore, our results would be expected to be different than those of Oberlin et al. (2008). The poor prognosis in adult metastatic RMS may depend on the tumor biology and drug delivery.

Histopathological classification of adult RMS is somewhat difficult to categorize conventional subtypes. Although our data include alveolar subtype most, pleomorphic and spindle subtypes in part may be included in the heterogeneous tumor and these subtypes are suggested poor prognosis (Mentzel, 2000 #3204). For the drug delivery, unpublished data in our institute suggest that the dose intensity of vincristine and cyclosporine is lower in adult when compared to children as hematological toxicities and neurotoxicity are severe. These data suggest that categorizing adult RMS and its treatment may be necessary to be developed independently to that of child RMS.

Radiation therapy and surgery are important for local tumor control and survival in the treatment of RMS. However, the optimal timing of radiation therapy is unclear. IRSG and COG protocols incorporate radiation therapy scheduled at weeks 9 or 12 after the induction of initial chemotherapy (Crist et al. 2001; Arndt et al. 2009). Minn et al. (2010) analyzed the risk of early

treatment failure in intermediate-risk RMS, and the majority of patients with early progression experienced local failure. Earlier radiation therapy may improve outcomes by the prevention of early local progression, and the current COG study (ARST0531, <http://www.clinicaltrials.gov>) plans to perform radiation therapy at week 4 for intermediate-risk RMS. Although there has been no randomized trial to compare the timing of local therapy in RMS, early initiation of local treatment would seem to be preferable. In our study, local therapy was effective in improving survival even in metastatic disease. We could find the efficacy of radiotherapy in metastatic patients but not for surgery probably because of the shortage of patients number included. However, except for local radiotherapy in patients with metastatic disease, the timing of local therapy had no significantly different effect on outcomes in patients who received local therapy during the induction phase versus the maintenance phase. The threshold we used for dichotomization (within 18 weeks or later than 18 weeks after initial treatment onset) may have been a factor in our inability to detect a significant difference in outcomes. This result implies that the timing of local therapy for metastatic disease, whether radiotherapy or surgery, may be varied depending on the individual patient's characteristics, that is, the radiotherapeutic field or the operability of the patient's local site.

Several limitations to our study should be mentioned. Our analysis was limited by its retrospective design and small sample size. Patients receiving VAC-like chemotherapy had undergone chemotherapy during the period prior to 2000, and the dose intensity of chemotherapy varied by protocol. The dose of irradiation and radiation methods also varied. Further, the patients who received local therapy might have been in better general condition or had a smaller primary tumor, which could be included in one radiation field, compared with those who did not. To reduce these biases, we compared the baseline characteristics of each group and demonstrated their similarity. However, adult RMS is a rare cancer; thus, our results should contribute to further advances in this field of oncology.

In conclusion, we showed that age was a negative prognostic factor for PFS and OS in RMS patients with localized disease, but age was not associated with survival in metastatic disease. For metastatic disease, local therapy may have a beneficial effect on survival, but the optimal timing of local therapy is unclear and should be determined individually. Future clinical trials for metastatic RMS should focus on the timing of local therapy, and evaluation of treatment strategies limited to adult RMS patients is warranted.

Conflict of interest None.

References

- Arndt CA, Stoner JA, Hawkins DS, Rodeberg DA, Hayes-Jordan AA, Paidas CN, Parham DM, Teot LA, Wharam MD, Breneman JC, Donaldson SS, Anderson JR, Meyer WH (2009) Vincristine, actinomycin, and cyclophosphamide compared with vincristine, actinomycin, and cyclophosphamide alternating with vincristine, topotecan, and cyclophosphamide for intermediate-risk rhabdomyosarcoma: children's oncology group study D9803. *J Clin Oncol* 27(31):5182–5188. doi:10.1200/JCO.2009.22.3768
- Breitfeld PP, Meyer WH (2005) Rhabdomyosarcoma: new windows of opportunity. *Oncologist* 10(7):518–527. doi:10.1634/theoncologist.10-7-518
- Breneman JC, Lyden E, Pappo AS, Link MP, Anderson JR, Parham DM, Qualman SJ, Wharam MD, Donaldson SS, Maurer HM, Meyer WH, Baker KS, Paidas CN, Crist WM (2003) Prognostic factors and clinical outcomes in children and adolescents with metastatic rhabdomyosarcoma—a report from the intergroup rhabdomyosarcoma study IV. *J Clin Oncol* 21(1):78–84
- Carli M, Colombatti R, Oberlin O, Bisogno G, Treuner J, Koscielniak E, Tridello G, Garaventa A, Pinkerton R, Stevens M (2004) European intergroup studies (MMT4-89 and MMT4-91) on childhood metastatic rhabdomyosarcoma: final results and analysis of prognostic factors. *J Clin Oncol* 22(23):4787–4794. doi:10.1200/JCO.2004.04.083
- Crist W, Gehan EA, Ragab AH, Dickman PS, Donaldson SS, Fryer C, Hammond D, Hays DM, Herrmann J, Heyn R et al (1995) The third intergroup rhabdomyosarcoma study. *J Clin Oncol* 13(3):610–630
- Crist WM, Anderson JR, Meza JL, Fryer C, Raney RB, Ruymann FB, Breneman J, Qualman SJ, Wiener E, Wharam M, Lobe T, Webber B, Maurer HM, Donaldson SS (2001) Intergroup rhabdomyosarcoma study-IV: results for patients with nonmetastatic disease. *J Clin Oncol* 19(12):3091–3102
- Eснаоla NF, Rubin BP, Baldini EH, Vasudevan N, Demetri GD, Fletcher CD, Singer S (2001) Response to chemotherapy and predictors of survival in adult rhabdomyosarcoma. *Ann Surg* 234(2):215–223
- Ferrari A, Dileo P, Casanova M, Bertulli R, Meazza C, Gandola L, Navarria P, Collini P, Gronchi A, Olmi P, Fossati-Bellani F, Casali PG (2003) Rhabdomyosarcoma in adults. A retrospective analysis of 171 patients treated at a single institution. *Cancer* 98(3):571–580. doi:10.1002/cncr.11550
- Hawkins WG, Hoos A, Antonescu CR, Urist MJ, Leung DH, Gold JS, Woodruff JM, Lewis JJ, Brennan MF (2001) Clinicopathologic analysis of patients with adult rhabdomyosarcoma. *Cancer* 91(4):794–803. doi:10.1002/1097-0142(20010215)91:4<794:AID-CNCR1066>3.0.CO;2-Q
- Klingebiel T, Boos J, Beske F, Hallmen E, Int-Veen C, Dantonello T, Treuner J, Gardner H, Marky I, Kazanowska B, Koscielniak E (2008) Treatment of children with metastatic soft tissue sarcoma with oral maintenance compared to high dose chemotherapy: report of the HD CWS-96 trial. *Pediatr Blood Cancer* 50(4):739–745. doi:10.1002/pbc.21494
- La Quaglia MP, Heller G, Ghavimi F, Casper ES, Vlamis V, Hajdu S, Brennan MF (1994) The effect of age at diagnosis on outcome in rhabdomyosarcoma. *Cancer* 73(1):109–117
- La TH, Wolden SL, Su Z, Linardic C, Randall RL, Hawkins DS, Donaldson SS (2011) Local therapy for rhabdomyosarcoma of the hands and feet: is amputation necessary? A report from the Children's Oncology Group. *Int J Radiat Oncol Biol Phys* 80(1):206–212. doi:10.1016/j.ijrobp.2010.01.053
- Lager JJ, Lyden ER, Anderson JR, Pappo AS, Meyer WH, Breitfeld PP (2006) Pooled analysis of phase II window studies in children with contemporary high-risk metastatic rhabdomyosarcoma: a report from the Soft Tissue Sarcoma Committee of the Children's Oncology Group. *J Clin Oncol* 24(21):3415–3422. doi:10.1200/JCO.2005.01.9497
- Leaphart C, Rodeberg D (2007) Pediatric surgical oncology: management of rhabdomyosarcoma. *Surg Oncol* 16(3):173–185. doi:10.1016/j.suronc.2007.07.003
- Little DJ, Ballo MT, Zagars GK, Pisters PW, Patel SR, El-Naggar AK, Garden AS, Benjamin RS (2002) Adult rhabdomyosarcoma: outcome following multimodality treatment. *Cancer* 95(2):377–388. doi:10.1002/cncr.10669
- Maurer HM, Beltangady M, Gehan EA, Crist W, Hammond D, Hays DM, Heyn R, Lawrence W, Newton W, Ortega J et al (1988) The intergroup rhabdomyosarcoma study-I. A final report. *Cancer* 61(2):209–220
- Maurer HM, Gehan EA, Beltangady M, Crist W, Dickman PS, Donaldson SS, Fryer C, Hammond D, Hays DM, Herrmann J et al (1993) The Intergroup Rhabdomyosarcoma Study-II. *Cancer* 71(5):1904–1922
- Meza JL, Anderson J, Pappo AS, Meyer WH (2006) Analysis of prognostic factors in patients with nonmetastatic rhabdomyosarcoma treated on intergroup rhabdomyosarcoma studies III and IV: the Children's Oncology Group. *J Clin Oncol* 24(24):3844–3851. doi:10.1200/JCO.2005.05.3801
- Michalski JM, Meza J, Breneman JC, Wolden SL, Laurie F, Jodoin M, Raney B, Wharam MD, Donaldson SS (2004) Influence of radiation therapy parameters on outcome in children treated with radiation therapy for localized parameningeal rhabdomyosarcoma in Intergroup Rhabdomyosarcoma Study Group trials II through IV. *Int J Radiat Oncol Biol Phys* 59(4):1027–1038. doi:10.1016/j.ijrobp.2004.02.064
- Minn AY, Lyden ER, Anderson JR, Million L, Arndt CA, Brown K, Hawkins DS, Donaldson SS (2010) Early treatment failure in intermediate-risk rhabdomyosarcoma: results from IRS-IV and D9803—a report from the Children's Oncology Group. *J Clin Oncol* 28(27):4228–4232. doi:10.1200/JCO.2010.29.0247
- Oberlin O, Rey A, Lyden E, Bisogno G, Stevens MC, Meyer WH, Carli M, Anderson JR (2008) Prognostic factors in metastatic rhabdomyosarcomas: results of a pooled analysis from United States and European cooperative groups. *J Clin Oncol* 26(14):2384–2389. doi:10.1200/JCO.2007.14.7207
- Pappo AS, Shapiro DN, Crist WM (1997) Rhabdomyosarcoma. Biology and treatment. *Pediatr Clin North Am* 44(4):953–972
- Pappo AS, Lyden E, Breitfeld P, Donaldson SS, Wiener E, Parham D, Crews KR, Houghton P, Meyer WH (2007) Two consecutive phase II window trials of irinotecan alone or in combination with vincristine for the treatment of metastatic rhabdomyosarcoma: the Children's Oncology Group. *J Clin Oncol* 25(4):362–369. doi:10.1200/JCO.2006.07.1720
- Raney RB, Maurer HM, Anderson JR, Andrassy RJ, Donaldson SS, Qualman SJ, Wharam MD, Wiener ES, Crist WM (2001) The Intergroup Rhabdomyosarcoma Study Group (IRSG): major lessons from the IRS-I through IRS-iv studies as background for the current IRS-V treatment protocols. *Sarcoma* 5(1):9–15. doi:10.1080/13577140120048890
- Raney RB, Meza J, Anderson JR, Fryer CJ, Donaldson SS, Breneman JC, Fitzgerald TJ, Gehan EA, Michalski JM, Ortega JA, Qualman SJ, Sandler E, Wharam MD, Wiener ES, Maurer HM, Crist WM (2002) Treatment of children and adolescents with localized parameningeal sarcoma: experience of the Intergroup Rhabdomyosarcoma Study Group protocols IRS-II

- through -IV, 1978–1997. *Med Pediatr Oncol* 38(1):22–32. doi:10.1002/mpo.1259
- Rodeberg DA, Anderson JR, Arndt CA, Ferrer FA, Raney RB, Jenney ME, Brecht IB, Koscielniak E, Carli M, Bisogno G, Oberlin O, Rey A, Ullrich F, Stevens MC, Meyer WH (2011) Comparison of outcomes based on treatment algorithms for rhabdomyosarcoma of the bladder/prostate: combined results from the Children's Oncology Group, German Cooperative Soft Tissue Sarcoma Study, Italian Cooperative Group, and International Society of Pediatric Oncology Malignant Mesenchymal Tumors Committee. *Int J Cancer* 128(5):1232–1239. doi:10.1002/ijc.25444
- Schuck A, Mattke AC, Schmidt B, Kunz DS, Harms D, Knietig R, Treuner J, Koscielniak E (2004) Group II rhabdomyosarcoma and rhabdomyosarcoma like tumors: is radiotherapy necessary? *J Clin Oncol* 22(1):143–149. doi:10.1200/JCO.2004.04.180
- Sultan I, Qaddoumi I, Yaser S, Rodriguez-Galindo C, Ferrari A (2009) Comparing adult and pediatric rhabdomyosarcoma in the surveillance, epidemiology and end results program, 1973 to 2005: an analysis of 2,600 patients. *J Clin Oncol* 27(20):3391–3397. doi:10.1200/JCO.2008.19.7483

Development of treatment strategies for advanced neuroblastoma

Junichi Hara

Received: 15 April 2012/Published online: 16 May 2012
© Japan Society of Clinical Oncology 2012

Abstract Neuroblastoma is the most common cancer in childhood. The majority of patients with neuroblastoma are assigned to the high-risk group based on age at diagnosis, stage, histology, MYCN status, and DNA ploidy. Their prognosis remains unsatisfactory; the 5-year event-free survival (EFS) rate is generally 40 %. During the past 20 years, much effort has been made to reinforce chemotherapy, including the introduction of high-dose chemotherapy with autologous stem cell rescue, resulting in a 5-year EFS rate of around 30 %. Subsequently, maintenance therapy aimed at eradicating residual tumors after induction and consolidation therapies was introduced, consisting of differentiation-inducing agents, retinoids, and immunotherapy using anti-GD2 antibodies combined with cytokines. However, such additional treatment provided benefit to only 10–20 % of patients, while the prognosis of about half the patients remains poor. Currently, novel targeted agents are under development. Among them, anaplastic lymphoma kinase (ALK) inhibitors and aurora kinase A inhibitors are promising. ALK somatic mutation or gene amplification predisposing neuroblastoma development occurs in up to 15 % of neuroblastomas. Crizotinib is a dual-specific inhibitor of ALK/Met and inhibits proliferation of neuroblastoma cells harboring R1275Q-mutated ALK or amplified wild-type ALK, but not cells harboring F1174L. Instead, cells with F1174L are sensitive

to another small molecule ALK inhibitor, TAE684. Aurora kinase A plays a pivotal role in centrosome maturation and spindle formation during mitosis. MLN8237 (alisertib) is a small molecule inhibitor of aurora kinase A that is currently in early-phase clinical testing. Future treatment will be individually planned, adapting targeted agents based on personal biological tumor characteristics.

Keywords Neuroblastoma · High-risk · Treatment · Review

Introduction

Neuroblastoma is the most common extracranial cancer in childhood and generally occurs in very young children, with a median age at diagnosis of 17 months [1]. The tumors arise in tissues of the sympathetic nervous system, the adrenal medulla, or paraspinal ganglia. Patients with neuroblastoma are stratified into very low-, low-, intermediate-, and high-risk groups based on age at diagnosis, stage, histology, MYCN status, and DNA ploidy [2]. Neuroblastomas have unique characteristics, with age at diagnosis being a powerful prognostic factor. Patients with hyperdiploidy and no MYCN amplification are assigned to the low-risk group, if younger than 18 months even if stage 4 disease, while in very low-risk patients, a subset of tumors shows spontaneous regression or complete remission with short-term chemotherapy [3, 4]. The prognosis of patients assigned to the high-risk group remains poor; the 5-year event-free survival (EFS) rate is around 40 %. The high-risk group is currently defined by MYCN amplification or age over 18 months. Neuroblastomas comprise several subsets of diseases currently characterized by surrogates. Molecular characterization for identifying underlying tumor

J. Hara (✉)
Department of Pediatric Hematology/Oncology,
Children's Medical Center, Osaka City General Hospital,
2-13-22 Miyakojimahondouri, Miyakojimaku,
Osaka 534-0021, Japan
e-mail: j-hara@hospital.city.osaka.jp

biology is in progress using modern molecular technologies. In this article, recent developments in the treatment of high-risk neuroblastoma are described.

Principles of therapy

Since high-risk neuroblastoma including localized disease is a systemic disease, the role of modalities for local treatment is limited and the significance of total resection or local radiation has not been proven. Chemotherapy plays a major role in the treatment of high-risk neuroblastoma. Historically, the probability of long-term survival for high-risk neuroblastoma patients was <15 %. The survival rate has increased in proportion to the intensity of chemotherapy [5]. The development of supportive therapy has made it possible to increase chemotherapy intensity. Treatment consists of induction, consolidation, and maintenance phases. Tumors are usually resected during or after the induction phase, and irradiation is delivered to the primary site and residual metastatic sites after completion of the induction phase. The role of induction and consolidation therapies is to reduce tumor burden as much as possible and rapidly, before tumor cells acquire drug resistance. In the 1970s, even vincristine plus cyclophosphamide showed a considerable effect at an early phase of treatment, but almost all tumors recurred after 3–4 months, indicating that neuroblastoma cells become resistant faster than other pediatric tumors. Therefore, it is important to accomplish treatment without delay according to a well-scheduled plan. The aim of maintenance therapy is to eradicate minimal residual disease after high-dose myeloablative chemotherapy. Since residual neuroblastoma cells are highly resistant to conventional chemotherapy, alternative strategies are desirable. In this context, tumor differentiation therapy and immunotherapy are currently under

development, using retinoids and anti-GD2 monoclonal antibodies combined with cytokines, respectively.

Induction chemotherapy

In the last 30 years, phase II clinical trials have established active agents against neuroblastoma, such as platinum analogs, anthracyclines, alkylating agents, and epipodophyllotoxins. More recently, the topoisomerase I inhibitors, topotecan and irinotecan, were shown to be effective. These agents demonstrated a 30–50 % response rate in newly diagnosed patients. Current first-line chemotherapy regimens generally consist of combinations of cisplatin, doxorubicin, vincristine, cyclophosphamide, and etoposide. Table 1 shows the induction chemotherapy regimens used by major cooperative groups. Regimens using drugs at higher doses achieved higher response rates; POG-8742 Regimen 1 containing higher doses of cisplatin and etoposide achieved better results than Regimen 2 [7]. The Japanese Cooperative Group uses higher doses of cisplatin and pirarubicin (THP-adriamycin) for induction therapy and reported a 92 % response rate [9]. Older studies may seemingly have shown better results but they lacked a sensitive method for assessment of tumor response at the time, ¹²³I-meta-iodobenzylguanidine (MIBG) scintigraphy. There is virtual consensus about the reinforcement of the dose intensity to raise response rates. To strengthen treatment intensity, one method is to shorten the treatment interval. Recently, the European Neuroblastoma Study Group (ENSG-5) compared the standard schedule (OPEC/OJEC) using a 21-day interval with a rapid COJEC schedule using a 10-day interval. The same total drug doses were administered in 11 and 21 weeks in the rapid and standard schedules, respectively [10]. There was no significant difference in overall survival (OS) between the rapid and standard regimens at 5 and 10 years, while there

Table 1 Induction therapies and their response rates

Study [reference]	Period	Dose per course (mg/m ²)				Course duration	No. of courses	Response rate (CR + PR) (%)
		Cisplatin	Doxorubicin	Etoposide	Cyclophosphamide			
CCG-321P2 [6]	1985–1989	60	30	100 × 2	900 × 2	Day 1–6	5–7	76
POG-8742 (1) [7]	1987–1991 A ^a	40 × 5		100 × 3		Day 1–5	3	77
	1987–1991 B ^a		35		150 × 7 (po)	Day 1–8	2	
POG-8742 (2) [7]	1987–1991	90	35	100	150 × 8	Day 1–11	5	68
CCG-3891 [8]	1991–1996	60	30	100 × 2	900 × 2	Day 1–6	5	78
Japanese Cooperative Group [9]	1985–1990	90	THP-ADM 40	VCR 1.5	1200	Day 1–5	6	92

CR complete response, po orally, PR partial response, THP-ADM pirarubicin (THP-adriamycin), VCR vincristine

^a Alternative administration

was a significant difference in the 5-year EFS rate (30.2 vs. 18.2 %; $P = 0.022$). Myeloablative consolidation therapy was given a median of 55 days earlier in patients assigned to rapid treatment than in those given standard treatment. Although this study showed that shortening of the chemotherapy interval might be a promising method, the significance of the results should be carefully considered as there was no difference in OS and, furthermore, the survival rates for both regimens were lower than current regimens. The Japanese Cooperative Group (the Japan Neuroblastoma Study Group) is currently conducting a phase II trial under the hypothesis that the interruption of chemotherapy with local therapy might contribute to acquisition of chemoresistance. In this study, local treatment including tumor resection and radiotherapy are postponed till the end of myeloablative consolidation therapy. However, it is certain that the strategy of strengthening chemointensity for the improvement of survival probability is approaching a limit and incorporation of new drugs is required. Topoisomerase I inhibitors are good candidates in this respect as their toxicity is limited and their myelotoxicity is less than for classic drugs [11–13]. The Children's Oncology Group has shown the efficacy of a combination of cyclophosphamide and topotecan in a phase I study and has followed this with an ongoing phase III study incorporating this combination in induction chemotherapy [14–17].

Myeloablative consolidation therapy

An increase in antineoplastic drug dosages has been considered as a means of overcoming tumor cell chemoresistance. Neuroblastoma is a unique tumor in that the advantage of myeloablative chemotherapy has been demonstrated in phase III studies (Table 2) [8, 18, 19]. In consolidation therapy, it is required to eradicate surviving tumor cells that have acquired chemoresistance after induction chemotherapy. The first confirmed evidence was obtained with the CCG-3891 randomized study, in that

myeloablative therapy including total body irradiation, carboplatin, etoposide, and melphalan (CEM) followed by purged autologous bone marrow stem cell rescue significantly improved 5-year EFS (myeloablative therapy $34 \pm 4\%$ vs. intensive chemotherapy $22 \pm 4\%$; $P = 0.034$) [8]. This observation was confirmed during longer follow-up (5-year EFS: $30 \pm 4\%$ vs. $19 \pm 3\%$, respectively; $P = 0.04$) [20]. The German Cooperative Group compared a non-total body irradiation myeloablative regimen including CEM with oral maintenance chemotherapy [18]. They demonstrated that patients allocated megatherapy had increased 3-year EFS compared with those allocated maintenance therapy [47 % (95 % confidence interval (CI) 38–55) vs. 31 % (95 % CI 23–39); hazard ratio (HR) 1.404 (95 % CI 1.048–1.881); $P = 0.0221$], but did not significantly increase 3-year OS [62 % (95 % CI 54–70) vs. 53 % (95 % CI 45–62); HR 1.329 (95 % CI 0.958–1.843); $P = 0.0875$]. More recently, the European Cooperative Group (SIOPEN) compared CEM and busulfan plus melphalan (BuMel) myeloablative regimens [19]. A significant difference in EFS in favor of BuMel (3-year EFS: 49 vs. 33 %, $P < 0.001$) was observed as well as in OS (3-year OS: 60 vs. 48 %, $P = 0.004$). Trials incorporating ^{131}I -MIBG as a component of myeloablative regimens have been performed and showed their feasibility [21].

Another approach to consolidation is the administration of two or three consecutive courses of myeloablative therapy with peripheral blood stem cell (PBSC) rescue. Extensive pilot studies have shown its feasibility and have suggested its efficacy [18, 22–24]. The Cooperative Oncology Group (COG) is currently comparing tandem myeloablative consolidation with a thiotepa and cyclophosphamide regimen followed by an attenuated CEM regimen to a single CEM regimen (COG-ANBL0532).

In autologous stem cell transplantation, contaminating tumor cells in autografts play a role in spreading disease after myeloablative therapy. Since the number of tumor cells in peripheral blood is small after several courses of induction chemotherapy and PBSC rescue provides rapid

Table 2 Phase III clinical trials of myeloablative consolidation therapy

Study [reference]	No. of patients	Regimen	EFS (%)	EFS observation period (years)	<i>P</i> value
CCG-3891 [8]	379	Myeloablative carboplatin/etoposide/melphalan + rescue vs. intensive chemotherapy	34 vs. 22	5	0.034
German Cooperative Group [18]	295	Myeloablative carboplatin/etoposide/melphalan + rescue vs. oral maintenance chemotherapy with cyclophosphamide	47 vs. 31	3	0.0221
European Cooperative Group (SIOPEN) [19]	598	Myeloablative carboplatin/etoposide/melphalan + rescue vs. myeloablative busulfan/melphalan + rescue	33 vs. 49	3	<0.001

EFS event-free survival

hematopoietic recovery, PBSC is preferential to bone marrow. The COG confirmed no benefit of immunomagnetic bead-based purging of pheresates on EFS or OS [25].

Maintenance therapy

Retinoid compounds

Retinoids are natural and synthetic derivatives of vitamin A that have been shown to induce terminal differentiation of neuroblastoma cells [26]. Among the retinoids, 13-*cis*-retinoic acid has been shown to have high bioavailability in a phase I study [27]. In the CCG-3891 phase II study, patients who achieved a complete or very good partial response after induction therapy were randomly assigned to 6-month treatment with 13-*cis*-retinoic acid or no further treatment following consolidation therapy [8]. This study showed a significant benefit of 13-*cis*-retinoic acid on outcome. Oral administration of 13-*cis*-retinoic acid following consolidation therapy has since become the standard for treating minimal residual disease in high-risk patients. Currently, clinical studies are focused on exploring more effective and less toxic retinoids with high bioavailability and a capacity for maximum tumor terminal differentiation. Fenretinide, a synthetic retinoid, is under development. In a phase II clinical trial of fenretinide in patients with recurrent or refractory diseases conducted by the COG, 14 of 59 evaluable patients (24 %) experienced response (1 partial response and 13 prolonged stable disease). Low bioavailability may have limited the activity of fenretinide [28]. Novel fenretinide formulations with improved bioavailability are currently being evaluated in pediatric phase I studies.

Anti-GD2

GD2 is a surface disialoganglioside that is almost uniformly expressed on the surface of neuroblastoma cells, making it an optimal target for an immunotherapeutic approach. Since GD2 expression in normal tissues is restricted to the central nervous system, peripheral sensory nerves, and skin melanocytes, monoclonal antibodies against GD2 have been expected to be suitable candidates for tumor-specific therapy [29]. Their function is not fully understood; antitumor effects can be either dependent or independent of the immune system. Immune-mediated mechanisms include antibody-dependent cellular cytotoxicity (ADCC) and complement-dependent cytotoxicity. Murine, chimeric, and humanized antibodies have been developed and their antitumor activities have been demonstrated in preclinical models and in phase I and II studies [30–37]. However, since their activity has been minimal,

development of anti-GD2 antibodies has been aimed at eliminating minimal residual disease. Murine anti-GD2 antibody, 3F8, showed modest activity in clearing residual neuroblastoma cells contaminating bone marrow [38]. A major adverse event is neuropathic pain, which is universal among all antibodies and dose limiting. The human–mouse chimeric antibody ch14.18 has been extensively tested in clinical trials. It is 50–100 times more efficient at mediating tumor ADCC in vitro than murine antibody 14G2a [39]. In German trials (NB90 and 97) for patients with newly diagnosed high-risk neuroblastoma, ch14.18 was administered to 166 patients every 2 months over a period of 1 year in the maintenance phase. A total of 99 patients received a 12-month course of maintenance chemotherapy and 65 had no further treatment. There was no significant difference in EFS or OS [40]. To strengthen immunocytotoxicity, coadministration of interleukin-2 (IL-2) and GM-CSF has been attempted. The COG evaluated the toxicities and efficacy of a combination of ch14.18, IL-2 alternating with granulocyte–macrophage colony stimulating factor (GM-CSF) in a phase I trial followed by a phase III randomized clinical trial [36, 41]. In the phase III trial of newly diagnosed patients with high-risk neuroblastoma, patients who achieved a complete or partial response to induction therapy were randomized after myeloablative consolidation therapy to receive maintenance therapy with *cis*-retinoic acid versus *cis*-retinoic acid plus ch14.18 in combination with IL-2 and GM-CSF. Randomization was stopped early because interim monitoring revealed significantly improved 2-year OS and EFS rates. Immunotherapy was superior to standard therapy with respect to 2-year EFS rate (66 ± 5 vs. 46 ± 5 %, $P = 0.01$) and 2-year OS rate (86 ± 4 vs. 75 ± 5 %, $P = 0.02$). Major toxicities were neuropathic pain, capillary leak syndrome, and hypersensitivity reaction [36]. To reduce systemic toxicities associated with the addition of cytokines, fusion antibodies in which the cytokine is linked to the Fc end of the monoclonal antibody are currently under development. Fusion antibodies provide high cytokine concentrations to the tumor microenvironment. The COG has conducted a phase I followed by a phase II trial of the humanized hu14.18 linked to IL-2 [34, 35]. In the phase II trial, while no objective response was observed in patients with disease measurable by standard radiographic criteria, in patients with disease evaluated only by MIBG scintigraphy and/or bone marrow histology, five patients (21.7 %) achieved a complete response.

New drug development

The Pediatric Preclinical Testing Program (PPTP) was established with National Cancer Institute support in the

US for new drug development. It is a comprehensive program to systematically evaluate new agents against molecularly characterized childhood solid tumor and leukemia models. The primary goal of the PPTP is to identify new agents that have the potential for significant activity when evaluated clinically against selected childhood cancers. The PPTP seeks to test these agents near the time that they are entering phase I evaluation in adults with cancer. So far, an NEDD8-activating enzyme inhibitor (MLN4942) [42], a CENP-E inhibitor (GSK923295A) [43], a polyamine analog (PG11047) [44], insulin-like growth factor-1 receptor inhibitors (BMS-754807, IMC-A12, SCH717454) [45–47], an aurora kinase A inhibitor (MLN8237) [48], a multikinase inhibitor (sunitinib) [49], an HSP90 inhibitor alvespimycin (17-DMAG, KOS-1022) [50], and a vascular endothelial growth factor inhibitor (AZD2171) have been tested [51]. Of them, the aurora kinase A inhibitor is the most encouraging. MLN8237 is a small molecule inhibitor of aurora kinase A that is currently in early-phase clinical testing. Aurora kinase A plays a pivotal role in centrosome maturation and spindle formation during mitosis [52]. A phase III trial of adult peripheral T-cell lymphoma has just started.

Sorafenib, a multikinase inhibitor, has demonstrated inhibition of neuroblastoma growth in a xenograft mouse model [53]. Sorafenib treatment also decreases neuroblastoma cell proliferation, attenuates ERK signaling, and enhances G1/G0 cell cycle arrest in vitro. Sorafenib inhibits phosphorylation of signal transducer and activator of transcription 3 (STAT3), which is associated with inhibition of phosphorylated Janus kinase 2 (JAK2), an upstream kinase that mediates STAT3 phosphorylation. Sorafenib also inhibits the phosphorylation of STAT3 induced by IL-6 and sphingosine-1-phosphate (S1P), a recently identified regulator for STAT3, in tumor cells. Moreover, sorafenib downregulates phosphorylation of MAP kinase (p44/42) in neuroblastoma cells, consistent with inhibition of their upstream regulators MEK1/2. Sorafenib inhibited expression of cyclin E, cyclin D1/D2/D3, key regulators for cell cycling, and the antiapoptotic proteins Mcl-1 and survivin [54].

Recently, polo-like kinase 1 (PLK1) was identified as a key player in oncogenesis in neuroblastoma-initiating cells [55]. Polo-like kinases are recognized as key regulators of mitosis, meiosis, and cytokinesis [56]. PLK1 is being studied as a target for cancer drugs. Many colon and lung cancers caused by K-RAS mutations are dependent on PLK1. When PLK1 expression is silenced with RNA interference in cell culture, K-RAS cells are selectively killed, without harming normal cells [57, 58]. Treatment with PLK1 inhibitors in clinical trials of adult malignancies has shown that BI2536 or BI6727 (volasertib) are cytotoxic to neuroblastoma-initiating cells. Furthermore, BI2536

significantly inhibited tumor growth in a xenograft model [55].

The discovery of anaplastic lymphoma kinase (ALK) as the major neuroblastoma predisposition gene was immediately extended to show that ALK somatic mutation or gene amplification occurs in up to 15 % of neuroblastomas [59, 60]. The ALK gene is located at 2p23, near the MYCN locus (2p24). ALK mutations frequently occurred within the kinase domain, in which three highly conserved amino acid positions were predominantly affected. The constitutive activation induced by mutations or amplification transmits signals through activation of a variety of signal transducers, including PLC γ , PI3K/AKT, STAT3 and RAS [61–64]. ALK mutations are distributed evenly across different clinical stages, although the most frequent somatic mutation, F1174L, is associated with MYCN amplification. The combination appears to confer a worse prognosis than MYCN amplification alone. ALK encodes an orphan receptor tyrosine kinase with an extracellular domain, belonging to the insulin family of proteins [65]. Expression of ALK is largely restricted to neural tissues [66–69] and is observed at high frequencies in primary neuroblastoma specimens [70]. Since several ALK inhibitors have been shown to be effective for non-small-cell lung cancers (NSCLCs) and ALK-deficient mice seem to show apparently normal development, these inhibitors are expected to play a substantial role in the treatment of neuroblastoma. Currently, the sole commercially available ALK inhibitor, crizotinib, is a dual-specific inhibitor of the ALK and Met tyrosine kinases. It shows substantial activity against NSCLCs and also inhibits proliferation of neuroblastoma cells expressing R1275Q-mutated ALK or amplified wild-type ALK. In contrast, cell lines harboring F1174L-mutated ALK were relatively resistant to crizotinib [71]. Another small molecule ALK inhibitor, TAE684, inhibited neuroblastoma cells harboring F1174L-mutated ALK [72]. Recently, an antagonistic ALK antibody has been reported, which inhibits cell growth and induces in vitro ADCC [73]. This strategy may overcome intrinsic insensitivity against small molecule inhibitors.

Conclusion

During the past 20 years, much effort has been directed towards the improvement of treatment results in advanced neuroblastoma. Most effort has been to reinforce chemotherapy, including the introduction of high-dose chemotherapy with autologous stem cell rescue. As a result, improvement of treatment results was achieved little by little. More recently, the introduction of maintenance therapy including administration of differentiation agents and immunotherapy has contributed to further improvement.

However, such treatment provided benefit only to 10–20 % of patients, while the prognosis of about half the patients remains poor. Thus, it is difficult to expect further improvement of treatment results using past treatment strategies. It is obvious that novel strategies are required to develop further improvement. Fortunately, a large number of novel targeted agents are under development. Comprehensive genome-wide characterization is now being increasingly used to extensively profile individual tumors. Future treatment would appear to be heading towards individualization of therapy by adapting targeted agents based on personal biological tumor characteristics.

Conflict of interest The author has no conflict of interest to declare.

References

- London WB, Castleberry RP, Matthay KK et al (2005) Evidence for age cutoff greater than 365 days for neuroblastoma risk group stratification in the Children's Oncology Group. *J Clin Oncol* 23:6459–6465
- Cohn SL, Pearson AD, London WB et al (2009) The International Neuroblastoma Risk Group (INRG) classification system: an INRG Task Force report. *J Clin Oncol* 27:289–297
- Yamamoto K, Harada R, Kikuchi A et al (1998) Spontaneous regression of localized neuroblastoma detected by mass screening. *J Clin Oncol* 16:1265–1269
- Carlsen NL (1990) How frequent is spontaneous remission of neuroblastomas? Implications for screening. *Br J Cancer* 61:441–446
- Cheung NV, Heller G (1991) Chemotherapy dose intensity correlates strongly with response, median survival, and median progression-free survival in metastatic neuroblastoma. *J Clin Oncol* 9:1050–1058
- Halperin EC, Cox EB (1986) Radiation therapy in the management of neuroblastoma: the Duke University Medical Center experience 1967–1984. *Int J Radiat Oncol Biol Phys* 12:1829–1837
- Russo C, Cohn SL, Petruzzi MJ et al (1997) Long-term neurologic outcome in children with opsoclonus–myoclonus associated with neuroblastoma: a report from the Pediatric Oncology Group. *Med Pediatr Oncol* 28:284–288
- Matthay KK, Villablanca JG, Seeger RC et al (1999) Treatment of high-risk neuroblastoma with intensive chemotherapy, radiotherapy, autologous bone marrow transplantation, and 13-*cis*-retinoic acid. Children's Cancer Group. *N Engl J Med* 341:1165–1173
- Sawaguchi S, Kaneko M, Uchino J et al (1990) Treatment of advanced neuroblastoma with emphasis on intensive induction chemotherapy. A report from the Study Group of Japan. *Cancer* 66:1879–1887
- Pearson AD, Pinkerton CR, Lewis IJ et al (2008) High-dose rapid and standard induction chemotherapy for patients aged over 1 year with stage 4 neuroblastoma: a randomised trial. *Lancet Oncol* 3:247–256
- Vassal G, Doz F, Frappaz D et al (2003) A phase I study of irinotecan as a 3-week schedule in children with refractory or recurrent solid tumors. *J Clin Oncol* 21:3844–3852
- Bomgaars LR, Bernstein M, Krailo M et al (2007) Phase II trial of irinotecan in children with refractory solid tumors: a Children's Oncology Group Study. *J Clin Oncol* 25:4622–4627
- Vassal G, Giammarile F, Brooks M et al (2008) A phase II study of irinotecan in children with relapsed or refractory neuroblastoma: a European cooperation of the Société Française d'Oncologie Pédiatrique (SFOP) and the United Kingdom Children Cancer Study Group (UKCCSG). *Eur J Cancer* 44:2453–2460
- Saylor RL 3rd, Stine KC, Sullivan J et al (2001) Cyclophosphamide plus topotecan in children with recurrent or refractory solid tumors: a Pediatric Oncology Group phase II study. *J Clin Oncol* 19:3463–3469
- Kretschmar CS, Kletzel M, Murray K et al (2004) Response to paclitaxel, topotecan, and topotecan-cyclophosphamide in children with untreated disseminated neuroblastoma treated in an upfront phase II investigational window: a pediatric oncology group study. *J Clin Oncol* 22:4119–4126
- Park JR, Scott JR, Stewart CF et al (2011) Pilot induction regimen incorporating pharmacokinetically guided topotecan for treatment of newly diagnosed high-risk neuroblastoma: a Children's Oncology Group study. *J Clin Oncol* 29:4351–4357
- London WB, Frantz CN, Campbell LA et al (2010) Phase II randomized comparison of topotecan plus cyclophosphamide versus topotecan alone in children with recurrent or refractory neuroblastoma: a Children's Oncology Group study. *J Clin Oncol* 28:3808–3815
- Berthold F, Boos J, Burdach S et al (2005) Myeloablative megatherapy with autologous stem-cell rescue versus oral maintenance chemotherapy as consolidation treatment in patients with high-risk neuroblastoma: a randomised controlled trial. *Lancet Oncol* 6:649–658
- Ladenstein RL, Poetschger U, Luksch R et al (2011) Busulfan-melphalan as a myeloablative therapy (MAT) for high-risk neuroblastoma: results from the HR-NBL1/SIOPEN trial. *J Clin Oncol* 29(Suppl; abstr 2)
- Matthay KK, Reynolds CP, Seeger RC et al (2009) Long-term results for children with high-risk neuroblastoma treated on a randomized trial of myeloablative therapy followed by 13-*cis*-retinoic acid: a Children's Oncology Group study. *J Clin Oncol* 27:1007–1013
- Matthay KK, Tan JC, Villablanca JG et al (2006) Phase I dose escalation of iodine-131-metaiodobenzylguanidine with myeloablative chemotherapy and autologous stem-cell transplantation in refractory neuroblastoma: a new approaches to Neuroblastoma Therapy Consortium Study. *J Clin Oncol* 24:500–506
- Monnereau-Laborde S, Munzer C, Valteau-Couanet D et al (2011) A dose-intensive approach (NB96) for induction therapy utilizing sequential high-dose chemotherapy and stem cell rescue in high-risk neuroblastoma in children over 1 year of age. *Pediatr Blood Cancer* 57:965–971
- Pradhan KR, Johnson CS, Vik TA et al (2006) A novel intensive induction therapy for high-risk neuroblastoma utilizing sequential peripheral blood stem cell collection and infusion as hematopoietic support. *Pediatr Blood Cancer* 46:793–802
- Qayed M, Chiang KY, Ricketts R et al (2012) Tandem stem cell rescue as consolidation therapy for high-risk neuroblastoma. *Pediatr Blood Cancer* 58:448–452
- Kreissman SG, Villablanca JG, Seeger RC et al (2008) A randomized phase III trial of myeloablative autologous peripheral blood stem cell (PBSC) transplant (ASCT) for high-risk neuroblastoma (HR-NB) employing immunomagnetic purged (P) versus unpurged (UP) PBSC: a Children's Oncology Group study. *J Clin Oncol* 26(Suppl; abstr 10011)
- Sidell N (1982) Retinoic acid-induced growth inhibition and morphologic differentiation of human neuroblastoma cells in vitro. *J Natl Cancer Inst* 68:589–596
- Reynolds CP, Matthay KK, Villablanca JG et al (2003) Retinoid therapy of high-risk neuroblastoma. *Cancer Lett* 197:185–192

28. Villablanca JG, London WB, Naranjo A et al (2011) Phase II study of oral capsular 4-hydroxyphenylretinamide (4-HPR/fenretinide) in pediatric patients with refractory or recurrent neuroblastoma: a report from the Children's Oncology Group. *Clin Cancer Res* 17:6858–6866
29. Modak S, Cheung NK (2007) Disialoganglioside directed immunotherapy of neuroblastoma. *Cancer Invest* 25:67–77
30. Frost JD, Hank JA, Reaman GH et al (1997) A phase I/II trial of murine monoclonal anti-GD2 antibody 14.G2a plus interleukin-2 in children with refractory neuroblastoma: a report of the Children's Cancer Group. *Cancer* 80:317–333
31. Yu AL, Uttenreuther-Fischer MM, Huang CS et al (1998) Phase I trial of a human-mouse chimeric anti-disialoganglioside monoclonal antibody ch14.18 in patients with refractory neuroblastoma and osteosarcoma. *J Clin Oncol* 16:2169–2180
32. Ozkaynak MF, Sondel PM, Krailo MD et al (2000) Phase I study of chimeric human/murine anti-ganglioside G(D2) monoclonal antibody (ch14.18) with granulocyte-macrophage colony-stimulating factor in children with neuroblastoma immediately after hematopoietic stem-cell transplantation: a Children's Cancer Group Study. *J Clin Oncol* 18:4077–4085
33. Kushner BH, Kramer K, Cheung NK (2001) Phase II trial of the anti-G(D2) monoclonal antibody 3F8 and granulocyte-macrophage colony-stimulating factor for neuroblastoma. *J Clin Oncol* 19:4189–4194
34. Osenga KL, Hank JA, Albertini MR et al (2006) A phase I clinical trial of the hu14.18-IL2 (EMD 273063) as a treatment for children with refractory or recurrent neuroblastoma and melanoma: a study of the Children's Oncology Group. *Clin Cancer Res* 12:1750–1759
35. Shusterman S, London WB, Gillies SD et al (2010) Antitumor activity of hu14.18-IL2 in patients with relapsed/refractory neuroblastoma: a Children's Oncology Group (COG) phase II study. *J Clin Oncol* 28:4969–4975
36. Yu AL, Gilman AL, Ozkaynak MF et al (2010) Anti-GD2 antibody with GM-CSF, interleukin-2, and isotretinoin for neuroblastoma. *N Engl J Med* 363:1324–1334
37. Kushner BH, Kramer K, Modak S et al (2011) Successful multifold dose escalation of anti-GD2 monoclonal antibody 3F8 in patients with neuroblastoma: a phase I study. *J Clin Oncol* 29:1168–1174
38. Cheung NK, Kushner BH, Yeh SD et al (1998) 3F8 monoclonal antibody treatment of patients with stage 4 neuroblastoma: a phase II study. *Int J Oncol* 12:1299–1306
39. Mueller BM, Romerdahl CA, Gillies SD et al (1990) Enhancement of antibody-dependent cytotoxicity with a chimeric anti-GD2 antibody. *J Immunol* 144:1382–1386
40. Simon T, Hero B, Faldum A et al (2004) Consolidation treatment with chimeric anti-GD2-antibody ch14.18 in children older than 1 year with metastatic neuroblastoma. *J Clin Oncol* 22:3549–3557
41. Gilman AL, Ozkaynak MF, Matthay KK et al (2009) Phase I study of ch14.18 with granulocyte-macrophage colony-stimulating factor and interleukin-2 in children with neuroblastoma after autologous bone marrow transplantation or stem-cell rescue: a report from the Children's Oncology Group. *J Clin Oncol* 27:85–91
42. Smith MA, Maris JM, Gorlick R et al (2011) Initial testing of the investigational NEDD8-activating enzyme inhibitor MLN4924 by the pediatric preclinical testing program. *Pediatr Blood Cancer*. doi:10.1002/pbc.23357
43. Lock RB, Carol H, Morton CL et al (2012) Initial testing of the CENP-E inhibitor GSK923295A by the pediatric preclinical testing program. *Pediatr Blood Cancer* 58:916–923
44. Smith MA, Maris JM, Lock R et al (2011) Initial testing (stage 1) of the polyamine analog PG11047 by the pediatric preclinical testing program. *Pediatr Blood Cancer* 57:268–274
45. Kolb EA, Gorlick R, Houghton PJ et al (2008) Initial testing (stage 1) of a monoclonal antibody (SCH 717454) against the IGF-1 receptor by the pediatric preclinical testing program. *Pediatr Blood Cancer* 50:1190–1197
46. Houghton PJ, Morton CL, Gorlick R et al (2010) Initial testing of a monoclonal antibody (IMC-A12) against IGF-1R by the Pediatric Preclinical Testing Program. *Pediatr Blood Cancer* 54:921–926
47. Kolb EA, Gorlick R, Lock R et al (2011) Initial testing (stage 1) of the IGF-1 receptor inhibitor BMS-754807 by the pediatric preclinical testing program. *Pediatr Blood Cancer* 56:595–603
48. Maris JM, Morton CL, Gorlick R et al (2010) Initial testing of the aurora kinase A inhibitor MLN8237 by the Pediatric Preclinical Testing Program (PPTP). *Pediatr Blood Cancer* 55:26–34
49. Maris JM, Courtright J, Houghton PJ et al (2008) Initial testing (stage 1) of sunitinib by the pediatric preclinical testing program. *Pediatr Blood Cancer* 51:42–48
50. Smith MA, Morton CL, Phelps DA et al (2008) Stage I testing and pharmacodynamic evaluation of the HSP90 inhibitor alvespimycin (17-DMAG, KOS-1022) by the pediatric preclinical testing program. *Pediatr Blood Cancer* 51:34–41
51. Maris JM, Courtright J, Houghton PJ et al (2008) Initial testing of the VEGFR inhibitor AZD2171 by the pediatric preclinical testing program. *Pediatr Blood Cancer* 50:581–587
52. Faisal A, Vaughan L, Bavetsias V et al (2011) The aurora kinase inhibitor CCT137690 downregulates MYCN and sensitizes MYCN-amplified neuroblastoma in vivo. *Mol Cancer Ther* 10:2115–2123
53. Kakodkar NC, Peddinti RR, Tian Y et al (2011) Sorafenib inhibits neuroblastoma cell proliferation and signaling, blocks angiogenesis, and impairs tumor growth. *Pediatr Blood Cancer*. doi:10.1002/pbc.240047
54. Yang F, Jove V, Buettner R et al (2012) Sorafenib inhibits endogenous and IL-6/S1P induced JAK2-STAT3 signaling in human neuroblastoma, associated with growth suppression and apoptosis. *Cancer Biol Ther* [Epub ahead of print]
55. Grinshtein N, Datti A, Fujitani M et al (2011) Small molecule kinase inhibitor screen identifies polo-like kinase 1 as a target for neuroblastoma tumor-initiating cells. *Cancer Res* 71:1385–1395
56. Barr FA, Silljé HH, Nigg EA (2004) Polo-like kinases and the orchestration of cell division. *Nat Rev Mol Cell Biol* 5:429–441
57. Downward J (2009) Finding the weakness in cancer. *N Engl J Med* 361:922–924
58. Luo J, Emanuele MJ, Li D et al (2009) A genome-wide RNAi screen identifies multiple synthetic lethal interactions with the Ras oncogene. *Cell* 137:835–848
59. Chen Y, Takita J, Choi YL et al (2008) Oncogenic mutations of ALK kinase in neuroblastoma. *Nature* 455:971–974
60. George RE, Sanda T, Hanna M et al (2008) Activating mutations in ALK provide a therapeutic target in neuroblastoma. *Nature* 455:975–978
61. Bai RY, Dieter P, Peschel C et al (1998) Nucleophosmin-anaplastic lymphoma kinase of large-cell anaplastic lymphoma is a constitutively active tyrosine kinase that utilizes phospholipase C-gamma to mediate its mitogenicity. *Mol Cell Biol* 18:6951–6961
62. Bai RY, Ouyang T, Miething C et al (2000) Nucleophosmin-anaplastic lymphoma kinase associated with anaplastic large-cell lymphoma activates the phosphatidylinositol 3-kinase/Akt anti-apoptotic signaling pathway. *Blood* 96:4319–4327
63. Slupianek A, Nieborowska-Skorska M, Hoser G et al (2001) Role of phosphatidylinositol 3-kinase-Akt pathway in nucleophosmin/anaplastic lymphoma kinase-mediated lymphomagenesis. *Cancer Res* 61:2194–2199
64. Amin HM, McDonnell TJ, Ma Y et al (2004) Selective inhibition of STAT3 induces apoptosis and G(1) cell cycle arrest in ALK-

- positive anaplastic large cell lymphoma. *Oncogene* 23:5426–5434
65. Duyster J, Bai RY, Morris SW (2001) Translocations involving anaplastic lymphoma kinase (ALK). *Oncogene* 20:5623–5637
66. Shiota M, Fujimoto J, Semba T et al (1994) Hyperphosphorylation of a novel 80 kDa protein-tyrosine kinase similar to Ltk in a human Ki-1 lymphoma cell line, AMS3. *Oncogene* 9:1567–1574
67. Iwahara T, Fujimoto J, Wen D et al (1997) Molecular characterization of ALK, a receptor tyrosine kinase expressed specifically in the nervous system. *Oncogene* 14:439–449
68. Morris SW, Naeve C, Mathew P et al (1997) ALK, the chromosome 2 gene locus altered by the t(2;5) in non-Hodgkin's lymphoma, encodes a novel neural receptor tyrosine kinase that is highly related to leukocyte tyrosine kinase (LTK). *Oncogene* 14:2175–2188
69. Pulford K, Lamant L, Morris SW et al (1997) Detection of anaplastic lymphoma kinase (ALK) and nucleolar protein nucleophosmin (NPM)-ALK proteins in normal and neoplastic cells with the monoclonal antibody ALK1. *Blood* 89:1394–1404
70. Lamant L, Pulford K, Bischof D et al (2000) Expression of the ALK tyrosine kinase gene in neuroblastoma. *Am J Pathol* 156:1711–1721
71. Bresler SC, Wood C, Haglund EA et al (2011) Differential inhibitor sensitivity of anaplastic lymphoma kinase variants found in neuroblastoma. *Sci Transl Med* 3:108ra114
72. Heuckmann JM, Hölzel M, Sos ML et al (2011) ALK mutations conferring differential resistance to structurally diverse ALK inhibitors. *Clin Cancer Res* 17:7394–7401
73. Carpenter EL, Haglund EA, Mace EM et al (2012) Antibody targeting of anaplastic lymphoma kinase induces cytotoxicity of human neuroblastoma. *Oncogene*. doi:10.1038/onc.2011.647

Implications of surgical intervention in the treatment of neuroblastomas: 20-year experience of a single institution

Tatsuro Tajiri · Ryota Souzaki · Yoshiaki Kinoshita ·
Yuhki Koga · Aiko Suminoe · Toshiro Hara ·
Tomoaki Taguchi

Received: 9 November 2010 / Accepted: 9 February 2011 / Published online: 19 January 2012
© Springer 2012

Abstract

Purpose The implications of surgical intervention for neuroblastomas were assessed in one institution.

Methods We analyzed the clinical characteristics and extension of resection in 123 pediatric patients with neuroblastoma diagnosed between 1985 and 2004.

Results The 5-year survival rate of the 82 patients under 12 months of age, 59 of whom were treated with complete resection of the primary tumor, was 97%. The 5-year survival rate of the 41 patients over 12 months of age did not differ significantly according to whether complete ($n = 19$) or incomplete resection ($n = 22$) was performed (46 vs. 38%, respectively). No local recurrence was observed in ten patients over 12 months of age with stage 4 disease who underwent complete resection of the primary tumor; however, four of these ten patients died of metastatic recurrence.

Conclusion Considering that the majority of infantile neuroblastomas in this study had favorable biology, complete resection might be unnecessary for patients under 12 years of age. For advanced neuroblastomas in patients over 12 months of age, the main treatment for metastasis is systemic chemotherapy, although extirpation of the primary tumor without extensive surgery might prevent local recurrence when combined with radiation therapy.

Keywords Neuroblastoma · Surgical intervention · Biology

Introduction

Neuroblastoma is the most common solid tumor in children, and its development is still uncharacterized [1]. The prognosis varies greatly, based on the clinical prognostic and biological prognostic factors [2]; thus, it is important to select the optimal therapy according to the properties of these tumors [3]. There are three types of surgical intervention for neuroblastoma: initial tumor extirpation, biopsy of the tumor at initial diagnosis; and radical surgery as a second-look operation after biopsy and induction chemotherapy. The role of surgical resection in the treatment of neuroblastomas is still controversial [4]. We conducted the present study to evaluate the implications of surgical intervention for neuroblastomas in patients under 12 months of age versus those over 12 months of age, based on an analysis of patients treated at one institution.

Patients and methods

A total of 123 patients had neuroblastoma diagnosed and treated at the Department of Pediatric Surgery, Kyushu University, between 1985 and 2004. This study was performed according to the Ethical Guidelines for Clinical Research published by the Ministry of Health, Labor, and Welfare of Japan on July 30, 2003. Consent for tumor preservation and biological analysis was obtained from the parents of each pediatric patient before surgery. Of the 123 patients, 82 were less than 12 months of age and 41 were 12 months of age or older. Of the 82 neuroblastomas in

T. Tajiri (✉) · R. Souzaki · Y. Kinoshita · T. Taguchi
Department of Pediatric Surgery, Graduate School of Medical Sciences, Kyushu University, 3-1-1 Maidashi, Higashi-ku, Fukuoka 812-8582, Japan
e-mail: taji@pedsurg.med.kyushu-u.ac.jp

Y. Koga · A. Suminoe · T. Hara
Department of Pediatrics, Graduate School of Medical Sciences, Kyushu University, 3-1-1 Maidashi, Higashi-ku, Fukuoka 812-8582, Japan

patients under 12 months of age, 73 were detected through mass screening at 6 months of age. In all cases, the status of MYCN amplification was determined by Southern blotting, quantitative polymerase chain reaction (PCR), and fluorescent in situ hybridization (FISH) [5]. According to the International Neuroblastoma Staging System (INSS) [6], there were 79 (64%) patients with stages 1, 2, and 4S; 16 (13%) with stage 3; and 28 (23%) with stage 4. Seventeen (14%) patients had MYCN amplification. The 5-year survival rate was 76%.

Survival curves for each category were constructed using the Kaplan–Meier method and then statistically evaluated by the log-rank test.

Results

Treatment and outcomes of the patients less than 12 months of age

In principle, since 1994, the protocol of the Japanese Infantile Neuroblastoma Study Group has been applied to patients under 12 months of age [7, 8]. This protocol consists of the following: An initial tumor extirpation is performed for localized resectable neuroblastomas; then, if no MYCN amplification is detected, postoperative chemotherapy is not administered. A biopsy is taken of an unresectable neuroblastoma, followed by mild chemotherapy if no MYCN amplification is detected in the tumor. Usually, no second-look operation is performed for residual tumors that decrease in size with chemotherapy after a biopsy, if the biology, including the MYCN gene status, is favorable. If MYCN amplification is detected in the tumor, intensive chemotherapy with a decrease in dose according to age is given, with or without tumor extirpation.

Of our 82 patients under 12 months of age, 70 (85%) had stage 1, 2, or 4S and 2 (2%) had MYCN amplification; the 5-year survival rate was 97% (Table 1). There were no significant differences in the survival rates between the 59 patients who underwent complete resection and the 23 who underwent incomplete resection (Fig. 1). Moreover, of the 59 patients who underwent complete resection, there were

no significant differences in the survival rates of the 38 who received chemotherapy and the 21 who did not. All 23 patients who underwent incomplete resection of the tumor received postoperative chemotherapy, and all these patients survived (Table 2).

Of the nine patients with neuroblastoma detected clinically, and not through mass screening, four had stage 4S, three had stage 1, and two had stage 4 disease. One patient with stage 4S disease had MYCN amplification. Seven of these nine patients underwent complete resection of the primary tumor. Six patients with stage 4 or 4S received mild chemotherapy after operation. Three patients with stage 1 received no postoperative chemotherapy after complete resection of primary tumor. The patient who had stage 4S disease with MYCN amplification died of the disease.

Surgical complications developed in five patients: postoperative bleeding in one, renal atrophy in three, and adhesive intestinal obstruction in one. One patient with partial resection of a stage 2 tumor suffered postoperative bleeding; two patients with complete resection of a stage 1 tumor and one patient with partial resection of a stage 3 tumor suffered renal atrophy; and one patient with complete resection of a stage 1 tumor suffered adhesive intestinal obstruction. All five patients with a surgical complication were alive without disease at the time of writing.

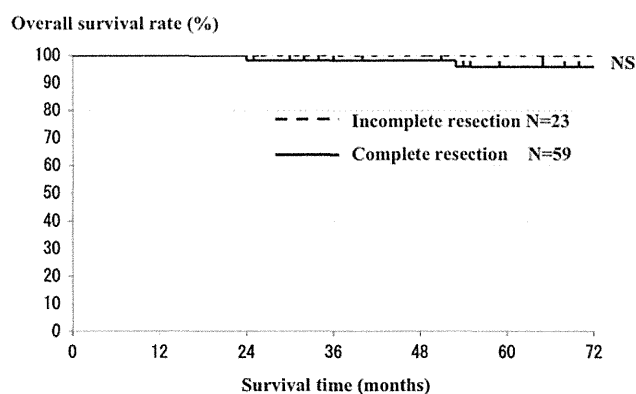


Fig. 1 Correlation between tumor resection and prognosis in 82 neuroblastoma patients less than 1 year of age. *NS* not significant

Table 1 Characteristics of 82 patients less than 12 months old with neuroblastoma

	No. of patients
Stages 1, 2, 4S	70 (85%)
Stages 3, 4	12
No MYCN amplification	80 (98%)
With MYCN amplification	2
5-year survival rate	97%

Table 2 Outcome of the 82 patients less than 12 months old with neuroblastoma based on chemotherapy and type of resection

Chemotherapy	Tumor resection	Survival
Received (<i>n</i> = 61)	CR (<i>n</i> = 38)	35 (92%)
	ICR (<i>n</i> = 23)	23 (100%)
Not received (<i>n</i> = 21)	CR (<i>n</i> = 21)	21 (100%)
	ICR (<i>n</i> = 0)	

CR complete resection, *ICR* incomplete resection

Treatment and outcomes of the patients aged 12 months or older with advanced neuroblastoma

In principle, since 1985, the protocol of the Japan Study Group for Advanced Neuroblastoma (JANB) has been applied to patients aged 12 months or older with advanced neuroblastomas [9, 10]. This protocol consists of the following: First, a biopsy is taken of the tumor, followed by intensive induction chemotherapy based on the MYCN gene status. A second-look operation is performed for residual tumors that decreased in size following the induction chemotherapy after biopsy. The second-look operation usually involves complete resection of the primary tumor, avoiding injury to the surrounding organs and major vessels. Enlarged lymph nodes are usually resected with sampling the surrounding lymph nodes, but systematic lymphadenectomy is not performed. If the second-look operation involves the complete resection of the tumor, then postoperative localized external-beam radiation (2–30 Gy) is given, followed by high-dose chemotherapy with stem cell transplantation. If the second-look operation involves incomplete resection of the tumor, postoperative localized external-beam radiation (20–30 Gy) is given, followed by consolidation chemotherapy.

Regarding the degree of resection of the primary tumor, macroscopic complete resection is defined as complete resection without systematic lymphadenectomy at the initial diagnosis or at the second-look operation after induction chemotherapy, and surgical intervention for the primary tumor, such as a biopsy only, partial resection, and subtotal resection, is defined as incomplete resection.

Of our 41 patients more than 1 year old with neuroblastomas, 32 (78%) had stage 3 and 4 disease and 15 (36%) showed MYCN amplification. The 5-year survival rate of these 41 patients was 42% (Table 3). The 86% 5-year survival rate of the 9 patients with stage 1 and 2 disease was significantly better than the 30% 5-year survival rate of the 32 patients with stage 3 and 4 disease ($P < 0.05$). Moreover, the 25% 5-year survival rate of the 15 patients with MYCN amplification was significantly worse than the 53% 5-year

Table 3 Clinical characteristics of the 41 patients aged 12 months or older with neuroblastoma

Clinical characteristics	No. of patients
Stage	
Stage 1, 2, and 4S	9
Stage 3 and 4	32 (78%)
MYCN amplification	
No amplification	26
Amplification	15 (36%)
5-year survival rate	42%

survival rate of the 26 patients without MYCN amplification ($P < 0.05$) (Fig. 2). Of 9 patients with early (stage 1 or 2) disease and no MYCN amplification, 5 with stage 1 underwent initial complete resection of the tumor, and 4 with stage 2 underwent initial incomplete resection of the tumor. All except 1 of the 8 patients with stage 1 disease underwent postoperative mild chemotherapy. One of these patients died of another disease.

There was no significant difference in 5-year survival rate between the 19 (46%) patients who underwent complete resection and the 22 (38%) who underwent incomplete resection (Fig. 3). Furthermore, the survival rate of the 32 patients with stage 3 and 4 disease did not differ significantly between the 11 patients who underwent complete resection and the 21 who underwent incomplete resection.

No local recurrence was observed in the ten patients over 1 year old with stage 4 disease who underwent complete resection of the primary tumor without systematic lymphadenectomy and local irradiation after 1994, although four of these patients died of metastatic recurrence (Table 4). Seven of these ten patients underwent stem cell transplantation (SCT); however, SCT was not associated with their outcome. No major surgical complications occurred.

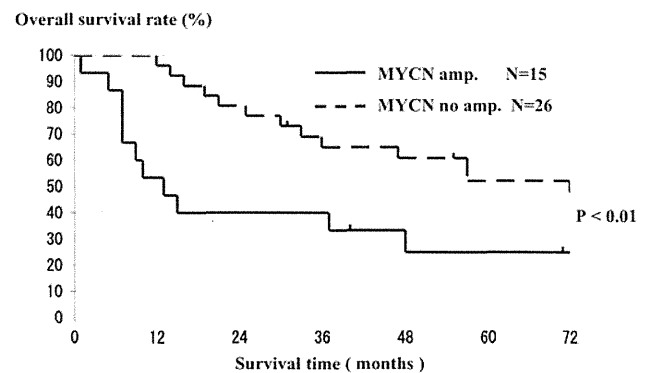


Fig. 2 Correlation between MYCN amplification (amp.) and prognosis in 41 neuroblastoma patients aged 12 months or older

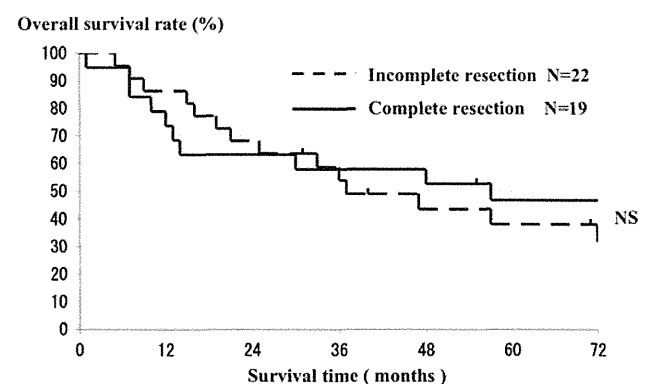


Fig. 3 Correlation between tumor resection and prognosis in 41 neuroblastoma patients aged 12 months or older

Table 4 Clinical course of the ten patients with stage 4 neuroblastoma who underwent complete resection of the primary tumor (1994–2004)

Patient no	Initial metastatic site	MYCN amplification	Local radiation	Local recurrence	Metastatic recurrence	Outcome
1	N, B, E, bm	no amp.	30 Gy	(–)	B	Died
2	N, B, E, bm	amp.	30 Gy	(–)	(–)	Alive 13 years after surgery
3	N, bm	amp.	30 Gy	(–)	(–)	Alive 10 years after surgery
4	N, bm	amp.	30 Gy	(–)	B, bm	Died
5	B	no amp.	30 Gy	(–)	B	Died
6	B, bm	amp.	30 Gy	(–)	N, B, bm	Died
7	B, bm, H	no amp.	30 Gy	(–)	(–)	Alive 6 years after surgery
8	B, bm, H	no amp.	18 Gy	(–)	(–)	Alive 6 years after surgery
9	N, bm	amp.	24 Gy	(–)	(–)	Alive 5 years after surgery
10	B, bm	amp.	18 Gy	(–)	(–)	Alive 5 years after surgery

N lymph node, B bone, E orbit, bm bone marrow, amp. amplification, no amp. no amplification

Discussion

The prognosis of patients with neuroblastoma tends to vary greatly, based on clinical prognostic factors, such as age and stage, and biological prognostic factors, such as MYCN amplification, DNA ploidy, and chromosome 1p deletion [11]. Thus, it is important to select the optimal therapy, including surgical intervention, according to the characteristics of these tumors [12]. This study is the experience of one institution between 1985 and 2004, during which time the treatment regimen for patients under 12 months of age with neuroblastomas and that for patients aged 12 months or over with advanced neuroblastomas did not change. Other investigators recently reported that 18 months of age is more preferable for risk assessment. In this study, the protocol of the Japanese Infantile Neuroblastoma Study Group was applied for patients less than 12 months of age with neuroblastomas, and the protocol of the Japan Study Group for Advanced Neuroblastoma (JANB) was applied for patients aged 12 months or older with advanced neuroblastomas. Therefore, investigating the borderline of age for risk group classification was not suitable for the analysis in the present study.

The majority of infant neuroblastomas are localized tumors with low-grade malignancy [13]. In particular, neuroblastomas detected by mass screening include spontaneously regressing tumors [14]. In the present series of 82 patients under 12 months of age, the outcome of infant neuroblastomas was excellent, regardless of whether they underwent complete or incomplete resection of the tumor. Furthermore, the outcome of patients who underwent complete resection of the tumor was excellent, regardless of whether they received postoperative chemotherapy. We could not compare patients who underwent initial extirpation with those who did not, because biopsies were performed for

all unresectable neuroblastomas, followed by mild chemotherapy. Although complete resection might be unnecessary for infantile neuroblastoma, the majority of which have favorable biology, performing initial tumor extirpation might avoid the need chemotherapy or irradiation.

In the present study, of nine patients whose disease was detected clinically and not through mass screening, only one patient who had stage 4S disease with MYCN amplification died of the disease. Irrespective of mass screening, most patients under 12 months of age had a good prognosis. It is clear that MYCN gene amplification was a powerful prognostic factor, even for infantile neuroblastoma [8].

In the present study, all five major surgical complications occurred in the patients with localized neuroblastoma (stages 1, 2, and 3). Recently, in an effort to establish a new risk-adapted preoperative neuroblastoma staging system, the International Neuroblastoma Risk Group (INRG) task force proposed the use of surgical risk factors (SRFs) to classify localized neuroblastomas [15]. SRFs were defined by objective and subjective radiologic imaging characteristics thought to be associated with an increased risk of surgical complications. These radiologic criteria are known as “image-defined risk factors” (IDRF) [16]. In a retrospective radiologic review of the five patients with surgical complication, all those who suffered postoperative renal atrophy had a positive IDRF. The Japan Neuroblastoma Study Group (JNBSG) proposed guidelines for surgical intervention for localized neuroblastoma based on the IDRF and began observational study of the treatment for low-risk neuroblastomas in 2010.

The role of surgery in the treatment of advanced neuroblastoma in patients 12 months or older remains controversial. La Quaglia et al. [17] reported that gross total resection improved the survival of 39 patients with stage IV neuroblastoma. Conversely, Adkins et al. [18] reported that complete resection was of little benefit for high-risk

neuroblastomas treated by CCG-3891. Kuroda et al. [19] found that intensive surgery with intraoperative radiation therapy dramatically increased local eradication and improved the outcome of patients even if they had advanced neuroblastomas with MYCN amplification. On the other hand, Castel et al. [20] found that delayed surgery after chemotherapy contributes to the good control of stage IV disease, although the final outcome of these patients was determined more by metastatic relapses than by the degree of resection. Kaneko et al. and Kubota et al. reported that systemic extensive surgery for advanced or metastatic neuroblastoma is no longer required if therapy supplemented with intensive pre- and postoperative chemotherapy is given [4, 21]. In the present study, the clinical stage and tumor biology of advanced neuroblastoma in patients aged 12 months or older was associated with the overall survival rate. The degree of tumor resection did not correlate significantly with the overall survival rate. In this study, the second-look operation was conservative tumor resection of the primary tumor, avoiding the injury to the surrounding organs and major vessels, and systematic lymphadenectomy was not performed. Therefore, we could not examine the complications of surgery and the delay in administering intensive chemotherapy resulting from major surgery. No major complications occurred after the second-look operation for the advanced neuroblastomas in patients aged more than 1 year old in this study, and we avoided a delay in intensive chemotherapy after the operation. Furthermore, complete resection of the primary tumor without systematic lymphadenectomy and localized external-beam radiation prevented local recurrence; however, the outcome of patients depended on metastatic recurrence. These results indicate that the main treatment for advanced neuroblastoma in patients aged 12 months or older is systemic chemotherapy, and that extirpation of the primary tumor without major surgery might prevent local recurrence, when combined with irradiation therapy.

In the JNBSG, two clinical phase II studies for high-risk neuroblastoma were begun in 2008 and completed in 2010. The guidelines for surgical intervention in these clinical studies recommend complete resection of the primary tumor without systematic lymphadenectomy, and localized irradiation. The long-term outcomes, including late complications, revealed by these clinical studies will be interesting.

Acknowledgments This work was supported in part by a grant-in-aid for scientific research from the Japanese Society for the Promotion of Science.

References

- Crist WM, Kun LE. Common solid tumors of childhood. *N Engl J Med*. 1991;324:461–71.
- Bodeur GM. Molecular basis for heterogeneity in human neuroblastoma. *Eur J Cancer*. 1995;31:505–10.
- Tajiri T, Shono K, Tanaka S, Suita S. Evaluation of genetic heterogeneity in neuroblastoma. *Surgery (St. Louis)*. 2002;131:283–7.
- Kubota M. The role of surgery in the treatment of neuroblastoma. *Surg Today*. 2010;40:526–32.
- Tanaka S, Tajiri T, Noguchi S, Ihara K, Hara T, Suita S. Clinical significance of a highly sensitive analysis for gene dosage and the expression level of MYCN in neuroblastoma. *J Pediatr Surg*. 2004;39:63–8.
- Brodeur GM, Pritchard J, Berthold F. Revision of the international criteria for neuroblastoma diagnosis, staging, and response to treatment. *J Clin Oncol*. 1993;11:1466–77.
- Matsumura T, Sawada T, Shikata T. New trend in treatment strategy for neuroblastoma infants in Japan. Proceedings of the 32nd Annual Meeting of American Society of Clinical Oncology. *J Clin Oncol*. 1996;15:461.
- Iehara T, Hosoi H, Akazawa K, Matsumoto Y, Suita S, et al. MYCN gene amplification is a powerful prognostic factor even in infantile neuroblastoma detected by mass screening. *Br J Cancer*. 2006;94:1510–5.
- Kaneko M, Tsuchida Y, Uchino J, Takeda T, Iwafuchi M, Ohnuma N, et al. Treatment results of advanced neuroblastoma with the First Japanese Study Group Protocol. *J Pediatr Hematol Oncol*. 1999;21:190–7.
- Kaneko M, Tsuchida Y, Mugishima H, Ohnuma N, Yamamoto K, Kawa K, et al. Intensified chemotherapy increases the survival rates in stage 4 neuroblastoma with MYCN amplification. *J Pediatr Hematol Oncol*. 2002;24:613–21.
- Brodeur GM, Maris JM, Yamashiro DJ. Biology and genetics of human neuroblastomas. *J Pediatr Hematol Oncol*. 1997;19:93–101.
- Suita S, Tajiri T, Kaneko M, Hirai M, Mugishima H, Sugimoto T, Tsuchida Y. Implications of MYCN amplification in patients with stage 4 neuroblastoma who undergo intensive chemotherapy. *J Pediatr Surg*. 2007;42:489–93.
- Suita S, Tajiri T, Higashi M, Tanaka S, Kinoshita Y, Takahashi Y, et al. Insights into infant neuroblastomas based on an analysis of neuroblastomas detected by mass screening at 6 months of age in Japan. *Eur J Pediatr Surg*. 2007;17:23–8.
- Yamamoto K, Hanada R, Tanimura M, Aihara T, Hayashi Y. Natural history of neuroblastoma found by mass screening. *Lancet*. 1997;349:1102.
- Cecchetto G, Mosseri V, De Bernardi B. Surgical risk factors in primary surgery for localized neuroblastoma: the LNESG1 study of the European International Society of Pediatric Oncology Neuroblastoma Group. *J Clin Oncol*. 2005;23:8483–9.
- Simon T, Hero B, Bohm GB, Schweinitz D, Berthold F. Review of image defined risk factors in localized neuroblastoma patients: results of the GPOH NB97 trial. *Pediatr Blood Cancer*. 2008;50:965–9.
- La Quaglia MP, Kushner BH, Heller G. Stage 4 neuroblastoma diagnosed at more than 1 year of age: gross total resection and clinical outcome. *J Pediatr Surg*. 1994;29:1162–6.
- Adkins ES, Sawin R, Gerbing RB, London WB, Matthay KK, Haase GM. Efficacy of complete resection for high risk neuroblastoma: a Children's Cancer Group study. *J Pediatr Surg*. 2004;39:931–6.
- Kuroda T, Saeki M, Honna T. Clinical significance of intensive surgery with intraoperative radiation for advanced neuroblastoma: does it really make sense? *J Pediatr Surg*. 2003;38:1735–8.
- Castel V, Tovar JA, Costa E. The role of surgery in stage IV neuroblastoma. *J Pediatr Surg*. 2002;37:1574–8.
- Kaneko M, Ohkawa H, Iwakawa M. Is extensive surgery required for treatment of advanced neuroblastoma? *J Pediatr Surg*. 1997;32:1616–9.

III. 臨床応用の進歩と展望 免疫療法(免疫細胞療法)

Glypican-3 などのがん特異的抗原を
標的とした免疫療法

澤田 雄 中面 哲也

The cancer specific antigen, glypican-3 (GPC3)-targeted immunotherapy

Yu Sawada, Tetsuya Nakatsura

Division of Cancer Immunotherapy, Research Center for Innovative Oncology,
National Cancer Center Hospital East

Abstract

The carcinoembryonic antigen glypican-3 (GPC3) is an ideal target of tumor antigen-specific immunotherapy against hepatocellular carcinoma (HCC), because it is overexpressed specifically in HCC. We have reported that a GPC3-derived peptide vaccination was well-tolerated, and immune responses and antitumor efficacy were noted in a phase I trial for HCC patients. We have begun a phase II study of the GPC3-derived peptide vaccine as an adjuvant therapy for HCC patients, and a pilot study of liver biopsies performed before and after GPC3 peptide vaccination for advanced HCC to determine whether tumor-infiltrating lymphocytes are indeed GPC3 peptide-specific CTLs. Furthermore, we are initiating clinical trials of a GPC3-derived peptide vaccine for patients with hepatoblastoma or ovarian clear cell carcinoma.

Key words: glypican-3 (GPC3), peptide vaccine, cytotoxic T lymphocyte (CTL)

はじめに

現在までに様々ながん拒絶抗原が同定され、これらの分解産物であるペプチドと HLA クラス I 分子を認識する CD8 陽性細胞傷害性 T 細胞 (cytotoxic T lymphocyte: CTL) が、がん細胞だけを攻撃するメカニズムを用いたがん抗原特異的免疫療法を目指すことが可能になった。同定されたがん拒絶抗原を用いた臨床試験が世界で行われており、最近では、前立腺がんに対して樹状細胞療法 sipuleucel-T (Provenge®) の第 III 相臨床試験での免疫療法の有効性も報告され、米国食品医薬品局 (Food and Drug Admin-

istration: FDA) に承認されている。日本国内でも様々な施設からがんに対するペプチドワクチンの有効性の報告が散見される。著者らは、新規がん胎児性抗原 glypican-3 (GPC3) を同定し、基礎研究の成果を基に国立がん研究センター東病院で GPC3 を標的とするペプチドワクチン療法を行っている。

本稿では、著者らの基礎から臨床応用への一連の研究、完了した肝細胞がんに対する GPC3 ペプチドワクチン第 I 相臨床試験の概略および現在行っている臨床試験について紹介する。

1. がん特異抗原 GPC3 の同定と前臨床試験

がん特異抗原の免疫療法への応用を考える場合、がん抗原の発現頻度、腫瘍特異性、免疫原性、消失性(免疫からの逃避が起こりにくい)および自己免疫などの有害事象の誘導の危険性などの特徴をとらえる必要がある。著者らは、東京大学医科学研究所(中村祐輔教授)との共同研究により、cDNA マイクロアレイのデータを基に、肝細胞がんの特異的な新規がん胎児性抗原として GPC3 を同定した¹⁻⁴⁾。がん胎児性抗原 GPC3 は、580 アミノ酸からなる 65 kDa の膜タンパク質であり、ヘパラン硫酸プロテオグリカンファミリーに属する。また GPC3 遺伝子およびタンパクが、肝細胞がんにおいて特異的に高発現し、正常組織においては胎生期の肝臓あるいは免疫学的に隔離された胎盤でのみ発現していることを確認した。発現の組織特異性が優れていることから、著者らは、この新規がん胎児性抗原 GPC3 が、理想的な腫瘍拒絶抗原になりうるかどうかを検討し、マウスや肝細胞がん患者の血液中リンパ球を用いて、日本人の約 60% が陽性である HLA-A24 拘束性 GPC3 由来ペプチド(EYILSLEEL)を同定した⁵⁾。同様に日本人の 40% が陽性で、欧米白人のメジャータイプである HLA-A2 拘束性 GPC3 由来ペプチド(FVGEFFTDV)を同定した⁶⁾。またマウスを用いた実験で GPC3 抗原の免疫によってペプチド特異的 CTL が誘導され⁷⁾、自己免疫現象の誘導なく抗腫瘍効果が認められることを示した。

このようにほとんどのがん患者において高発現しているようながん抗原に関して、HLA-A24 あるいは A2 拘束性のがん拒絶抗原を同定することにより、多くの患者を対象にペプチドワクチン、樹状細胞ワクチン、更には養子免疫療法などががん抗原特異的免疫療法が可能になると考えられる。また卵巣明細胞腺がん、肺扁平上皮がん、一部の小児がん(肝芽腫、腎芽腫、卵黄嚢腫)などにも発現があり、卵巣明細胞腺がん、小児がんについては、現在 GPC3 ペプチ

ドワクチン臨床試験を開始している。

2. 進行肝細胞がんに対する GPC3 ペプチドワクチン第 I 相臨床試験の概要⁸⁻¹⁴⁾

進行肝細胞がん 33 例を対象に GPC3 ペプチドワクチン第 I 相臨床試験を 2007 年 2 月に開始し 2009 年 11 月に完了した。主要評価項目は、安全性、副次評価項目として、無増悪期間(TTP)、全生存期間(OS)などの臨床効果のほか、免疫学的反応を設定した。1 回の投与量を 0.3, 1, 3, 10, 30 mg の 5 段階とし、2 週間おきに 3 回左右の腋窩部、腹部および鼠径部の皮内に不完全フロイントアジュバント(incomplete Freund's adjuvant: IFA)と混ぜたエマルジョン製剤を、安全性を確認しながら用量を増して投与した。

この試験で認められた有害事象として、投与局所の発赤・硬結は、ほぼ全例の患者にみられ、grade 2 相当の一過性の発熱、異所性の皮疹が 6 人にみられるのみであった。grade 3 の有害事象として、肝機能障害が 4 人の患者で観察されたが、効果安全性評価委員会により、いずれもがんの進行によるものと判断された。これらの結果より、GPC3 ペプチドワクチン療法は安全性に問題ないと判断された。

臨床効果については、全 33 症例の無増悪期間中央値は 3.4 カ月、全生存期間中央値は 9.0 カ月であった。3 回のワクチン投与後 1 カ月後の CT の RECIST version 1.0 での評価では、全 33 例中、1 例部分奏効(PR)と判定され(図 1-a)、19 例で不変(SD)と判定された。2 カ月間の病勢コントロール率(PR+SD)は 60.6%であった。SD と判定された患者のうち 4 人で、PR の基準を満たしていないが腫瘍の壊死または腫瘍の部分的な縮小が観察された。腫瘍マーカーである AFP、PIVKA-II は、33 例中 9 例(27%)で投与前と比べて少なくとも一度の低下が観察された。

また免疫学的反応の解析のため、全 33 症例でワクチン投与前後での末梢血単核球細胞中の GPC3 ペプチド特異的 CTL の検出に、*ex vivo* IFN- γ enzyme-linked immunospot (ELISPOT)

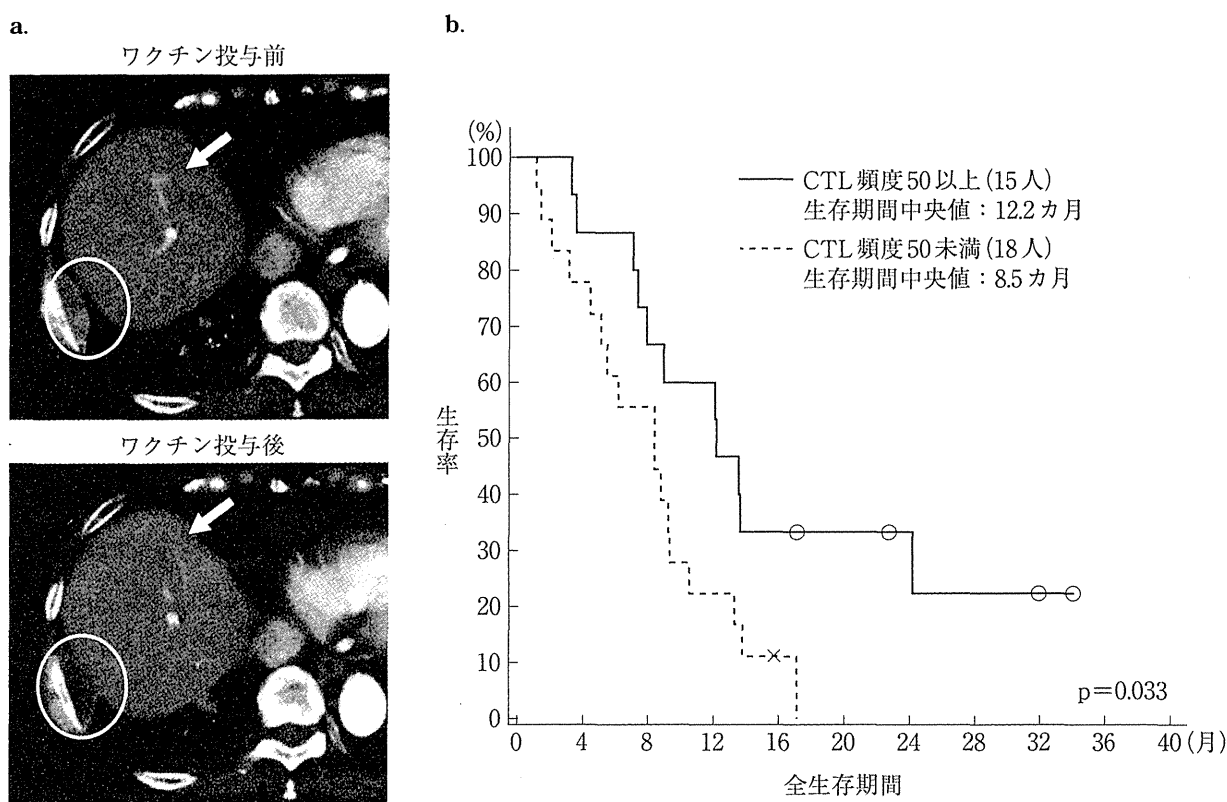


図1 GPC3 ペプチドワクチン第I相臨床試験(文献⁹⁾より改変)

進行肝細胞がん患者 33 例を対象とした臨床試験で、安全性、抗腫瘍効果ならびに免疫学的有効性を証明した。

a. 部分奏効をきたした症例のワクチン投与後の CT 画像では、腫瘍の壊死、消失を認める。

b. 末梢血中の CTL の頻度が高頻度群で生存期間の延長がみられた。

解析を施行した。GPC3 ペプチドワクチンの投与により、33 例中 30 例 (91%) において末梢血中の GPC3 ペプチド特異的 CTL の増加が確認された。十分なインフォームドコンセントのもと、ワクチン投与後の治療効果の評価目的に腫瘍生検を実施し、免疫組織化学的染色によって CD8 陽性 CTL の浸潤を評価した。生検を施行した 7 例中 5 例で、ワクチン投与後に腫瘍に浸潤する CD8 陽性 CTL の存在を確認した。GPC3 ペプチド特異的 CTL の生命予後に対する効果を検討するため、*ex vivo* IFN- γ ELISPOT 解析により得られた末梢血単核球 50 万個中の GPC3 ペプチド特異的 CTL の最大頻度と OS の関連について、統計学的な解析を行った。OS の予後因子について多変量解析 (cox 回帰分析) で解析したところ、AFP 100 ng/mL 以上 ($p=0.004$, $\exp(b)=4.66$), RECIST 腫瘍径 10 cm 以上 ($p=0.005$, $\exp(b)=4.36$), GPC3 ペプチド特異的 CTL の頻

度 50 未満 ($p=0.032$, $\exp(b)=2.71$) が予後因子として選択された。全 33 症例について GPC3 ペプチド特異的 CTL の頻度 50 以上 ($n=15$) または 50 未満 ($n=18$) の 2 群に分けて検討したところ、GPC3 ペプチド特異的 CTL 頻度 50 以上群の OS 中央値は 12.2 カ月、と 50 未満群 8.5 カ月に比べ、有意に延長していた ($p=0.033$, 図 1-b)。

第 I 相臨床試験の解析から、がん特異的な免疫応答が確認され、GPC3 ペプチド特異的 CTL 頻度は GPC3 ペプチドワクチン療法の効果予測マーカーとなりうることを示した。もちろん今後の臨床試験での検証が必要であるが、これらの結果は、GPC3 ペプチドワクチン療法は、副作用が少なく QOL を保ちながら OS を延ばす可能性があることを示唆していると考えられた。

3. 現在施行中の GPC3 ペプチド ワクチン臨床試験

ペプチドワクチン療法の‘proof of concept (POC)’は、投与後に血液中にペプチド特異的 CTL が増えるかどうか、更にその CTL が実際がんの組織の中に浸潤するかどうかを証明することである。著者らは、GPC3 ペプチドワクチン投与により末梢血中に GPC3 ペプチド特異的 CTL が誘導できるという十分な証拠を、前述の第 I 相臨床試験から得ることができたが、ワクチン投与後の腫瘍浸潤 CD8 陽性 CTL が、GPC3 ペプチド特異的 CTL であるかの十分な証明はできていない。現在、ワクチン投与後の腫瘍浸潤リンパ球が、GPC3 ペプチド特異的 CTL であることの証明を目指して、進行肝細胞がん患者を対象とし GPC3 ペプチドワクチン療法前後で全例に肝生検を行う臨床試験を行っている(図 2-a)。またその POC を更に確固たるものにするため、GPC3 ペプチドワクチンの術前投与の臨床試験も計画しているところである。ペプチドワクチンは、今後は国内でも製薬企業での治療の実施が見込まれるが、このようながん免疫療法概念実証となる可能性をもった臨床研究は、アカデミアが行う価値があるのではないかと考えている。

ペプチドワクチン療法は腫瘍がない、あるいは CT で見えない、腫瘍があったとしても腫瘍量が少ない状態でこそ威力を発揮すると考えられ、手術やラジオ波焼灼療法(RFA)などの肝細胞がん根治的治療後の再発予防効果を検証する第 II 相臨床試験を実施中である(図 2-b)。またがんワクチン療法標準化へ向けては、第 II 相臨床試験のデザインこそが大事だと考えており、誰もが納得するような有効性の証明が重要と考えている。著者らの行っている GPC3 ペプチドワクチンの再発予防効果を検証する第 II 相臨床試験は、早期に次相のランダム化試験につなげることを前提とし、1年、2年再発率をエンドポイントとした単群早期第 II 相試験であり、解析予定症例数は 40 例としている。

前述したように GPC3 は、卵巣明細胞腺がん、一部の小児がん(肝芽腫、腎芽腫、卵黄嚢腫)などにも発現しており、これらのがんに対しても臨床応用が期待できる。卵巣明細胞腺がんに関しては、共同研究先である名古屋大学産婦人科で有効性を確かめる第 II 相臨床試験を開始している。また小児がんについては、国立がん研究センター中央病院など 5 施設の小児がんグループにおいて、GPC3 が発現している肝芽腫や腎芽腫などの小児がんを対象にした第 I 相臨床試験もスタートし、症例登録中である。この小児がんグループでは、更に、比較的予後不良な神経芽腫やユーイング肉腫、横紋筋肉腫を対象に、これらに発現する抗原のペプチドカクテルワクチンを用いて、Good Clinical Practice (GCP) に準じた臨床試験体制の下で、薬事承認につなげるための第 I 相の医師主導治験を実施する計画である。

一方で、ペプチドワクチン療法単独では進行がんへの効果は決して劇的とはいえず、更に強力な免疫療法あるいは様々な治療法との併用なども基礎研究で開発し、臨床応用することも目指している。現在、GPC3 ペプチド特異的 CTL の大量培養法に関する研究を応用し、著者らの保有する Good Manufacturing Practice (GMP) 準拠細胞培養設備(セルプロセッシング・センター: CPC)を用い、GPC3 ペプチド特異的 CTL の大量培養および養子免疫療法の臨床試験を計画中である。

おわりに

著者らはがん胎児性抗原 glypican-3 (GPC3) を同定し、基礎研究の成果を基に、GPC3 ペプチドワクチンの臨床試験を実施してきた。免疫療法は国内において標準治療になっていないが、副作用のないがん特異的免疫療法が、今後示される有効性によってはがん治療を大きく変える可能性があると考えられる。がん特異的免疫療法が、がん治療を変える可能性を信じて、質の高い研究と臨床試験を繰り返すことで、多くの患者に役立つ治療法の開発を行っていきたい。