

Surgical Outcomes of Progressive Tractional Retinal Detachment Associated With Familial Exudative Vitreoretinopathy

TAKAHIRO YAMANE, TADASHI YOKOI, YURI NAKAYAMA, SACHIKO NISHINA, AND NORIYUKI AZUMA

- **PURPOSE:** To evaluate various surgeries for treating retinal detachment (RD) associated with familial exudative vitreoretinopathy (FEVR).
- **DESIGN:** Retrospective, interventional case series.
- **METHODS:** The charts of 22 patients who underwent surgery were reviewed. A complete ophthalmic examination was performed including wide-field fundus images with fluorescein angiography. The primary and secondary outcomes were fundus features (vascular activity of the fibrovascular proliferation and extent of tractional RD) and visual acuity (VA), respectively.
- **RESULTS:** Thirty-one eyes were included (12 eyes underwent scleral buckling, 1 scleral buckling and vitrectomy, 7 vitrectomy alone, and 11 lensectomy and vitrectomy). Twenty-six eyes were reattached during 1 surgery. Scleral buckling resulted in cessation of fibrovascular proliferation and retinal reattachment; only 1 of these eyes required vitrectomy. Lens-sparing vitrectomy resulted in stabilized fibrovascular proliferation and retinal reattachment. Vitrectomy with lensectomy did not achieve retinal reattachment in 4 eyes. Fibrovascular proliferation has a rich vascular component in patients younger than 3 years, and collagen fibers were present mainly with more advanced age. The postoperative VA improved in 5 of 8 eyes examined, was unchanged in 1 eye, and decreased in 2 eyes with macular involvement.
- **CONCLUSIONS:** FEVR-induced RDs are highly variable and require careful preoperative evaluation to determine the best surgical procedure. Vitrectomy with release of posterior traction is essential in younger patients with vascularly active fibrovascular proliferation, whereas scleral buckling may be important for cases with peripheral traction anterior to the equator. In all cases, peripheral thermal treatment applied to all ischemic areas contributed to reduced peripheral neovascularization. (*Am J Ophthalmol* 2014;158:1049–1055. © 2014 by Elsevier Inc. All rights reserved.)

FAMILIAL EXUDATIVE VITREORETINOPATHY (FEVR) IS a hereditary vitreoretinal abnormality with diverse fundus findings similar to those of retinopathy of pre-

maturity (ROP).¹ Mild FEVR is characterized by insufficient vascular development, areas of avascularity, and degeneration in the peripheral retina with a generally normal posterior retina. In contrast, the severe form includes fibrovascular proliferation, tractional retinal detachment (RD), and radial retinal folds, which result in serious visual impairment in children.

The retinal changes in FEVR may progress throughout childhood; however, the peak age and pathologic conditions remain unknown.² Disease onset may be in the prenatal stage when retinal vessels develop; and the active phase, and progression of fibrovascular proliferation and tractional RD, generally ends by the time of birth, leaving scarring. However, in some cases the disease continues after birth or reoccurs during the growth years. We previously investigated the natural course of congenital retinal folds associated with FEVR and showed that fibrovascular proliferation recurred and tractional RD developed in 21.7% of affected eyes.³

Despite the fact that this disease threatens vision in children, few studies have investigated the clinical characteristics and surgical treatment of FEVR,^{4–6} especially in patients with progressive proliferation that continues after birth.

We report the surgical outcomes of tractional RD associated with FEVR that occurred after birth.

PATIENTS AND METHODS

THIS RETROSPECTIVE, INTERVENTIONAL CASE STUDY WAS approved by the ethics committee of the National Center for Child Health and Development, Tokyo, Japan. It was in compliance with the tenets of the Declaration of Helsinki. Written informed consent was obtained from all parents of participants.

Thirty-one eyes of 22 patients (12 girls, 10 boys) with FEVR underwent vitreoretinal surgery at the National Center for Child Health and Development between August 1, 2003 and September 31, 2011, when the fibrovascular proliferation continued to progress after birth or reoccurred during patient observation. Vascular activity of fibrovascular proliferation was determined by fundus fluorescein angiography (FA) and continuous series of fundus photography. Eyes were excluded when fibrovascular proliferation had stabilized, a total RD was present that was

Accepted for publication Aug 6, 2014.

From the Department of Ophthalmology, National Center for Child Health and Development, Tokyo, Japan.

Inquiries to Noriyuki Azuma, Department of Ophthalmology, National Center for Child Health and Development, 2-10-1, Okura, Setagaya-ku, Tokyo 157-8535, Japan; e-mail: azuma-n@ncchd.go.jp

diagnosed as cicatricial during the initial examination, or a rhegmatogenous RD was present. The same surgeon (N.A.) performed all surgeries.

Scleral buckling first was performed in eyes with fibrovascular proliferation that was present in the extreme peripheral retina and extended circumferentially for fewer than 2 quadrants. In all eyes, an encircling buckle was placed under the fibrovascular proliferation using a silicone sponge that was 2–3 mm in diameter or 3 × 5 mm. The silicone sponge was removed or cut when fibrovascular proliferation was confirmed to have stabilized to prevent constriction of the growing eyeball.

Photocoagulation alone was never the treatment choice, because fibrovascular proliferation already had occurred. When fundus FA detected a significant dye leakage, photocoagulation also was applied to an avascular area away from the fibrovascular proliferation.

Vitreotomy was performed when fibrovascular proliferation was present in the posterior retina or the periphery and extended circumferentially for 2 or more quadrants, for which condition scleral buckling is ineffective. Lensectomy also was performed when the fibrovascular proliferation was attached extensively to the posterior lens surface or vitreous base or when an extensive tractional RD rapidly progressed owing to aggressive proliferation.

The formed vitreous was removed extensively, especially around the fibrovascular proliferation, along which fibrovascular proliferation can grow. Resection and delamination of the fibrovascular proliferation tissue were minimized when the tissue adhered tightly to the retina and/or ciliary body or contained new vessels.

The preoperative and postoperative fundus features, including the vascular activity of the fibrovascular proliferation and extent of the tractional RDs, were evaluated on color fundus photographs and fundus FA images using the RetCam camera (Massie Research Laboratories, Inc., Pleasanton, California, USA). The best-corrected visual acuity (VA) was measured with a VA chart using Landolt rings or pictures at 5 m and converted to Snellen notation.

RESULTS

THE GESTATIONAL AGES AT BIRTH RANGED FROM 35 TO 41 weeks (mean, 39 weeks); the birth weights ranged from 1768 to 3644 g (mean, 2907 g). The ages at the first visit ranged from 1 month to 10 years (mean, 24 months); the ages at surgery ranged from 1 month to 18 years (mean, 36 months). Nine patients underwent bilateral surgeries at different times; 13 eyes underwent a unilateral surgery.

Active fibrovascular proliferation was seen in 13 eyes of 8 patients who were less than 6 months of age at the time of the first surgery in our hospital, suggesting that the disease continues after the prenatal stage. In 18 eyes of 14 patients, the fibrovascular proliferation regrew during the follow-up period up to age 18 years.

The preoperative fundus findings were fibrovascular proliferation on the posterior retinal pole in 10 eyes, fibrovascular proliferation on the peripheral retina in 1 eye, a serous RD in 1 eye, and a total RD in 4 eyes. Radial retinal folds were already present in 15 eyes: in the temporal quadrant in 14 eyes and in the nasal quadrant in 1 eye.

When patients were 3 years or older, the extent and location of the recurrent fibrovascular proliferation were fewer than 2 quadrants in the periphery in 7 of 10 eyes (70%) and localized in the posterior retina in 3 eyes (30%). In contrast, the types of fibrovascular proliferation varied when patients were younger than 3 years of age; the disease ranged from 2 quadrants or more in the periphery in 5 of 21 eyes (24%), fewer than 2 quadrants in the periphery in 9 eyes (43%), and mainly in the posterior retina in 7 eyes (33%). In 3 of 7 eyes in which the fibrovascular proliferation was restricted to the posterior retina, photocoagulation had been applied previously at referral hospitals.

Ophthalmoscopy identified hemorrhages in 12 of 21 eyes (57%) and exudates in 1 eye (5%) when patients were younger than 3 years of age but failed to identify hemorrhages and exudates without hemorrhage in 2 of 10 eyes (20%) when patients were 3 years of age or older. When patients were younger than 3 years of age, the fibrovascular proliferation appeared reddish, probably because it was composed of many vessels, and FA showed dye leakage in all 21 eyes. In contrast, when patients were 3 years or older, the fibrovascular proliferation, which appeared reddish with fluorescein dye leakage, was seen in only 1 of 10 eyes (10%). In other cases, the fibrovascular proliferation appeared whitish, with no fluorescein dye leakage; however, the tractional RDs slowly developed in accordance with their extension and contraction (Table 1). Thirteen eyes of 11 patients underwent scleral buckling between ages 5 months and 18 years (mean, 52.9 months). Eighteen eyes of 12 patients underwent vitreous surgery; 7 eyes underwent lens-sparing vitrectomy between ages 4 months and 10 years (mean, 52.4 months) and 11 eyes underwent vitrectomy and lensectomy simultaneously between ages 5 and 15 months (mean, 6.3 months). Thirteen eyes underwent laser ablation to the avascular area far from the fibrous proliferation at the time of surgery (7 eyes treated with scleral buckling and 6 eyes with vitrectomy).

During vitrectomy, the vitreous gel was rarely liquefied and was firmly adhered to the avascular retina in all eyes. The fibrovascular proliferation that contained many epicenters also was attached firmly to the retina. Thus, formation of a posterior vitreous detachment and delamination of the fibrovascular proliferation were minimized to avoid bleeding and retinal break formation when the RD was partial. Cicatricial tissues from fibrovascular proliferation were dissected and delaminated after stabilization of vascular activity, when the retina totally detached.

In 4 of 13 fellow eyes not treated surgically, photocoagulation was applied to the peripheral avascular area, because FA identified dye leakage at the growth end of

TABLE 1. Clinical Characteristics of Preoperative Fundus Findings With Familial Exudative Vitreoretinopathy

	Month 0-35 N = 21 Eyes	Month 36+ N = 10 Eyes
Range and location of FP		
More than 2 quadrants in periphery	5 (24%)	0
Less than 2 quadrants in periphery	9 (43%)	7 (70%)
Posterior retina	7 (33%)	3 (30%)
Appearance of FP and surrounding retina		
Abundant vascular proliferation	21 (100%)	1 (10%)
White fibrous tissue	0	9 (90%)
Fluorescein dye leakage	21 (100%)	1 (10%)
Hemorrhages	12 (57%)	0
Hard exudates	1 (5%)	2 (20%)

FP = fibrovascular proliferation.

the retinal vessels. Four eyes with an avascular area and 1 eye with retinal folds that showed no dye leakage were only observed. Four eyes with a total RD that had cicatrized did not satisfy the surgical criteria, because the fellow eyes were expected to obtain relatively good vision. Table 2 shows the details of all cases.

Thirty-one eyes of 22 patients were included in the study. Twelve eyes (38.7%) underwent scleral buckling, 1 (3.2%) underwent scleral buckling and vitrectomy, 7 (22.6%) underwent vitrectomy alone, and 11 (35.5%) underwent lensectomy and vitrectomy. Overall, reattachment was achieved in 26 eyes (83.9%) during 1 surgery.

Postoperatively, scleral buckling suppressed progression of fibrovascular proliferation and released traction in 12 eyes (Figure 1), but additional lens-sparing vitrectomy was needed in 1 eye to remove residual fibrovascular proliferation in the posterior retina. Scleral buckles were removed in all eyes in an average of 5.8 months postoperatively. Stabilization of the fibrovascular proliferation and retinal reattachment were obtained after lens-sparing vitrectomy in 7 eyes and vitrectomy with lensectomy in 7 eyes (Figure 2). However, 4 eyes did not achieve retinal reattachment because of rapid preoperative progression to a total RD. Other associated ocular pathologies, including cataract and glaucoma, did not occur postoperatively.

The patients were followed postoperatively for periods ranging from 17 to 112 months (mean, 52 months). The preoperative and postoperative VAs were compared in only 8 eyes of 7 patients in which retinal reattachment occurred (5 eyes after scleral buckling and 3 eyes after lens-sparing vitrectomy), because the other 15 patients were too young or mentally challenged. The postoperative VAs ranged from no light perception to 20/16; the VA increased in 5 eyes, was unchanged in 1 eye, and decreased in 2 eyes with macular traction. The other 13 eyes in which

the postoperative VA could not be measured had good visual fixation and following behavior postoperatively.

DISCUSSION

THE CURRENT STUDY SHOWED THAT FIBROVASCULAR PROLIFERATION in FEVR recurs even in patients as old as 18 years, although we have never observed recurrence in adults. The mechanism of recurrence is unknown; however, hormonal changes during the growth years may play a role in adolescent reactivation, with sudden release of vascular endothelial growth factor (VEGF) and the retinal response to it,⁷ which may be similar to the relationship between growth hormone and progression of retinopathy in juvenile diabetes.⁸

The characteristics of fibrovascular proliferation also differ depending on patient age. Younger patients tend to have a more aggressive form.⁹ When patients are younger than 3 years, the fibrovascular proliferation is rich in vascularization, occurs over a wide area, and grows rapidly. In contrast, in older patients, fibrovascular proliferation is rich in collagen but poor in vascular components, occurs in a restricted area, and progresses slowly. Thus, careful follow-up every 2–3 months is recommended, especially in patients younger than 3 years. Further follow-up even over a longer period also is needed to detect recurrences, and retinal break formation can occur during the patients' entire lives. Fundus photography and FA that covers a wide field are useful to identify early signs of fibrovascular proliferation recurrence and evaluate disease activity.

The vitreoretinal surgeries performed according to our indications, which were similar to those for ROP, obtained good surgical outcomes, including stabilized fibrovascular proliferative activity and retinal reattachment, except for vitrectomy for a total RD. When the fibrovascular proliferation was in the extreme retinal periphery, vitrectomy could not be performed without lensectomy. Lens removal is a substantial disadvantage for visual development in children. Thus, we first opted to perform scleral buckling to treat such eyes; vitrectomy with lensectomy was the second choice. The effect of scleral buckling for FEVR, which may be similar to that for stage 4 ROP, not only reduces the tractional force of fibrovascular proliferation but also reduces its activity.¹⁰ A cell culture study showed that stretching of the vascular endothelial cell body causes increased sensitivity to VEGF.¹¹ Buckling likely reduces stretching of the vascular endothelial cells in fibrovascular proliferation, resulting in downregulation of sensitivity to VEGF and stabilization of new vessel formation. The surgical challenge in FEVR is related to peripheral ischemia and posterior-to-peripheral (generally temporal) traction. Therefore, the key to surgery is separation of the hyaloid from the nerve, then the very tight adherence to the macula, and finally careful trimming of the posterior cortical vitreous at the junction of the vascular avascular retina where the proliferation invariably occurs. The peripheral traction

TABLE 2. Surgical Outcomes of Vitreoretinal Surgery for Tractional Retinal Detachment Associated With Familial Exudative Vitreoretinopathy

Patient	Sex	First Visit (mo)	Eye	Preoperative Fundus Findings	Age at Surgery (mo)	First Surgery	Additional Surgery	Final Fundus Findings	Preop VA	Final VA
1	F	1	OD	Retinal fold	1	L&V		Attached		Not measured
			OS	Retinal fold	1	L&V	SB	Attached		Not measured
2	M	2	OD	FP of posterior pole	2	L&V		Attached		Not measured
			OS	FP of posterior pole	2	L&V		Attached		Not measured
3	F	3	OD	Total RD AC(-)						NLP
			OS	Retinal fold	3	L&V	SB	Attached		LP
4	M	2	OD	Preretinal hemorrhage	4	LSV		Attached		Not measured
			OS	Preretinal hemorrhage	5	L&V		Attached		Not measured
5	F	3	OD	FP of posterior pole	5	LSV		Attached		20/100
			OS	FP of posterior pole	5	LSV		Attached		20/125
6	M	4	OD			PC				20/50
			OS	Retinal fold	5	SB		Attached		CF
7	M	4	OD	Total RD						Not measured
			OS	Retinal fold	6	SB		Attached		Not measured
8	M	4	OD	Retinal fold	6	SB		Attached		Not measured
			OS	Retinal fold	6	SB		Attached		Not measured
9	M	4	OD	Retinal fold	8	L&V		Detached		NLP
			OS	Retinal fold	74	SB		Attached		20/250
10	M	4	OD	Retinal fold	10	L&V		Detached		Not measured
			OS	Retinal fold	8	L&V		Attached		Not measured
11	M	12	OD	Avascularity		PC				Not measured
			OS	Total RD	12	SB		Attached		Not measured
12	F	12	OD	Avascularity		PC				Not measured
			OS	Retinal fold	13	SB		Attached		Not measured
13	F	12	OD	Retinal fold	14	L&V		Detached		NLP
			OS	Avascularity						20/20
14	M	6	OD	Retinal fold	15	L&V		Detached		LP
			OS	Total RD AC(-)						NLP
15	F	32	OD	Total RD						NLP
			OS	FP of posterior pole	34	LSV		Attached		20/200
16	M	39	OD	Avascularity						20/32
			OS	Retinal fold	39	SB		Attached	20/320	20/250
17	M	25	OD	FP of periphery	40	SB		Attached		20/25
			OS	Retinal fold						20/500
18	F	44	OD	Serous RD	45	SB		Attached	20/200	20/125
			OS	Avascularity		PC				20/32
19	M	70	OD	FP of posterior pole	63	LSV		Attached	20/63	20/40
			OS	Avascularity						20/16
20	F	97	OD	Retinal fold	113	SB		Attached	20/16	20/16
			OS	Retinal fold	113	SB	LSV	Attached	20/125	20/20
21	F	122	OS	FP of posterior pole	127	LSV		Attached	20/50	20/100
			OD	FP of posterior pole	129	LSV		Attached	20/63	20/25
22	F	41	OD	Retinal fold	216	SB		Attached	20/200	20/32
			OS	Normal						20/16

AC = anterior chamber; CF = counting fingers; FP = fibrovascular proliferation; LP = light perception; LSV = lens-sparing vitrectomy; L&V = lensectomy and vitrectomy; NLP = no light perception; PC = photocoagulation; Preop VA = preoperative visual acuity; RD = retinal detachment; SB = scleral buckling.

often remains, but because it is truncated it can be stable over time, and this is exactly where a well-placed buckle can be helpful.¹² However, when fibrovascular proliferation ranged circumferentially over 2 or more quadrants, buckling did not release the wide traction.

Lens-sparing vitrectomy also obtained good results when fibrovascular proliferation was present in the posterior retina or the periphery over 2 or more quadrants. Dissection and delamination of fibrovascular proliferation that contains new vessels and firmly adheres to the retina are

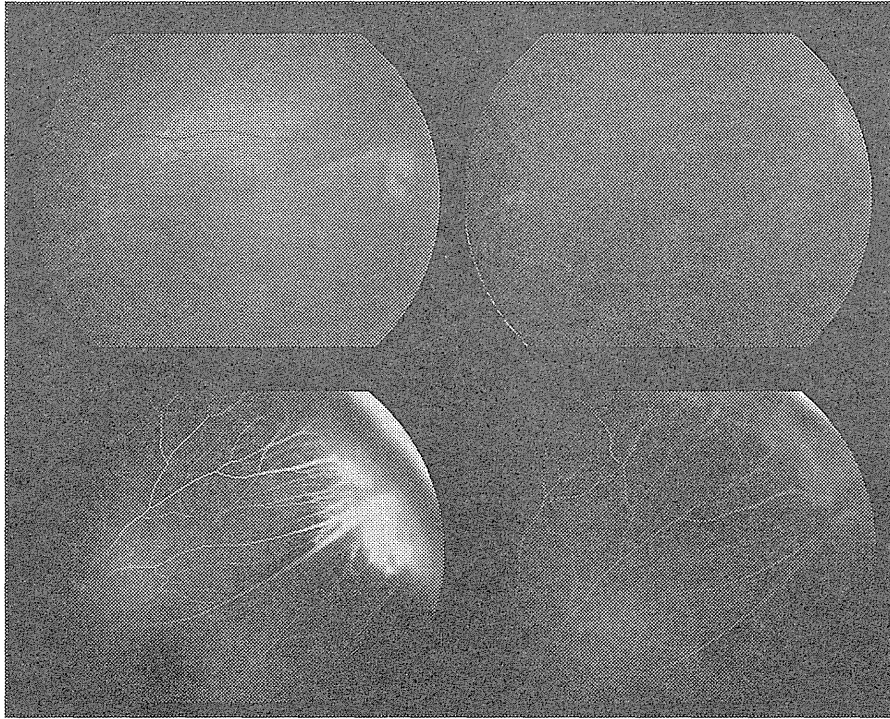


FIGURE 1. Case 12. Fundus photographs and fluorescein angiography (FA) images obtained before and after scleral buckling for tractional retinal detachment in the peripheral retina with familial exudative vitreoretinopathy. (Top left) A fundus photograph of the left eye obtained preoperatively at age 12 months shows a radial retinal fold and reddish vessel-rich fibrovascular proliferation in the peripheral retina. (Bottom left) An FA image obtained preoperatively shows fluorescein dye leakage from the fibrovascular proliferation. (Top right) A fundus photograph of the left eye obtained postoperatively at age 16 months shows a radial retinal fold and whitish vessel-poor fibrovascular proliferation in the peripheral retina. (Bottom right) An FA image obtained postoperatively shows no fluorescein dye leakage.

difficult to perform¹³; thus, the primary surgical goals are to remove the vitreous gel around the fibrovascular proliferation, along which the fibrovascular proliferation grows, and wash the VEGF from the vitreous cavity. Eyes with fibrovascular proliferation localized to a certain area with low vascular activity underwent lens-sparing vitrectomy. When the vascular activity of fibrovascular proliferation is high, the vitreous gel should be removed extensively.

Lens preservation is important to prevent amblyopia and promote visual development. However, the area in which the vitreous gel is removed by lens-sparing vitrectomy is limited to the relatively posterior vitreous cavity; thus, lensectomy performed before vitrectomy is unavoidable when fibrous proliferation is present in the extreme periphery or reaches the posterior lens surface or vitreous base or rapidly progresses.

Nevertheless, in the current study, high rates of stabilization of fibrovascular proliferation and retinal reattachment were achieved postoperatively that were comparable to those achieved in patients with ROP,^{14,15} because detection of the early signs of recurrent fibrovascular proliferation may facilitate immediate surgical treatment. When the fibrovascular proliferation stabilizes and the retina reattaches early, eyes may maintain postoperative

vision that is about the same as that which could have been obtained preoperatively, if it had not been for residual macular traction.

Retinal reattachment was not obtained in 4 eyes of 4 patients aged 3 years or younger, in which the RD rapidly progressed to a total detachment. Vitrectomy could not be performed safely in those eyes, which is similar to conditions in eyes with severe ROP that rapidly progresses to stage 5, because significant hemorrhaging from the active fibrovascular proliferation prevents surgery. Furthermore, unlike patients with ROP, the vitreous gel in eyes with FEVR rarely liquefies, and the fibrovascular proliferation extends and adheres to a wide area of the retinal surface; thus, fibrovascular proliferation is difficult to remove, even after it has cicatrized.

The indication for surgery also is affected profoundly by the status of the fellow eye. When 1 eye has a total RD, and the fellow eye must have good lifetime vision, further surgical intervention may not be recommended, because the eye may obtain poor visual outcomes ranging from light perception to ambulatory vision, despite successful retinal reattachment after vitrectomy. When both eyes have a total RD, vitrectomy should be performed in 1 or both eyes.

Photocoagulation is also important to control progression of fibrovascular proliferation. In the current study,

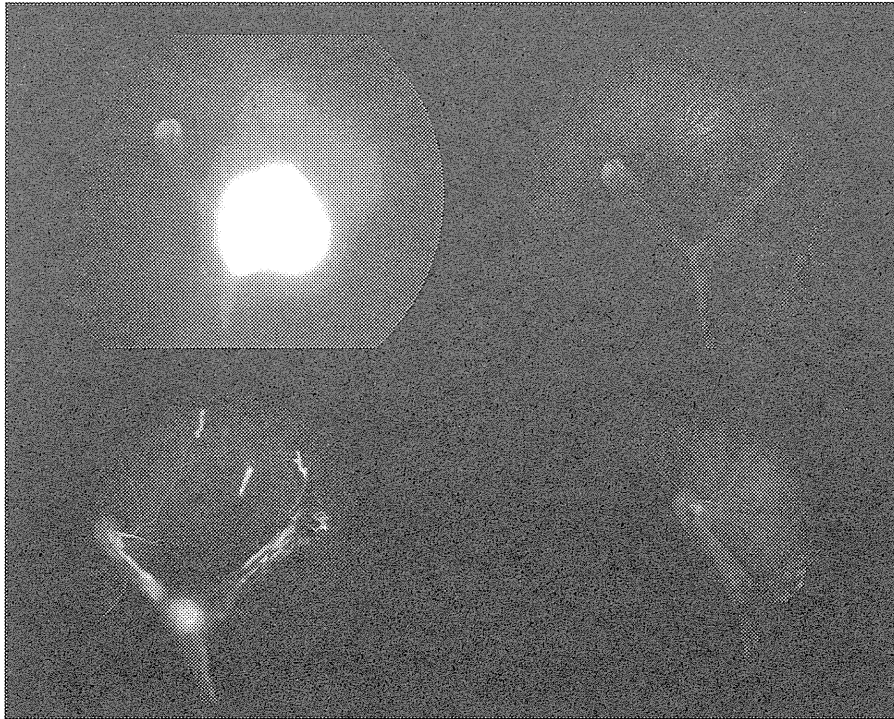

FIGURE 2. Case 10. Fundus photographs and fluorescein angiography (FA) images performed before and after vitrectomy and lensectomy for tractional retinal detachment in posterior retina with familial exudative vitreoretinopathy. (Top left) A fundus photograph of the left eye obtained preoperatively at age 8 months shows reddish fibrovascular proliferation that reaches the posterior lens surface and is rich in vessels with hemorrhages. (Bottom left) An FA image obtained preoperatively shows fluorescein dye leakage from the fibrovascular proliferation. (Top right) A fundus photograph of the left eye obtained postoperatively at age 10 months shows whitish vessel-poor fibrovascular proliferation. (Bottom right) An FA image obtained postoperatively shows no fluorescein dye leakage.

photocoagulation was applied around the time of the surgery in 9 of 13 eyes that underwent scleral buckling and in 14 of 18 eyes that underwent vitrectomy, which might contribute to stabilization of the fibrovascular proliferation. However, photocoagulation performed at a referral hospital long ago did not prevent recurrence of fibrovascular proliferation in 5 eyes. Thus, photocoagulation is limited in that it does not completely prevent fibrovascular proliferation from recurring and is applied only to the avascular retina away from the fibrovascular proliferation to avoid retinal break formation.

Intraocular injections of anti-VEGF drugs, primarily bevacizumab (Avastin; Genentech Inc, South San Francisco, California, USA), to treat fibrovascular proliferation have been administered to treat ROP.^{16–18} VEGF also may be related to recurrent fibrovascular proliferation in eyes with FEVR, although in the current study we did not measure

the VEGF concentration in the vitreous cavity. Anti-VEGF therapy may stabilize fibrovascular proliferation; however, the optimal timing and the drug dose are uncertain. Contraction of fibrovascular proliferation, an adverse drug effect, which promotes retinal dragging and detachment, is critical when the fibrovascular proliferation is extensive. From our experience after administration of an anti-VEGF drug, the tissues are inflexible and the cutting using vitreous scissors is difficult and dangerous. Serum evaluation has shown that intravitreally injected bevacizumab can migrate from the eye into the systemic circulation and reduce the serum level of VEGF in infants with ROP.¹⁹ This adverse effect might affect development and growth of organs during childhood. Thus, the efficacy and safety of photocoagulation, vitreoretinal surgery, and anti-VEGF therapy for treating FEVR should be investigated further, in accordance with the patients' physical condition and genetic background.

ALL AUTHORS HAVE COMPLETED AND SUBMITTED THE ICMJE FORM FOR DISCLOSURE OF POTENTIAL CONFLICTS OF INTEREST and none were reported. The authors indicate no funding support. Contributions of authors: design and conduct of the study (Tak.Y., N.A.); collection and management of data (Tak.Y., Tad.Y., Y.N., S.N., N.A.); analysis and interpretation of the data (Tak.Y., Tad.Y., Y.N., S.N., N.A.); and preparation, review, or approval of the manuscript (Tak.Y., N.A.).

REFERENCES

1. Campo RV. Similarity of familial exudative vitreoretinopathy and retinopathy of prematurity. *Arch Ophthalmol* 1983; 101(5):821.
2. Taylor D, Hoyt CS. *Pediatric Ophthalmology and Strabismus*. 3rd ed. Edinburgh, Scotland: Elsevier Saunders; 2005:480-481.
3. Nishina S, Suzuki Y, Yokoi T, Kobayashi Y, Noda E, Azuma N. Clinical features of congenital retinal folds. *Am J Ophthalmol* 2012;153(1):81-87.
4. Shubert A, Tasman W. Familial exudative vitreoretinopathy: surgical intervention and visual acuity outcomes. *Graefes Arch Clin Exp Ophthalmol* 1997;235(8):490-493.
5. Pendergast SD, Trese MT. Familial exudative vitreoretinopathy. Results of surgical management. *Ophthalmology* 1998; 105(6):1015-1023.
6. Ranchod TM, Ho LY, Drenser KA, Capone A Jr, Trese MT. Clinical presentation of familial exudative vitreoretinopathy. *Ophthalmology* 2011;118(10):2070-2075.
7. Tagami M, Kusuhara S, Honda S, Tsukahara Y, Negi A. Rapid regression of retinal hemorrhage and neovascularization in a case of familial exudative vitreoretinopathy treated with intravitreal bevacizumab. *Graefes Arch Clin Exp Ophthalmol* 2008;246(12):1787-1789.
8. Peczyńska J, Urban M, Urban B, Glowńska B, Florys B. Assessment of growth factor levels in adolescents with type 1 diabetes mellitus and the beginning of diabetic microangiopathy. *Endokrynol Diabetol Chor Przemiany Materii Wieku Rozw* 2004;10(1):41-48.
9. Benson WE. Familial exudative vitreoretinopathy. *Trans Am Ophthalmol Soc* 1995;93:473-521.
10. Yokoi T, Yokoi T, Kobayashi Y, Hiraoka M, Nishina S, Azuma N. Evaluation of scleral buckling for stage 4A retinopathy of prematurity by fluorescein angiography. *Am J Ophthalmol* 2009;148(4):544-550.
11. Mammoto A, Connor KM, Mammoto T, et al. A mechanosensitive transcriptional mechanism that controls angiogenesis. *Nature* 2009;457(7233):1103-1108.
12. Drenser KA, Trese MT, Capone A. Familial exudative vitreoretinopathy (FEVR). In: Hartnett ME, ed. *Pediatric Retina*. 2nd ed. Philadelphia: Lippincott Williams & Wilkins; 2013:345-349.
13. Ikeda T, Fujikado T, Tano Y, et al. Vitrectomy for rhegmatogenous or tractional retinal detachment with familial exudative vitreoretinopathy. *Ophthalmology* 1999;106(6): 1081-1085.
14. Singh R, Reddy DM, Barkmeier AJ, Holz ER, Ram R, Carvounis PE. Long term visual outcomes following lens-sparing vitrectomy for retinopathy of prematurity. *Br J Ophthalmol* 2012;96(11):1395-1398.
15. Trese MD, Droste PJ. Long term postoperative result of a consecutive series of stage 4 and 5 ROP. *Ophthalmology* 1998;105(6):992-997.
16. Mintz-Hittner HA, Kennedy KA, Chuang AZ, BEAT-ROP Cooperative Group. Efficacy of intravitreal bevacizumab for stage 3+ retinopathy of prematurity. *N Engl J Med* 2011; 364(7):603-615.
17. Law JC, Recchia FM, Morrison DG, Donahue SP, Estes RL. Intravitreal bevacizumab as adjunctive treatment for retinopathy of prematurity. *J AAPOS* 2010;14(1):6-10.
18. Kusaka S, Shima C, Wada K, et al. Efficacy of intravitreal injection of bevacizumab for severe retinopathy of prematurity: a pilot study. *Br J Ophthalmol* 2008;92(11):1450-1455.
19. Sato T, Wada K, Arahori H, et al. Serum concentrations of bevacizumab (Avastin) and vascular endothelial growth factor in infants with retinopathy of prematurity. *Am J Ophthalmol* 2012;153(2):327-333.



Biosketch

Takahiro Yamane, MD, PhD, received his PhD degree in 2006 from Yokohama city University School of Medicine, Japan. He has practiced pediatric ophthalmology and strabismus at the Department of Ophthalmology, National Center for Child Health and Development, Japan since 2011. His clinical and research interests include the vitreoretinal disease and pediatric ophthalmology.

Editorial Manager(tm) for Retinal Cases & Brief Reports
Manuscript Draft

Manuscript Number: CABR 210-1132

Title: THREE CASES OF RHEGMATOGENOUS RETINAL DETACHMENT ASSOCIATED WITH REGRESSED RETINOBLASTOMA AFTER CONSERVATIVE TUMOR THERAPY

Short Title: RETINAL DETACHMENT AFTER TUMOR THERAPY

Article Type: Case Report

Keywords: rhegmatogenous retinal detachment, retinoblastoma, vitrectomy, scleral buckling, preretinal membrane.

Corresponding Author: Dr Noriyuki Azuma, M.D., Ph,D

Corresponding Author's Institution: National Center for Child Health and Development

First Author: Michiko Tanaka, M.D.

Order of Authors: Michiko Tanaka, M.D.; Tadashi Yokoi, M.D.; Makiko Ito, M.D.; Yuri Kobayashi, M.D.; Eiichiro Noda, M.D.; Sachiko Nishina, M.D.,Ph,D; Kentaro Matsuoka, M.D.,Ph,D; Noriyuki Azuma, M.D., Ph,D

Abstract: Purpose: To report three cases of rhegmatogenous retinal detachment (RRD) associated with regressed retinoblastoma after conservative therapy.

Methods: Three eyes of three patients with a RRD, in which retinal breaks were present at the edge of the tumor scar, were treated with vitrectomy and scleral buckling.

Results: In two eyes in which cryopexy and silicone oil injection were performed, a preretinal membrane formed that was comprised primarily of glial cells. Additional vitrectomy and membrane peeling reattached the retina. In one eye, in which photocoagulation and gas injection were performed, an initial vitrectomy and scleral buckling reattached the retina without postoperative membrane formation.

Conclusions: Vitrectomy and scleral buckling contributed to closure of the irregularly shaped retinal tear at the edge of the tumor scar. Photocoagulation and gas injection instead of cryopexy and silicone oil injection may avoid postoperative glial proliferation from the tumor scar.

Suggested Reviewers:

Opposed Reviewers:

**THREE CASES OF RHEGMATOGENOUS RETINAL DETACHMENT ASSOCIATED WITH
REGRESSED RETINOBLASTOMA AFTER CONSERVATIVE TUMOR THERAPY**

**MICHIKO TANAKA, MD, TADASHI YOKOI, MD, YURI KOBAYASHI, MD, SACHIKO
NISHINA, MD, EIICHIROU NODA, MD, MAKIKO ITO, MD, AND NORIYUKI AZUMA, MD**

Short title: RETINAL DETACHMENT AFTER TUMOR THERAPY

From the Department of Ophthalmology, National Center for Health and Development, 2-10-1, Okura,
Setagaya-ku, Tokyo 157-8535 Japan.

Reprint requests: Noriyuki Azuma, MD, Department of Ophthalmology, Center for Health and
Development, 2-10-1, Okura, Setagaya-ku, Tokyo 157-8535 Japan (tel: +81334110111; fax:
+81334129811; e-mail: azuma-n@ncchd.go.jp).

The authors have no proprietary interest in any aspect of this report.

Key words: rhegmatogenous retinal detachment, retinoblastoma, vitrectomy, scleral buckling, preretinal membrane.

Abstract

Purpose: To report three cases of rhegmatogenous retinal detachment (RRD) associated with regressed retinoblastoma after conservative therapy.

Methods: Three eyes of three patients with a RRD, in which retinal breaks were present at the edge of the tumor scar, were treated with vitrectomy and scleral buckling.

Results: In two eyes in which cryopexy and silicone oil injection were performed, a preretinal membrane formed that was comprised primarily of glial cells. Additional vitrectomy and membrane peeling reattached the retina. In one eye, in which photocoagulation and gas injection were performed, an initial vitrectomy and scleral buckling reattached the retina without postoperative membrane formation.

Conclusions: Vitrectomy and scleral buckling contributed to closure of the irregularly shaped retinal tear at the edge of the tumor scar. Photocoagulation and gas injection instead of cryopexy and silicone oil injection may avoid postoperative glial proliferation from the tumor scar.

Vision in eyes with a retinoblastoma is preserved by conservative treatment, including chemotherapy, radiotherapy, photocoagulation, cryotherapy, episcleral plaque brachytherapy, direct intra-arterial (ophthalmic artery) chemotherapy, or a combination of therapies. Once remission is achieved, rhegmatogenous retinal detachment (RRD) is a serious complication. Bauman et al. reported that 1% of eyes with conservatively treated retinoblastoma are complicated by development of a RRD during 20 years after treatment.¹ Retinal breaks often occur near the edge of the tumor scar, which is difficult to treat with conventional scleral buckling or vitrectomy. We report three patients with a RRD after conservative therapy for retinoblastoma who were successfully treated with scleral buckling and vitrectomy.

Case reports

Case 1, a 7-year-old boy, received external irradiation for retinoblastoma (international classification grade B) in the right eye (Fig. 1A). One month after the end of radiotherapy, a RRD developed with a retinal tear at the border of the tumor scar (Fig. 1B). The RRD progressed to proliferative vitreoretinopathy (PVR) while tumor regression was confirmed. The initial vitrectomy with cryopexy and encircling scleral buckle that attempted to seal the retinal break reattached the retina temporarily; however, PVR recurred 1 month later (Fig. 1C). Additional vitrectomy and silicone oil injection reattached the retina, but a severe preretinal membrane expanded from the break (Fig. 1D) The retina is still attached after silicone oil removal and partial membrane peeling (Fig. 1E). Two 2 years after the last surgery, the visual acuity (VA) of his right eye is counting fingers at 20 cm.

Case 2, a 3-year-old girl, had bilateral retinoblastomas. The left eye with a large tumor (grade D) was

enucleated, and the right eye with a small tumor (grade B) was treated by systemic chemoreduction with vincristine, cyclophosphamide, and etoposide, direct intra-arterial chemotherapy with melphalan, and episcleral plaque brachytherapy. At 6 years of age, a RRD developed in the right eye with a retinal tear at the edge of the tumor scar, which was near the optic disc (Fig. 2A). The initial conventional surgery of radial scleral buckling, encircling, and cryopexy failed, but additional vitrectomy, endophotocoagulation, and silicone oil injection reattached the retina. One month later, a severe preretinal membrane developed from the retinal break and folded the posterior retina including the macula (Fig. 2B). An additional surgical procedure with membrane peeling and silicone oil removal unfolded the retina (Fig. 2C). Immunohistochemistry showed that the preretinal membrane obtained by peeling surgery was strongly positive for glial fibrillary acidic protein and faintly positive for vimentin but negative for neuron-specific enolase and desmin (Fig. 2D, E). One year after the final surgery, the retina is still attached and the corrected VA of the right eye is 0.3.

Case 3, a 1-year-old boy, had bilateral retinoblastomas. The right eye with a large tumor (grade D) was enucleated, and the left eye with a small tumor (grade B) was treated with systemic chemoreduction with vincristine, cyclophosphamide, and etoposide, direct intra-arterial chemotherapy with melphalan, episcleral plaque brachytherapy, and photocoagulation. At 2 years of age, a RRD developed in the left eye with a retinal tear at the edge of the tumor scar and rapidly progressed to PVR (Fig. 3A). Vitrectomy with an encircling scleral buckle, endophotocoagulation, and SF₆ gas tamponade successfully reattached the retina. A preretinal membrane has not developed postoperatively for 1 year (Fig. 3B). The visual acuity cannot be measured because the patient is mentally challenged, but the left eye shows good fixation and following behavior.

In all eyes that underwent vitrectomy, no malignant cells were detected in the vitreous cavity by intraoperative cytologic examination of the vitreous. The retinoblastomas have not recurred in any eye after conservative tumor treatment.

Comments

There is a risk of recurrent malignancy in associated with eyes with a RRD associated with a retinoblastoma. Bauman et al. reported that retinoblastomas recurred after surgery for RRD in three of eight cases.¹ Thus, preoperative confirmation of tumor regression and cytologic examination for vitreous or subretinal fluid during surgery are necessary, when vitrectomy or drainage of subretinal fluid to treat PVR or bullous retinal detachment is attempted.

Retinal breaks often occur at the edge of the tumor scar, with hard calcification in the scar and a fragile degenerative retinal border, resulting in an irregular shape and hardness of the break edge. The retina around the tumor becomes atrophied as the result of radiotherapy, photocoagulation, and vitreous adhesion.^{2,3} Thus, a wide scleral buckle should be positioned not only to seal the retinal break but to support the tumor scar and surrounding fragile retina. Vitrectomy also removes adhesion and traction of the vitreous to the tumor scar.

We observed preretinal membrane formation in cases 1 and 2, in which cryopexy and silicone oil injection were performed but not in case 3 treated with endophotocoagulation and fluid-gas exchange. We

previously reported glial proliferation from a conservatively treated retinoblastoma scar.⁴ The tumor scars are the likely source of glial proliferation. It is well known that cryopexy and silicone oil injection cause postoperative PVR.^{5,6} Excessive freezing by cryopexy and injection of silicone oil also may trigger glial proliferation from the tumor scar. Endophotocoagulation that encircles the entire tumor scar and gas tamponade may avoid formation of a preretinal membrane.

References

1. Bauman CR, Shields CL, Shields JA, Tasman WS. Surgical repair of rhegmatogenous retinal detachment after treatment for retinoblastoma. *Ophthalmology* 1998; 105:2134-2139.
2. Shields CL, Shields JA. Recent developments in the management of retinoblastoma. *J Pediatr Ophthalmol Strabismus* 1999;36:8-18.
3. Egbert PR, Fajardo LF, Donaldson SS, Moazed K. Posterior ocular abnormalities after irradiation for retinoblastoma: a histopathological study. *Br J Ophthalmol* 1998;64:660-665.
4. Yokoi T, Hiraoka M, Suzuki Y, et al. Glial extrusion from regressed retinoblastoma after conservative treatment. *Acta Ophthalmol* 2008;86:462-464.
5. Bonnet M, Fleury J, Guenoun S, et al. Cryopexy in primary rhegmatogenous retinal detachment: a risk factor for postoperative proliferative vitreoretinopathy? *Graefes Arch Clin Exp Ophthalmol* 1996;234:739-743.
6. Lewis H, Burke JM, Abrams GW, Aaberg TM. Perisilicone proliferation after vitrectomy for proliferative vitreoretinopathy. *Ophthalmology* 1988;95:583-591.

Legends

Fig. 1. (A) Fundus photograph of the right eye of case 1 shows a retinoblastoma before radiotherapy. (B) Total retinal detachment with a tear (arrowhead) has occurred 1 month after radiotherapy. (C) Retinal redetachment has progressed to PVR 1 month after the initial surgery. (D) After the second surgery, the retina is reattached, but a severe preretinal membrane has formed around the break. (E) Fundus photograph after silicone oil removal and partial membrane peeling.

Fig. 2. (A) Fundus photographs of the right eye of case 2 shows a retinal detachment with a tear (arrowhead) near the optic disc. (B) A severe preretinal membrane that folded the posterior retina has developed after the additional vitrectomy. (C) The retina is reattached after silicone oil removal and membrane peeling. (D) Examination of the preretinal membrane obtained by peeling surgery shows spindle-shaped cells hematoxylin-eosin staining. (E) The membrane is strongly positive for glial fibrillary acidic protein (GFAP) immunostaining (anti-GFAP staining; bar= 50 μ m).

Fig. 3. (A) A fundus photograph of the left eye of case 3 shows retinal detachment with a tear (arrowhead) at the edge of the tumor scar. (B) The retina reattached after vitrectomy, scleral buckling, and endophotocoagulation.

Cover Letter (Optional)

Dear the Editor

We will pay for the extra-fee of color figures, when accepted.

We report here three cases with retinal detachment that were treated vitrectomy and scleral buckling. Our results open a new framework in treatment of the most severe type of retinal detachment. Hence, we believe that our data draw keen interests of readers. Hoping that our data fit the scope of retinal cases and brief reports, we wish to submit this manuscript.

Thank you very much for your consideration.

Dr. Noriyuki Azuma

Department of Ophthalmology, National Center for Child Health and Development
2-10-1, Okura, Setagaya-ku, Tokyo 157-8535, Japan

phone +81-3-3416-0181 ext. 7035;

fax +81-3-3416-2222;

e-mail azuma-n@ncchd.go.jp

Figure1

[Click here to download high resolution image](#)

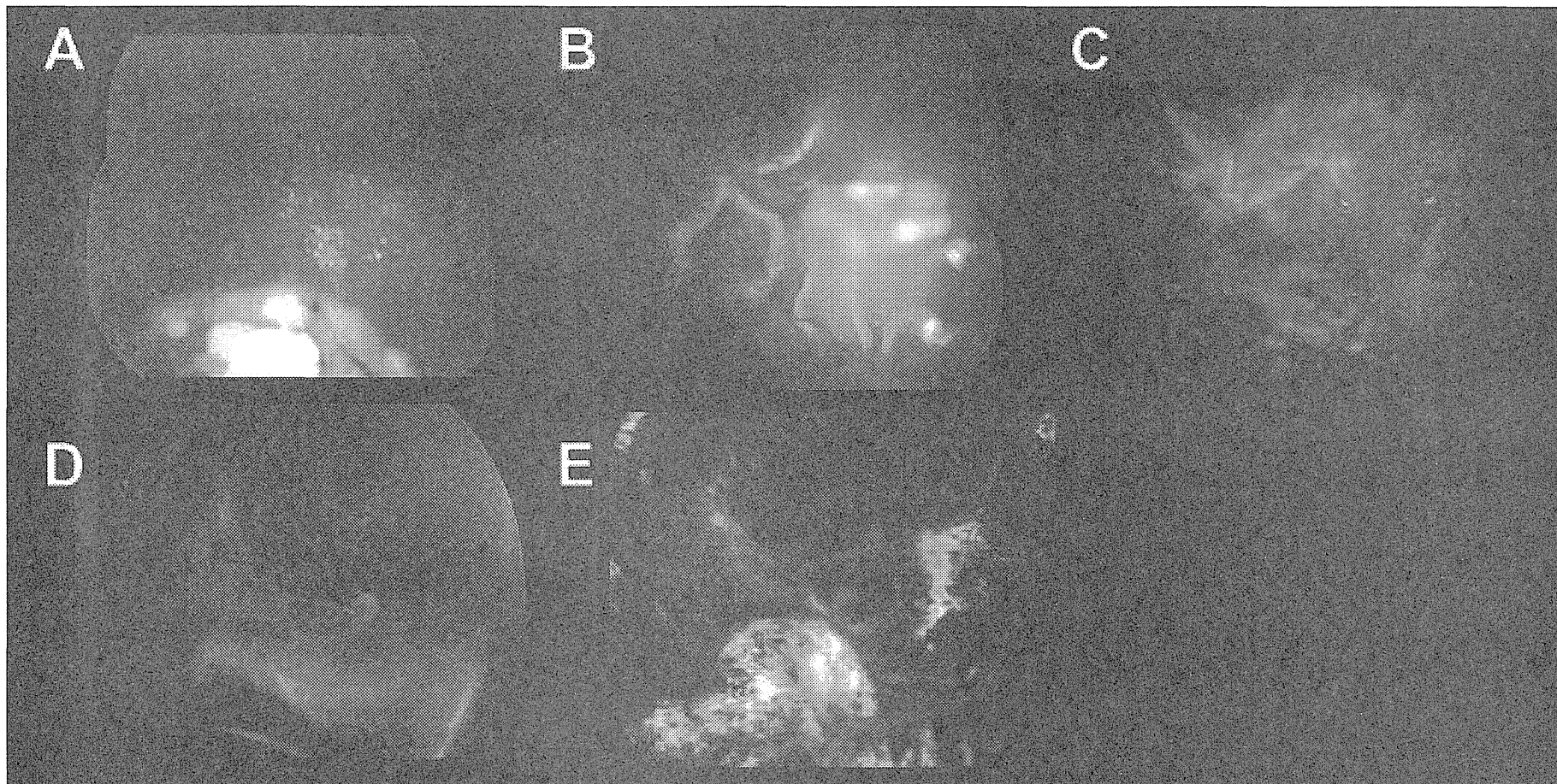


Figure2
[Click here to download high resolution image](#)

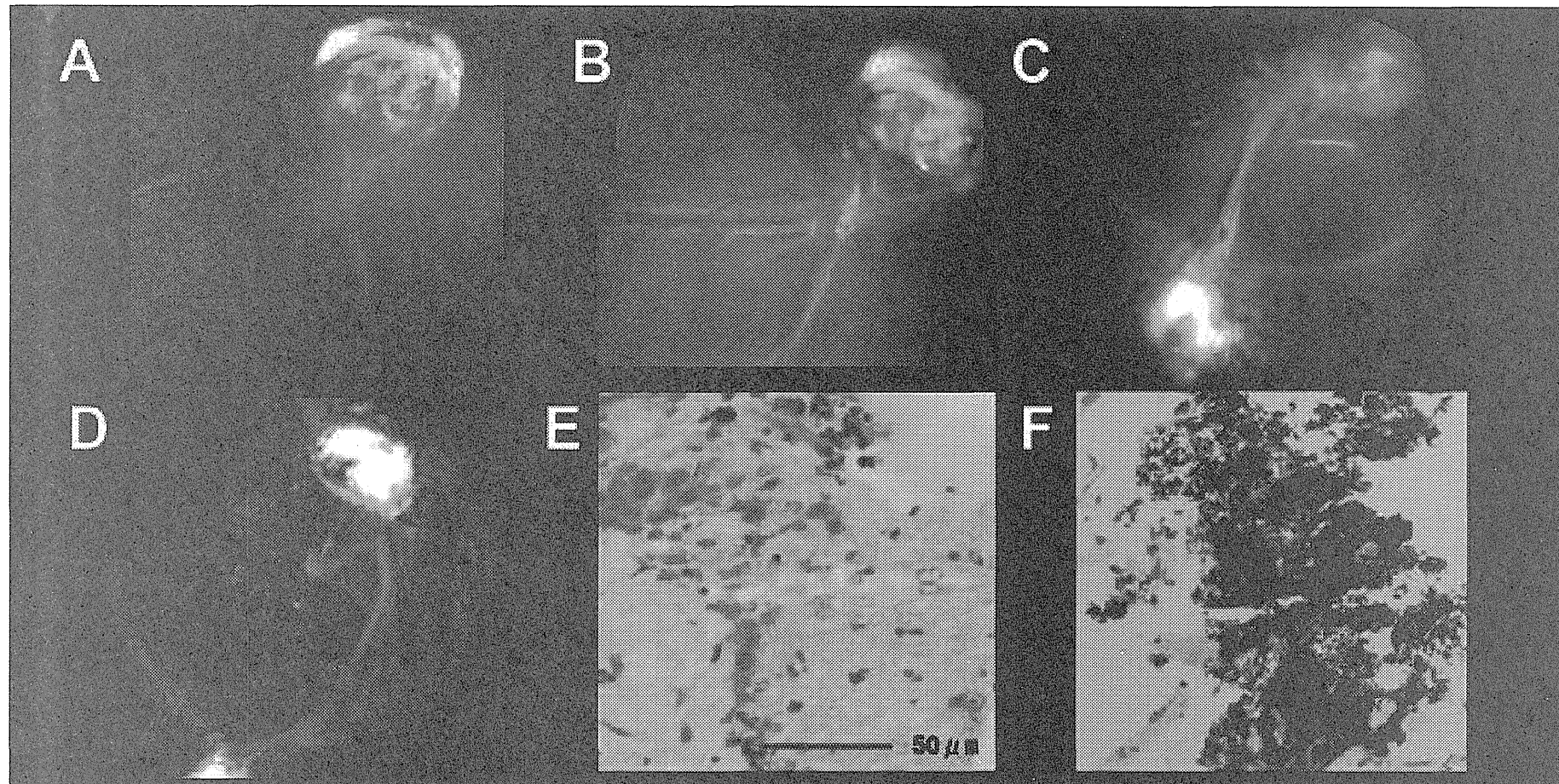
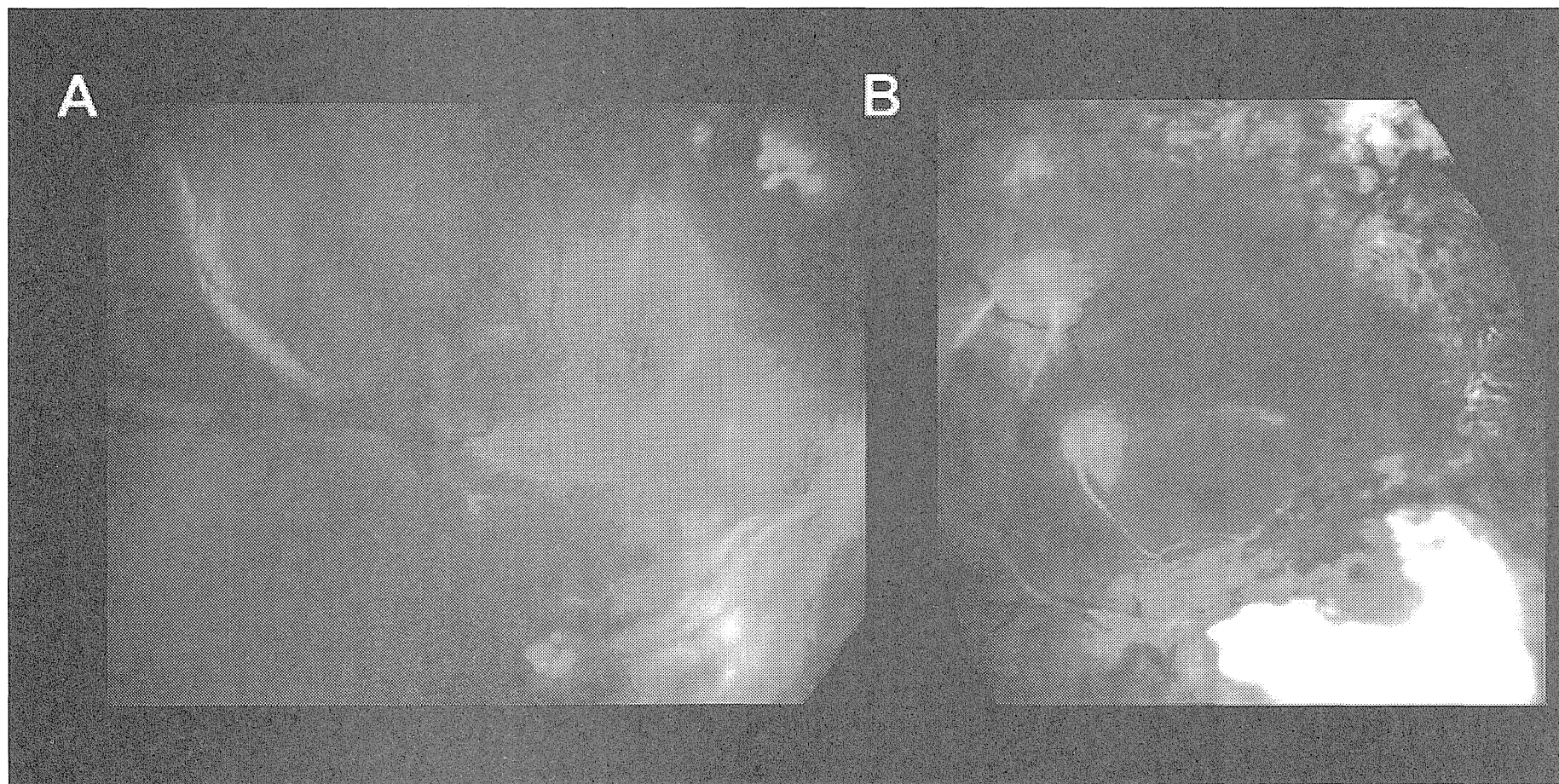


Figure3

[Click here to download high resolution image](#)



RETINAL CASES & BRIEF REPORTS

Authorship Responsibility, Financial Disclosure, and Copyright Transfer

Manuscript Title: (the “Work”) Three cases of rhegmatogenous retinal detachment associated with regressed retinoblastoma after conservative therapy

Corresponding Author: Noriyuki Azuma, MD

Mailing Address and Telephone/Fax Numbers: Department of Ophthalmology, National Center for Health and Development, 2-10-1, Okura, Setagaya-ku, Tokyo 157-8535 Japan.

tel: +81334110111; fax: +81334129811

Each author must read and sign the following statements; if necessary, photocopy this document and distribute to coauthors for their original ink signatures. Completed forms should be signed, scanned, & submitted with your online submission at <http://retinalcases.edmgr.com/>. Your completed form may also be faxed to 610-526-9876.

CONDITIONS OF SUBMISSION

RETAINED RIGHTS: Except for copyright, other proprietary rights related to the Work (e.g., patent or other rights to any process or procedure) shall be retained by the authors. To reproduce any text, figures, tables, or illustrations from this Work in future works of their own, the authors must obtain written permission from Ophthalmic Communications Society, Inc.; such permission will not be unreasonably withheld by Ophthalmic Communications Society, Inc.

ORIGINALITY: Each author warrants that his or her submission to the Work is original and that he or she has full power to enter into this agreement. Neither this Work nor a similar work has been published nor shall be submitted for publication elsewhere while under consideration by this Publication.

AUTHORSHIP RESPONSIBILITY: Each author warrants that he or she has participated sufficiently in the intellectual content, the analysis of data, if applicable, and the writing of the Work to take public responsibility for it. Each has reviewed the final version of the Work, believes it represents valid work, and approves it for publication. Moreover, should the editors of the Publication request the data upon which the work is based, they shall produce it.

DISCLAIMER: Each author warrants that this Work shall not violate any trademark registrations nor the right of privacy of any person, contains no libelous, obscene, or other unlawful matter, and does not infringe upon the statutory or common law copyright or any other right of any person or party. If excerpts (text, figures, tables, or illustrations) from copyrighted works are included, a written release will be secured by the authors prior to submission, and credit to the original publication will be properly acknowledged. Each author further warrants that he or she has obtained, prior to submission, written releases from patients whose names or photographs are submitted as part of the Work. Should Ophthalmic Communications Society, Inc. request copies of such written releases, authors shall provide them to Ophthalmic Communications Society, Inc. in a timely manner.