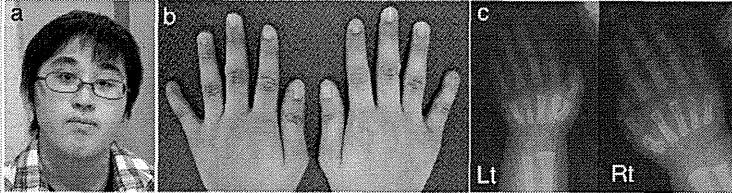
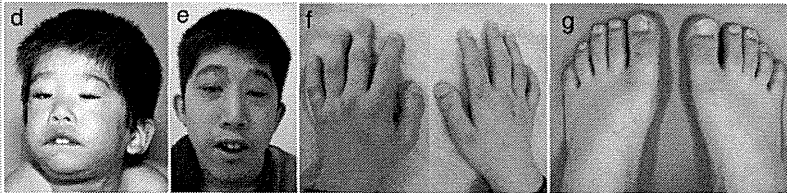


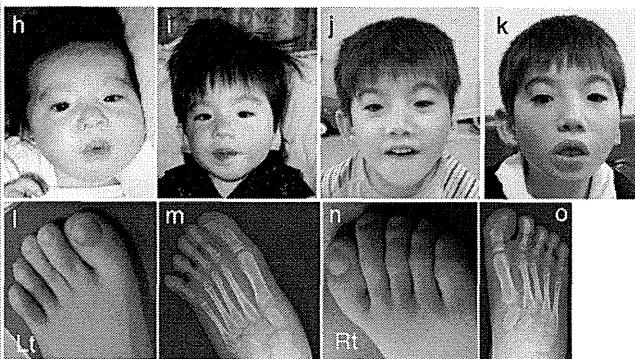
SMARCA4-1



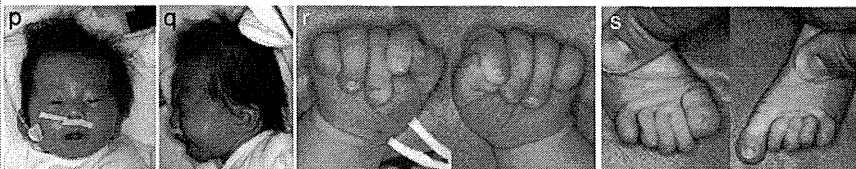SMARCA4-2



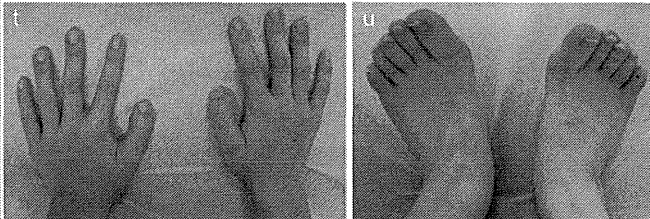
SMARCA4-3



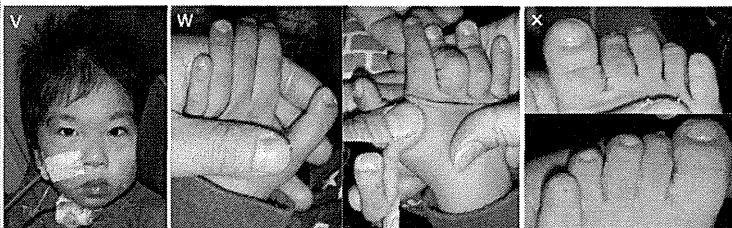
SMARCA4-4



SMARCA4-5



SMARCA4-6



SMARCA2-1

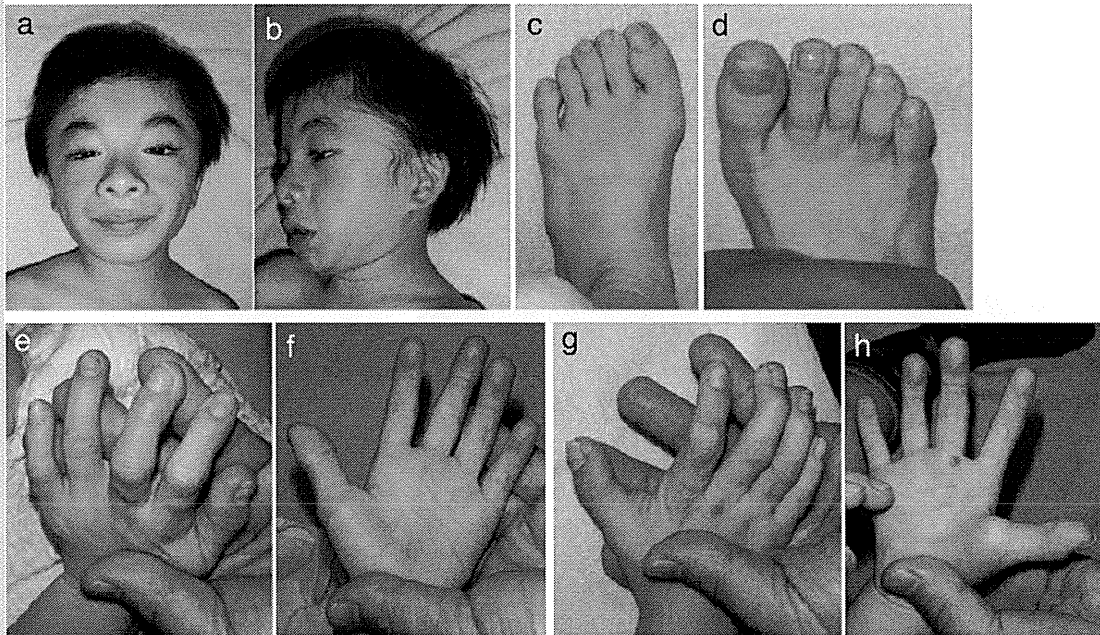


FIG. 3. Clinical photographs of a patient (SMARCA2-1) with an *SMARCA2* mutation. Craniofacial features [a, b], feet [c, d], and hands [e–h] at age 6 6/12 years. Note sparse hair, thick, and arched eyebrows, a broad nasal bridge with anteverted nostrils, a broad philtrum, a wide mouth, and thick upper and lower lip vermilions; and prominent interphalangeal joints and prominent distal phalanges of all fingers and toes without nail hypoplasia. [Figure a, d originally published in Tsurusaki et al. [2012], in *Nature Genetics*.]

7 months, sat alone at 1 3/12 years, and walked independently at 6 years. His developmental quotient (DQ) was 17 at age 5 9/12 years. MRI of the brain at age 6 11/12 years showed hypoplasia of the upper cerebellar vermis and mild hypoplasia of the corpus callosum. At age 9 10/12 years, he weighs 22.1 kg (−1.5 SD), has a height of 114 cm (−3.2 SD), and an OFC of 48 cm (−3.6 SD). He suffers

from unstable body temperature, facial flushing, aerophagia, and intractable constipation. His skeletal problems have included bilateral genu recurvatum with an episode of patella dislocation, bilateral pes valgus, subluxation in the left hip, and Perthes disease-like changes in the right hip. He has autism spectrum disorder with hypersensitivity, hyperactivity, self-injurious behaviors, obsession,

FIG. 2. Clinical photographs of patients with *SMARCA4* mutations. SMARCA4-1: Craniofacial features [a] and hands [b] at age 18 years and hand radiographs [c] at age 5 months. Note a slender face with thick eyebrows, an everted upper lip vermilion, a protruding jaw; hypoplasia of bilateral distal phalanges of the first and fifth fingers, and bilateral hypoplastic fifth fingernails. SMARCA4-2: Craniofacial features at age 2 years [d] and 20 years [e]. Note hypertrichosis, a narrow forehead, blepharophimosis that was corrected surgically, thick and slightly arched eyebrows, long eyelashes, a short and low nose with anteverted nostrils, a short philtrum, an everted upper lip vermilion, and low-set ears in the early childhood; and later a slender face with a long nose and a thick lower lip vermilion. Hands at age 20 years [f]. Note hypoplasia of the distal phalanges and nails of bilateral fingers and prominent interphalangeal joints. Feet at age 20 years [g]. Note prominent distal phalanges of bilateral first toes and hypoplasia of bilateral fifth toes as well as aplasia of bilateral fifth toenails. SMARCA4-3: Craniofacial features at age 4 months [h], 2 2/12 years [i], 5 1/12 months [j], and 9 10/12 years [k]. Note arched eyebrows growing thicker, left ptosis, prominent ears, an everted upper lip vermilion, and a thick lower lip vermilion. Feet at age 9 10/12 years [l–o]. Note prominent distal phalanges of bilateral first toes, hypoplasia of bilateral second-to-fifth toes, hypoplasia of bilateral fourth toenails, and aplasia of bilateral fifth toenails. SMARCA4-4: Craniofacial features [p, q], hands [r], and feet [s] in the neonatal period. Note a round face with thin and arched eyebrows, blepharophimosis, low-set ears, a thin upper lip vermilion, and micro-retrognathia; hypoplasia of bilateral fifth fingers and toes, aplasia of bilateral fifth fingernails and toenails, and hypoplasia of bilateral second-to-fifth fingernails and toenails. SMARCA4-5: Hands [t] and feet [u] at age 8 years. Note hypoplasia of bilateral fifth fingers and toes, hypoplasia of bilateral first and fifth fingernails and second-to-fifth toenails, prominent distal phalanges of bilateral first toes, and prominent interphalangeal joints. SMARCA4-6: Craniofacial features [v], hands [w], and feet [x] at age 3 7/12 years. Note thick and arched eyebrows and small mouths, hypoplasia of bilateral fifth fingers and toes, bilateral all fingernails and bilateral first-to-fourth toenails, aplasia of bilateral fifth toenails, and prominent distal phalanges of bilateral first toes. [Figure k, n, p, r originally published in Tsurusaki et al. [2012], in *Nature Genetics*.]

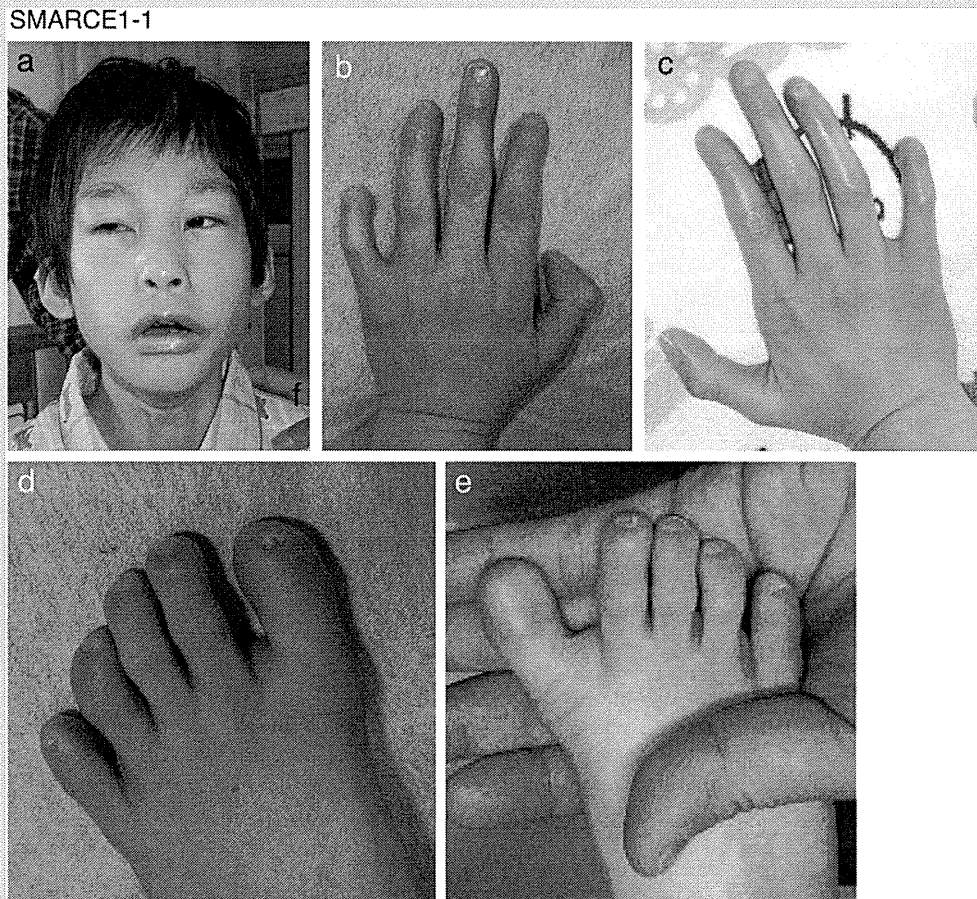


FIG. 4. Clinical photographs of a patient [SMARCE1-1] with an *SMARCE1* mutation. Craniofacial features (a), hands (b, c), and feet (d, e) at age 14 years. Note a slender face with slightly thick eyebrows, a narrow nasal bridge with anteverted nostrils, low-set prominent ears, a long philtrum, an everted upper lip vermilion, and a thick lower lip vermilion; hypoplasia of bilateral second and fifth fingers and bilateral first toes, hypoplasia of all finger/toenails, and aplasia of bilateral fifth fingernails and the right first toenail. [Figure e originally published in Tsurusaki et al. [2012], in *Nature Genetics*.]

and severely retarded language development (developmental age on speech, 6–7 months; comprehension, 10 months).

SMARCA4-4 (Subject 16 [Tsurusaki et al., 2012]; Fig. 2p–s): He was born at 41 weeks of gestation. His birth weight was 2,502 g (–1.7 SD), length was 47 cm (–1.6 SD), and OFC was 33 cm (–0.6 SD). He showed respiratory insufficiency with apnea because of laryngomalacia, which required oxygen supplementation for 15 days. He had sucking/feeding difficulties and was gavage-fed until 7 months of age. He had a small VSD and a small patent ductus arteriosus (PDA): both closed spontaneously. At age 1 4/12 years, he had surgical correction for bilateral inguinal herniae. At age 1 9/12 years, he underwent emergency surgery for a perforated duodenal ulcer. Motor development was severely delayed: he raised his head at age 7–8 months, stood with support at 1 10/12 years, and walked independently at 6 years. At age 11 years, he weighs 22.9 kg (–1.8 SD), has a height of 122.5 cm (–3.1 SD), and an OFC of 49.3 cm (–2.9 SD). He has mild pulmonary regurgitation and

optic disk coloboma with reduced visual acuity (0.3). He experiences constipation and rhinitis, and has difficulty in opening his mouth. He is friendly and understands language, but speaks no words and communicates to others with gestures. Autistic behaviors have not been reported.

SMARCA4-5 (Subject 25 [Tsurusaki et al., 2012]; Fig. 2t, u): She was born at 40 weeks of gestation. Her birth weight was 2,820 g (–1.0 SD), length was 46 cm (–1.9 SD), and OFC was 33.5 cm (+0.1 SD). She suffered from recurrent infections, sucking/feeding difficulties, constipation, visual impairment, and hearing loss in the left ear. She showed hypotonia and motor development was severely delayed: she raised her head at age 8 months, sat alone at 1.5 year, and walked independently at 2 8/12 years. The DQ at age 8 years was 38. MRI of the brain showed hypoplasia of the corpus callosum. At age 16 years, she weighs 39 kg (–1.9 SD), has a height of 148 cm (–1.9 SD), and an OFC of 52 cm (–2.3 SD). She suffers from constipation and scoliosis (which is treated with a brace). She makes

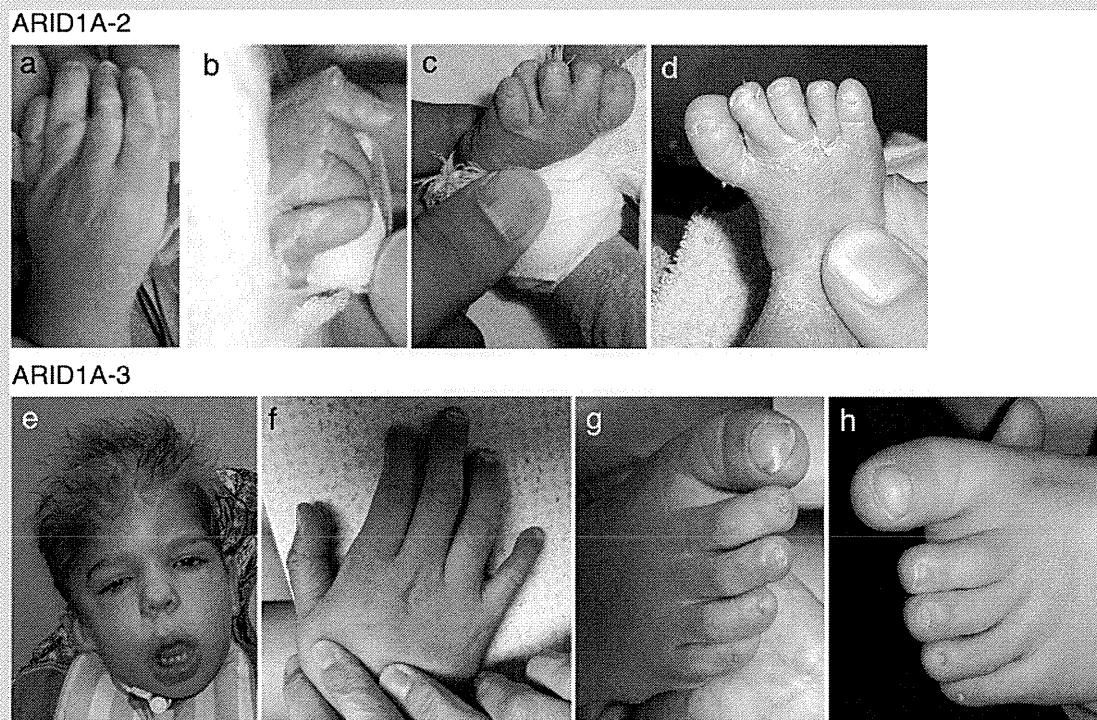


FIG. 5. Clinical photographs of patients with *ARID1A* mutations. *ARID1A-2*: Hands [a, b] and feet [c, d] in the neonatal period. Note hypoplasia of the left fifth finger and the left fifth toe, severe hypoplasia of bilateral fifth fingernails and the left fifth toenail, and mild hypoplasia of the other finger/toenails. *ARID1A-3*: Craniofacial features [e], the right hand [f], and feet [g, h] at age 10 years. Note thick eyebrows, downslanting palpebral fissures, hemifacial microsomia, a long philtrum, thick upper and lower lip vermilions, and a large mouth; hypoplasia of bilateral fifth toes, hypoplasia of all finger/toenails, and prominent distal phalanges of fingers and toes. [Figure e originally published in Tsurusaki et al. [2012], in *Nature Genetics*.]

simple conversations and reads “hiragana” (Japanese cursive characters). She needs a lot of help in her daily life. She shows repetitive behavior (moving her hands) but other autistic behaviors have not been reported.

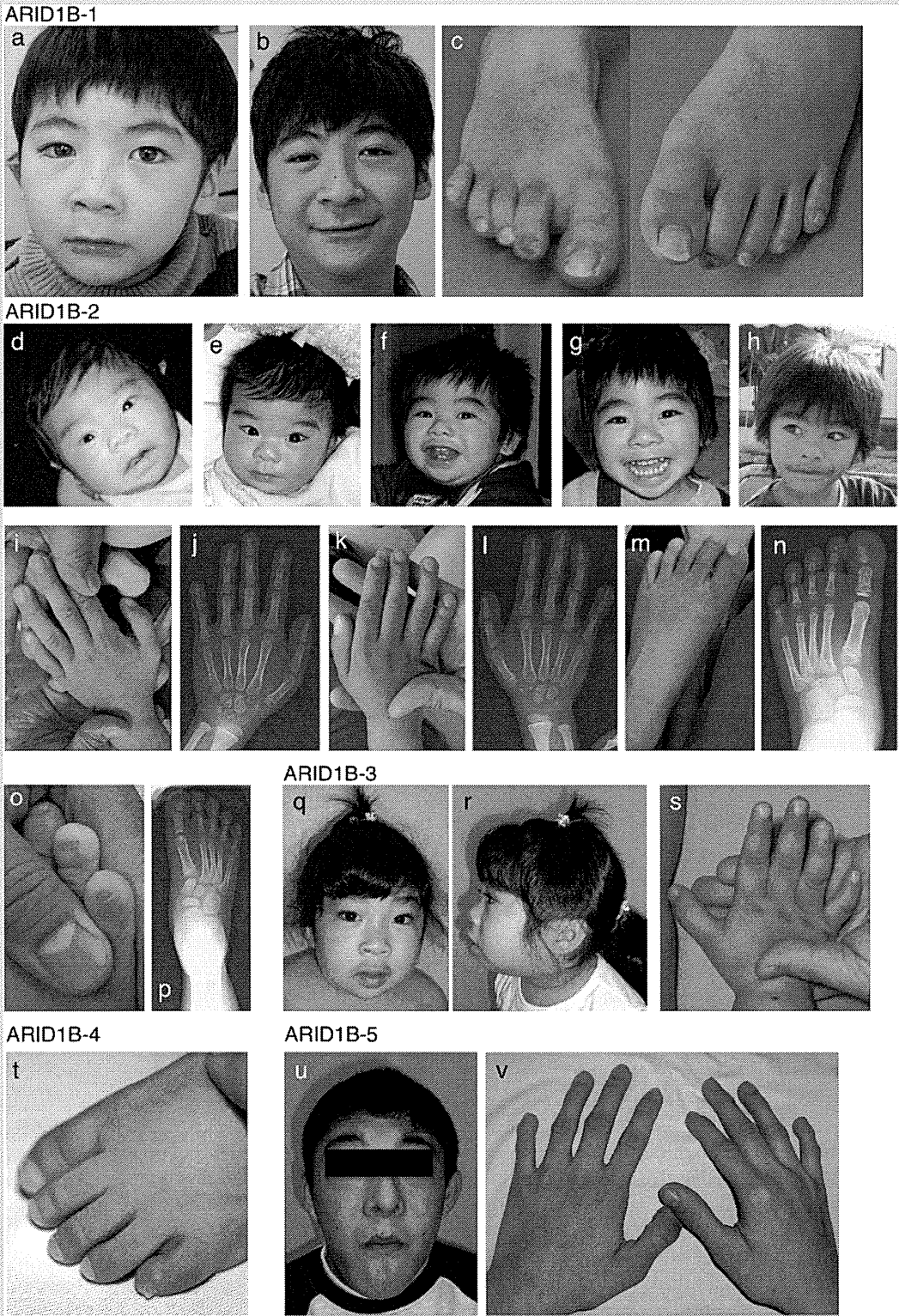
SMARCA4-6 (Subject 17 [Tsurusaki et al., 2012]; Fig. 2v–x): He was born at 41 weeks of gestation. His birth weight was 2,704 g (–1.1 SD), length was 46 cm (–2.3 SD), and OFC was 32 cm (–1.3 SD). He was admitted to hospital for respiratory insufficiency with cyanosis and multiple congenital anomalies (cleft palate, broad thumbs, omphalocele, bilateral cryptorchidism). He had surgical correction of omphalocele at age 1 day. He had complex heart defects, including mitral atresia, pulmonary atresia, a single right ventricle, an atrial septal defect (ASD) and a PDA, and received intravenous administration of prostaglandin E1. He underwent a right Blalock–Taussig shunt at age 1 month, surgical enlargement of the ASD at age 1 1/12 year, a left Blalock–Taussig shunt at age 2 years, a Glenn procedure at age 3 3/12 years, and a Fontan procedure at age 4 6/12 years. He had tracheostomy for hypoxemia caused by bronchomalacia at age 1 8/12 years. He suffered from recurrent infections. His motor development was severely delayed: he raised his head at age 7 months and rolled over at 1 year. MRI of

the brain at age 1 year showed hypoplasia of the corpus callosum. At age 4 9/12 years, he weighs 11.1 kg (–3.0 SD), has a height of 90.6 cm (–3.4 SD), and an OFC of 46.6 cm (–2.7 SD). He underwent laparoscopic fundoplication and gastrostomy for GER. He is unable to sit alone.

SMARCA4-7: She was born at 41 weeks of gestation. Her birth weight was 2,230 g (–2.6 SD), length was 45 cm (–2.7 SD), and OFC was 28 cm (–3.9 SD). She had sucking/feeding difficulties and vomited frequently due to GER. She suffered from recurrent infections. Inguinal and umbilical herniae were corrected surgically. She showed hypotonia and motor development was moderately delayed: she walked independently at age 2 6/12 years. At age 8 years, she weighs 17.4 kg (–1.9 SD), has a height of 115.8 cm (–1.8 SD), and an OFC of 47.5 cm (–3.0 SD). She speaks three-word sentences but cannot read “hiragana.” She is hyperactive.

SMARCA2 Mutation

SMARCA2-1 (Subject 19 [Tsurusaki et al., 2012]; Fig. 3a–h): He was born at 38 weeks of gestation. His birth weight was 1,774 g (–2.6 SD), length was 42 cm (–3.1 SD), and OFC was 32 cm (–0.5 SD).



He had sucking/feeding difficulties. He underwent surgical correction for a left inguinal hernia and cryptorchidism as well as an umbilical hernia at age 4 months; for recurrence of the umbilical hernia at age 2 3/12 years; and for hypospadias at age 3 1/12 years. He developed a complex febrile convulsion at age 1 8/12 years and an afebrile seizure at age 7 years. At age 6 years, renal biopsy for gross hematuria showed immunoglobulin (Ig)A nephropathy that was treated through corticosteroids and tonsillectomy. A radiograph at age 7 years showed scoliosis with a Cobb angle of 38° at Th6–L1 that required a brace. Ventilation tubes were placed for chronic exudative otitis media. He showed hypotonia and motor development was delayed: he raised his head at 4 months, sat alone at 9 months, and walked independently at 3 8/12 years. At age 8 7/12 years, he weighs 16.9 kg (−2.1 SD), has a height of 107.8 cm (−3.8 SD), and an OFC of 47.8 cm (−3.3 SD). He vomits readily if he is in poor physical condition such as infection. He speaks no words. Autistic behaviors have not been reported.

SMARCE1 Mutation

SMARCE1-1 (Subject 24 [Tsurusaki et al., 2012]; Fig. 4a–e): She was born at 37 weeks of gestation. Her birth weight was 1,642 g (−2.3 SD). Mechanical ventilation was required for the first 7 months. She was gavage-fed and underwent gastrostomy at age 10 years. Tricuspid regurgitation, mitral regurgitation, and aortic stenosis were detected and have been treated with diuretics. Seizures occurred in her infancy, and valproic acid and carbamazepine were administered. Cleft palate and progressive scoliosis were corrected surgically. She had hearing impairment that was profound in the right ear and which was moderate (threshold, 50 dB) in the left ear. She suffered from recurrent infections. At age 14 years, she weighs 15.3 kg (−4.4 SD), has a height of 121 cm (−6.8 SD), and an OFC of 45 cm (−6.7 SD). She has to be supported to stand up, but can walk and trot independently (albeit in an ataxic manner) from a standing position. She speaks no words. She can assess her situation simply and can operate a DVD player.

ARID1A Mutations

ARID1A-1 (Subject 3 [Tsurusaki et al., 2012]): Intrauterine growth retardation, enlargement of the third ventricle and posterior fossa,

and a single umbilical artery were detected through fetal ultrasonography. He was born at 39 5/7 weeks of gestation. His birth weight was 2,675 g (−1.0 SD) and length was 47 cm (−1.4 SD). He had coarctation of the aorta, an ASD, and a VSD; the ASD was closed surgically at age 3 months. Congenital pyloric stenosis was corrected surgically at age 12 days, but GER developed. He suffered from sucking/feeding difficulties and frequent infections. MRI of the brain showed agenesis of the corpus callosum and a posterior fossa arachnoid cyst. At age 2 1/12 years, he weighed 3,969 g (−6.2 SD), had a height of 59.6 cm (−8.9 SD), and an OFC of 41.7 cm (−3.7 SD). Hepatoblastoma, noticed at age 1 10/12 years, progressed to death at 2 3/12 years.

ARID1A-2 (Subject 6 [Tsurusaki et al., 2012]; Fig. 5a–d): He was born at 37 weeks of gestation. His birth weight was 2,546 g (−0.6 SD), length was 45 cm (−1.1 SD), and OFC was 36.4 cm (+2.2 SD). He was admitted to the Neonatal Intensive Care Unit (NICU) due to asphyxia, multiple malformations (choanal atresia, cleft palate, hypospadias, and bilateral cryptorchidism) as well as profound hypotonia. Mechanical ventilation was started for respiratory weakness, and tracheostomy carried out at age 9 months. Cardiovascular complications included a VSD, coarctation of the aorta, and stenosis of the aortic valve, which were corrected surgically at age 20 days. A colostomy was placed at age 6 days for anal atresia with retrourethral fistula. Agenesis of the corpus callosum, cerebellar hypoplasia, and a Dandy–Walker malformation were detected. Motor development was severely delayed: he was bedridden with no head control. He suffered from recurrent urinary tract infections. At age 1 year, atrioventricular block occurred with a heart rate of ≈40–50/min, and he died 1 month later. He weighed 3,940 g (−5.5 SD), had a height of 55.0 cm (−8.2 SD), and an OFC of 41.9 cm (−3.1 SD).

ARID1A-3 (Subject 8 [Tsurusaki et al., 2012]; Fig. 5e–h): He is a Caucasian male, born at term after an uncomplicated pregnancy and delivery. His birth weight was 3,350 g. He showed respiratory distress due to laryngomalacia and was admitted to the NICU. MRI of the brain in the neonatal period showed agenesis of the corpus callosum. At age 6 months, he had surgery for an inguinal hernia and intestinal obstruction, and a gastrostomy was undertaken due to sucking/feeding difficulties and GER. A large ASD closed spontaneously before the age of 3 years. Bilateral strabismus repair was carried out at age 1 year. He had mild hearing impairment in the

FIG. 6. Clinical photographs of patients with *ARID1B* mutations. *ARID1B-1*: Craniofacial features at age 5 years (a) and 13 years (b). Note thick and arched eyebrows, a broad nasal bridge, a broad philtrum, and a thin upper lip vermilion. Feet at age 13 years (c). Note hypoplasia of the right fifth toe, hypoplasia of the right fifth toenail and the left fourth and fifth toenails, and prominent distal phalanges of bilateral first toes. *ARID1B-2*: Craniofacial features in the neonatal period (d), at age 5 months (e), 1 3/12 years (f), 3 4/12 years (g), and 6 8/12 years (h). Note thick eyebrows, a broad nasal bridge with anteverted nostrils, a broad philtrum, a thin upper lip vermilion, and change in facial shape from round to slender. Hands (i, left; k, right) with the radiographs (j, left; l, right) and feet (m, left; o, right) with the radiographs (n, left; p, right) at age 6 9/12 years. Note hypoplasia of bilateral fifth toes and toenails and prominent distal joints in bilateral second-to-fifth fingers and the left first toes. *ARID1B-3*: Craniofacial features (q, r) and the right hand (s) at age 4 5/12 years. Note a round face with thick eyebrows, a broad nasal bridge, a long philtrum, a thick lower lip vermilion, a small mouth, and micro-retrognathia; and hypoplasia of the fifth finger with mild hypoplasia of the fifth fingernail. *ARID1B-4*: The left foot (t) at age 6 months. Note hypoplasia of the fifth toe and the toenail. *ARID1B-5*: Craniofacial features (u) and hands (v) at age 19 years. Note a slender face with thick and arched eyebrows, a narrow nasal bridge, a long philtrum, and a protruding jaw; hypoplasia of bilateral fifth fingers and fingernails, prominent interphalangeal joints of all fingers, and prominent distal phalanges of bilateral first and fifth fingers. [Figure b and o originally published in Tsurusaki et al. [2012], in *Nature Genetics*.]

right ear. He was hospitalized twice for respiratory distress triggered by infections, which required placement of a tracheostomy tube at age 1 year. He had three surgical procedures for thoracolumbar kyphoscoliosis. Motor development was severely delayed: he sat at 9 months, pulled up to a stand at 2 6/12 years, crawled at 4 years, and walked with assistance from age 4 years. At age 10 years, he weighs 31.5 kg (50th percentile), has a height of 122 cm (3rd percentile), and an OFC of 52.5 cm (50th percentile). He speaks no words and is not toilet trained. He has hyperactivities.

ARID1B Mutations

ARID1B-1 (Subject 1 [Tsurusaki et al., 2012]; Fig. 6a–c): He was born at 39 weeks of gestation after an uncomplicated prenatal period. His birth weight was 2,760 g (−0.9 SD), length was 50 cm (+0.4 SD), and OFC was 34 cm (+0.3 SD). He had sucking/feeding difficulties and vomited frequently, resulting in failure to thrive. His feeding improved after 3 years of age. He suffered from atopic dermatitis and recurrent infections. He showed hypotonia and motor development was moderately delayed: he raised his head at age 6 months, sat alone at 1 year, and walked independently at 2 9/12 years. MRI of the brain at age 7 years showed hypoplasia of the corpus callosum. At age 13 years, he weighs 44 kg (−0.5 SD), has a height of 150 cm (−1.4 SD), and an OFC of 55 cm (+0.7 SD). Pes planus has become evident. He has difficulty in fine finger movement. He speaks no words but can write “kanji” (Chinese characters) and communicate in writing. He can also summate two-digit numbers. He has autism spectrum disorder with hyperactivity, impulsiveness, and an obsession with trains. He has normal secondary sexual characteristics and no susceptibility to infection.

ARID1B-2 (Subject 15 [Tsurusaki et al., 2012]; Fig. 6d–p): He was born at 40 weeks of gestation after an uncomplicated prenatal period. His birth weight was 2,620 g (−1.2 SD), length was 47.5 cm (−1.2 SD), and OFC was 32.0 cm (−1.1 SD). He had sucking/feeding difficulties. He showed hypotonia and motor development was delayed: he raised his head at 3–4 months, rolled over at 4–5 months, sat alone at 1 2/12 years, and walked independently at 2 10/12 years. MRI of the brain at age 2 years did not show abnormalities. He had three episodes of febrile seizures. He suffered from frequent upper respiratory infections with vomiting from age 5 years when his younger sister entered a nursery. He was suspected to have an autism spectrum disorder at age 3 years, and received risperidone for impulsiveness from age 6 years. At age 7 9/12 years, he weighs 20.4 kg (−1.1 SD), has a height of 118 cm (−1.1 SD), and an OFC of 50.3 cm (−1.4 SD). Though he speaks only “Ah, oh” in simple voices without meaningful words, he understands what he needs to do in his daily life and what his parents say, indicates what he wants, and answers yes–no questions by changing the tone of his voice. He is defiant, but seems to have become less autistic: he likes others, reads other people’s faces, and settles quarrels. He becomes exhausted easily.

ARID1B-3 (Subject 23 [Tsurusaki et al., 2012]; Fig. 6q–s): Ventricular enlargement and a sacral cystic lesion were observed on fetal ultrasonography at 28 weeks of gestation. She was born at 38 weeks of gestation. Her birth weight was 2,966 g (+0.5 SD), length was 44.5 cm (−1.7 SD), and OFC was 33.8 cm (+0.4 SD). She had a deep sacral dimple without a neurological deficit. Oxygen

was administered to treat transient tachypnea of the newborn, followed by inspiratory stridor caused by laryngomalacia. In infancy, she had sucking/feeding difficulties that resulted in failure to thrive. Obesity started at age 3 years. Obstructive apnea associated with hypertrophic tonsils and adenoids as well as allergic rhinitis developed, and was treated with medication. At age 4 years, intermittent exotropia and mild scoliosis with a Cobb angle of 2.5° at Th11–L3 were noted. MRI of the brain at age 5 years showed agenesis of the corpus callosum and colpocephaly. She showed hypotonia and motor development was delayed: she raised her head at age 7 months, sat alone at 1 year, walked independently at 2 8/12 years, and spoke one word after 2 years of age. The DQ at age 5 6/12 years was 36. She suffered from recurrent infections. At age 10 years, she weighs 40.9 kg (+1.5 SD), has a height of 128.3 cm (−1.3 SD), and an OFC of 56.2 cm (+1.8 SD). She practices reading, writing, and arithmetic, but is not good at speaking in public. She has difficulty in moving her left hand quickly compared with her right hand.

ARID1B-4 (Subject 10 [Tsurusaki et al., 2012]; Fig. 6t): He was born at 39 weeks of gestation. His birth weight was 2,730 g (−1.0 SD), length was 47 cm (−1.1 SD), and OFC was 34 cm (+0.3 SD). He had right cryptorchidism. He received thyroid hormone replacement for congenital hypothyroidism. He had sucking/feeding difficulties. He showed hypotonia and motor development was moderately delayed: he raised his head at age 7 months, sat alone at 1 6/12 years, and walked independently at 2 1/12 months. The DQ at age 6 years was 47. He suffered from occasional vomiting attacks. At age 11 years, he weighs 30 kg (−0.5 SD), has a height of 124 cm (−2.4 SD), and an OFC of 51 cm (−1.1 SD). Scoliosis has appeared. He can ride a bicycle and swim several meters. He tells his mother what happens at school, reads kanji (which children at his age learn), and likes proverbs. He can do arithmetic at a level comparable to that seen in the lower grade of an elementary school. Behavioral abnormalities have not been reported.

ARID1B-5 (Subject 12 [Tsurusaki et al., 2012]; Fig. 6u, v): He was born at 41 weeks of gestation. His birth weight was 2,264 g (−2.3 SD) and length was 43 cm (−3.7 SD). Motor development was moderately delayed: he walked by holding onto something at 2 years, and spoke only “no” at age 6 years. He had complex partial seizures at age 7 years. Scoliosis appeared and an infectious tumor at the sacral region was resected. He suffered from recurrent infections, gastric ulcers, and reflux esophagitis. At age 19 years, his weight is 40.7 kg (−2.3 SD) and height is 136 cm (−6.1 SD). He has mild mitral regurgitation. He walks independently and goes upstairs without support, but has severe ID and cannot speak meaningful words. He is irritable and hyperactive.

DISCUSSION

We have provided the clinical information of 21 patients with mutations in the components of the SWI/SNF complex. These patients were recruited with a clinical diagnosis of CSS, and 20 of them (except SMARCA4-7) were included in our previous study [Tsurusaki et al., 2012]. Combined with previous and recently published articles [Nagamani et al., 2009; Halgren et al., 2012; Hoyer et al., 2012; Michelson et al., 2012; Santen et al., 2012; van Houdt et al., 2012], *SMARCB1* mutations have been identified in

four patients, *SMARCA4* mutations in seven, *SMARCA2* mutations in 37, *SMARCE1* mutation in one, *ARID1A* mutations in three, and *ARID1B* mutations in 33 (Tables Ia–Ic). The mutations occurred de novo in all the patients whose parental samples were available.

The *SMARCB1* mutation “p.Lys364del.” the only recurrent mutation in our series, has been found in three patients with strikingly similar manifestations. They all showed severe ID without speaking words, had typical coarse facial features (in early childhood: round face with thick and arched eyebrows, short nose with bulbous tip and anteverted nostrils, long philtrum, small mouth, and micro-retrognathia; later: broad nasal bridge without anteverted nostrils, broad philtrum, large tongue, and protruding jaw), significant hypoplasia of fifth fingers/toes and nail hypoplasia of fifth and other fingers/toes, sucking/feeding difficulties, and postnatal growth retardation. However, congenital malformations of internal organs were mild. The mutation “p.Lys364del” as well as the other missense mutation is supposed to exert dominant-negative or gain-of-function effects (excluding haploinsufficiency as a cause) [Tsurusaki et al., 2012].

Patients with *SMARCA4* mutations showed a wide range of ID and speech impairment. One patient with mild ID and one patient with moderate ID both had mild speech delay. In those with severe ID, one patient could speak several words and one patient could have a simple conversation. Autistic features/behavioral abnormalities including hyperactivity were observed in 4/5 (80%). Facial coarseness was minimal and everted upper lip vermilion with a short philtrum was characteristic in 4/7 (57%). Hypoplasia of fifth fingers/toes and nail hypoplasia of fifth and other fingers/toes were significant. Although sucking/feeding difficulties were noted in 6/7 (86%), postnatal growth was delayed in 4/7 (57%). One 3-bp in-frame deletion and six missense mutations identified in each patient could exert dominant-negative or gain-of-function effects [Tsurusaki et al., 2012].

Since heterozygous *SMARCA2* mutations in NCBRS were reported [van Houdt et al., 2012] after the submission of our previous work [Tsurusaki et al., 2012], the physical features of *SMARCA2*-1 (Subject 19 [Tsurusaki et al., 2012]) have been reassessed, and NCBRS is indeed appropriate as the clinical diagnosis. *SMARCA2*-1 had the main clinical features of NCBRS [Sousa et al., 2009]: prenatal growth retardation (29%), postnatal growth retardation (53%), moderate developmental delay (25%) with absent speech, seizures (63%), microcephaly (54%), sparse hair (97%), thick and anteverted alai nasi (89%), a broad philtrum (86%), a large mouth (94%), a thick lower lip vermilion (89%), prominent interphalangeal joints (80%), and prominent distal phalanges (60%; % values in parentheses indicate frequencies in *SMARCA2*-positive NCBRS patients [van Houdt et al., 2012]). Furthermore, hypoplastic fifth fingers/toes or fingernails/toenails have not been noted. van Houdt et al. [2012] speculated that the *SMARCA2* mutations identified in NCBRS patients would act in a dominant-negative or gain-of-function manner because of: the lack of NCBRS phenotypes in the 9p distal monosomy syndrome with deletions encompassing *SMARCA2*; absent major developmental abnormalities in mice lacking functional *Smarca2*; the lack of truncating *SMARCA2* mutations found in their series. *SMARCA2*-1 has a 55-kb intragenic deletion of *SMARCA2* resulting in the skipping of exons 20–27 [Tsurusaki et al., 2012], which

overlaps the mutation-clustering region (exons 15–25) of *SMARCA2* found in NCBRS patients. Furthermore, the deletion of exons 20–27 results in in-frame deletion, which was confirmed by reverse transcription-polymerase chain reaction of the patient’s lymphoblastoid cells (data not shown). Thus, abnormal *SMARCA2* in this patient lacking one part of the DNA-dependent ATPase domain is suggested to cause abnormal functions.

SMARCE1-1, the only one with an *SMARCE1* mutation, showed severe ID without speaking words and significant hypoplasia of fifth fingers/toes and nail hypoplasia of fifth and other fingers/toes, whereas facial appearances were not typically coarse. Evaluation of more patients with *SMARCE1* mutations would be necessary to ascertain whether and how *SMARCE1* mutations can cause CSS-related phenotypes.

ARID1A mutations were associated with the severest phenotypes. All three patients showed severe ID without speaking words. They had severe physical complications requiring intensive treatment and surgery and which lead to early deaths in two subjects. Considering that the mutations included one frameshift mutation and two nonsense mutations, the haploinsufficiency of *ARID1A* would cause these phenotypes. The mutated transcripts from one of the nonsense mutations (p.Gln920*) were found to be subject to nonsense-mediated decay (NMD) [Tsurusaki et al., 2012].

ARID1B mutations have been associated with CSS in 11 patients [Santen et al., 2012; Tsurusaki et al., 2012] and syndromic ID in 22 [Nagamani et al., 2009; Halgren et al., 2012; Hoyer et al., 2012; Michelson et al., 2012]. Developmental delay/ID was severe in 12/25 (48%), moderate in 11/25 (44%), and mild in 2/25 (8%). Speech impairment was profound (no words) in 14/31 (45%), severe (several words) in 11/31 (35%), moderate (sentences) in 4/31 (13%), and mild in 2/31 (6%). Ten patients were reported to have autistic features/behavioral abnormalities including hyperactivity and impulsiveness. Agenesis or hypoplasia of the corpus callosum with or without colpocephaly was detected in 13/24 (54%). Facial coarseness was not significant and thin upper lip vermilion with a long or broad philtrum was characteristic. Hypoplasia of fifth digits/nails was mild or limited to toes or fingers. Although sucking/feeding difficulties were noted frequently (4/5 in our series), postnatal growth was delayed in 13/31 (42%). Considering that the mutations included seven nonsense mutations, seven frameshift mutations, 17 deletions (0.2–14.5 Mb), one translocation and one duplication of exons 4 and 5, the haploinsufficiency of *ARID1B* would cause the phenotypes. The mutated transcripts forming the mutations in *ARID1B*-1 (Subject 1 [Tsurusaki et al., 2012]; p.Ile560Glyfs*89) and *ARID1B*-3 (Subject 23 [Tsurusaki et al., 2012]; p.Arg1102*) were found to be subject to NMD, whereas the transcript from the mutated allele in *ARID1B*-4 (Subject 10 [Tsurusaki et al., 2012]; p.Asp1878Metfs*96), creating a premature stop codon in the last exon, escaped from NMD [Tsurusaki et al., 2012].

The most phenotypically similar condition to CSS is NCBRS [Schrier et al., 2012] and vice versa [Sousa et al., 2009]. Exome sequencing has proved the mutations in the genes comprising the SWI/SNF complex: *SMARCB1*, *SMARCA4*, *SMARCE1*, *ARID1A*, and *ARID1B* in CSS [Santen et al., 2012; Tsurusaki et al., 2012]; *SMARCA2* in NCBRS [Tsurusaki et al., 2012; van Houdt et al., 2012]. Interestingly, prominent interphalangeal joints and

prominent distal phalanges (i.e., the main features distinguishing NBS from CSS) were observed in a considerable number of patients (especially in older ones) in our series: prominent interphalangeal joints in 1/3 patients (21 years old) with an *SMARCB1* mutation, in 2/7 (16, 20 years) with *SMARCA4* mutations, in 2/5 (11, 19 years) with *ARID1B* mutations; prominent distal phalanges in 2/3 (7, 21 years) with an *SMARCB1* mutation, in 5/7 (4, 9, 11, 16, 20 years) with *SMARCA4* mutations, in 1/3 (10 years) with an *ARID1A* mutation, in 3/5 (7, 11, 13 years) with *ARID1B* mutations. Furthermore, array-based screening of patients with syndromic ID has demonstrated that *ARID1B* would be an important causative gene [Nagamani et al., 2009; Halgren et al., 2012; Hoyer et al., 2012; Michelson et al., 2012]. Clinical information about facial and digital features in those with *ARID1B*-related syndromic ID is limited, so whether they show the CSS phenotype is not known. With regard to patients with mutations in the components of the SWI/SNF complex in general, developmental delay/ID was a cardinal feature: severe in 49/77 (64%), moderate in 22/77 (29%), and mild in 6/77 (8%). Speech impairment was also observed in all subjects and was usually more severe than intellectual status: no words in 39/60 (65%), severe (several words) in 12/60 (20%), moderate (sentences, simple conversation) in 5/60 (8%), and mild in 4/60 (7%). Agenesis or hypoplasia of the corpus callosum was common (noted in 19/32 (59%)). Hypoplastic/absent fifth finger/toe as well as hypoplastic/absent fifth fingernail/toenail, which have been heavily emphasized in previous clinical descriptions of patients with CSS, are still considered to be physical hallmarks, observed in all but *SMARCA2* (Subject 19 [Tsurusaki et al., 2012]) in our series. Careful clinical investigation including observation of toes and toenails is crucial to detect these patients, because some of them do not have hypoplastic fifth finger(nail) but only have hypoplastic fifth toe(nail).

In conclusion, mutations in the components of the SWI/SNF complex are associated with syndromic developmental delay/ID that predominantly affect speech, and which are frequently accompanied by agenesis or hypoplasia of the corpus callosum. Mutations in *SMARCB1* can cause “classical” CSS with typical facial coarseness, significant digital/nail hypoplasia, severe ID impairment, and profound speech impairment. Mutations in *SMARCA4* can cause CSS without typical facial coarseness and with significant digital/nail hypoplasia and variable severities of ID and speech impairment. Mutations in *SMARCA2* can cause NBS. Mutations in *SMARCE1* can cause CSS without typical facial coarseness and with significant digital/nail hypoplasia, severe ID impairment, and profound speech impairment. Mutations in *ARID1A* can cause the severest type of CSS, with severe ID impairment, profound speech impairment, and serious physical complications. Mutations in *ARID1B* can cause CSS without typical facial coarseness and with mild digital/nail hypoplasia, variable severities of ID impairment, and speech impairment or cause syndromic ID. Considering practical clinical approaches such as rehabilitation focusing on communicative skills besides speech and future gene-based treatment [Gray, 2013], pathway-based “lumping” of these conditions “SWI/SNF-related ID syndromes” might be useful, whereas feature-based “splitting” is surely important in more careful management of patients with each condition. Exome sequencing could be a powerful tool to establish such a reclassification of disorders by uniting

independently observed (but clinically similar) conditions such as oral-facial-digital syndrome type 1, Simpson–Golabi–Behmel syndrome, type 2, and Joubert syndrome-10 [Tsurusaki et al., 2013].

ACKNOWLEDGMENTS

We are grateful to all the patients and their families who participated in this study. We are also thankful to Professor Hennekam (Academic Medical Center, University of Amsterdam, Amsterdam, the Netherlands) for clinical assessment of *SMARCA2-1* and meaningful suggestions. This work was supported by Research Grants from the Ministry of Health, Labour and Welfare (T.K., N.O., H.O., H.S., N.M., and N.M.); the Japan Science and Technology Agency (N.M.); the Strategic Research Program for Brain Sciences (N.M.); a Grant-in-Aid for Scientific Research on Innovative Areas (Transcription cycle) from the Ministry of Education, Culture, Sports, Science and Technology of Japan (N.M.); a Grant-in-Aid for Scientific Research from the Japan Society for the Promotion of Science (N.M.); a Grant-in-Aid for Young Scientists from the Japan Society for the Promotion of Science (H.S. and N.M.); a Grant for 2011 Strategic Research Promotion of Yokohama City University (N.M.); and Research Grants from the Japan Epilepsy Research Foundation (H.S.) and the Takeda Science Foundation (N.M. and N.M.).

REFERENCES

- Coffin GS, Siris E. 1970. Mental retardation with absent fifth fingernail and terminal phalanx. *Am J Dis Child* 119:433–439.
- Devy P, Baraitser M. 1991. Coffin–Siris syndrome. *J Med Genet* 28:338–341.
- Fleck BJ, Pandya A, Vanner L, Kerkerling K, Bodurtha J. 2001. Coffin–Siris syndrome: Review and presentation of new cases from a questionnaire study. *Am J Med Genet* 68:136–142.
- Gray SJ. 2013. Gene therapy and neurodevelopmental disorders. *Neuropharmacology* 99:1–7.
- Halgren K, Kjaergaard S, Bak M, Hansen C, El-Schich Z, Anderson C, Henriksen K, Hjalgrim H, Kirchhoff M, Bijlsma E, Nielsen M, den Hollander N, Ruivenkamp C, Isidor B, Le Caignec C, Zannolli R, Mucciolo M, Renieri A, Mari F, Anderlid BM, Andrieux J, Dieux A, Tommerup N, Bache I. 2012. Corpus callosum abnormalities, intellectual disability, speech impairment, and autism in patients with haploinsufficiency of *ARID1B*. *Clin Genet* 82:248–255.
- Hoyer J, Ekici AB, Ende S, Popp B, Zweier C, Wiesener A, Wohlleber E, Dufke A, Rossier E, Petsch C, Zweier M, Göhring I, Zink AM, Rappold G, Schröck E, Wieczorek D, Riess O, Engels H, Rauch A, Reis A. 2012. Haploinsufficiency of *ARID1B*, a member of the SWI/SNF-a chromatin-remodeling complex, is a frequent cause of intellectual disability. *Am J Hum Genet* 90:565–572.
- Michelson M, Ben-Sasson A, Vinkler C, Leshinsky-Silver E, Netzer I, Frumkin A, Kivity S, Lerman-Sagie T, Lev D. 2012. Delineation of the interstitial 6q25 microdeletion syndrome: Refinement of the critical causative region. *Am J Med Genet Part A* 158A:1395–1399.
- Nagamani SC, Erez A, Eng C, Ou Z, Chinault C, Workman L, Coldwell J, Stankiewicz P, Patel A, Lupski JR, Cheung SW. 2009. Interstitial deletion of 6q25.2–q25.3: A novel microdeletion syndrome associated with microcephaly, developmental delay, dysmorphic features and hearing loss. *Eur J Hum Genet* 17:573–581.

- Nicolaides P, Baraitser M. 1993. An unusual syndrome with mental retardation and sparse hair. *Clin Dysmorphol* 2:360–364.
- Santen GW, Aten E, Sun Y, Almomani R, Gilissen C, Nielsen M, Kant SG, Snoeck IN, Peeters EA, Hilhorst-Hofstee Y, Wessels MW, den Hollander NS, Ruivenkamp CA, van Ommen GJ, Breuning MH, den Dunnen JT, van Haeringen A, Kriek M. 2012. Mutations in SWI/SNF chromatin remodeling complex gene *ARID1B* cause Coffin–Siris syndrome. *Nat Genet* 44:379–380.
- Schrier SA, Bodurtha JN, Burton B, Chudley AE, Chiong MA, D’avanzo MG, Lynch SA, Musio A, Nyazov DM, Sanchez-Lara PA, Shalev SA, Deardorff MA. 2012. The Coffin–Siris syndrome: A proposed diagnostic approach and assessment of 15 overlapping cases. *Am J Med Genet Part A* 158A:1865–1876.
- Sousa SB, Abdul-Rahman OA, Bottani A, Cormier-Daire V, Fryer A, Gillessen-Kaesbach G, Horn D, Josifova D, Kuechler A, Lees M, MacDermot K, Magee A, Morice-Picard F, Rosser E, Sarkar A, Shannon N, Stolte-Dijkstra I, Verloes A, Wakeling E, Wilson L, Hennekam RC. 2009. Nicolaides–Baraitser syndrome: Delineation of the phenotype. *Am J Med Genet Part A* 149A:1628–1640.
- Tsurusaki Y, Okamoto N, Ohashi H, Kosho T, Imai Y, Hibi-Ko Y, Kaname T, Naritomi K, Kawame H, Wakui K, Fukushima Y, Homma T, Kato M, Hiraki Y, Yamagata T, Yano S, Mizuno S, Sakazume S, Ishii T, Nagai T, Shiina M, Ogata K, Ohta T, Niikawa N, Miyatake S, Okada I, Mizuguchi T, Doi H, Saitsu H, Miyake N, Matsumoto N. 2012. Mutations affecting components of the SWI/SNF complex cause Coffin–Siris syndrome. *Nat Genet* 44:376–378.
- Tsurusaki Y, Kosho T, Hatasaki K, Narumi Y, Wakui K, Fukushima Y, Doi H, Saitsu H, Miyake N, Matsumoto N. 2013. Exome sequencing in a family with an X-linked lethal malformation syndrome: Clinical consequences of hemizygous truncating OFD1 mutations in male patients. *Clin Genet* 83:135–144.
- van Houdt JK, Nowakowska BA, Sousa SB, van Schaik BD, Seuntjens E, Avonce N, Sifrim A, Abdul-Rahman OA, van den Boogaard MJ, Bottani A, Castori M, Cormier-Daire V, Deardorff MA, Filges I, Fryer A, Fryns JP, Gana S, Garavelli L, Gillessen-Kaesbach G, Hall BD, Horn D, Huylebroeck D, Klapecki J, Krajewska-Walasek M, Kuechler A, Lines MA, Maas S, Macdermot KD, McKee S, Magee A, de Man SA, Moreau Y, Morice-Picard F, Obersztyn E, Pilch J, Rosser E, Shannon N, Stolte-Dijkstra I, van Dijck P, Vilain C, Vogels A, Wakeling E, Wieczorek D, Wilson L, Zuffardi O, van Kampen AH, Devriendt K, Hennekam R, Vermeesch JR. 2012. Heterozygous missense mutations in *SMARCA2* cause Nicolaides–Baraitser syndrome. *Nat Genet* 44:445–449.