

Omori Y, Araki F, Chaya T, Kajimura N, Irie S, Terada K, Muranishi Y, Tsujii T, Ueno S, Koyasu T, Tamaki Y, Kondo M, Amano S, Furukawa T	Presynaptic dystroglycan-pikachurin complex regulates the proper synaptic connection between retinal photoreceptor and bipolar cells.	J Neurosci.	32	6126-6137	2012
Hosono K, Ishigami C, Takahashi M, Park DH, Hiramami Y, Nakanishi H, Ueno S, Yokoi T, Hikoya A, Fujita T, Zhao Y, Nishina S, Shin JP, Kim IT, Yamamoto S, Azuma N, Terasaki H, Sato M, Kondo M, Minoshima S, Hotta Y	Two novel mutations in the EYE gene are possible major causes of autosomal recessive retinitis pigmentosa in the Japanese population	PLos One.	7	e31036	2012
Hirota R, <u>Kondo M</u> , Ueno S, Sakai T, Koyasu T, Terasaki H:	Photoreceptor and post-photoreceptoral contributions to photopic ERG a-wave in rhodopsin P347L transgenic rabbits.	Invest Ophthalmol Vis Sci.	53(3)	1467-1472	2012
Nojima K, Hosono K, Zhao Y, Toshiba T, Hikoya A, Kato M, <u>Kondo M</u> , Minoshima S, Hotta Y:	Clinical features of a Japanese case with Bothnia dystrophy.	Ophthalmic Genet.	33(2)	83-88	2012
Hood DC, Bach M, Brigell M, Keating D, <u>Kondo M</u> , Lyons JS, Marmor MF, McCulloch DL, Palmowski-Wolfe AM	International Society For Clinical Electrophysiology of Vision	ISCEV standard for clinical multifocal electroretinography (mfERG) (2011 edition). Doc Ophthalmol.	124(1)	1-13	2012
Kleinman ME, Kaneko H, Cho WG, Dridi S, Fowler BJ, Blandford AD, Albuquerque RJ, Hirano Y, Terasaki H, <u>Kondo M</u> , Fujita T, Ambati BK, Tarallo V, Gelfand BD, Bogdanovich S, Baffi JZ, Ambati J	Short-interfering RNAa induce retinal degeneration via TLR3 and IRF3	Mol Ther.	20(1)	101-108	2012

Nakaseko Y, Kamatani M, <u>Kondo M</u> , Uji Y, Sugimoto M	Complications Following Inappropriate Intravitreal Triamcinolone Acetonide Injection.	Case Reports in Ophthalmological Medicine.			2012
<u>近藤峰生</u>	黄斑ジストロフィの診断	日本の眼科	83	12-19	2012
安田千映子、 <u>近藤峰生</u> 、上野真治、吉田茂生、石橋達朗、寺崎浩子	卵黄状黄斑ジストロフィに伴う脈絡膜新生血管に対しベバシズマブ硝子体内注射を施行した1例.	臨床眼科	66(7)	1063-1067	2012
水川憲一、 <u>近藤峰生</u> 、春石和子、後藤克聡、桐生純一	完全型先天停在性夜盲の経過中に dome-shaped macula を合併した13歳男子.	臨床眼科	66(3)	307-311	2012
<u>近藤峰生</u>	腫瘍随伴網膜症の新しい自己抗体の発見.	あたらしい眼科	29(臨増)	95-100	2012
生杉謙吾、伊藤邦生、江崎弘治、杉本浩多、三浦功也、築留英之、八木達哉、宇治幸隆、 <u>近藤峰生</u>	トラボプロスト/ チモロールマレイン酸塩配合点眼液への切り替え効果	あたらしい眼科	29(7)	979-983	2012
高畠祐布子、松原央、佐野徹、佐宗幹夫、宇治幸隆、 <u>近藤峰生</u>	血液透析導入後に急速な白内障進行を認めた1例	眼科	54(9)	1203-1206	2012
Ushida H, Kachi S, Asami T, Ishikawa K, <u>Kondo M</u> , Terasaki H	Influence of Preoperative Intravitreal Bevacizumab on Visual Function in Eyes with Proliferative Diabetic	Ophthalmic Res.	49(1)	30-36	2013
Ueno S, Koyasu T, Kominami T, Sakai T, <u>Kondo M</u> , Yasuda S, Terasaki H	Focal cone ERGs of rhodopsin Pro347Leu transgenic rabbits.	Vision Res.	18 ; 91	118-123	2013
Fukuda S, Nagano M, Yamashita T, Kimura K, Tsuboi I, Salazar G, Ueno S, <u>Kondo M</u> , Kunath T, Oshika T, Ohneda O	Functional Endothelial Progenitor Cells Selectively Recruit Neurovascular Protective Monocyte-Derived F4/80+ /Ly6c+ Macrophages in a Mouse Model of Retinal Degeneration.	Stem Cells.	31(10)	2149-2161	2013

Toyoda H, Azuma E, Kawasaki Y, Iwasa T, Ohashi H, Otsuki S, Iwamoto S, Hirayama M, Itoh-Habe N, Wada H, <u>Kondo M</u> , Keida Y, Ito T, Komada Y	Cord blood transplantation combined with rituximab for Wiskott-Aldrich syndrome with autoimmune thrombotic thrombocytopenic purpura	J Allergy Clin Immunol	132(1)	226-227	2013
Matsui Y, Tsukitome H, Uchiyama E, Wada Y, Yagi T, Matsubara H, <u>Kondo M</u>	Peripheral capillary nonperfusion and full-field electroretinographic changes in eyes with frosted branch-like appearance retinal vasculitis.	Clinical Ophthalmology	7	137-140	2013
Nishiguchi KM, Tearle RG, Liu YP, Oh EC, Miyake N, Benaglio P, Harper S, Koskiniemi-Kuendig H, Venturini G, Sharon D, Koenekoop RK, Nakamura M, <u>Kondo M</u> , Ueno S, Yasuma TR, Beckmann JS, Ikegawa S, Matsumoto N, Terasaki H, Berson EL, Katsanis N, Rivolta C.	Whole genome sequencing in patients with retinitis pigmentosa reveals pathogenic DNA structural changes and NEK2 as a new disease gene	Proc Natl Acad Sci U S A.	110(40)	16139-16144	2013
Morita Y1, Kimura K, Fujitsu Y, Enomoto A, Ueno S, <u>Kondo M</u> , Sonoda KH.	Autoantibodies to transient receptor potential cation channel, subfamily M, member 1 in a Japanese patient with melanoma-associated retinopathy.	Jpn J Ophthalmol	in press		2014
小林加寿子、 <u>近藤峰生</u> 、伊藤逸毅、杉田二郎、渡邊直孝、寺崎浩子	鉄片が眼内に飛入したまま1年間経過した病例の網膜機能と形態	眼科臨床紀要	6(4)	269-276	2013
宮田良平、宮田真衣、杉本昌彦、 <u>近藤峰生</u> 、山田知美	ピオグリタゾン塩酸塩製剤(アクトス)による糖尿病黄斑浮腫発症に関与する因子	眼科臨床紀要	6(8)	659-662	2013
小林加寿子、 <u>近藤峰生</u> 、伊藤逸毅、杉田二郎、渡邊直孝、寺崎浩子	鉄片が眼内に飛入したまま1年間経過した病例の網膜機能と形態	眼科臨床紀要	6(4)	269-273	2013

近藤峰生	硝子体出血、血管新生緑内障の予防と EMB	眼科	55(13)	1603-1610	2013
長屋匡俊、上野真治、近藤峰生、寺崎浩子	LE-4000 と PuREC における皮膚電極 ERG の比較	眼科臨床紀要	6(6)	472-476	2013
貝田智子、松永芙絵、花谷淳子、中村ヤス子、大谷伸一郎、宮田和典、近藤峰生	サブトラクション法を用いた皮膚電極による網膜電図と LED 内臓コンタクトレンズ電極を用いた網膜電図の比較	日本眼科学会誌	117(1)	5-11	2013

平成23～25年度 研究成果の刊行に関する一覧表（氏名 篠田啓）

書籍

著者氏名	論文タイトル名	書籍全体の編集者名	書籍名	出版社名	出版地	出版年	ページ
篠田啓	視覚誘発電位 (VEP)	大鹿哲郎	眼科学 第2版	文光堂	東京	2011	1019-1023
篠田啓	先天網膜分離症	仁科幸子	専門医のための眼科診療クオリファイ/9. 子どもの眼と疾患.	中山書店	東京	2012	172-176
篠田啓	X染色体網膜分離症	近藤峰生、山下英俊	遺伝性網膜・黄斑ジストロフィ アップデート. あたらしい眼科	メディカル葵出版	東京	2011	945-951
Shinoda K, Matsumoto CS, Ohde H.	Objective Assessment of Local Retinal Function by Focal Macular and Multifocal Electroretinograms.	Gregor Belusic	ELECTRORETINOGRAMS.	INTECHWEB.ORG.	Rijeka, Croatia.	2011	33-54.
Miyake Y, Shinoda K	<u>Chapter 8 - Clinical Electrophysiology.</u>	Stephen J. Ryan	RETINA. 5 th eds.	Elsevier	London	2012	202-226
篠田啓	眼循環と網膜疾患の関与	石田晋	Retina Medicine	先進医学社	東京	2013	43-49
篠田啓	強膜内陥術. 眼圧上昇・低眼圧.	喜多美穂里	網膜硝子体手術SOS-トラブルとその対策.	医学書院	東京	2012	31-33
篠田啓	強膜内陥術. 通糸時の穿孔.	喜多美穂里	網膜硝子体手術SOS-トラブルとその対策.	医学書院	東京	2012	20-21
篠田啓	IOL 脱臼.	喜多美穂里	網膜硝子体手術SOS-トラブルとその対策.	医学書院	東京	2012	74-75
篠田啓	網膜剥離に対する手術 6. 特殊な網膜剥離 (3) アトピー性皮膚炎に伴う網膜剥離.	小椋祐一郎	眼手術学7(網膜・硝子体 I I)	文光堂	東京	2012	64-72

篠田啓	I網膜剥離に対する手術4. 特殊な網膜剥離(1)巨大裂孔網膜剥離.	小椋祐一郎	眼手術学7(網膜・硝子体 I I)	文光堂	東京	2012	46-53
篠田啓	2. 視機能検査 I. 網膜電図(ERG), 視覚誘発電位(VEP), 暗順応検査. 1. ~3.	坪田一男、大鹿哲郎	テキスト眼科学	南山堂	東京	2012	64-69
篠田啓	9. 網膜疾患 A. 黄斑疾患. 1. ~11.	坪田一男、大鹿哲郎	テキスト眼科学	南山堂	東京	2012	166-178
篠田啓	網膜機能検査A to Z	近藤峰生	専門医のための眼科診療クオリファイ/14. 昼盲(羞明)	中山書店	東京	2012	37-42
篠田啓	網膜機能検査A to Z	近藤峰生	専門医のための眼科診療クオリファイ/14. 全視野ERG: 記録方法と正常波形.	中山書店	東京	2012	136-142

雑誌

発表者氏名	論文タイトル名	発表誌名	巻号	ページ	出版年
Matsumoto CS, Shinoda K, Satofuka S, Nakatsuka K, Mizota A, Miyake Y.	The impact of Stiles-Crawford effect on Focal Macular ERGs in Monkeys.	JOV	6;12(3)	pii: 6. doi: 10.1167/12..3.6.	2012.
Sonoyama H, Shinoda K, Ishigami C, Tada Y, Ideta H, Ideta R, Takahashi M, Miyake Y.	Oguchi disease masked by retinitis pigmentosa.	Doc Ophthalmol.	123(2)	127-33	2011
So K, Shinoda K, Matsumoto CS, Satofuka S, Imamura Y, Mizota A.	Functional and microstructural change of the localized photoreceptors in acute zonal occult outer retinopathy.	Case Reports Ophthalmol.	2(3)	307-13.	2011
Hirasawa M, Noda K, Noda S, Suzuki M, Ozawa Y, Shinoda K, Inoue M, Ogawa Y, Tsuibota K, Ishida S.	Transcriptional Factors Associated with Epithelial-Mesenchymal Transition in Choroidal Neovascularization.	Mol Vis.	17	1222-30.	2011

Kawamura R, Inoue M, Shinoda H, Shinoda K, Itoh Y, Ishida S, Tsubota K.	Incidence of Increased Intraocular Pressure after Subtenon Injection of Triamcinolone Acetonide.	J Ocul Pharmacol Ther.	27(3)	299-304	2011
Sugahara M, <u>Shinoda K</u> , Matsumoto CS, Satofuka S, Hanazono G, Imamura Y, Mizota A.	Outer Retinal Microstructure in Case of Acute Idiopathic Blind Spot Enlargement Syndrome.	Case Reports Ophthalmol.	2(1)	116-22.	2011
Matsumoto CS, <u>Shinoda K</u> , Satofuka S, Nakatsuka K, Mizota A, Miyake Y.	The impact of Stiles-Crawford effect on Focal Macular ERGs in Monkeys.	JOV	6;12(3)	pii: 6. doi: 10.1167/12..3.6.	2012.
So K, <u>Shinoda K</u> , Watanabe E, Mashiko T, Mizota, A.	Vitrectomy for Proliferative Retinopathy in Patient with advanced Duchenne Muscular Dystrophy.	Retinal Cases & Brief Reports	6(2)	142-144	2012
Akiyama Y, <u>Shinoda K</u> , Watanabe E, Mashiko T, Mizota A.	Simultaneous bilateral central retinal artery occlusion in Churg-Strauss syndrome.	Retinal Cases & Brief Reports.	6(1)	60-64	2012
Uchida A, <u>Shinoda K</u> , Matsumoto CS, Ohde H, Ozawa Y, Ishida S, Inoue M, Mizota A, Tsubota K.	Acute visual field defect following vitrectomy was determined as optic nerve origin by Electrophysiology.	Case Reports Ophthalmol.	3	396-405	2012
Matsumoto K, Matsumoto CS, <u>Shinoda K</u> , Watanabe E, Mizota A.	Tissue plasminogen activator assisted vitrectomy for an eye with suprachoroidal hemorrhage after rupture.	Case Report in Ophthalmol	3(2)	258-61	2012
Fujita K, <u>Shinoda K</u> , Matsumoto CS, Imamura Y, Tanaka E, Mizutani Y, Yuzawa M, Mizota A.	Microperimetric evaluation on the half-dose photodynamic therapy for chronic central serous chorioretinopathy.	Clin Ophthalmol	6	1681-7	2012
Mochizuki Y, Ohkuma S, <u>Shinoda K</u> , Matsumoto CS, Satofuka S, Mizota A.	A case of unilateral peripheral cone dysfunction.	Case Report in Ophthalmol	3(2)	162-8.	2012
Fujita K, Matsumoto CS, Imamura Y, Satofuka S, <u>Shinoda K</u> , Mizutani Y, Yuzawa M, Mizota A, Oda K.	Low luminance visual acuity in patients with central serous chorioretinopathy.	Clin Exp Optom.	96(1)	100-5	2012

Fujita K, <u>Shinoda K</u> , Imamura Y, Matsumoto CS, Mizutani Y, Mizota A, Yuzawa M.	Correlation of integrity of cone outer segment tip line with retinal sensitivity after half-dose photodynamic therapy for chronic central serous chorioretinopathy.	Am J Ophthalmol	154(3)	579-85.	2012
Hanazono G, <u>Shinoda K</u> , Obazawa M, Imamura Y, Matsumoto CS, Satofuka S, Mizota A, Ando Y.	Valsalva hemorrhagic retinopathy during cheerleading training (Ouendan).	Retinal Cases & Brief Reports.	7(1)	78-81	2013
<u>Shinoda K</u> , Imamura Y, Matsumoto CS, Satofuka S, Mizota A, Ando Y.	Wavy and elevated RPE line in optical coherence tomographic images of eyes with posterior scleritis.	Graefe's Archive for Clinical and Experimental Ophthalmology	250(9)	1399-1402	2013
Kawamura R, <u>Shinoda K</u> , Inoue M, Noda T, Ohnuma K, Hirakata A.	Images of intravitreal objects projected onto posterior surface of model eye.	Acta Ophthalmol.	91(7)	561-6.	2013
Matsumoto CS, <u>Shinoda K</u> , Matsumoto H, Matsumoto K, Funada H, Mizota A.	Liquid Crystal Display Screens as Stimulators for Visually Evoked Potentials: flash effect due to delay in	Documenta Ophthalmol.	127(2)	103-12.	2013
Ozeki N, <u>Shinoda K</u> , Ohde H, Ishida S, Tsubota K.	Transcorneal electrical stimulation to treat Best vitelliform macular dystrophy.	Graefe's Archive for Clinical and Experimental Ophthalmology,	251(7)	1867-70.	2013
Fujinami K, Tsunoda K, Nakamura N, Kato Y, Noda T, <u>Shinoda K</u> , Tomita K, Hatase T, Usui T, Akahori M, Itabashi T, Iwata T, Ozawa Y, Tsubota K, Miyake Y.	Molecular Characteristics of Four Japanese Cases with KCNV2-retinopathy: Report of Novel Disease-causing Variants.	Mol Vis.	19	1580-90	2013
Matsumoto CS, <u>Shinoda K</u> , Matsumoto H, Funada H, Mizota A.	Comparison of flash effect during pattern visually evoked potentials in different driving frequency Liquid Crystal Display monitors.	Ophthalmic Res	In press		

Fujita K, Imamura Y, <u>Shinoda K</u> , Matsumoto CS, Mizutani Y, Mizota A, Yuzawa M.	Quantitative evaluation of metamorphopsia in chronic central serous chorioretinopathy undergoing half-dose verteporfin photodynamic therapy.	RETINA	In press		
Gocho K, Kikuchi S, Kabuto T, Kameya S, <u>Shinoda K</u> , Mizota A, Yamaki K, Takahashi K.	High-resolution en face images of microcystic macular edema in patients with autosomal dominant optic atrophy.	J Ophthalmol, BioMed Research International	Epub 2013 Nov 28.		
Terauchi G, Matsumoto CS, <u>Shinoda K</u> , Watanabe E, Kondo T, Matsumoto H, Mizota A.	Pars plana vitrectomy combined with endolaser photocoagulation in the treatment of idiopathic macular telangiectasia.	Case Reports in Medicine	2014		2014
Terauchi G, Matsumoto CS, <u>Shinoda K</u> , Matsumoto H, Mizota A.	Effect of intraocular lens diameter on the scleral depression at peripheral fundus observation during vitrectomy.	J Ophthalmol, BioMed Research International	In press		

別紙4

平成23～25年度 研究成果の刊行に関する一覧表（氏名 國吉一樹）

書籍

著者氏名	論文タイトル名	書籍全体の編集者名	書籍名	出版社名	出版地	出版年	ページ
國吉一樹	Q&A 眼科診療ピットフォール	下村嘉一・松本長太	Q&A 眼科診療ピットフォール	金芳堂	京都市	2013	79-90
國吉一樹	ERG の有用性	白神史雄	専門医のための眼科診療クオリファイ 16 糖尿病合併症	中山書店	東京都	2013	37-40
國吉一樹	さまざまな網膜疾患における ERG	近藤峰生	専門医のための眼科診療クオリファイ 14 網膜機能検査 A to Z	中山書店	東京都	2012	143-155
國吉一樹	夜盲	近藤峰生	専門医のための眼科診療クオリファイ 14 網膜機能検査 A to Z	中山書店	東京都	2012	29-36
若山曉美, 國吉一樹	動的視野検査	近藤峰生	専門医のための眼科診療クオリファイ 14 網膜機能検査 A to Z	中山書店	東京都	2012	54-62

雑誌

発表者氏名	論文タイトル名	発表誌名	巻号	ページ	出版年
Kuniyoshi K, Sakuramoto H, Nakao Y, Matsumoto C, Shimomura Y	Two types of acute zonal occult outer retinopathy differentiated by dark- and light-adapted perimetry	Japanese Journal of Ophthalmology	58	17187	2014
Kuniyoshi K, Sugioka K, Sakuramoto H, Kusaka S, Wada N, Shimomura Y	Intravitreal injection of bevacizumab for retinopathy of prematurity	Japanese Journal of Ophthalmology		In press	2014
Kuniyoshi K, Terasaki H, Arai M, Hirose T	Multifocal electroretinograms in Stargardt's disease/fundus flavimaculatus	Ophthalmologica		In press	2014

櫻本宏之, <u>國吉一樹</u>	電気生理学的検査. 全視野 ERG	眼科	56	65-75	2014
<u>Kuniyoshi K</u> , <u>Hayashi T</u> , Sakuramoto H, Nakao A, Sato T, Utsumi T, Tsuneoka H, Shimomura Y.	Novel mutations in enhanced S-cone syndrom	Ophthalmology	120	431 e1-6	2013
Sakuramoto H, <u>Kuniyoshi K</u> , <u>Tsunoda</u> <u>K</u> , Akahori M, <u>Iwata T</u>	Two siblings with late-onset cone-rod dystrophy and no visible macular degeneration	Clinical Ophthalmology	7	1703-1711	2013
<u>國吉一樹</u>	抗アクアポリン4抗体陽 性視神経炎	臨床眼科 臨時増刊号	67	188-193	2013
<u>Kuniyoshi K</u> , Sakuramoto H, Nakao A, Takada S, Shimomura Y	A case of bilateral, acquired and acute dysfunction of short-wavelength-sensitive cone systems	Documenta Ophthalmologica	125	75-80	2012
櫻本宏之, <u>國吉一樹</u> , 咲山豊, 中尾彰, 岡崎 能久, 松本長太, 下村 嘉一	左右差の著しい網膜変 性の長期経過	眼科臨床紀要	4	567-573	2011

平成23年度～25年度 研究成果の刊行に関する一覧表 (氏名 林 孝彰)

書籍 平成23～25年度

著者氏名	論文タイトル名	書籍全体の編集者名	書 籍 名	出版社名	出版地	出版年	ページ
林 孝彰	色の生理 7.1 (b) 先天青黄色覚異常		新編色彩科学 ハンドブック 第3版	東京大学 出版会	東京	2011	382-383
林 孝彰	色の生理 7.1 (c) 先天全色盲		新編色彩科学 ハンドブック 第3版	東京大学 出版会	東京	2011	384-385
林 孝彰	網膜色素変性	伊藤利之、 江藤文夫、 木村彰男	今日のリハビリ テーション 指針	医学書院	東京	2013	374-377
林 孝彰	全色盲	伊藤利之、 江藤文夫、 木村彰男	今日のリハビリ テーション 指針	医学書院	東京	2013	382-383

雑誌 平成23～25年度

発表者氏名	論文タイトル名	発表誌名	巻号	ページ	出版年
Hayashi T, Tsuzuranuki S, Kozaki K, Urashima M, Tsuneoka H.	Macular dysfunction in Ogunchi disease with the frequent mutation 1147delA in the <i>SAG</i> gene	Ophthalmic Res	46	175-180	2011
Hayashi T, Gekka T, Nakano T, Tsuneoka H.	Improvement in S-cone-mediated visual fields and rod function after correction of vitamin A deficiency	Eur J Ophthalmol	21	657-660	2011
Rocha Sousa A, Hayashi T, Lourenço Gomes N, Brandão E, Penas S, Rocha P, Urashima M, Yamada H, Tsuneoka H, Falcão Reis F.	A novel mutation (Cys83Tyrr) in the second zinc finger of <i>NR2E3</i> in enhanced S-cone syndrome	Graefes Arch Clin Exp Ophthalmol	249	201-208	2011
Kitakawa T, Hayashi T, Tsuzuranuki S, Kubo A, Tsuneoka H.	Color vision in an elderly patient with protanopic genotype and successfully treated unilateral age-related macular degeneration	Int Ophthalmol	31	471-475	2011

Aoyagi R, <u>Hayashi T</u> , Masai A, Mitooka K, Gekka T, Kozaki K, Tsuneoka H.	Subfoveal choroidal thickness in multiple evanescent white dot syndrome	Clin Exp Optom	95	212-217	2012
<u>Hayashi T</u> , Gekka T, Kozaki K, Ohkuma Y, Tanaka I, Yamada H, Tsuneoka H.	Autosomal dominant occult macular dystrophy with an <i>RP11</i> mutation (R45W)	Optom Vis Sci	89	684-691	2012
Kitakawa T, <u>Hayashi T</u> , Takashina H, Mitooka K, Gekka T, Tsuneoka H.	Improvement of central visual function following steroid pulse therapy in acute zonal occult outer retinopathy	Doc Ophthalmol	124	249-254	2012
Kuniyoshi K, <u>Hayashi T</u> , Sakuramoto H, Nakao A, Sato T, Utsumi T, Tsuneoka H, Shimomura Y.	Novel mutations in enhanced S-cone syndrome	Ophthalmology	120	431.e1-6	2013
Ohkuma Y, <u>Hayashi T</u> , Sakai T, Watanabe A, Tsuneoka H.	One year results of reduced fluence photodynamic therapy for central serous chorioretinopathy: the outer nuclear layer thickness is associated with visual prognosis	Graefes Arch Clin Exp Ophthalmol	251	1909-1971	2013
Aoyagi R, <u>Hayashi T</u> , Gekka T, Kozaki K, Tsuneoka H.	Multifocal electroretinographic evaluation of macular function in acute posterior multifocal placoid pigment epitheliopathy	Doc Ophthalmol	126	253-258	2013
Okuno T, <u>Hayashi T</u> , Sugawara J, Oku H, Yamada H, Tsuneoka H, Ikeda T.	Elderly case of pseudo-unilateral occult macular dystrophy with Arg45Trp mutation	Doc Ophthalmol	127	141-146	2013
Kubota M, <u>Hayashi T</u> , Arai K, Tsuneoka H.	Choroidal neovascularization after blunt ocular trauma in angioid streaks	Clin Ophthalmol	7	2123-2126	2013
Shibata A, Ohkuma Y, <u>Hayashi T</u> , Tsuneoka H.	Efficacy of reduced-fluence photodynamic therapy for serous retinal pigment epithelial detachment with choroidal hyperpermeability	Clin Ophthalmol	7	2123-2126	2013
Katagiri S, Yoshitake K, Akahori M, <u>Hayashi T</u> , Furuno M, Nishino J, Ikeo K, Tsuneoka H, Iwata T.	Whole-exome sequencing identifies a novel <i>ALMS1</i> mutation (Q2051X) in two Japanese brothers with Alström Syndrome	Mol Vis	19	2393-2406	2013

Ogasawara M, Matsumoto Y, <u>Hayashi T</u> , Ohno K, Yamada H, Kawakita T, et al.	<i>KRT12</i> mutations and in vivo confocal microscopy in two Japanese families with Meesmann corneal dystrophy	Am J Ophthalmol	157	93-102	2014
Ohkuma Y, <u>Hayashi T</u> , Sakai T, Watanabe A, Yamada H, Akahori M, et al.	Retinal angiomatous proliferation associated with risk alleles of <i>ARMS2/HTRA1</i> gene polymorphisms in Japanese patients	Clin Ophthalmol	8	143-148	2014
Katagiri S, Gekka T, <u>Hayashi T</u> , Ida H, Ohashi T, Eto Y, Tsuneoka H.	<i>OAT</i> mutations and clinical features in two Japanese brothers with gyrate atrophy of the choroid and retina	Doc Ophthalmol	128	137-148	2014
Katagiri S, Akahori M, <u>Hayashi T</u> , Yoshitake K, Gekka T, Ikeo K, Tsuneoka H, Iwata T.	Autosomal recessive cone-rod dystrophy associated with compound heterozygous mutations in the <i>EYS</i> gene	Doc Ophthalmol	in press		

書籍

著者氏名	論文タイトル名	書籍全体の 編集者名	書 籍 名	出版社名	出版地	出版年	ページ
なし							

雑誌

発表者氏名	論文タイトル名	発表誌名	巻号	ページ	出版年
<u>Ueno S</u> , Nishiguchi KM, Tanioka H, Enomoto A, Yamanouchi T, Kondo M, Yasuma TR, Yasuda S, Kuno N, Takahashi M, Terasaki H	Degeneration of retinal on bipolar cells induced by serum including autoantibody against TRPM1 in mouse model of paraneoplastic retinopathy.	PLoS One.	25	e81507	2013
Hibi N, <u>Ueno S</u> , Ito Y, Piao CH, Kondo M, Terasaki H.	Relationship between retinal layer thickness and focal macular electroretinogram components after epiretinal membrane surgery.	Investigative Ophthalmology and Visual Science.	1	7207-7214	2013
<u>Ueno S</u> , Koyasu T, Kominami T, Sakai T, Kondo M, Yasuda S, Terasaki H	Focal cone ERGs of rhodopsin Pro347Leu transgenic rabbits.	Vision Research	18	118-123	2013
Fukuda S, Nagano M, Yamashita T, Kimura K, Tsuboi I, Salazar G, <u>Ueno S</u> , Kondo M, Kunath T, Oshika T, Ohneda O.	Functional endothelial progenitor cells selectively recruit neurovascular protective monocyte-derived F4/80(+) /Ly6c(+) macrophages in a mouse model of retinal degeneration.	Stem Cells.	31	2149	2013
Watanabe S, Sanuki R, <u>Ueno S</u> , Koyasu T, Hasegawa T, Furukawa T	Tropisms of AAV for subretinal delivery to the neonatal mouse retina and its application for in vivo rescue of developmental retinopathy	PLoS One.	8	E54146	2013
Iwata E, <u>Ueno S</u> , Ishikawa K, Ito Y, Uetani R, Piao CH, Kondo M, Terasaki H	Focal macular electroretinograms after intravitreal injections of bevacizumab for age-related macular degeneration.	Investigative Ophthalmology and visual Science	28	4185-90	2012

IV. 研究成果の刊行物・別刷

Longitudinal clinical course of three Japanese patients with Leber congenital amaurosis/early-onset retinal dystrophy with *RDH12* mutation

Kazuki Kuniyoshi · Hiroyuki Sakuramoto · Kazutoshi Yoshitake ·
Kosuke Abe · Kazuho Ikeo · Masaaki Furuno · Kazushige Tsunoda ·
Shunji Kusaka · Yoshikazu Shimomura · Takeshi Iwata

Received: 11 February 2014 / Accepted: 10 April 2014
© Springer-Verlag Berlin Heidelberg 2014

Abstract

Purpose To report the longitudinal clinical course of three Japanese patients from two families with Leber congenital amaurosis/early-onset retinal dystrophy (LCA/EORD), and the results of next-generation DNA sequences on them.

Patients and methods The patients were three Japanese children: a 4-year-old girl, a 6-year-old boy, and a 3-year-old girl. Patients 1 and 2 were siblings, and patient 3 was from an unrelated family. Standard ophthalmic examinations including perimetry, electroretinography, optical coherence tomography, and ultrasonography were performed on each patient. The patients were

observed for 28, 16, and 10 years. Whole exomes of the patients and their non-symptomatic parents were analyzed using a next-generation sequence technique.

Results The decimal visual acuity varied between 0.07 and 0.6 at the initial visit and decreased to counting finger to hand motion in their teens. Funduscopy showed diffuse retinal and macular degeneration. During the follow-up period, a posterior staphyloma developed and the macular area became atrophic. Patient 1 developed cataracts in her early twenties. Genetic analysis revealed a homozygous A126V substitution in the *RDH12* gene in all patients.

Conclusions The three patients with LCA/EORD had a progressive decrease of their vision with the formation of a posterior staphyloma. This is the first report of Japanese patients with LCA/EORD with a *RDH12* mutation.

A part of this paper was presented at the 8th congress of Asia Pacific Vitreo-retina Society in Nagoya, Japan, on December 7, 2013.

K. Kuniyoshi (✉) · H. Sakuramoto · K. Abe ·
Y. Shimomura
Department of Ophthalmology, Kinki University Faculty
of Medicine, 377-2 Ohno-Higashi, Osaka-Sayama City,
Osaka 589-8511, Japan
e-mail: kuniyoshi-kazuki@umin.net

K. Yoshitake · K. Ikeo
Laboratory of DNA Data Analysis, National Institute of
Genetics, Shizuoka, Japan

M. Furuno
Transcriptome Technology Team, Life Science
Accelerator Technology Group, Division of Genomic
Technologies, RIKEN Center for Life Science
Technologies, Yokohama, Japan

K. Tsunoda
Laboratory of Visual Physiology, National Institute of
Sensory Organs, National Hospital Organization Tokyo
Medical Center, Tokyo, Japan

S. Kusaka
Department of Ophthalmology, Sakai Hospital, Kinki
University Faculty of Medicine, Sakai City, Osaka, Japan

T. Iwata
Division of Molecular and Cellular Biology, National
Institute of Sensory Organs, National Hospital
Organization Tokyo Medical Center, Tokyo, Japan

Keywords Leber congenital amaurosis · Early-onset retinal dystrophy · *RDH12* · Macular dystrophy · Posterior staphyloma · Electroretinogram · Next-generation sequence analysis

Introduction

Leber congenital amaurosis (LCA) is the most severe form of early-onset retinal dystrophy and was first reported by Theodor Leber in 1869 [1]. He reported blind infants who had nystagmus and no pupillary light reflexes, and their fundus was initially normal and progressed to pigmentary retinal dystrophy [1]. For the diagnosis of LCA, it is necessary to show the presence of searching nystagmus, absence of pupillary light reflexes, and non-recordable electroretinograms (ERGs) [2]. Leber also described milder forms of this disease [3], which is now referred to as early-onset severe retinal dystrophy (EOSRD), severe

early-childhood-onset retinal dystrophy (SECORD), or early-onset retinal dystrophy (EORD). The appearance of the fundus of LCA/EORD varies widely, including normal fundus appearance, flecked retina, diffuse pigmentary retinal degeneration, and macular coloboma/posterior staphyloma. In addition, keratoconus and cataract can be present in these patients [4].

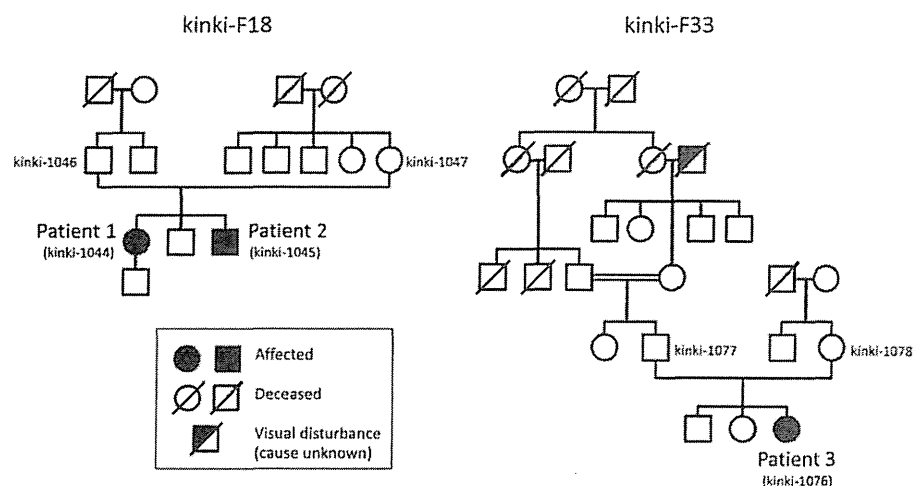
Most cases of LCA/EORD have an autosomal recessive inheritance pattern. To date, 17 causative genes have been identified for LCA/EORD (LCA1-17, Table 1) [5, 6]. Since *RDH12* was reported as a causative gene for LCA/EORD in 2004 [7, 8], several studies have reported on the phenotype of LCA/EORD patients with a *RDH12* mutation [9–16]. These studies reported a progressive reduction in vision leading to legal blindness in young adulthood, and the presence of diffuse retinal degeneration with macular degeneration and cataract formation [7–16]. However, the longitudinal clinical course of cases of LCA/EORD with the *RDH12* mutation has not been reported.

Table 1 Genes reported as causative for Leber congenital amaurosis or early-onset retinal dystrophy (LCA/EORD) [5,6]

Phenotype	Name	Loci	Year reported in LCA/EORD	Note
LCA1 (ar)	<i>GUCY2D</i>	17q13.1	1996	CORD6 (ad)
LCA2 (ar)	<i>RPE65</i>	1q31.3-2	1997	keratoconus, RP20 (ar)
LCA3 (ar)	<i>SPATA7</i>	14q31.3	2009	
LCA4 (ar)	<i>AIPL1</i>	17p13.2	2000	macular degeneration, juvenile CRD (ad)
LCA5 (ar)	<i>LCA5</i>	6q14.1	2003	coloboma
LCA6 (ar)	<i>RPGRIP1</i>	14q11.2	2001	CORD13 (ar)
LCA7 (ad/ar)	<i>CRX</i>	19q13.32	1998	coloboma, CORD2 (ad)
LCA8 (ar)	<i>CRB1</i>	1q31.3	2001	coloboma, PPRPE (ar), RP12 (ar)
LCA9 (ar)	<i>NMNAT1</i>	1q36.22	2012	coloboma
LCA10 (ar)	<i>CEP290</i>	12q21.32	2006	BBS14 (ar), JBTS5 (ar), SLSN6 (ar), MKS4 (ar)
LCA11 (ad)	<i>IMPDH1</i>	7q32.1	2006	RP10 (ad)
LCA12 (ar)	<i>RD3</i>	1q32.3	2006	
LCA13 (ar)	<i>RDH12</i>	14q24.1	2004	maculopathy, RP53 (ad)
LCA14 (ar)	<i>LRAT</i>	4q32.1	2001	
LCA15 (ar)	<i>TULP1</i>	6q21.31	2004	maculopathy, RP14 (ar)
LCA16 (ar)	<i>KCNJ13</i>	2q37.1	2011	SVD (ad)
LCA17 (ar)	<i>GDF6</i>	8q22.1	2013	

ar autosomal recessive, ad autosomal dominant, *CORD* and *CRD* cone-rod dystrophy, *RP* retinitis pigmentosa, *PPRPE* RP with para-arteriolar preservation of the retinal pigment epithelium, *BBS* Bardet-Biedl syndrome, *JBTS* Joubert syndrome, *SLSN* Senior-Loken syndrome, *MKS* Meckel syndrome, *SVD* snowflake vitreoretinal degeneration

Fig. 1 Pedigrees of two unrelated families with Leber congenital amaurosis/early-onset retinal dystrophy (LCD/EORD) with *RDH12* mutation. Patients 1 and 2 were siblings (*left*, kinki-F18), and Patient 3 is from an unrelated family (*right*, kinki-F33). No consanguinity was reported between parents of the patients



We report the 10- to 28-year continuous course of three Japanese patients with LCA/EORD, and the results of next-generation sequence analyses on them.

Patients and methods

The patients were three Japanese individuals from two unrelated families (Fig. 1). Patients 1 and 2 were siblings (kinki-F18), and Patient 3 was a member of another unrelated family (kinki-F33; Fig. 1).

The research protocol was approved by the Ethics Review Board of the Kinki University Faculty of Medicine in November 2011, and the procedures conformed to the tenets of the Declaration of Helsinki. The genetic analysis was performed after obtaining a signed informed consent form from all patients and/or their parents.

Clinical studies

The ophthalmic examinations consisted of measurements of the visual acuity, slit-lamp biomicroscopy, ophthalmoscopy, Goldmann kinetic perimetry, full-field ERGs, optical coherence tomography (OCT), and ultrasonography. ERG recordings were performed according to the guideline of the International Society for Clinical Electrophysiology of Vision (ISCEV Standard, 2008 update) [17]. OCT was performed with the CirrusTM HD-OCT version 5.1 (Carl Zeiss Meditec, Dublin, CA, USA). All clinical tests were performed in the Kinki University Hospital, and all patients were examined yearly from the initial visit to year 2013.

DNA preparation and exome sequencing analysis

The genetic analyses were performed in 2013. We obtained venous blood samples from the patients and their non-symptomatic parents in the Kinki University Hospital. The blood samples were sent to the Division of Molecular and Cellular Biology in National Institute of Sensory Organs of the National Hospital Organization Tokyo Medical Center, and genomic DNA was extracted from the blood samples using Gentra Puregene Blood Kit (Qiagen, Tokyo, Japan). The purified genomic DNA was sent to RIKEN or MacroGen Japan (Tokyo, Japan) and shared with Covaris UltrasonicatorTM (Covaris, Woburn, MA, USA). Construction of paired-end sequence libraries and exome capture were performed using the Agilent Bravo Automated Liquid Handling Platform with SureSelect XT Human All Exon V4 + UTRs kit (Agilent Technologies, Santa Clara, CA, USA) according to the manufacturer's instructions. Enriched libraries were sequenced with the Illumina HiSeq 2000 sequencer (San Diego, CA, USA), according to the manufacturer's instructions for 100-bp paired-end sequencing. The results of the sequence analysis were sent to Laboratory of DNA Data Analysis in National Institute of Genetics and analyzed. Reads were mapped to the reference human genome (1,000 genomes, phase 2 reference, hs37d5) with the Burrows-Wheeler Aligner software, version 0.6.2 [18]. Duplicated reads were then removed by Picard MarkDuplicates module version 1.62, and mapped reads around insertion-deletion polymorphisms (INDELs) were realigned using the Genome Analysis

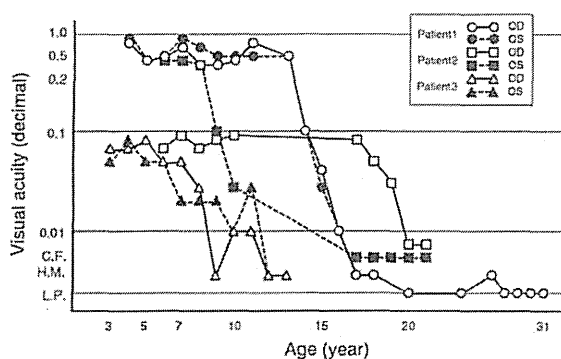


Fig. 2 Clinical course of visual acuity in each patient. OD oculus dexter, OS oculus sinister

Toolkit (GATK) version 2.7-4 [19]. Base-quality scores were recalibrated using GATK. The calling of mutations was performed using the GATK UnifiedGenotyper module, and the called single-nucleotide variants and INDELs were annotated with the snpEff software, version 3.3 [20]. The mutations were annotated with the snpEff score (“HIGH,” “MODERATE,” or “LOW”) and with the allele frequency in the 1,000 genomes database and Human Genetic Variation Browser (HGVD) [21]. The mutations were then filtered so that only those with “HIGH” or “MODERATE” snpEff scores indicating that the amino acid sequence would be functionally affected, and a frequency <1 % in the 1,000 genomes database and HGVD were further analyzed. We also used new variations, which were not found in the in-house database of exome data of seven people with control individuals without ocular diseases. Mutations were classified by hereditary information into homozygous recessive, heterozygous recessive, and de novo mutations in the family members. Filtered mutations were scored with PolyPhen software version 2.2.2 [22], which predicts the effect on the structure and function of the protein. This exome analysis pipeline is available at Management and Analysis System for Enormous Reads (Maser) [23].

Results

The clinical course of the visual acuity in the three patients is presented in Fig. 2. Summaries of the clinical findings are shown in Figs. 3, 4, and 5.

Patient 1 (Fig. 3, kinki-1044 in Fig. 1): Patient 1 was a girl who was 4-year old when we first examined her in 1986. Her parents reported that she seemed to

have difficulty in the dark from the age of 3 years. Her decimal best-corrected visual acuity (BCVA) at the initial visit was 0.6 with +1.25 diopter sphere (DS) and −0.75 D cylinder (DC) ax 160° in the right eye and 0.6 with +0.5 DS and −0.25 DC ax 20° in the left eye. Her visual fields were severely constricted, and ophthalmoscopy showed diffuse retinal degeneration with macular degeneration (Fig. 3). Her fundi appeared reticulated before the age 10 years. Her vision markedly decreased in her middle teens resulting in hand motion vision at age 17 years (Fig. 2). At this age, the macular degeneration appeared atrophic and a posterior staphyloma was present in both eyes (Fig. 3). A posterior subcapsular cataract was noticed when she was 23-year old. She is now 31-year old, and her vision is light perception in both eyes (Fig. 2).

Single-bright flash full-field ERGs recorded at age 9 years were non-recordable, and the flicker ERGs were barely recordable (Fig. 3). OCT and ultrasonography performed at 30 and 31 years of age showed deep excavation and a thinning of the retina at the posterior pole of both eyes (Fig. 3). The axial length at age 31 years was 22.72 ± 0.05 mm in the right eye and 21.20 ± 0.09 mm in the left eye.

When the sequences of her whole exome were compared with the reference human genome (hs37d5), 940,138 mutations were found. We focused only on mutations that could change the amino-acid sequence and excluded common mutations by 1,000 genomes, HGVD [21], and our in-house database (see methods). As a result, 467 mutations remained as candidate mutations. We filtered the remaining mutations by using the pattern of inheritance (homozygous recessive, heterozygous recessive, or de novo mutation) with her parents and her brother (Patient 2) and found only 2 genes as causal candidates. Finally, *RDH12*, which was the only one of the genes registered in the RetNet database of genes and the loci causing inherited retinal diseases [6], was assumed to be the