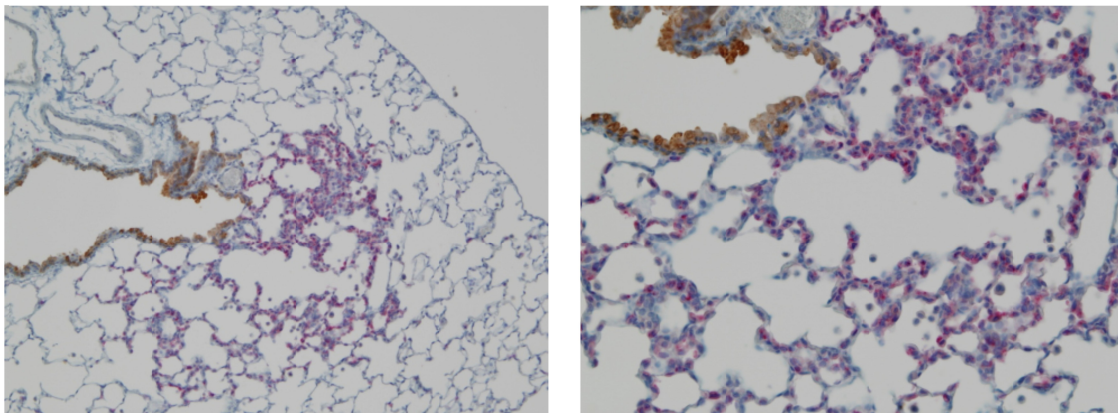
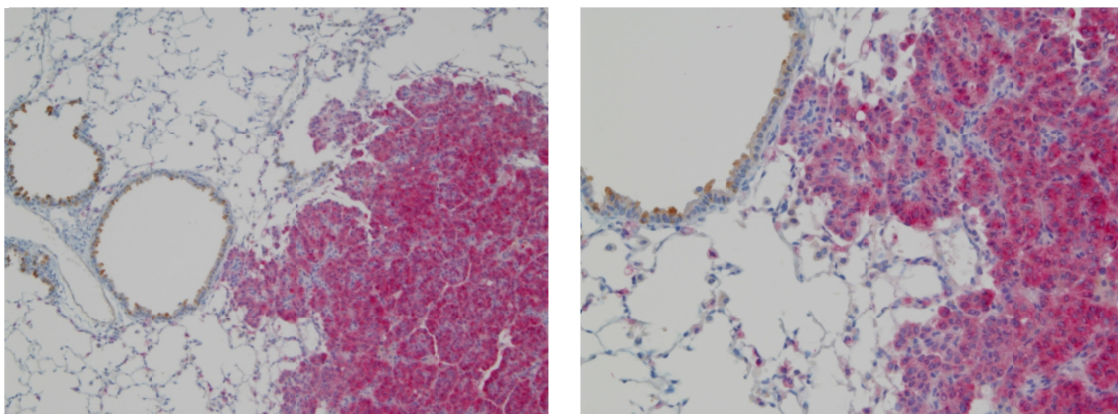


図1, NNK誘発マウス肺におけるCCSPとSP-Cの発現

Hyperplasia

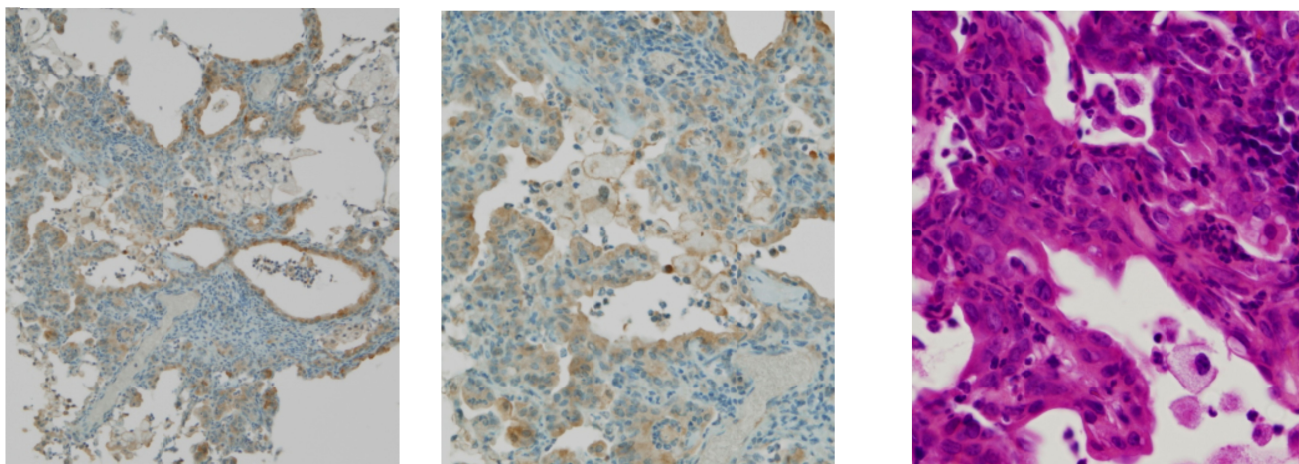


Adenoma



CCSP+SP-C (brown;CCSP, red; SP-C)

図2, NTCU誘発マウス肺扁平上皮異形成におけるCCSPとSP-Cの発現

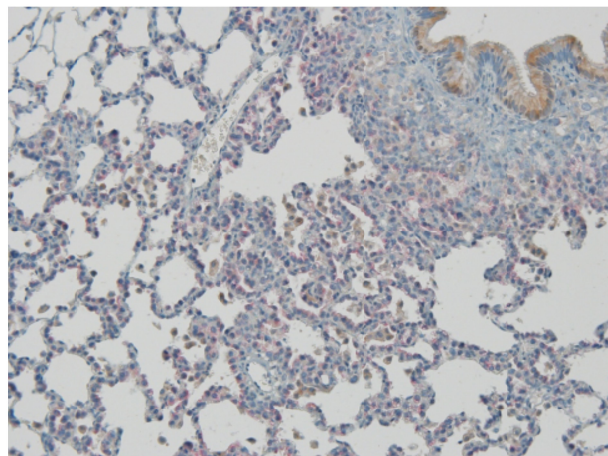
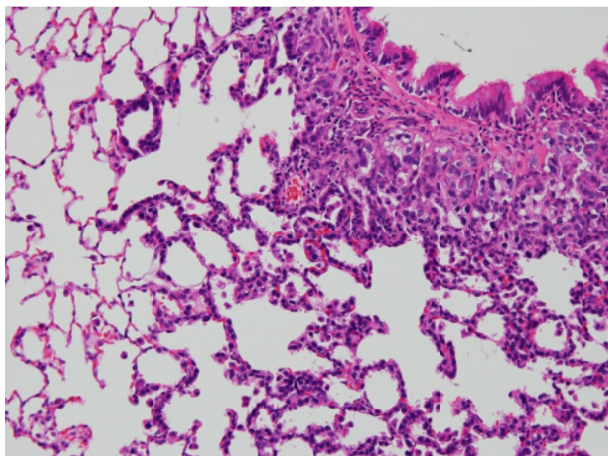


CCSP+SP-C (brown;CCSP, red; SP-C)

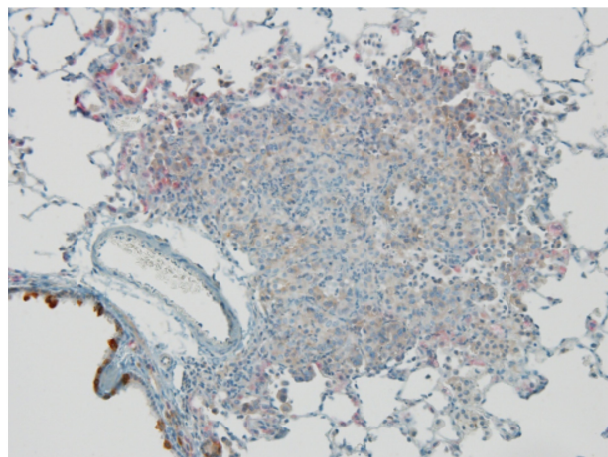
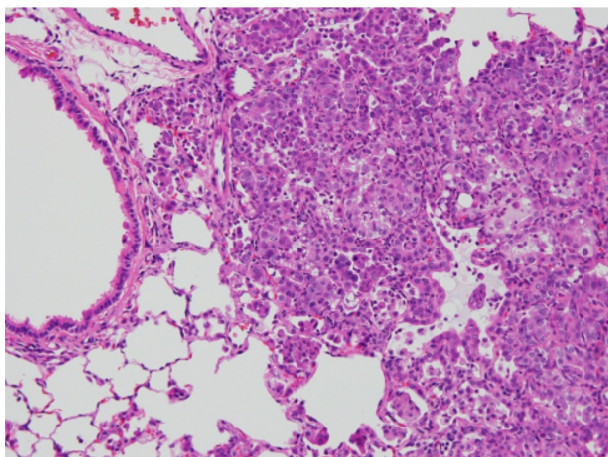
H. E.

図3, DHPN誘発ラット肺におけるCCSPとSP-Cの発現

Hyperplasia



Adenocarcinoma



H. E.

CCSP+SP-C  
(brown;CCSP, red; SP-C)