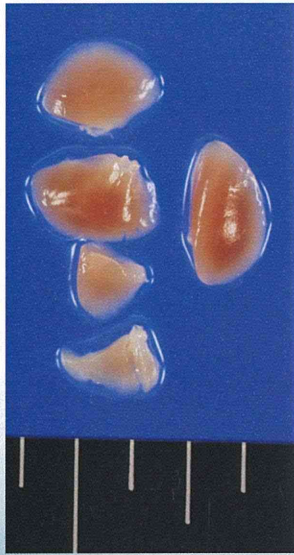
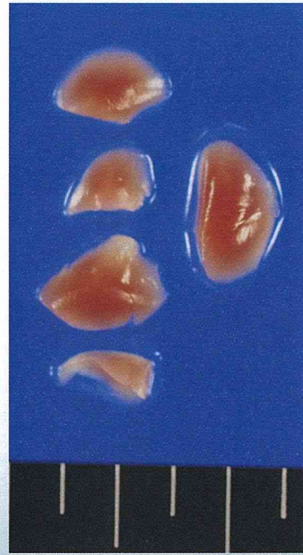

Control 群

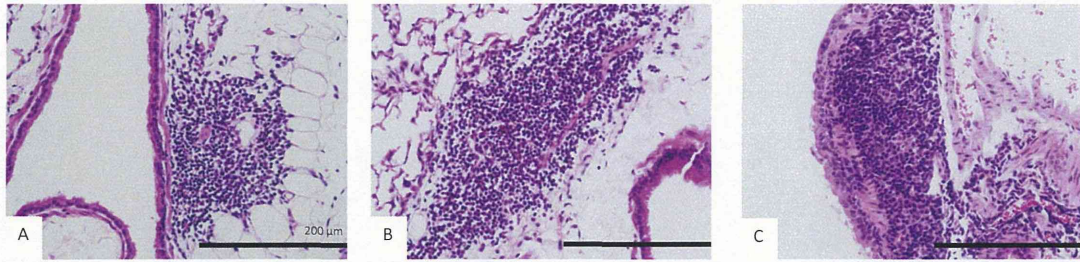


MWCNT 投与群



Organ weights

Group	body weight	Liver weight		Lung weight		Kidney weight	
		absolute weight	relative weight	absolute weight	relative weight	absolute weight	relative weight
Control	39.68 ± 3.58	1.63 ± 0.16	0.041 ± 0.002	0.18 ± 0.03	0.005 ± 0.001	0.37 ± 0.03	0.009 ± 0.001
MWCNT	36.97 ± 2.40 *	1.62 ± 0.11	0.045 ± 0.003 *	0.17 ± 0.02	0.005 ± 0.001	0.37 ± 0.03	0.010 ± 0.001 *
	p=0.0083		p=0.0017	p=0.383			p=0.0260



+1

+2

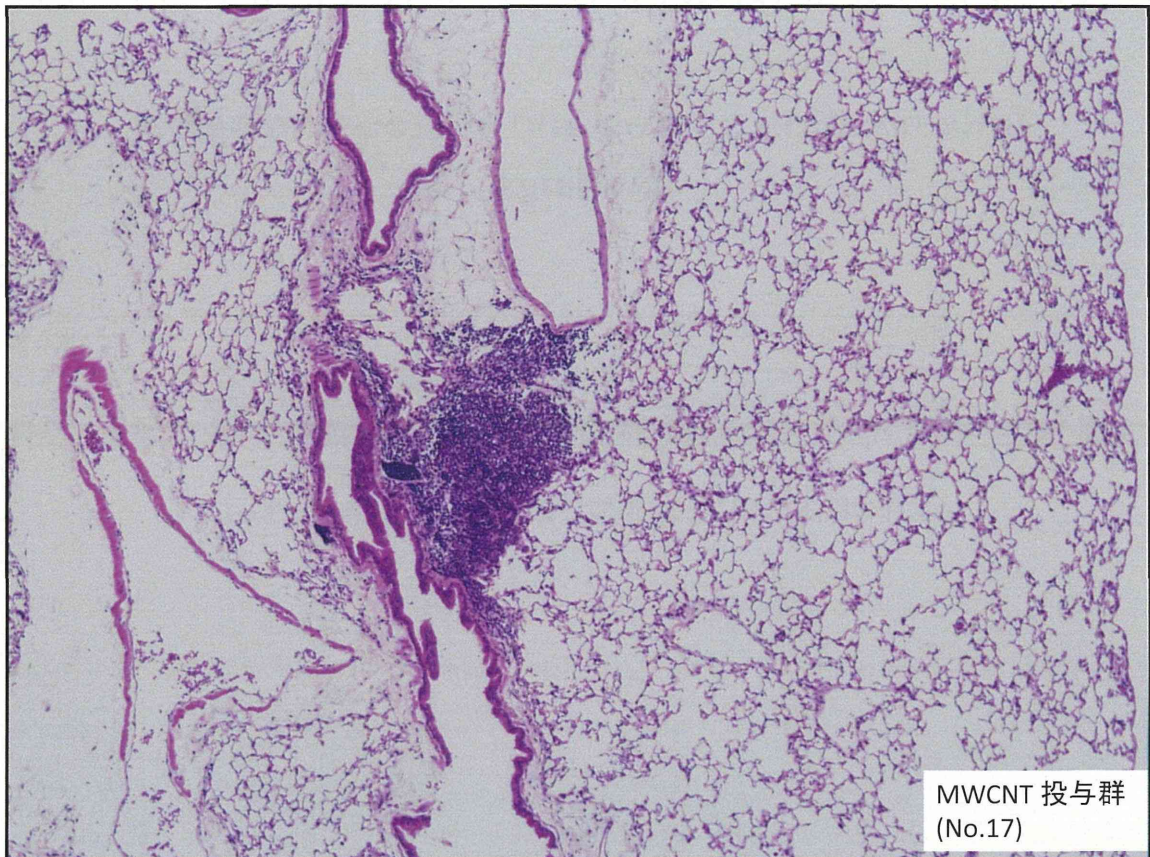
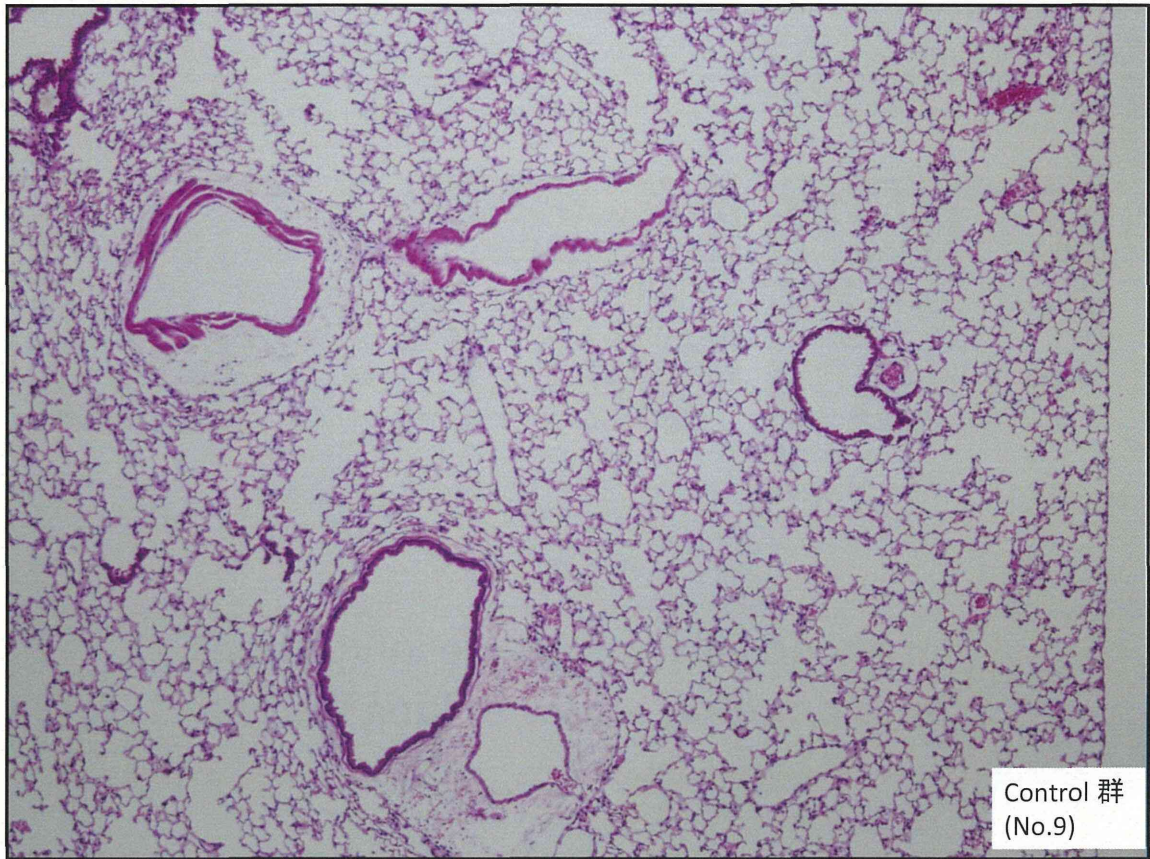
+3

Peribronchial lymphocyte infiltrations Inflammation scores of lung lesions

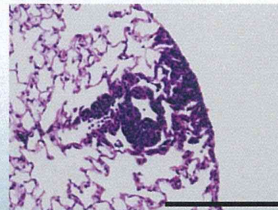
Inflammation scores and Histopathological Findings

Group	No.	Lymphocyte infiltration		Neutrophil infiltration			Histopathological changes				
		peritracheal	in the spaces of alveoli	interstitial (wall)	in the spaces of alveoli	Pulmonary edema	Pulmonary fibrosis	Alveolar macrophage aggregation	Focal granulomatous inflammation	Bronchial hyperplasia	Squamous metaplasia
Control	10	1.1 ± 0.9	0.0 ± 0.0	0.0 ± 0.0	0.0 ± 0.0	0.0 ± 0.0	0.0 ± 0.0	0.0 ± 0.0	0.0 ± 0.0	0.0 ± 0.0	0.0 ± 0.0
MWCNT	19	1.3 ± 1.0	0.1 ± 0.2	0.0 ± 0.0	0.0 ± 0.0	0.0 ± 0.0	0.0 ± 0.0	0.0 ± 0.0	0.0 ± 0.0	0.1 ± 0.5	0.0 ± 0.0

いずれの因子においても、群間で有意差は見られませんでした。

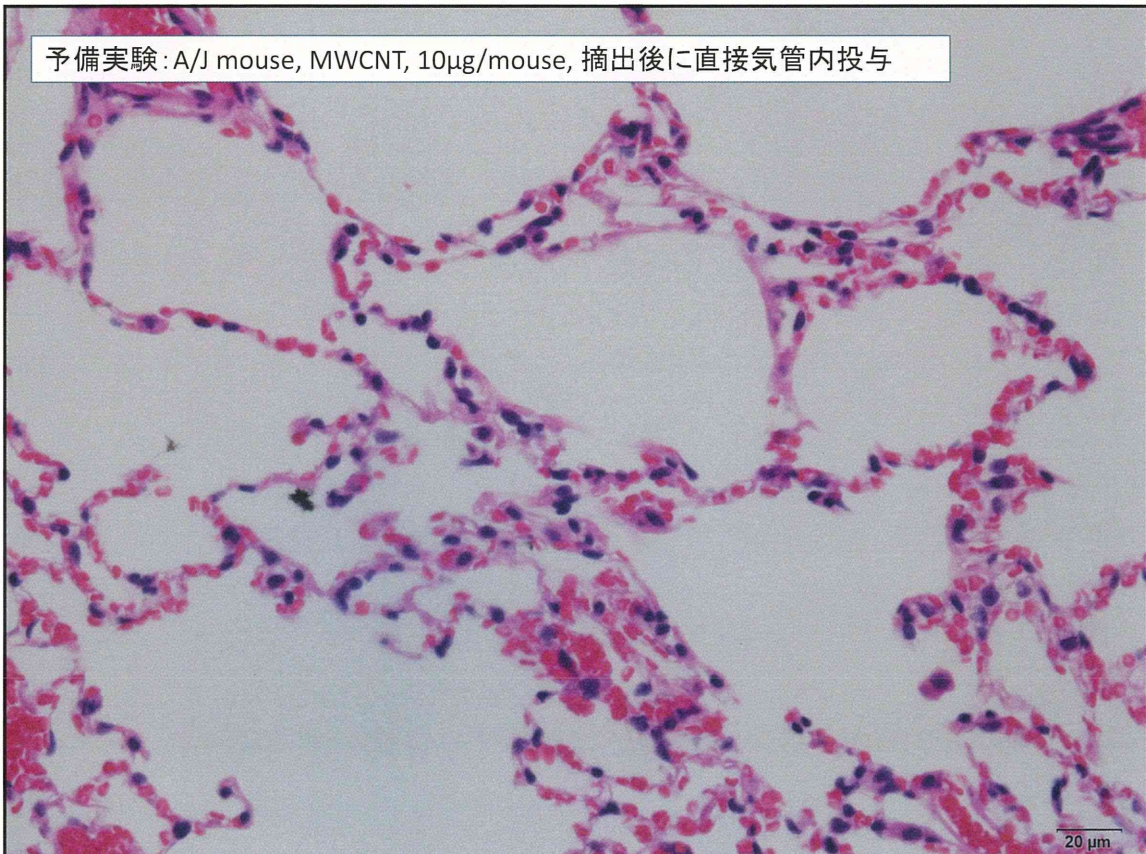


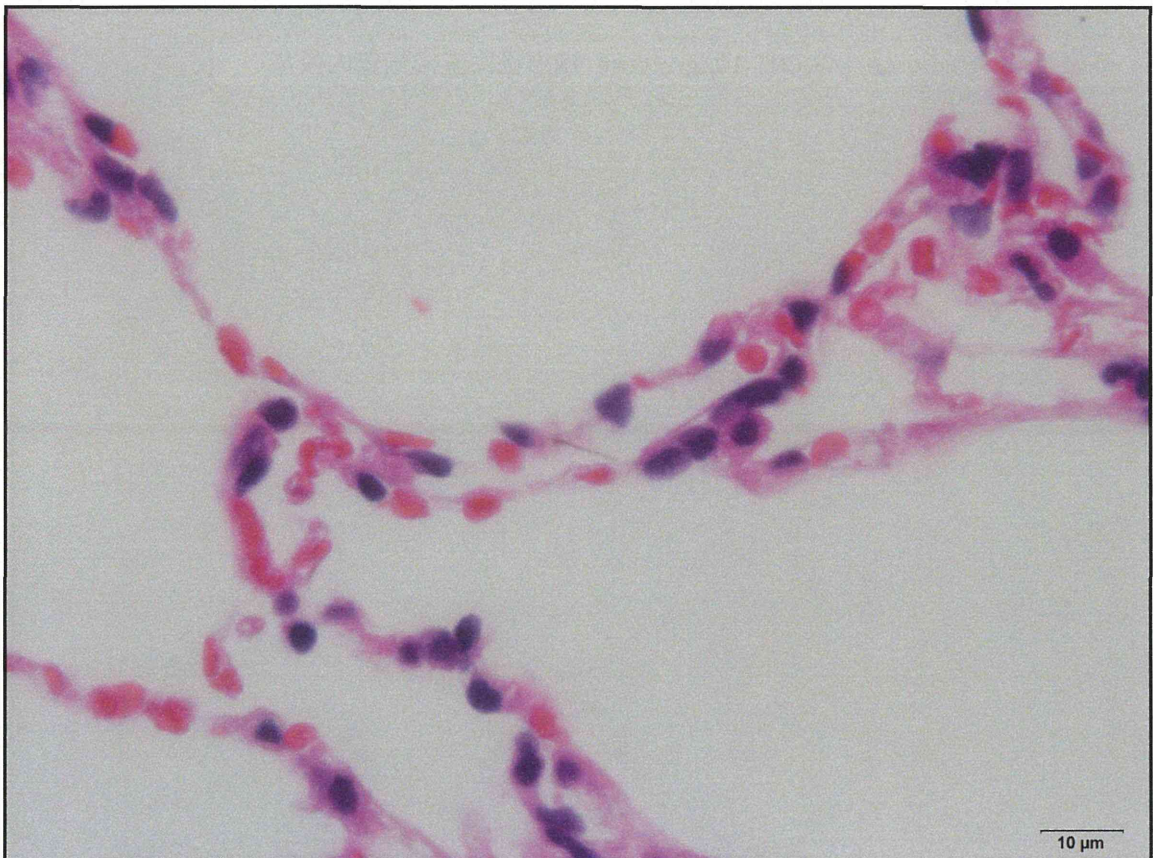
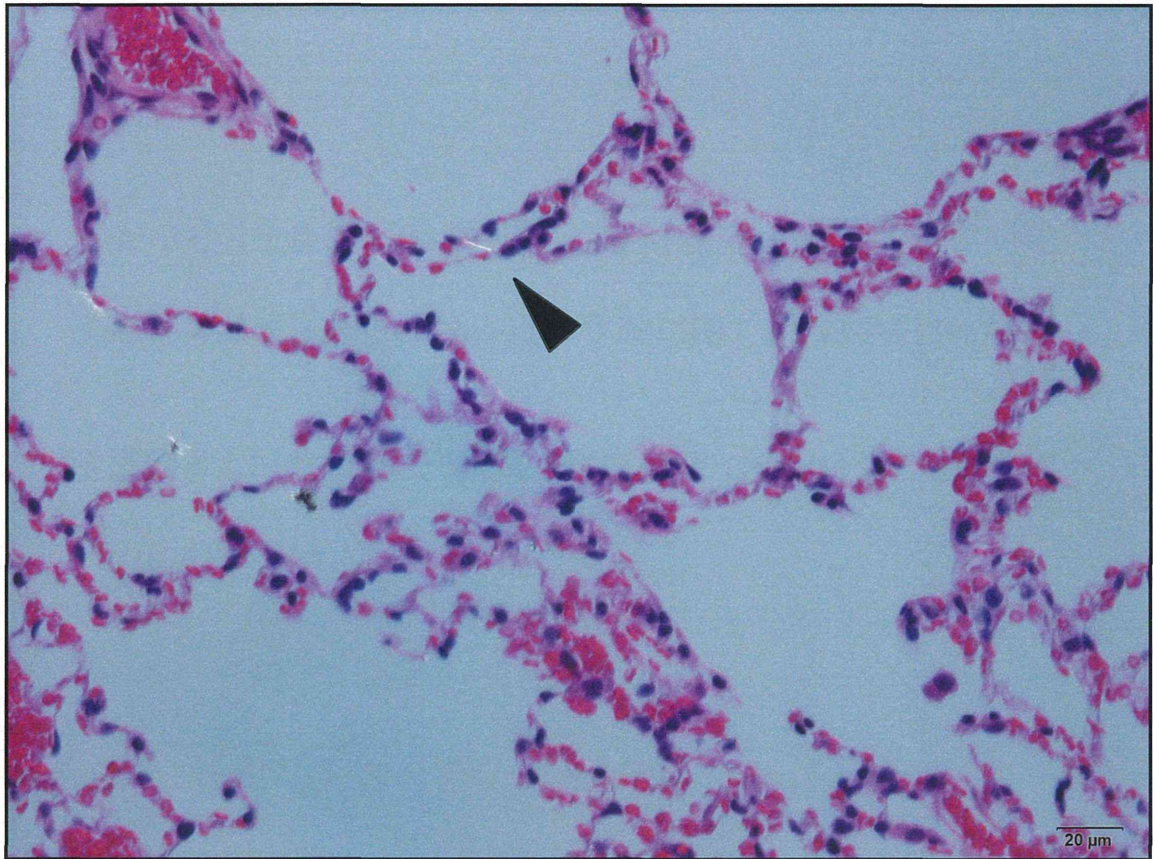
- 群間で炎症性Scoreに差はなく、腫瘍性病変は発生しなかった。
- MWCNT投与群で、1例に肺で hyperplasia を生じた個体が見られた。
- HE 標本では MWCNT を同定できず、偏光顕微鏡による観察を行った。

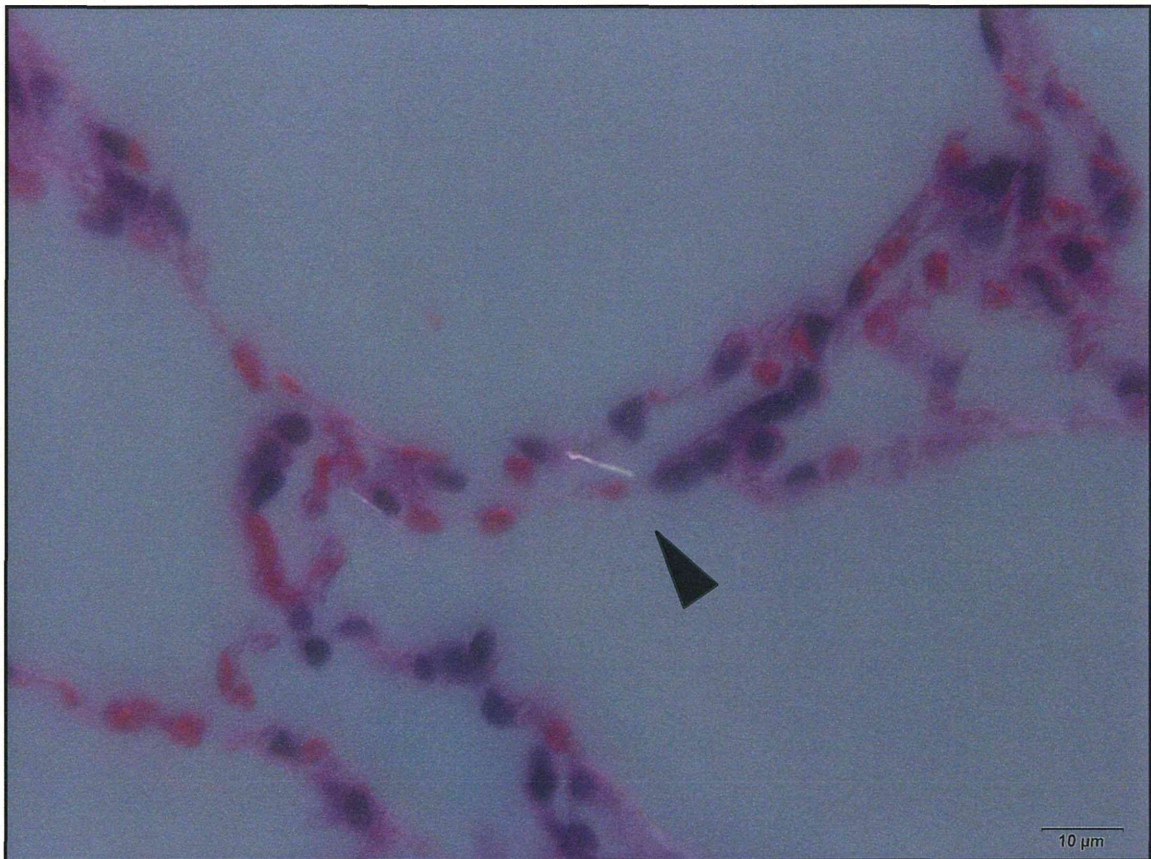


Hyperplasia, observed in the MWCNT group.

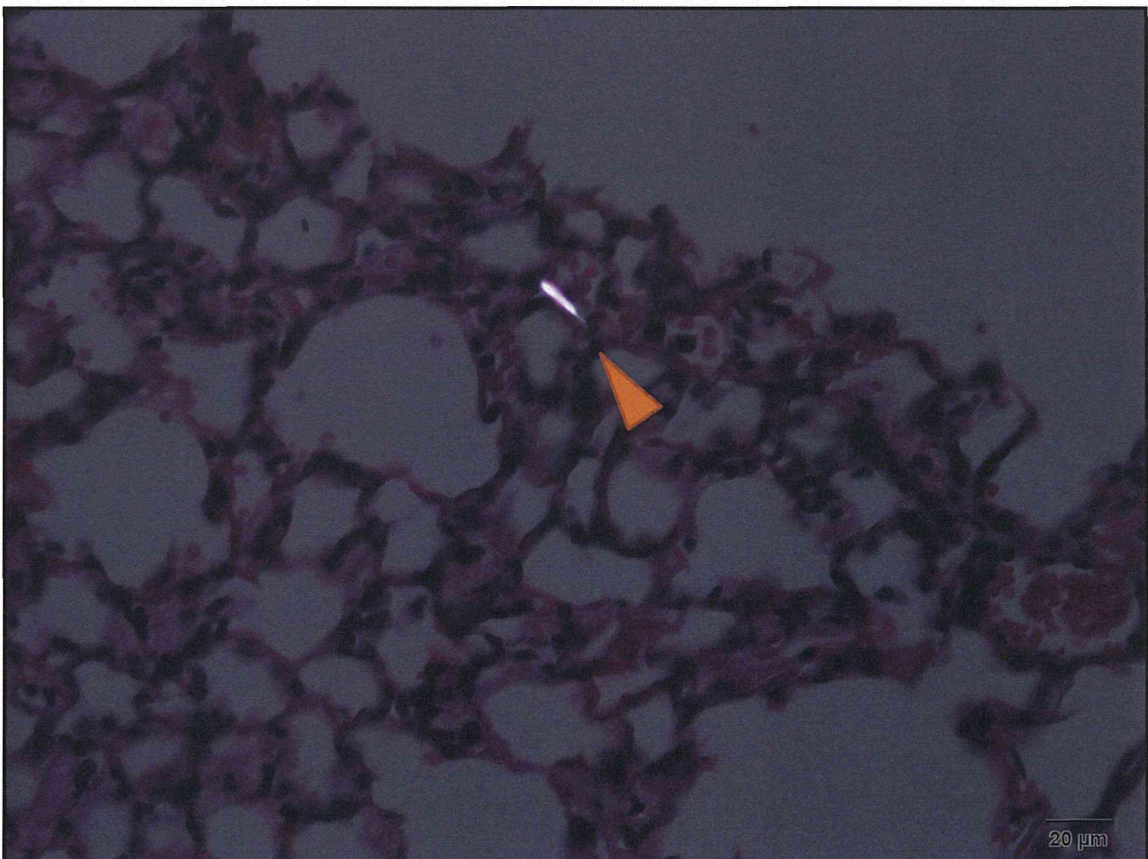
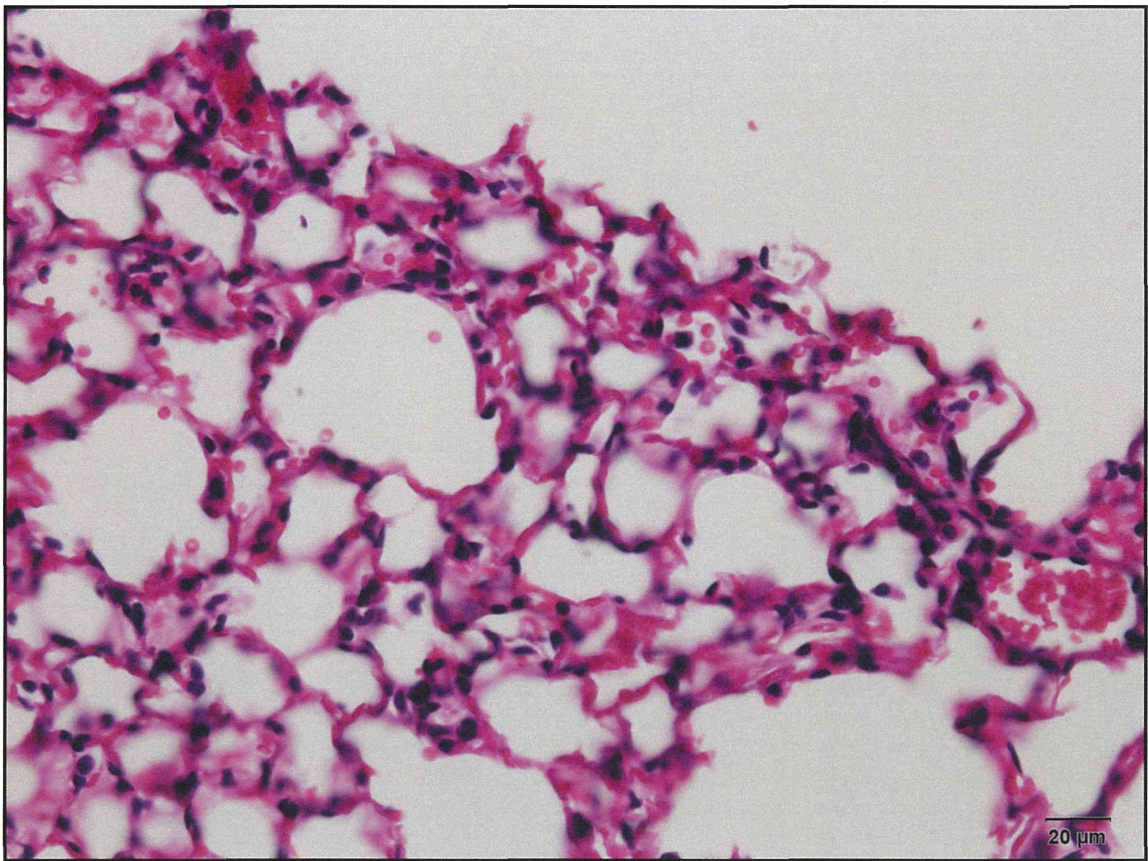
予備実験: A/J mouse, MWCNT, 10 μ g/mouse, 摘出後に直接気管内投与



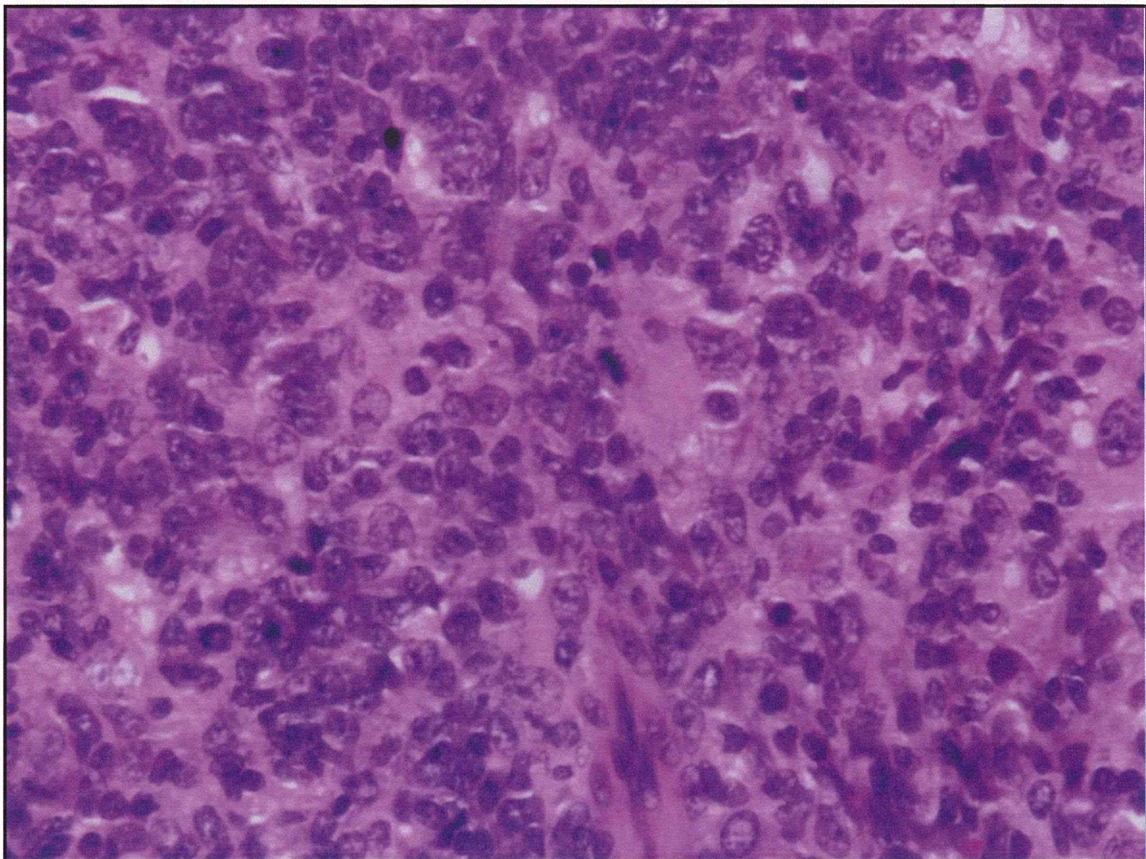
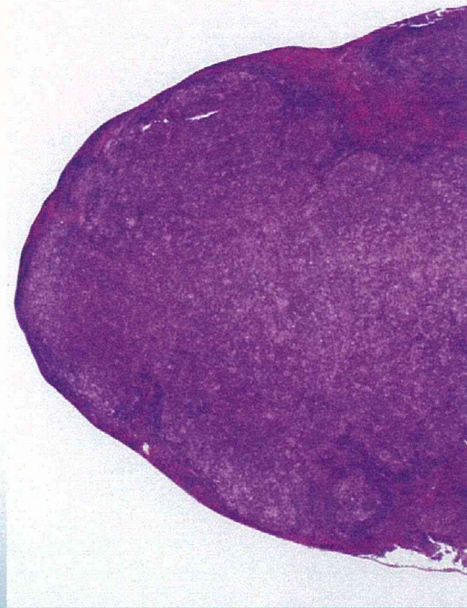
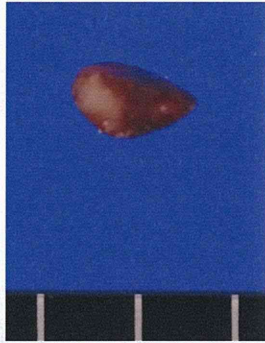


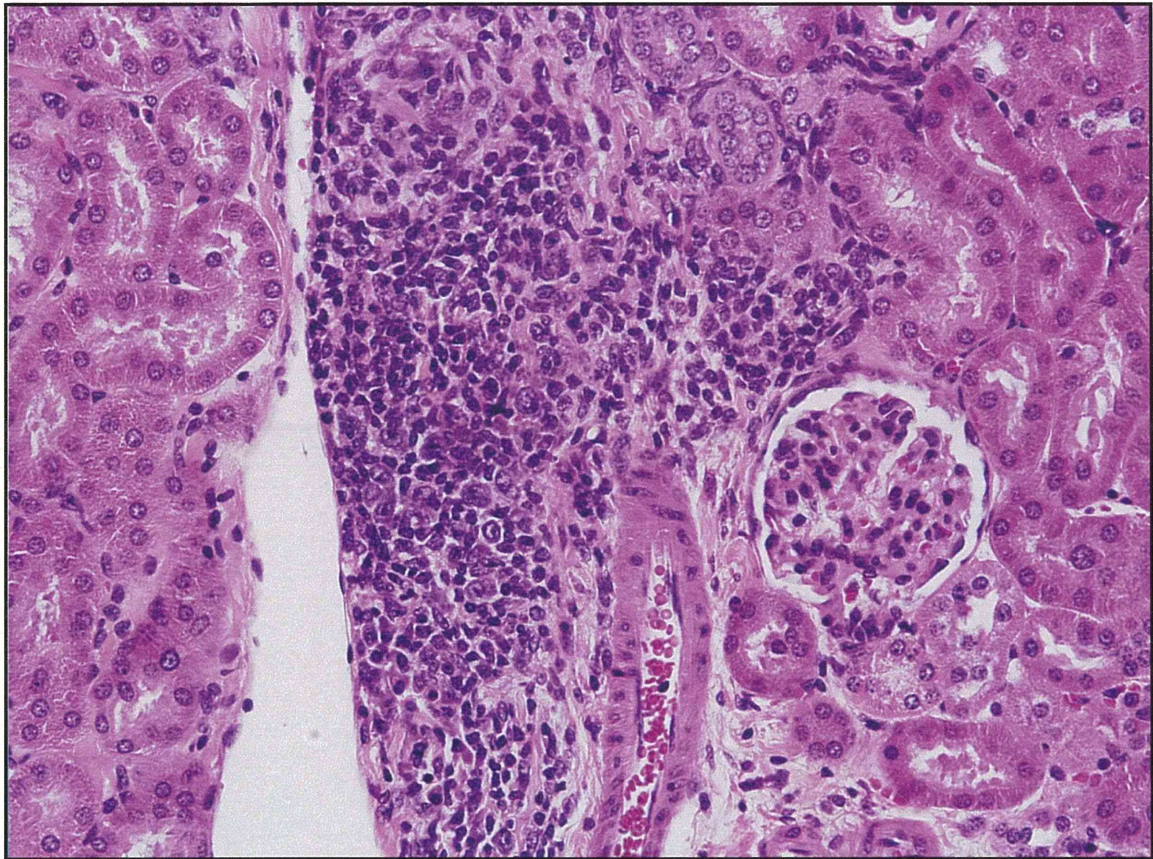
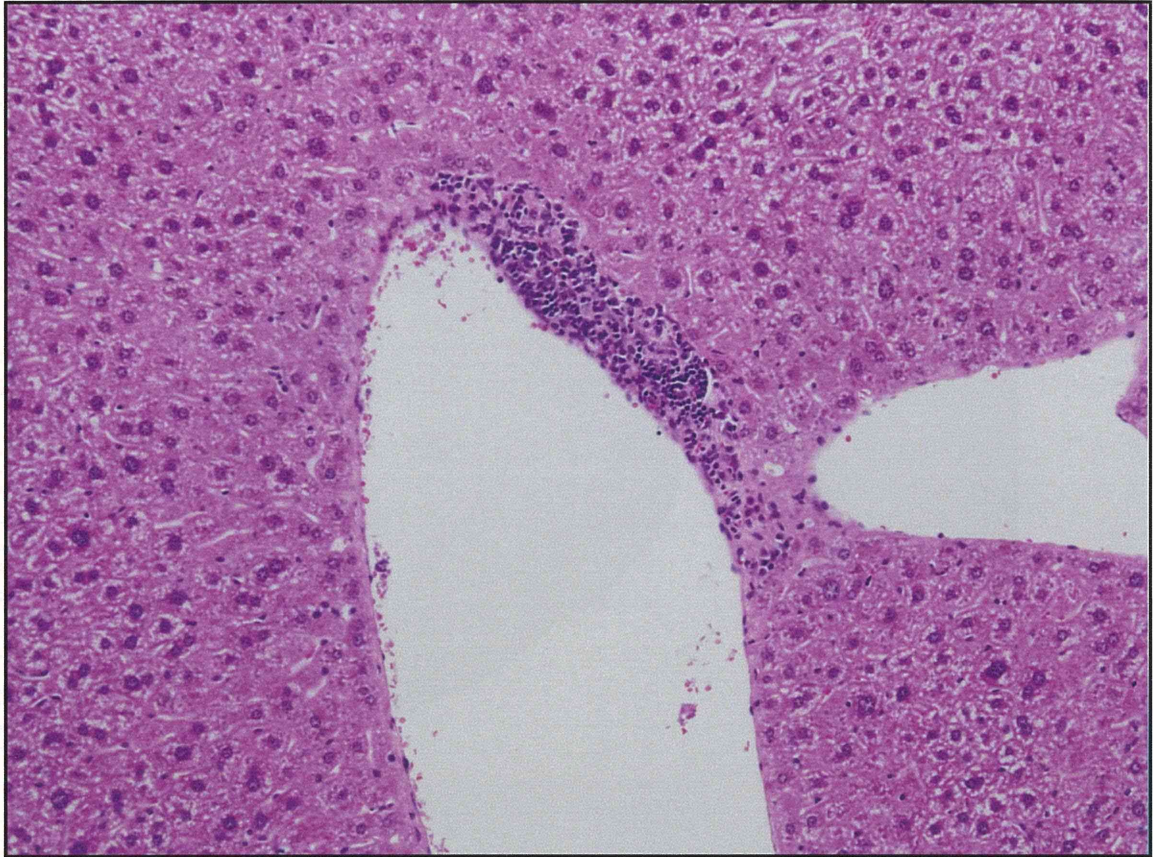


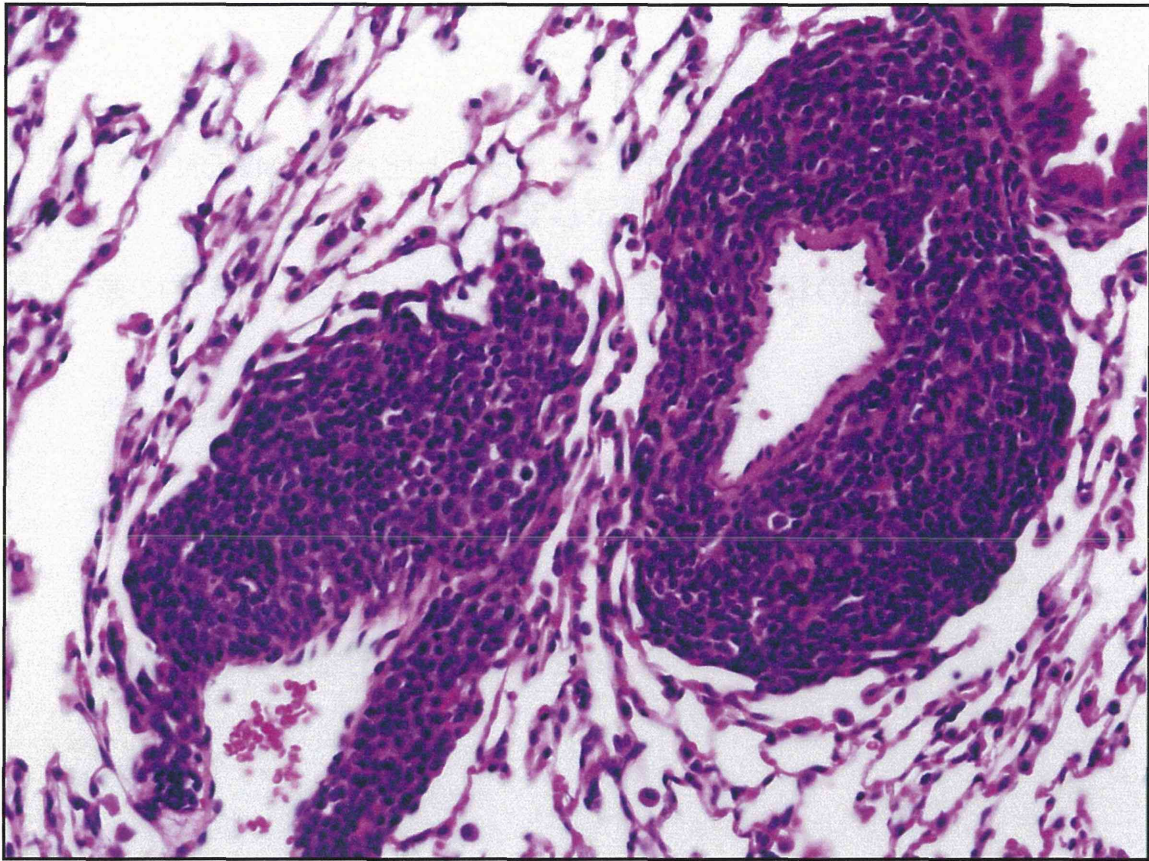
雄性C57BI6/J マウスにおける
MWCNT 単回気管内投与実験(52w)



MWCNT 投与群 1 個体の脾臓に白色結節







- MWCNT 投与群の1例で、lymphoma, malignant の発生が見られた。
- 腫瘍部を含め、肺、肝、腎および脾臓で、MWCNT を疑う針状物質は見られず、自然発症腫瘍と考えられる。