

ボランティアに対する無作為割り付けクロスオーバー試験において、PCC 50 U/kg の投与はリバーロキサバンに対してはプロトロンビン時間の延長を回復し、内因性トロンビン産生能の抑制から回復するものの、ダビガトランに対しては、APTT、ECT、トロンビン時間の延長を回復しなかったとされる<sup>19)</sup>。また、活性型 PCC 100 U/kg 投与でエドキサバンで延長したプロトロンビン時間を回復できたとされる<sup>20)</sup>。また、遺伝子組み換え活性型第 VII 因子製剤は動物実験ではリバーロキサバンのリバースに効果があったとされる<sup>21)</sup>。これらは十分なエビデンスとは言えず、致死性出血が起こっている患者に対しても PCC や遺伝子組み換え活性型第 VII 因子製剤を投与することが、本当にいいのかは現時点では分からない。

以上、抗凝固療法中の周術期管理について概説した。特に新規経口抗凝固薬に対するリバース薬は現在、治験が進行中であり、今後の動向が注目される。

#### 文 献

- 1) Mahadoo J, Heibert L, Jaques LB: Vascular sequestration of heparin. *Thromb Res* 1978 ; 12 : 79-90
- 2) Friedman Y, Arsenis C: Studies on the heparin sulphamidase activity from rat spleen. Intracellular distribution and characterization of the enzyme. *Biochem J* 1974 ; 139 : 699-708
- 3) Meuleman DG: Orgaran (Org 10172) : its pharmacological profile in experimental models. *Haemostasis* 1992 ; 22 : 58-65
- 4) Wolowacz SE, Roskell NS, Plumb JM, et al: Efficacy and safety of dabigatran etexilate for the prevention of venous thromboembolism following total hip or knee arthroplasty. A meta-analysis. *Thromb Haemost* 2009 ; 101 : 77-85
- 5) Alquwaizani M, Buckley L, Adams C, et al: Anticoagulants: A review of the pharmacology, dosing, and complications. *Curr Emerg Hosp Med Rep* 2013 ; 1 : 83-97
- 6) Abcede HG, Ovbiagele B: Update on antithrombotic therapy for stroke prevention in atrial fibrillation. *Curr Treat Options Cardiovasc Med* 2010 ; 12 : 250-60
- 7) Eriksson BI, Borris LC, Friedman RJ, et al: Rivaroxaban versus enoxaparin for thromboprophylaxis after hip arthroplasty. *N Engl J Med* 2008 ; 358 : 2765-75
- 8) Turpie AG, Lassen MR, Davidson BL, et al: Rivaroxaban versus enoxaparin for thromboprophylaxis after total knee arthroplasty (RECORD4) : a randomised trial. *Lancet* 2009 ; 373 : 1673-80
- 9) Patel MR, Mahaffey KW, Garg J, et al: Rivaroxaban versus warfarin in nonvalvular atrial fibrillation. *N Engl J Med* 2011 ; 365 : 883-91
- 10) Eriksson BI, Quinlan DJ, Weitz JI: Comparative pharmacodynamics and pharmacokinetics of oral direct thrombin and factor Xa inhibitors in development. *Clin Pharmacokinet* 2009 ; 48 : 1-22
- 11) Granger CB, Alexander JH, McMurray JJ, et al: Apixaban versus warfarin in patients with atrial fibrillation. *N Engl J Med* 2011 ; 365 : 981-92
- 12) Grand'Maison A, Charest AF, Geerts WH: Anticoagulant use in patients with chronic renal impairment. *Am J Cardiovasc Drugs* 2005 ; 5 : 291-305

## 12. 抗凝固療法-薬理と周術期管理

---

- 13) Douketis JD, Spyropoulos AC, Spencer FA, et al: Perioperative management of antithrombotic therapy: Antithrombotic Therapy and Prevention of Thrombosis, 9th ed: American College of Chest Physicians Evidence-Based Clinical Practice Guidelines. Chest 2012; 141: e326 S-50 S
- 14) Horlocker TT, Wedel DJ, Rowlingson JC, et al: Regional anesthesia in the patient receiving antithrombotic or thrombolytic therapy: American Society of Regional Anesthesia and Pain Medicine Evidence-Based Guidelines (Third Edition). Reg Anesth Pain Med 2010; 35: 64-101
- 15) Working Party: Association of Anaesthetists of Great Britain & Ireland, Obstetric Anaesthetists' Association, Regional Anaesthesia UK. Regional anaesthesia and patients with abnormalities of coagulation: the Association of Anaesthetists of Great Britain & Ireland The Obstetric Anaesthetists' Association Regional Anaesthesia UK. Anaesthesia 2013; 68: 966-72
- 16) Gogarten W, Vandermeulen E, Van Aken H, et al: Regional anaesthesia and antithrombotic agents: recommendations of the European Society of Anaesthesiology. Eur J Anaesthesiol 2010; 27: 999-1015
- 17) Sie P, Samama CM, Godier A, et al: Surgery and invasive procedures in patients on long-term treatment with direct oral anticoagulants: thrombin or factor-Xa inhibitors. Recommendations of the Working Group on Perioperative Haemostasis and the French Study Group on Thrombosis and Haemostasis. Arch Cardiovasc Dis 2011; 104: 669-76
- 18) Stangier J, Rathgen K, Stahle H, et al: Influence of renal impairment on the pharmacokinetics and pharmacodynamics of oral dabigatran etexilate: an open-label, parallel-group, single-centre study. Clin Pharmacokinet 2010; 49: 259-68
- 19) Eerenberg ES, Kamphuisen PW, Sijpkens MK, et al: Reversal of rivaroxaban and dabigatran by prothrombin complex concentrate: a randomized, placebo-controlled, crossover study in healthy subjects. Circulation 2011; 124: 1573-9
- 20) Fukuda T, Honda Y, Kamisato C, et al: Reversal of anticoagulant effects of edoxaban, an oral, direct factor Xa inhibitor, with haemostatic agents. Thromb Haemost 2012; 107: 253-9
- 21) Godier A, Miclot A, Le Bonniec B, et al: Evaluation of prothrombin complex concentrate and recombinant activated factor VII to reverse rivaroxaban in a rabbit model. Anesthesiology 2012; 116: 94-102

\* \* \*

## Contemporary open aortic arch repair with selective cerebral perfusion in the era of endovascular aortic repair

Yutaka Iba, MD,<sup>a</sup> Kenji Minatoya, MD, PhD,<sup>a</sup> Hitoshi Matsuda, MD, PhD,<sup>a</sup> Hiroaki Sasaki, MD, PhD,<sup>a</sup> Hiroshi Tanaka, MD, PhD,<sup>a</sup> Junjiro Kobayashi, MD, PhD,<sup>a</sup> and Hitoshi Ogino, MD, PhD<sup>b</sup>

**Objective:** With the recent advance of endovascular aortic repair, conventional open repair for aortic arch lesions should be reassessed. We reviewed our contemporary open arch repair with selective antegrade cerebral perfusion by way of the axillary artery with deep or moderate hypothermia.

**Methods:** From 2001 to 2011, 1007 patients (median age, 72 years) underwent open arch repair with selective cerebral perfusion through the right axillary artery and hypothermic circulatory arrest: deep (<25°C) in 48% and moderate (25°-28°C) in 52%. Of the 1007 patients, 73% underwent total arch replacement and 26% emergent surgery for aneurysm rupture or acute aortic dissection.

**Results:** The early mortality was 4.7% for all patients. Permanent and temporary neurologic dysfunction occurred in 3.5% and 6.7%, respectively. No spinal cord injury occurred, even with moderate hypothermia. The independent predictors of in-hospital mortality included chronic obstructive pulmonary disease, liver dysfunction, chronic kidney disease, and concomitant coronary artery bypass. The independent predictors of permanent neurologic dysfunction included cerebrovascular disease, emergency surgery, and concomitant coronary artery bypass. The cumulative survival rate was 80.4% and 71.2% at 5 and 8 years, respectively. Freedom from reoperation related to the initial arch repair was 98.0% and 96.9% at 5 and 8 years, respectively.

**Conclusions:** Conventional open arch repair yielded satisfactory outcomes and should remain the standard therapy, with good long-term durability in all but high-risk patients. (*J Thorac Cardiovasc Surg* 2013;145:S72-7)

Open surgical repair for aortic arch aneurysm is associated with considerable mortality and morbidity, especially stroke. However, its outcome has been dramatically improved by innovations in surgical technique, including brain protection, in the past 2 decades. In particular, the widespread use of antegrade selective cerebral perfusion (SCP) for cerebral protection has contributed to the reduction in mortality and stroke rate.<sup>1-4</sup> However, thoracic endovascular aortic repair (TEVAR) has been recognized as an alternative therapeutic option for thoracic aortic aneurysm, and it has been attempted, mainly for high-risk patients. Although this new technology was initially applied for descending aortic aneurysm, its adoption has extended to complex aortic arch lesions, predominantly in conjunction with several debranching techniques of the arch vessels as a less-invasive alternative: hybrid TEVAR.<sup>5,6</sup> Thus, contemporary open arch repair needs to be reassessed as

a benchmark for consideration of the optimal therapeutic strategy for aortic arch aneurysm. In the present study, the results with our well-established contemporary open arch repair procedure during the past decade—with sophisticated SCP by way of right axillary artery (RAXA) perfusion and hypothermic circulatory arrest (HCA)—were reviewed.

### PATIENTS AND METHODS

From April 2001 to September 2011, 1007 consecutive patients underwent open aortic arch repair at the National Cerebral and Cardiovascular Center, Japan. The inclusion criteria included an approach through a median sternotomy, the use of SCP with HCA, and hemi- or partial or total prosthetic replacement of the aortic arch. The patient characteristics are listed in Table 1. The median age was 72 years, and 66.3% of patients were men. The present cohort included 30 patients (3.0%) who had a connective tissue disorder such as the Marfan or Loeys-Dietz syndrome. Of the 1007 patients, 33 (3.3%) had a history of previous cardiac surgery and 38 (3.8%) had undergone previous aortic surgery of the aortic root, ascending aorta, or aortic arch. Aortic pathologic features included acute type A aortic dissection in 230 patients (22.8%). Emergency operations were performed in 259 patients (25.7%), including 76 (7.5%) with shock.

The surgical variables are listed in Table 2. In most patients (73.1%), total arch replacement (TAR) was performed. Concomitantly, coronary artery bypass grafting (CABG) was performed in 186 patients (18.5%) and root replacement in 59 (5.9%).

Data were collected from the medical records for the patients who were followed up in our outpatient department. The data for the others were investigated by telephone or mail. The follow-up rate was 93.0%. The mean follow-up period was 44.9 ± 33.7 months, with a maximum of 128 months. The institutional review board of our center approved the present retrospective study and waived patient consent on the condition that the patients were not identified.

From the Department of Cardiovascular Surgery,<sup>a</sup> National Cerebral and Cardiovascular Center, Suita, Osaka, Japan; and Department of Cardiovascular Surgery,<sup>b</sup> Tokyo Medical University, Shinjuku-ku, Tokyo, Japan.

Disclosures: Drs Iba, Minatoya, Matsuda, Sasaki, Tanaka, Kobayashi, and Ogino have nothing to disclose with regard to commercial support.

Presented at the American Association for Thoracic Surgery Aortic Surgery Symposium 2012, April 26-27, 2012, New York, NY.

Received for publication April 26, 2012; revisions received Aug 13, 2012; accepted for publication Nov 20, 2012; available ahead of print Dec 26, 2012.

Address for reprints: Yutaka Iba, MD, Department of Cardiovascular Surgery, National Cerebral and Cardiovascular Center, 5-7-1 Fujishiro-dai, Suita, Osaka 565-8565, Japan (E-mail: iba@hsp.ncvc.go.jp).

0022-5223/\$36.00

Copyright © 2013 by The American Association for Thoracic Surgery

http://dx.doi.org/10.1016/j.jtcvs.2012.11.047

### Abbreviations and Acronyms

CABG	= coronary artery bypass grafting
CKD	= chronic kidney disease
COPD	= chronic obstructive pulmonary disease
CVD	= cerebrovascular disease
HCA	= hypothermic circulatory arrest
PND	= permanent neurologic dysfunction
RAXA	= right axillary artery
SCP	= selective cerebral perfusion
TAR	= total arch replacement
TEVAR	= thoracic endovascular aortic repair

### Operative Techniques

The details of our surgical technique of open arch repair have been previously reported.<sup>7-10</sup> Aortic arch aneurysms were approached through a median sternotomy. For establishment of cardiopulmonary bypass, perfusion by way of the distal part of the RAXA in the axilla was routinely used, in conjunction with ascending aortic or femoral artery cannulation. Our routine brain protection was SCP, with perfusion through the RAXA and 2 other arch vessels, with deep or moderate HCA. In the early series, the lowest bladder and nasopharyngeal temperatures during HCA were 16° to 22°C. With the increase in our experience, both temperatures were increased gradually to 28°C, except for high-risk patients with cerebrovascular disease (CVD) or chronic kidney disease (CKD). Thus, for 529 patients (52.5%), moderate HCA of 25° to 28°C was applied. After the introduction of HCA, RAXA perfusion enabled quick conversion to SCP by clamping the innominate artery. After the ascending aorta and aortic arch were opened, balloon-tipped SCP cannulas were inserted into the left carotid and left subclavian arteries.

Open distal anastomosis was performed during HCA of the lower body. In TAR, a stepwise distal anastomosis was frequently used for an easy and secure anastomosis. An invaginated tube graft was inserted into the descending aorta. The proximal end was anastomosed to the descending aorta, and the distal end of the inserted graft was extracted proximally. Debris was flushed from the descending aorta by femoral artery perfusion. The multibranched arch graft was connected to this interposed graft. Then, the systemic circulation was resumed through a side branch of the arch graft. The left subclavian artery was reconstructed using a branch of the main graft, and the patient was rewarmed to 30° to 32°C. The proximal aortic anastomosis was made above the sinotubular junction. Finally, the coronary circulation was initiated by unclamping the main graft. The other 2 arch vessels were reconstructed with branch grafts, and the patient was fully rewarmed.

### Definitions

Early mortality was defined as death during the hospitalization or within 30 days postoperatively. Permanent neurologic dysfunction (PND) was defined as the presence of either new focal or global permanent neurologic dysfunction persisting at discharge. Transient neurologic dysfunction was defined as the presence of postoperative reversible motor deficit, confusion, agitation, or transient delirium, with normal computed tomography findings of the brain and resolution of all symptoms before discharge. CVD included a history of cerebrovascular event or a severe carotid artery lesion with more than 75% stenosis or multiple plaques on the ultrasound examination. Chronic obstructive pulmonary disease (COPD) was defined as

a forced expiratory volume less than 70% of the normal value or daily use of a bronchodilator. Liver dysfunction was defined as a serum transaminase level more than twice the normal value or a total bilirubin level greater than 2.0 mg/dL. CKD was defined as a serum creatinine level greater than 1.5 mg/dL or a requirement for hemodialysis.

### Statistical Analysis

Continuous data are presented as the mean  $\pm$  standard deviation. Multivariate stepwise logistic analysis was used to identify independent predictors for early mortality and PND. The predictive factors with  $P \leq .1$  on univariate analysis were used for subsequent multivariate analysis. The results are presented as the odds ratios and 95% confidence intervals. Cumulative survival and freedom from reoperation rates were calculated using the Kaplan-Meier methods. All statistical analyses were performed using SPSS software (IBM SPSS Inc, Chicago, Ill).

### RESULTS

The overall early mortality, including 30-day and in-hospital deaths, was 4.7%. It was 5.0% even for the emergency cases. The cause of early death was low output syndrome in 16 patients (34.0%), sepsis in 15 patients (31.9%), respiratory failure in 10 patients (21.3%), rupture of residual aneurysm in 3 patients (6.4%), and intestinal ischemia in 3 patients (6.4%). On multivariate analysis, the independent risk factors for early mortality were COPD ( $P = .041$ ), liver dysfunction ( $P = .014$ ), CKD ( $P < .001$ ), and concomitant CABG ( $P < .001$ ; Table 3).

Cerebral deficits developed in 102 patients (10.2%) postoperatively, including PND in 35 patients (3.5%) and transient neurologic dysfunction in 67 (6.7%). No spinal cord injury occurred in any patient. The multivariate analysis showed that the independent predictors for PND were CVD ( $P = .002$ ), emergency surgery ( $P < .001$ ), and concomitant CABG ( $P = .006$ ; Table 4).

Prolonged ventilation—for more than 72 hours—was required for 146 patients (14.5%). The length of stay in the intensive care unit and duration of postoperative hospitalization was 3 days (interquartile range, 2-6 days) and 25 days (interquartile range, 19-35 days), respectively.

During the follow-up period, there were 140 late deaths (14.6%). Of these, 13 were aorta-related deaths, including rupture of a descending thoracic aneurysm in 5, an abdominal aortic aneurysm in 5, and sudden death in 3. Of the 10 patients with aneurysm rupture, regular examinations at the hospital had been suspended for 5, and the remaining 5 patients had been observed medically because of their condition or their wish. Cardiac-related deaths occurred in 25 patients (17.9%), including congestive heart failure in 14, acute myocardial infarction in 8, and arrhythmia in 3. Other nonaortic- or noncardiac-related deaths occurred as follows: respiratory failure in 28 patients (20.0%), cancer in 21 (15.0%), cerebrovascular accident in 16 (11.4%), sepsis in 10 (7.1%), gastrointestinal complications in 5 (3.6%), renal failure in 4 (2.9%), accidents in 4 (2.9%), senility in 7 (5.0%), and unknown in 7 (5.0%). The cumulative survival was 80.4% and 71.2% at 5 and 8 years, respectively (Figure 1).

TABLE 1. Patient characteristics (n = 1007)

Characteristic	Value
Age (y)	
Median	72
Range	12-93
Male gender	668 (66.3%)
Hypertension	828 (82.2%)
Diabetes	149 (14.8%)
Hyperlipidemia	381 (37.8%)
Smoking	221 (21.9%)
Cerebrovascular disease	124 (12.3%)
Coronary artery disease	280 (27.8%)
Ejection fraction <30%	14 (1.4%)
COPD	116 (11.5%)
Liver dysfunction	16 (1.6%)
CKD (creatinine ≥ 1.5 mg/dL)	104 (10.3%)
Patients with CKD requiring hemodialysis	16
Connective tissue disorder	30 (3.0%)
Marfan syndrome	25
Loeys-Dietz syndrome	5
Aortitis	23 (2.3%)
Previous cardiac surgery	33 (3.3%)
Aortic redo surgery	38 (3.8%)
Shock	76 (7.5%)
Emergency	259 (25.7%)
Acute dissection	230 (22.8%)

COPD, Chronic obstructive pulmonary disease; CKD, chronic kidney disease.

Late aortic operations related to the previously repaired arch segment were required for false aneurysm of the anastomotic site in 12 patients and for graft infection in 2. Of the patients with false aneurysms at the distal anastomotic site, 8 underwent TEVAR. Four patients who developed false aneurysms at the proximal anastomotic site and two who developed graft infection underwent redo graft replacement of the aortic arch. Freedom from reoperation for the initially repaired arch segment was 98.0% and 96.9% at 5 and 8 years, respectively (Figure 2, A). Other late aortic reoperations unrelated to the initial aortic arch replacement included composite graft replacement in 6, valve-sparing root replacement in 2, completion arch replacement after hemiarch repair in 5, descending aortic replacement in 36, thoracoabdominal aortic replacement in 28, abdominal aortic repair in 59, and endovascular repair of the descending aorta in 46 and the abdominal aorta in 10 patients. Freedom from all late aortic reoperations at 5 and 8 years was 78.0% and 71.7%, respectively (Figure 2, B).

DISCUSSION

Open aortic arch repair remains challenging, with some difficulties. In most patients, the etiology of the arch aneurysm is atherosclerosis; therefore, most of patients are quite elderly and have many atherosclerotic lesions. However, recent advances in brain protection, surgical techniques, anesthesia, and critical care have improved the surgical

TABLE 2. Surgical procedures

Variable	Value
Extent of graft replacement	
Total arch replacement	736 (73.1%)
Partial arch replacement	28 (2.8%)
Hemiarch replacement	243 (24.1%)
Concomitant procedure	
CABG	186 (18.5%)
Root replacement	59 (5.9%)
Composite graft	47
Aortic valve sparing	12
Aortic valve replacement	85 (8.4%)
Aortic valve repair	2 (0.2%)
Sinotubular junction plication	63 (6.3%)
Mitral valve replacement	5 (0.5%)
Mitral valve repair	10 (1.0%)
Tricuspid annuloplasty	9 (0.9%)
Maze	6 (0.6%)
Intraoperative variables	
Lower body circulatory arrest time (min)	55.5 ± 17.6
Selective cerebral perfusion time (min)	129.4 ± 67.0
Myocardial ischemic time (min)	139.3 ± 53.9
Cardiopulmonary bypass time (min)	240.3 ± 99.2
Core temperature at HCA	
Moderate (25°-28°C)	529 (52.5%)
Deep (<25°C)	478 (47.5%)

CABG, Coronary artery bypass grafting; HCA, hypothermic circulatory arrest.

outcomes. Thus, antegrade SCP with HCA has achieved widespread acceptance as a reliable brain protection technique.<sup>1-4</sup> Recent reports have suggested some refinement of surgical techniques, in addition to SCP, and have demonstrated lower mortality rates of 4% to 8%.<sup>4,11-15</sup> A gradual increase of the core temperature during HCA from deep to moderate hypothermia has been encouraged to avoid deep hypothermia-associated coagulopathy and reduce the inflammatory substances associated with prolonged cardiopulmonary bypass.<sup>4,16</sup> Our current basic management of the core temperature during HCA with SCP is moderate hypothermia, which has produced favorable outcomes in aortic arch surgery.<sup>17</sup> However,

TABLE 3. Risk factors for in-hospital mortality

Factor	Univariate	Multivariate	
	P value	P value	OR 95% CI
Previous cardiac surgery	.063	.234	
CAD	<.001	.223	
COPD	.009	.041	2.157 1.030-4.518
Liver dysfunction	.007	.014	5.629 1.419-22.331
CKD (creatinine > 1.5 mg/dL)	<.001	<.001	4.637 2.392-8.988
Concomitant CABG	<.001	<.001	3.424 1.837-6.382
Deep hypothermia (<25°C)	.089	.476	

OR, Odds ratio; CI, confidence interval; CAD, coronary artery disease; COPD, chronic obstructive pulmonary disease; CKD, chronic kidney disease; CABG, coronary artery bypass grafting.

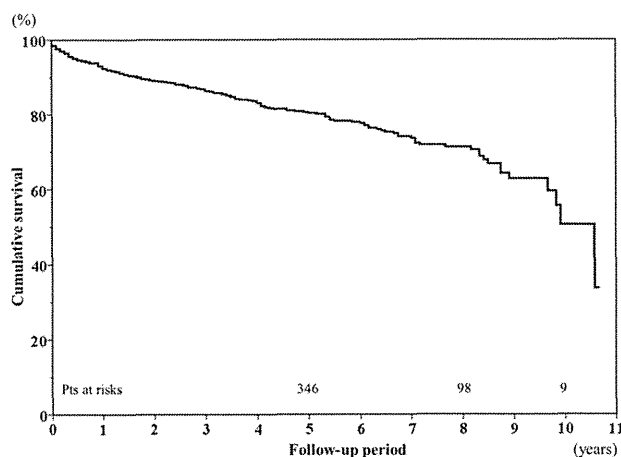
**TABLE 4. Risk factors for permanent neurologic dysfunction**

Factor	Univariate	Multivariate		
	P value	P value	OR	95% CI
Elderly (age $\geq$ 75 y)	.073	.068		
CVD	<.001	.002	3.374	1.589-7.162
CKD (creatinine > 1.5 mg/dL)	.081	.201		
Emergent surgery	.002	<.001	4.013	1.887-8.535
Concomitant CABG	.044	.006	3.119	1.379-7.057

OR, Odds ratio; CI, confidence interval; CVD, cerebrovascular disease; CKD, chronic kidney disease; CABG, coronary artery bypass grafting.

deep hypothermia of about 22°C, which has a great advantage for more secure brain, spinal cord, and visceral organ protection during HCA, is still used in selected higher risk patients with severe CVD and CKD or requiring a longer duration of HCA of the lower body because of anticipated difficulty in performing the distal anastomosis to the descending aorta.<sup>10</sup>

To the best of our knowledge, the present study is the largest scale study of open aortic arch replacement. The period of surgery was limited to 10 years, and a similar surgical technique—including SCP with RAXA perfusion—was used for all cases. Thus, we believe the outcome is worthy of assessment. The mortality rate of 4.7% is comparable to those of recent other reports,<sup>4,11-15</sup> with a range of 4% to 9%, although more than 70% of our patients underwent more extensive TAR and 25% were emergency cases. In addition, 15.5% of the patients were older than 80 years, and 24.4% required concomitant coronary or aortic root surgery. At least 10 surgeons—including some residents—were involved in the present series of arch repairs. In terms of the incidence of neurologic deficits, although the overall rate of 10.2% was similar, the stroke (PND) rate of 3.3% was lower than those of other reports (4%-7%). We believe our



**FIGURE 1.** Survival curve for all patients by Kaplan-Meier method. Cumulative survival rate was 80.4% and 71.2% at 5 and 8 years, respectively.

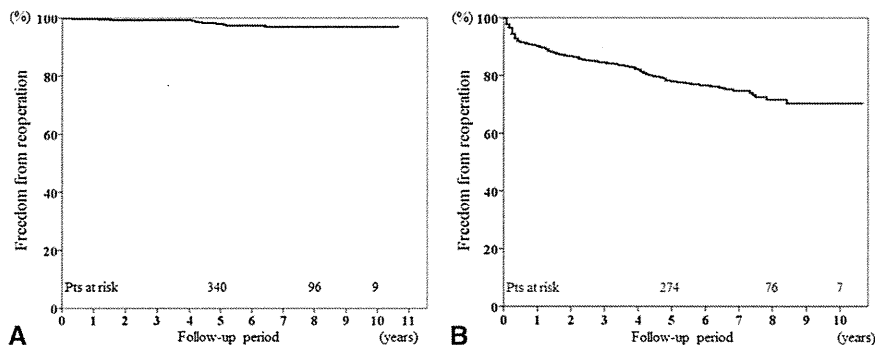
outcomes have been so satisfactory that our contemporary aortic arch replacement technique should be recognized as the standard repair for arch aneurysms.

With regard to risk factor analyses, the independent risk factors for early mortality were COPD, liver dysfunction, CKD, and concomitant CABG. The number of in-hospital deaths from respiratory failure, in particular, interstitial pneumonia or pulmonary fibrosis, has recently increased with the increase in patient age. These serious complications seem to be untreatable after their occurrence postoperatively. For these patients, arch TEVAR should be recommended. Regarding CKD and concomitant CABG, most such patients have more severe atherosclerosis and are critically compromised hosts, with diabetes and hemodialysis. For some of these patients, percutaneous coronary intervention before arch repair might be a good option to improve the outcome.

In terms of PND, CVD, emergency operation, and concomitant CABG were risk factors. The former 2 factors are easily recognized as risk factors for stroke. More meticulous brain protection with deep hypothermia is recommended for such conditions. A requirement for concomitant CABG is another risk factor for stroke. We believe this did not result from technical problems, but rather that these patients tended to have severe atherosclerotic vascular lesions, particularly in the aorta, arch vessels, or intracranial arteries, which might be related to the occurrence of stroke.

Regarding the technical aspect, our aortic arch repair technique has some characteristic features. The first is our routine use of RAXA perfusion by simple direct cannulation in the axilla.<sup>7</sup> It can be established easily and quickly, even in an emergency setting, and can prevent the cerebral emboli caused by retrograde femoral artery perfusion. Right-sided SCP through the RAXA can also be quickly achieved by simple clamping of the innominate artery. The second characteristic strategy is a preference for the use of stepwise distal anastomosis with a mini- or standard elephant trunk insertion for easier and more secure anastomoses for TAR.<sup>8</sup> The third technique is separate reconstruction of the arch vessels using a multibranch prosthetic graft for TAR.<sup>2</sup> We are encouraged to thoroughly remove the atheromatous arterial wall around the origin of the arch vessels and to perform the anastomosis at less atherosclerotic parts of the arch vessels, resulting in fewer embolic cerebrovascular events.

Long-term survival after open aortic arch repair has been demonstrated in some other reports. Kazui and colleagues<sup>2</sup> reported an actuarial survival at 5 and 7 years of 79% and 77%, respectively, and a recent report by Patel and colleagues<sup>12</sup> demonstrated a 12-year survival of 51.2%. Their survival curves were similar to ours, with 80.4% and 71.7% survival at 5 and 8 years, respectively. The median patient age in the present series was 72 years, and some of our



**FIGURE 2.** A, Kaplan-Meier analysis of freedom from reoperation related to initial arch repair. The rate of freedom from reoperation for the initially repaired arch segment was 98.0% and 96.9% at 5 and 8 years, respectively. B, Kaplan-Meier analysis of freedom from all aortic reoperation, including other segments. Freedom from late aortic surgery was 78.0% and 71.7% at 5 and 8 years, respectively.

patients died of cancer. Thus, we believe the long-term survival rate was acceptable in our patient cohort.

Furthermore, reoperation related to the initial arch repair during follow-up—for anastomotic false aneurysm or graft infection—was very rare. Most secondary aortic interventions after open arch repair were necessary for the other aortic lesions, including the aortic root, descending aorta, or abdominal aorta. For anastomotic false aneurysm, open repair or TEVAR can be successfully performed. In particular, TEVAR is easily applied to such limited lesions, with the proximal landing zone in the arch graft.

However, endovascular treatments have expanded in the past decade, and in 2008 some commercially available devices for TEVAR were introduced in Japan. Since then, our surgical strategy for aortic arch aneurysm has gradually shifted toward TEVAR. Currently, open aortic repair remains our basic surgical option, because it has been well established and has provided satisfactory early and long-term outcome. However, for its **lesser invasiveness**, this new surgical technique—including hybrid TEVAR—has been applied predominantly in limited high-risk patients, including the elderly (>75 years old), patients with severe comorbidities (eg, impaired cardiac, pulmonary, liver, or renal function), and those with a history of previous cardiac surgery.<sup>18</sup> Some reports of hybrid arch procedures have demonstrated an overall mortality rate of 3.2% to 11% and a stroke rate of 0% to 11%.<sup>5,6,19,20</sup> A recent meta-analysis of 463 patients who underwent hybrid arch surgery reported a 30-day mortality of 8.3% and an incidence of stroke and paraplegia of 4.4% and 3.9%, respectively.<sup>21</sup> Although the study included high-risk patients unsuitable for conventional open aortic repair, the mortality was slightly greater rather than the current results of open arch surgery, including in our study. In addition, the meta-analysis had a mean follow-up period of 18.9 to 61 months, leaving the long-term results still unclear.

Several innovations in endovascular devices and techniques have occurred within the past few years. For

instance, the chimney graft technique, involving the supra-aortic branches, which can treat up to zone 0 lesions without sternotomy, was recently introduced. Gehringhoff and colleagues<sup>22</sup> reported their experience using this technique for aortic arch pathologic features in 9 patients. In that report, 1 patient (11.1%) underwent surgical arch replacement because of a persistent type I endoleak, and 1 early death (11.1%) occurred. However, the safety and durability of these new techniques remains unclear, and future studies are necessary.

Comparing the outcomes between open aortic repair and TEVAR is complicated by the patient selection bias. In general, arch TEVAR has been indicated for higher risk patients with severe comorbidities. Milewski and colleagues<sup>19</sup> reported that hybrid arch procedures have their primary benefit in high-risk cases, especially elderly patients previously considered at prohibitively high risk to undergo conventional open arch repair. In the present analysis, the risk factors for early mortality were COPD, liver dysfunction, and CKD. We agree that arch TEVAR is a beneficial therapeutic option for patients expected to experience high mortality and morbidity with conventional open arch repair. However, we are skeptical about the adoption of this new technology for patients with a reasonable operative risk and younger patients, especially those with connective tissue disorders, because the mid- and long-term outcomes of TEVAR are still unclear. We have experienced extremely difficult and high-risk surgical conversion after TEVAR required for endoleak, infection, and esophageal fistula in some patients. These less-invasive TEVAR repairs, including hybrid procedures, should still be applied predominantly in high-risk patients with advanced age or many comorbidities.

The present study had some limitations. It was a retrospective study of a single group of patients who underwent open aortic arch repair with SCP. To compare the results of the 2 surgical strategies more clearly, a multicenter, prospective, randomized study is required.

## CONCLUSIONS

A well-established contemporary open aortic arch repair using SCP with hypothermia produced satisfactory early and long-term outcomes and remains a standard therapy with good long-term durability. It is highly recommended, except for high-risk patients.

## References

- Bachet J, Guilmet D, Goudot B, Dreyfus GD, Delentdecker P, Brodaty D, et al. Antegrade cerebral perfusion with cold blood: a 13-year experience. *Ann Thorac Surg.* 1999;67:1874-8.
- Kazui T, Washiyama N, Muhammad BA, Terada H, Yamashita K, Takinami M, et al. Total arch replacement using aortic arch branched grafts with the aid of antegrade selective cerebral perfusion. *Ann Thorac Surg.* 2000;70:3-9.
- Kazui T, Yamashita K, Washiyama N, Terada H, Bashar AH, Suzuki K, et al. Aortic arch replacement using selective cerebral perfusion. *Ann Thorac Surg.* 2007;83:S796-8.
- Zierer A, Detho F, Dzemali O, Aybek T, Moritz A, Bakhtiari F. Antegrade cerebral perfusion with mild hypothermia for aortic arch replacement: single-center experience in 245 consecutive patients. *Ann Thorac Surg.* 2011;91:1868-74.
- Zhou W, Reardon M, Peden EK, Lin PH, Lumsden AB. Hybrid approach to complex thoracic aortic aneurysms in high-risk patients: surgical challenges and clinical outcome. *J Vasc Surg.* 2006;44:688-93.
- Bavaria J, Milewski RK, Baker J, Moellaer P, Szeto W, Pochettino A. Classic hybrid evolving approach to distal arch aneurysms: toward the zone zero solution. *J Thorac Cardiovasc Surg.* 2010;140(6 Suppl):S77-80.
- Numata S, Ogino H, Sasaki H, Hanafusa Y, Hirata M, Ando M, et al. Total arch replacement using antegrade selective cerebral perfusion with right axillary artery perfusion. *Eur J Cardiothorac Surg.* 2003;23:771-5.
- Ogino H, Ando M, Sasaki H, Minatoya K. Total arch replacement using a stepwise distal anastomosis for arch aneurysms with distal extension. *Eur J Cardiothorac Surg.* 2006;29:255-7.
- Sasaki H, Ogino H, Matsuda H, Minatoya K, Ando M, Kitamura S. Integrated total arch replacement using selective cerebral perfusion: a 6-year experience. *Ann Thorac Surg.* 2007;83:S805-10.
- Ogino H, Sasaki H, Minatoya K, Matsuda H, Tanaka H, Watanuki H, et al. Evolving arch surgery using integrated antegrade selective cerebral perfusion: impact of axillary artery perfusion. *J Thorac Cardiovasc Surg.* 2008;136:641-9.
- Halkos ME, Kerendi F, Myung R, Kilgo P, Puskas JD, Chen EP. Selective antegrade cerebral perfusion via right axillary artery cannulation reduces morbidity and mortality after proximal aortic surgery. *J Thorac Cardiovasc Surg.* 2009;138:1081-9.
- Patel HJ, Nguyen C, Diener AC, Passow MC, Salata D, Deeb GM. Open arch reconstruction in the endovascular era: analysis of 721 patients over 17 years. *J Thorac Cardiovasc Surg.* 2011;141:1417-23.
- Kulik A, Castner CF, Kouchoukos NT. Outcomes after total aortic arch replacement with right axillary artery cannulation and a pre-sewn multibranch graft. *Ann Thorac Surg.* 2011;92:889-97.
- Thomas M, Li Z, Cook DJ, Greason KL, Sundt TM. Contemporary results of open aortic arch surgery. *J Thorac Cardiovasc Surg.* 2012;144:838-44.
- Okada K, Omura A, Kano H, Sakamoto T, Tanaka A, Okita Y, et al. Recent advancements of total aortic arch replacement. *J Thorac Cardiovasc Surg.* 2012;144:139-45.
- Kamiya H, Hagl C, Kropivnitskaya I, Böthig D, Kallenbach K, Khaladj N, et al. The safety of moderate hypothermic lower body circulatory arrest with selective cerebral perfusion: a propensity score analysis. *J Thorac Cardiovasc Surg.* 2007;133:501-9.
- Minatoya K, Ogino H, Matsuda H, Sasaki H, Tanaka H, Kobayashi J, et al. Evolving selective cerebral perfusion for aortic arch replacement: high flow rate with moderate hypothermic circulatory arrest. *Ann Thorac Surg.* 2008;86:1827-32.
- Murashita T, Matsuda H, Domae K, Iba Y, Tanaka H, Sasaki H, et al. Less invasive surgical treatment for aortic arch aneurysm in high-risk patients: a comparative study of hybrid thoracic endovascular aortic repair and conventional total arch replacement. *J Thorac Cardiovasc Surg.* 2012;143:1007-13.
- Milewski RK, Szeto WY, Pochettino A, Moser GW, Moeller P, Bavaria JE. Have hybrid procedures replaced open aortic arch reconstruction in high-risk patients? A comparative study of elective open arch debranching with endovascular stent graft placement and conventional elective open total and distal aortic arch reconstruction. *J Thorac Cardiovasc Surg.* 2010;140:590-7.
- Ferrero E, Ferri M, Viazzo A, Robaldo A, Zingarelli E, Sansone F, et al. Is total debranching a safe procedure for extensive aortic-arch disease? A single experience of 27 cases. *Eur J Cardiothorac Surg.* 2012;41:177-82.
- Koullias GJ, Wheatley GH III. State-of-the-art of hybrid procedures for the aortic arch: a meta-analysis. *Ann Thorac Surg.* 2010;90:689-97.
- Gehringhoff B, Torsello G, Pitoulias GA, Austerlmann M, Donas KP. Use of chimney grafts in aortic arch pathologies involving the supra-aortic branches. *J Endovasc Ther.* 2011;18:650-5.



# How should aortic arch aneurysms be treated in the endovascular aortic repair era? A risk-adjusted comparison between open and hybrid arch repair using a propensity score-matching analysis<sup>†</sup>

Yutaka Iba\*, Kenji Minatoya, Hitoshi Matsuda, Hiroaki Sasaki, Hiroshi Tanaka,  
Tatsuya Oda and Junjiro Kobayashi

Department of Cardiovascular Surgery, National Cerebral and Cardiovascular Center, Suita, Osaka, Japan

\* Corresponding author. Department of Cardiovascular Surgery, National Cerebral and Cardiovascular Center, 5-7-1 Fujishiro-dai, Suita, Osaka 565-8565, Japan. Tel: +81-6-68335012; fax: +81-6-68339865; e-mail: iba@ncvc.go.jp (Y. Iba).

Received 12 September 2013; received in revised form 15 November 2013; accepted 21 November 2013

## Abstract

**OBJECTIVES:** Recent advances in endovascular aortic repair have changed the treatment of aortic arch aneurysms. The purpose of this study was to compare the early and mid-term outcomes of open repair and hybrid arch repair for aortic arch aneurysms.

**METHODS:** This study included 143 and 50 patients who underwent open aortic repair and hybrid thoracic endovascular aortic repair (TEVAR), respectively, for non-dissecting aortic arch aneurysms from 2008 to 2013. The European System for Cardiac Operative Risk Evaluation II scores were  $4.35 \pm 3.65\%$  and  $7.78 \pm 5.49\%$  for the open and hybrid TEVAR groups, respectively ( $P < 0.001$ ). Furthermore, 35 patients from each group were matched using propensity scores to adjust for differences in patient characteristics.

**RESULTS:** There was no significant difference in early mortality between the open and hybrid groups (3 vs 2%,  $P = 0.76$ ). Early morbidity was equivalent in both groups, but intensive care unit (ICU) lengths of stay were shorter in members of the hybrid group (4.7 vs 1.6 days,  $P = 0.018$ ). During the follow-up, survival rates were not significantly different (87 vs 81% at 3 years,  $P = 0.13$ ), but reinterventions for the aortic arch were required in 1 patient (pseudoaneurysm) in the open group and 5 (endoleak in 4, brachiocephalic artery stenosis in 1) in the hybrid group. The rates of freedom from reintervention at 3 years were 99% in the open group and 80% in the hybrid group ( $P < 0.001$ ). Propensity score matching yielded similar results for shorter ICU and hospital lengths of stay and more frequent reintervention in the hybrid group.

**CONCLUSIONS:** Surgical outcomes in both groups were satisfactory. Hybrid TEVAR was superior in terms of early recovery from surgery; however, open arch repair showed more reliable long-term outcomes. When properly selected according to patient risk, these two strategies improve the surgical results in all patients with aortic arch aneurysms.

**Keywords:** Aortic arch aneurysms • Hybrid arch repair • Open arch repair • Endovascular procedures • Propensity score matching

## INTRODUCTION

Surgical treatment for aortic arch aneurysms has been considered challenging because of its significantly high mortality and morbidity. However, recent advances in surgical techniques and management have improved outcomes during the past two decades. In particular, the widespread use of selective cerebral perfusion (SCP) to prevent brain damage has contributed to lower mortality and stroke rate for open arch repair [1–4]. Endovascular aortic repair has been implemented as an alternative option for the treatment of aortic aneurysms. This new technology was used initially for descending thoracic and abdominal aortic aneurysms. However, with improvements in devices and techniques, the application of this endovascular repair modality has been extended to aortic arch lesions. Thoracic endovascular aortic repair (TEVAR) of the arch lesion often requires a supra-aortic bypass to debranch

the arch vessels; therefore, this less-invasive alternative technology is regarded as hybrid TEVAR [5, 6]. Ever since a commercially available TEVAR device was introduced in Japan in 2008 [7], this new surgical technique has been used at our institution mainly for high-risk patients such as elderly patients, those with severe comorbidities and those with a history of cardiac surgery.

Therefore, the surgical technique used for repairing aortic arch aneurysms must be reconsidered given the widespread application of hybrid TEVAR and the improved outcomes of open aortic arch repair. However, to our knowledge, few reports comparing the surgical outcomes of these two therapeutic strategies exist [8]. We assumed that this is perhaps related to the differences of pre-operative patient characteristics because hybrid TEVAR is usually indicated for high-risk patients.

In the present study, we assessed the early and mid-term results of open repair and hybrid arch repair for aortic arch aneurysms, and compared propensity score-matched groups for adjusting the differences in patient characteristics.

<sup>†</sup>Presented at the 27th Annual Meeting of the European Association for Cardio-Thoracic Surgery, Vienna, Austria, 5–9 October 2013.

## MATERIALS AND METHODS

From 2008 to 2013, 143 patients underwent total arch replacement (TAR) and 50 patients also underwent hybrid TEVAR for non-dissecting aortic arch aneurysms at our institution. The exclusion criteria included thoracic aneurysms extending below the level of the carina, acute or chronic aortic dissection, and those in patients requiring a concomitant cardiac procedure. The patient characteristics of both groups are listed in Table 1. The mean ages were  $72.1 \pm 9.2$  years in the TAR group and  $78.6 \pm 9.3$  years in the hybrid group ( $P < 0.001$ ). Six patients each in the TAR group (4%) and in the hybrid group (12%) had a past history of cardiac surgery ( $P = 0.049$ ). There were 3 (2%) patients with poor cardiac function in the TAR group and 5 (10%) in the hybrid group ( $P = 0.016$ ). European System for Cardiac Operative Risk Evaluation (EuroSCORE) II is a new model for calculating the risk of death after heart surgery [9]. EuroSCORE II was  $4.35 \pm 3.65\%$  for the TAR group and  $7.78 \pm 5.49\%$  for the hybrid group ( $P < 0.001$ ). Characteristics of a matched population according to propensity scores are given in Table 1, and the procedural details of TAR and hybrid TEVAR are given in Table 2.

Data were collected from the medical records for patients who visited our outpatient department for follow-up, and the data for the others were acquired by telephone or mail. The follow-up rate was 94% and the mean follow-up period was  $25 \pm 16$  months (1–63 months: median, 24 months). Our institution approved this retrospective study and patient consent was waived on the condition that the patients were not identified.

### Operative techniques

**Open arch repair (TAR).** The details of our surgical technique for open arch repair (TAR) have been reported previously [10–15]. Median sternotomy was performed as the approach to repair aortic arch aneurysms. To establish a cardiopulmonary bypass, perfusion using the distal part of the right axillary artery (RAXA) in the axilla

was routinely used together with ascending aortic or femoral artery cannulation. Our strategy for brain protection employed SCP with perfusion through the RAXA and two other arch vessels using hypothermic circulatory arrest (HCA). During the term of this study, we have preferably used moderate HCA of  $25^{\circ}\text{C}$ – $28^{\circ}\text{C}$  at the lowest bladder and nasopharyngeal temperatures, except in high-risk patients with cerebrovascular disease (CVD) or chronic kidney disease (CKD). After the induction of HCA, RAXA perfusion permitted rapid conversion to SCP by clamping the brachiocephalic artery (BCA). After the ascending aorta and aortic arch were opened, balloon-tipped SCP cannulas were inserted into the left common carotid artery (LCCA) and left subclavian artery (LSCA). Open distal anastomosis was performed during HCA of the lower body. A stepwise distal anastomosis was frequently used to perform an easy and secure anastomosis. An invaginated tube graft was inserted into the descending aorta. The proximal end was anastomosed to the descending aorta and the distal end of the inserted graft was extracted proximally. Debris was flushed from the descending aorta using femoral artery perfusion. The multibranched aortic arch graft was connected to this interposed graft. Systemic circulation was resumed through a side branch of the arch graft. The LSCA was reconstructed using a branch of the arch graft and the patient was rewarmed to  $30$ – $32^{\circ}\text{C}$ . The proximal aortic stump was anastomosed to the main graft above the sinotubular junction. Finally, the coronary circulation was initiated by unclamping the main graft. The other two arch vessels were reconstructed individually with the branch of the arch graft and the patient was fully rewarmed.

### Hybrid thoracic endovascular repair

**Zone 2 (n = 6).** In cases in which the RAXA was used as the inflow artery, both axillary arteries were exposed under the subclavicular incision. An 8 mm expanded polytetrafluoroethylene (ePTFE) graft was sutured onto both axillary arteries in a side-to-end fashion. In patients for whom the LCCA was used as the inflow, the LCCA and

**Table 1:** Patient characteristics

	Overall			Matched cohorts				
	TAR	Hybrid TEVAR	P-value	TAR	Hybrid TEVAR	P-value		
Number of patients	143	50		35	35			
Age (year)	$72.1 \pm 9.2$	$78.6 \pm 9.3$	<0.001	$76.3 \pm 8.5$	$75.7 \pm 9.3$	0.85		
Median	73	80		77	77			
Range	17–87	44–95		37–87	44–89			
Male gender	117	40	82%	25	29	71%	83%	0.26
Hypertension	127	48	89%	33	33	94%	94%	>0.99
Diabetes	23	9	16%	5	5	14%	14%	>0.99
Hypelipidaemia	64	18	45%	15	16	43%	46%	0.81
Prior cardiomy	6	6	4%	4	5	11%	14%	0.72
CVD	25	12	18%	12	9	34%	26%	0.43
Coronary artery disease	28	14	20%	8	10	23%	29%	0.58
Low ejection fraction (<40%)	3	5	2%	2	3	6%	9%	0.64
COPD	20	10	14%	5	7	14%	20%	0.53
Arteriopathy	63	25	44%	13	15	37%	43%	0.63
CKD (Creatinine>1.5)	18	8	13%	4	6	11%	17%	0.50
Emergency	12	1	8%	2	1	6%	3%	0.56
EuroSCORE II (%)	$4.35 \pm 3.65$	$7.78 \pm 5.49$	<0.001	$5.81 \pm 4.39$	$7.03 \pm 5.19$			0.46

COPD: chronic obstructive pulmonary disease, CKD: chronic kidney disease, EuroSCORE: European System for Cardiac Operative Risk Evaluation; TAR: total arch replacement; TEVAR: thoracic endovascular aortic repair.

**Table 2** Details of the procedures

Variables		
Open arch repair (TAR)		
Operation time (min)	393 ± 103	
Cardiopulmonary bypass time (min)	220 ± 49	
Myocardial ischaemic time (min)	128 ± 35	
Selective cerebral perfusion time (min)	148 ± 42	
Lower body circulatory arrest time (min)	63 ± 13	
Bleeding (ml)	2326 ± 1762	
Hybrid arch TEVAR		
Proximal landing zone of stent-graft		Design of bypass
Zone 0		
Total debranching bypass through sternotomy	14 (28%)	
	8	Asc Ao to BCA, LCCA and LSCA: 4 Asc Ao to BCA, LCCA and LxA: 4
Chimney graft technique and supra-aortic bypass	5	RCCA to LCCA and LxA: 4 RxA to LCCA and LxA: 1
Bypass from abdominal aorta	1	Abd Ao to RxA, LCCA and LxA: 1
Zone 1		
	30 (60%)	RxA to LCCA and LxA: 20 RxA to LCCA and LSCA: 5 RCCA to LCCA and LSCA: 3 RCCA to LCCA and LxA: 2
Zone 2		
	6 (12%)	RxA to LxA: 5 LCCA to LSCA: 1
Device		
TAG	41 (82%)	
Valiant	7 (14%)	
Talent	2 (4%)	

TEVAR: thoracic endovascular aortic repair; Asc Ao: ascending aorta; BCA: brachiocephalic artery; LCCA: left common carotid artery; LSCA: left subclavian artery; LxA: left axillary artery; RCCA: right common carotid artery; RxA: right axillary artery.

the LSCA were exposed through the same incision, and an ePTFE graft connected the LCCA to the LSCA in an end-to-side fashion.

**Zone 1 (n = 30).** Either the right common carotid artery (RCCA) or the RxA was chosen as the inflow artery. The RCCA and the LCCA were exposed through a middle cervical incision, and the RxA was exposed at the subclavicular incision. The LSCA was often exposed at the supraclavicular incision when the RCCA was the inflow artery for the bypass, and the left axillary artery (LxA) was exposed through the subclavicular incision when the RxA was the inflow artery. After systemic heparinization, a T-shaped branched-type 8-mm ePTFE graft was anastomosed.

**Zone 0 (n = 14).** In cases involving total debranching of the arch vessels, median sternotomy was performed. After systemic heparinization, the ascending aorta was partially clamped and a Dacron prosthetic graft was sutured in a side-to-end fashion. The BCA was clamped and divided while the mean systemic blood pressure was increased to >80 mmHg, reconstructed in an end-to-end fashion. Then, the LCCA was anastomosed in the same fashion. Next, the LSCA was reconstructed in an end-to-end fashion near its origin, or the LxA was reconstructed in a side-to-end fashion at the axillary segment. The origin of the LSCA was closed by coil embolization after TEVAR. In cases using the chimney graft technique, supra-aortic bypass was established in the same fashion as for Zone 1 landing, and a sheath was inserted through the RxA as a chimney graft access. The main device was advanced into the ascending aorta from the femoral artery to

provide a sufficient proximal landing zone. Furthermore, a self-expandable stent graft (Excluder Iliac Extender; W.L. Gore & Associates, Inc., Flagstaff, AZ, USA) was introduced into the ascending aorta from the RxA and positioned at the proximal edge of the main stent graft. Next, the stent graft in the BCA was deployed first, followed by the main stent graft.

The transfemoral approach was selected as the access route for main stent-graft placement, if possible. If the femoral artery was unsuitable as the access route, the external iliac artery was selected. The Gore TAG (W.L. Gore & Associates, Inc.) was used in 41 patients (84%), the Valiant (Medtronic, Inc., Minneapolis, MN, USA) was used in 7 patients (14%) and the Talent (Medtronic, Inc.) was used in 2 patients (2%). For preventing supra-aortic bypass graft occlusion, all patients were given low-dose aspirin. Warfarin was concomitantly administered to patients who had severely diseased arteries or whose left vertebral artery was reconstructed.

## Definitions

Early mortality was defined as death during hospitalization or within 30 days after surgery. Permanent neurological dysfunction (PND) was defined as the presence of either new permanent focal or global neurological dysfunction persisting at discharge. CVD included a history of cerebrovascular events or severe carotid artery lesions with >75% stenosis or multiple plaques revealed using ultrasound examination. Chronic obstructive pulmonary disease (COPD) was defined as a forced expiratory volume <70% of the normal value

or daily use of a bronchodilator. Arteriopathy was defined as previous or planned intervention on the abdominal aorta or coexistence of peripheral artery disease. CKD was defined as a serum creatinine level >1.5 mg/dl or a requirement for haemodialysis.

## Statistical analysis

Continuous variables were expressed as mean  $\pm$  standard deviation and compared using Student's *t*-test or the Mann-Whitney *U*-test. Category variables were compared using  $\chi^2$  tests or Fisher's exact tests. Survival and aortic reintervention-free rates were estimated using the Kaplan-Meier method, and differences between each group were determined using log-rank analysis. *P*-values <0.05 were considered significant. When we noted marked differences in a patient's preoperative characteristics, patient matching was employed to compare the results between both groups. Therefore, propensity score-matching analysis was performed to compensate for this difference. The propensity scores were estimated using multivariable logistic regression analyses for each patient, and the covariables included age, gender, hypertension, diabetes, hyperlipidemia, prior cardiectomy, CVD, coronary artery disease, poor cardiac function, COPD, arteriopathy, CKD and emergencies. A patient in the hybrid group was then matched with a patient in the TAR group with the closest propensity score, and the maximum difference of the propensity score was <0.02. Statistical analysis was performed using JMP version 9.0 (SAS Institute, Inc., Cary, NC, USA).

## RESULTS

### All patients

Early mortalities were 3 and 2% in the TAR and hybrid groups, respectively (*P*=0.76). The causes of early death in the TAR groups were sepsis in 2 patients and respiratory failure in 2 patients, and 1 patient in the hybrid group died because of cerebral infarction. PND developed in 3 patients each in the TAR (2%) and hybrid (6%) groups (*P*=0.17). No spinal cord injury occurred in either group. Renal failure requiring haemodialysis occurred in 2 patients (1% in the TAR group, but not in the hybrid group (*P*=0.40). Re-entry for bleeding was required necessary for 8 (6%) patients in the TAR

group and for 4 patients (8%) in the hybrid group (*P*=0.54). Prolonged ventilation for >72 h was required for 8 (6%) and 2 (4%) in the TAR and hybrid groups, respectively (*P*=0.66). The lengths of stay in the intensive care unit (ICU) were  $4.7 \pm 9.0$  and  $1.6 \pm 2.2$  days for the TAR and hybrid groups, respectively (*P*<0.001). The duration of postoperative hospitalization was  $32.9 \pm 35.7$  and  $25.9 \pm 29.5$  days in the TAR and the hybrid groups, respectively (*P*=0.001) (Table 3).

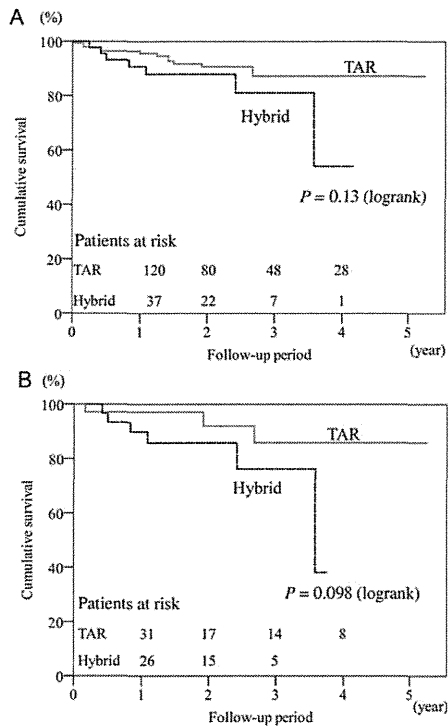
During the follow-up period, there were 9 deaths in the TAR group; 2 were cardiovascular related, including 1 due to ventricular arrhythmia and the other due to residual thoracoabdominal aortic aneurysm rupture. The patient with thoracoabdominal aortic aneurysm rupture had been observed medically because of her compromised condition. The other causes of late death were sepsis in 2, cancer in 2, gastrointestinal complication in 2 and pneumonia in 1. In contrast, there were 6 late deaths in the hybrid group, including respiratory failure in 3, a cerebrovascular event in 2 and due to cancer in 1. The cumulative survival rates at 1, 2 and 3 years were 96, 91 and 87%, respectively, in the TAR group and 91, 88 and 81%, respectively, in the hybrid group (*P*=0.13) (Fig. 1A).

Late reintervention for the previously repaired arch segment was required for 1 patient in the TAR group and 5 patients in the hybrid group. The patient in the TAR group received TEVAR for a pseudoaneurysm at a distal anastomotic site 1 month after TAR. In the hybrid group, the causes of late reintervention for the aortic arch were type Ia endoleak in 4 patients including one case of aneurysmal rupture, and BCA stent-graft stenosis after the chimney graft technique in 1 patient. In recurring cases of type Ia endoleak, 3 patients had endoleaks after the Zone 1 landing endografting and 1 had an endoleak at the Zone 2 landing. All reintervention cases of type Ia endoleak underwent another endografting, which was performed at a more proximal site. Of 3 cases of type Ia endoleak after TEVAR with Zone 1 landing, 1 patient underwent a total debranching bypass from the ascending aorta through a median sternotomy for Zone 0 landing TEVAR, and the other case received Zone 0 landing TEVAR using the chimney graft technique. The last case involved an additional left external iliac artery to supra-aortic bypass and followed Zone 0 landing endografting. The patient with endoleak after Zone 2 landing TEVAR underwent an additional LCCA bypass from the previous RxA-to-LxA bypass, and a Zone 1 landing endografting was performed. The remaining case of the BCA stenosis after the chimney graft technique received stenting using a bare stent. The rates of freedom from

**Table 3:** Early outcomes

	Overall			<i>P</i> -value	Matched cohorts			<i>P</i> -value
	TAR		Hybrid TEVAR		TAR		Hybrid TEVAR	
Number of patients	143		50		35		35	
In-hospital death	4	3%	1	0.76	1	3%	1	3%
PND	3	2%	3	0.17	0	0%	3	9%
Renal failure	2	1%	0	0.40	1	3%	0	0.31
Re-entry	8	6%	4	0.54	2	6%	3	9%
Prolonged ventilation	8	6%	2	0.66	2	6%	2	6%
ICU length of stay	$4.7 \pm 9.0$		$1.6 \pm 2.2$	<0.001	$4.8 \pm 5.1$		$1.8 \pm 2.5$	<0.001
Median (IQR)	3 (2-4)		1 (1-1)		3 (2-5)		1 (1-1)	
Hospitalization (day)	$32.9 \pm 35.7$		$25.9 \pm 29.5$	0.001	$32.8 \pm 21.3$		$27.7 \pm 31.4$	0.015
Median (IQR)	23 (16-30)		15 (11-29)		28 (18-38)		17 (11-31)	

PND: permanent neurological dysfunction; ICU: intensive care unit; IQR: interquartile range; TAR: total arch replacement; TEVAR: thoracic endovascular aortic repair.



**Figure 1:** Cumulative survival curve. (A) All patients. (B) Propensity score-matched cohorts of the TAR and hybrid groups.

reintervention for previously repaired arch segment at 1, 2 and 3 years were 99, 99 and 99%, respectively, in the TAR group, and 97, 86 and 80%, respectively, in the hybrid groups ( $P < 0.001$ ) (Fig. 2A).

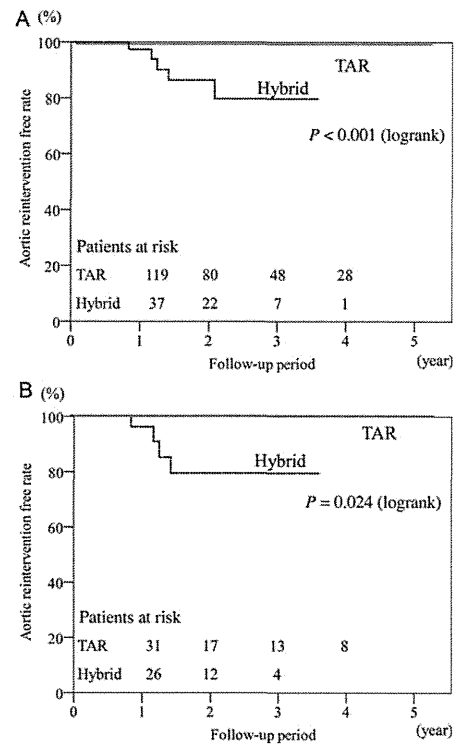
### Analysis of matched cohorts by propensity score matching

There was no significant difference in baseline patient characteristics of matched pairs (Table 1). The early mortality rate was identical (3%) in the TAR and hybrid groups. There was no significant difference in early morbidity in both groups, and the incidence of PND ( $P = 0.077$ ), postoperative renal failure ( $P = 0.31$ ), re-entry for bleeding ( $P = 0.64$ ) and prolonged ventilation ( $P > 0.99$ ). The ICU lengths of stay ( $P < 0.001$ ) and the duration of postoperative hospitalization ( $P = 0.015$ ) were significantly shorter in the hybrid group (Table 3). There was no significant difference in cumulative survival ( $P = 0.098$ ) (Fig. 1B); however, freedom from aortic reintervention for a previously repaired arch segment was higher in the hybrid group ( $P = 0.024$ ) (Fig. 2B).

### DISCUSSION

Because of the recent widespread application of endovascular aortic repair, the surgical strategy for aortic arch aneurysms needs to be reconsidered on the basis of recent outcomes of open arch repair and hybrid arch repair.

In open arch repair, recent advances in brain protection, surgical techniques, prosthetic grafts and critical care have improved surgical outcomes. Of these, antegrade SCP with HCA is widely accepted as a reliable technique for brain protection. Subsequent to the



**Figure 2:** Freedom from late aortic reintervention for previous arch repair. (A) All patients. (B) Propensity score-matched cohorts of the TAR and hybrid groups.

widespread use of SCP, some reports indicate that the core temperature at circulatory arrest should be increased from deep hypothermia to moderate or mild hypothermia to avoid deep hypothermia-associated coagulopathy and to decrease the level of inflammatory substances associated with prolonged cardiopulmonary bypass [4, 16]. Moreover, recent reports demonstrated that some refinement of technical aspects and modification of SCP resulted in lower mortality rates of 3.4–5.2% and lower incidence rates of PND of 2.5–6.7% [15–20]. Kazui *et al.* [2] reported actuarial survival rates at 5 and 7 years of 79 and 77%, respectively, and Patel *et al.* [17] reported a 12-year survival rate of 51.2%. Furthermore, we reported that the rate of freedom from aortic reintervention related to initial arch repair was 96.9% at 8 years [15].

The results of the present study indicate that our surgical technique of open arch repair, which included routine use of SCP, preferable application of moderate HCA and stepwise distal anastomosis, contributed to the low mortality rate of 3% and the lower incidence rate of PND of 2%. The data show that open arch repair was reliable with a remarkably lower incidence of aortic reintervention for previous aortic repair during follow-up.

Endovascular aortic repair has recently been recognized as an alternative therapy for thoracic aortic aneurysms because of its minimal invasiveness. This new technique requires a supra-aortic bypass or debranching of arch vessels with or without sternotomy to repair aortic arch lesions. Milewski *et al.* [6] also published a comparative study of open arch debranching with endovascular stent placement and conventional total and distal aortic arch reconstruction, which concluded that the hybrid arch approach had a lower mortality for high-risk patients aged more than 75 years. In our institution, this less-invasive alternative was applied predominantly to high-risk patients such as the elderly (>75 years of age), those with

severe comorbidities (e.g. impaired cardiac, pulmonary, liver or renal function) and those with a history of cardiac surgery [21]. Some reports of hybrid arch procedures reveal an early mortality rate of 7.4–23.7% and incidence rate of stroke of 0–13.1% [5, 6, 22, 23]. Furthermore, Koullias *et al.* [24] reported a meta-analysis of 463 patients who underwent hybrid arch surgery that reveals a 30-day mortality rate of 8.3% and incidence rates of stroke and paraplegia of 4.4 and 3.9%, respectively. Compared with these findings, our results for hybrid TEVAR are favourable with a low mortality rate of 2%, lower incidence rate of PND of 6% and no spinal cord injury.

Therefore, the optimal therapeutic strategy for aortic arch aneurysms should be considered on the basis of these recent data for both procedures. The results of a meta-analysis of open TAR vs hybrid TEVAR for aortic arch aneurysms showed that hybrid TEVAR did not significantly improve operative mortality, whereas it was associated with a slight, insignificant increase in PND. The authors concluded that no definitive evidence supports the superiority of the hybrid TEVAR relative to open arch repair [8]. However, most cases of employing hybrid TEVAR have included high-risk patients unsuitable for conventional open aortic repair. Thus, these results cannot be easily compared. Prospective randomized control trials seem to be the most desirable to compare the outcomes of both surgical strategies; however, this was difficult. To overcome this issue, we performed propensity score-matching analysis to compensate for the patient selection bias. This analysis shows that there were no significant differences in early mortality and PND incidence; however, the hybrid group experienced shorter ICU lengths of stay and lesser in-hospital days. In the mid-term follow-up, late survival rates were similar in both groups; however, more frequent late aortic reintervention occurred significantly in the hybrid group. Most of the reinterventions for previous aortic repair were performed for type Ia endoleaks, which caused further dilatation of the aneurysm with persistent risk of rupture. Hence, the superiority of hybrid TEVAR compared with open arch repair was not evident except for shorter ICU lengths of stay and lesser in-hospital days even in this matched analysis. Recently, Cao *et al.* [25] published a systematic review of the clinical outcomes for the hybrid arch procedure and concluded that the hybrid repair of the aortic arch carries not negligible risks of perioperative mortality and neurological morbidity, and also described that no reliable long-term data exist to ascertain the durability of the hybrid arch procedure. As we previously reported, we agree that hybrid TEVAR is a beneficial alternative for high-risk patients in whom high mortality and morbidity rates are expected by conventional open arch repair [21]. Hybrid arch TEVAR is still in a developing stage and new techniques such as the chimney stent graft technique, or new fenestrated or branched devices are under trial; however, we now advocate that the extended application of this new technology to patients with a reasonable risk should be reconsidered according to the results of the present risk-adjusted study. In any case, we should reconsider the classification criteria for regarding patients as high risk for aortic repair. Furthermore, we suggest that the establishment of a 'risk-oriented strategy' based on a proper risk evaluation for aortic repair is an important issue to be addressed in the future.

In conclusion, the recent outcomes of open arch repair and hybrid TEVAR demonstrate acceptable results, particularly early after the procedure; however, open arch repair provides more reliable outcomes in follow-up. These two surgical strategies when properly selected according to each patient's risk improve the surgical outcomes in all patients with aortic arch aneurysms. The limitations of this study include the size of each cohort and the small number of

matched pairs between both groups. Therefore, further investigations and follow-up are required to support decision-making in choosing a surgical strategy for aortic arch pathologies.

**Conflict of interest:** none declared.

## REFERENCES

- [1] Bachet J, Guilmet D, Goudot B, Dreyfus GD, Delentdecker P, Brodaty D *et al.* Antegrade cerebral perfusion with cold blood: a 13-year experience. *Ann Thorac Surg* 1999;67:1874–8.
- [2] Kazui T, Washiyama N, Muhammad BA, Terada H, Yamashita K, Takinami M *et al.* Total arch replacement using aortic arch branched grafts with the aid of antegrade selective cerebral perfusion. *Ann Thorac Surg* 2000;70:3–9.
- [3] Kazui T, Yamashita K, Washiyama N, Terada H, Bashar AH, Suzuki K *et al.* Aortic arch replacement using selective cerebral perfusion. *Ann Thorac Surg* 2007;83:S796–8.
- [4] Zierer A, Detho F, Dzemali O, Aybek T, Moritz A, Bakhtiyari F. Antegrade cerebral perfusion with mild hypothermia for aortic arch replacement: single-center experience in 245 consecutive patients. *Ann Thorac Surg* 2011;91:1868–74.
- [5] Czerny M, Gottardi R, Zimpfer D, Schoder M, Grabenwoger M, Lammer J *et al.* Mid-term results of supraaortic transpositions for extended endovascular repair of aortic arch pathologies. *Eur J Cardiothorac Surg* 2007;31:623–7.
- [6] Milewski RK, Szeto WY, Pochettino A, Moser GW, Moeller P, Bavaria JE. Have hybrid procedures replaced open aortic arch reconstruction in high-risk patients? A comparative study of elective open arch debranching with endovascular stent graft placement and conventional elective open total and distal aortic arch reconstruction. *J Thorac Cardiovasc Surg* 2010;140:590–7.
- [7] Sakata R, Fujii Y, Kuwano H. Thoracic and Cardiovascular surgery in Japan during 2008. *Gen Thorac Cardiovasc Surg* 2010;58:356–83.
- [8] Benedetto U, Melina G, Angeloni E, Codispoti M, Sinatra R. Current results of open total arch replacement versus hybrid thoracic endovascular aortic repair for aortic arch aneurysm: a meta-analysis of comparative studies. *J Thorac Cardiovasc Surg* 2013;145:305–6.
- [9] Nashaf SA, Roques F, Sharples LD, Nilsson J, Smith C, Goldstone AR *et al.* EuroSCORE II. *Eur J Cardiothorac Surg* 2012;41:734–44.
- [10] Numata S, Ogino H, Sasaki H, Hanafusa Y, Hirata M, Ando M *et al.* Total arch replacement using antegrade selective cerebral perfusion with right axillary artery perfusion. *Eur J Cardiothorac Surg* 2003;23:771–5.
- [11] Ogino H, Ando M, Sasaki H, Minatoya K. Total arch replacement using a stepwise distal anastomosis for arch aneurysms with distal extension. *Eur J Cardiothorac Surg* 2006;29:255–7.
- [12] Sasaki H, Ogino H, Matsuda H, Minatoya K, Ando M, Kitamura S. Integrated total arch replacement using selective cerebral perfusion: a 6-year experience. *Ann Thorac Surg* 2007;83:S805–10.
- [13] Minatoya K, Ogino H, Matsuda H, Sasaki H, Tanaka H, Kobayashi J *et al.* Evolving selective cerebral perfusion for aortic arch replacement: high flow rate with moderate hypothermic circulatory arrest. *Ann Thorac Surg* 2008;86:1827–31.
- [14] Ogino H, Sasaki H, Minatoya K, Matsuda H, Tanaka H, Watanuki H *et al.* Evolving arch surgery using integrated antegrade selective cerebral perfusion: impact of axillary artery perfusion. *J Thorac Cardiovasc Surg* 2008;136:641–9.
- [15] Iba Y, Minatoya K, Matsuda H, Sasaki H, Tanaka H, Kobayashi J *et al.* Contemporary open aortic arch repair with selective cerebral perfusion in the era of endovascular aortic repair. *J Thorac Cardiovasc Surg* 2013;145: S72–77.
- [16] Zierer A, El-Sayed Ahmad A, Papadopoulos N, Moritz A, Diegeler A, Urbanski PP. Selective antegrade cerebral perfusion and mild (28 C–30 C) systemic hypothermic circulatory arrest for aortic arch replacement: results from 1002 patients. *J Thorac Cardiovasc Surg* 2012;144: 1042–50.
- [17] Patel HJ, Nguyen C, Diener AC, Passow MC, Salata D, Deeb GM. Open arch reconstruction in the endovascular era: analysis of 721 patients over 17 years. *J Thorac Cardiovasc Surg* 2011;141:1417–23.
- [18] Thomas M, Li Z, Cook DJ, Greason KL, Sundt TM. Contemporary results of open aortic arch surgery. *J Thorac Cardiovasc Surg* 2012;144:838–44.
- [19] Matsuyama S, Tabata M, Shimokawa T, Matsushita A, Fukui T, Takanashi S. Outcomes of total arch replacement with stepwise distal anastomosis technique and modified perfusion strategy. *J Thorac Cardiovasc Surg* 2012;143:1377–81.

- [20] Okita Y, Okada K, Omura A, Kano H, Minami H, Inoue T *et al.* Total arch replacement using antegrade cerebral perfusion. *J Thorac Cardiovasc Surg* 2013;145:S63-71.
- [21] Murashita T, Matsuda H, Domae K, Iba Y, Tanaka H, Sasaki H *et al.* Less invasive surgical treatment for aortic arch aneurysm in high-risk patients: a comparative study of hybrid thoracic endovascular aortic repair and conventional total arch replacement. *J Thorac Cardiovasc Surg* 2012;143:1007-13.
- [22] Ferrero E, Ferri M, Viazzo A, Robaldo A, Zingarelli E, Sansone F *et al.* Is total debranching a safe procedure for extensive aortic-arch disease? A single experience of 27 cases. *Eur J Cardiothorac Surg* 2012;41:177-82.
- [23] Vallejo N, Rodriguez-Lopez JA, Heidari P, Wheatley G, Caparrelli D, Ramaiah V *et al.* Hybrid repair of thoracic aortic lesions for zone 0 and 1 in high-risk patients. *J Vasc Surg* 2012;55:318-25.
- [24] Koullias GJ, Wheatley GH III. State-of-the-art of hybrid procedures for the aortic arch: a meta-analysis. *Ann Thorac Surg* 2010;90:689-97.
- [25] Cao P, Rango PD, Czerny M, Evangelista A, Fattori R, Nienaber C *et al.* Systematic review of clinical outcomes in hybrid procedures for aortic arch dissections and other arch diseases. *J Thorac Cardiovasc Surg* 2012;144:1286-300.

## APPENDIX. CONFERENCE DISCUSSION

**Dr V.X. Mosquera Rodríguez (A. Coruna, Spain):** Dr Iba and coworkers have presented an interesting study comparing early and mid-term outcomes of open repair and hybrid endovascular procedures for treating aortic arch aneurysms. There is a lack of prospective randomized or large nonrandomized studies addressing this issue, which is why this sort of study is so important.

The proportion of patients with previous cardiac surgery or low ejection fraction was significantly higher in the hybrid group. Thus, as expected, hybrid patients presented a higher surgical risk, and their predicted in-hospital mortality was almost two-fold. The authors concluded with an important issue suggesting that the establishment of a "risk-oriented strategy" based on proper preoperative risk evaluation of patients with aortic arch disease is of paramount importance in deciding from which approach patients will derive most benefit.

Dr Iba, I would like to draw your attention to some shortcomings present in your study as well as to ask you a couple of technical questions. My first technical question is whether or not you used any neuroprotective measures such as carotid filters to prevent atheroembolic events, especially when performing the chimney technique. In case of an affirmative answer, do you use them on a routine basis when stenting the aortic arch? Secondly, it is quite striking that the rate of reoperation for bleeding was so high at 8% in the hybrid group. Please, could you comment more on this fact?

Another point which is one of the major drawbacks of this study is that the authors resorted to the use of many different techniques for hybrid procedures. Therefore such heterogeneity in the hybrid techniques may have jeopardized the comparability of the outcomes. Although the authors claim that there were no significant differences in the rate of PND between both groups, the matched cohort reveals a marked trend to a higher incidence of PND in the hybrid group: it was indeed 8.6% versus 0%. Furthermore, I think it would be very interesting to underline which type of hybrid procedure the patients who suffered a stroke had undergone. Please, can you specify which proximal landing zone was used in the hybrid patients suffering a preoperative stroke?

And finally, although in my opinion the patient population in the present study reflects the wide anatomical spectrum normally seen in clinical practice, this study may lack sufficient statistical power to determine with confidence clinically relevant differences between both approaches. Future studies should incorporate data on outcome variables acquired during a longer follow-up period and use objective assessment of outcomes to make definitive conclusions on the effectiveness and indications of the hybrid arch repair.

**Dr Iba:** I will first answer your question about the detail of the chimney graft technique. The indication for the chimney graft technique is in high-risk patients where sternotomy is not feasible for those with prior cardiac surgery or severely compromised respiratory function. With regard to the chimney graft procedure, supra-aortic bypass was established at first. Recently, we performed right carotid to left carotid and left axillary artery bypass as a supra-aortic bypass, because a sheath was inserted through the right axillary artery as a chimney graft access. The main device was advanced into the ascending aorta from the femoral artery. Furthermore, an iliac extender device was introduced into the ascending aorta. Next, the stent-graft in the brachiocephalic artery was deployed first, followed by the main stent graft. There have been no stroke events in the chimney group up to the present; however, one patient experienced type Ia endoleak two years after the hybrid procedure with the chimney graft technique.

Turning to your question about stroke events, there were three strokes in our series in the hybrid group. Two of them received hybrid TEVAR with zone 1 landing. The remaining patient underwent zone 2 landing TEVAR. The patients who received hybrid TEVAR with zone 0 landing had no stroke events. In three stroke cases, one patient had a shaggy aorta and developed multiple cerebral emboli. The other two cases sustained cerebral embolism in the occipital lobe and the cerebellum, perhaps through the vertebrobasilar artery system.

So in our recent hybrid arch TEVAR series, a left subclavian artery balloon occlusion is routinely carried out at the time of the deployment of the stent graft for protection from embolism. We think it may reduce stroke.

About bleeding complications, postoperative bleeding occurred in four patients in our hybrid series. Three of them were due to retroperitoneal haematoma after iliac artery exposure as an access for the stent graft. The remaining patient experienced postoperative bleeding at a subclavian incision for supra-aortic bypass. As you say, there were rather frequent bleeding events in our series, though all cases were not fatal.

Regarding comparability in the study, as you say, TAR is a uniform and established procedure for arch pathologies. On the other hand, a hybrid procedure is now developing. And the outcomes of that hybrid arch procedure may depend on the concept or the method. The patients' backgrounds are somewhat different. So a simple comparison of the results of both procedures may be difficult. Therefore, we performed propensity score-matched analyses of both procedures.

Even in this risk-adjusted study, early mortality and morbidity were similar except for shorter ICU stay in the hybrid group. And the mid-term outcomes showed that TAR is more reliable. The indication may change depending on future technical advancement or more long-term follow-up data. However, we think hybrid arch TEVAR should be indicated for limited high-risk patients at the moment.

**Dr J. Bachet (Paris, France):** Your experience confirms what I thought for years: I don't understand the superiority of debranching and the hybrid procedures. Indeed, you showed us statistics demonstrating that conventional surgery had less important mortality, that the late survival was much better, and that the rate of reinterventions was much less. So why do you still propose debranching?

In my opinion, it is not comparing a very simple procedure to a very difficult one. If the hybrid procedure was very simple, I would understand, but you have to open the chest exactly as in conventional surgery. You have to do a lot of anastomosis, et cetera, so it is heavy surgery. So how do you explain your choice? And in particular, how do you explain that you prefer to do this in what you call "high-risk patients"?

This is indeed another important issue. Nobody can tell what a high-risk patient is. I've seen on your slides, for instance, that in both groups, the EuroSCORE, which is a bad score for aortic surgery by the way, was 5 and 7. 5 and 7 are not high-risk scores. So what are your criteria for deciding that the patient is a high-risk patient who should have this kind of surgery?

**Dr Iba:** What constitutes a high-risk group for aortic repair is a very important issue. Our previously reported experience showed that some organ failures such as COPD, renal failure, and liver dysfunction are risk factors for early mortality following open arch repair, and age is not necessarily a risk factor of early mortality and stroke. However, the reliability of long-term outcome is more important, more especially for young patients than elderly patients. So the determinants of our surgical strategy for arch lesions include the patient's age. Anyway, what represents a high-risk group patient for aortic repair is a very important issue, we think. So proper methods of risk evaluation should also be established in the near future.

**Dr Bachet:** Yes, but for instance, look at the mid-term outcome of your patients, and the rate of reinterventions, which are not a promenade in the park from the patient's point of view, as being called again to have a new stent graft, et cetera, is a real psychological and physical stress. Do you really think that this is better than having a conventional surgery with maybe a slightly increased risk than to come back to have one, two, three reinterventions? I don't think so, really. I'm sorry for this disagreement, but I think we should stop saying that a hybrid procedure, which represents for me a real heavy surgery, is a very simple thing as compared to conventional surgery because this is not true and, obviously, your data show that this is not true.

**Dr E. Weigang (Berlin, Germany):** That is a very important comment from Dr Bachet. However, I also agree with the authors' conclusion. It makes good sense to establish a risk score for hybrid procedures in the arch and to have available a genuine tool to help in deciding which patient is most likely to benefit from the procedure.

**Dr K. Minatoya (Osaka, Japan):** This was a great comment from Dr. Bachet. But the main message from this presentation is that open surgery is still sort of mainstream, in my understanding, and reintervention is sometimes okay for a really old, high-risk patient. So, therefore, we have the same problem using this terminology "high-risk". In really high-risk patients who sometimes had demen-

tia, who could not have major surgery, we applied this hybrid TEVAR operation for the pathology. So both of them are applied properly, as Professor Harringer said. That's my comment.

**Dr G. D'Ancona** (*Palermo, Italy*): I have a comment. I am not sure that you are proposing the correct stent for the arch. There are better stents tailor-made, so to speak: for example, the Najuta precurved fenestrated graft that's been proposed in over 400 patients by a group from Tokyo, with excellent results in arch

hybrid, fully percutaneously with a precurved stent, without even debranching, just with fenestration. The results are superior to what you are presenting, in over 400 patients presented last year at the European meeting. So I'm not sure you can really come and say something about hybrid arch if you're using the standard stents. Those are not done for the arch.

**Dr Iba**: That Najuta fenestrated graft has not been used in our centre because we don't know its durability.



## Cerebral blood flow after hybrid distal hemiarch repair

Hideyuki Shimizu<sup>a,\*</sup>, Tadaki Nakahara<sup>b</sup>, Kiyoshi Ohkuma<sup>b</sup>, Satoshi Kawaguchi<sup>a</sup>,  
Akihiro Yoshitake<sup>a</sup> and Ryohei Yozu<sup>a</sup>

<sup>a</sup> Department of Cardiovascular Surgery, Keio University, Shinjuku-ku, Tokyo, Japan

<sup>b</sup> Department of Radiology, Keio University, Shinjuku-ku, Tokyo, Japan

\* Corresponding author. Department of Cardiovascular Surgery, Keio University, 35 Shinanomachi, Shinjuku-ku, Tokyo 160-8582, Japan. Tel: +81-3-53633804; fax: +81-3-53793034; e-mail: shimizu.md@gmail.com (H. Shimizu).

Received 30 October 2012; received in revised form 31 January 2013; accepted 8 February 2013

### Abstract

**OBJECTIVES:** Aortic arch disease can be treated with hybrid repair (extra-anatomic bypass plus placement of aortic endoprotheses), but there is controversy about whether a bypass from one relatively small vessel will provide adequate blood flow to the entire brachiocephalic system. We, therefore, compared flow volumes before and after hybrid repair.

**METHODS:** We reviewed the records of 16 patients who underwent a hybrid distal hemiarch repair between October 2010 and May 2012. The procedure consisted of debranching of the left subclavian and left common carotid arteries, creation of a bypass to these vessels from the right subclavian artery by using a T-shaped synthetic graft, and placement of a stent graft. Preoperative and postoperative measurements of blood flow volume in the carotid and vertebral arteries and of regional cerebral blood flow were performed in ~70% of the patients.

**RESULTS:** Perioperative complications were one new-onset, fatal acute aortic dissection and two minor strokes. No major endoleaks occurred. Postoperatively, mean flow volumes in the right and left common carotid arteries, right and left internal carotid arteries, and right and left vertebral arteries were 423 and 393, 271 and 189, and 87 and 80 ml/min, respectively. Regional cerebral blood flow in the territories of the anterior, middle and posterior cerebral arteries was not significantly different from preoperative levels, as assessed both with and without administration of acetazolamide.

**CONCLUSIONS:** Hybrid distal hemiarch repair preserved regional cerebral blood flow and vasoreactivity, although flow in the common and internal carotid arteries was right-side dominant postoperatively.

**Keywords:** Aortic arch • Brain • Hybrid repair • Cerebral blood flow

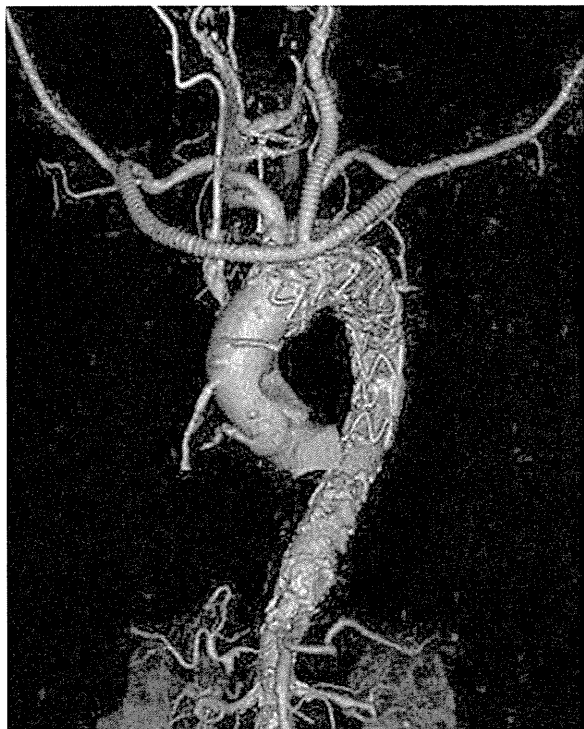### INTRODUCTION

Open repair of aortic arch disease remains a challenge, particularly in patients at high risk of operative complications. The endovascular approach is useful for treating complex aortic disease, but its application is limited when the arch is affected because adequate landing zones cannot be obtained without interrupting the supra-arch vessels. Hybrid repair, which includes endovascular aortic repair plus debranching and reconstruction of the supra-arch vessels, may be an option when standard endovascular procedures are not possible for anatomical reasons [1]. Several different hybrid repairs have been described [2]. To treat disease in the distal aortic arch, we preferably perform debranching of the left subclavian artery (SA) and left common carotid artery (CCA) and creation of a bypass to these vessels from the right SA by using a T-shaped synthetic graft. This method is less invasive and simpler than other hybrid procedures, but concerns have been raised about the adequacy of blood flow to the entire brachiocephalic system provided by one relatively small vessel. We, therefore, measured global cerebral blood flow and blood flow in the carotid and vertebral arteries

before and after hybrid repair in patients with distal aortic arch disease.

### METHODS

We retrospectively reviewed the records of all 16 patients (14 men; mean age, 75.4 years [range 64–86 years]; 5 octogenarians) with aortic disease who underwent a distal hemiarch hybrid repair between October 2010 and May 2012. The repair was elective in 13 cases, urgent in 2, and emergency in 1. Aside from aortic disease, patients in the series had shock due to rupture of an aneurysm ( $n=1$ ), hemothorax ( $n=1$ ), congestive heart failure ( $n=1$ ), chronic obstructive pulmonary disease (COPD) ( $n=2$ ), cerebral infarction ( $n=2$ ), dementia ( $n=2$ ), cancer ( $n=2$ ), previous aortic surgery ( $n=7$ ), previous coronary artery bypass surgery ( $n=2$ ) and previous percutaneous coronary intervention ( $n=5$ ). Patients in whom preoperative Doppler echocardiography and magnetic resonance imaging assessments showed abnormal findings, such as the occlusion of the right SA and the right carotid artery and poor communication in the Circle of

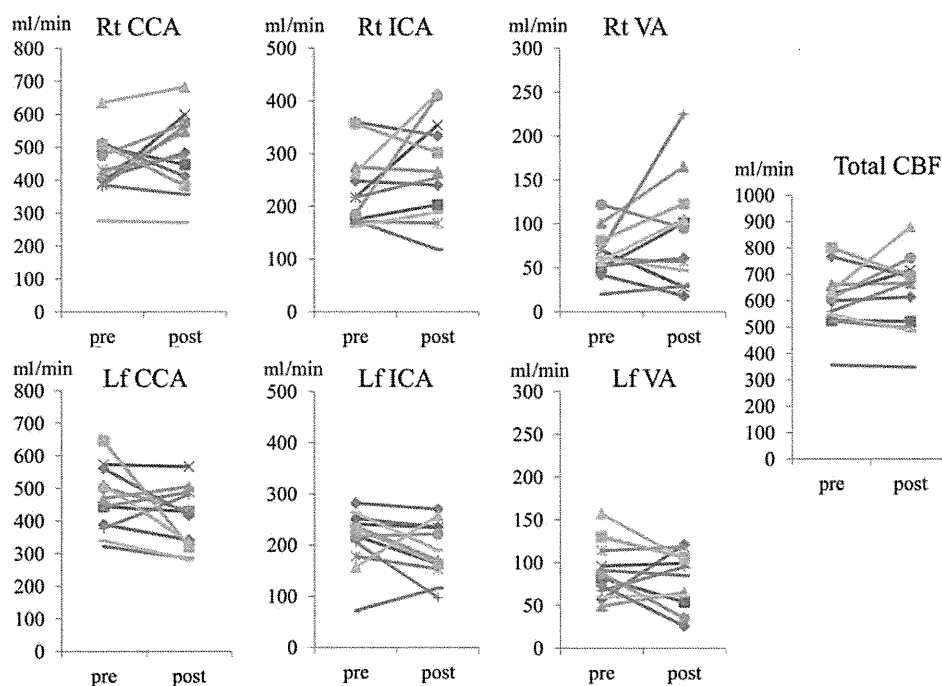


**Figure 1:** Computed tomographic image of distal hemiarch hybrid repair. A subcutaneous bypass is achieved by using a one-branched (T-shaped) graft. Each end of the graft is anastomosed to a SA in an end-to-side fashion, and the end of the branch is anastomosed to the left CCA in an end-to-end fashion. The proximal stump of the left CCA is then ligated. The proximal end of a covered stent graft is between the brachiocephalic and left common carotid arteries (Zone 1). A bare spring crosses the ostium of the brachiocephalic artery, but does not occlude blood flow.

Willis, were excluded from undergoing the procedure. The Institutional Review Board of Keio University Hospital approved the study, and written informed consent to undergo all procedures associated with the study was obtained from each patient.

The repair procedure was performed with the patient under general anaesthesia. The patient was placed supine, and the left CCA and both SAs were exposed. A ringed, 8-mm diameter, expanded polytetrafluoroethylene (ePTFE) prosthesis (W.L. Gore & Associates, Flagstaff, AZ, USA) with one branch (T-shaped device) was used as the conduit for a subcutaneous bypass (Fig. 1). Each end of the graft was anastomosed to an SA in an end-to-side fashion, and the end of the branch was anastomosed to the left CCA in an end-to-end fashion under simple clamping. The proximal stump of the left CCA was ligated. Neither extracorporeal circulation nor a shunt tube was used. After creation of the bypass, a stent graft (either a GORE TAG Thoracic Endoprosthesis, W.L. Gore & Associates; a Zenith TX2 TAA Endovascular Graft, Cook Medical, Bloomington, IN, USA; a Talent Thoracic Stent Graft, Medtronic, Santa Rosa, CA, USA or a Najuta Endograft, Kawasumi Laboratories, Tokyo, Japan) was deployed through the femoral artery and positioned so that the proximal end of the covered stent graft was in the aortic arch between the brachiocephalic artery and left CCA. All procedures were performed during the same operation.

Measurements of blood flow volume in the CCAs, internal carotid arteries (ICAs) and vertebral arteries (VAs) were done ~1 month postoperatively in 13 patients and preoperatively in 11 of those 13. Blood flow volume was determined by using Doppler sonography. Measurements of regional cerebral blood flow were done postoperatively in 13 patients and preoperatively in 12. Regional cerebral blood flow was determined by means of the graph-plot method employing N-isopropyl-p [I-123] iodoamphetamine (I-123 IMP) single-photon emission computed



**Figure 2:** Flow volumes in arteries in individual patients and the calculated total cerebral blood flow before and after hybrid aortic repair. The total cerebral blood flow was calculated as the sum of flow volumes in both ICAs and both vertebral arteries. Rt: right; CCA: common carotid artery; ICA: internal carotid artery; VA: vertebral artery; Lf: left.

tomography (SPECT). This technique permits quantitative assessment of cerebral blood flow without arterial blood sampling [3, 4]. Two SPECT investigations were performed: a baseline study that did not include administration of acetazolamide and, ~10 days later, a study of the response to intravenous acetazolamide (1 g). The I-123 IMP SPECT method measures regional cerebral blood flow as accurately as does positron emission tomography using oxygen 15-labelled water [4], even in areas of hyper-perfusion; therefore, it can be employed for quantitative assessment of cerebral vasoreactivity to acetazolamide.

Statistical analyses of the blood flow assessments were performed by using SPSS software (Version 17.0, SPSS, Inc., Chicago, IL, USA). Results are expressed as the mean  $\pm$  SD. Student's paired *t*-test was used to compare parametric variables. A *P*-value of  $<0.05$  was considered to represent a significant difference between groups.

**Table 1:** Mean blood flow volumes in individual arteries and calculated total cerebral blood flow before and after hybrid aortic repair

Artery	Volume before repair (ml/min)	Volume after repair (ml/min)	<i>P</i> -value
Rt CCA	443 $\pm$ 91	482 $\pm$ 117	0.24
Lf CCA	465 $\pm$ 99	406 $\pm$ 93	0.11
Rt ICA	234 $\pm$ 69	271 $\pm$ 94	0.17
Lf ICA	213 $\pm$ 56	189 $\pm$ 55	0.18
Rt VA	66 $\pm$ 27	88 $\pm$ 62	0.18
Lf VA	89 $\pm$ 32	81 $\pm$ 32	0.46
ICA + VA	601 $\pm$ 117	629 $\pm$ 144	0.36

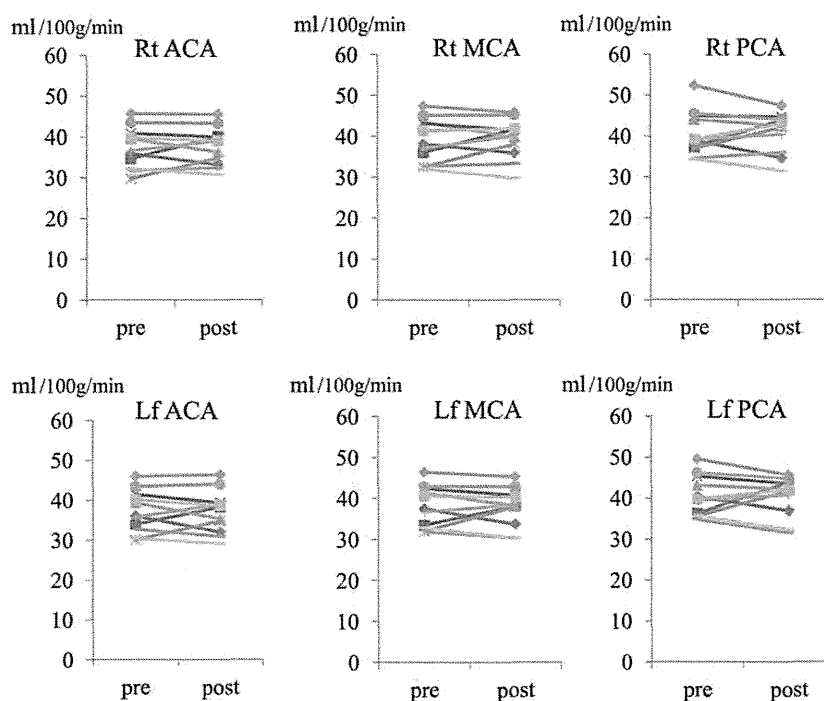
Rt: right; CCA: common carotid artery; Lf: left; ICA: internal carotid artery; VA: vertebral artery.

## RESULTS

One of the 16 patients who underwent a hybrid distal hemiarach repair died perioperatively of a new-onset acute aortic dissection. Two patients had a minor stroke postoperatively. No major endoleaks were observed on computed tomographic scanning performed before hospital discharge in the 15 surviving patients. The mean age of the 13 patients (12 men) in whom cerebral blood flow was studied was  $74.1 \pm 6.0$  years (range 64–82 years), with 3 of those patients being octogenarians. Two of the 13 patients had an urgent operation and 11 had an elective procedure.

Figure 2 shows the preoperative and postoperative blood flow volumes in the CCAs and VAs, as well as the calculated total cerebral blood flow, for each of the 13 patients assessed. The mean preoperative and postoperative flow volumes in the right CCA, left CCA, right ICA, left ICA, right VA and left VA in the 12 patients for whom both preoperative and postoperative data were obtained are given in Table 1. Preoperatively, the mean flow volume values for the left and right CCAs were similar ( $P=0.403$ ), as were those for the left and right ICAs ( $P=0.327$ ). Postoperatively, mean flow volume was significantly greater in the right CCA compared with the left CCA ( $P=0.025$ ) and in the right ICA compared with the left ICA ( $P=0.002$ ). The mean total cerebral blood flow, calculated as the sum of flow volumes in both ICAs and both VAs, was  $601 \pm 117$  ml/min preoperatively and  $629 \pm 144$  ml/min postoperatively. There was no significant difference between preoperative and postoperative total cerebral blood flow ( $P=0.362$ ).

Individual results of baseline (no administration of acetazolamide) SPECT assessments of regional cerebral blood flow performed preoperatively (11 patients) and postoperatively (13 patients) are shown in Fig. 3. The mean preoperative and postoperative blood flow values (ml/100 g/min) in the territories of the right anterior cerebral artery (ACA), left ACA, right middle



**Figure 3:** Baseline preoperative and postoperative regional cerebral blood flow in arteries in individual patients, as detected with SPECT. Rt: right; ACA: anterior cerebral artery territory; MCA: middle cerebral artery territory; PCA: posterior cerebral artery territory; Lf: left.

cerebral artery (MCA), left MCA, right posterior cerebral artery (PCA) and left PCA are given in Table 2.

Values obtained for regional cerebral blood flow on SPECT analysis after administration of acetazolamide in individual patients are shown in Fig. 4. The mean preoperative (11 patients) and postoperative (13 patients) blood flow values (ml/100 g/min) in the territories of the right ACA, left ACA, right MCA, left MCA, right PCA and left PCA are given in Table 3.

So far, none of the patients in the series have had a procedure-related complication, although the patient with COPD died 10 months postoperatively, after progression of the disease. The 2-year actuarial survival rate in the series, calculated with use of Kaplan–Meier analysis by including this patient and the patient who died during initial hospitalization, was  $85.2\% \pm 9.8\%$  (Fig. 5).

**Table 2:** Baseline mean preoperative and postoperative regional cerebral blood flow values, as detected with SPECT

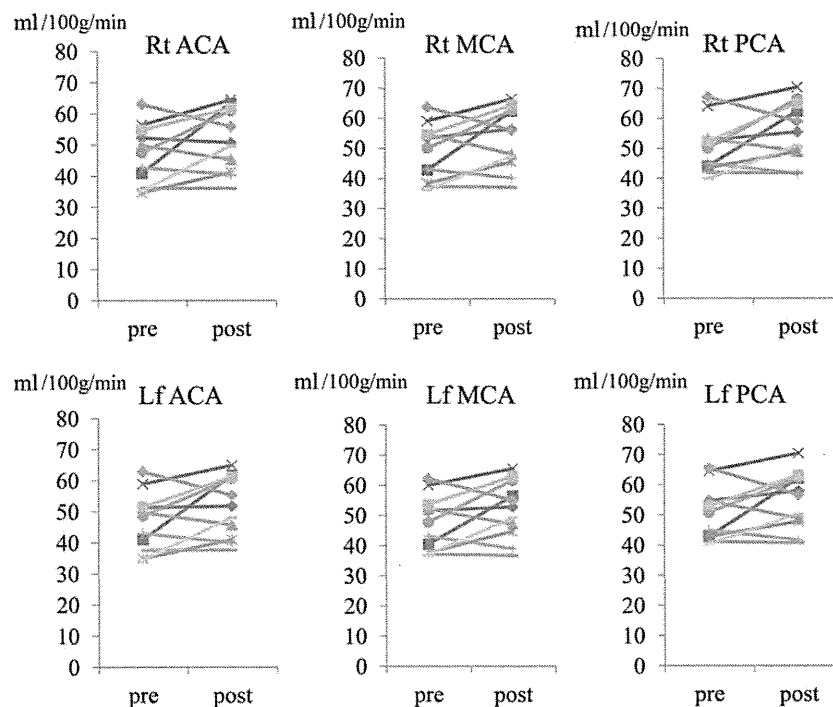
Artery	Preoperative flow (ml/100 g/min)	Postoperative flow (ml/100 g/min)	P-value
Rt ACA	37.2 ± 5.1	37.6 ± 4.6	0.64
Lf ACA	37.2 ± 5.3	37.1 ± 5.3	0.91
Rt MCA	38.9 ± 5.4	39.4 ± 4.9	0.29
Lf MCA	38.0 ± 5.0	37.8 ± 4.8	0.86
Rt PCA	40.6 ± 5.5	40.8 ± 4.9	0.84
Lf PCA	40.5 ± 4.9	40.4 ± 4.8	0.96

Rt: right; ACA: anterior cerebral artery territory; Lf: left; MCA: middle cerebral artery territory; PCA: posterior cerebral artery territory.

## DISCUSSION

Recent advances have improved the outcomes of open repair of aortic arch disease, but the procedure remains a challenge, particularly in patients at high risk of complications [5]. Several innovative methods for treating aortic arch disease have been described. With respect to minimally invasive repair, procedures using fenestrated or branched stent grafts have yielded some promising results, but experience with these new endovascular devices is still limited. Hybrid repair is another alternative. In our previous experience with hybrid repair (33 patients), the source of the blood flow for the bypasses was the aorta. However, avoiding sternotomy and cardiopulmonary bypass has several potential advantages for high-risk patients [6, 7]. Because the greatest advantage of a hybrid procedure is its decreased invasiveness compared with open repair, sternotomy should be avoided if possible. In this study, we found evidence that the blood flow provided to the brachiocephalic system via the relatively small SA after a specific hybrid repair is adequate. In our patients who underwent this repair, postoperative total cerebral blood flow was similar to preoperative flow, although postoperative flow volume was significantly greater in the right compared with the left CCA ( $P = 0.025$ ) and the right compared with the left ICA ( $P = 0.002$ ). Moreover, there were no significant differences between preoperative and postoperative cerebral flow volumes (i.e., flow in the ACAs, MCAs and PCAs), with or without acetazolamide administration.

Using colour duplex sonography, Schöning *et al.* [8] measured blood flow volumes in the CCAs, ICAs and VAs in healthy adults and reported mean values of 470, 265 and 85 ml/min (either side), respectively. The mean value for total cerebral blood flow in their investigation was 701 ml/min (corresponding to  $54 \pm 8$  ml/100 g/min), and no variations according to age or sex were



**Figure 4:** Preoperative and postoperative regional cerebral blood flow in arteries in individual patients after administration of acetazolamide, as detected with SPECT. Rt: right; ACA: anterior cerebral artery territory; MCA: middle cerebral artery territory; PCA: posterior cerebral artery territory; Lf: left.