

戻り、筋活動も消失した。このことより、ハンガー装着にて回旋が誘発され、対側 SCM に対して興奮性に働くことが示された。

ハンガー反射における筋活動の変化を観察したところ、圧迫した前額部の左右方向と同側の回旋が誘発させることが確認できた。ハンガー反射は健常者においても CD の回旋症例においても観察された。健常者においては表面筋電図を用いて SCM での観察を行った。ハンガー反射は、圧迫した前額部の左右方向と同側の SCM に対しては抑制性、対側の SCM に対しては興奮性に働くことを確認した。左回旋患者においては携帯筋電計を用いて下頭斜筋の観察を行った。この観察では、ハンガー反射は圧迫した前額部の左右方向と対側の下頭斜筋に対しては抑制性に働くことを確認できた。同側の下頭斜筋に対しては筋電計での観察はしていないものの、左回旋症例で左前額部にハンガーを装着したときに左回旋が悪化し、後方へ倒れそうになったことから、圧迫した前額部と同側の下頭斜筋に興奮性に働くと考えられた。ハンガー反射と感覚トリックは類似しているように見えるが、異なるものとして捉えている。理由としては前述したように、ハンガー反射は健常者でも観察されることに加え、回旋症例における感覚トリックでは、手を当てる寸前から姿勢異常が改善することがあることがあげられる。<sup>6)</sup>ハンガー反射はむしろハンガーの圧迫を受けてからゆっくりと頭部が回旋するので、異なる機序であることが想定される。しかし、回旋を呈する痙性斜頸においてはハンガー反射をひとつの感覚トリックと同様に利用できる症例が存在するため、広く臨床応用できる可能性があると考えられた。

引用文献：

- 1) 目崎高広, 梶 龍児: ジストニアとボツリヌス治療, 改訂第 2 版、診断と治療社, 2005.
- 2) 旭雄二, 林央周, 浜田秀雄, 佐藤未知, 梶本裕之, 高嶋修太郎, 遠藤俊郎: ハンガー反射を用いた頸部ジストニアの治療の試み. 機能的脳神経外科 49(2010)173-176.

3) Christensen JE, New treatment of spasmodic torticollis? , Lancet 1991;vol 338:p573

4) R.Matsue, M.Sato, Y.Hashimoto, H.Kajimoto: Hanger reflex -a reflex motion of a head by temporal pressure for wearable interface, SICE Annual Conference 2008, 2008.

5) M.Sato, R.Matsue, Y.Hashimoto, H.Kajimoto, "Development of a Head Rotation Interface by Using Hanger Reflex (I)," IEEE RO-MAN2009

6) 柴崎浩: 神経診断学を学ぶ人のために 第 2 版, 医学書院, 2013

## 5 結論

頸部ジストニアに対する治療を今後さらに向上させることが必要である。

## 6 研究発表

### 1) 国内

原著論文 1 件

学会発表 5 件

1. 相場彩子、林明人: 携帯筋音計を用いた痙性斜頸に対するボツリヌス治療

2013 年 7 月 6 日 第 46 回日本運動障害研究会、東京

2. 相場彩子、旭 雄士、梶本 裕之、佐藤 未知、大山 彦光、平 孝臣、林明人: 携帯筋音計を用いた痙性斜頸に対するボツリヌス治療およびハンガー反射の応用、2013 年 10 月 12 日 第 7 回パーキンソン病・運動障害疾患コンgres (MDSJ)、東京

3. Takashi Asahi<sup>1</sup>, Michi Sato<sup>2</sup>, Hiroyuki Kajimoto<sup>2</sup>, Takuto Nakamura<sup>2</sup>, Genko Oyama<sup>3</sup>, Takaomi Taira<sup>4</sup>, Akito Hayashi<sup>5</sup>, Masami Fujii<sup>6</sup>, Satoshi Kuroda<sup>1</sup> Clinical application of the hanger reflex to the treatment of cervical dystonia - interim report of the multicenter trial 第 28 回日本脳神経外科国際学会フォーラム (Japan Neurosurgical English Forum: JNEF)

4. 林明人, 相場彩子: 携帯筋音計を用いた痙性斜頸に対するボツリヌス治療およびハンガー反射の応用、2013年10月12日 第7回パーキンソン病・運動障害疾患コンgres (MDSJ)、東京

5. 林明人, 相場彩子: 痙性斜頸のボツリヌス治療: 携帯筋音計とハンガー反射の利用。第50回日本リハビリテーション医学会学術集会、2013年6月13日、東京。

## 7 知的財産権の出願・登録状況 (予定を含む)

1. 特許取得  
該当なし
2. 実用新案登録  
該当なし
3. その他  
該当なし

## 2) 海外

原著論文 該当なし

学会発表

1. Takashi Asahi, Michi Sato, Hiroyuki Kajimoto, Genko Oyama, Takaomi Taira, Akito Hayashi, Masami Fujii, Shutaro Takashima, Kortaro Tanaka, Satoshi Kuroda. Clinical multicenter trial for the treatment of cervical dystonia using the hanger reflex - interim report 15th WFNS World Congress in Seoul for one week. in September 8-13, 2013.

2. Takashi Asahi, Michi Sato, Hiroyuki Kajimoto, Genko Oyama, Takaomi Taira, Akito Hayashi, Masami Fujii, Shutaro Takashima, Kortaro Tanaka, Satoshi Kuroda. Clinical multicenter trial for the treatment of cervical dystonia using the hanger reflex - interim report 2013年5月27-30日、世界定位機能神経外科学会総会 2013 東京

3. Takashi Asahi, Michi Sato, Hiroyuki Kajimoto, Genko Oyama, Takaomi Taira, Akito Hayashi, Masami Fujii, Shutaro Takashima, Kortaro Tanaka, Satoshi Kuroda. Clinical application of the hanger reflex for the treatment of cervical dystonia - interim report of the multicenter trial. 2013年6月8-13日、International Neuromodulation Society 11th World Congress ドイツ、ベルリン

研究協力者：所属機関 都立神経病院 脳神経内科  
氏名 横地房子

研究：fixed dystonia の病状を呈した全身性ジストニア例に対する両側淡蒼球刺激療法の効果と臨床症状について

## 1 研究目的

fixed dystonia は主に四肢末端の固定性姿勢、痛みなど CRPS に類似した症状を呈する症例が多く、精神症状や気分障害を合併すると考えられており、外傷歴などが先行する場合が多く、治療は非常に難治である。

## 2 研究方法

全身性 fixed dystonia の病態を呈し、両側淡蒼球内節刺激術(GPi-DBS)で症状が改善した症例を経験したので、臨床経過などについて報告する。

## 3 研究結果

家族歴：なし、既往歴：外傷・手術を含めて特記事項なし。手術時 17 才女性、15 才頃から眠気、意識消失発作が出現、歩行障害が次第に強くなり、上肢・顔面にも筋強直が出現し、歩行不能になった。食事摂取困難・呼吸困難の症状も出現した。18 才時両側 GPi-DBS を施行して、徐々に運動症状が改善し ADL に支障がなくなった。気分障害はなく、認知機能、特に記憶力・注意力低下が進行性に認められた。深部知覚障害が認められ、上下肢の位置覚が閉眼に著しく悪化した。表在覚はほぼ正常であった。術前に施行した SEP は正常であった。15 才時 (DBS 前) と 20 才時 (DBS 治療中) の MRI、SPECT で前頭葉>頭頂葉、側頭葉萎縮、前頭葉優位な脳血流低下が認められた。

## 4 考察

GPi-DBS が fixed dystonia の症状を改善するために有効であった。しかし本例の臨床経過から幾つかの問題が提起される。①外傷・手術などの

既往はなく、身体表現性障害を認めない。②進行性の記憶力低下・注意障害がある。③後索障害、身体表現性障害によると思えない深部知覚を認める。④5 年間で前頭葉に強い脳萎縮、脳血流低下を認める。同様な臨床症状を呈する疾患についての報告を検索でいなかった。

## 5 結論

ジストニアは症状が多彩であり、診断を含めて病態が不明な疾患が多い。また治療も困難であることが多い。臨床病態の検討、薬物・ボツリヌス・DBS などによる治療を通して長期的な経過を観察する必要がある。

## 6 研究発表

### 1) 国内

原著論文 該当なし

学会発表

- 1 遺伝性ジストニアと脳深部刺激療法の効果、日本定位・機能神経外科学会、2013/1
- 2 海綿状血管腫に伴って出現した hemichorea の自然経過、日本大脳基底核研究会、2013/7

### 2) 海外

原著論文 該当なし

学会発表

- 1) Long-term Outcome Of Bilateral Pallidal Deep Brain Stimulation In Patients With Primary Torsion Dystonia. WSSFN, 2013/5
- 2 Dystonia-parkinsonism and deep brain stimulation, Second international congress on treatment of dystonia, 2013/5

## 7 知的財産権の出願・登録状況（予定を含む）

### 1. 特許取得

該当なし

### 2. 実用新案登録

該当なし

### 3. その他

該当なし

### III. 研究成果の刊行に関する一覧表

研究成果の刊行に関する一覧表（厚生労働科学研究費の補助を受けたことが明記されたものに限る）

書籍

著者氏名	論文タイトル名	書籍全体の編集者名	書籍名	出版社名	出版地	出版年	ページ
梶龍兒、長谷川一子、目崎高広、他	ジストニアのすべて—最新の治療指針	梶龍兒	ジストニアのすべて—最新の治療指針	診断と治療者	東京	2013	1-128

雑誌

発表者氏名	論文タイトル名	発表誌名	巻号	ページ	出版年
Ryosuke Miyamoto, Hiroyuki Morino, Akio Yoshizawa, et al.	Exome sequencing reveals a novel MRE11 mutation in a patient with progressive myoclonic ataxia.	Journal of the Neurological Sciences	337(1-2)	219-223	2013
Ryosuke Miyamoto, Hidetaka Koizumi, Hiroyuki Morino, et al.	DYT6 in Japan—genetic screening and clinical characteristics of the patients.	Movement Disorders	29(2)	278-280	2014
Hideyuki Matsumoto, Yasuo Terao, Yoshikazu Ugawa	Ocular paradoxical movement and severity of Parkinson's disease.	Brain	136(10)		2013
Toshiaki Furubayashi, Hitoshi Mochizuki, Yasuo Terao, et al.	Cortical hemoglobin concentration changes underneath the coil after single-pulse transcranial magnetic stimulation: a near-infrared spectroscopy study.	Journal of Neurophysiology	109(6)	1626-1637	2013

#### IV. 研究成果の刊行物・別刷

Dystonia

# ジストニアのすべて

最新の治療指針

編集


梶 龍兒

徳島大学大学院ヘルスバイオサイエンス研究部感覚情報医学講座臨床神経科学 教授



診断と治療社





## Short communication

Exome sequencing reveals a novel *MRE11* mutation in a patient with progressive myoclonic ataxia

Ryosuke Miyamoto <sup>a,b,\*</sup>, Hiroyuki Morino <sup>b</sup>, Akio Yoshizawa <sup>b</sup>, Yoshimichi Miyazaki <sup>a</sup>, Hirofumi Maruyama <sup>b</sup>, Nagahisa Murakami <sup>a</sup>, Kei Fukada <sup>c</sup>, Yuishin Izumi <sup>a</sup>, Shinya Matsuura <sup>d</sup>, Ryuji Kaji <sup>a</sup>, Hideshi Kawakami <sup>b</sup>

<sup>a</sup> Department of Clinical Neuroscience, Institute of Health Biosciences, Graduate School of Medicine, University of Tokushima, Tokushima, Japan

<sup>b</sup> Department of Epidemiology, Research Institute for Radiation Biology and Medicine, Hiroshima University, Hiroshima, Japan

<sup>c</sup> Department of Neurology, Osaka General Medical Center, Osaka, Japan

<sup>d</sup> Department of Genetics and Cell Biology, Research Institute for Radiation Biology and Medicine, Hiroshima University, Hiroshima, Japan

## ARTICLE INFO

## Article history:

Received 20 July 2013

Received in revised form 26 October 2013

Accepted 20 November 2013

Available online 1 December 2013

## Keywords:

Myoclonus

Progressive myoclonic ataxia

Tremor

Ataxia–telangiectasia-like disorder

Neurogenetics

*MRE11*

## ABSTRACT

Progressive myoclonic ataxia (PMA) is a clinical syndrome defined as progressive ataxia and myoclonus and infrequent seizures in the absence of progressive dementia. Due to the extremely heterogeneous nature of PMA, a large proportion of PMA cases remain molecularly undiagnosed. The aim of this study was to clarify the molecular etiology of PMA. The patient was a 52-year-old female from consanguineous parents. She developed a jerking neck movement at age 9, which gradually expanded to her entire body. On physical examination at age 47, she exhibited generalized, spontaneous myoclonus that occurred continuously. She also presented with mild limb and truncal ataxia. An electroencephalogram revealed no abnormalities. A brain MRI displayed no atrophy of the cerebellum. Electrophysiological studies suggested myoclonus of a subcortical origin. For further evaluation, we performed exome sequencing, and we identified a novel homozygous missense mutation in the *MRE11* gene (NM\_005590:c.140C>T:p.A47V). Subsequently, we analyzed the expression of *MRE11* and related proteins (RAD50 and NBS1) via Western blot, and they were markedly decreased compared to a healthy control. Mutations in the *MRE11* gene have been known to cause an ataxia–telangiectasia-like (ATLD) disorder. Accumulating evidence has indicated that its wide phenotypic variations in ATLD correspond to genotypic differences. Interestingly, our case exhibited a relatively mild decrease in NBS1 compared to previously reported cases of a homozygous missense mutation, which may account for the milder phenotype in this patient. Moreover, together with a recently reported case of an *MRE11* mutation, it is suggested that *MRE11* mutations can present as PMA.

© 2013 Elsevier B.V. All rights reserved.

## 1. Introduction

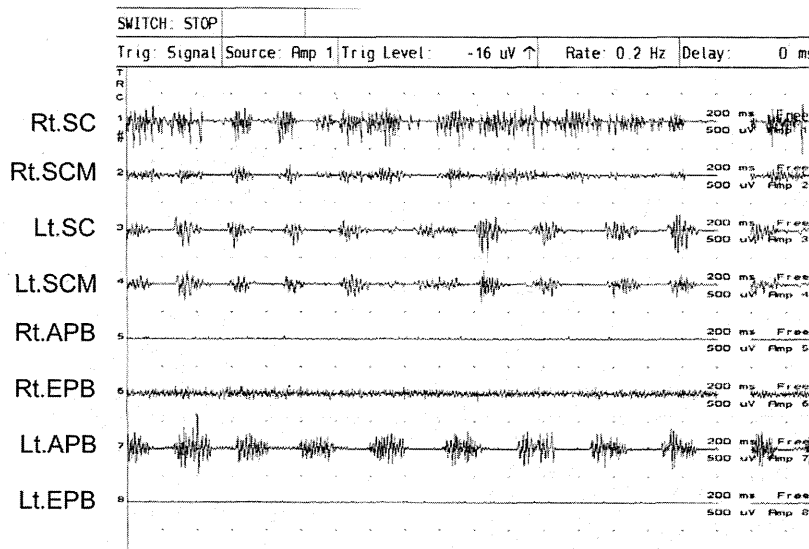
Progressive myoclonic ataxia (PMA) is a clinical syndrome defined as progressive ataxia and myoclonus with no or infrequent seizures in the absence of progressive dementia [1]. Known causes of PMA include various diseases characterized by distinct molecular etiologies [1]: Unverricht–Lundborg disease, caused by mutation in the cystatin B gene (*CSTB*) [2]; mitochondrial encephalomyopathy; sialidosis caused by mutation in the gene encoding neuraminidase (*NEU1*) [3]; Lafora

body disease, caused by dysfunctions of a dual-specificity protein phosphatase (*EPH2A*) [4] or a single E3 ubiquitin ligase subunit (*NHLRC1*) [5]; neuronal ceroid lipofuscinosis, caused by the intracellular accumulation of autofluorescent lipopigment storage material [6]; and spinocerebellar degeneration. In the case series on PMA by Marsden et al., the authors emphasized the low diagnostic yields of PMA, and since the publication of the case series in 1990, no new specific etiology of classical PMA has been reported. One reasonable explanation for the difficulties in the etiological diagnosis of PMA could be that PMA consists of rare heterogeneous disorders that escape the conventional diagnostic approach.

In this report, due to advances in molecular diagnostic technologies, we performed exome sequencing of a PMA patient and identified a novel mutation in the *MRE11* meiotic recombination 11 homolog A (*MRE11*) gene. Mutations in *MRE11* have been known to cause an ataxia–telangiectasia-like disorder (ATLD), which typically produces gradually progressive cerebellar ataxia and oculomotor apraxia but rarely exhibits tumors or immunodeficiency, as observed in ataxia–telangiectasia (AT) [7,8]. Although ATLD is a very rare disease and only a few

\* Corresponding author at: Department of Clinical Neuroscience, Institute of Health Biosciences, Graduate School of Medicine University of Tokushima, 3-18-15, Kuramotocho, Tokushima City 770-0042, Japan. Tel.: +81 88 633 7207; fax: +81 88 633 7208.

E-mail addresses: ryom@tokushima-u.ac.jp (R. Miyamoto), morino@hiroshima-u.ac.jp (H. Morino), akiyoshizawa@hiroshima-u.ac.jp (A. Yoshizawa), miyazaki@clin.med.tokushima-u.ac.jp (Y. Miyazaki), hmaru@hiroshima-u.ac.jp (H. Maruyama), n.murakami@clin.med.tokushima-u.ac.jp (N. Murakami), fukada@gh.opho.jp (K. Fukada), yizumi@clin.med.tokushima-u.ac.jp (Y. Izumi), shinya@hiroshima-u.ac.jp (S. Matsuura), rkaji@clin.med.tokushima-u.ac.jp (R. Kaji), hkawakami@hiroshima-u.ac.jp (H. Kawakami).



**Fig. 1.** Superficial EMG. Rhythmic bursts of approximately 3 Hz were observed in Lt.SC and Lt.SCM. In Rt.SC and Lt.APB, the burst duration was much longer, which suggested the co-existence of myoclonus and dystonia. These findings suggested that she experienced a combination of tremor, myoclonus, and dystonia. We placed an emphasis on myoclonus throughout this report due to the clinical phenomenology (see video). Abbreviations: SC = splenius capitis muscle; SCM = sternocleidomastoid muscle; APB = abductor pollicis brevis muscle; EPB = extensor pollicis brevis muscle; Rt = right; Lt = left.

mutations have been reported, increasing evidence has suggested that ATLD patients can present with different symptoms [8–10]. In this study, we describe the unique clinical characteristics of a patient with a novel homozygous *MRE11* mutation, and we discuss the genotype–phenotype correlation.

## 2. Methods

The study was approved by the ethics committee of Hiroshima University, and the patient provided written informed consent.

### 2.1. Patient

The patient was a 52-year-old Japanese female who was born to half cousin parents. Her mother and two siblings were in good health, and her father had a history of stroke due to a carotid artery occlusion. She grew normally until age 9, when she developed an intermittent jerking neck movement. She underwent an examination that included an EEG, but the results were normal. Three years later, she presented with myoclonus

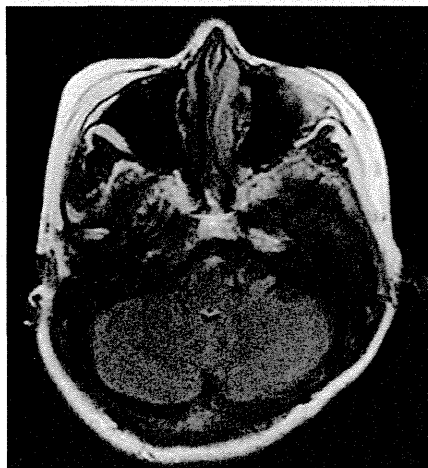and a tremor in her right hand that was triggered by writing. Her myoclonus slowly expanded to her entire body, which forced her to leave her job as a dressmaker at age 21. The involuntary movement was refractory to the administration of clonazepam, L-3,4-dihydroxyphenylalanine, and benzodiazepines. She began to exhibit mild walking instabilities at approximately age 40.

She was referred to our hospital at age 47, while being able to take care of normal household tasks. On physical examination, she experienced upper body-dominant spontaneous myoclonus that occurred continuously and was exacerbated by fine movements or emotional stress. A startle response was not induced by touching or sound. She exhibited dysmetria based on the finger–nose–finger test and the heel–knee test, as well as dysidiachokinesia based on the pronation–

**Table 1**  
Sequence information and filtering criteria used to identify the mutation.

	Patient
Total reads	129,722,696
Total yield (bp)	12,972,269,600
Mappable reads	114,690,581
% mappable reads (out of total reads)	88.4
Mean read depth of target regions	116X
<b>Filters applied</b>	<b>Number of variants</b>
Total variants	80,852
Homozygous variants	37,439
Exonic/splicing variants	9581*
Not present in dbSNP135, 1000 genomes or ESP5400	57
Frameshift/nonsense/nonsynonymous variants	8
In identity by descent (IBD) regions (cut-off 3.0 cM)	5
Not present in 206 population-matched control alleles	4**
Predicted as damaging via >2 algorithms	1 ( <i>MRE11</i> )

\*Of the 9581 variants, 65 had rsIDs with a minor allele frequency <0.005. None of the 65 variants were included in the flagged SNPs or located in the genes known to cause ataxia or myoclonus. \*\*Variants were identified in the following genes: *TRIM63*, *DDX4*, *IL6ST*, and *MRE11* (see Table 2). We verified that this patient did not harbor a novel or low-frequency (<0.005) heterozygous/homozygous variant in the *MRE11*, *NBS1*, or *RAD50* genes except for the identified mutation in *MRE11*. Additionally, we have searched for mutations in the genes that have been known to cause a PMA phenotype: *CSTB* (Unverricht–Lundborg disease), *NEU1* (sialidosis), *EPM2A*, *NHLRC1* (Lafora body disease), *PPT1*, *TPP1*, *CLN3*, *CLN6*, *DNAJC5*, *CLN5*, *CLN6*, *MPSD8*, *CLN8*, *CTSD*, and *GRN* (neuronal ceroid lipofuscinosis). None of these genes harbored possible causative variants.



**Fig. 2.** Brain MRI at age 47 (FLAIR). The cerebellum was preserved.

**Table 2**  
Information of the remained four variants.

Variants			Results of prediction algorithm				Validation in the family members				
Location	Gene	Amino acid change	SIFT	PolyPhen2	LRT	MutationTaster	Patient	Mother	Father	Sister	Brother
chr1:26386831	TRIM63	NM_032588:c.T523C;p.S175P	T (0.89)	P (0.481)	D (0.999999)	D (0.693335)	m/m	m/w	m/w	w/w	w/w
chr5:55082379	DDX4	NM_001166534:c.A451C;p.N151H	T (0.84)	B (0)	D (0.999797)	N (0.038222)	m/m	m/m	m/w	m/w	m/w
chr5:55253077	IL6ST	NM_001190981:c.C1016T;p.S339F	D (0.96)	P (0.644)	N (0.717027)	D (0.974338)	m/m	m/w	m/w	m/w	m/w
chr11:94224012	MRE11A	NM_005590:c.C140T;p.A47V	D (1)	D (0.991)	D (1)	D (0.999715)	m/m	m/w	m/w	m/w	m/w

Abbreviations: T, tolerated; P, possibly damaging; D, damaging; B, benign; N, neutral; m, mutant; w, wild type. Values in brackets show prediction scores.

supination test of the hand. Her ataxia was predominantly observed in the lower limb and the trunk. She also presented with dysarthria and walking instabilities, with a wide-based gait. She did not exhibit spasticity or muscle weakness. She did not experience ocular apraxia or nystagmus. Her Mini-Mental State Examination score was 29/30. Electrophysiological tests revealed a pattern of myoclonus of subcortical origin with 100–150 ms jerks (Fig. 1). There were no features of cortical hyperexcitability; specifically, there was neither an abnormal C-reflex response nor a short-latency premyoclonic potential based on back-averaging studies. Brain MRI demonstrated slight atrophy of the cerebral cortex; however, no atrophy was observed in the cerebellum (Fig. 2). Technetium-99m-ECD spectroscopy revealed diffusely reduced cerebral blood flow, while the uptake of the radioisotope was normal in the cerebellum. Blood tests, including albumin, alpha-fetoprotein, and immunoglobulins, were within the normal range. She did not possess telangiectasia. An aggressive investigation for obscure cancer revealed no signs of neoplasms. She did not present with any gastrointestinal symptoms that would be indicative of celiac disease [11]. Abnormal CAG expansion was not detected in the ATN1 [12], ATXN1, ATXN2, and ATXN3 genes [13]. Her parents and two siblings underwent clinical examination and exhibited no myoclonus, tremor, or ataxia.

## 2.2. Genetic analysis

Genomic DNA (gDNA) was extracted from the peripheral lymphocytes of the patients. A genome-wide scan of single nucleotide polymorphisms (SNPs) was performed using the GeneChip Human Mapping 500K Array Set (Affymetrix), selecting for runs of homozygous SNPs (RHSS) more than 3cM in length. Under this condition, the RHSS are able to retrieve more than 98% of the entire length of the autozygous segments generated in first-cousin or second-cousin offspring [14]. gDNA libraries were prepared using SeqCap EZ Human Exome Library v2.0 (Roche NimbleGen, Madison, WI). Sequencing was performed on 100-bp paired-end reads using a HiSeq2000 sequencer (Illumina, San Diego, CA). The reads were aligned to the human reference genome using Burrows–Wheeler Aligner software [15]. Variants were identified using GATK software [16] and annotated using the Annovar tool [17] with the dbSNP Build 135 database, 1000 genomes, and ESP5400 exomes. The sequencing depth was calculated using GATK. All of the

reported genomic locations were in GRCh37/hg19. Control exomes were obtained from 103 patients undergoing exome analysis, and the most common diseases were spinocerebellar ataxia, amyotrophic lateral sclerosis, and Parkinson's disease. The identified mutations were validated via standard polymerase chain reaction (PCR)-based amplification followed by sequence analysis using an Applied Biosystems 3130 Genetic Analyzer (Life Technologies, Carlsbad, CA).

## 2.3. EB virus-transformed lymphoblastoid cell lines (LCLs)

LCLs were established from peripheral blood lymphocytes of the patient [18]. We also used LCLs from a Nijmegen breakage syndrome (NBS) patient, an ATLD patient, parents of the ATLD patient, and a healthy individual [8]. LCLs were cultured in RPMI 1640 media (Life Technologies Corporation, Carlsbad, CA) with 10% fetal bovine serum.

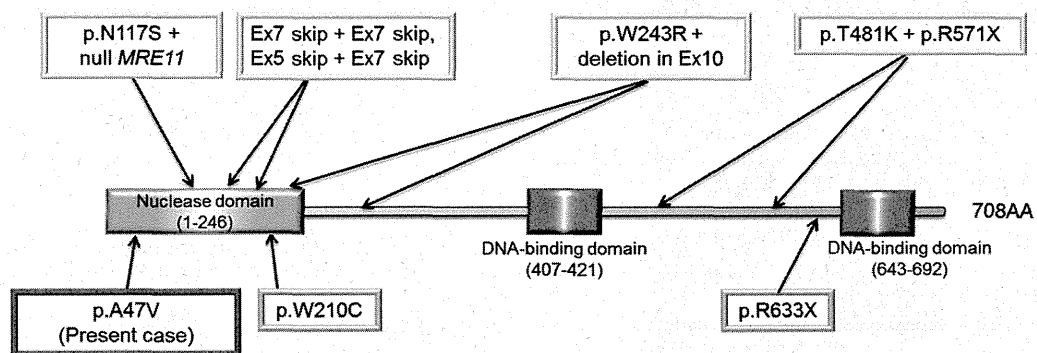
## 2.4. Western blot analysis

Western blot was performed as described previously [8]. We utilized the same primary antibodies as in a previous report [8], except for the inclusion of a rabbit anti-GAPDH polyclonal antibody (1:1000, R&D systems, Minneapolis, MN).

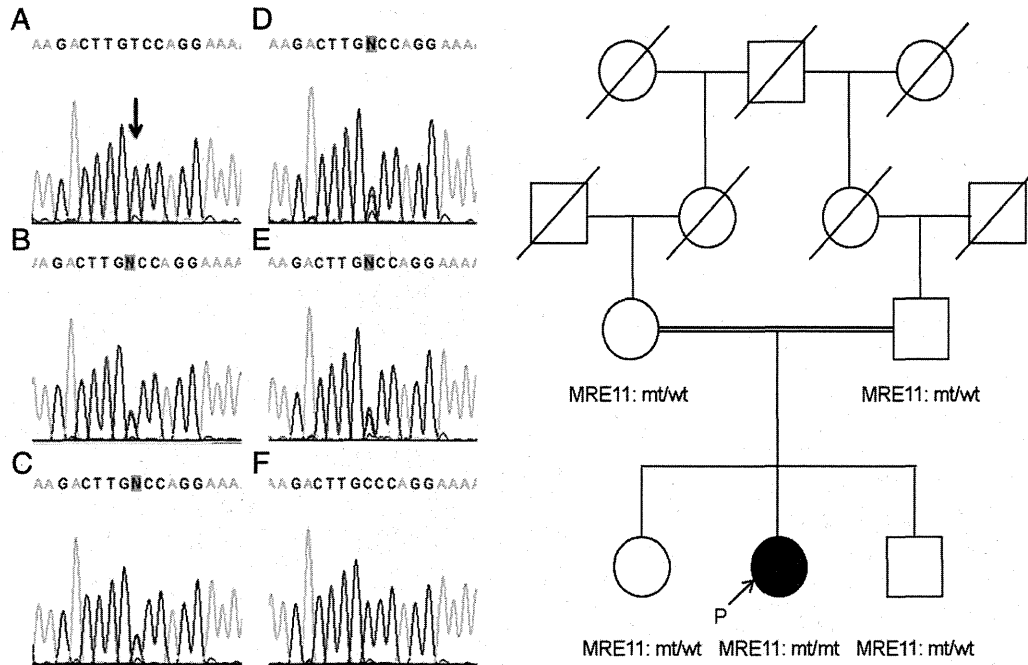
## 3. Results

### 3.1. Genetic analysis

After filtering, we identified one sequence variant in the *MRE11* gene, which was predicted to be damaging based on all four algorithms we adopted (SIFT, polyphen-2, MutationTaster, and LRT) (Tables 1, 2). The mutation (NM\_005590:c.140C>T: p.A47V) was located in the nuclease domain, which is among the most highly conserved regions of DNA damage response factors, and two NBS1 subunits stretch around the outside of the domain (Fig. 3) [19,20]. Additionally, several mutations have been reported in this domain in patients with ATLD [7,8,21,22]. We further validated the mutation in the family using Sanger sequencing, which revealed that her parents and two siblings were heterozygous carriers of this mutation (Fig. 4). This mutation



**Fig. 3.** Schematic representation of the MRE11 protein, including previously reported mutations.



**Fig. 4.** Sanger sequencing results of the identified mutation and the pedigree chart. A, patient; B, mother; C, father; D, sister; E, brother; F, control. The affected residue is indicated by the arrow. The proband's mother, father, sister, and brother are heterozygous carriers of the mutation. Primer sequence: forward primer, TGTCCTCAATTGTGTTGAATATCCCTT; reverse primer, AGGCAAGGTAAGCACCTGAG.


was not detected in 174 healthy subjects. There were no mutations in either *RAD50* or *NBS1*.

### 3.2. Western blot analysis

The expression of Mre11, Rad50, and NBS1 proteins was markedly decreased in the patient compared to a healthy control (Fig. 5).

## 4. Discussion

This patient from consanguineous parents exhibited progressive myoclonic ataxia and was found to possess a novel homozygous mutation in the *MRE11* gene. Accumulating evidence suggests that the clinical symptoms associated with *MRE11* mutations can vary; NBS-like microcephaly, generalized cerebral hypoplasia, dystonia, and facial abnormalities have been reported [8,9,21,23]. Indeed, our patient presented with myoclonus as the primary symptom, and the onset of ataxia was unusually late. Furthermore, this case lacked cerebellar atrophy, which was a novel finding in long-term ATLD.



**Fig. 5.** Western blot analyses of MRE11, RAD50, and NBS1 expression in lymphoblastoid cell lines (LCLs) from the present case (patient). The expression of Mre11 (patient/normal ratio: 0.17), Rad50 (0.08), and NBS1 (0.40) proteins was markedly decreased compared to the healthy control. Nijmegen breakage syndrome (NBS) cells were used as an NBS1-deficient reference, and an anti-GAPDH antibody was used to ensure equal loading. \*, previously reported ATLD family (Family 2, see [8]).

*MRE11* is a component of the MRN (*MRE11/RAD50/NBS1*) complex and is recruited in DNA double-strand break repair with ataxia-telangiectasia mutated protein [8]. A recent structural study suggested that *MRE11-RAD50* is functionally influenced by *NBS1*, and the binding between *MRE11* and *NBS1* is mediated by several distributed, independent interaction sites; thus, single point mutations in the *MRE11* gene most likely do not completely disrupt the *MRE11-NBS1* complex [20]. This hypothesis would be well supported by this patient, who experienced milder symptoms and harbored a single homozygous missense mutation. However, another single homozygous mutation, W210C, has been reported to cause a different phenotype from the present case; all of the examined patients with W210C exhibited cerebellar atrophy [21]. A W210C mutation was suggested to affect an *NBS1* interaction region in *MRE11* [20], and accordingly, the expression of the *NBS1* protein was found to be severely decreased in those patient [21]. In contrast, the decrease in *NBS1* expression was relatively mild in the present case, which may account for the phenotypic differences among patients with different single *MRE11* mutations. Additionally, the non-polar to non-polar modification of the affected residue may play a role in the attenuated phenotype and the less drastic effect on the associated proteins. Moreover, the patient's attenuated ATLD phenotype could be the result of some other modifying mutations that lessen the effect of the mutation.

The primary clinical symptom of this patient was generalized spontaneous myoclonus, which was most prominent in her head and neck. Although we could not identify any lesion that was precisely responsible, rhythmic bursts of approximately 3 Hz accompanying cerebellar ataxia led us to speculate that her involuntary movements originated from a dysfunction in the Triangle of Guillain-Mollaret [24], which is likely altered in ATLD patients. Interestingly, as described in the original PMA cases by Ramsay Hunt [16], our patient also presented with tremors in her upper limbs in addition to myoclonus.

Recently, a separate report also addressed myoclonus and ataxia in a patient with an *MRE11* mutation, and that the patient did not present with apparent epilepsy (personal communications) [17]. Taken together, these cases suggest that patients with *MRE11* mutations can present as PMA.

Finally, this case further supports the theory that mutations in the *MRE11* gene represent a broader phenotype and expands our understanding of these phenotype–genotype correlations. Additionally, *MRE11* mutations should be considered as a potential cause of PMA.

Supplementary data to this article can be found online at <http://dx.doi.org/10.1016/j.jns.2013.11.032>.

#### Conflict of interest

The authors report no conflict of interest.

#### Acknowledgments

Dr. Maruyama was supported by a Funding Program for Next Generation World-Leading Researchers from Cabinet Office, Government of Japan. Dr. Kaji was supported by Grants-in-Aid from the Research Committee of Dystonia, the Ministry of Health, Labour and Welfare of Japan. Dr. Kawakami was supported by a Grant-in-Aid for Scientific Research on Innovative Areas (Brain Environment) from the Ministry of Education, Culture, Sports, Science and Technology in Japan, and a Grant-in-Aid from the Research Committee of CNS Degenerative Diseases, the Ministry of Health, Labour and Welfare of Japan. We thank E. Nakajima (Department of Epidemiology, Research Institute for Radiation Biology and Medicine, Hiroshima University, Hiroshima, Japan) for technical assistance.

#### References

- [1] Marsden CD, Harding AE, Obeso JA, Lu CS. Progressive myoclonic ataxia (the Ramsay Hunt syndrome). *Arch Neurol* 1990;47:1121–5.
- [2] Pennacchio LA, Lehesjoki AE, Stone NE, Willour VL, Virtaneva K, Miao J, et al. Mutations in the gene encoding cystatin B in progressive myoclonus epilepsy (EPM1). *Science* 1996;271:1731–4.
- [3] Bonten E, van der Spoel A, Fornerod M, Grosveld G, d'Azzo A. Characterization of human lysosomal neuraminidase defines the molecular basis of the metabolic storage disorder sialidosis. *Genes Dev* 1996;10:3156–69.
- [4] Minassian BA, Lee JR, Herbrick JA, Huizenga J, Soder S, Mungall AJ, et al. Mutations in a gene encoding a novel protein tyrosine phosphatase cause progressive myoclonus epilepsy. *Nat Genet* 1998;20:171–4.
- [5] Chan EM, Young EJ, Ianzano L, Munteanu I, Zhao X, Christopoulos CC, et al. Mutations in *NHLRC1* cause progressive myoclonus epilepsy. *Nat Genet* 2003;35:125–7.
- [6] Mole SE, Williams RE, Goebel HH. Correlations between genotype, ultrastructural morphology and clinical phenotype in the neuronal ceroid lipofuscinoses. *Neurogenetics* 2005;6:107–26.
- [7] Stewart GS, Maser RS, Stankovic T, Bressan DA, Kaplan MI, Jaspers NG, et al. The DNA double-strand break repair gene *hMRE11* is mutated in individuals with an ataxia–telangiectasia-like disorder. *Cell* 1999;99:577–87.
- [8] Matsumoto Y, Miyamoto T, Sakamoto H, Izumi H, Nakazawa Y, Ogi T, et al. Two unrelated patients with *MRE11A* mutations and Nijmegen breakage syndrome-like severe microcephaly. *DNA Repair (Amst)* 2011;10:314–21.
- [9] Saunders-Pullman R, Raymond D, Stoessl AJ, Hobson D, Nakamura K, Pullman S, et al. Variant ataxia–telangiectasia presenting as primary-appearing dystonia in Canadian Mennonites. *Neurology* 2012;78:649–57.
- [10] Taylor AM, Groom A, Byrd PJ. Ataxia–telangiectasia-like disorder (ATLD)—its clinical presentation and molecular basis. *DNA Repair (Amst)* 2004;3:1219–25.
- [11] Bhatia KP, Brown P, Gregory R, Lennox GG, Manji H, Thompson PD, et al. Progressive myoclonic ataxia associated with coeliac disease. The myoclonus is of cortical origin, but the pathology is in the cerebellum. *Brain* 1995;118(Pt 5):1087–93.
- [12] Becher MW, Rubinsztein DC, Leggo J, Wagster MV, Stine OC, Ranen NG, et al. Dentatorubral and pallidolysian atrophy (DRPLA). Clinical and neuropathological findings in genetically confirmed North American and European pedigrees. *Mov Disord* 1997;12:519–30.
- [13] van Gaalen J, Giunti P, van de Warrenburg BP. Movement disorders in spinocerebellar ataxias. *Mov Disord* 2011;26:792–800.
- [14] Huqun, Fukuyama S, Morino H, Miyazawa H, Tanaka T, Suzuki T, et al. A quantitatively-modeled homozygosity mapping algorithm, qHomozygosityMapping, utilizing whole genome single nucleotide polymorphism genotyping data. *BMC Bioinforma* 2010;11(Suppl. 7):S5.
- [15] Li H, Durbin R. Fast and accurate short read alignment with Burrows–Wheeler transform. *Bioinformatics* 2009;25:1754–60.
- [16] McKenna A, Hanna M, Banks E, Sivachenko A, Cibulskis K, Kernytzky A, et al. The genome analysis toolkit: a MapReduce framework for analyzing next-generation DNA sequencing data. *Genome Res* 2010;20:1297–303.
- [17] Wang K, Li M, Hakonarson H. ANNOVAR: functional annotation of genetic variants from high-throughput sequencing data. *Nucleic Acids Res* 2010;38:e164.
- [18] Bird AG, McLachlan SM, Britton S. Cyclosporin A promotes spontaneous outgrowth in vitro of Epstein–Barr virus-induced B-cell lines. *Nature* 1981;289:300–1.
- [19] Stracker TH, Petrini JH. The *MRE11* complex: starting from the ends. *Nat Rev Mol Cell Biol* 2011;12:90–103.
- [20] Schiller CB, Lammens K, Guerini I, Coordest B, Feldmann H, Schlauderer F, et al. Structure of *Mre11–Nbs1* complex yields insights into ataxia–telangiectasia-like disease mutations and DNA damage signaling. *Nat Struct Mol Biol* 2012;19:693–700.
- [21] Fernet M, Gribaa M, Salih MA, Seidahmed MZ, Hall J, Koenig M. Identification and functional consequences of a novel *MRE11* mutation affecting 10 Saudi Arabian patients with the ataxia telangiectasia-like disorder. *Hum Mol Genet* 2005;14:307–18.
- [22] Oba D, Hayashi M, Minamitani M, Hamano S, Uchisaka N, Kikuchi A, et al. Autopsy study of cerebellar degeneration in siblings with ataxia–telangiectasia-like disorder. *Acta Neuropathol* 2010;119:513–20.
- [23] Delia D, Piane M, Buscemi G, Savio C, Palmeri S, Lulli P, et al. *MRE11* mutations and impaired ATM-dependent responses in an Italian family with ataxia–telangiectasia-like disorder. *Hum Mol Genet* 2004;13:2155–63.
- [24] Shibasaki H. Electrophysiological studies of myoclonus. *Muscle Nerve* 2000;23:321–35.

tried to run (as result of a verbal order or spontaneously), a dissynergic, propulsive pattern emerged, resulting in a festinating gait with lateral displacement of the body (see Video Segment 1). Skilled movements of the upper limbs were preserved. The boy's score on the Leiter-R IQ test was 78, and his performance on the Tower of London test was within normal range ( $z = -0.50$ ). A trial with levodopa (L-dopa)/carbidopa was ineffective. Starting from age 9 years, brain magnetic resonance imaging revealed progressive cerebral and cerebellar atrophy. Proton magnetic resonance spectroscopy detected a decline in N-acetylaspartate levels and increased lipid signals in both the cerebral white matter and the basal ganglia. Generalized myoclonic and tonic seizures, which were triggered by photic stimulation, were observed first at age 11 years. Somatosensory stimulation of the limbs evoked giant cortical potentials, suggesting cortical myoclonus.

At age 12 years, the boy lost the ability to read and write, although social interaction and verbal comprehension were relatively preserved (Vineland Adaptive Behavior Scale: socialization domain, 6 years and 2 months; receptive sub-domain, 7 years and 9 months). Between ages 12 and 15 years, he experienced a further clinical decline, with severe hypokinesia and bradykinesia, impairment of postural reactions, ataxia, continuous rest and action myoclonic jerks, hypomimia, anarthric mutism, and upper limb-kinetic apraxia (see Video Segment 2). Visual functions remained unaffected. *CLN6* gene sequencing revealed a homozygous c.700T→C transition (p.Phe234Leu), which involved a transmembrane domain (TM6) of the protein.<sup>3</sup> The alteration was confirmed in the parents' DNA, thus suggesting possible consanguinity.

### Discussion

Hypokinetic rigid syndrome has been associated with *CLN2*, *CLN3*, and *CLN6* (Kufs type A) diseases and *CLN6* with *ATP13A2* gene mutation.<sup>4,5</sup> In some patients, L-dopa/carbidopa-responsiveness was reported.<sup>4,5</sup> In our patient, alteration in the running pattern during the early stage of the disease could evoke the freezing phenomenon observed in Parkinson's disease.<sup>6</sup> However, he never exhibited a freezing gait phenomenon; in addition, the deteriorated pattern of running did not totally fit with the current definition of freezing.<sup>6</sup> Alternatively, the dissociation between walking and running would suggest a high-order motor disorder, such as apraxia.<sup>7</sup> The extension of the term *apraxia* to motor disorders, which cannot be considered *sensu stricto* learned<sup>8</sup> (such as walking or running), is questionable. Nevertheless, gait apraxia has become a common term in both adult neurology<sup>7</sup> and child neurology, and the description of the movement disorder affecting our patient as *running apraxia* best summarizes the characteristics we observed.

### Legends to the Videos

**Video Segment 1.** At age 8 years, mild action tremor is observed during the finger-to-nose test (left > right); bradykinesia and hypomimia are present; and clumsiness and festination are observed when the boy tries to jump. His gait exhibits reduced stride length, and he has a slightly reduced arm swing on the left. A slight asymmetry in dragging the

left foot is also observed. When running, the patient shows a remarkable and selective running inability. In the effort to run, a sort of festinating gait is observed. (This video segment is part of a protracted recording that lasted longer than 1 hour, and no variation in the pattern of dissociation between gait and running was observed for the entire duration of the test).

**Video Segment 2.** At age 15 years, the patient exhibits hypokinetic rigid syndrome with severe postural reaction impairment; continuous rest and action, multifocal, myoclonic jerks; and kinetic apraxia of the fingers. ■

**Acknowledgments:** We thank Federica Invernizzi (Fondazione IRCCS Istituto Neurologico Carlo Besta, Milan) for her help in *CLN6* gene sequencing and Fiorella Piemonte (Ospedale Bambino Gesù, Rome) for the enzymatic assay of palmitoyl protein thioesterase 1 and tripeptidyl peptidase 1 activities in fibroblasts.

Vincenzo Leuzzi, MD,<sup>1\*</sup> Barbara Garavaglia, BioD,<sup>2</sup>  
Filippo Manti, MD,<sup>1</sup> Sara Bertino, MD,<sup>1</sup> and  
Nardo Nardocci, MD<sup>2</sup>

<sup>1</sup>Department of Paediatrics, Child Neurology and  
Psychiatry, Sapienza Università di Roma, Rome, Italy;

<sup>2</sup>Department of Child Neurology, Fondazione IRCCS  
Istituto Neurologico Carlo Besta, Milan, Italy

### References

- Williams RE, Mole SE. New nomenclature and classification scheme for the neuronal ceroid lipofuscinoses. *Neurology* 2012;79:183-191.
- Garcia-Cazorla A, Ortez C, Perez-Duenas B, et al. Hypokinetic-rigid syndrome in children and inborn errors of metabolism. *Eur J Paediatr Neurol* 2011;15:295-302.
- Heine C, Quitsch A, Storch S, et al. Topology and endoplasmic reticulum retention signals of the lysosomal storage disease-related membrane protein *CLN6*. *Mol Membr Biol* 2007;24:74-87.
- Le NM, Parikh S. Late infantile neuronal ceroid lipofuscinosis and dopamine deficiency. *J Child Neurol* 2012;27:234-237.
- Bras J, Verloes A, Schneider SA, Mole SE, Guerreiro RJ. Mutation of the parkinsonism gene *ATP13A2* causes neuronal ceroid-lipofuscinosis. *Hum Mol Genet* 2012;21:2646-2650.
- Nutt JG, Bloem BR, Giladi N, Hallett M, Horak FB, Nieuwboer A. Freezing of gait: moving forward on a mysterious clinical phenomenon. *Lancet Neurol* 2011;10:734-744.
- Elble RJ. Gait and dementia: moving beyond the notion of gait apraxia. *J Neural Transm* 2007;114:1253-1258.

## DYT6 in Japan—Genetic Screening and Clinical Characteristics of the Patients



*THAP1* (thanatosis-associated protein [THAP] domain-containing, apoptosis-associated protein 1) has been identified as a cause of autosomal dominant primary dystonia (DYT6). Mutations in the *THAP1* gene were first reported in Amish-Mennonites families,<sup>1</sup> then in European and other American families,<sup>2,3</sup> and recently in Chinese families.<sup>4</sup> Patients with *THAP1* mutations typically develop dystonia

**TABLE 1.** Clinical characteristics of the four patients with THAP1 sequence variants

Patient	Variant (amino acid change)	Sex	Family history	Onset, y	Onset symptom	Disease course	Treatment	Response to treatment
1	c.389_390delCA (p.S130fs133X)	Male	Positive <sup>a</sup>	12	WC	Gradually expanded to the entire body	BTX, GPI-DBS, Vo-DBS	Partial
2	c.413delC (p.T137fs151X)	Female	Positive: Father; WC	9	WC	Localized in the right hand for- > 30 y, then developed tor- ticollis and expanded to the trunk and legs	BTX	Refractory
3	c.89C>A (p.Pro30His)	Male	Positive: Father, brother; WT	12	Right hand tremor	Localized in the right hand for- > 30 y, then developed torticollis	BTX	Refractory
4	c.173T>C (p.Phe58Ser)	Female	Negative	8	Bilateral hand tremor	Gradually expanded to the entire body	Clonazepam	Refractory

<sup>a</sup>See Miyamoto et al., 2012.<sup>5</sup>

WC, writers' cramp; BTX, botulinum toxin injection; GPI-DBS, deep brain stimulation to the internal globus pallidus; Vo-DBS, deep brain stimulation to the ventral oral nucleus of the thalamus; WT, writing tremor.

in their youth, and the muscles of the cranium, neck, and larynx are commonly involved. Here, we report the frequency of the *THAP1* gene mutation in primary dystonia among the Japanese population, and we describe their clinical characteristics.

Two hundred eighty Japanese patients who had primary dystonia (183 with focal dystonia, 51 with segmental dystonia, 5 with multifocal dystonia, and 41 with generalized dystonia) without *DYT1* mutations were enrolled. The genetic study was approved by the ethics committee, and participants provided written informed consent. The mean age of onset was  $41.9 \pm 15.9$  years (range, 5–89 years), and 52 patients (17.7%) had an age of onset < 26 years. Twenty-

seven patients (9.6%) had a positive family history of dystonia. All three exons of the *THAP1* gene were directly sequenced. We identified four sequence variants, and all of them were novel: two deletions (patient 1, c.389\_390delCA [p.S130fs133X]<sup>5</sup>; patient 2, c.413delC [p.T137fs151X]) and two missense sequence variants (patient 3, c.89C>A [p.Pro30His]; patient 4, c.173T>C [p.Phe58Ser]). These four sequence variants were not present in 206 population-matched control alleles or in the dbSNP135 or Exome Variant Server databases. The two missense variations were predicted to be damaging by the PolyPhen-2 (Polymorphism Phenotyping version 2) and scale-invariant feature transform (SIFT) algorithms, although their pathogenic state is not certain.

Additional Supporting Information may be found in the online version of this article.

**Correspondence to:** Dr. Ryosuke Miyamoto, Department of Clinical Neuroscience, Institute of Health Biosciences, Graduate School of Medicine, University of Tokushima, Tokushima, Japan 770-8503; ryom@tokushima-u.ac.jp

**Funding agencies:** This work was supported by Grants-in-Aid from the Dystonia Research Committee, Ministry of Health, Labor, and Welfare of Japan (to R.K.); the Funding Program for Next-Generation, World-Leading Researchers from the Cabinet Office, Government of Japan; a Grant-in-Aid for Scientific Research on Innovative Areas (Brain Environment) from the Ministry of Education, Culture, Sports, Science and Technology of Japan (to H.Maryama); and a Grant-in-Aid from the Research Committee of Central Nervous System Degenerative Diseases, the Ministry of Health, Labor, and Welfare of Japan (to H.Kawakami).

**Relevant conflicts of interest/financial disclosures:** Nothing to report. Full financial disclosures and author roles may be found in the online version of this article.

**Received:** 18 August 2013; **Revised:** 6 October 2013; **Accepted:** 21 October 2013

**Published online 13 November 2013 in Wiley Online Library** (wileyonlinelibrary.com). DOI: 10.1002/mds.25745

## Cases

Patient 1 (c.389\_390delCA) was a member of a large family that exhibited various types of dystonia, and he had the *THAP1* mutation identified during the course of this screening project.<sup>5</sup> Because his dystonia symptoms became exacerbated a few years after he underwent deep brain stimulation (DBS) to the internal globus pallidus, we performed a secondary DBS surgery targeting the thalamic ventral oral complex nucleus (Vo-DBS). The Vo-DBS alleviated hand, limb, and axial symptoms. Patient 2 (c.413delC) and patient 3 (c.89C>A) exhibited similar clinical courses, which were characterized by a long progression-free period. Patient 2 developed mild writers' dystonia in her childhood followed by a torticollis after a 30-year period of no apparent disease progression. Patient 3 presented a right-hand tremor at age 12 years, which was localized in the right hand over the next 30 years, and then developed torticollis.

Notably, these patients claimed an unendurable emotional stress shortly before the onset of the torticollis, and they had a family history of upper-limb dystonia. Patient 4 (c.173T>C), who was without an apparent family history of dystonia, exhibited unique, generalized myoclonic movements. Her atypical myoclonic movements fluctuated wildly; they were inconsistent and were accompanied by prominent exacerbation from emotional stress. Although she eventually was diagnosed with writers' dystonia and torticollis, we first gave her a diagnosis of psychogenic dystonia (Table 1).

### Discussion

The frequency of the *THAP1* gene mutation was 1.4% (4 of 280 patients) in Japanese patients with primary dystonia, which was similar to the rates reported in other ethnicities. In addition, our findings further support the possibility that tremors and myoclonic movements may be potential presentations associated with *THAP1* mutations.<sup>6,7</sup> The findings also suggest that the clinical disease course in *DYT6* patients, who have rarely been studied, are not invariably linear and could include a long-term progression-free period. Respite periods can have importance in terms of planning treatment strategies for *THAP1* mutation carriers. ■

### Legends to the Video

**Video Segment 1:** At age 61 years, patient 2 exhibited neck and truncal dystonia with slow wiggle movement. Her arm swing was slightly reduced and seemed stiff. She claimed to have severe stiffness in her neck and trunk, which was refractory to botulinum toxin. She also had moderate writer's cramp, but she refused to be video-recorded only when writing.

**Video Segment 2:** At age 51 years, upon finger-nose-finger testing, patient 3 exhibited continuous tremor in his right hand. His left hand seemed to escape from the tremulous movement. Note that his right hand tremor was seen at rest, at fixed position, and when moving. He also had severe writer's cramp.

Ryosuke Miyamoto, MD,<sup>1,2,3\*</sup> Hidetaka Koizumi, MD,<sup>1,3</sup>  
Hiroyuki Morino, MD,<sup>2</sup> Toshitaka Kawarai, MD,<sup>1</sup>

Hirofumi Maruyama, MD,<sup>2</sup> Yohei Mukai, MD,<sup>3,4</sup>  
Ai Miyashiro, MD,<sup>1,3</sup> Wataru Sako, MD,<sup>5</sup>  
Yuishin Izumi, MD,<sup>1</sup> Hideshi Kawakami, MD,<sup>2</sup>  
and Ryuji Kaji, MD<sup>1,3</sup>

<sup>1</sup>*Department of Clinical Neuroscience, Institute of Health Biosciences, Graduate School of Medicine, University of Tokushima, Tokushima, Japan*

<sup>2</sup>*Department of Epidemiology, Research Institute for Radiation Biology & Medicine, Hiroshima University, Hiroshima, Japan*

<sup>3</sup>*The Movement Disorders Clinic, Ijinkai Takeda General Hospital, Kyoto, Japan*

<sup>4</sup>*Department of Neurology, National Center of Neurology and Psychiatry, Tokyo, Japan*

<sup>5</sup>*Center for Neurosciences, The Feinstein Institute for Medical Research, Manhasset, New York, USA*

### References

1. Fuchs T, Gavarini S, Saunders-Pullman R, Raymond D, Erlich ME, Bressman SB, Ozelius LJ. Mutations in the *THAP1* gene are responsible for *DYT6* primary torsion dystonia. *Nat Genet* 2009; 41:286-288.
2. Bressman SB, Raymond D, Fuchs T, Heiman GA, Ozelius LJ, Saunders-Pullman R. Mutations in *THAP1* (*DYT6*) in early-onset dystonia: a genetic screening study. *Lancet Neurol* 2009;8:441-446.
3. Djarmati A, Schneider SA, Lohmann K, et al. Mutations in *THAP1* (*DYT6*) and generalised dystonia with prominent spasmodic dysphonia: a genetic screening study. *Lancet Neurol* 2009;8: 447-452.
4. Song W, Chen Y, Huang R, Chen K, Pan P, Yang Y, Shang HF. Novel *THAP1* gene mutations in patients with primary dystonia from southwest China. *J Neurol Sci* 2011;309:63-67.
5. Miyamoto R, Ohta E, Kawarai T, et al. Broad spectrum of dystonia associated with a novel thanatosis-associated protein domain-containing apoptosis-associated protein 1 mutation in a Japanese family with dystonia 6, torsion. *Mov Disord* 2012;27: 1324-1325.
6. Houlden H, Schneider SA, Paudel R, et al. *THAP1* mutations (*DYT6*) are an additional cause of early-onset dystonia. *Neurology* 2010;74:846-850.
7. Clot F, Grabli D, Burbaud P, et al. Screening of the *THAP1* gene in patients with early-onset dystonia: myoclonic jerks are part of the dystonia 6 phenotype. *Neurogenetics* 2011;12:87-89.



## LETTER TO THE EDITOR

### Ocular paradoxical movement and severity of Parkinson's disease

Hideyuki Matsumoto,<sup>1,2</sup> Yasuo Terao<sup>2</sup> and Yoshikazu Ugawa<sup>3</sup>

1 Department of Neurology, Japanese Red Cross Medical Centre, Japan

2 Department of Neurology, University of Tokyo, Japan

3 Department of Neurology, School of Medicine, Fukushima Medical University, Japan

Correspondence to: Hideyuki Matsumoto, MD, PhD,  
Department of Neurology,  
Japanese Red Cross Medical Centre,  
4-1-22 Hiroo, Shibuya-ku, Tokyo 150-8935, Japan  
E-mail: hideyukimatsumoto.jp@gmail.com

Sir,

We read with great interest the article entitled 'Visual exploration in Parkinson's disease and Parkinson's disease dementia' recently published in *Brain* by Archibald *et al.* (2013), because the pattern of results shows a remarkable coincidence with the results of our study on visual exploration in Parkinson's disease (Matsumoto *et al.*, 2011a, 2012).

Archibald *et al.* (2013) investigated how cognitive function affects saccade amplitude and fixation duration during visual exploration in Parkinson's disease. In an observation similar to our own (Matsumoto *et al.*, 2011a), they demonstrated that the visual exploration of complex figures in patients with Parkinson's disease was characterized by a scanning pattern consisting of hypometric saccades with fixation durations longer than those seen in normal healthy subjects. Hallett (2011) pointed out that these ocular features in Parkinson's disease could represent a type of bradykinesia called 'ocular bradykinesia', and that they might be caused by basal ganglia dysfunction. We also presented data supporting the contribution of basal ganglia dysfunction to the ocular bradykinesia and ocular paradoxical movement in Parkinson's disease based on our experiments with a visual exploration task as well as oculomotor tasks (Matsumoto *et al.*, 2012).

An important implication of the Archibald *et al.* (2013) results is the influence of cognitive function on visual exploration. In experiments consisting of five kinds of tasks that demand higher brain function in which subjects matched comparator images against a central stimulus using four different images, Archibald *et al.* (2013) found that patients with Parkinson's disease with dementia with more severe motor dysfunction as well as cognitive decline made saccades with smaller amplitudes and longer fixation durations compared with those made by patients with Parkinson's

disease without cognitive impairment. They also showed that saccade amplitude and fixation duration did not largely differ between patients with Parkinson's disease without cognitive impairment and normal healthy subjects. They propose that the observed changes in scanning behaviour reveal the efficiency with which fixations and saccades are deployed in the build-up to a cognitive response, and that the fixation duration in particular may be used as a predictor of cognitive decline. This is a very important point since the visual fixation pattern and duration of a visual scene is known to affect the perception and memory of that scene (Chapman *et al.*, 2003), and since changes in scanning behaviour may hamper the cognition of the scene explored.

It should be noted, however, that scanning parameters such as saccade amplitude and fixation duration can vary greatly depending on the task in use or even on the characteristics of the presented images. In our eye-tracking study, which excluded cognitively impaired patients with Parkinson's disease (Matsumoto *et al.*, 2011a), patients with Parkinson's disease memorizing images of varying complexity (a cube, two overlapping pentagons, a house, and the Rey-Osterrieth complex figure) made saccades with smaller amplitudes and longer fixation durations compared with healthy control subjects. Importantly, although patients with Parkinson's disease made saccades with long fixation durations when scanning simple figures, they reduced their fixation durations when scanning more complex figures. Interestingly, the differences in scanning parameters between patients with Parkinson's disease and normal healthy subjects did not correspond to differences in their rates of success at accurately reproducing the figures. Therefore, the differences in exploration strategy in patients with Parkinson's disease did not directly translate into disruption of their visual memory of the images.

Received April 14, 2013. Accepted April 18, 2013. Advance Access publication June 5, 2013

© The Author (2013). Published by Oxford University Press on behalf of the Guarantors of Brain. All rights reserved.

For Permissions, please email: journals.permissions@oup.com

These changes in scanning parameters emerged even though we did not explicitly instruct the subjects to scan the images with saccades. To explain this phenomenon, we proposed the notion of 'ocular kinesie paradoxale' or 'ocular paradoxical movement'. The number of visual cues is greater in complex figures, and it seems that patients with Parkinson's disease can use these visual cues to generate saccades. Similarly, akinetic patients with Parkinson's disease can move easily if sensory guidance is present, such as when they are asked to walk along regularly-spaced lines drawn on the floor; this phenomenon is called somatomotor paradoxical movement (Glickstein and Stein, 1991; Okuma, 2006). Similarly, patients with Parkinson's disease may be able to initiate saccades more efficiently, without ocular freezing, with the help of the many visual cues found in complex images.

The purposes, subjects, devices, tasks, etc. differ between our study and that of Archibald *et al.* (2013), but some aspects of their study merit comment based on our experience in a similar analysis, with particular reference to ocular paradoxical movement.

First, the tasks in their study used complex figures with many visual cues. When subjects visually explore such images, ocular paradoxical movement is expected to play a more important role than it does in the exploration of simpler images. It should have been especially important in viewing the overlapping figures, which contained abundant visual cues. However, Archibald *et al.* (2013) did not point out the possibility that ocular paradoxical movement could contribute to impairment of visual exploration in patients with Parkinson's disease or Parkinson's disease with dementia. Because all of their tasks contain relatively abundant visual cues, we assume that the similarity between saccade amplitudes and fixation durations in patients with Parkinson's disease without cognitive impairment and those in healthy control subjects could be explained by ocular paradoxical movement.

Secondly, the severity of cognitive and motor dysfunction in Parkinson's disease can influence not only the scanning parameters used during visual exploration, such as saccade amplitude and fixation duration, but also ocular paradoxical movement. Although the relationship between somatomotor paradoxical movement and the severity of motor symptoms in Parkinson's disease remains to be elucidated, patients with Parkinson's disease in the advanced stage are known to compensate for their motor deficits by relying on sensory guidance (Brown and Marsden, 1988). Neuroimaging studies have shown that, whereas the dysfunction of the supplementary motor area plays a substantial role in the pathophysiology of Parkinson's disease (Playford *et al.*, 1992; Samuel *et al.*, 1997), enhanced lateral premotor cortex activity can compensate for impaired supplementary motor area function in the presence of visual input (Hanakawa *et al.*, 1999). Although it is not clear whether this holds true in the oculomotor domain (Alexander *et al.*, 1986), our study on saccade abnormalities in patients with Parkinson's disease found that, as patients with Parkinson's disease become progressively impaired in making voluntary saccades in the absence of visual signals, they tend to inadvertently make 'reflexive' saccades towards suddenly presented visual signals (Terao *et al.*, 2011). Terao *et al.* (2013) suggested that these inadvertent saccades may emerge as a functional compensation for basal ganglia dysfunction in Parkinson's disease. In patients with Parkinson's disease with normal cognition,

mild cognitive impairment, or Parkinson's disease with dementia, these changes can arise from different extents of pathological burden in the oculomotor system, not only in the basal ganglia but also in the frontal cortex as well as the parieto-occipital cortex.

Finally, shifts in the strategy of visual exploration could also contribute to the differences between patients with Parkinson's disease and Parkinson's disease with dementia. In visual exploration, both the mechanism of top-down instruction (in which attention is allocated to an object in a goal-oriented manner) and that of bottom-up salience (in which attention is captured by a visually conspicuous object irrespective of the subject's intention) are most likely at work. A similar shift from one exploratory strategy to the other is also noted in healthy control subjects depending on the context (Ludwig and Gilchrist, 2002; Terao *et al.*, 2002; Matsumoto *et al.*, 2011b). Some of the cognitively demanding tasks in Archibald *et al.* (2013) experiments would have predominantly engaged the top-down instruction mechanism, as the subjects had to actively search for a target (e.g. the overlapping figures task), whereas other easier tasks (e.g. the clock-matching task) may have involved the bottom-up salience mechanism. The interaction between the scanning strategy used in a particular task and oculomotor paradoxical movement must be considered, and can be assessed using images with minimal and maximal numbers of visual cues. To clarify this interaction, the authors could compare saccade amplitudes and fixation durations in tasks with varying levels of cognitive demand (as reflected in the varying error rates), and also varying numbers of visual cues, between patients with Parkinson's disease and Parkinson's disease with dementia. The most difficult task, defined as that with the largest number of visual cues, would be the overlapping figures task. To reveal the effect of greater Parkinson's disease severity on ocular paradoxical movement, a sub-analysis might be useful.

Taking all the data together, we consider that ocular paradoxical movement and visual exploration strategy both contributed to the results of the eye-tracking analysis reported by Archibald *et al.* (2013). We assume that an analysis comparing the scanning parameters used in simple and complex tasks by patients with Parkinson's disease and Parkinson's disease with dementia would yield information about how Parkinson's disease severity relates to ocular paradoxical movement. Resolving the relationship between ocular paradoxical movement, scanning strategy and the severity of Parkinson's disease through studies such as ours and that of Archibald *et al.* (2013) will certainly lead to a breakthrough regarding the pathophysiology of Parkinson's disease and related cognitive impairments.

## Funding

Dr Terao is supported by a Research Project Grant-in-Aid for Scientific Research from the Ministry of Education, Culture, Sports, Science, and Technology of Japan (22590954), and research funds from THE KATO MEMORIAL TRUST FOR NAMBYO RESEARCH, Japan. Dr Ugawa is supported by a Research Project Grant-in-Aid for Scientific Research from the Ministry of Education, Culture, Sports, Science, and Technology of Japan (22390181, 25293206), and grants from the Research

Committee for rTMS Treatment of Parkinson's Disease, the Research Committee for Intractable Pain, the Research Committee for Dystonia, and the Research Committee for Ataxic Disease, the Ministry of Health, Labour, and Welfare of Japan, and by grants from the Magnetic Health Science Foundation, NOVARTIS Foundation (Japan) for the Promotion of Science, and from the Uehara Memorial Foundation.

## References

- Alexander GE, DeLong MR, Strick PL. Parallel organization of functionally segregated circuits linking basal ganglia and cortex. *Annu Rev Neurosci* 1986; 9: 357–81.
- Archibald NK, Hutton SB, Clarke MP, Mosimann UP, Burn DJ. Visual exploration in Parkinson's disease and Parkinson's disease dementia. *Brain* 2013; 136: 739–50.
- Brown RG, Marsden CD. Internal versus external cues and the control of attention in Parkinson's disease. *Brain* 1988; 111: 323–45.
- Chapman P. Remembering what we've seen: Predicting recollective experience from eye movements when viewing everyday scenes. Underwood G, editor. *Cognitive Processes in Eye Guidance*. New York: Oxford University Press; 2003. p. 237–58.
- Glickstein M, Stein J. Paradoxical movement in Parkinson's disease. *Trends Neurosci* 1991; 14: 480–2.
- Hallett M. Bradykinesia: why do Parkinson's patients have it and what trouble does it cause? *Mov Disord* 2011; 26: 1579–81.
- Hanakawa T, Fukuyama H, Katsumi Y, Honda M, Shibasaki H. Enhanced lateral premotor activity during paradoxical gait in Parkinson's disease. *Ann Neurol* 1999; 45: 329–36.
- Ludwig CJ, Gilchrist ID. Stimulus-driven and goal-driven control over visual selection. *J Exp Psychol Hum Percept Perform* 2002; 28: 902–12.
- Okuma Y. Freezing of gait in Parkinson's disease. *J Neurol* 2006; 253 (suppl 7): VII27–32.
- Matsumoto H, Terao Y, Furubayashi T, Yugeta A, Fukuda H, Emoto M, et al. Small saccades restrict visual scanning area in Parkinson's disease. *Mov Disord* 2011a; 26: 1619–26.
- Matsumoto H, Terao Y, Yugeta A, Fukuda H, Emoto M, Furubayashi T, et al. Where do neurologists look when viewing brain CT images? An eye-tracking study involving stroke cases. *PLoS One* 2011b; 6: e28928.
- Matsumoto H, Terao Y, Furubayashi T, Yugeta A, Fukuda H, Emoto M, et al. Basal ganglia dysfunction reduces saccade amplitude during visual scanning in Parkinson's disease. *Basal Ganglia* 2012; 2: 73–8.
- Playford ED, Jenkins IH, Passingham RE, Nutt J, Frackowiak RS, Brooks DJ. Impaired mesial frontal and putamen activation in Parkinson's disease: a positron emission tomography study. *Ann Neurol* 1992; 32: 151–61.
- Samuel M, Ceballos-Baumann AO, Turjanski N, Boecker H, Gorospe A, Linazasoro G, et al. Pallidotomy in Parkinson's disease increases supplementary motor area and prefrontal activation during performance of volitional movements an H2(15)O PET study. *Brain* 1997; 120: 1301–13.
- Terao Y, Andersson NE, Flanagan JR, Johansson RS. Engagement of gaze in capturing targets for future sequential manual actions. *J Neurophysiol* 2002; 88: 1716–25.
- Terao Y, Fukuda H, Ugawa Y, Hikosaka O. New perspectives on the pathophysiology of Parkinson's disease as assessed by saccade performance: a clinical review. *Clin Neurophysiol* 2013, in press.
- Terao Y, Fukuda H, Yugeta A, Hikosaka O, Nomura Y, Segawa M, et al. Initiation and inhibitory control of saccades with the progression of Parkinson's disease—changes in three major drives converging on the superior colliculus. *Neuropsychologia* 2011; 49: 1794–806.

# Cortical hemoglobin concentration changes underneath the coil after single-pulse transcranial magnetic stimulation: a near-infrared spectroscopy study

Toshiaki Furubayashi, Hitoshi Mochizuki, Yasuo Terao, Noritoshi Arai, Ritsuko Hanajima, Masashi Hamada, Hideyuki Matsumoto, Setsu Nakatani-Enomoto, Shingo Okabe, Akihiro Yugeta, Satomi Inomata-Terada and Yoshikazu Ugawa  
*J Neurophysiol* 109:1626-1637, 2013. First published 28 December 2012; doi:10.1152/jn.00980.2011

---

## You might find this additional info useful...

---

This article cites 84 articles, 24 of which can be accessed free at:

</content/109/6/1626.full.html#ref-list-1>

Updated information and services including high resolution figures, can be found at:

</content/109/6/1626.full.html>

Additional material and information about *Journal of Neurophysiology* can be found at:

<http://www.the-aps.org/publications/jn>

---

This information is current as of July 7, 2014.