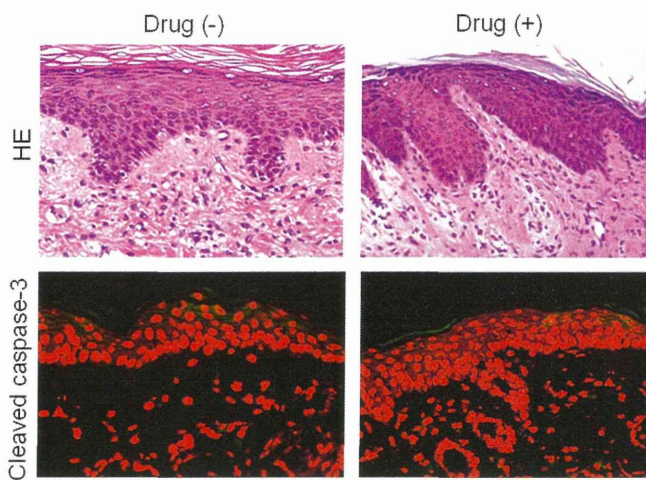

**FIG E8.** Skin grafts from patients with ODSRs were transplanted onto NOG mice, which were then injected with PBMCs from the same patients, followed by the causative drug or vehicle. These mice showed no changes in appearance of the skin-grafted areas. Histopathologically, there were few dead keratinocytes and few cleaved caspase-3-positive cells in the skin graft. Samples from patient 2 with ODSR were analyzed. *HE*, Hematoxylin and eosin.

**TABLE E1.** Patient information

Case	Age (y)/sex	Causative drug	Type of cADR	SI
SJS/TEN				
1	55/M	Acetaminophen	TEN	2.4
2	46/M	Acetaminophen	SJS	2.0
3	49/F	Acetaminophen	SJS	2.3
4	49/M	Benzbromarone	SJS	2.9
5	37/F	Amoxicillin	SJS	2.0
6	71/M	Phenytoin	SJS	2.5
ODSR				
1	70/M	Acetaminophen	Maculopapular	2.0
2	78/M	Phenytoin	Maculopapular	6.7

cADR, Cutaneous adverse drug reaction; F, female; M, male; SI, stimulation index.

- 5 Thom J, Gilmore G, Yi Q et al. Measurement of soluble P-selectin and soluble CD40 ligand in serum and plasma. *J Thromb Haemost* 2004; **11**:2067–9.
- 6 Kasperska-Zajac A, Sztylec J, Machura E, Jop G. Plasma IL-6 concentration correlates with clinical disease activity and serum C-reactive protein concentration in chronic urticaria patients. *Clin Exp Allergy* 2011; **41**:1386–91.
- 7 Toubi E, Adir-Shani A, Kessel A et al. Immune aberrations in B and T lymphocytes derived from chronic urticaria patients. *J Clin Immunol* 2000; **20**:371–8.
- 8 Hermes B, Worm M, Nowak F et al. Upregulation of CD40 and CD40 ligand expression in IgE-associated cutaneous diseases. *Acta Derm Venereol* 1997; **77**:441–5.
- 9 Kasperska-Zajac A, Rogala B. Platelet activation during allergic inflammation. *Inflammation* 2007; **30**:161–6.
- 10 Kasperska-Zajac A, Rogala B, Nowakowski M. Assessment of platelet activity as expressed by plasma levels of platelet factor 4 and  $\beta$ -thromboglobulin in patients with chronic idiopathic urticaria. *Exp Dermatol* 2005; **14**:515–18.
- 11 Kasperska-Zajac A, Brzoza Z, Rogala B. Platelet function in cutaneous diseases. *Platelets* 2008; **19**:317–21.
- 12 Kasperska-Zajac A. Acute phase response in chronic urticaria. *J Eur Acad Dermatol Venereol* 2011; (in press).
- 13 Kasperska-Zajac A, Grzanka A, Czecior E, Misiolek M, Rogala B, Machura E. Acute phase inflammatory markers in patients with non-steroidal anti-inflammatory drugs (NSAIDs)-induced acute urticaria/angioedema and after aspirin challenge. *J Eur Acad Dermatol Venereol* 2012; 21 February. doi: 10.1111/j.1468-3083.2012.04486.x.

Funding sources: this study was supported by a research grant from the Committee for Scientific Research (KNW-1-130/P/1/0).

Conflicts of interest: none declared.

## Prolonged elevation of serum granulysin in drug-induced hypersensitivity syndrome

DOI: 10.1111/j.1365-2133.2012.10921.x

MADAM, Drug-induced hypersensitivity syndrome (DIHS),<sup>1</sup> also known as drug rash with eosinophilia and systemic symptoms (DRESS),<sup>2</sup> has been established as a clinical entity in severe cutaneous adverse drug reactions. DIHS is characterized by the limited number of causative drugs, late onset, clinical similarity to infectious mononucleosis-like syndrome and prolonged clinical course due to relapse.<sup>1</sup>

Granulysin is a cytotoxic molecule produced against virus-infected cells, tumour cells, transplant cells, bacteria, fungi and parasites.<sup>3</sup> It plays an important role in the host defence against pathogens. A recent paper reported that granulysin is highly expressed in blisters of two other severe cutaneous adverse drug reactions: Stevens–Johnson syndrome (SJS) and toxic epidermal necrolysis (TEN).<sup>4</sup> In addition, we found that serum granulysin is more elevated in patients with early-stage SJS/TEN than in those with ordinary drug-induced skin reactions (ODSRs).<sup>5</sup>

This paper investigates the serum granulysin level of patients with DIHS. We assembled serum samples of patients with DIHS and analysed the correlation between granulysin concentrations with clinical manifestations and disease courses.

Sera of 15 patients with DIHS (10 men and five women; mean  $\pm$  SD age  $55.4 \pm 19.9$  years) were obtained from multiple institutions. All the patients had actively progressing reactions meeting the criteria for DIHS, as previously defined.<sup>1</sup> The disease onset (day 1) was defined as when the skin eruption appeared. Sera of patients with ODSRs ( $n = 24$ ) and healthy controls ( $n = 31$ ) were also obtained. ODSRs included maculopapular-type and erythema multiforme-type reactions. The granulysin concentrations of the serum samples were measured with an enzyme-linked immunosorbent assay as previously described.<sup>6</sup> In brief, serum samples were incubated on plates coated with RB1 antibody (MBL, Nagoya, Japan) and then reacted with biotinylated RC8 antibody (MBL). We performed assays in blind of the clinical features.

In serum samples taken from day 1 to day 10 ( $n = 9$ ), eight samples (89%) showed elevated serum granulysin levels, over  $10 \text{ ng mL}^{-1}$  (mean  $\pm$  SD  $21.9 \pm 12 \text{ ng mL}^{-1}$ ). In serum samples taken from day 11 to day 20 ( $n = 11$ ), we detected elevated serum granulysin levels in seven (64%; mean  $\pm$  SD  $16.1 \pm 14.8 \text{ ng mL}^{-1}$ ). Serum granulysin levels decreased gradually after day 21 ( $n = 20$ ) [six elevated (30%; mean  $\pm$  SD  $7.6 \pm 3.4 \text{ ng mL}^{-1}$ ] (Fig. 1). By day 20, the skin

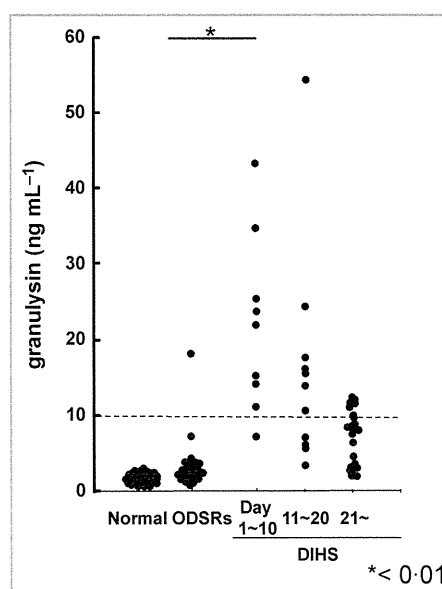


Fig 1. Granulysin levels of healthy controls, and of patients with ordinary drug-induced skin reactions (ODSRs) and drug-induced hypersensitivity syndrome (DIHS) at different stages of the disease. In patients with DIHS, we examined the concentration of granulysin for three periods: day 1–10, day 11–20, and day 21 onwards. The granulysin level was elevated from day 1 to 20, compared with levels for ODSRs and normal controls (\* $P < 0.01$ ).

eruptions of all the patients with DIHS had disappeared. As we reported previously, no increase of granulysin level was detected in 31 healthy control subjects (mean  $\pm$  SD  $1.6 \pm 0.6$  ng mL<sup>-1</sup>) and elevated granulysin was detected in only one of 24 patients with ODSRs (4%; mean  $\pm$  SD  $3.5 \pm 3.4$  ng mL<sup>-1</sup>).<sup>5</sup>

To distinguish DIHS from ODSRs, the following clinical information is helpful: limited causative drugs; late onset after medication; manifestations similar to infectious mononucleosis such as fever, lymphadenopathy, hepatitis and haematological abnormalities. However, because of the diversity of ODSRs and similarity to viral exanthema, DIHS sometimes poses a diagnostic challenge. In addition, some patients have multiple organ failure. Therefore, early diagnosis and appropriate treatment is essential.

Unique mechanisms have been implicated in DIHS development, including detoxification defects leading to reactive metabolite formation and subsequent immunological reactions,<sup>7</sup> and reactivation of human herpesvirus (HHV).<sup>8</sup> In addition, it is increasingly apparent that there is a genetic predisposition to adverse drug reactions. Human leucocyte antigen-related genes have been identified as predictors of DIHS.<sup>9</sup>

In particular, the observation that HHV reactivation occurs during the acute phase of DIHS has led to suggestions of a pathogenic link. Shiohara *et al.*<sup>8</sup> identified early reactivation of HHV6 and Epstein–Barr virus (EBV), with later involvement of HHV7 and cytomegalovirus. The resulting expansion of virus-specific T cells might mediate the clinical disease. A recent paper showed that cutaneous and visceral symptoms of DIHS/DRESS are mediated by activated CD8+ T lymphocytes, which are directed against herpesviruses such as EBV.<sup>10</sup>

Granulysin exhibits potent cytotoxicity against a broad panel of microbial targets, including tumour cells, transplant cells, bacteria, fungi and parasites, damaging negatively charged cell membranes because of its positive charge.<sup>3</sup> Granulysin plays important roles in the host defence against pathogens and induces apoptosis of the target cells in a mechanism involving caspases and other pathways.<sup>3</sup> In the present study, we showed that granulysin levels in sera were significantly elevated in patients with DIHS compared with those with ODSRs. It is suggested that, in DIHS, activation of virus-specific cytotoxic T cells resulted in granulysin release in circulating blood. In contrast, granulysin was identified as the most highly expressed cytotoxic molecule in blisters of SJS/TEN resulting in massive keratinocyte apoptosis,<sup>4</sup> and we revealed that serum granulysin increased in early stage of SJS/TEN.<sup>5</sup> We speculated that granulysin is involved in SJS/TEN pathogenesis, inducing keratinocyte death in the early stage of these diseases, whereas serum granulysin in DIHS might be released against virus-infected cells. This speculation is consistent with the present data that show the duration of DIHS manifestation to coincide with the timing of elevated serum granulysin levels. Recently we developed a rapid immunochromatographic test to detect high serum granulysin level in 15 min.<sup>6</sup> We expect that monitoring of serum granulysin by this rapid test might contribute to the early diagnosis of DIHS as well as of

SJS/TEN. In conclusion, serum granulysin might help early diagnosis and predict disease prognosis.

<sup>1</sup>Department of Dermatology, Hokkaido University Graduate School of Medicine, N15 W7, Kita-ku, Sapporo 060-8638, Japan  
Correspondence: Riichiro Abe.  
E-mail: aberi@med.hokudai.ac.jp

N. SAITO<sup>1</sup>  
R. ABE<sup>1</sup>  
N. YOSHIOKA<sup>1</sup>  
J. MURATA<sup>1</sup>  
Y. FUJITA<sup>1</sup>  
H. SHIMIZU<sup>1</sup>

## References

- Tohyama M, Hashimoto K. New aspects of drug-induced hypersensitivity syndrome. *J Dermatol* 2011; **38**:222–8.
- Kardaun SH, Sidoroff A, Valeyrie-Allanore L *et al.* Variability in the clinical pattern of cutaneous side-effects of drugs with systemic symptoms: does a DRESS syndrome really exist? *Br J Dermatol* 2007; **156**:609–11.
- Kaspar AA, Okada S, Kumar J *et al.* A distinct pathway of cell-mediated apoptosis initiated by granulysin. *J Immunol* 2001; **167**:350–6.
- Chung WH, Hung SI, Yang JY *et al.* Granulysin is a key mediator for disseminated keratinocyte death in Stevens–Johnson syndrome and toxic epidermal necrolysis. *Nat Med* 2008; **14**:1343–50.
- Abe R, Yoshioka N, Murata J *et al.* Granulysin as a marker for early diagnosis of the Stevens–Johnson syndrome. *Ann Intern Med* 2009; **151**:514–15.
- Fujita Y, Yoshioka N, Abe R *et al.* Rapid immunochromatographic test for serum granulysin is useful for the prediction of Stevens–Johnson syndrome and toxic epidermal necrolysis. *J Am Acad Dermatol* 2011; **65**:65–8.
- Shear NH, Spielberg SP. Anticonvulsant hypersensitivity syndrome. In vitro assessment of risk. *J Clin Invest* 1988; **82**:1826–32.
- Shiohara T, Inaoka M, Kano Y. Drug-induced hypersensitivity syndrome (DIHS): a reaction induced by a complex interplay among herpesviruses and antiviral and antidrug immune responses. *Allergol Int* 2006; **55**:1–8.
- Ozeki T, Mushirola T, Yowang A *et al.* Genome-wide association study identifies HLA-A\*3101 allele as a genetic risk factor for carbamazepine-induced cutaneous adverse drug reactions in Japanese population. *Hum Mol Genet* 2011; **20**:1034–41.
- Picard D, Janela B, Descamps V *et al.* Drug reaction with eosinophilia and systemic symptoms (DRESS): a multiorgan antiviral T cell response. *Sci Transl Med* 2010; **2**:46ra62.

Funding sources: none.

Conflicts of interest: none declared.

## DLQI and CDLQI scores should not be combined

DOI: 10.1111/j.1365-2133.2012.10922.x

MADAM, There have been few attempts to assess the impact of interventions on quality of life in people with ichthyosis, so Bodeimer *et al.*<sup>1</sup> are to be congratulated on their interest in this area and on collecting Dermatology Life Quality Index (DLQI) data from 24 adults and Children's Dermatology Life Quality Index (CDLQI)

# Visual Improvement after Cultivated Oral Mucosal Epithelial Transplantation

Chie Sotozono, MD, PhD,<sup>1</sup> Tsutomu Inatomi, MD, PhD,<sup>1</sup> Takahiro Nakamura, MD, PhD,<sup>1</sup> Noriko Koizumi, MD, PhD,<sup>1</sup> Norihiko Yokoi, MD, PhD,<sup>1</sup> Mayumi Ueta, MD, PhD,<sup>1</sup> Kotone Matsuyama, BS,<sup>2</sup> Keiko Miyakoda, MS, MPH,<sup>2</sup> Hideaki Kaneda, MD, PhD,<sup>2</sup> Masanori Fukushima, MD, PhD,<sup>2</sup> Shigeru Kinoshita, MD, PhD<sup>1</sup>

**Purpose:** To report the effectiveness, disease-specific outcomes, and safety of cultivated oral mucosal epithelial sheet transplantation (COMET), with the primary objective of visual improvement.

**Design:** Noncomparative, retrospective, interventional case series.

**Participants:** This study involved 46 eyes in 40 patients with complete limbal stem cell deficiency (LSCD) who underwent COMET for visual improvement. These LSCD disorders fell into the following 4 categories: Stevens-Johnson syndrome (SJS; 21 eyes), ocular cicatricial pemphigoid (OCP; 10 eyes), thermal or chemical injury (7 eyes), or other diseases (8 eyes).

**Methods:** Best-corrected visual acuity (BCVA) and ocular surface grading score were examined before surgery; at the 4th, 12th, and 24th postoperative week; and at the last follow-up. Data on COMET-related adverse events and postoperative management were collected. The outcomes in each disease category were evaluated separately.

**Main Outcome Measures:** The primary outcome was the change in median logarithm of the minimum angle of resolution (logMAR) BCVA at the 24th postoperative week. The secondary outcome was the ocular surface grading score.

**Results:** Median logMAR BCVA at baseline was 2.40 (range, 1.10 to 3.00). In SJS, logMAR BCVA improved significantly during the 24 weeks after surgery. In contrast, the BCVA in OCP was improved significantly only at the 4th postoperative week. In 6 of the 7 thermal or chemical injury cases, logMAR BCVA improved after planned penetrating keratoplasty or deep lamellar keratoplasty. Grading scores of ocular surface abnormalities improved in all categories. Of 31 patients with vision loss (logMAR BCVA, >2) at baseline, COMET produced improvement (logMAR BCVA, ≤2) in 15 patients (48%). Visual improvement was maintained with long-term follow-up (median, 28.7 months). Multivariate stepwise logistic regression analysis showed that corneal neovascularization and symblepharon were correlated significantly with logMAR BCVA improvement at the 24th postoperative week ( $P = 0.0023$  and  $P = 0.0173$ , respectively). Although postoperative persistent epithelial defects and slight to moderate corneal infection occurred in the eyes of 16 and 2 patients, respectively, all were treated successfully with no eye perforation.

**Conclusions:** Long-term visual improvement was achievable in cases of complete LSCD. Cultivated oral mucosal epithelial sheet transplantation offered substantial visual improvement even for patients with end-stage severe ocular surface disorders accompanying severe tear deficiency. Patients with corneal blindness such as SJS benefited from critical improvement of visual acuity.

**Financial Disclosure(s):** The author(s) have no proprietary or commercial interest in any materials discussed in this article. *Ophthalmology* 2013;120:193–200 © 2013 by the American Academy of Ophthalmology.



Corneal renewal and repair are mediated by corneal epithelial stem cells situated mainly in the limbus, the narrow region between the cornea and the bulbar conjunctiva.<sup>1</sup> Damage or depletion of the corneal epithelial stem cells, known as limbal stem cell deficiency (LSCD), leads to conjunctival invasion that results in vascularization and scarring of the cornea with an associated profound loss of vision.<sup>1</sup> Limbal stem cell deficiency can be caused by Stevens-Johnson syndrome (SJS), ocular cicatricial pemphigoid (OCP), and thermal or chemical injury, which are all characterized by the loss of corneal epithelial stem cells. Such LSCD may cause severe ocular surface diseases (OSDs) in which cicatrization resulting from conjunctival fibrosis, symblepha-

ron, and severe dry eye greatly disrupt visual function and can progress gradually with chronic inflammation.<sup>2–4</sup> To date, few effective medical or surgical treatments for severe OSDs have been available.<sup>5–15</sup>

Since 1998, the authors have used amniotic membrane transplantation to treat severe OSDs. Amniotic membrane exhibits an anti-inflammatory effect and also acts as a substrate for epithelialization.<sup>16</sup> The results of previous studies have shown that amniotic membrane transplantation alone<sup>17,18</sup> or amniotic membrane transplantation combined with limbal transplantation<sup>6,19,20</sup> promoted epithelialization, reduced pain, reconstructed the fornix, and minimized inflammation of the ocular surface to a remarkable degree in

patients with severe OSDs. Based on these promising results, novel methods have been developed for the cultivation of allogeneic corneal<sup>7,8,21</sup> or autologous oral mucosal<sup>22–25</sup> epithelial cells on a denuded amniotic membrane. Immunologic rejection and increased risk of infection or systemic adverse effects associated with the long-term immunosuppressive therapy accompanying allograft transplantation<sup>6</sup> encouraged changing to autologous cultivated oral mucosal epithelial transplantation (COMET) in patients with severe OSDs in 2002.<sup>10,11,23,26</sup>

To clarify the effectiveness, disease-specific outcomes, and safety of COMET, all of the clinical data from all 72 patients that the authors treated with COMET since 2002 were analyzed. The objective of this present study was to summarize the long-term clinical outcomes of 40 of those 72 patients who underwent COMET with the primary objective of visual improvement between June 2002 and December 2008.

## Patients and Methods

### Patients

Autologous COMET was performed on consecutive patients who were diagnosed with total LSCD based on the complete disappearance of the palisades of Vogt and 360° of conjunctivalization.<sup>1</sup> The COMET treatment protocol was approved by the ethical review board of Kyoto Prefectural University of Medicine, Kyoto, Japan, in 2002. The final decision to perform COMET was made by the university's team of corneal specialists. Before the surgery, written informed consent was obtained from all patients in accordance with the tenets of the Declaration of Helsinki for research involving human subjects. The current retrospective study used an itemized data collection form, and the medical records of all patients who underwent COMET between June 2002 and December 2008 were examined retrospectively. This retrospective study protocol was approved by the ethical review board of Kyoto Prefectural University of Medicine in 2009. In this study, 40 of the 72 patients who underwent COMET were analyzed with the primary objective of visual improvement.

### Cell Culture

All of the COMET sheets were prepared at the good manufacturing practices—graded Cell Processing Center at Kyoto Prefectural University of Medicine as previously described.<sup>23,26</sup> Autologous oral mucosal epithelial cells were obtained from a 6-mm-diameter biopsy specimen obtained from each patient's buccal mucosa, and the cells then were cultured on an amniotic membrane spread on the bottom of a culture insert and were cocultured with mitomycin C-inactivated 3T3 fibroblasts (NIH-3T34; RIKEN Cell Bank, Tsukuba, Japan). The cultured cells were submerged in medium for approximately 1 week and then were exposed to air by lowering the medium level (airlifting) for 1 to 2 days. All amniotic membrane was obtained from caesarean sections according to the preparation method described previously.<sup>23</sup> Although fetal bovine serum initially was used as a culture medium, autologous serum was used in later cultures to reduce the risk of transmitting non-human pathogens.<sup>26</sup>

### Transplantation and Postoperative Management

The surgical procedure (see the Supplemental Video, available at <http://aaojournal.org>) and postoperative management have been described previously.<sup>24,25</sup> In patients with severe symblepharon or

a large area of bare sclera exposed during surgery, amniotic membrane was transplanted onto the bare sclera to reconstruct conjunctival fornices.<sup>18</sup> In patients with a cataract, phacoemulsification and aspiration plus intraocular lens implantation were performed simultaneously with COMET. No penetrating keratoplasty or deep lamellar keratoplasty was performed simultaneously with COMET. For patients with severe corneal stromal opacity, a 2-step surgical approach was planned, with the first step being COMET and the second step being either penetrating or deep lamellar keratoplasty.<sup>25</sup>

Systemic corticosteroid (betamethasone, 1 mg/day) and cyclosporine (2 to 3 mg/kg daily) were administered to prevent postoperative inflammation and immunologic response and then were tapered, depending on the clinical findings. Dexamethasone (0.1%) and antibiotic eye drops were instilled 4 times daily. Dry-eye patients were administered artificial tears. A therapeutic soft contact lens was used for at least 1 month to protect transplanted epithelium from mechanical ablation.

### Postoperative Follow-up and Outcomes

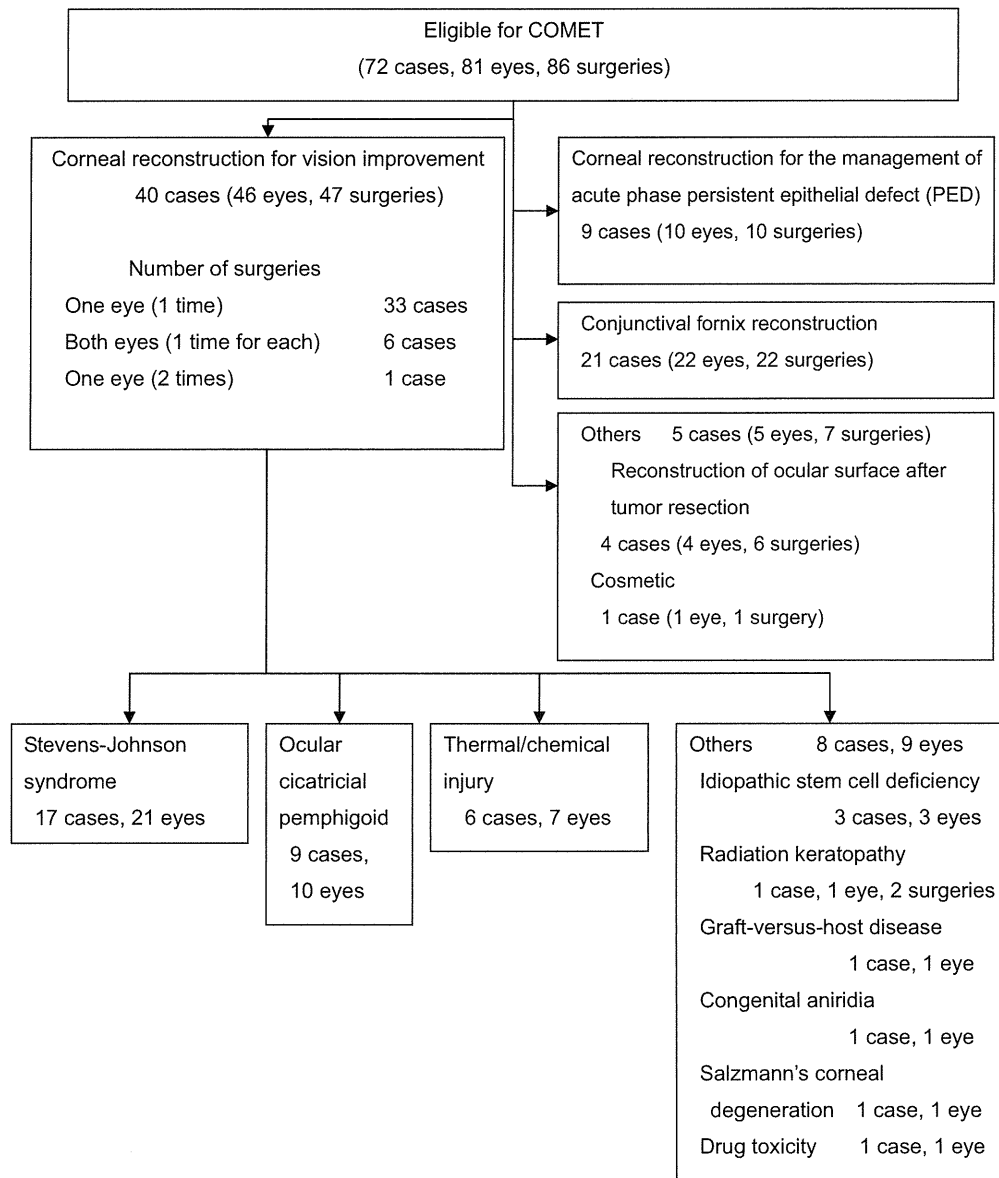
Best-corrected visual acuity (BCVA) was converted to the logarithm of the minimum angle of resolution (logMAR). Ocular surface conditions including corneal appearance (epithelial defects, clinical conjunctivalization, neovascularization, opacification, keratinization, and symblepharon) were graded by at least 2 ophthalmologists (C.S., T.I., and T.N.) on a scale from 0 to 3 according to their severity, in accordance with a previously reported grading system.<sup>27</sup> Severe OSDs are characterized by an associated loss of conjunctival stem cells, and the severity of conjunctival involvement affects the visual prognosis. Therefore, findings on upper and lower fornix shortening were added to evaluate the grade of conjunctival appearance. Fornix shortening was graded from 0 to 3 based on the following clinical features: normal depth (grade 0), shortened by less than one quarter (grade 1), shortened by one quarter to one half (grade 2), and shortened by more than one half (grade 3). Upper and lower fornix shortenings were graded separately. The sum of each grading score was defined as the ocular surface grading score (maximum, 24).

Each patients logMAR BCVA, ocular surface grading score, and data on adverse events related to COMET or postoperative management were collected from the medical records at these specific time points: before surgery; at the 4th, 12th, and 24th postoperative weeks; and at the last follow-up examination. The primary outcome was the change in logMAR BCVA at the 24th postoperative week. Because other ocular diseases can affect this visual outcome, a secondary outcome, the ocular surface grading score, also was defined.

### Statistical Analysis

The change in BCVA and ocular surface grading score from baseline at each visit, except for the last visit, was analyzed using the Wilcoxon signed-rank test in each disease category (SJS, OCP, thermal or chemical injury) except for other diseases. Multivariate stepwise logistic regression analysis was used to determine the factors influencing visual improvement.

This study defined the critical visual improvement rate as the proportion of patients in whom BCVA at the 24th postoperative week had improved to at least 0.01, as a percentage of the patients with a BCVA of less than 0.01 at baseline. Patients with a visual acuity of 0.01 or more can read and walk using vision aids. Thus, an improvement to at least 0.01 indicates a capacity for independence in daily life. If data were missing from the 24th postoperative week, data from follow-up at the last visit were substituted.



**Figure 1.** Diagram showing flow of study. Seventy-two patients (81 eyes) underwent cultivated oral mucosal epithelial sheet transplantation (COMET) between June 2002 and December 2008, and 40 patients (46 eyes) were analyzed for visual improvement in this study. Both corneal reconstruction and conjunctival fornix reconstruction were carried out in 3 cases, in the same eye in 1 case, and counted separately.

All statistical analyses were conducted at the Translational Research Informatics Center (Kobe, Japan) with the use of SAS software, version 9.1 (SAS Inc, Cary, NC) or JMP software, version 8.2 (SAS Inc). *P* values of less than 0.05 were considered statistically significant.

## Results

### Patient Characteristics

Between 2002 and 2008, 47 COMETs (46 eyes in 40 patients) were performed on 21 eyes with SJS, 10 eyes with OCP, 7 eyes with thermal or chemical injury, and 9 eyes with other causes of LSCD (Fig 1). Although 23 eyes (48.9%) previously had been treated with ocular surgery, all of these previous treatments had

failed and recurrence of fibrovascular ingrowth on the cornea was observed. Of the 47 surgeries performed, symblepharon and keratinization of the cornea were present in 37 eyes (78.7%) and 10 eyes (21.3%), respectively, thus indicating that most of the eyes were inflicted with end-stage severe OSDs (Table 1).

### Outcomes of Cultivated Oral Mucosal Epithelial Sheet Transplantation

Cultivated autologous oral mucosal epithelial sheets were generated successfully from all patients. In all patients, COMET was performed successfully and no epithelial damage was observed during surgery. Cultivated oral mucosal epithelial sheet transplantation was combined with amniotic membrane transplantation in 34 (72%) of the 47 surgeries and with cataract surgery in 11 eyes (23%; Table 2, available at <http://aaojournal.org>). In 10 patients

Table 1. Baseline Characteristics in Patients Who Underwent Autologous Cultivated Oral Mucosal Epithelial Transplantation

	Total	Stevens-Johnson Syndrome	Ocular Pemphigoid	Thermal/Chemical Injury	Others
No. of COMETs	47	21	10	7	9
Age (yrs)					
Median	57.0	43.0	73.5	50.0	34.0
Range	9–86	14–71	62–86	27–79	9–75
Duration of illness (yrs)					
Median	12.3	17.9	3.5	6.0	5.08
Range	0.3–40.0	3.0–38.0	0.3–15.0	0.5–24.0	0.5–40.0
Prior ocular surgery (%)	23 (48.9)	9 (42.9)	4 (40.0)	3 (42.9)	7 (77.8)
Planned 2-step operations (%)	10 (21.3)	2 (9.5)	0 (0)	6 (85.7)	2 (22.2)
Symblepharon (%)	37 (78.7)	18 (85.7)	10 (100.0)	6 (85.7)	3 (33.3)
Keratinization (%)	10 (21.3)	8 (38.1)	1 (10.0)	0 (0)	1 (11.1)
Preoperative visual acuity*					
Median	2.40	2.4	2.70	2.70	2.40
Range	1.11–3.00	1.40–3.00	1.52–2.70	1.22–2.70	1.10–2.70
Preoperative ocular surface grading score					
Median	14.0	15.0	17.0	13.0	8.0
Range	5.0–21.0	8.0–21.0	10.0–21.0	7.0–17.0	5.0–19.0

COMET = autologous cultivated oral mucosal epithelial transplantation.  
\*Logarithm of the minimum angle of resolution units.

with severe corneal stromal opacity, a 2-step surgical approach was planned, with COMET followed by penetrating keratoplasty or deep lamellar keratoplasty.<sup>25</sup> Three patients underwent the second surgery before the 24th postoperative week and 5 patients underwent the surgery after the 24th week, but 2 patients did not undergo the second surgery during the study period.

The median preoperative logMAR BCVA was 2.40, and in 31 of the eyes (66%), visual acuity was poorer than 20/2000 ( $<0.01$ , logMAR  $>2$ ). The median preoperative ocular surface grading score was 18.0 (range, 5 to 21). The median patient follow-up period with observation of the primary outcome was 28.7 months after transplantation (range, 6.2 to 85.6 months). Because of heterogeneous etiologic mechanisms, the outcomes in each category are described separately.

### Disease-Specific Outcomes

**Stevens-Johnson Syndrome.** Seventeen patients with SJS underwent COMET (Table 2, available at <http://aaojournal.org>). The BCVA improved significantly at 4, 12, and 24 weeks after surgery ( $P = 0.0005$ ,  $P = 0.0010$ , and  $P = 0.0117$ , respectively; Fig 2A). The ocular surface grading score also improved significantly at 4, 12, and 24 weeks after surgery ( $P < 0.0001$  for each time point; Fig 2B).

**Ocular Cicatricial Pemphigoid.** Nine patients (10 eyes) with OCP underwent COMET (Table 1). All 9 patients were older than 60 years, older than many of the patients in this study with other diseases (Table 2, available at <http://aaojournal.org>). The BCVA was improved significantly at the 4th postoperative week ( $P = 0.0156$ ), but this improvement later disappeared (Fig 2A). In contrast, improvement of the ocular surface grading score was sustained throughout the follow-up period ( $P = 0.0020$ ,  $P = 0.0020$ , and  $P = 0.0078$ , respectively; Fig 2B).

**Thermal or Chemical Injury.** Seven patients (7 eyes) with thermal or chemical injury underwent COMET. Their BCVA did not change until the 24th postoperative week; however, the ocular surface grading score in all 7 patients improved significantly ( $P = 0.0156$  for each visit; Fig 2A, B). Although penetrating keratoplasty or deep lamellar keratoplasty surgery was planned for 6 of these 7 patients, only 2 patients underwent this second surgery

before the 24th postoperative week visit. Both the BCVA and ocular surface score improved in all 7 patients after the planned surgeries were performed.

**Others.** Eight other patients underwent COMET: 3 with idiopathic stem cell deficiency, 1 with radiation keratopathy, 1 with graft-versus-host disease, 1 with congenital aniridia, 1 with Salzmanns corneal degeneration, and 1 with drug-toxicity-induced LSCD. In 6 of these 8 patients, BCVA was improved significantly; however, no improvement was seen in 2 of these patients (Table 2, available at <http://aaojournal.org>; Fig 2A). The 2 patients with no improvement had severe dryness on the ocular surface and had the highest ocular surface grading score in this group. In addition, severe lagophthalmos was present in the 1 patient with radiation keratopathy because of severe lid scarring after irradiation for retinoblastoma. One other patient with graft-versus-host disease had longstanding inflammation on the ocular surface. In both of these 2 cases, keratinization and symblepharon progressed gradually after COMET. Six patients who demonstrated improvement had a low preoperative ocular surface grading score, yet this score was improved considerably in all patients at the 24th postoperative week (Table 2; Fig 2B).

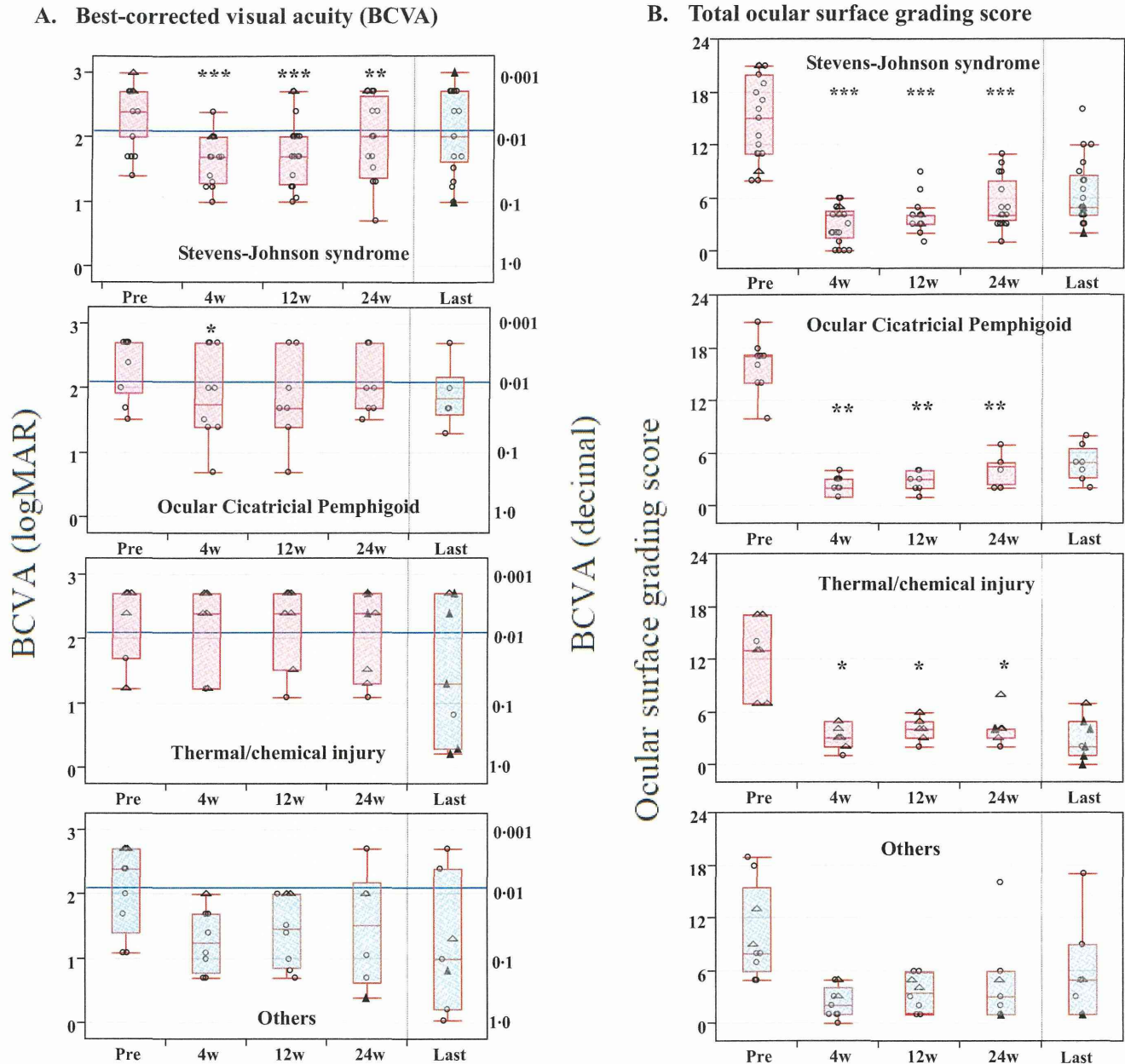
### Critical Visual Improvement Rate

The critical visual improvement rate for SJS, OCP, and thermal or chemical injury was 50.0% (7/14), 42.9% (3/7), and 20.0% (1/5), respectively, although the second planned surgery<sup>25</sup> (penetrating or deep lamellar keratoplasty) had yet to be carried out at the 24th postoperative week in 7 of 10 eyes. The clinical observations on both preoperative and postoperative anterior segment slit-lamp photographs are shown in Figure 3 (available at <http://aaojournal.org>). All patients demonstrated an improvement in their BVCA to 0.01 or more, from a baseline condition of vision loss.

### Factors Influencing Visual Improvement

Multivariate stepwise logistic regression analysis was used to estimate the factors influencing postoperative visual acuity after COMET, and the following factors were chosen as variables:





**Figure 2.** Graphs showing preoperative (Pre) and postoperative clinical outcomes. **A,** Best-corrected visual acuity (BCVA). The BCVA values for each patient are shown grouped according to the cause of corneal dysfunction: Stevens-Johnson syndrome (SJS), ocular cicatricial pemphigoid (OCP), thermal or chemical injury, and others. The change in BCVA from baseline at each visit, except for the last visit, was analyzed using the Wilcoxon signed-rank test in each disease category (SJS, OCP, thermal or chemical injury) except others. Open circles represent cases treated with autologous cultivated oral mucosal epithelial transplantation (COMET) only. Triangles represent cases treated with a planned 2-step surgical combination of COMET followed by penetrating keratoplasty (PK) or deep lamellar keratoplasty (DLKP). Open triangles are before the second operation, and closed triangles are after the second operation. The horizontal line within each box represents the median value, the bottom and top lines of the box represent the 25th and 75th percentiles, respectively, and the horizontal lines below and above the box represent the lowest and highest values, respectively (or are located 1.5 times the interquartile range away from the box). \* $P < 0.05$ , \*\* $P < 0.01$ , \*\*\* $P < 0.001$  (2-sided). **B,** Total ocular surface grading score. Ocular surface grading scores for each patient were calculated and are shown according to each cause of corneal dysfunction: SJS, OCP, thermal or chemical injury, and others. Scores for 8 components of the ocular surface were calculated by the grading system. The total scores before surgery and at the 4th, 12th, and 24th postoperative weeks and at last follow-up examination were calculated. Open circles represent patients treated with COMET only. Triangles represent patients treated with a planned 2-step surgical combination of COMET followed by PK or DLKP. Open triangles are before the second operation, and closed triangles are after the second operation. The change in ocular surface grading score from baseline at each visit, except for the last visit, was analyzed using the Wilcoxon signed-rank test in each disease category (SJS, OCP, thermal or chemical injury) except others. The horizontal line within each box represents the median value, the bottom and top lines of the box represent the 24th and 75th percentiles, respectively, and the horizontal lines below and above the box represent the lowest and highest values, respectively (or are located 1.5 times the interquartile range away from the box). \* $P < 0.05$ , \*\* $P < 0.01$ , \*\*\* $P < 0.001$  (2-sided). w = weeks.

Table 3. Summary of Adverse Events in Patients Who Underwent Autologous Cultivated Oral Mucosal Epithelial Transplantation

Event	Total	Disease Category			
		Stevens-Johnson Syndrome	Ocular Cicatricial Pemphigoid	Thermal or Chemical Injury	Others
Hepatic dysfunction	1	1			
Drug-induced allergy	1				1
Persistent epithelial defect	16	10	3	2	1
Corneal stromal melting after the epithelial defect	2		1		1
Ocular infection (keratitis, endophthalmitis)	2	2			
Infiltration	3	2	1		
Elevation of IOP resulting from steroid use	4		1	2	1

IOP = intraocular pressure.  
No life-threatening serious adverse events were observed.

disease category, patient age, 2-step surgery, combination with amniotic membrane transplantation, combination with cataract surgery, preoperative logMAR BCVA, and the 8 components of the ocular surface grading system. Corneal neovascularization and symblepharon were found to be correlated significantly with logMAR improvement at the 24th postoperative week ( $P = 0.0023$  and  $P = 0.0173$ , respectively). Visual prognosis was better in the eyes with slight symblepharon than in the eyes with severe symblepharon. In contrast, it was better in the eyes with severe neovascularization than in the eyes with slight neovascularization.

### Adverse Events

A summary of the adverse events in the 40 patients who underwent COMET is shown in Table 3. No life-threatening serious adverse events were observed in any of the transplantations. Systemically, moderate liver dysfunction occurred in 1 patient (2.5%; 95% confidential interval [CI], 0.1 to 13.2), but liver function normalized after the discontinuation of systemic drugs.

Postoperative persistent epithelial defects occurred in the eyes of 16 (40.0%) of the 40 patients (95% CI, 24.9 to 56.7), and rather frequently in the SJS eyes (60.0% of SJS patients). Corneal stromal melting after the epithelial defect occurred in 2 patients (5.0%; 95% CI, 0.6 to 16.9), but neither eye became perforated. All of these patients were treated successfully. Slight to moderate corneal infection occurred in 2 patients (5.0%; 95% CI, 0.6 to 16.9); however, both patients healed without scarring. A suspected infection with cell infiltration on the cornea<sup>28</sup> occurred in 3 patients, yet in each patient, it healed within 1 week after receiving a topical instillation of antibiotics. Although a slight elevation of intraocular pressure resulting from steroid use was seen in 4 patients (10.0%; 95% CI, 2.8 to 23.7), this returned to the normal range after reduction of the steroid dose. None of the patients required glaucoma surgery.

### Discussion

Severe OSD has proven to be one of the most difficult disorders to treat, and for many patients, vision loss is the end result.<sup>29,31</sup> Keratoprosthesis surgery is one possible way to obtain visual improvement in end-stage severe OSDs; however, serious complications such as endophthalmitis,

glaucoma, and tissue melting can arise, especially in SJS or OCP, and can lead to permanent vision loss.<sup>32,33</sup>

At the beginning of 2002, the authors performed ocular surface reconstruction using tissue-engineered autologous oral mucosal epithelial sheets for the first time.<sup>23</sup> In a report of the initial results from the first 12 cases, the successful long-term engraftment of cultivated oral mucosal cells and their transparency was confirmed.<sup>24</sup> Since then, COMET has been used to treat OSD patients, with careful consideration of the surgical indications.<sup>24-26,34</sup> The authors performed 86 COMET operations between 2002 and the end of 2008 for visual improvement, epithelialization of persistent epithelial defects, or conjunctival reconstruction (Fig 1).

In this study, the clinical efficacy and safety of 47 COMETs were evaluated for visual improvement. In 23 eyes (48.9%), previous ocular surgery such as corneal transplantation or amniotic membrane transplantation already had been carried out unsuccessfully at other hospitals. Symblepharon was involved in 37 eyes (78.7%) and keratinization was involved in 10 eyes (21.3%). Symblepharon indicates conjunctival involvement, and pathologic keratinization means that the eye is at the end stage of a severe OSD with chronic inflammation.<sup>3,35</sup> Most of these eyes had severe tear deficiency, which is an important prognostic parameter for surgical outcome.<sup>36</sup> Although such eyes commonly are considered to have contraindications for ocular surface reconstruction, COMET offered substantial visual improvement even for patients with such advanced disease.

In more than half of the eyes, preoperative visual acuity was limited to counting fingers or hand movements. It is striking that such patients were able to come to the hospital without assistance during the 24 weeks after undergoing COMET. For this reason, critical visual improvement rate is proposed as a clear end point for measuring surgical outcome. Considering that most of the eyes in this study were at the end stage of a severe OSD, these results are very favorable and encouraging.

In this study, the preoperative ocular surface grading score was higher (more diseased) in patients with SJS and OCP than in those with thermal or chemical injuries or other

diseases. It should be noted that visual improvement was statistically significant in SJS. In contrast, visual acuity was not improved at the 24th postoperative week in patients with thermal or chemical injury, despite the improvement in total ocular surface grading score. The corneal stroma was damaged severely in most cases of thermal or chemical injury, and such patients obtained visual improvement after undergoing the planned second surgery with penetrating keratoplasty or deep lamellar keratoplasty. In general, the prognosis of penetrating or deep lamellar keratoplasty alone for severe OSDs is very poor.<sup>2</sup> However, the findings of this study show that patients with severe OSDs with corneal stromal opacity can obtain visual improvement after undergoing the surgical combination of COMET and penetrating or deep lamellar keratoplasty.

Best-corrected visual acuity was not improved at the 24th postoperative week in patients with OCP, despite significant improvement of the ocular surface grading score. Because OCP is a progressive autoimmune disease, pathologic keratinization or thickening of the epithelium occurred readily after COMET, thus disrupting visual acuity.

No serious systemic complications occurred in any of the patients. The incidence of postoperative persistent epithelial defects was relatively high, yet still similar to or lower than that reported with other therapies.<sup>6,36–38</sup> Considering that corneal perforation is a common complication after corneal reconstruction in severe OSDs,<sup>38–40</sup> it is noteworthy that no perforation occurred and that none of the eyes demonstrated vision loss after COMET. Ocular surface reconstruction with a combination of COMET and amniotic membrane transplantation was needed to achieve the total replacement of cicatrized tissue. Because cultured epithelial cells on amniotic membrane attach to a basement membrane with hemidesmosomes,<sup>22</sup> these cells can avoid being dropped off and actually survive, regardless of an unstable tear film and the mechanical trauma of blinking. When used as the substrate for oral mucosal cells, amniotic membrane may play a role in protecting the cornea from melting.

Multivariate stepwise logistic regression analysis showed that symblepharon and neovascularization are prognostic factors for visual improvement. Although disease-specific outcomes showed different patterns as described above, disease category was not related to visual prognosis. However, the sample size may be too small to perform such subgroup analyses. Multivariate stepwise logistic regression analysis also was performed for all 86 surgeries to determine the factors influencing persistent epithelial defects. Having SJS and a very low tear meniscus were the prognostic factors for persistent epithelial defects ( $P = 0.0204$  and  $P = 0.0388$ , respectively). Thus, it is likely that both the disease category and dryness of the eye influenced the prognosis.

Long-term ocular surface appearance was examined in 17 of the 72 patients with a follow-up of more than 3 years.<sup>34</sup> No further surgery was carried out in these patients. The ocular surface in each case became stable from 6 months after COMET, with a gradual reduction in corneal neovascularization,<sup>34</sup> as others have reported in similar studies.<sup>40</sup> Moreover, postoperative invasion of conjunctival tissue and symblepharon formation was inhibited significantly for more than 3 years.<sup>34</sup> Deep lamellar or penetrating

keratoplasty was performed for the patients with corneal stromal opacity after the stabilization of the ocular surface (as the second step of a 2-step surgical combination), in most cases from 24 weeks after COMET.

After COMET, upper or lower eyelid cicatricial entropion with various degrees of tarsal-plate atrophy sometimes was found. In cases with an eyelid abnormality, eyelid surgery was performed to correct entropion, trichiasis, or lagophthalmos. Eyelid condition is an important factor for maintaining ocular surface stability, as well as for avoiding complications such as infection or persistent epithelial defects.

In conclusion, the findings of this retrospective study showed that long-term visual improvement can be obtained in end-stage severe OSDs with complete LSCD and that COMET offered substantial visual improvement even for patients with severe tear deficiency. The findings also showed that patients with corneal blindness resulting from severe OSDs such as SJS benefited from critical improvement of visual acuity.

**Acknowledgments.** The authors thank Dr. Shin Kawamata of the Foundation for Biological Research and Innovation and Dr. Kazunori Takeda, Dr. Hiroaki Kato, Dr. Hiroshi Tanaka, Dr. Yuji Yamamoto, and Dr. Takahiro Yamawaki of Kyoto Prefectural University of Medicine for data collection.

## References

- Kinoshita S, Adachi W, Sotozono C, et al. Characteristics of the human ocular surface epithelium. *Prog Retin Eye Res* 2001;20:639–73.
- Tugal-Tutkun I, Akova YA, Foster CS. Penetrating keratoplasty in cicatrizing conjunctival diseases. *Ophthalmology* 1995;102:576–85.
- Kawasaki S, Nishida K, Sotozono C, et al. Conjunctival inflammation in the chronic phase of Stevens-Johnson syndrome. *Br J Ophthalmol* 2000;84:1191–3.
- Wall V, Yen MT, Yang MC, et al. Management of the late ocular sequelae of Stevens-Johnson syndrome. *Ocul Surf* 2003;1:192–201.
- Kenyon KR, Tseng SC. Limbal autograft transplantation for ocular surface disorders. *Ophthalmology* 1989;96:709–22.
- Tsubota K, Satake Y, Kaido M, et al. Treatment of severe ocular-surface disorders with corneal epithelial stem-cell transplantation. *N Engl J Med* 1999;340:1697–703.
- Koizumi N, Inatomi T, Suzuki T, et al. Cultivated corneal epithelial transplantation for ocular surface reconstruction in acute phase of Stevens-Johnson syndrome. *Arch Ophthalmol* 2001;119:298–300.
- Koizumi N, Inatomi T, Suzuki T, et al. Cultivated corneal epithelial stem cell transplantation in ocular surface disorders. *Ophthalmology* 2001;108:1569–74.
- Nakamura T, Inatomi T, Sotozono C, et al. Successful primary culture and autologous transplantation of corneal limbal epithelial cells from minimal biopsy for unilateral severe ocular surface disease. *Acta Ophthalmol Scand* 2004;82:468–71.
- Kinoshita S, Koizumi N, Nakamura T. Transplantable cultivated mucosal epithelial sheet for ocular surface reconstruction. *Exp Eye Res* 2004;78:483–91.
- Kinoshita S, Koizumi N, Sotozono C, et al. Concept and clinical application of cultivated epithelial transplantation for ocular surface disorders. *Ocul Surf* 2004;2:1–33.
- Nishida K, Yamato M, Hayashida Y, et al. Corneal reconstruction with tissue-engineered cell sheets composed of autologous oral mucosal epithelium. *N Engl J Med* 2004;351:1187–96.

13. Nakamura T, Inatomi T, Sotozono C, et al. Transplantation of autologous serum-derived cultivated corneal epithelial equivalents for the treatment of severe ocular surface disease. *Ophthalmology* 2006;113:1765–72.
14. Ang LP, Sotozono C, Koizumi N, et al. A comparison between cultivated and conventional limbal stem cell transplantation for Stevens-Johnson syndrome. *Am J Ophthalmol* 2007;143:178–80.
15. Rama P, Matuska S, Paganoni G, et al. Limbal stem-cell therapy and long-term corneal regeneration. *N Engl J Med* 2010;363:147–55.
16. Tseng SC, Espana EM, Kawakita T, et al. How does amniotic membrane work? *Ocul Surf* 2004;2:177–87.
17. Tseng SC, Prabhawar P, Lee SH. Amniotic membrane transplantation for conjunctival surface reconstruction. *Am J Ophthalmol* 1997;124:765–74.
18. Solomon A, Espana EM, Tseng SC. Amniotic membrane transplantation for reconstruction of the conjunctival fornices. *Ophthalmology* 2003;110:93–100.
19. Tsubota K, Satake Y, Ohyama M, et al. Surgical reconstruction of the ocular surface in advanced ocular cicatricial pemphigoid and Stevens-Johnson syndrome. *Am J Ophthalmol* 1996;122:38–52.
20. Tsai RJ, Li LM, Chen JK. Reconstruction of damaged corneas by transplantation of autologous limbal epithelial cells. *N Engl J Med* 2000;343:86–93.
21. Koizumi N, Inatomi T, Quantock AJ, et al. Amniotic membrane as a substrate for cultivating limbal corneal epithelial cells for autologous transplantation in rabbits. *Cornea* 2000;19:65–71.
22. Nakamura T, Endo K, Cooper LJ, et al. The successful culture and autologous transplantation of rabbit oral mucosal epithelial cells on amniotic membrane. *Invest Ophthalmol Vis Sci* 2003;44:106–16.
23. Nakamura T, Inatomi T, Sotozono C, et al. Transplantation of cultivated autologous oral mucosal epithelial cells in patients with severe ocular surface disorders. *Br J Ophthalmol* 2004;88:1280–4.
24. Inatomi T, Nakamura T, Koizumi N, et al. Midterm results on ocular surface reconstruction using cultivated autologous oral mucosal epithelial transplantation. *Am J Ophthalmol* 2006;141:267–75.
25. Inatomi T, Nakamura T, Kojyo M, et al. Ocular surface reconstruction with combination of cultivated autologous oral mucosal epithelial transplantation and penetrating keratoplasty. *Am J Ophthalmol* 2006;142:757–64.
26. Ang LP, Nakamura T, Inatomi T, et al. Autologous serum-derived cultivated oral epithelial transplants for severe ocular surface disease. *Arch Ophthalmol* 2006;124:1543–51.
27. Sotozono C, Ang LP, Koizumi N, et al. New grading system for the evaluation of chronic ocular manifestations in patients with Stevens-Johnson syndrome. *Ophthalmology* 2007;114:1294–302.
28. Sotozono C, Inagaki K, Fujita A, et al. Methicillin-resistant *Staphylococcus aureus* and methicillin-resistant *Staphylococcus epidermidis* infections in the cornea. *Cornea* 2002;21:S94–101.
29. Samson CM, Nduaguba C, Baltatzis S, Foster CS. Limbal stem cell transplantation in chronic inflammatory eye disease. *Ophthalmology* 2002;109:862–8.
30. Solomon A, Ellies P, Anderson DF, et al. Long-term outcome of keratolimbal allograft with or without penetrating keratoplasty for total limbal stem cell deficiency. *Ophthalmology* 2002;109:1159–66.
31. Sotozono C, Ueta M, Koizumi N, et al. Diagnosis and treatment of Stevens-Johnson syndrome and toxic epidermal necrolysis with ocular complications. *Ophthalmology* 2009;116:685–90.
32. Khan B, Dudenhofer EJ, Dohlman CH. Keratoprosthesis: an update. *Curr Opin Ophthalmol* 2001;12:282–7.
33. Liu C, Okera S, Tandon R, et al. Visual rehabilitation in end-stage inflammatory ocular surface disease with the osteo-odonto-keratoprosthesis: results from the UK. *Br J Ophthalmol* 2008;92:1211–7.
34. Nakamura T, Takeda K, Inatomi T, et al. Long-term results of autologous cultivated oral mucosal epithelial transplantation in the scar phase of severe ocular surface disorders. *Br J Ophthalmol* 2011;95:942–6.
35. Tanioka H, Kawasaki S, Sotozono C, et al. The relationship between preoperative clinical scores and immunohistological evaluation of surgically resected tissues in chronic severe ocular surface diseases. *Jpn J Ophthalmol* 2010;54:66–73.
36. Shimazaki J, Shimmura S, Fujishima H, Tsubota K. Association of preoperative tear function with surgical outcome in severe Stevens-Johnson syndrome. *Ophthalmology* 2000;107:1518–23.
37. Turgeon PW, Nauheim RC, Roat MI, et al. Indications for keratoepithelioplasty. *Arch Ophthalmol* 1990;108:233–6.
38. Ma DH, Kuo MT, Tsai YJ, et al. Transplantation of cultivated oral mucosal epithelial cells for severe corneal burn. *Eye (Lond)* 2009;23:1442–50.
39. Shimazaki J, Aiba M, Goto E, et al. Transplantation of human limbal epithelium cultivated on amniotic membrane for the treatment of severe ocular surface disorders. *Ophthalmology* 2002;109:1285–90.
40. Satake Y, Higa K, Tsubota K, Shimazaki J. Long-term outcome of cultivated oral mucosal epithelial sheet transplantation in treatment of total limbal stem cell deficiency. *Ophthalmology* 2011;118:1524–30.

## Footnotes and Financial Disclosures

Originally received: March 10, 2012.

Final revision: July 17, 2012.

Accepted: July 18, 2012.

Available online: October 16, 2012. Manuscript no. 2012-353.

<sup>1</sup> Department of Ophthalmology, Kyoto Prefectural University of Medicine, Kyoto, Japan.

<sup>2</sup> Translational Research Informatics Center, Foundation for Biomedical Research and Innovation, Kobe, Japan.

Presented at: American Academy of Ophthalmology Annual Meeting, October 2011, Orlando, Florida.

Financial Disclosure(s):

The author(s) have no proprietary or commercial interest in any materials discussed in this article.

Supported in part by a Grant-in-aid for Scientific Research from the Japanese Ministry of Health, Labor and Welfare, Tokyo, Japan; and a Research Grant of the Coordination, Support and Training Program for Translational Research from the Japanese Ministry of Education, Culture, Sports, Science and Technology, Tokyo, Japan.

Correspondence:

Chie Sotozono, MD, PhD, Department of Ophthalmology, Kyoto Prefectural University of Medicine, 465 Kajii-cho, Hirokoji-agaru, Kawaramachi-dori, Kamigyo-ku, Kyoto 602-0841, Japan. E-mail: csotozon@koto.kpu-m.ac.jp.

## Research Article

# ***In Silico* Risk Assessment of HLA-A\*02:06-Associated Stevens-Johnson Syndrome and Toxic Epidermal Necrolysis Caused by Cold Medicine Ingredients**

**Hideto Isogai,<sup>1</sup> Hiroko Miyadera,<sup>2</sup> Mayumi Ueta,<sup>3</sup> Chie Sotozono,<sup>3</sup> Shigeru Kinoshita,<sup>3</sup> Katsushi Tokunaga,<sup>2</sup> and Noriaki Hirayama<sup>1</sup>**

<sup>1</sup> Basic Medical Science and Molecular Medicine, Tokai University School of Medicine, 147 Shimokasuya, Isehara, Kanagawa 259-1143, Japan

<sup>2</sup> Department of Human Genetics, School of International Health, Graduate School of Medicine, The University of Tokyo, 7-3-1 Hongo, Bunkyo-ku, Tokyo 113-0033, Japan

<sup>3</sup> Department of Ophthalmology, Kyoto Prefectural University of Medicine, Hirokoji Kawaramachi, Kamigyo-ku, Kyoto 602-0841, Japan

Correspondence should be addressed to Noriaki Hirayama; [hirayama@is.icc.u-tokai.ac.jp](mailto:hirayama@is.icc.u-tokai.ac.jp)

Received 12 July 2013; Revised 4 September 2013; Accepted 4 September 2013

Academic Editor: Anthony DeCaprio

Copyright © 2013 Hideto Isogai et al. This is an open access article distributed under the Creative Commons Attribution License, which permits unrestricted use, distribution, and reproduction in any medium, provided the original work is properly cited.

Stevens-Johnson syndrome (SJS) and toxic epidermal necrolysis (TEN) are severe drug hypersensitivities with high mortality. Typical over-the-counter drugs of cold medicines are suggested to be causative. As multiple ingredients are generally contained in cold medicines, it is of particular interest to investigate which ingredients are responsible for SJS/TEN. However, experimental examination of causal relationships between SJS/TEN and a particular drug molecule is not straightforward. Significant association between HLA-A\*02:06 and SJS/TEN with severe ocular surface complications has been observed in the Japanese. In the present study, we have undertaken *in silico* docking simulations between various ingredients contained in cold medicines available in Japan and the HLA-A\*02:06 molecule. We use the composite risk index (CRI) that is the absolute value of the binding affinity multiplied by the daily dose to assess the potential risk of the adverse reactions. The drugs which have been recognized as causative drugs of SJS/TEN in Japan have revealed relatively high CRI, and the association between SJS/TEN and HLA-A\*02:06 has been qualitatively verified. The results have also shown that some drugs whose links to SJS/TEN have not been clinically recognized in Japan show the high CRI and suggested that attention should be paid to their adverse drug reactions.

## 1. Introduction

Adverse drug reactions (ADRs) are a serious public health problem. Drug hypersensitivity which constitutes a major category of ADRs is typically severe in nature. In particular, Stevens-Johnson syndrome (SJS) and toxic epidermal necrolysis (TEN) are severe drug hypersensitivities with high mortality. Various drugs have been pointed out as causes of SJS/TEN. In addition to certain prescription drugs, typical over-the-counter drugs of cold medicines are suggested to be causative [1, 2]. These reactions often result in severe and

definitive sequelae such as vision loss in some cases [2]. The reported incidence of ocular complications in SJS/TEN is 50–68% [3].

Considering the fact that cold medicines are the most widely used over-the-counter drugs, it is extremely important to know the potential causative ingredients of SJS/TEN. Although nonsteroidal anti-inflammatory drugs which are major ingredients of cold medicines were suggested as causative drugs [2], no systematic studies about drug hypersensitivities of other ingredients have been undertaken. Since it is possible that certain ingredients might cause more severe

TABLE 1: Ingredients contained in popular cold medicines available in Japan. Chinese herbs, vitamins, and lysozyme are excluded from the table.

Drug name	Therapeutic category
Acetaminophen	Analgesic; antipyretic
Ambroxol	Expectorant
Bromhexine	Expectorant; mucolytic
Caffeine	CNS stimulant; respiratory stimulant
Carbinoxamine	Antihistaminic
<i>d</i> -Chlorpheniramine	Antihistaminic
Clemastine	Antihistaminic
Dextromethorphan	Antitussive
Dihydrocodeine	Analgesic (narcotic); antitussive
Ethenzamide	Analgesic
Guaiacol	Expectorant
Guaiifenesin	Expectorant
Ibuprofen	Anti-inflammatory; analgesic; antipyretic
Isopropamide	Antispasmodic
Loxoprofen ( <i>R, S</i> )	Anti-inflammatory; analgesic
Mequitazine	Antihistaminic
<i>d</i> -Methylephedrine	Analeptic
Noscapine	Antitussive
Pseudoephedrine	Decongestant
Tranexamic acid	Hemostatic

adverse reactions, predicting the potential adverse reactions of other ingredients will be undoubtedly beneficial to avoid the latent ADRs.

Significant associations between certain ADRs and specific alleles of human leukocyte antigen (HLA) have been pointed out [4]. Recently, the detailed molecular mechanism underlying the strong association between HLA-B\*57 and the hypersensitivity of reverse-transcriptase inhibitor abacavir has been disclosed [5]. The relevant adverse drug reaction is triggered by the strong binding of abacavir into the antigenic peptide binding groove of the HLA molecule. It has been reported that the frequency of carriers of the HLA-A\*02:06 antigen is significantly higher among Japanese patients with severe ocular surface complications than in other populations [6]. It is highly possible that the adverse drug reactions associated with HLA-A\*02:06 are also triggered by the direct interactions between the causative drug molecules and the HLA molecule.

However, it is generally intractable to ascertain experimentally the causation between a specific drug and an incidence of a particular adverse drug reaction especially in cases where multiple drugs are administered simultaneously such as cold medicines. *In silico* analysis based on the underlying molecular mechanism of the ADRs can be employed as a powerful alternative method in these situations. In this study, *in silico* analysis using docking simulations between various ingredient molecules in cold medicines and the HLA-A\*02:06 molecule has been undertaken in order to predict

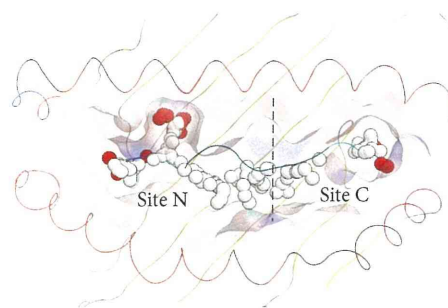


FIGURE 1: The antigenic-peptide binding groove of HLA-A\*02:06 is depicted schematically with the two alpha helices represented by helical lines running horizontally. The white and red alpha spheres calculated in the groove represent hydrophobic and hydrophilic positions, respectively. The binding groove is divided into sites C and N.

what ingredient molecules might cause SJS/TEN through the interactions with HLA-A\*02:06.

## 2. Methods

We examined all ingredients contained in four popular over-the-counter cold medicines available in Japan, that is, Lulu, Pabron, Contac, and Benza Block. The ingredient molecules used in docking simulations are given in Table 1. As Chinese herbs contained in all of these over-the-counter cold medicines are mixtures of various agents whose molecular structures are not fully identified, they are excluded from the docking simulations. Lysozyme and vitamins are also excluded. A software system molecular operating environment (MOE) [7] was used throughout this study and all the calculations were performed on a DELL PC workstation T7500.

The X-ray structure of the HLA-A\*02:06 molecule deposited in the Protein Data Bank [8] (PDB ID: 3OXR) was used for docking simulations. It is highly possible that the molecules shown in Table 1 bind to the antigenic-peptide binding groove located between two  $\alpha$  helices as in the case of abacavir. Since the groove is relatively wide, we have specified the possible binding sites by use of the alpha site finder function [9] implemented in MOE. Small spheres named alpha spheres shown in Figure 1 correspond to locations of tight atomic packing at the antigenic-peptide binding groove. A site where the alpha spheres are clustered is designated alpha site which is considered to be the potential binding site of drug molecules. Two alpha sites designated sites N and C were identified in the antigenic-peptide binding groove of the HLA-A\*02:06 molecule and these two sites were considered in docking simulations. All docking simulations were undertaken by use of software ASEDock [10]. ASEDock based on unique concept of ASE model and ASE score uses the alpha sites for docking the small molecule. Since ASEDock is free from any bias except for shape, it is one of the very robust docking methods. The binding affinity of a drug molecule to the HLA molecule was judged by

TABLE 2: Binding affinities of the ingredients of cold medicines to the antigenic-peptide binding groove of HLA-A\*02:06. Composite risk index is calculated by multiplying the maximum daily dose and the absolute value of GBVI/WSA<sub>dG</sub>.

Drug name	Maximum dose/day (mmol)	GBVI <sub>dG</sub> * (site N) (kcal/mol)	GBVI <sub>dG</sub> * (site C) (kcal/mol)	Composite risk index (site N)**	Composite risk index (site C)**	Preferential binding site
Ethenzamide	6.356	-4.966	-5.335	31.565	33.914	C
Acetaminophen	5.954	-4.623	-4.608	27.523	27.438	N
Tranexamic acid	4.771	-5.550	-5.613	26.478	26.776	C
Ibuprofen	2.181	-5.491	-5.720	11.979	12.477	C
Abacavir***	1.789		-6.562		11.740	C
Guaifenesin	1.211	-6.482	-5.820	7.848	7.047	N
Guaiaacolsulfonate	0.991	-4.562	-5.482	4.519	5.430	C
Pseudoephedrine	0.669	-5.581	-5.348	3.736	3.579	N
Caffeine	0.463	-5.333	-5.128	2.471	2.377	N
Loxoprofen	0.168	-6.468	-6.184	1.086	1.038	N
Dextromethorphan	0.130	-6.537	-6.315	0.847	0.819	N
Noscapine	0.116	-7.464	-6.792	0.867	0.789	N
<i>d</i> -Methylephedrine	0.139	-6.029	-5.636	0.838	0.784	N
Ambroxol	0.109	-6.763	-6.247	0.734	0.678	N
Dihydrocodeine	0.060	-5.401	-5.709	0.325	0.343	C
Bromhexine	0.029	-6.602	-5.655	0.192	0.164	N
Carbinoxamine	0.018	-7.616	-6.073	0.140	0.112	N
Isopropamide	0.012	-7.729	-6.102	0.097	0.076	N
<i>d</i> -Chlorpheniramine	0.010	-7.265	-6.690	0.070	0.064	N
Mequitazine	0.012	-7.021	-5.021	0.087	0.062	N
Clemastine	0.003	-7.680	-6.265	0.022	0.018	N

\*GBVI<sub>dG</sub>: GBVI/WSA<sub>dG</sub>. \*\*Composite risk index: |GBVI/WSA<sub>dG</sub>| × (maximum daily dose).

\*\*\*Binding to the HLA-B\*57:01 molecule.

scoring functions of GBVI/WSA<sub>dG</sub> [11] which is considered to express protein-ligand binding free energy.

Redocking simulations were performed using the crystal structure of the complex between abacavir and the HLA-B\*57:01 molecule (PDB ID: 3VRI) to assess the appropriateness of using ASEDock for the drug-HLA systems. The root-mean square deviation (rmsd) between nonhydrogen atoms of abacavir in the crystal and docked structures is 0.99 Å. Prediction within rmsd of 2.0 Å is held as the passing standard. The validation clearly indicated that ASEDock can simulate accurately enough the structure and position of the bound abacavir molecule in the crystal structure and the docking algorithm is suitable for the docking simulations of the drug-HLA systems. A superposition of the simulated and experimental structures is shown in Figure 2. The GBVI/WSA<sub>dG</sub> value is calculated to be -6.56 kcal/mol.

### 3. Results and Discussion

The binding affinities to both sites are given in Table 2. As the racemates of methylephedrine and chlorpheniramine are used, the optical isomers with higher binding affinities are given in the table. Although the binding affinity to the HLA molecule would play an important role to trigger the following immunological response, the probability of occurrence of the adverse reactions might significantly depend on the dose

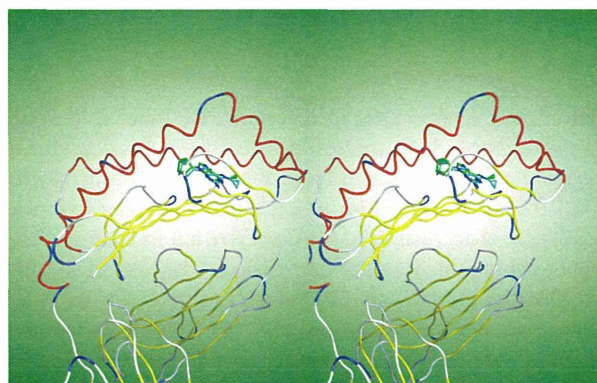


FIGURE 2: A superposition of simulated and experimental structures of abacavir. The drug is bound at the antigenic-peptide binding groove of the HLA-B\*57:01 molecule. The HLA molecules are depicted schematically. The alpha helix and beta strand are shown by red and yellow tubes, respectively. The drug molecules are depicted by stick models. The carbon atoms of abacavir located by X-ray analysis and docking simulations are colored in cyan and green, respectively. This figure is a cross-eyed stereoscopic drawing.

of the drug. Therefore it may be reasonable to use a composite risk index (CRI) calculated by multiplying the absolute value of the binding affinity by the daily dose together to assess the

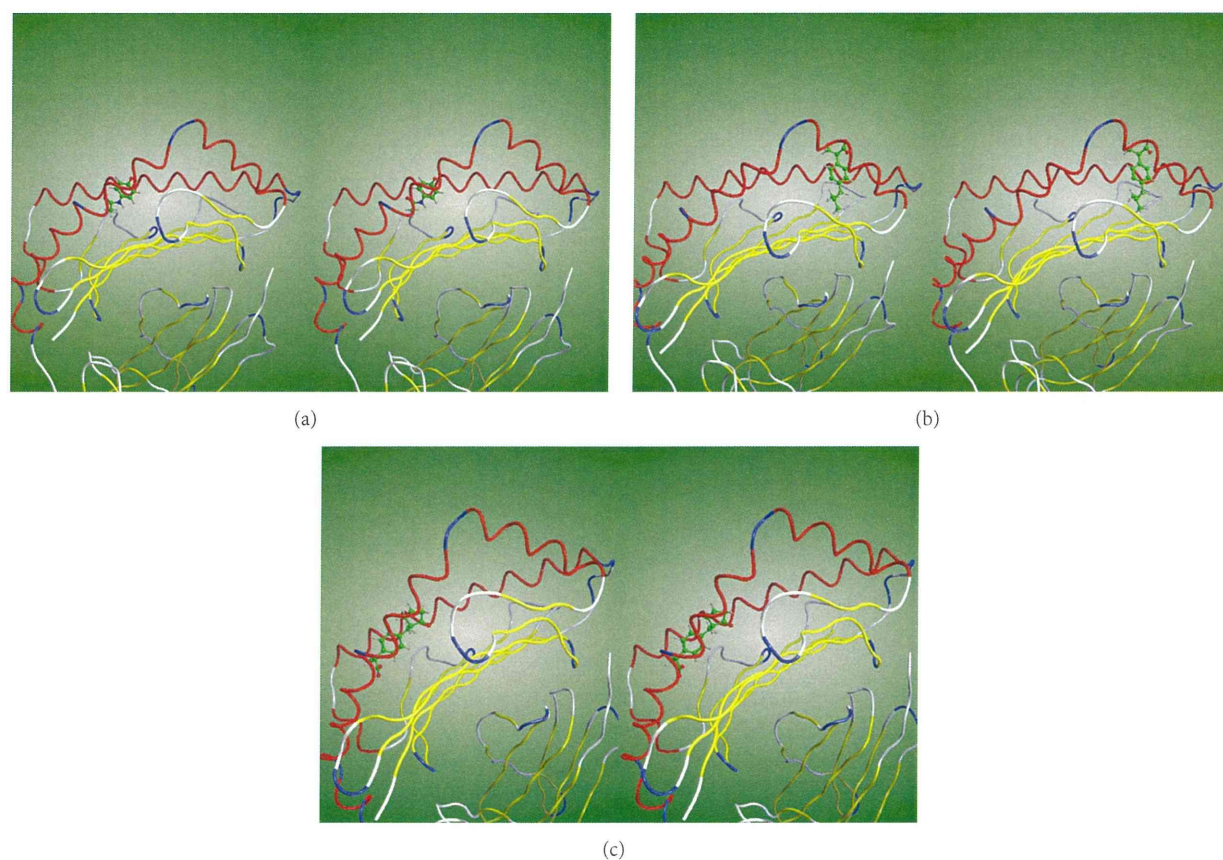


FIGURE 3: Cross-eyed stereoscopic drawings of the drugs bound at the antigenic-peptide binding grooves of ADR-associated HLA molecules. The drugs are represented by stick models with carbon atoms and bonds colored in green. The interaction modes of acetaminophen, ibuprofen, and loxoprofen at the peptide-binding groove of the HLA-A\*02:06 molecule are shown in (a), (b), and (c), respectively.

potential risk of the adverse reactions. In Table 2, the CRI is given and the drug molecules are sorted by descending order of the CRI calculated from the binding affinity to the site C. The maximum dose of each drug per day in mmol was calculated according to the dose written in each package insert of cold medicines. For comparison, the binding affinity of abacavir to the HLA-B\*57 molecule is given. Most of the drugs are preferentially bound at the site N. Drugs with higher CRIs are, however, inclined to bind preferentially at the site C as abacavir.

If we set a CRI threshold of, for example, 1.0 mmol·kcal/mol arbitrarily, nine drugs are judged to be high-risk drugs causing adverse drug reactions through binding to HLA-A\*02:06. In Japan, warnings about potential side effects of SJS and TEN are explicitly stated in the ethical drug package inserts of acetaminophen, ibuprofen, and loxoprofen [12]. Cases of SJS/TEN caused by acetaminophen [13], ibuprofen [14], and loxoprofen [15] have been reported, albeit the associations with HLA-A\*02:06 have not been noticed. Ethenzamide was reported as a causative drug of SJS in Japan [16]. Since it is highly possible that the SJS caused by these four drugs is associated with HLA-A\*02:06, studies to verify the associations are urgently required to understand

the molecular mechanisms of the adverse reactions and find countermeasures against them. As to tranexamic acid, guaifenesin, guaiacol, pseudoephedrine, and caffeine, they are not considered as significant causative drugs of SJS at least in Japan. However, 17, 4, and 2 SJS cases caused by guaifenesin, pseudoephedrine, and caffeine, respectively, have been reported from the FDA [17]. TEN caused by tranexamic acid was reported [18]. Although it is highly possible that these adverse drug reactions are associated with different alleles, rather high CRIs of these drugs imply the involvement of these drugs in SJS/TEN. As comprehensive analysis about causative factors of SJS has not been undertaken, unknown factors might be involved in the SJS cases. Under these circumstance, we believe that SJS-like symptoms caused by drugs with the high CRIs should be monitored carefully.

The drugs with the CRI being lesser than 1.0 have not been noticed as culprit drugs for SJS/TEN at least in Japan. The low incidence of SJS/TEN caused by these drugs in Japan supports that the SJS/TEN associated with HLA-A\*02:06 should be mainly determined by CRI. Although certain numbers of SJS cases have been reported on drugs such as clemastine, mequitazine and bromhexine from the FDA, the causative alleles in these cases may be different from HLA-A\*02:06.



Hypersensitivities against these drugs are described in the ethical drug package inserts in Japan.

Metabolites for each drug molecule have not been fully disclosed yet. It is possible that some of such metabolites rather than the parent drugs would play more important roles in certain cases of ADRs. Therefore further simulation studies including the metabolites will be essential and interesting in the more distant future. Nevertheless, these uncertainties do not preclude the usefulness of the simulation results obtained for the parent drugs in the context of a weight of evidence approach for the time being. The *in silico* risk assessment methodology as used in the present study will certainly play an important role in identifying testing needs, setting testing priorities, and above all attracting our attention to the potential toxicities of the relevant drugs.

The binding modes of acetaminophen, ibuprofen, and loxoprofen at the antigenic peptide-binding groove of the HLA-A\*02:06 molecule are illustrated in Figures 3(a), 3(b), and 3(c), respectively. The binding mode of abacavir to the HLA-B\*57:01 is shown in Figure 2. In the crystal structure [5], abacavir binds deep across the bottom of the antigen-binding groove of the HLA molecule. Therefore new endogenous peptides can bind on top of the bound abacavir leading to the adverse drug reaction of abacavir. On the other hand, acetaminophen and loxoprofen are bound near the surface of the HLA molecule. Although one end of the ibuprofen molecule is bound to the bottom of the groove, the carboxyl group is exposed on the surface of the HLA molecule. Since the binding modes of these drugs appear different from that of abacavir, it is not clear whether new endogenous peptides can bind on top of the bound drugs. Hence further studies to confirm the molecular mechanisms leading to the ADRs are required.

#### 4. Conclusions

Prompt recovery from SJS/TEN upon withdrawal of the relevant drugs indicates the importance of early diagnosis. However, identification of the culprit drugs is usually intractable especially in the cases where patients take drugs with multiple ingredients such as cold medicines. In these situations, a comprehensive risk assessment taking both of circumstantial evidence and theoretically deduced risk index into account would be helpful. In the present study we have shown that docking simulations between drug molecules and the HLA-A\*02:06 molecule can explain the episodes of culprit drugs of SJS/TEN reported so far in Japan. In addition, the present study has pointed out the potential risk of several drugs whose involvement in SJS/TEN has not been explicitly noticed until now. This study urges further investigations of verifying the ADRs of these drugs in detail.

#### Conflict of Interests

The authors declare that they have no conflict of interests.

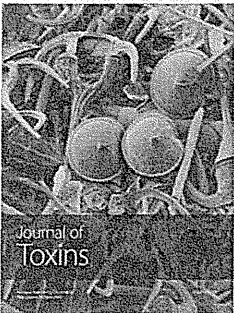

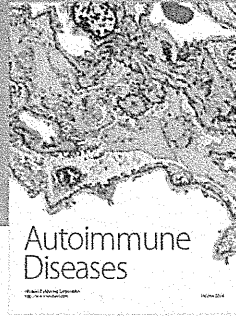
#### Acknowledgment

This work was partly supported by Grant-in-Aid for Scientific Research on Innovative Areas (22133012) from the Ministry of Education, Culture, Sports, Science and Technology (MEXT) for Noriaki Hirayama.


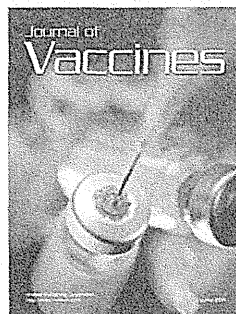


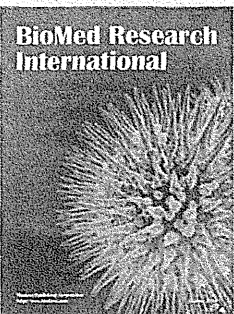
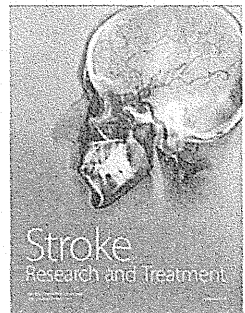

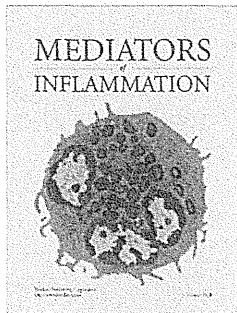



#### References

- [1] Y. Yamane, M. Aihara, and Z. Ikezawa, "Analysis of Stevens-Johnson syndrome and toxic epidermal necrolysis in Japan from 2000 to 2006," *Allergology International*, vol. 56, no. 4, pp. 419–425, 2007.
- [2] M. Ueta, C. Sotozono, M. Nakano et al., "Association between prostaglandin E receptor 3 polymorphisms and Stevens-Johnson syndrome identified by means of a genome-wide association study," *Journal of Allergy and Clinical Immunology*, vol. 126, no. 6, pp. 1218–1225, 2010.
- [3] W. J. Power, M. Ghoraishi, J. Merayo-Llives, R. A. Neves, and C. S. Foster, "Analysis of the acute ophthalmic manifestations of the erythema multiforme/Stevens-Johnson syndrome/toxic epidermal necrolysis disease spectrum," *Ophthalmology*, vol. 102, no. 11, pp. 1669–1676, 1995.
- [4] P. T. Illing, J. P. Vivian, A. W. Purcell, J. Rossjohn, and J. McCluskey, "Human leukocyte antigen-associated drug hypersensitivity," *Current Opinion in Immunology*, vol. 25, no. 1, pp. 81–89, 2013.
- [5] P. T. Illing, J. P. Vivian, N. L. Dudek et al., "Immune self-reactivity triggered by drug-modified HLA-peptide repertoire," *Nature*, vol. 486, no. 7404, pp. 554–558, 2012.
- [6] M. Ueta, K. Tokunaga, C. Sotozono et al., "HLA class I and II gene polymorphisms in Stevens-Johnson syndrome with ocular complications in Japanese," *Molecular Vision*, vol. 14, pp. 550–555, 2008.
- [7] MOE (Molecular Operating Environment), 2011.01; Chemical Computing Group: Montreal, Quebec, Canada, 2011.
- [8] F. C. Bernstein, T. F. Koetzle, and G. J. B. Williams, "The protein data bank: a computer based archival file for macromolecular structures," *Journal of Molecular Biology*, vol. 112, no. 3, pp. 535–542, 1977.
- [9] P. Labute and M. Santavy, "Locating binding sites in protein structures," *Journal of Chemical Computing Group*, 2007.
- [10] J. Goto, R. Kataoka, H. Muta, and N. Hirayama, "ASEDock-docking based on alpha spheres and excluded volumes," *Journal of Chemical Information and Modeling*, vol. 48, no. 3, pp. 583–590, 2008.
- [11] C. R. Corbeil, C. I. Williams, and P. Labute, "Variability in docking success rates due to dataset preparation," *Journal of Computer-Aided Molecular Design*, vol. 26, no. 6, pp. 775–786, 2012.
- [12] [http://www.info.pmda.go.jp/psearch/html/menu\\_tenpu\\_base.html](http://www.info.pmda.go.jp/psearch/html/menu_tenpu_base.html).
- [13] A. Khawaja, A. Shahab, and S. A. Hussain, "Acetaminophen induced Steven Johnson Syndrome-Toxic epidermal necrolysis overlap," *Journal of the Pakistan Medical Association*, vol. 62, no. 5, pp. 524–527, 2012.
- [14] "Ibuprofen: Stevens-Johnson syndrome," *WHO Drugs Information*, vol. 19, no. 3, pp. 208–209, 2005.
- [15] H. Nagata, T. Harada, Y. Nariyai, H. Matsushima, and Y. Yoshimura, "Allergic reaction originated from loxoprofen sodium; Report a case," *Journal of The Japanese Stomatological Society*, vol. 52, no. 2, pp. 67–72, 2003.

- [16] A. Inoue, R. Takebayashi, and A. Shoji, "A case of Stevens-Johnson syndrome due to ethenzamide," *Japanese Journal of Dermatoallergology*, vol. 7, no. 3, pp. 61–64, 1999.
- [17] FDA Adverse Event Reporting System (FAERS), <http://www.fda.gov/Drugs/GuidanceComplianceRegulatoryInformation/Surveillance/AdverseDrugEffects/default.htm>.
- [18] M. P. Irazabal, L. M. Martin, L. A. Gil, and M. A. I. Gastearena, "Tranexamic acid-induced toxic epidermal necrolysis," *The Annals of Pharmacotherapy*, vol. 47, article e16, 2013.



**Hindawi**  
Submit your manuscripts at  
<http://www.hindawi.com>



# The Relation Between Visual Performance and Clinical Ocular Manifestations in Stevens-Johnson Syndrome

MINAKO KAIDO, MASAKAZU YAMADA, CHIE SOTOZONO, SHIGERU KINOSHITA, JUN SHIMAZAKI, YOSHITSUGU TAGAWA, YUKO HARA, TAIICHIRO CHIKAMA, AND KAZUO TSUBOTA

- **PURPOSE:** To investigate the relation between visual function, clinical findings, and visual symptoms in Stevens-Johnson syndrome (SJS) and to compare the results with Sjögren syndrome (SS) patients and normal subjects.
- **DESIGN:** Cross-sectional comparative study.
- **METHODS:** One hundred fifteen eyes of 59 consecutive patients with SJS and toxic epidermal necrolysis (TEN), 208 eyes of 104 healthy normal subjects, and 132 eyes of 66 SS patients were investigated in this multicenter study. All study subjects underwent tear function and ocular surface examinations, Landolt and functional visual acuity examinations, and the Japanese version of the NEI VFQ-25 (National Eye Institute Visual Function Questionnaire).
- **RESULTS:** The mean ocular surface grading scores were significantly higher and the mean score of all 12 NEI VFQ subscales was significantly lower in the SJS patients compared to the SS patients and the normal subjects ( $P < .05$ ). The conventional and functional logarithm of minimal angle of resolution (logMAR) visual acuities in SJS patients with minimal corneal complications were significantly higher and the mean total composite NEI VFQ scores were lower compared to SS patients. The conventional and functional logMAR visual acuities and the mean ocular surface grading scores in SJS with aqueous deficiency were significantly higher and the mean total composite NEI VFQ scores were lower compared to SS patients. Strong correlations between best-corrected logMAR functional visual acuities and either ocular surface grading scores or the composite NEI VFQ-25 scores were observed.
- **CONCLUSIONS:** The functional visual acuity examination reflects the severity of clinical ocular surface findings and vision-related quality of life more than the

standard conventional visual acuity in SJS. (Am J Ophthalmol 2012;154:499–511. © 2012 by Elsevier Inc. All rights reserved.)

**S**TEVENS-JOHNSON SYNDROME (SJS) IS AN ACUTE, self-limiting disease of the skin and mucous membranes associated with symblepharon, adhesive occlusion of the lacrimal puncta, and corneal opacification with conjunctivalization and severe dry eyes leading to worsening of the ocular surface health and poor quality of vision.<sup>1–8</sup>

Previous reports have demonstrated that contrast sensitivity, contrast visual acuity, glare disability, and wavefront aberrations are useful to detect quality of vision in everyday life.<sup>9–19</sup> Visual function assessment using these measurement methods has been reported to be useful in keratorefractive surgery, mild cataract, and dry eye diseases.<sup>9–19</sup> To the best of our knowledge, however, there are no reports about visual function assessment in patients with SJS except a previously published report by us.<sup>8</sup>

It has been our experience that SJS patients with good visual acuity and mild ocular surface morbidity may still complain of similar severe eye irritation and visual complaints as patients with Sjögren syndrome (SS). However, the differences in visual symptoms and conventional and dynamic visual acuity between these 2 entities have not been quantified and compared so far. In an attempt to investigate the visual function and ocular surface differences between SJS and SS, we performed this multicenter cross-sectional study, using a previously reported ocular surface morbidity severity questionnaire and functional visual acuity measurement.<sup>20–24</sup>

## METHODS

- **SUBJECTS:** One hundred fifteen eyes of 59 consecutive patients (28 male, 31 female; mean age:  $47.5 \pm 16.0$  years; range: 14–79 years) with SJS, including its more severe variant, toxic epidermal necrolysis (TEN), seen at the Cornea Subspecialty Outpatient Clinic of the Departments of Ophthalmology of Keio University, Tokyo Dental College, Tokyo Medical Center, Kyoto Prefectural University of Medicine, Hokkaido University, Ehime University, and Yamaguchi University were studied in this cross-sectional multicenter study. Clinicians participating

Accepted for publication Mar 28, 2012.

From the Department of Ophthalmology, Keio University School of Medicine, Tokyo, Japan (M.K., K.T.); Department of Ophthalmology, Tokyo Medical Center, Tokyo, Japan (M.Y.); Department of Ophthalmology, Kyoto Prefectural University of Medicine, Kyoto, Japan (C.S., S.K.); Department of Ophthalmology, Tokyo Dental College, Ichikawa, Japan (J.S.); Department of Ophthalmology, Hokkaido University School of Medicine, Hokkaido, Japan (Y.T.); Department of Ophthalmology, Ehime University School of Medicine, Ehime, Japan (Y.H.); and Department of Ophthalmology, Yamaguchi University Graduate School of Medicine, Yamaguchi, Japan (T.C.).

Inquiries to Minako Kaido, Department of Ophthalmology, Keio University School of Medicine, Shinanomachi 35, Shinjuku-ku, Tokyo, 160-8582, Japan; e-mail: fwiw1193@nib.infoweb.ne.jp