



TOP

新着情報

SJS 病気説明

社会保障制度

SJS患者会

励まの会

掲示板

外部リンク

お問い合わせ

SJS患者会

更新履歴



[ブログ開設しました](#)

<http://sjsten.exblog.jp/>

当患者会活動記録に記載してない

発言や著作物はSJS患者会とは一切関係ありません

患者会より

病気を治すため、症状を緩和するために飲んだ薬。それらの副作用によって、より重篤な症状になることがあります。それら薬疹の一つ、スティーブンス・ジョンソン症候群に私たちはかかりました。

私たちは、自分たちと同じように辛い体験をする人が、少しでもいなくなるように、また後遺症などの治療が安心して受けられるような体制が早く確立されるように、活動を続けています。

サイトはSJS患者会の著作物です。無断転載や再配布などの2次使用は一切お断りいたします。

重症薬疹について調査研究、治療を行っている医療機関（順不同）

<皮膚科>

- ◆ 杏林大学医学部皮膚科学教室
- ◆ 愛媛大学大学院医学研究科感覚皮膚医学
- ◆ 昭和大学医学部皮膚科学教室
- ◆ 横浜市立大学大学院医学研究科環境免疫病態皮膚科学教室
- ◆ 島根大学医学部皮膚科学教室
- ◆ 奈良県立医科大学医学部皮膚科学教室
- ◆ 京都大学大学院医学研究科皮膚科学教室
- ◆ 市立島田市民病院皮膚科
- ◆ 慶應義塾大学医学部皮膚科学教室
- ◆ 北海道大学大学院医学研究科感覚器病学講座皮膚科学分野

<眼科>

- ◆ 京都府立医科大学大学院医学研究科視覚機能再生外科学教室

[V]

研究成果の刊行物に関する一覧表

論文

*印：巻末別刷りあり

太字著者：研究代表者・分担者

下線著者：研究協力者

塩原哲夫

| | | | | | | |
|---|--------|--|-----|-----------|-----|----------|
| 1 | 発表者 | 佐藤洋平, 平原和久, 狩野葉子, 塩原哲夫 | | | | |
| | 論文タイトル | 肺真菌症患者に生じた急性汎発性発疹性膿疱症 (AGEP)の1例. | | | | |
| | 発表誌 | 臨床皮膚科 | | | | |
| | 巻号 | | ページ | | 出版年 | In press |
| 2 | 発表者 | 狩野葉子, 塩原哲夫 | | | | |
| | 論文タイトル | アレルギー疾患ガイドライン改訂について. | | | | |
| | 発表誌 | トピックス. アレルギー・免疫 | | | | |
| | 巻号 | 21 | ページ | 470-479 | 出版年 | 2014 |
| 3 | 発表者 | 塩原哲夫 | | | | |
| | 論文タイトル | 皮膚アレルギー —内科医のための診断・鑑別と治療の要点— | | | | |
| | 発表誌 | Medical Practice | | | | |
| | 巻号 | 31(2) | ページ | 287-290 | 出版年 | 2014 |
| 4 | 発表者 | 塩原哲夫 | | | | |
| | 論文タイトル | 薬剤性過敏症症候群. | | | | |
| | 発表誌 | アレルギー・免疫 | | | | |
| | 巻号 | 20(12) | ページ | 1793-1802 | 出版年 | 2013 |
| 5 | 発表者 | 塩原哲夫 | | | | |
| | 論文タイトル | 免疫再構築症候群. | | | | |
| | 発表誌 | リウマチ科 | | | | |
| | 巻号 | 49 | ページ | 741-749 | 出版年 | 2013 |
| 6 | 発表者 | 塩原哲夫 | | | | |
| | 論文タイトル | 薬疹の臨床型と病因. | | | | |
| | 発表誌 | 日本医師会雑誌 | | | | |
| | 巻号 | 142 | ページ | 493-497 | 出版年 | 2013 |
| 7 | 発表者 | Shiohara T, Ushigome U, Kano Y | | | | |
| | 論文タイトル | Crucial role of viral reactivations in the development of severe drug eruptions. | | | | |
| | 発表誌 | Clinical Reviews in Allergy & Immunology | | | | |
| | 巻号 | | ページ | | 出版年 | In press |
| 8 | 発表者 | Saraya T, Mikoshiba M, Kamiyama H, Yoshizumi M, Tsuchida S, Tsukagoshi H, Ishioka T, Terada M, Tanabe E, Tomioka C, Ishii H, Kimura H, Kozawa K, | | | | |

| | | | | | | |
|-----|--------|---|-----|-----------|-----|---------|
| | 発表者 | Shiohara T, Takizawa H, Goto H | | | | |
| | 論文タイトル | Evidence for reactivation of human herpesvirus 6 in generalized lymphadenopathy in a patient with drug-induced hypersensitivity syndrome. | | | | |
| | 発表誌 | J Clin Microbiol | | | | |
| | 巻号 | 51(6) | ページ | 1979-1982 | 出版年 | 2013 |
| 9* | 発表者 | Shiohara T | | | | |
| | 論文タイトル | The role of viral infection in the development of severe drug eruptions. | | | | |
| | 発表誌 | Dermatologica Sinica | | | | |
| | 巻号 | 31 | ページ | 205-210 | 出版年 | 2013 |
| 10 | 発表者 | Kano Y, Shiohara T | | | | |
| | 論文タイトル | Long-term outcome of patients with severe cutaneous adverse reactions. | | | | |
| | 発表誌 | Dermatologica Sinica | | | | |
| | 巻号 | 31 | ページ | 211-216 | 出版年 | 2013 |
| 11 | 発表者 | Hirahara K, Kano Y, Sato Y, Horie C, Okazaki A, Ishida T, Aoyama Y, Shiohara T | | | | |
| | 論文タイトル | Methylprednisolone pulse therapy for Stevens-Johnson syndrome/toxic epidermal necrolysis: Clinical evaluation. | | | | |
| | 発表誌 | J Am Acad Dermatol | | | | |
| | 巻号 | 69 | ページ | 496-498 | 出版年 | 496-498 |
| 12* | 発表者 | Ushigome Y, Kano Y, Ishida T, Hirahara K, Shiohara T | | | | |
| | 論文タイトル | Short-and long-term outcomes of 34 patients with drug-induced hypersensitivity syndrome in a single institution. | | | | |
| | 発表誌 | J Am Acad Dermatol | | | | |
| | 巻号 | 68 | ページ | 721-728 | 出版年 | 2013 |
| 13 | 発表者 | Shiohara T | | | | |
| | 論文タイトル | Die rolle viraler infektionen bei schwerer arzneimittelreaktionen. | | | | |
| | 発表誌 | Der Bayerische Internist | | | | |
| | 巻号 | 33 | ページ | 14-20 | 出版年 | 2013 |

橋本公二

| | | | | | | |
|-----|--------|-------------|-----|---------|-----|------|
| 14* | 発表者 | <u>藤山幹子</u> | | | | |
| | 論文タイトル | 重症薬疹の診断と治療. | | | | |
| | 発表誌 | 日医師会誌 | | | | |
| | 巻号 | 142 | ページ | 513-516 | 出版年 | 2013 |
| 15* | 発表者 | <u>藤山幹子</u> | | | | |
| | 論文タイトル | 薬剤性過敏症症候群. | | | | |
| | 発表誌 | 別冊日本臨床 | | | | |

| | | | | | | |
|----|--------|----------------------------------|-----|---------|-----|------|
| | 巻号 | 24 | ページ | 364-365 | 出版年 | 2013 |
| 16 | 発表者 | 薬師寺直喜, 藤山幹子, 渡部裕, 白方裕, 村上信, 佐山浩二 | | | | |
| | 論文タイトル | デュロテップパッチによる接触皮膚炎症候群の1例. | | | | |
| | 発表誌 | 臨床皮膚科 | | | | |
| | 巻号 | 67 | ページ | 12-16 | 出版年 | 2013 |

相原道子

| | | | | | | |
|----|--------|---|-----|-----------|-----|------|
| 17 | 発表者 | 三津山信治, 松倉節子, 蒲原毅, 相原道子 | | | | |
| | 論文タイトル | TNF- α 阻害薬で誘発された乾癬様皮疹の3例. | | | | |
| | 発表誌 | 皮膚臨床 | | | | |
| | 巻号 | 55(7) | ページ | 893-897 | 出版年 | 2013 |
| 18 | 発表者 | 高橋ユエ, 松倉節子, 今井満ちる, 廣門未知子, 池澤優子, 池澤善郎, 相原道子, 蒲原毅 | | | | |
| | 論文タイトル | セレコキシブによる薬疹の4例. | | | | |
| | 発表誌 | J Environ Dermatol Cutan Allergol | | | | |
| | 巻号 | 7 | ページ | 93-99 | 出版年 | 2013 |
| 19 | 発表者 | 相原道子 | | | | |
| | 論文タイトル | 薬疹の診断・治療ガイドラインとその使い方. | | | | |
| | 発表誌 | 日医雑誌 | | | | |
| | 巻号 | 142 | ページ | 498-502 | 出版年 | 2013 |
| 20 | 発表者 | 相原道子 | | | | |
| | 論文タイトル | 小児の薬疹. | | | | |
| | 発表誌 | 日小皮会誌 | | | | |
| | 巻号 | 32(3) | ページ | 225-229 | 出版年 | 2013 |
| 21 | 発表者 | 藤田浩之, 相原道子 | | | | |
| | 論文タイトル | 見逃したくない皮膚症状～全身疾患を診断するための考え方《他科医が知っておくべき内科関連皮膚疾患》 5 Stevens-Johnson 症候群. | | | | |
| | 発表誌 | Modern Physician | | | | |
| | 巻号 | 33(8) | ページ | 1023-1027 | 出版年 | 2013 |
| 22 | 発表者 | 藤田浩之, 相原道子 | | | | |
| | 論文タイトル | 特集Ⅱ/重症薬疹の診断と治療 SJS/TEN の治療法. | | | | |
| | 発表誌 | 臨床免疫・アレルギー科 | | | | |
| | 巻号 | 59(4) | ページ | 445-452 | 出版年 | 2013 |
| 23 | 発表者 | 藤田浩之, 相原道子 | | | | |
| | 論文タイトル | 薬剤アレルギー検査. | | | | |
| | 発表誌 | 皮膚科の臨床 11 月号臨時増刊号 皮膚科 日常診療 レベルアップエッセ | | | | |

| | | | | | | |
|-----|--------|--|-----|-----------|-----|------|
| | | センス | | | | |
| | 巻号 | 55 | ページ | 1522-1526 | 出版年 | 2013 |
| 24 | 発表者 | 山口由衣, 相原道子 | | | | |
| | 論文タイトル | Ⅷ生物学的製剤による過敏症. | | | | |
| | 発表誌 | アレルギー・免疫 | | | | |
| | 巻号 | 20 | ページ | 77-84 | 出版年 | 2013 |
| 25 | 発表者 | 小森 (山口) 絢子, 相原道子 | | | | |
| | 論文タイトル | 6 重症薬疹. | | | | |
| | 発表誌 | Modern Physician | | | | |
| | 巻号 | 33 | ページ | 173-178 | 出版年 | 2013 |
| 26 | 発表者 | 小森 (山口) 絢子, 相原道子 | | | | |
| | 論文タイトル | Part5 薬物アレルギー : 他科との連携—原因薬剤処方医への説明と指示. | | | | |
| | 発表誌 | Visual Dermatology | | | | |
| | 巻号 | 12(4) | ページ | 420-423 | 出版年 | 2013 |
| 27 | 発表者 | Kaniwa N, Sugiyama E, Saito Y, Kurose K, Maekawa K, Hasegawa R, Furuya H, Ikeda H, Takahashi Y, Muramatsu M, Tohkin M, Ozeki T, Mushiroda T, Kubo M, Kamatani N, Abe M, Yagami A, Ueta M, Aihara M , the Japan Pharmacogenomics Data Science Consortium | | | | |
| | 論文タイトル | Specific HLA types are associated with anti-epileptic drug-induced Stevens-Johnson syndrome and toxic epidermal necrolysis in Japanese subjects. | | | | |
| | 発表誌 | Pharmacogenomics | | | | |
| | 巻号 | 14(15) | ページ | 1821-1831 | 出版年 | 2013 |
| 28* | 発表者 | Fujita H, Watanabe T, Okada R, Nozaki Y, Ayabe M, Imagawa T, Yokota S, Aihara M | | | | |
| | 論文タイトル | Multiple fixed drug eruption caused by cyclophosphamide and its metabolite. | | | | |
| | 発表誌 | European Journal of Dermatology | | | | |
| | 巻号 | 23(2) | ページ | 275-277 | 出版年 | 2013 |
| 29* | 発表者 | Watanabe Y, <u>Matsukura S</u> , Isoda Y, Morita A, Aihara M , Kambara T | | | | |
| | 論文タイトル | A case of toxic epidermal necrolysis induced by allopurinol with human herpesvirus-6 reactivation. | | | | |
| | 発表誌 | Acta Derm Venereol | | | | |
| | 巻号 | 93(6) | ページ | 731-732 | 出版年 | 2013 |

末木博彦

| | | | | | | |
|----|--------|--------------------|--|--|--|--|
| 30 | 発表者 | 末木博彦, 鳥居秀嗣, 大槻マミ太郎 | | | | |
| | 論文タイトル | テラプレビルによる皮膚障害. | | | | |

| | | | | | | |
|-----|--------|--|-----|-----------|-----|-----------------|
| | 発表誌 | 臨皮 | | | | |
| | 巻号 | 67 | ページ | 8-12 | 出版年 | 2013 |
| 31 | 発表者 | 末木博彦 | | | | |
| | 論文タイトル | 精神科医が知っておくべき各診療科との連携のポイント 薬疹. | | | | |
| | 発表誌 | 精神科 | | | | |
| | 巻号 | 22 | ページ | 522-528 | 出版年 | 2013 |
| 32 | 発表者 | 末木博彦 | | | | |
| | 論文タイトル | 特集：肥満とアレルギー．肥満とアトピー性皮膚炎． | | | | |
| | 発表誌 | アレルギー・免疫 | | | | |
| | 巻号 | 20 | ページ | 1636-1641 | 出版年 | 2013 |
| 33* | 発表者 | Ohtoshi S, Kitami Y, Sueki H , Nakada T | | | | |
| | 論文タイトル | Utility of patch testing for patients with drug eruption. | | | | |
| | 発表誌 | Clin Exp Dermatol | | | | |
| | 巻号 | 39(3) | ページ | 279-283 | 出版年 | 2014 [In press] |
| 34* | 発表者 | Torii H, Sueki H , Kumada H, Sakurai Y, Aoki K, Yamada I, Ohtsuki M | | | | |
| | 論文タイトル | Dermatological side-effects of telaprevir-based triple therapy for chronic hepatitis C in phase III trials in Japan. | | | | |
| | 発表誌 | J Dermatol | | | | |
| | 巻号 | 40 | ページ | 587-595 | 出版年 | 2013 |

森田栄伸

| | | | | | | |
|-----|--------|---|-----|---------|-----|------|
| 35 | 発表者 | 新原寛之, 森田栄伸 | | | | |
| | 論文タイトル | 薬剤のアナフィラキシー分類と対応. | | | | |
| | 発表誌 | 日本医師会雑誌 | | | | |
| | 巻号 | 142 | ページ | 532 | 出版年 | 2013 |
| 36 | 発表者 | Niihara H, Kohno K, Taketani T, Kaneko S, Ito T, Sugamori T, Takahashi N, Miyaoka T, Okazaki S, Yasuda H, Furuya T, Morita E | | | | |
| | 論文タイトル | Simple and rapid detection of <i>HLA-A*31:01</i> using loop-mediated isothermal amplification. | | | | |
| | 発表誌 | J Dermatol Sci | | | | |
| | 巻号 | 74(1) | ページ | 88-92 | 出版年 | 2014 |
| 37* | 発表者 | Niihara H, Kaneko S, Ito T, Sugamori T, Takahashi N, Kohno K, Morita E | | | | |
| | 論文タイトル | <i>HLA-B*58:01</i> strongly associates with allopurinol-induced adverse drug reactions in a Japanese sample population. | | | | |
| | 発表誌 | J Dermatol Sci. | | | | |
| | 巻号 | 71(2) | ページ | 150-152 | 出版年 | 2013 |

浅田秀夫

| | | | | | | |
|-----|--------|--|-----|-----------|-----|-----------------|
| 38 | 発表者 | 平野亜由子, 福本隆也, 藤井秀孝, 藤澤章弘, 浅田秀夫 | | | | |
| | 論文タイトル | アセトアミノフェンによる紫斑型薬疹の1例. | | | | |
| | 発表誌 | 西日皮 | | | | |
| | 巻号 | 75 | ページ | 444-447 | 出版年 | 2013 |
| 39* | 発表者 | 浅田秀夫 | | | | |
| | 論文タイトル | ウイルス感染と重症薬疹 | | | | |
| | 発表誌 | 日皮会誌 | | | | |
| | 巻号 | 123(13) | ページ | 2752-2754 | 出版年 | 2013 |
| 40* | 発表者 | Morito H, Ogawa K, Fukumoto T, Kobayashi N, Morii T, Kasai T, Nonomura A, Kishimoto T, Asada H | | | | |
| | 論文タイトル | Increased ratio of FoxP3+ regulatory T cells/CD3+ T cells in skin lesions in drug-induced hypersensitivity syndrome/drug rash with eosinophilia and systemic symptoms. | | | | |
| | 発表誌 | Clin Exp Dermatol | | | | |
| | 巻号 | 39(3) | ページ | 284-291 | 出版年 | 2014 [in press] |
| 41 | 発表者 | Ogawa K, Morito H, Hasegawa A, Daikoku N, Miyagawa F, Okazaki A, Fukumoto T, Kobayashi N, Kasai T, Watanabe H, Sueki H, Iijima M, Tohyama M, Hashimoto K, Asada H | | | | |
| | 論文タイトル | Identification of thymus and activation-regulated chemokine (TARC/CCL17) as a potential marker for early indication of disease and prediction of disease activity in drug-induced hypersensitivity syndrome (DIHS)/ drug rash with eosinophilia and systemic symptoms (DRESS). | | | | |
| | 発表誌 | J Dermatol Sci | | | | |
| | 巻号 | 69 | ページ | 38-43 | 出版年 | 2013 |

谷崎英昭

| | | | | | | |
|-----|--------|---|-----|------|-----|------|
| 42 | 発表者 | Ono S, <u>Nakajima S</u> , Otsuka A, Miyachi Y, <u>Kabashima K</u> | | | | |
| | 論文タイトル | Pigmented purpuric dermatitis with high expression levels of serum TARC/CCL17 and epidermal TSLP. | | | | |
| | 発表誌 | Eur J Dermatol | | | | |
| | 巻号 | | ページ | Epub | 出版年 | 2013 |
| 43* | 発表者 | Otsuka A, <u>Nakajima S</u> , Kubo M, Egawa G, Honda T, Kitoh A, Nomura T, Hanakawa S, Sagita Moniaga C, Kim B, Matsuoka S, Watanabe T, Miyachi Y, <u>Kabashima K</u> | | | | |
| | 論文タイトル | Basophils are required for the induction of Th2 immunity to haptens and peptide | | | | |

| | | | | | | |
|-----|--------|---|-----|---------|-----|------|
| | | antigens. | | | | |
| | 発表誌 | Nat Commun. | | | | |
| | 巻号 | 4 | ページ | 1739 | 出版年 | 2013 |
| 44 | 発表者 | Tanizaki H, Nakamizo S, Nakahigashi K, Miyachi Y, Kabashima K | | | | |
| | 論文タイトル | A double dose of levocetirizine leads to better control of histamine-induced flare, wheal and itch in healthy donors. | | | | |
| | 発表誌 | Pharmacology | | | | |
| | 巻号 | 92(1-2) | ページ | 71-74 | 出版年 | 2013 |
| 45 | 発表者 | Murata T, Yamamoto M, Kore-Eda S, Azuma T, Kabashima K, Morita K | | | | |
| | 論文タイトル | Reactivation of Herpes Simplex Virus and Cytomegalovirus in a Case of Thymoma-associated Graft-versus-host Disease-like Erythroderma. | | | | |
| | 発表誌 | Acta Derm Venereol | | | | |
| | 巻号 | 93(6) | ページ | 761-762 | 出版年 | 2013 |
| 46* | 発表者 | Minegaki Y, Higashida Y, Ogawa M, Miyachi Y, Fujii H, Kabashima K | | | | |
| | 論文タイトル | Drug-induced hypersensitivity syndrome complicated with concurrent fulminant type 1 diabetes mellitus and Hashimoto's thyroiditis. | | | | |
| | 発表誌 | Int J Dermatol | | | | |
| | 巻号 | 52(3) | ページ | 355-357 | 出版年 | 2013 |
| 47 | 発表者 | Kitoh A, Nomura T, Kabashima K | | | | |
| | 論文タイトル | TGFβ1, an epidermal controller of skin dendritic cell homeostasis. | | | | |
| | 発表誌 | J Invest Dermatol | | | | |
| | 巻号 | 133(1) | ページ | 9-11 | 出版年 | 2013 |

小豆澤宏明

| | | | | | | |
|-----|--------|---|-----|---------|-----|------|
| 48* | 発表者 | 小豆澤宏明 | | | | |
| | 論文タイトル | 【重症薬疹の診断と治療】 薬疹におけるリンパ球刺激試験でとらえる薬剤特異的 T 細胞. | | | | |
| | 発表誌 | 臨床免疫・アレルギー科 | | | | |
| | 巻号 | 59(4) | ページ | 438-444 | 出版年 | 2013 |
| 49* | 発表者 | 小豆澤宏明 | | | | |
| | 論文タイトル | 【薬疹を診る-注意点とその対応】 最近の薬疹 注意すべき薬剤とその臨床症状. | | | | |
| | 発表誌 | 日本医師会雑誌 | | | | |
| | 巻号 | 142(3) | ページ | 503-507 | 出版年 | 2013 |

橋爪秀夫

| | | | | | | |
|-----|--------|--|-----|---------|-----|------|
| 50* | 発表者 | 橋爪秀夫 | | | | |
| | 論文タイトル | 【重症薬疹の診断と治療】重症薬疹の発症機序. | | | | |
| | 発表誌 | 臨床免疫・アレルギー科 | | | | |
| | 巻号 | 59(4) | ページ | 461-470 | 出版年 | 2013 |
| 51 | 発表者 | 橋爪秀夫 | | | | |
| | 論文タイトル | 薬疹のデータベースの現状. | | | | |
| | 発表誌 | 日本医師会雑誌 | | | | |
| | 巻号 | 142(3) | ページ | 492 | 出版年 | 2013 |
| 52* | 発表者 | Fujiyama T, Kawakami C, Sugita K, Kubo-Kabashima R, Sawada Y, Hino R, Nakamura M, Shimauchi T, Ito T, Kabashima K, Hashizume H , Tokura Y | | | | |
| | 論文タイトル | Increased frequencies of Th17 cells in drug eruptions. | | | | |
| | 発表誌 | J Dermatol Sci | | | | |
| | 巻号 | 73 | ページ | 85-88 | 出版年 | 2014 |
| 53* | 発表者 | Hashizume H , Hata M | | | | |
| | 論文タイトル | J Eur Acad Dermatol Venereol | | | | |
| | 発表誌 | Deep venous thrombosis associated with cytomegalovirus reactivation in drug-induced hypersensitivity syndrome. | | | | |
| | 巻号 | 27 | ページ | 658-659 | 出版年 | 2013 |
| 54* | 発表者 | Hashizume H , Fujiyama T, Kanebayashi J, Kito Y, Hata M, Yagi H | | | | |
| | 論文タイトル | Skin recruitment of monomyeloid precursors involves human herpesvirus-6 reactivation in drug allergy. | | | | |
| | 発表誌 | Allergy | | | | |
| | 巻号 | 68 | ページ | 681-689 | 出版年 | 2013 |

永尾圭介

| | | | | | | |
|----|--------|---|-----|-----------|-----|----------|
| 55 | 発表者 | Watanabe-okada E, Nagao K , <u>Takahashi H</u> , Amagai M, Ohyama M | | | | |
| | 論文タイトル | Immune response involving the bulge region besides telogen conversion contribute to hair loss in a case of atypical drug-induced hypersensitivity syndrome. | | | | |
| | 発表誌 | Journal of Dermatology | | | | |
| | 巻号 | | ページ | | 出版年 | In press |
| 56 | 発表者 | Nishimoto S, Kotani H, Tsuruta S, Shimizu N, Ito M, Shichita T, Morita R, <u>Takahashi H</u> , Amagai M, Yoshimura A | | | | |
| | 論文タイトル | Th17 cells carrying TCR recognizing epidermal autoantigen induce psoriasis-like skin inflammation. | | | | |
| | 発表誌 | J Immunol | | | | |
| | 巻号 | 191(6) | ページ | 3065-3072 | 出版年 | 2013 |

阿部理一郎

| | | | | | | |
|-----|--------|---|-----|---------|-----|------|
| 57* | 発表者 | Saito N, Yoshioka N, Abe R , Qiao H, Fujita Y, Hoshina D, Suto A, Kase S, Kitaichi N, Ozaki M, Shimizu H | | | | |
| | 論文タイトル | Stevens-Johnson syndrome/toxic epidermal necrolysis mouse model generated by using PBMCs and the skin of patients. | | | | |
| | 発表誌 | J Allergy Clin Immunol | | | | |
| | 巻号 | 131(2) | ページ | 434-441 | 出版年 | 2013 |
| 58 | 発表者 | Yoshioka N, Suto A, Abe R , Saito N, Murata J, Hayashi-Ujiie I, Hoshina D, Fujita Y, Shimizu H | | | | |
| | 論文タイトル | Disturbed balance in three subpopulations of CD4(+)Foxp3(+) regulatory T cells in Stevens-Johnson syndrome and toxic epidermal necrolysis patients. | | | | |
| | 発表誌 | Clin Immunol | | | | |
| | 巻号 | 148 | ページ | 89-91 | 出版年 | 2013 |

外園千恵

| | | | | | | |
|-----|--------|---|-----|---------|-----|----------|
| 59 | 発表者 | 外園千恵 | | | | |
| | 論文タイトル | 前眼部の管理 | | | | |
| | 発表誌 | 日本の眼科 | | | | |
| | 巻号 | 84(5) | ページ | 17-22 | 出版年 | 2013 |
| 60 | 発表者 | Watanabe A, Sotozono C , Ueta M, Katsuhiko Shinomiya, Kinoshita S, Kakizaki H, Selva D, FRANZCO F | | | | |
| | 論文タイトル | Folliculitis in Clinically “Quiet” Chronic Stevens-Johnson syndrome. | | | | |
| | 発表誌 | Ophthalmic Plastic and Reconstructive Surgery | | | | |
| | 巻号 | | ページ | | 出版年 | In press |
| 61 | 発表者 | Tohkin M, Kaniwa N, Saito Y, Sugiyama E, Kurose K, Nishikawa J, Hasegawa R, Aihara M, Matsunaga K, Abe M, Furuya H, Takahashi Y, Ikeda H, Muramatsu M, Ueta M, Sotozono C , Kinoshita S, Ikezawa Z | | | | |
| | 論文タイトル | A whole-genome association study of major determinants for allopurinol-related Stevens-Johnson syndrome and toxic epidermal necrolysis in Japanese patients. | | | | |
| | 発表誌 | Pharmacogenomics J | | | | |
| | 巻号 | 13(1) | ページ | 60-69 | 出版年 | 2013 |
| 62* | 発表者 | Sotozono C , Inatomi T, Nakamura T, Koizumi N, Yokoi N, Ueta, M, Matsuyama K, Miyakoda K, Kaneda H, Fukushima M, Kinoshita S | | | | |
| | 論文タイトル | Visual Improvement after Cultivated Oral Mucosal Epithelial Transplantation. | | | | |
| | 発表誌 | Ophthalmol | | | | |
| | 巻号 | 120(1): | ページ | 193-200 | 出版年 | 2013 |
| 63 | 発表者 | Sotozono C , Fukuda M, Ohishi M, Yano K, Origasa H, Saiki Y, Shimomura Y, | | | | |

| | | | | | | |
|-----|--------|--|-----|---------|-----|------|
| | | Kinoshita S | | | | |
| | 論文タイトル | Vancomycin Ophthalmic Ointment 1% for methicillin-resistant Staphylococcus aureus or methicillin-resistant Staphylococcus epidermidis infections: a case series. | | | | |
| | 発表誌 | BMJ Open | | | | |
| | 巻号 | 29;3(1) | ページ | e001206 | 出版年 | 2013 |
| 64* | 発表者 | Isogai H, Miyadera H, Ueta M, Sotozono C , Kinoshita S, Tokunaga K, Hirayama N | | | | |
| | 論文タイトル | In Silico Risk Assessment of HLA-A*02:06-Associated Stevens-Johnson Syndrome and Toxic Epidermal Necrolysis Caused by Cold Medicine Ingredients. | | | | |
| | 発表誌 | J Toxicol | | | | |
| | 巻号 | Oct 12 | ページ | Epub | 出版年 | 2013 |
| 65 | 発表者 | Ueta M, Sotozono C , Yokoi N, Kinoshita S | | | | |
| | 論文タイトル | Rebamipide suppresses PolyI:C-stimulated cytokine production in human conjunctival epithelial cells. | | | | |
| | 発表誌 | J Ocul Pharmacol Ther | | | | |
| | 巻号 | 29(7) | ページ | 688-693 | 出版年 | 2013 |

書籍

塩原哲夫

| | | | | | | | | |
|---|--------|--|-----|----------|-----|---------|-----|------|
| 1 | 著者氏名 | 塩原哲夫 | | | | | | |
| | 論文タイトル | 薬剤による多形滲出性紅斑の最新知見 | | | | | | |
| | 書籍名 | 皮膚科臨床アセット 18 紅斑と痒疹－病態治療の新たな展開 | | | | | | |
| | 編集者名 | 古江増隆, 横関博雄 編 | | | | | | |
| | 出版社 | 中山書店 | 出版地 | 東京 | ページ | 30-38 | 出版年 | 2013 |
| 2 | 著者氏名 | Descamps V, Tohyama M, Kano Y, Shiohara T | | | | | | |
| | 論文タイトル | HHV-6A and HHV-6B in drug-induced hypersensitivity syndrome/drug reaction with eosinophilia and systemic symptoms. | | | | | | |
| | 書籍名 | In: Human herpesviruses HHV-6A, HHV-6B, and HHV-7, Diagnosis and clinical management. 3rd Ed. | | | | | | |
| | 編集者名 | Louis Flamand, Irmeri Lautenschlager, Gerhard R.F.Krueger, Dharam V. Abrashi, eds. | | | | | | |
| | 出版社 | Elsevier | 出版地 | New York | ページ | 179-200 | 出版年 | 2014 |

末木博彦

| | | | | | | | | |
|---|--------|---------------------------------|-----|----|-----|---------|-----|------|
| 3 | 著者氏名 | 末木博彦 | | | | | | |
| | 論文タイトル | テラプレビルの皮膚障害とその対策. | | | | | | |
| | 書籍名 | 皮膚科治療スペシャリティシリーズ 1冊でわかる最新皮膚科治療. | | | | | | |
| | 編集者名 | 五十嵐敦之, ほか 編 | | | | | | |
| | 出版社 | 文光堂 | 出版地 | 東京 | ページ | 116-117 | 出版年 | 2013 |

橋爪秀夫

| | | | | | | | | |
|---|--------|-------------------|-----|----|-----|-----------|-----|------|
| 4 | 著者氏名 | 橋爪秀夫 | | | | | | |
| | 論文タイトル | 薬疹・中毒疹. | | | | | | |
| | 書籍名 | 皮膚疾患トップ20 攻略本 | | | | | | |
| | 編集者名 | 古川福実 編 | | | | | | |
| | 出版社 | 南江堂 | 出版地 | 東京 | ページ | 187-196 | 出版年 | 2013 |
| 5 | 著者氏名 | 橋爪秀夫 | | | | | | |
| | 論文タイトル | 薬疹. | | | | | | |
| | 書籍名 | 今日の治療指針 | | | | | | |
| | 編集者名 | 山口徹, 北原光夫, 福井次矢 編 | | | | | | |
| | 出版社 | 医学書院 | 出版地 | 東京 | ページ | 1041-1042 | 出版年 | 2013 |
| 6 | 著者氏名 | 上田真由美, 外園千恵 | | | | | | |



| | | | | | | | | |
|---|--------|---|-----|----|-----|---------|-----|------|
| | 論文タイトル | Stevens-Johnson 症候群、眼類天疱瘡とドライアイ. | | | | | | |
| | 書籍名 | 専門医のための眼科診療クオリファイ. ⑩ドライアイスペシャリストへの道. | | | | | | |
| | 編集者名 | | | | | | | |
| | 出版社 | 中山書店 | 出版地 | 東京 | ページ | 376-379 | 出版年 | 2013 |
| 7 | 著者氏名 | 上田真由美、外園千恵 | | | | | | |
| | 論文タイトル | 重篤な眼合併症を伴う Stevens-Johnson 症候群ならびに中毒性表皮壊死症. | | | | | | |
| | 書籍名 | 図で早わかり実戦！眼科薬理. 臨床眼科. 2013 年増刊号. Vol.67. No.11 | | | | | | |
| | 編集者名 | | | | | | | |
| 8 | 著者氏名 | 上田真由美、外園千恵 | | | | | | |
| | 論文タイトル | Stevens-Johnson 症候群の眼障害. | | | | | | |
| | 書籍名 | Visual Dermatology . 2013, Vol.12 No.2 | | | | | | |
| | 編集者名 | | | | | | | |
| | 出版社 | 医学書院 | 出版地 | 東京 | ページ | 132-136 | 出版年 | 2013 |
| | 著者氏名 | 上田真由美, 外園千恵 | | | | | | |
| | 論文タイトル | Stevens-Johnson 症候群の眼障害. | | | | | | |
| | 書籍名 | Visual Dermatology . 2013, Vol.12 No.2 | | | | | | |
| 8 | 編集者名 | | | | | | | |
| | 出版社 | 秀潤社 | 出版地 | 東京 | ページ | 172-174 | 出版年 | 2013 |

外園千恵

| | | | | | | | | |
|---|--------|---|-----|----|-----|---------|-----|------|
| 6 | 著者氏名 | 上田真由美, 外園千恵 | | | | | | |
| | 論文タイトル | Stevens-Johnson 症候群、眼類天疱瘡とドライアイ. | | | | | | |
| | 書籍名 | 専門医のための眼科診療クオリファイ. ⑩ドライアイスペシャリストへの道. | | | | | | |
| | 編集者名 | | | | | | | |
| 7 | 出版社 | 中山書店 | 出版地 | 東京 | ページ | 376-379 | 出版年 | 2013 |
| | 著者氏名 | 上田真由美、外園千恵 | | | | | | |
| | 論文タイトル | 重篤な眼合併症を伴う Stevens-Johnson 症候群ならびに中毒性表皮壊死症. | | | | | | |
| | 書籍名 | 図で早わかり実戦！眼科薬理. 臨床眼科. 2013 年増刊号. Vol.67. No.11 | | | | | | |
| 8 | 編集者名 | | | | | | | |
| | 出版社 | 医学書院 | 出版地 | 東京 | ページ | 132-136 | 出版年 | 2013 |
| | 著者氏名 | 上田真由美, 外園千恵 | | | | | | |
| | 論文タイトル | Stevens-Johnson 症候群の眼障害. | | | | | | |
| 8 | 書籍名 | Visual Dermatology . 2013, Vol.12 No.2 | | | | | | |
| | 編集者名 | | | | | | | |
| | 出版社 | 秀潤社 | 出版地 | 東京 | ページ | 172-174 | 出版年 | 2013 |

[VI]

研究成果の刊行物（抜粋）



REVIEW ARTICLE

The role of viral infection in the development of severe drug eruptions



Tetsuo Shiohara*

Department of Dermatology, Kyorin University School of Medicine, Mitaka, Tokyo, Japan

ARTICLE INFO

Article history:

Received: Aug 15, 2013

Revised: Sep 24, 2013

Accepted: Sep 24, 2013

Keywords:

autoimmunity
 drug-induced hypersensitivity syndrome
 Epstein-Barr virus
 herpes viruses
 regulatory T cells

ABSTRACT

The role of viral infections in the development of drug allergy has recently received increasing attention. Evidence is accumulating that immune responses to drugs can be profoundly influenced by herpesvirus infection that occurs before, concurrent with, or subsequent to drug administration. The current advances in our understanding of the role of viral infections in drug eruptions have been sparked by recent studies on human herpesvirus 6 (HHV-6) reactivation in severe systemic hypersensitivity reactions to drugs, eventually referred to as drug-induced hypersensitivity syndrome (DiHS)/drug reaction with eosinophilia and systemic symptoms (DRESS). It becomes clear that HHV-6 is not the only herpes virus reactivated during the course of DiHS and other herpes viruses are also reactivated in sequence as shown in graft-versus-host disease (GVHD), which can explain frequent deterioration or several flare-ups of clinical symptoms occurring after withdrawal of the causative drug in DiHS. Here we describe how sequential reactivations of herpesviruses occur during the course of DiHS and discuss how the reactivation events could influence the initiation and maintenance of drug-specific immune responses, resulting in severe immunopathology.

Copyright © 2013, Taiwanese Dermatological Association.
 Published by Elsevier Taiwan LLC. All rights reserved.

Introduction

The list of drugs causing severe drug eruptions in susceptible individuals is constantly growing and includes hundreds of pharmacologic products. It has long been speculated but not clearly shown that viruses are involved in the development of drug allergy, in particular severe drug eruptions in different ways: for example, prior viral infections could predispose genetically susceptible individuals to the subsequent development of drug allergy.^{1,2} Alternatively, dysregulated immune responses to viruses have also been associated with development and/or pathogenesis of drug eruptions. Thus, circumstantial evidence is accumulating that immune responses to drugs can be profoundly influenced by viral infections that occur before, concurrent with, or subsequent to drug administration.^{1–3} In this regard, herpesviruses are the increasingly recognized pathogens involved in the development of drug eruptions, because they have the ability to infect the majority of the human population, persist in a latent asymptomatic infection in various immune cells for the lifetime of the host, and be reactivated in an immunosuppressive setting; they include Epstein-Barr virus

(EBV), herpes simplex virus (HSV), human herpesvirus 6 (HHV-6), HHV-7, cytomegalovirus (CMV), and varicella-zoster virus (VZV).

In this review, we focus primarily on how herpesvirus infections and dysregulated immune responses to the virus could influence the initiation and maintenance of drug-specific immune responses resulting in severe immunopathology.

Involvement of herpesviruses in drug allergy

A relationship between viral infections and the simultaneous or subsequent development of drug eruptions has been observed in a number of clinical situations. One of the well-known examples is ampicillin rash during infectious mononucleosis (IM), an acute illness which is generally the result of delayed primary infection with EBV and is characterized by pharyngitis, cervical lymphadenopathy, fever, and fatigue (Figure 1).⁴ Although earlier studies reported that most IM patients, once treated with ampicillin, developed extensive maculopapular rashes in the 2nd week after the administration of the drug,⁵ similar rashes have been reported to occur in IM patients who had received other antibiotics, thus indicating that ampicillin is not the sole factor. Because only 10% of patients recovered from IM showed sensitivity to ampicillin and there is a similar prevalence found in the general population, ampicillin rashes during IM are unlikely to be due to a *de novo* induction of drug antigen-specific T cells uniquely generated by

* Professor and Chairman of Dermatology, Kyorin University School of Medicine, 6-20-2 Shinkawa, Mitaka-shi, Tokyo 181-8611, Japan. Tel.: +81 422 47 5511; fax: +81 422 41 4741.

E-mail addresses: tpshio@ks.kyorin-u.ac.jp, tetsuoshiohara@gmail.com.

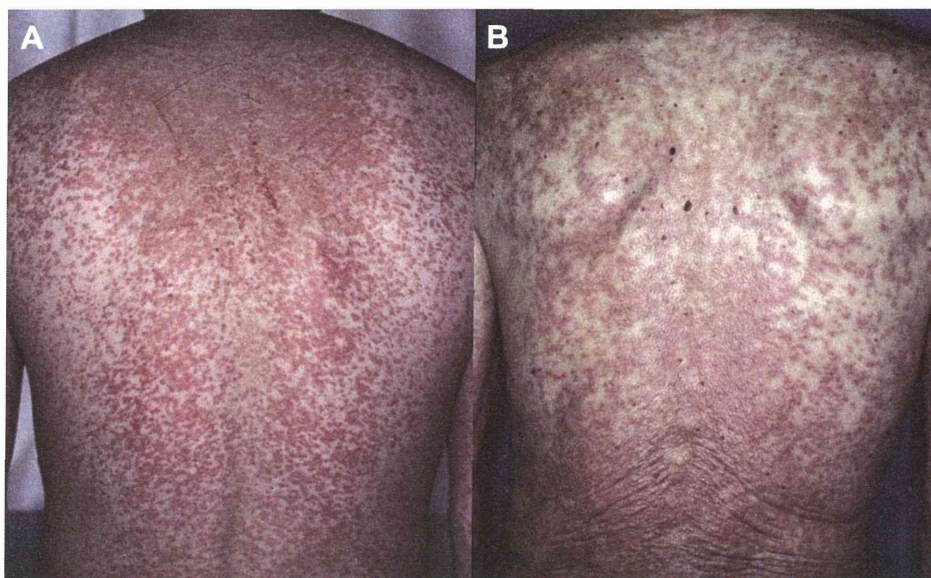


Figure 1 Clinical similarity between ampicillin rash in infectious mononucleosis (A) and drug-induced hypersensitivity syndrome (B).

ampicillin alone in the setting of delayed primary infection with EBV. In view of the observation that large expansions of activated EBV-specific CD8⁺ T cells and increased natural killer (NK) cell numbers are observed during the disease⁴ and that EBV-specific T cells have been shown to cross-react with self-human leukocyte antigen (HLA) alleles of several common HLA-B alleles,^{6,7} preferential development of drug rashes during the disease may be due to a selective expansion of CD8⁺ T cells, which are cross-reactive to the drug, from EBV-specific CD8⁺ T cells already present in large amounts before administration of the drug. Thus, it remains unclear why only a proportion of IM patients develop drug rashes, but it may be related to the attendant release of interleukin (IL) 6, whose level showed correlation with the symptom severity of IM.⁸

Interestingly, the acute symptoms of IM resolve in 2–6 weeks, but relapse can occur in the first 6–12 months following infection,⁸ a finding that can be also observed in a severe systemic hypersensitivity reaction to drug as described later. Given the similarity in sequences of clinical symptoms and clinical manifestations between IM and such a severe systemic hypersensitivity reaction (Figure 1), knowledge on the immune control of primary and persistent herpesvirus infection could be translated into clinical practice contributing to improved patient care in severe drug eruptions.

Severe systemic hypersensitivity reaction associated with herpesvirus reactivation

Fifteen years ago, we⁹ and Dr. Hashimoto's group¹⁰ independently published landmark studies that sparked the current advances in our understanding of the role of viral infections in drug allergy. These initial studies detected HHV-6 DNA by polymerase chain reaction (PCR) in blood and skin specimens from patients with the severe systemic hypersensitivity reaction to drug, eventually referred to as drug-induced hypersensitivity syndrome (DiHS). DiHS, also referred to as drug reaction with eosinophilia with systemic symptoms (DRESS), represents the opposite end of a spectrum of severe drug eruptions. The first description of DiHS is credited to Merritt and Putnam, who in 1938 reviewed the toxic symptoms caused by phenytoin and noted that the symptoms could be divided into two cutaneous reactions, a mild, morbilliform eruption and a severe, exfoliative dermatitis with fever and

eosinophilia.¹¹ Since then, it has become clear that the latter reaction is also associated with lymphadenopathy and multivisceral involvement. Although the latter reaction was recognized as a distinct syndrome in the early 1960s, there has been much debate about the diagnosis and considerable confusion about the name of this syndrome. Although the term DRESS is still widely used to describe the clinical symptoms, we proposed the alternative term 'DiHS' based on a retrospective nationwide survey of patients in Japan^{12,13}: in the survey, HHV-6 reactivations as evidenced by the significant rise in serologic immunoglobulin G (IgG) titers to HHV-6 or the detection of HHV-6 DNA in the blood were detected at a particular time point, 2–3 weeks after the onset of rash in the vast majority of patients regardless of treatment (Figure 2).^{14,15} Based on the survey, a Japanese consensus group named Japanese Research Committee on Severe Cutaneous Adverse Reaction (J-SCAR), established a set of criteria for the diagnosis of DiHS in 2006 (Table 1).¹⁶ The clinical and laboratory features of this syndrome in its florid form are currently well recognized in Japan but there has been debate about the inconsistent and variable terminology in other parts of the world. HHV-6 reactivations can be widely used as a specific and sensitive diagnostic clue in Japan, because they are

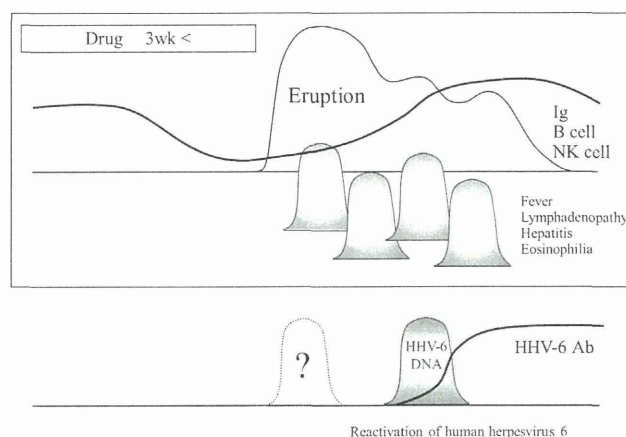


Figure 2 Typical clinical course of drug-induced hypersensitivity syndrome. HHV-6 reactivation occurs 2–3 weeks after onset despite variable clinical symptoms. HHV-6 = human herpesvirus 6.

Table 1 Diagnostic criteria for DiHS established by a Japanese consensus group.¹⁶

1. Maculopapular rash developing >3 weeks after starting with a limited number of drugs
2. Prolonged clinical symptoms after discontinuation of the causative drug
3. Fever (>38°C)
4. Liver abnormalities (ALT > 100 U/L)^a
5. Leukocyte abnormalities (at least one present)
 - a. Leukocytosis (>11 × 10⁹/L)
 - b. Atypical lymphocytosis (>5%)
 - c. Eosinophilia (>1.5 × 10⁹/L)
6. Lymphadenopathy
7. HHV-6 reactivation

Typical DiHS: the diagnosis is confirmed by the presence of the seven criteria above; atypical DiHS: five of the seven.

ALT = alanine aminotransferase; DiHS = drug-induced hypersensitivity syndrome; HHV-6 = human herpesvirus 6.

^a This can be replaced by other organ involvement, such as renal involvement.

rarely detected in a milder form of this syndrome. Nevertheless, the validity has not necessarily been confirmed in other parts of the world, largely due to an extraordinarily low prevalence of this test. In this regard, we investigated whether our definite DiHS cases could fall into the category “probable/definite DRESS” defined by the DRESS validation score Kardraun SH et al proposed.¹⁷ Our results showed that all of the definite DiHS cases associated with HHV-6 reactivations fell into the category “probable/definite DRESS”, although no significant correlation was noted between HHV-6 DNA loads detected in the blood and the DRESS validation score.¹⁸ In considering the rare detection of HHV-6 reactivations in a milder form of DiHS, which could be defined as “probable DRESS”, DRESS could represent a condition ranging from a clinically milder form to a florid form of DiHS. Thus, the DRESS validation score is a useful tool for diagnosis of DiHS/DRESS when HHV-6 tests are unavailable.

DiHS typically occurs with fever and rashes 3 weeks to 3 months after starting therapy with a limited number of drugs, mainly anticonvulsants (Table 2). This delayed onset in relation to the introduction of the causative drug is one of the most important features of this syndrome that can be distinguished from other types of drug eruptions, which usually start 1–2 weeks after starting therapy. Importantly, more severe reactions often occur 3–4 days after withdrawal of the causative drug, while most other milder forms of drug eruptions spontaneously resolve: this paradoxical worsening may be mistaken for severe infectious disease. DiHS has also been reported to occur in patients receiving anticonvulsants for up to 40 years. The maculopapular or erythematous eruptions are initially observed on the face, upper trunk, and upper extremities. The cutaneous eruption usually begins as patchy erythematous macules, which may be slightly pruritic and can become confluent (Figure 1). Most erythematous eruptions do not evolve into blisters and no mucous membrane involvement is usually seen,^{12,14} a finding that can be used to differentiate this syndrome from Stevens-Johnson syndrome (SJS)/toxic epidermal necrolysis (TEN).¹⁹ Fever usually precedes the rash by some or several days and temperature ranges from 38 °C to 40 °C with spikes that usually generate concern regarding an underlying infection.¹⁴ Periorbital and facial edema with pinhead-sized pustules, reminiscent of acute generalized exanthematous pustulosis,

is also one of the characteristic features of early cutaneous lesions in DiHS. Follicular accentuation of the erythematous papules is often observed in the early stage of the rash. The eruption often generalizes into severe exfoliative dermatitis or erythroderma, which usually occurs with continued treatment with the causative drug after this syndrome has developed. Lymphadenopathy can be seen in most patients (>70%), particularly early in the illness, predominantly affecting cervical nodes. Bilateral swelling of the salivary glands with xerostomia has frequently been seen, suggesting reactivation of the mumps virus. These clinical features can often be misdiagnosed as bacterial infection, which may place a substantial burden on physicians to consider unnecessary empirical antibiotic therapy, which may result in the development of additional drug hypersensitivity. This is because patients with DiHS often show unexplained cross-reactivity to multiple drugs with different structures. Other inflammatory conditions that are in the clinical differential diagnoses include measles, IM, Kawasaki syndrome, drug-induced pseudolymphoma, and staphylococcal toxic shock syndrome.²⁰ Variable clinical symptoms, such as liver and renal symptoms, continue to deteriorate one after another, even for weeks after withdrawal of the causative drug.

In most cases, marked leukocytosis with atypical lymphocytosis or eosinophilia of various degrees can often be seen early in the course, although leucopenia or lymphopenia may precede the leukocytosis in some cases. Depending on the drug, involvement of other organs varies: renal involvement is particularly evident in allopurinol-induced DiHS. Interstitial pneumonia with eosinophilia is often observed in patients receiving minocycline.²⁰ Myocarditis may also develop at onset or 40 days after onset: clinical symptoms suggestive of myocarditis include heart failure symptoms such as chest pain, unexplained tachycardia, breathlessness, and low blood pressure early in the course. We also reported a patient with DiHS who developed limbic encephalitis and the syndrome of inappropriate secretion of antidiuretic hormone long after resolution of rashes.²¹ A decrease in serum IgG, IgA, and IgM levels is typically observed at onset and the lowest levels are usually detected a week after withdrawal of the causative drug. Despite such variable clinical presentations, HHV-6 reactivations can be detected at a particular time point, 2–3 weeks after onset of rash in the vast majority of patients regardless of treatment,^{12,14} but not in those with other drug eruptions. Thus, this becomes a gold standard test for identifying patients with DiHS.¹⁶ Nevertheless, it has become clear that HHV-6 was not the only virus reactivated during the course of DiHS. Recently, our studies of real-time measurements for viral loads have demonstrated that other herpesviruses are also reactivated in sequence during the course of DiHS as demonstrated in graft-versus-host diseases (GVHD).^{19,22} According to our sequential analysis of viral loads, the cascade of reactivation events initiated by HHV-6 or EBV would extend, with some delay, to HHV-7 as well, and eventually to CMV (Figure 3). The magnitude of HHV-6 reactivations as evidenced by the increase in HHV-6 DNA levels was correlated well with the severity of inflammatory responses,²³ consistent with the previous observations in GVHD. Thus, frequent deterioration or several flare-ups of clinical symptoms occurring after withdrawal of the causative drug in DiHS patients can be explained by sequential reactivations of various herpesviruses in different organs, which may occur totally independently of that detected in the blood.

Table 2 The causative drugs of drug-induced hypersensitivity syndrome.

| | |
|---------------|---------------------|
| Carbamazepine | Allopurinol |
| Phenytoin | Dapsone |
| Phenobarbital | Salazosulfapyridine |
| Zonisamide | Mexiletine |
| Lamotrigine | Minocycline |

Mechanisms responsible for sequential reactivation of herpesviruses

Could the sequential reactivation of herpesviruses be a mere epiphenomenon of the underlying immunological disturbance in DiHS? In this regard, earlier studies suggested that DiHS represents

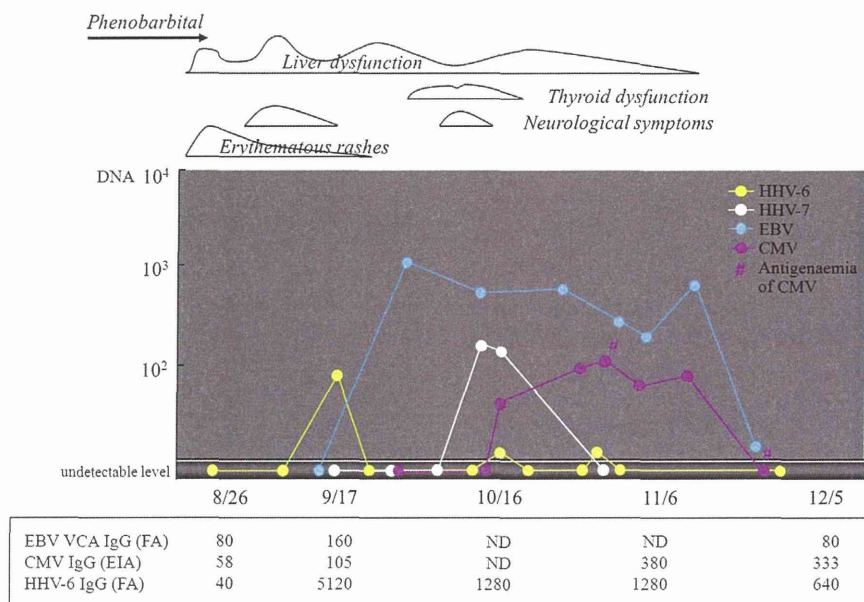


Figure 3 Sequential reactivations of various herpesviruses during the course of drug-induced hypersensitivity syndrome in a representative case. Occurrence of various clinical symptoms coincident with the reactivation of herpesviruses.

an exaggerated, hyperinflammatory response associated with inflammation-induced viral reactivations and subsequent organ injury.¹³ According to this hypothesis, sequential reactivations of herpesviruses could simply be the consequence of drug-induced severe immunopathology and thus not represent a causal factor. Consistent with this view, viral DNA was undetectable at the early phase of DiHS in the blood; indeed, viral DNA levels such as HHV-6 and EBV were undetectable in the vast majority of DiHS patients or low in those few individuals sampled within 7 days after onset. This argues against the idea that viruses and virus-specific CD8⁺ T cells are responsible for drug-induced immunopathology observed in the early phase of DiHS. Given the extraordinarily precursor frequency of drug-reactive T cells at the early phase and the degeneracy of T cell recognition, it is perhaps not surprising that virus-specific T cells become activated following administration of certain drugs, as observed in alloreactive T cells stimulated with viral infections in GVHD.^{24,25} In this regard, Picard et al have recently demonstrated that cutaneous and visceral symptoms of DiHS/DRESS are mediated by activated CD8⁺ effector T (Teff) cells, which are largely directed against herpesviruses such as EBV.³ Their observations suggest the possibility that herpesvirus reactivations triggered by the causative drug is an initiating event that presumably occurs well before patients become symptomatic and thus activation of CD4⁺ and CD8⁺ Teff cells including antiviral Teff and antidrug Teff cells, despite its early appearance after onset, appears to be a secondary event that requires and follows the prior reactivation of herpesviruses. This suggestion would be the opposite of that indicated by earlier studies. If, as suggested here, herpesvirus reactivations represent the actual initiating event in the disease process, it is logical to ask what causes the reactivation events only in susceptible patients receiving the causative drug.

Expansions of regulatory T cells in DiHS

We have recently demonstrated that the clinical phenotype of the severe drug eruptions can be determined when and how regulatory T (Treg) cell function could be impaired: in SJS/TEN, Treg function is profoundly impaired during the acute stage while expansions of functional Treg cells occur in the acute stage of DiHS and the

expanded Treg cells are contracted upon clinical resolution and eventually become functionally defective.²⁶ Various clinical features uniquely observed in DiHS could be explained by the expansions of Treg cells. The frequencies of CD4⁺FoxP3⁺ Treg cells were preferentially increased in the blood of all patients with DiHS at the acute stage before treatment, with a peak median value that was more than three times the baseline value, without affecting their suppressive function. Because the frequencies of Treg cells remained significantly elevated even at 1 week after initial treatment with systemic corticosteroids, expansions of Treg cells are not a universal feature of systemic corticosteroid therapy that improves DiHS. Treg cells were also abundantly detected in skin lesions of DiHS, thereby limiting severe epidermal damage. By contrast, high levels of Treg cells prevent efficient clearance of viral infections by suppressing antiviral immune responses and may allow latent herpesviruses to be reactivated. In view of our preliminary observation that the causative drug has the capacity to expand not only Treg cells, but also Teff cells from DiHS patients after resolution when stimulated the peripheral blood lymphocytes (PBL), Treg cells in DiHS patients would be unique in that they can proliferate in response to relevant drug antigen. Alternatively, other immune cells such as CD16⁺ monocytes, which may inhibit the induction and proliferation of Treg cells, may be defective in function in patients with DiHS. Thus, herpesvirus reactivations probably triggered by expansions of Treg cells are likely to activate polyclonal population of herpesvirus-specific T cells that include those that are both cross-reactive with the causative drug and noncross-reactive.

Long-term outcomes of viral reactivations

It remains unknown whether sequential reactivations of several herpesviruses could be also observed in other severe drug eruptions, and beyond the acute stage of DiHS. Our quantitative analysis of viral loads during a 2-year period after onset revealed persistently elevated EBV loads in patients with SJS during either the acute stage or long after clinical resolution: in many if not all patients with SJS, increased EBV DNA persisted for up to 2 years after onset, regardless of the clinical course and treatment. By contrast, only a fraction of patients with DiHS had increased levels of EBV