

授, 鈴木正章准教授に深謝致します。

本論文の主旨は第 814 回外科集談会(2009 年 9 月 12 日, 東京) および, 第 28 回日本肝移植研究会 (2010 年 7 月 1 日, 広島) において発表した。

#### 文 献

- 1) Zeegen R, Stansfeld AG, Dawson AM, et al. Bleeding oesophageal varices as presenting feature in primary biliary cirrhosis. *Lancet* 1969; II: 9—12
- 2) Abe M, Onji M. Natural history of primary biliary cirrhosis. *Hepato Res* 2008; 38: 639—645
- 3) Murata Y, Abe M, Furukawa S, et al. Clinical features of symptomatic primary biliary cirrhosis initially complicated with esophageal varices. *J Gastroenterol* 2006; 41: 1220—1226
- 4) Jaroch MT, Broughan TA, Hermann RE. The natural history of splenic infarction. *Surgery* 1986; 100: 743—570
- 5) Nores M, Phillips EH, Morgenstern L, et al. The clinical spectrum of splenic infarction. *Am Surg* 1998; 64: 182—188
- 6) Capron JP, Chivrac D, Dupas JL, et al. Massive splenic infarction in cirrhosis: report of a case with spontaneous disappearance of hypersplenism. *Gastroenterology* 1976; 71: 308—310
- 7) Chin JK, McCormick PA, Hilson AJ, et al. Liver/spleen scintigraphy for diagnosis of splenic infarction in cirrhotic patients. *Postgrad Med J* 1993; 69: 715—717
- 8) 湯浅圭一郎, 山田昇司, 植原政弘, 他. 巨大脾梗塞を伴った原発性胆汁性肝硬変の 1 剖検例. *日消誌* 1985 ; 82 : 1591—1595
- 9) Matsui A, Shimada T, Sasaki N, et al. Splenic infarction in a child with portal hypertension secondary to biliary atresia. *J Pediatr Surg* 1997; 32: 648—649
- 10) 小幡 裕, 橋本悦子. 原発性胆汁性肝硬変における肝移植の適応. 「肝移植適応基準」市田文弘, 谷川久一編, 国際医書出版, 東京, 1991, p13—25
- 11) Moore SW, Lewis RJ. Splenic artery aneurysm. *Ann Surg* 1961; 153: 1033—1046
- 12) Stanley JC, Fry WJ. Pathogenesis and clinical significance of splenic artery aneurysms. *Surgery* 1974; 76: 898—909
- 13) Kobori L, van der Kolk MJ, de Jong KP, et al. Splenic artery aneurysms in liver transplant patients. *Liver Transplant Group. J Hepatol* 1997; 27: 890—893
- 14) Ayalon A, Wiesner RH, Perkins JD, et al. Splenic artery aneurysms in liver transplant patients. *Transplantation* 1988; 45: 386—389
- 15) Jacobson IV, Crowe PJ. Splenic infarction: a complication of splenic artery aneurysm. *Aust NZ J Surg* 1994; 64: 53—54
- 16) Olin TB, Reuter SR. Splenic infarction secondary to a splenic artery aneurysm. *Vasc Dis* 1966; 3: 269—272
- 17) Lee PC, Rhee RY, Gordon RY, et al. Management of splenic artery aneurysms: The significance of portal and essential hypertension. *J Am Coll Surg* 1999; 189: 483—490
- 18) Heestand G, Sher L, Lightfoote J, et al. Characteristics and management of splenic artery aneurysm in liver transplant candidates and recipients. *Am Surg* 2003; 69: 933—940
- 19) Yoshizumi T, Taketomi A, Soejima Y, et al. The beneficial role of simultaneous splenectomy in living donor liver transplantation in patients with small-for-size graft. *Transpl Int* 2008; 21: 833—842

## Splenic infarction in a patient with end-stage primary biliary cirrhosis with splenomegaly before living donor liver transplantation: report of a case

Yuko Hara, Yoshiaki Kita\*, Shigeki Wakiyama,  
Takeshi Gocho, Taro Sakamoto, Shoichi Hirohara,  
Yuichi Ishida, Takeyuki Misawa, Katsuhiko Yanaga

Splenic infarcts are not uncommon in conditions with massive splenomegaly due to portal hypertension. A 44-year-old woman with end-stage primary biliary cirrhosis and a splenic artery aneurysm before living donor liver transplantation presented with a sudden onset of left upper quadrant pain with a fever of 39°C. Abdominal CT with contrast enhancement demonstrated a wedge-shaped defect suggestive of infarction in the spleen. One week later, living donor liver transplantation with splenectomy was performed as scheduled. The spleen weighted 1,120 g and demonstrated infarction of the lower pole of the spleen. Histopathological examination of the spleen demonstrated multiple thromboses of small venous and arterial vessels. Splenic infarction should be suspected for left upper quadrant pain and/or signs of inflammation such as fever in patient with known congestive splenomegaly.

**Key words:** splenic infarction    primary biliary cirrhosis    splenomegaly  
living donor liver transplantation

*Kanzo* 2011; 52: 36—41

---

Department of Surgery, The Jikei University School of Medicine

\*Corresponding author: kita@jikei.ac.jp

---

© 2011 The Japan Society of Hepatology

## Modified hanging method for liver resection

Tohru Utsunomiya · Mitsuo Shimada

Published online: 21 September 2011

© Japanese Society of Hepato-Biliary-Pancreatic Surgery and Springer 2011

**Abstract** The liver hanging maneuver (LHM) is a useful technique to transect the liver parenchyma while lifting it with a tape passed between the anterior surface of the inferior vena cava (IVC) and the liver parenchyma. The original method was employed mostly for right hepatectomy with an “anterior approach” for huge liver tumors. The tape serves as a guide to the transection plane and facilitates the control of bleeding in the deeper parenchyma of the liver while protecting the anterior surface of the IVC. On the other hand, several recent studies have shown the feasibility and usefulness of modified LHM techniques. These methods can be applied to left hepatectomy with or without caudate lobectomy (segmentectomy 1), even for patients undergoing orthotopic liver transplantation. This report explains the methods and pitfalls of the original and modified LHM. In addition, important anatomical and technical aspects of the mobilization of hepatic lobes are also included.

**Keywords** Hanging tape · Tunneling · Avascular thin route · Modified technique · Mobilization

### Introduction

The liver hanging maneuver (LHM) introduced by Belghiti et al. [1] is a technique to transect the liver parenchyma

---

This article is based on studies first reported in *Highly Advanced Surgery for Hepato-Biliary-Pancreatic Field* (in Japanese), Tokyo: Igaku-Shoin, 2010.

---

T. Utsunomiya (✉) · M. Shimada  
Department of Surgery, The University of Tokushima,  
13-18-15 Kuramoto-cho, Tokushima 770-8503, Japan  
e-mail: utsunomiya@clin.med.tokushima-u.ac.jp

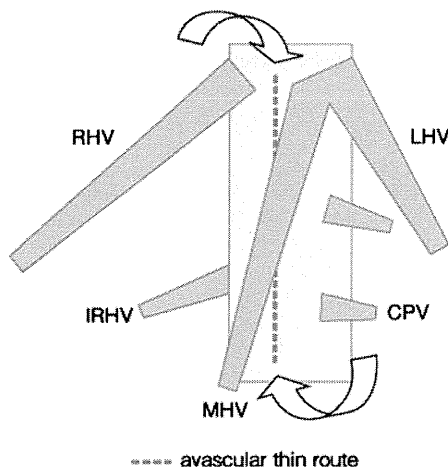
while lifting it with a piece of tape passed between the anterior surface of the inferior vena cava (IVC) and the liver parenchyma. This technique is usually used for right hepatectomy with an “anterior approach” for a large liver tumor. Upward pressure on the tape provides a direct linear plane during parenchymal division and facilitates the exposure and hemostasis of the deeper parenchymal plane in front of the IVC. Recently, various kinds of modified techniques, including an application to left hepatectomy, have been reported. This report explains the techniques and the pitfalls of two commonly used techniques for hepatectomy, the original and the modified LHM, and mobilization of the hepatic lobe.

### Liver hanging maneuver

#### Original and modified techniques

A hanging tape is passed through an avascular thin route on the midline of the anterior surface of the infra-hepatic portion of the IVC without any mobilization of the right liver (Fig. 1). The space between the right hepatic vein (RHV) and middle hepatic vein (MHV) is first dissected 2 cm downward. The dissection of the caudal portion starts with a long Kelly clamp posterior to the caudate lobe, proceeding cranially with great care along the middle plane of the IVC. The clamp appears between the RHV and MHV after 4–6 cm of blind dissection. It is important to confirm whether there are thick short hepatic veins or a right inferior hepatic vein by preoperative computed tomography and intraoperative ultrasonography [2].

This technique helps maintain a flat transection plane even at the deeper portion of the liver parenchyma. It also provides adequate hemostasis because the liver is lifted



**Fig. 1** Dissection of the anterior surface of the inferior vena cava (IVC). An avascular thin route is situated on the midline of the anterior surface of the infra-hepatic portion of the IVC up to the space between the trunk of the right and middle hepatic veins. *CPV* Caudate process veins, *IRHV* inferior right hepatic vein, *LHV* left hepatic vein, *MHV* middle hepatic vein, *RHV* right hepatic vein

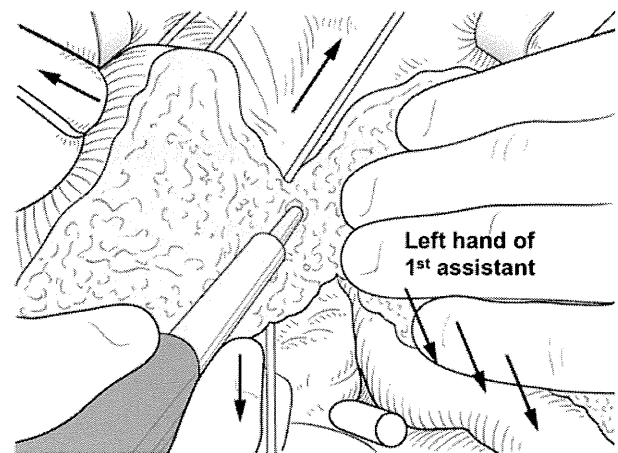
upward from the IVC. The surgeon's assistant applies counter traction with the left hand to maintain a good surgical view, and facilitate the parenchymal dissection of the deeper plane (Fig. 2).

The LHM can be applied to the left lobectomy with or without caudate lobectomy (segmentectomy 1) and central bisegmentectomy as a modified LHM [3–6]. It is also applied for extended left lobectomy by passing the lower end of the tape through the dorsal side of the left hepatic lobe, and placing it on the ventral side of the hilar plate (Fig. 3). Left lobectomy requires repositioning of the hanging tape from between the RHV and the MHV to between the MHV and the left hepatic vein (LHV). This technique provides a flat parenchymal dissection plane even for caudate lobe-preserving left lobectomy and right lobectomy combined with caudate lobectomy (segmentectomy 1).

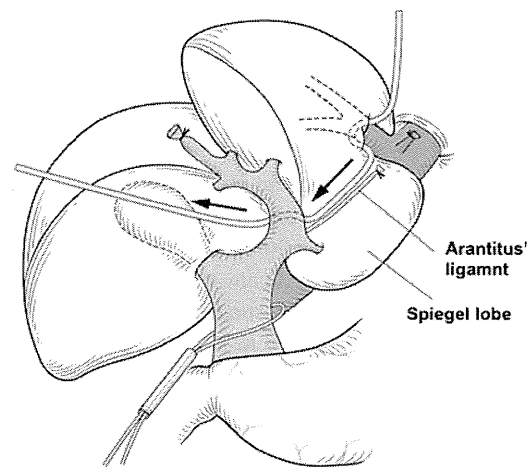
#### Anatomical view of short hepatic veins and IVC for LHM

Most of the confluences between the short hepatic veins and the IVC are on the right or left side of the IVC. Therefore, it is relatively safe to pass a long Kelly clamp through the midline of the anterior surface of the infra-hepatic portion of the IVC [1]. A cotton tape lifts the liver parenchyma for dissection, especially during the latter steps of liver dissection.

It is very important to avoid any forced movement of the tip of the Kelly clamp when resistance is encountered during the dissection of the anterior surface of the IVC. The clamp is inserted toward the 11 o'clock position (slightly left-sided plane) and short hepatic veins are rarely



**Fig. 2** Transection of the deeper parenchymal plane. Counter traction with the left hand of the first assistant facilitates parenchymal dissection



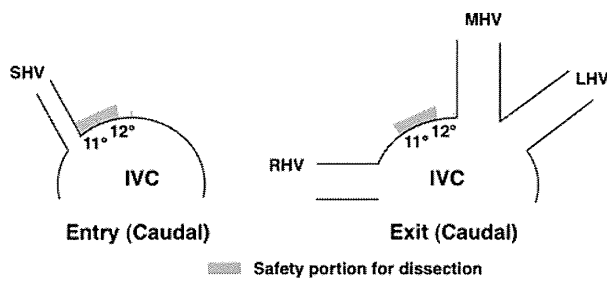
**Fig. 3** Modified liver hanging maneuver. The liver hanging maneuver can also be applied to left lobectomy and right lobectomy combined with caudate lobectomy by repositioning the hanging tape from between the right hepatic vein and middle hepatic vein to between the middle hepatic vein and left hepatic vein. The lower end of the tape is passed between the right and left Glisson's pedicles

encountered at this position (Fig. 4). However, extreme caution is still required for this procedure even when this route is selected. This procedure can be performed after mobilization of the right lobe and isolation of the RHV when the dissection is difficult.

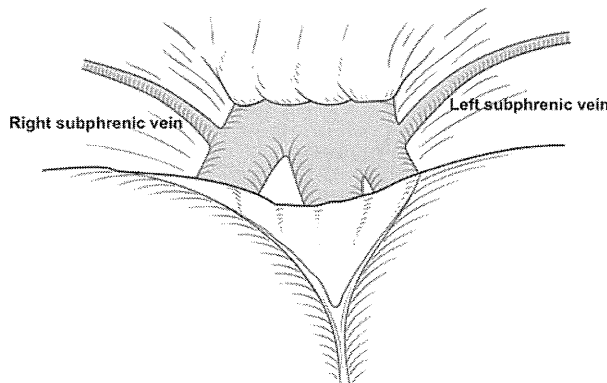
#### Mobilization of the hepatic lobes

##### Mobilization of the suprahepatic portion

The surgeon and the first assistant pull the liver in the caudal direction with folded gauze on the liver surface. The



**Fig. 4** Indication of the region which may be safe for dissection of the anterior surface of the inferior vena cava (IVC). SHV Short hepatic vein, LHV left hepatic vein, MHV middle hepatic vein, RHV right hepatic vein



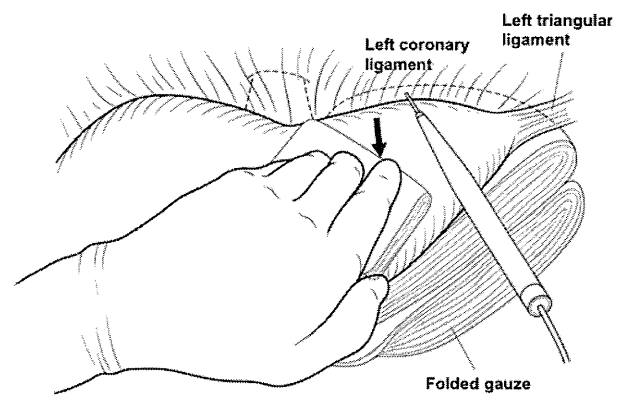
**Fig. 5** Anatomy around the roots of the hepatic veins in the suprahepatic space. The confluences of the right hepatic vein and the common trunk of the middle and left hepatic veins to the inferior vena cava are exposed by dissecting the coronary ligament

confluence of the RHV and the common trunk of the MHV and LHV with the IVC are exposed after dissecting the coronary ligament. The right subphrenic vein, which connects with the right side of the root of the RHV, can be a landmark to identify the site of caval insertion of the RHV (Fig. 5).

Shrinkage of the coronary ligament may be encountered during a second hepatectomy because of the adhesions in the suprahepatic space if the coronary ligament had been dissected in the previous operation. Special attention should also be given to the possible existence of hepatic veins on a relatively shallow plane under these conditions.

**Mobilization of the left hepatic lobe**

The left coronary and triangular ligaments are dissected. Folded gauze sheets are placed between the lateral segment of the liver and other organs, including the esophagus, stomach, and spleen. The surgeon pulls the liver caudally with the folded gauze placed on the liver surface. The left coronary ligament is dissected by electrocautery while



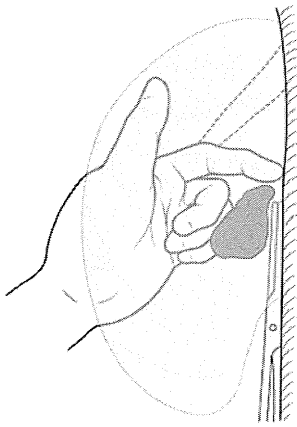
**Fig. 6** Dissection of the left coronary and triangular ligaments. The left coronary and triangular ligaments are dissected while visualizing the folded gauze (arrow) placed behind the lateral segment, which can be seen through the ligaments

visualizing the gauze, which can be seen through the ligament. These precautions prevent injury to the other organs (Fig. 6). The left triangular ligament is ligated and divided if it contains thick vessels, but it can usually be divided by electrocautery or a vessel-sealing system, such as Ligasure™.

**Mobilization of the right hepatic lobe**

The hepatorenal ligament is dissected by electrocautery from the IVC to the right triangular ligament while the surgeon pulls the right lobe cranially with the left hand. The right hepatic lobe is medially mobilized until the right adrenal gland is exposed by dividing the right coronary and triangular ligaments. The division of the whole ligaments around the right lobe is completed, and the loose connective tissue between the liver and the right diaphragm is exposed. This portion is the so-called “bare area”, and it can be divided by electrocautery along the surface of the liver. The anterior surface of the IVC is then cranially dissected starting from the infra-hepatic portion of the IVC, and several short hepatic veins are ligated and divided. The stump on the liver side is simply ligated for the division of short hepatic veins, while the stump on the IVC side is secured by Z-sutures using 5-0 monofilament polydioxanone suture.

The cranial side of the right adrenal gland is sufficiently exposed, and a Kelly clamp is gently and securely inserted between the right adrenal gland and the liver. The location of the tip of the clamp is confirmed by the surgeon’s left index finger placed on the caudal portion of the right adrenal gland (Fig. 7). The edge of the right adrenal gland is clamped with a vascular clamp, divided, and the stump on the liver side is ligated while the stump on the IVC side is covered by over-and-over running sutures using 4-0



**Fig. 7** Dissection of the right adrenal gland. A Kelly clamp is inserted along the right wall of the inferior vena cava between the right adrenal gland and the liver. The location of the tip of the clamp is confirmed by the surgeon's left index finger, which is placed on the caudal portion of the right adrenal gland

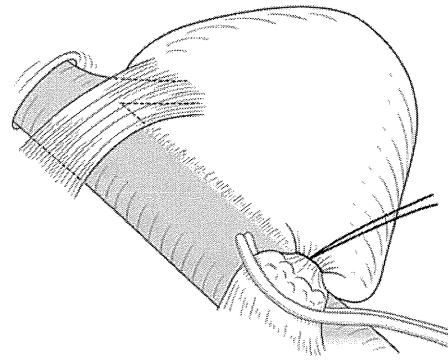
monofilament polydioxanone suture (Fig. 8). The IVC ligament is also divided and is secured by over-and-over running sutures using 4-0 or 5-0 monofilament polydioxanone suture. It is essential to obtain an adequate surgical field for a stress-free operation. The safe mobilization of the right hepatic lobe requires an adequate surgical field and the role of the first assistant is very important (Fig. 9).

#### Dos and Don'ts

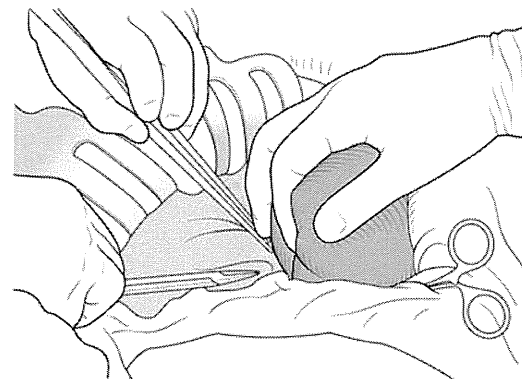
1. The tip of the Kelly clamp that is used to dissect the anterior surface of the IVC is advanced toward the 11 o'clock position.
2. Insertion and movement of the clamp by force should be strictly avoided if there is resistance on the tip (even if it is very weak).
3. Dissection between the liver and the right adrenal gland should be performed only after sufficiently exposing the cranial side of the right adrenal gland.

#### Experience of a potentially serious error

A patient with metastatic liver tumors underwent a right hepatectomy. The liver appeared to be normal, and the operation seemed to be progressing uneventfully without difficulties. A Kelly clamp was inserted along the anterior surface of the IVC toward the surgeon's left index finger, which was placed between the roots of the RHV and the MHV. The tip of the clamp moved cranially with faint resistance, and it reached the dorsal side of the left index finger. However, the tip of the clamp had damaged a short hepatic vein, and was unexpectedly inserted into the IVC. The mobilization of the right hepatic lobe was performed



**Fig. 8** Dissection of the right adrenal gland. This procedure can be accompanied by massive bleeding. The edge of the right adrenal gland is clamped with a vascular clamp, divided, and the stump is secured by over-and-over running sutures of 4-0 monofilament polydioxanone suture



**Fig. 9** Mobilization of the right hepatic lobe. An adequate surgical field created by the first assistant provides a stress-free operation

while the tip of clamp was left in place. The location of the injury site was confirmed from the right side, and then the hole was sutured. This accident demonstrates that the clamp should not be inserted by force if there is any resistance on the tip (even if it is very slight).

#### Modified liver hanging maneuver

The LHM has been modified, and is frequently used during hepatic resections other than a right hepatectomy. This method has been used for left hepatectomy without caudate lobectomy (segmentectomy 1) and extended right hepatectomy with caudate lobectomy (segmentectomy 1). The procedure includes the mobilization of the left lobe, and dissection behind the common trunk of the MHV and LHV. The upper end of the hanging tape is repositioned from between the RHV and MHV to between the MHV and LHV. The lower end of the tape is pulled caudally along the ligamentum venosum and passed between the right and left Glisson's pedicles.

### Tape for liver hanging maneuver

A nasogastric tube, Penrose tube, or umbilical tape is usually used as a tape for the LHM. A retrograde transhepatic biliary drainage tube is also used because the tip of this tube is atraumatic, and can be inserted cranially and advanced directly toward a space between the RHV and MHV.

### Discussion

The LHM has become an accepted surgical technique, as it enables an “anterior approach”, which reduces several risks caused by liver mobilization, such as bleeding, rupture of the tumor, and hemodynamic instability. In particular, for patients with huge liver tumors, this technique is preferred not only technically but also for prevention of tumor cell dissemination. The feasibility of this maneuver was reported to be 94%. An absolute contraindication for the LHM is tumor infiltration into the retrohepatic avascular space. Adhesions between the IVC and the liver have a negative impact on the feasibility of this technique. According to this indication, the LHM is easily achievable without risk of major bleeding during retrohepatic dissection [7]. More recently, various modified methods have also been developed for use in other kinds of hepatectomy with some advantages of the original LHM, such as left hepatectomy and caudate lobe resection for hilar bile duct cancer [3–6]. This technique has also been used in donor operations for living donor liver transplantation, where a hepatic parenchymal transection should be performed before dividing the feeding vessels for the graft [8]. The most important and technically difficult step of this technique is the dissection of the anterior plane of the IVC. However, a significant technical improvement has been achieved with an effort to minimize the length of the blind dissection [7]. In addition, it is noteworthy that intraoperative ultrasound may enable a safer and technically easier retrohepatic dissection to be performed [2].

**Conflict of interest** The authors declare that they have no conflict of interest.

### Appendix: Important points

1. Confirmation of the roots of hepatic veins: The falciform ligament is divided before mobilizing the hepatic lobes, the subphrenic serosa and connective tissues are dissected approximately 5 cm toward both the right and left sides, and the roots of the three hepatic veins are exposed.
2. Dissection of the coronary and triangular ligaments: Folded gauze is placed behind the lateral segment of the liver before dissecting the left coronary ligament. The left coronary and triangular ligaments are dissected while visualizing the gauze, which can be seen through the ligaments. These precautions prevent injury to the esophagus, stomach, and upper portion of the spleen.
3. Dissection of the anterior surface of the inferior vena cava (IVC): It is important to insert a long light curved Kelly clamp in the proper direction, and advance it toward the space between the right hepatic vein (RHV) and middle hepatic vein (MHV) while the anterior surface of the infra-hepatic portion of the IVC is dissected. The Kelly clamp is inserted through the avascular thin route (middle plane) of the anterior surface of the IVC in the 11 o'clock position (slightly left-sided plane), especially at the cranial site. It is important to strictly avoid forcing the clamp insertion if there is any resistance on the tip (even if it is only very slight).
4. Confirmation of the location of short hepatic veins using ultrasonography: Careful confirmation that there is no short hepatic vein using ultrasonography may help to prevent any unexpected injury to the short hepatic veins during the dissection of the anterior surface of the IVC.
5. Division between the right hepatic lobe and right adrenal gland: The surgeon may use the digital finger (cranial side) and thumb (dorsal side) to confirm that a small amount of connective tissue is left around the right adrenal gland following the mobilization of the right hepatic lobe. A clamp is cranially inserted between the liver and right adrenal gland toward the surgeon's left index finger placed on the cranial side of the right adrenal gland.
6. Dissection of short hepatic veins: Dissection of the short hepatic veins should be performed very carefully to ensure that there is sufficient length for ligation and division. The stump on the liver side is simply ligated while the stump on the IVC side is secured by Z-sutures using 5-0 monofilament polydioxanone suture.

### References

1. Belghiti J, Guevara OA, Noun R, Saldinger PF, Kianmanesh R. Liver hanging maneuver: a safe approach to right hepatectomy without liver mobilization. *J Am Coll Surg*. 2001;193:109–11.
2. Kokudo N, Imamura H, Sano K, Zhang K, Hasegawa K, Sugawara Y, et al. Ultrasonically assisted retrohepatic dissection for a liver hanging maneuver. *Ann Surg*. 2005;242:651–4.
3. Ettore GM, Vennarecci G, Boschetto A, Douard R, Santoro E. Feasibility of hanging maneuvers in orthotopic liver transplantation

- with inferior vena cava preservation and in liver surgery. *J Hepatobiliary Pancreat Surg.* 2004;11:155–8.
4. Kim SH, Park SJ, Lee SA, Lee WJ, Park JW, Hong EK, et al. Various liver resections using hanging maneuver by three glisson's pedicles and three hepatic veins. *Ann Surg.* 2007;245:201–5.
  5. Hwang S, Lee SG, Lee YJ, Kim KH, Ahn CS, Kim KW, et al. Modified liver hanging maneuver to facilitate left hepatectomy and caudate lobe resection for hilar bile duct cancer. *J Gastrointest Surg.* 2008;12:1288–92.
  6. Nanashima A, Sumida Y, Abo T, Nonaka T, Sengyoku H, Sawai T, et al. Resection of segments 4, 5 and 8 for a cystic liver tumor using the double liver hanging maneuver. *Case Rep Gastroenterol.* 2008;2:60–6.
  7. Ogata S, Belghiti J, Varma D, Sommacale D, Maeda A, Dondero F, et al. Two hundred liver hanging maneuvers for major hepatectomy: a single-center experience. *Ann Surg.* 2007;245: 31–5.
  8. Kokudo N, Sugawara Y, Imamura H, Sano K, Makuuchi M. Sling suspension of the liver in donor operation: a gradual tape-repositioning technique. *Transplantation.* 2003;76:803–7.



## A modified liver-hanging maneuver focusing on the ligamentum venosum for left hepatic lobectomy

Satoru Imura · Mitsuo Shimada · Tohru Utsunomiya ·  
Yuji Morine · Tetsuya Ikemoto · Hiroki Mori ·  
Jun Hanaoka · Hiroki Ishibashi · Hidenori Miyake

Received: 20 April 2011 / Accepted: 13 June 2011  
© Springer 2011

### Abstract

**Purpose** The liver-hanging maneuver (LHM) is a useful technique in major hepatectomy. We made modifications to this technique with special reference to the ligamentum venosum for performing a left hepatectomy (LH). The aim of this study was to clarify the usefulness of our new technique.

**Methods** Between August 2007 and May 2009, five patients underwent LH using our modified LHM and 12 patients underwent LH using a conventional procedure. The two groups were compared in terms of the patient characteristics, preoperative hepatic functions, surgical records, and outcomes.

**Results** The characteristics and preoperative hepatic function tests were similar between the modified LHM and non-LHM groups. Intraoperative blood loss was significantly reduced in the modified LHM group compared with the non-LHM group ( $193 \pm 133$  vs.  $375 \pm 167$  ml,  $P < 0.05$ ). The lengths of the operations and time required to perform a parenchymal transection did not differ significantly between the two groups (duration of operations  $273 \pm 37$  vs.  $337 \pm 70$  min; transection times  $29 \pm 10$  vs.  $28 \pm 13$  min). The postoperative complications and hospital stays did not differ significantly between the two groups.

**Conclusion** Our modified LHM can reduce the intraoperative blood loss during LH, and our results have shown the usefulness of this modified technique for LH.

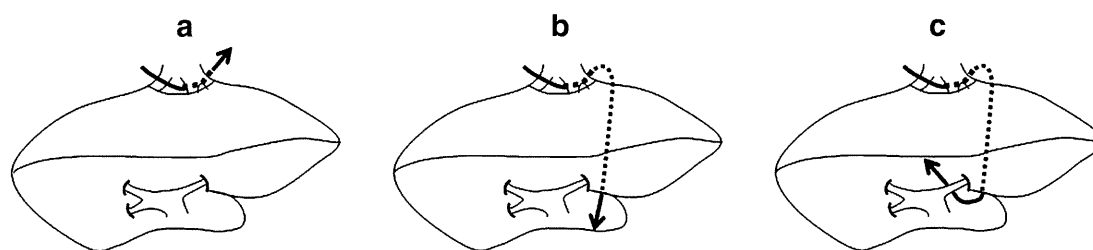
**Keywords** Left hepatic lobectomy · Liver-hanging maneuver · Ligamentum venosum

### Introduction

Initially described in 2001 by Belghiti et al. [1], the liver-hanging maneuver (LHM) uses a tape passed between the anterior surface of the inferior vena cava (IVC) and the liver parenchyma, and is commonly applied for right hepatectomy. The purpose of the LHM is to control bleeding at the deeper parenchymal plane during right hepatectomy without liver mobilization. The LHM is useful in difficult major right hepatectomies, especially those requiring the so-called anterior approach described by Lai et al., or in donor operations for living donor liver transplantation, in which a hepatic parenchymal transection needs to be performed before dividing the feeding vessels for the graft [2–4]. The LHM technique also has potential advantages in terms of a shortened operation, reduced malignant dissemination, improved remnant liver mobilization and function, better surgical exposure, transection, and hemostasis, and safer IVC protection [3, 5–10].

Since the first report of the LHM, various modifications to this procedure have been tried and reported, such as a technique applied to isolated caudate lobectomy and a tape-repositioning technique for donor operations [3, 7]. We herein introduce a procedure for left hepatic lobectomy without the caudate lobe using a modified LHM that can simplify the procedure and standardize liver surgery, and evaluate the usefulness of our new technique.

S. Imura · M. Shimada (✉) · T. Utsunomiya · Y. Morine ·  
T. Ikemoto · H. Mori · J. Hanaoka · H. Ishibashi · H. Miyake  
Department of Surgery, Institute of Health Biosciences,  
The University of Tokushima,  
3-18-15 Kuramoto-cho,  
Tokushima 770-8503, Japan  
e-mail: mshimada@clin.med.tokushima-u.ac.jp



**Fig. 1** Preparation of the modified liver-hanging maneuver (LHM). **a, b** A tape is placed along the ligamentum venosum between the caudate lobe and the left lateral segment and passed through the space

behind the common trunk of the middle hepatic vein and left hepatic vein. **c** The lower end of the tape is pulled up to the ventral side of the hilar plate

## Patients and methods

### Patients

Between August 2007 and May 2009, five patients underwent left hepatectomy (LH) using the modified LHM and 12 patients underwent LH using a conventional procedure. The two groups were compared in terms of the patient characteristics, preoperative hepatic functions, surgical records, and outcomes.

### Surgical procedures

#### *Dissection of the left Glissonean pedicle at the hepatic hilum*

The liver was exposed through an inverted L-shaped abdominal incision or a Benz incision. If there were no difficulties or problems, we usually perform Glissonean pedicle transection at the hepatic hilum during a hemihepatectomy. After cholecystectomy, hilar dissection was performed to free the right and left Glissonean pedicles. In caudate lobe-preserving left hepatic lobectomy, the left Glissonean pedicle was dissected at the distal level, and the caudal branches were diverged. The left Glissonean pedicle was dissected at the upper level of the lesser omentum in cases of caudate-preserving left hepatic lobectomy. The left Glissonean pedicle was encircled with a vinyl tape and clamped at that time. The falciform ligament was divided along the anterior surface of the liver, and the anterior surface of the suprahepatic IVC was exposed. The space between the right hepatic vein (RHV) and the middle hepatic vein (MHV) was blindly dissected in the downward direction for 2–3 cm using a finger in the caudal direction.

#### Modified LHM

The lesser omentum was divided to include an aberrant left hepatic artery originating from the left gastric artery, if present. After mobilizing the left lateral segment, the ligamentum venosum, which indicated the Arantius duct, was

ligated and divided near the root of the left hepatic vein (LHV). A careful dissection behind the common trunk of the MHV and LHV was performed using a curved clamp, and the hepatic veins were taped. Dissection around the common trunk was then easily accomplished by pulling the cranial stump of the divided ligamentum venosum. A cotton tape was placed along the ligamentum venosum between the caudate lobe and the left lateral segment through the space behind the common trunk of the MHV and LHV. The lower end of the tape was then pulled up to the ventral side of the hilar plate between the encircled left Glissonean pedicle and the liver (Fig. 1). During a left hepatic lobectomy without the MHV, the upper end of the tape was switched from the right to the left side of the MHV.

#### Left hepatectomy without the caudate lobe

The left Glissonean pedicle was divided using a mechanical stapler at the previously encircled level. A parenchymal dissection was routinely performed using a Cavitron Ultrasonic Surgical Aspirator (CUSA; Valleylab, Boulder, CA, USA) and electrocautery under intermittent hepatic inflow control. Almost all vessels of less than 5 mm in diameter that presented at the cut surface were divided using vessel-sealing devices such as a LigaSure (Valleylab). At the stage of the deeper parenchymal dissection, countertraction was applied continuously to the hanging tape by pulling both ends of the tape. This maneuver contributed to the reduction of bleeding by venous backflow and to keeping the transection plane dry. The other merit of this method was the ability to obtain and maintain a flat cutting plane instead of a curved plane. Finally the LHV, with or without the MHV, was divided using a mechanical stapler, and the left hepatic lobectomy was successfully completed.

#### Statistical analysis

All data are presented as the mean  $\pm$  SEM unless otherwise stated. Correlations, which were represented as scatter plots, were analyzed using the Pearson test (JMP 8.0.1.;

**Table 1** Patients' characteristics and preoperative liver function test results

Variable	Modified LHM	Non-LHM	<i>P</i> value
Age (years)	65.6 ± 15.0	68.5 ± 9.3	NS
Male/female	5/0	8/4	0.139
Tumor			
Benign/HCC/IHCC/meta	1/2/1/1	2/2/4/4	NS
Child–Pugh classification			
A/B	5/0	12/0	NS
Preoperative liver function			
Albumin (g/dl)	4.2 ± 0.43	3.8 ± 0.44	0.108
Total bilirubin (mg/dl)	0.76 ± 0.17	0.83 ± 0.33	NS
ICGR <sub>15</sub> (%)	10.0 ± 4.1	14.4 ± 8.4	NS

Data are the mean ± standard deviation with ranges in parentheses or numbers with percentages in parentheses, unless otherwise indicated. *LHM* liver-hanging maneuver, *HCC* hepatocellular carcinoma, *IHCC* intrahepatic cholangiocarcinoma, *ICGR<sub>15</sub>* indocyanine green retention rate at 15 min, *NS* not significant

**Table 2** Surgical details of the LHM

Parameter	Modified LHM	Non-LHM	<i>P</i> value
Blood loss (ml)	193 ± 133	375 ± 167	0.047
Length of surgery (min) <sup>a</sup>	273 ± 37	337 ± 70	0.104
Time of parenchymal transection (min)	29 ± 10	28 ± 13	NS

<sup>a</sup> Donor operation (*n* = 1) excluded

SAS Campus Drive, Cary, NC, USA). Values of *P* < 0.05 were considered to indicate statistical significance.

## Results

Table 1 shows the characteristics and comparisons of the modified LHM and non-LHM left hemihepatectomy groups. The patients in both groups were similar with regard to age and sex. Comparisons of the background liver function tests and liver tumor variables also showed no significant differences between the groups.

The surgical data of the patients in both groups are summarized in Table 2. The amount of intraoperative blood loss was significantly lower in the modified LHM group than in the non-LHM group (193 ± 133 vs. 375 ± 167 ml, *P* < 0.05). The duration of the operations and times required for parenchymal transection did not differ significantly between the groups (duration of operation 273 ± 37 vs. 337 ± 70 min; transection time 29 ± 10 vs. 28 ± 13 min).

Table 3 shows the data regarding postoperative complications. The incidence of bile leakage did not differ

**Table 3** Postoperative complications

Parameter	Modified LHM	Non-LHM	<i>P</i> value
Bile leak (yes/no)	¼	2/10	NS
Uncontrolled ascites (yes/no)	0/5	1/11	NS
Hepatic failure (yes/no)	0/5	0/12	NS
Duration of hospital stay (days) <sup>a</sup>	19.8 (8.0, 34.0)	26.4 (16.5, 31.0)	NS

<sup>a</sup> Median (25th, 75th percentile)

between the two groups. Hepatic failure was not observed in either group. The lengths of the postoperative hospital stay did not differ significantly between the two groups (19.8 vs. 26.4 days).

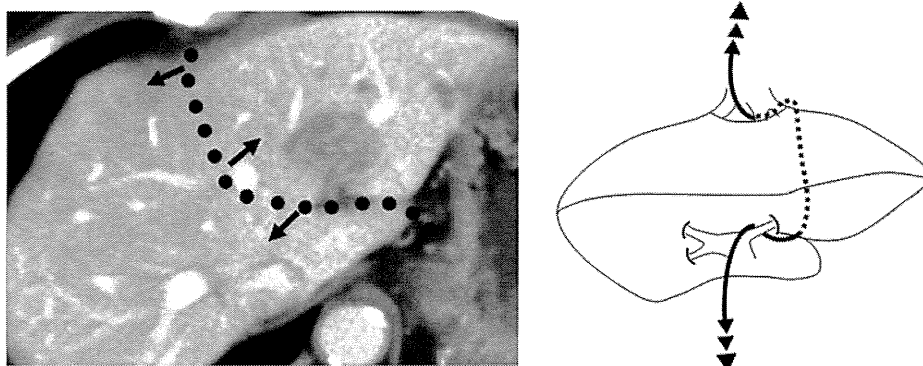
## Discussion

In general, the LHM offers several advantages for major hepatic resection: (1) it provides a straight transection plane from the anterior surface to the deeper area of the liver; and (2) lifting of the tape pulls the liver up and provides better exposure for hemostasis of the transection surface [1, 3].

Tape-guided major hepatectomy is feasible in some situations, not only for left hepatic lobectomy without the caudate lobe but also for right hepatic lobectomy with the caudate lobe, which has almost the same transection plane. The most important technical point for left hepatic lobectomy without the caudate lobe is considered to be that the transection plane should be curved toward the left ligamentum venosum, which lies along the border between the left lateral lobe and the caudate lobe. Using the LHM, the deep part of the parenchymal transection plane is lifted ventrally to obtain a flat cutting plane, instead of a curved plane (Fig. 2). Another merit of this procedure is that the tape placed along the ligamentum venosum serves as a landmark for the dissection at the late stage of the parenchymal transection. This procedure also provides better exposure of the hepatic transection surface to facilitate the hemostasis. In this study, although the lengths of the operations and times required for parenchymal transection did not differ significantly between the two groups, the amount of intraoperative blood loss was significantly lower in the modified LHM group than in the non-LHM group.

Nanashima et al. [5] reported that a shorter time was required for hepatic parenchymal transection in an LHM group compared with a control group treated with a conventional procedure. They proposed that the possible reasons for their results were as follows: (1) dissection of the

**Fig. 2** Photograph and drawing of LHM taken during a left hepatic lobectomy without the caudate lobe. Using the LHM technique, a flat cutting plane can be obtained for transection, instead of a curved plane



liver parenchyma was more easily and rapidly performed by parenchymal compression using the LHM; (2) dissection of the parenchyma in a deeper area could be performed without hesitation, while avoiding injury to the vena cava or short hepatic veins because of the shield provided by the covering tube; and (3) the surgeon could always target the tube position during the transection, allowing for an adequate transection plane to be obtained without hesitation regarding the direction of the transection.

To date, we have performed a left hepatic lobectomy without the caudate lobe using this procedure in five patients, including a living left liver donor operation. This technique is considered to be effective, especially for donor hepatectomy, in which the parenchymal transection should be completed just before dividing the portal veins. In our series, although the times for the parenchymal transection were similar between the modified LHM and conventional LHM groups, the amount of intraoperative blood loss during the donor operation was less than 250 ml using the modified LHM.

Our modified LHM includes two important techniques, namely, encircling of the Glissonean pedicle at the hepatic hilus and encircling of the common trunk of the MHV and LHV to place the tape for the LHM. Although these procedures are somewhat difficult, they remain basic techniques in liver surgery. We have not experienced any intraoperative complications related to these procedures.

Although the number of cases is still small to date, left hepatic lobectomy without the caudate lobe using our modified LHM appears to be a safe and feasible procedure that does not require special equipment or extensive experience. In conclusion, we have shown the usefulness and suitability of our modified LHM for left hepatic lobectomy without the caudate lobe. Use of the modified LHM

contributes to a reduction in the intraoperative blood loss, without the development of postoperative complications.

**Conflict of interest** All authors declare that they have no conflict of interest.

## References

1. Belghiti J, Guevara OA, Noun R, Saldinger PF, Kianmanesh R. Liver hanging maneuver: a safe approach to right hepatectomy without liver mobilization. *Am Coll Surg.* 2001;193:109–11.
2. Lai EC, Fan ST, Lo CM, Chu KM, Liu CL. Anterior approach for difficult major right hepatectomy. *World J Surg.* 1996;20:314–7.
3. Kokudo N, Sugawara Y, Imamura H, Sano K, Makuuchi M. Sling suspension of the liver in donor operation: a gradual tape repositioning technique. *Transplantation.* 2003;76:803–7.
4. Takatsuki M, Kawashita Y, Eguchi S, Tajima Y, Kanematsu T. Tape-guided living donor left hepatectomy. *Am J Surg.* 2007;194:107–9.
5. Nanashima A, Sumida Y, Abo T, Nagayasu T, Sawai T. Usefulness and application of the liver hanging maneuver for anatomical liver resections. *World J Surg.* 2008;32:2070–6.
6. Hwang S, Lee SG, Lee YJ, Kim KH, Ahn CS, Kim KW, et al. Modified liver hanging maneuver to facilitate left hepatectomy and caudate lobe resection for hilar bile duct cancer. *J Gastrointest Surg.* 2008;12:1288–92.
7. Kim SH, Park SJ, Lee SA, Lee WJ, Park JW, Kim CM. Isolated caudate lobectomy using the hanging maneuver. *Surgery.* 2006;139:847–50.
8. Ogata S, Belghiti J, Varma D, Sommaccalle D, Maeda A, Dondero F, et al. Two hundred liver hanging maneuvers for major hepatectomy. *Ann Surg.* 2007;245:31–5.
9. Kim SH, Park SJ, Lee SA, Lee WJ, Park JW, Hong EK, et al. Various liver resections using hanging maneuver by three Glisson's pedicles and three hepatic veins. *Ann Surg.* 2007;245:201–5.
10. Akamatsu N, Sugawara Y, Shin N, Ishida T, Shirakawa K, Ozawa F, et al. Modified liver-hanging maneuver designed to minimize blood loss during hepatic parenchymal transection in hemihepatectomy. *Surg Today.* 2010;40(3):239–44.

## Beneficial Effects of Follistatin in Hepatic Ischemia-Reperfusion Injuries in Rats

Mami Kanamoto · Mitsuo Shimada · Yuji Morine ·  
Tomoharu Yoshizumi · Satoru Imura · Toru Ikegami ·  
Hiroki Mori · Yusuke Arakawa

Received: 12 April 2010 / Accepted: 12 August 2010 / Published online: 8 September 2010  
© Springer Science+Business Media, LLC 2010

### Abstract

**Background** Ischemia-reperfusion injury has been demonstrated in a variety of clinical settings. The morbidity associated with liver transplantation and major hepatic resections is partly a result of ischemia-reperfusion injury. Follistatin, an activin-binding protein, binds to activins and subsequently blocks their action. It was reported that blockade of the action of activin with administration of follistatin accelerates recovery from ischemia renal injury. This study was conducted to investigate the involvement of the activin–follistatin system in hepatic ischemia-reperfusion injury.

**Methods** Total hepatic ischemia for 30 min was performed followed by reperfusion in a rat model. Rats were

divided into two groups: a follistatin group and a control group. Follistatin (1 µg/body), which is an activin-binding protein, was administered at the time of reperfusion.

**Results** Though 80% of animals survived in the follistatin group, four of five animals died in the control group within 3 days after reperfusion ( $p < 0.05$ ). AST was significantly lower at 3 h after reperfusion in the follistatin group ( $p < 0.05$ ). LDH was also lower at 6 h after reperfusion in the follistatin group ( $p < 0.05$ ). Follistatin inhibited the mRNA expression of the  $\beta$ A subunit of activin. Moreover, the expression of IL-6, which is an inflammatory cytokine, was suppressed at 6 h after reperfusion in the follistatin group ( $p < 0.05$ ).

**Conclusions** The present study demonstrated that treatment with follistatin reduced the expression of IL-6 and activin resulting in beneficial support for hepatic ischemia-reperfusion injuries.

M. Kanamoto · M. Shimada (✉) · Y. Morine · T. Yoshizumi ·  
S. Imura · T. Ikegami · H. Mori · Y. Arakawa  
Department of Surgery, Institute of Health Biosciences,  
The University of Tokushima Graduate School, 3-18-15,  
Kuramoto, Tokushima 770-8503, Japan  
e-mail: mshimada@clin.med.tokushima-u.ac.jp

M. Kanamoto  
e-mail: kanamoto@clin.med.tokushima-u.ac.jp

Y. Morine  
e-mail: ymorine@clin.med.tokushima-u.ac.jp

T. Yoshizumi  
e-mail: yosizumi@surg2.med.kyushu-u.ac.jp

S. Imura  
e-mail: s-imura@clin.med.tokushima-u.ac.jp

T. Ikegami  
e-mail: Ikegami@clin.med.tokushima-u.ac.jp

H. Mori  
e-mail: morihiroki@clin.med.tokushima-u.ac.jp

Y. Arakawa  
e-mail: yarakawa@clin.med.tokushima-u.ac.jp

**Keywords** Hepatic ischemia-reperfusion injury ·  
Follistatin · Activin · Cytokine

### Introduction

Ischemia-reperfusion injury (I/R) has been demonstrated in a variety of clinical settings, such as in a myocardial infarction [1], stroke [2], and organ transplantation [3]. The possible consequences of injury caused by I/R include both primary organ failure and/or secondary multi-organ system failure that eventually lead to mortality [4]. Moreover, I/R injuries to the liver are of clinical importance in humans after hemorrhagic and cardiogenic shock, liver surgery, or liver transplantation [5]. Hepatic ischemia-reperfusion injury is a complex, multifactorial pathophysiologic process. In the early stages of reperfusion, endothelial cell

swelling, vasoconstriction, leukocyte entrapment, and platelet aggregation within the sinusoids result in failure of the microcirculation. Consequently, activation of nuclear factor- $\kappa$ B in the liver promotes proinflammatory cytokine and adhesion molecule synthesis. These reactions cause oxygen-derived free-radical production and neutrophil recruitment, further contributing to cellular injury. Many studies have been carried out to understand the underlying mechanisms and sequences in an attempt to determine an ideal treatment for the prevention of both primary and secondary tissue injuries caused by ischemia reperfusion [4].

Follistatin is an activin-binding protein. This protein stoichiometrically binds to activins and blocks their action. Follistatin is expressed on the surface of the target cells of activins by binding to the extracellular matrix. Activins are members of the transforming growth factor- $\beta$  (TGF- $\beta$ ) supergene family [6, 7]. Among them, activin A, which is a homodimer  $\beta$ A subunit of activin, is an autocrine growth inhibitor produced in hepatocytes and tonically inhibits proliferation of hepatocytes [8, 9]. After partial hepatectomy, the expression of the  $\beta$ A subunit of activin abruptly drops [9, 10]. The expression of the  $\beta$ A subunit then increases gradually at 12–24 h after hepatectomy and remains elevated until the liver regeneration is terminated. The actions of activins are modified at several levels by various factors. Activins trapped by follistatin are internalized by endocytosis and subsequently degraded by proteolysis. It was reported that follistatin induces immediate deoxyribonucleic acid (DNA) synthesis in the remnant livers of 90% hepatectomized rat [11].

It was reported that blockade of the action of activin with administration of follistatin accelerates recovery from ischemia renal injury by accelerating regeneration after ischemia [12]. Activin was reported to support neuronal survival or neural differentiation in stroke injury [13]. However, there are no reports about the effect of follistatin on hepatic ischemia-reperfusion injuries. Therefore, in this study we evaluated the role of follistatin on hepatic ischemia-reperfusion injuries.

## Materials and Methods

### Animals

Male Wistar rats (180–220 g, Charles River Inc., Japan) were used after 7 days of acclimation to the animal room. The animals were allowed free access to water and standard laboratory chow ad libitum. They were fasted for 12 h before surgical procedure. The present study was conducted in compliance with the Division for Animal Research Resources, Institute of Health Biosciences, the

University of Tokushima. The experiments and procedures were approved by the Animal Care and Use Committee of the University of Tokushima.

### Experimental Operation Procedure of Ischemia-Reperfusion Model

The animals were randomly divided into two groups: a follistatin group ( $n = 31$ ) and a control group ( $n = 31$ ). The animals were anesthetized by inhalation with diethyl ether. A midline incision was made and the liver exposed. Total hepatic ischemia was induced by clamping the hepatoduodenal ligament. After 30 min of total hepatic ischemia, the clamp was removed to initiate hepatic reperfusion. At the indicated times (0, 3, 6, 12, and 24 h) after reperfusion, animals were killed ( $n = 5$  each) for collection of serum and liver tissue.

### Administration of Follistatin

After total hepatic ischemia and reperfusion, the cecum was washed out from the peritoneal cavity and the ileocolic vein was stretched. In the follistatin group, 1 mg of recombinant human follistatin, as in the previous study, dissolved in 0.5 ml of physiological saline, was infused into the portal vein via the ileocolic vein. The same volume of saline was infused in the control group [8, 14]. As previously described, a significant amount of recombinant human follistatin remained in the liver after intravenous infusion [8].

### Survival Study

Six rats in the each group were used for the survival study. Rats that had lived for more than 4 days after reperfusion were considered to be survivors.

### Histological Analysis

Liver tissue was fixed in 10% neutral buffered formalin, embedded in paraffin, and cut serially into 5- $\mu$ m sections. The hematoxylin and eosin (H&E)-stained sections were evaluated at 200 $\times$  magnification.

### Biochemical Analysis

To evaluate the liver injury at each time point, the levels of serum aspartate aminotransferase (AST), serum alanine aminotransferase (ALT), and lactate dehydrogenase (LDH) were measured using the Japan Society of Clinical Chemistry standardization matching method. All measurements were performed by Shikoku Chuken, Inc. Kagawa, Japan.

RT-PCR for IL-6, IL-10, Activin  $\beta$ A, and Activin  $\beta$ C

At each time after reperfusion, the messenger ribonucleic acid (mRNA) expression levels of interleukin-6 (IL-6), IL-10, activin  $\beta$ A, and activin  $\beta$ C were evaluated by reverse transcriptase-polymerase chain reaction (RT-PCR). Total ribonucleic acid (RNA) was extracted from 30 mg of rat liver tissue using RNeasy Mini Kit (QIAGEN, Hilden, Germany). The amount of purified RNA was measured by ultraviolet (UV) spectroscopy at 260 nm, and its purity was determined by calculating the ratio of absorbance at 260/280 nm. Using 1  $\mu$ g of total RNA isolated from each sample, synthesis of complementary deoxyribonucleic acid (cDNA) was carried out with M-MLV reverse transcriptase (Promega Co., Madison, WI). RT reactions were conducted in the presence of 25 pmol/ $\mu$ l random hexamer, RT 5  $\times$  reaction buffer, 2.5 mM dNTP Mix (GeneACT, Inc., Kurume, Japan), RNase inhibitor (Promega Co., Madison, WI), and reverse transcriptase in a final volume of 20  $\mu$ l; reactions were conducted at 42°C for 60 min. PCR was carried out in the final volume of 20  $\mu$ l containing 2  $\mu$ l of cDNA, 1  $\times$  PCR buffer containing 20 mM of MgCl<sub>2</sub> (Roche Applied Science, Basel, Switzerland), 2.5 mM of dNTP mix (GeneACT, Inc., Kurume, Japan), each specific primers and 1 unit of FastStart Taq DNA polymerase (Roche Applied Science, Basel, Switzerland). PCR was performed under the conditions shown in Table 1. PCR products were separated and stained in 2% agarose gels mixed ethidium bromide solution (10 mg/ml). After the electrophoresis and photographing, the data were analyzed using the public-domain ImageJ software (Version 1.34; developed at U.S. National Institutes of Health).

## Statistical Analysis

All results were expressed as mean values  $\pm$  standard deviations (SD). Comparisons between the two groups were performed with Student's *t* test, Mann–Whitney *U* test, or log-rank test for survival. Survival rate between groups of animals was compared using the log-rank test for comparison of survival curves. A *p* value of less than 0.05 was considered statistically significant.

**Table 1** Sequence of synthetic oligonucleotide primers and expected fragment sizes of PCR products in the rat

Gene	Primer sequence	Size (bp)
IL-6	5'-GAG GAT ACC ACC CAC ACC AGA CCA GTA-3'	525
	5'-GGT TTG CCG AGT AGA CCT CAT AGT GAC-3'	
IL-10	5'-TGC CTT CAG TCA AGT GAA GAC-3'	346
	5'-AAA CTC ATT CAT GGC CTT GTA-3'	
Activin $\beta$ A	5'-GAG AGG AGT GAA CTG TTG CT-3'	605
	5'-TAC AGC ATG GAC ATG GGT CT-3'	
Activin $\beta$ C	5'-CCA TAT GAC ACC AAC CTC ACC-3'	543
	5'-GAC AAT GTT GCT GTC CCT GTC-3'	

## Results

## Survival of Animals

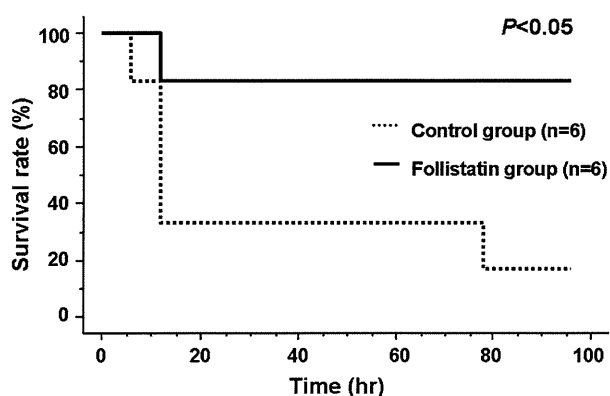
Four days after the experimental operation, the survival rate was significantly better in the follistatin group compared to the control group ( $n = 6$  each) (Fig. 1). Four of six died in the control group within 12 h after reperfusion. The survival rates 1 week after reperfusion were 17% in control group and 82% in the follistatin group.

## Effects of Follistatin on Hepatocellular Injury Induced by Ischemia Reperfusion

Hepatocellular injury was evaluated by measuring the liver enzymes (AST, ALT, and LDH). In the follistatin group, AST at 3 h, ALT at 3 h, and LDH at 3 h after reperfusion showed a significantly decrease in follistatin group compared to the levels in the control group ( $1,004 \pm 320$  vs.  $2,689 \pm 1225$ ;  $p < 0.05$ ,  $558 \pm 116$  vs.  $2,118 \pm 1,193$ ;  $p < 0.05$ ,  $5,730 \pm 2,178$  vs.  $11,325 \pm 3,105$ ;  $p < 0.05$ ) (Fig. 2). AST at 6 h and LDH at 6 h after the reperfusion tended to be lower in the follistatin group than the control group ( $1,231 \pm 226$  vs.  $1,617 \pm 349$ ;  $p < 0.1$ ,  $2,472 \pm 1,661$  vs.  $8,393 \pm 5,840$ ;  $p < 0.1$ ). This suggests that follistatin may protect hepatocellular injury in the early phase of ischemia reperfusion.

## Histological Assessment of Ischemia-Reperfusion Injury

In the control group, hepatocellular ballooning was shown in the peri-central area followed by 3, 6, and 12 h of reperfusion (Fig. 3a–c). In the follistatin group, the occurrence of hepatocellular ballooning in the peri-portal area was reduced compared to the control group followed by 3, 6, and 12 h of reperfusion (Fig. 3e–g). In the control group, hepatocellular necroses were shown in peri-central area at 3 and 6 h after reperfusion. At 12 h after reperfusion, the necrotic area was increased and shown in peri-central area (Fig. 3d). On the other hand, almost normal structures were shown in the follistatin group after 12 h of



**Fig. 1** Survival after ischemia reperfusion. Five of six animals in the control group died during 3 days after reperfusion, whereas survival significantly improved in the follistatin group

reperfusion (Fig. 3h). The extent of the necrosis was significantly reduced in the follistatin group at 12 h after reperfusion (Fig. 3i).

#### Cytokine Response

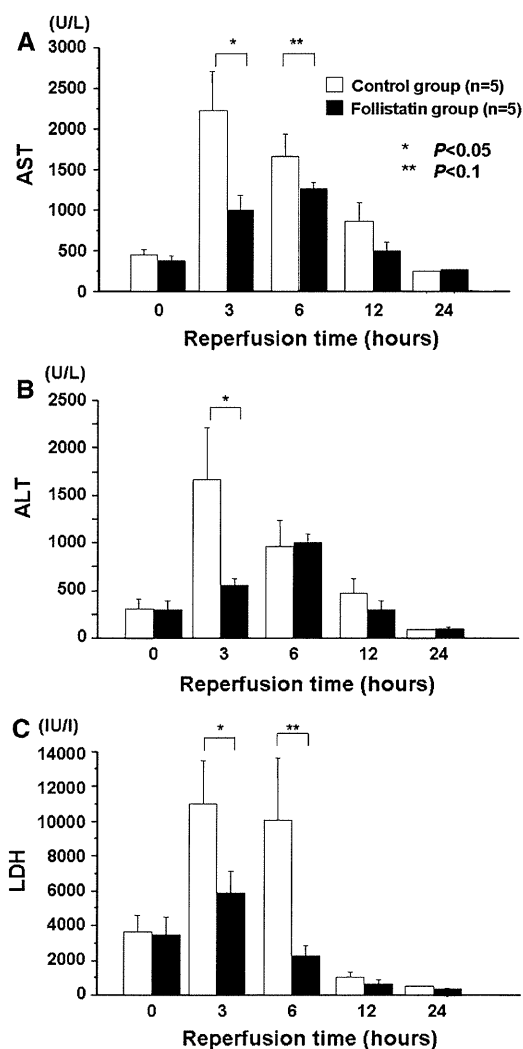
The highest expression of IL-6 was observed at 6 h after reperfusion in the control group (Fig. 4a). Administration of follistatin significantly reduced the IL-6 response at 6 h after reperfusion ( $0.075 \pm 0.025$  vs.  $0.926 \pm 0.336$ ;  $p < 0.05$ ). After 12 h of reperfusion, there was no significant difference in IL-6 between the two groups. The levels of IL-10, which is an anti-inflammatory cytokine, increased at 6 h after reperfusion in both groups, but there were no significant differences between the two groups (Fig. 4b).

#### Expression of Activin Subunits

Expression of the  $\beta A$  subunit of activin was significantly reduced at 6 h after reperfusion in the follistatin group ( $0.344 \pm 0.204$  vs.  $0.841 \pm 0.206$ ;  $p < 0.05$ ) (Fig. 5a). However, the expression of the  $\beta C$  subunit of activin showed no significant difference in two groups after 12 h reperfusion. The mRNA expression of the  $\beta C$  subunit of activin showed no significant difference due to administration of follistatin (Fig. 5b).

#### Discussion

Ischemia-reperfusion injury of the liver is clinically relevant in hepatic resectional surgery, live transplantation, and hemorrhagic shock [5]. In the present study, we examined the effects of follistatin on liver ischemia-reperfusion injury. The overall results demonstrate that administration of follistatin reduces the liver damage caused by ischemia



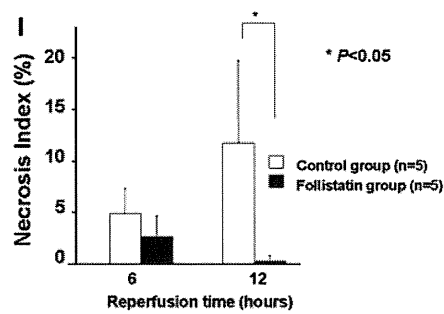
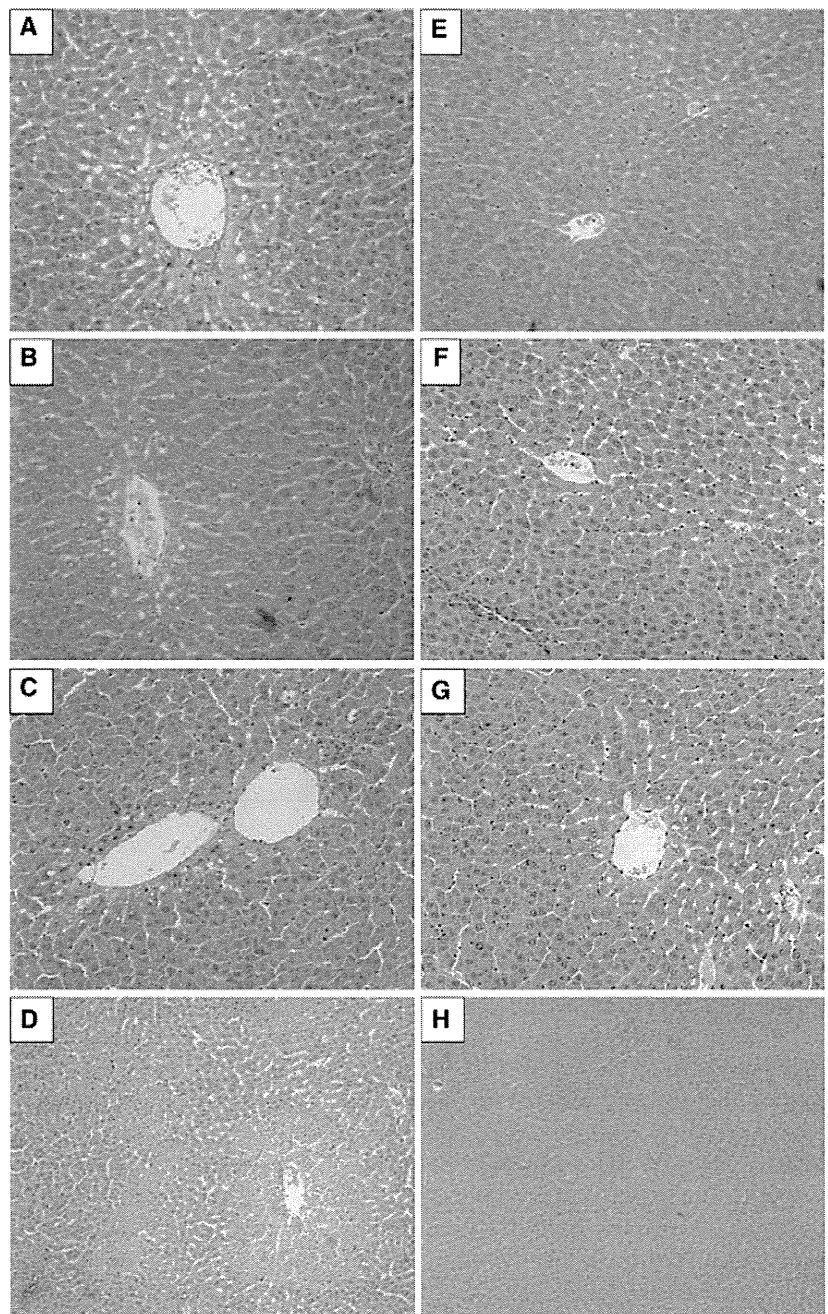
**Fig. 2** Inhibition of hepatic enzyme release. Rats were given infusion of follistatin (black bar) or saline solution (white bar) at the time of reperfusion. Serum aspartate aminotransferase (AST) levels (a), serum alanine aminotransferase (ALT) levels (b), and lactate dehydrogenase (LDH) levels (c), were measured at the indicated time points. Values are mean  $\pm$  SEM, \* $p < 0.05$ , \*\* $p < 0.1$  versus saline solution

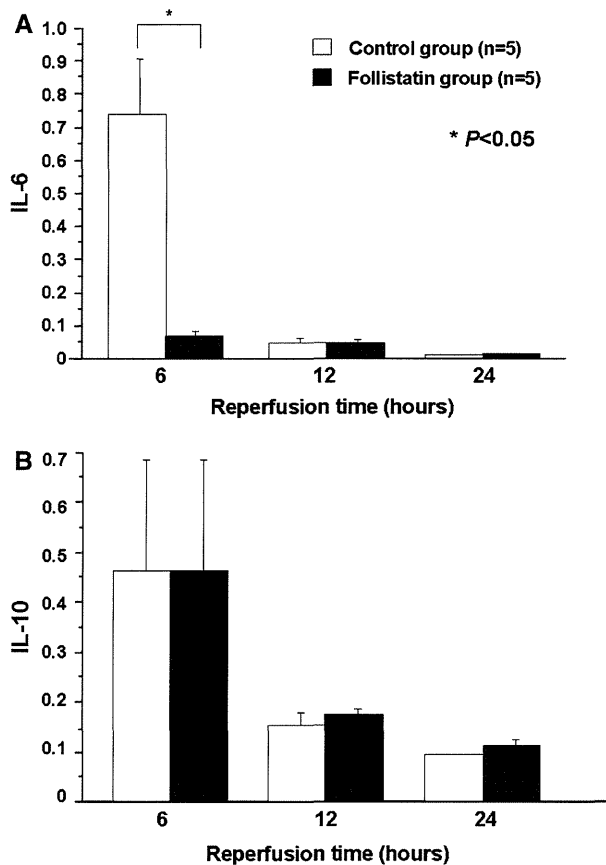
reperfusion with a resultant improvement of survival. This is the first study that examines the role of follistatin in liver ischemia-reperfusion injuries, though the number of animals included in this study was relatively small.

Activin A is an autocrine-negative regulator of DNA synthesis in hepatocytes. In addition, activin A also regulates the functions of non-parenchymal cells. For example, activin A augments tubulogenesis of sinusoidal endothelial cells, and the collagen production in hepatic stellate cells is stimulated by activin A. This is an important role of activin A because reconstruction of the hepatic sinusoid is critical for the reorganization of the liver architecture during liver



**Fig. 3** Histology of the liver after ischemia reperfusion. Liver specimens were obtained and H&E staining was performed for 3, 6, 12 h reperfusion in the control group (a–c photographs are at 100× magnification) and in the follistatin group (e–g photographs are at 100× magnification). d, h H&E-stained histology for 12 h reperfusion in the control group and the follistatin group (photographs are at 200× magnification). i Necrosis index was calculated. Results were expressed as the ratio of the necrotic area to the whole area in high-power fields (200× magnification)

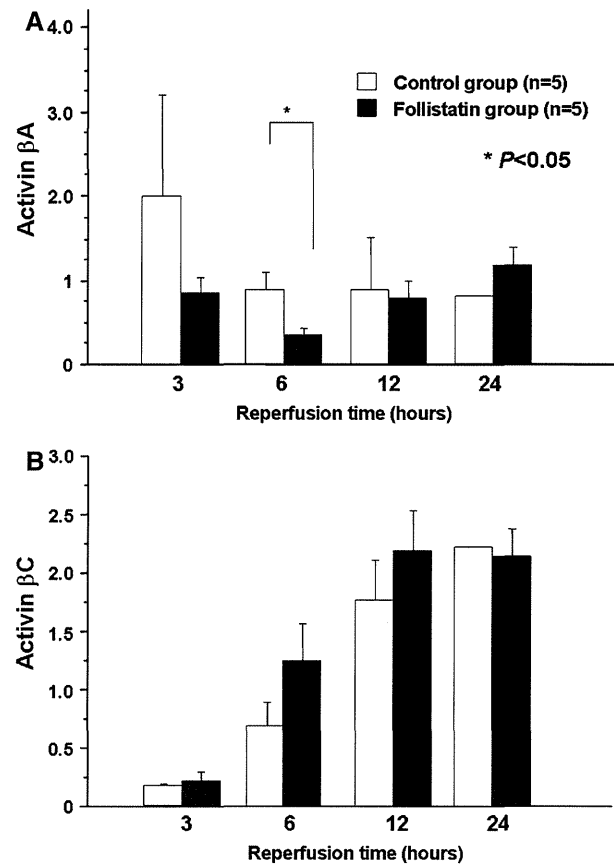




**Fig. 4** Effect of follistatin to ischemia reperfusion on expressions of cytokines

regeneration. Blockade of activin action by administration of follistatin accelerates liver regeneration after partial hepatectomy [8, 9]. In ischemia-reperfusion injury, it was reported that TGF- $\beta_1$  protects the heart from ischemia-reperfusion injury. TGF- $\beta$  inhibits tumor necrosis factor- $\alpha$  (TNF- $\alpha$ ) release and improve endothelium-dependent relaxation, and preserve of reactive oxygen species (ROS) generation. Moreover, TGF- $\beta$  suppresses expression of Matrix metalloproteinase-9 (MMP-9) and MMP-12 in monocytes and macrophages induced by cytokines, such as IL-1 $\beta$  and TNF- $\alpha$ , results in the protection of myocardium from the adverse effects of ischemia reperfusion and improvement of cardiac function. In cerebral ischemia-reperfusion injury, it was reported that activin protects neurons from ROS induced toxicity. On the other hand, in renal ischemia reperfusion, levels of mRNA for the  $\beta A$  subunit of activin were up-regulated at 12 h after ischemia [5]. Maeshima et al. reported that follistatin accelerated renal regeneration and attenuated histological changes and improved renal function in renal ischemia [12].

In this study, we examined the effects of administration of follistatin on hepatic ischemia-reperfusion injury. The



**Fig. 5** mRNA changes after ischemia reperfusion. Quantitative real-time PCR reveals an increase in mRNA for **a** activin  $\beta A$  subunit and **b** activin  $\beta C$  subunit. Values are mean  $\pm$  SEM, \* $p$  < 0.05, \*\* $p$  < 0.01 vs. saline solution

present study showed that the administration of follistatin down-regulated mRNA for  $\beta A$  subunit of activin and improved the liver function and survival rate. These results suggested that the acceleration of regeneration induced by exogenous follistatin after ischemia-reperfusion injury resulted in the beneficial effects in hepatic ischemia reperfusion.

Inflammation is also considered to be one of the most important causes of tissue injury in organs subjected to ischemia. Recent studies have suggested a novel role for activin in inflammation and repair processes in various organs [14–17]. For example, increased expression of activin was observed in various types of inflammatory processes, including cutaneous wound repair and inflammatory arthropathies. The level of activin expression correlated with the degree of inflammation in inflammatory bowel disease. Strong expression of activin A was induced in vitro by proinflammatory cytokines such as interleukin-1 and tumor necrosis factor- $\alpha$  (TNF- $\alpha$ ), which are known to be released from macrophages and stromal cells at the sites of tissue injury and inflammation [18]. Therefore,

proinflammatory cytokines are possible inducers of activin expression in this model. Regarding the action mechanism of activin, the release of activin into the circulation precedes the release of proinflammatory cytokines after lipopolysaccharide (LPS) treatment, suggesting a proinflammatory action of activin [16]. Activin A is released into the circulation at very acute phase in response to LPS. Activin A is capable of stimulating the production of the pro-inflammatory cytokines TNF- $\alpha$  and IL-1 $\beta$ . It was reported that administration of follistatin decreased releases of TNF- $\alpha$  and IL-1 $\beta$  by blocking the action of the activin [19]. In contrast, activin A produces anti-inflammatory effects by blocking the action of IL-6. It was reported that activin A significantly stimulated production of IL-6 at lower concentration, while at higher concentration production of IL-6 was significantly inhibited in human amnion cells [20]. On the other hand, IL-6 level was also significantly lower with follistatin treated group in colitis model of mouse [21]. In this study, administration of rh-follistatin reduced expression of IL-6 after ischemia reperfusion. This suggests that rh-follistatin may exert an anti-inflammatory action by blocking activin in hepatic ischemia reperfusion.

Finally, our results suggest a novel and important role of follistatin in the repair process of the hepatic ischemia-reperfusion injury. It is reported that it is acceptable to give 1  $\mu\text{g}$  ~ 1 mg/kg of follistatin to human (patent; JP, 4483276, B). However, the safety and toxicity of this drug for human use has not been revealed completely. So, we need clinical trials to determine the safety, proper dosage, efficacy, and adverse reactions of this drug. Follistatin has therapeutic potential for the prevention and treatment of hepatic damage leading to acute liver failure.

**Acknowledgments** This work was supported as part of Grants-in-Aid for Scientific Research of Japan.

## References

1. Fox KA. Reperfusion injury: Laboratory phenomenon or clinical reality? *Cardiovasc Res.* 1992;26:656–659.
2. Rizk NN, Rafols J, Dunbar JC. Cerebral ischemia induced apoptosis and necrosis in normal diabetic rats. *Brain Res.* 2005;1053:1–9.
3. Moens AL, Claeys MJ, Timmermans JP, Vrints CJ. Myocardial ischemia/reperfusion-injury, a clinical view on a complex pathophysiological process. *Int J Cardiol.* 2005;100:179–190.
4. Eum HA, Cha YN, Lee SM. Necrosis and apoptosis: sequence of liver damage following reperfusion after 60 min ischemia in rats. *Biochem Biophys Res Commun.* 2007;358:500505.
5. Sasaki H, Matsuno T, Ishikawa T, et al. Activation of apoptosis during early phase of reperfusion after liver transplantation. *Transplant Proc.* 1977;29:406–407.
6. Kogure K, Zhang YQ, Maeshima A, Suzuki K, Kuwano H, Kojima I. The role of activin and transforming growth factor- $\beta$  in the regulation of organ mass in the rat liver. *Hepatology.* 2000;31:916–921.
7. Mather JP, Moore A, Li RH. Activins, inhibins and follistatins: further thoughts on a growth family of regulator. *Proc Soc Exp Biol Med.* 1997;215:209–222.
8. Kogure K, Zhang YQ, Kanzaki M, Omata W, Mine T, Kojima I. Intravenous administration of follistatin: delivery to the liver and effect on liver regeneration after partial hepatectomy. *Hepatology.* 1996;24:361–366.
9. Endo D, Makuuchi M, Kojima I. Activin or follistatin: which is more beneficial to support liver regeneration after massive hepatectomy? *Endocr J.* 2006;53:73–78.
10. Yasuda H, Mine T, Shibata H, et al. Activin A: an autocrine inhibitor of initiation of DNA synthesis in rat hepatocytes. *J Clin Invest.* 1993;92:1491–1496.
11. Kogure K, Zhang YQ, Shibata H, Kojima I. Immediate onset of DNA synthesis in remnant liver after 90% hepatectomy by an administration of follistatin. *J Hepatol.* 1998;29:977–984.
12. Maeshima A, Zhang YQ, Nojima Y, Naruse T, Kojima I. Involvement of activin-follistatin system in tubular regeneration after renal ischemia in rats. *J Am Soc Nephrol.* 2001;12:1685–1695.
13. Mukerji SS, Rainey RN, Rhodes JL, Hall AK. Delayed activin A administration attenuates tissue death after transient focal cerebral ischemia and is associated with decreased stress-responsive kinase activation. *J Neurochem.* 2009;111:1138–1148.
14. Borgnon J, Djamouri F, Lorand I, et al. A. Follistatin allows efficient retroviral-mediated gene transfer into rat liver. *Biochem Biophys Res Commun.* 2005;328:937–943.
15. Hubner G, Alzheimer C, Werner S. Activin: A novel player in tissue repair process. *Histol Histopathol.* 1999;14:295–304.
16. Krester DM, der Hedger MP, Phillips DJ. A activin and follistatin: their role in the acute phase reaction. *J Endocrinol.* 1993;161:195–198.
17. Jones KL, Brauman JN, Groome NP, der Krester DM, Phillips DJ. Activin A release into circulation is an event in systemic inflammation and precedes the release of follistatin. *Endocrinology.* 2000;141:1905–1908.
18. Russell CE, Hedger MP, Brauman JN, Krester DM, der Phillips DJ. A Activin regulates growth and acute phase proteins in the human liver cell line, HepG2. *Mol Cell Endocrinol.* 1999;148:129–136.
19. Hubner G, Werner S. Serum growth factors and proinflammatory cytokines are potent inducers of activin expression in cultured fibroblasts and keratinocytes. *Exp Cell Res.* 1996;228:106–113.
20. Jones KL, Mansell A, Patella S, et al. Activin A is a critical component of the inflammatory response, and its binding protein, follistatin, reduces mortality in endotoxemia. *Proc Natl Acad Sci USA.* 2007;104:16239–16944.
21. Keelan JA, Zhou RL, Mitchell MD. Activin A exerts both pro- and anti-inflammatory effects on human term gestational tissues. *Placenta.* 2000;21:38–43.

## 新しい肝細胞癌適応基準 (Up to Seven) はミラノに変わるか

森 大 樹\* 島 田 光 生\* 宇 都 宮 徹\*  
 居 村 暁\* 森 根 裕 二\* 池 本 哲 也\*  
 花 岡 潤\* 金 本 真 美\* 岩 橋 衆 一\*  
 斉 藤 裕\* 浅野間 理 仁\* 山 田 眞一郎\*  
 三 宅 秀 則\*

索引用語：肝細胞癌，肝移植，適応基準，ミラノ基準，Up to Seven基準

## 1 はじめに

ミラノ基準(5 cm以下単発または3 cm以下3個以内)は、1996年Mazzaferroら<sup>1)</sup>によって提唱された。これまで10数年が経過し、肝細胞癌に対する肝移植の適応基準のスタンダードとして広く応用されてきた。このミラノ基準は、再発の可能性のほとんどない患者群を選別するには優れているといえる。しかし、ミラノ基準外症例でも長期生存例が報告されており、肝移植により治癒させ得る患者群の切り捨てという大きな問題点も指摘されるようになった。10数年前と比較して画像診断技術は格段に向上し、腫瘍径と腫瘍個数の診断においては、特に検出される腫瘍個数に大きな違いが生じているとの指摘もある。また腫瘍マーカーを含めた生物学的指標

を基にした適応決定についても報告されている。このように適応基準の拡大が提唱されており、国内外の各施設が独自の基準で検討を進めている。このような中、ミラノ基準を提唱したMazzaferroらが新たな適応基準として「Up to Seven基準」を報告した。

本稿では、Up to Seven基準がミラノ基準に替わる新たな肝細胞癌に対する適応基準となり得るかについて自験例での検討も含めて概説する。

## 2 肝細胞癌に対する肝移植と長期予後

現在までに肝細胞癌に対する肝切除術を含めた局所療法の治療成績は明らかに向上してきているが、長期予後、特に10年生存率に関しては肝切除例で約29%と決して満足はいくものではない(図1)。その一因が肝細胞

Hiroki MORI et al : Can the up to seven criteria be new expanded eligibility criteria for liver transplantation for patients with hepatocellular carcinoma compared to the conventional milan criteria?

\*徳島大学大学院消化器・移植外科学 [〒770-8503 徳島県徳島市蔵本町3-18-15]