

added to constitute the triple therapy. The levels of AST and ALT returned to normal during the first 7 d of TVR treatment without PEG-IFN and ribavirin. The serum creatinine level increased from 1.02mg/dL to 1.49mg/dL within 4 d, and BUN and uric acid levels also increased; therefore, the administration of febuxostat (10mg/d) was initiated. Because renal dysfunction worsened despite the temporal effect of febuxostat, the dosage of TVR was decreased to 1000mg/bid on day 15, and the dosage of febuxostat was increased to 20mg/d on day 16. Because of the reduced TVR dosage, the blood concentration of cyclosporine decreased to 141ng/mL in 7 d. Because the blood concentration of cyclosporine was around the lower limit of the target window, and the renal dysfunction was not completely ameliorated, the dosage of cyclosporine was maintained at 25mg/qd. After successful completion of the 12-week TVR treatment, the calcineurin inhibitor was switched back from cyclosporine to tacrolimus. The dosage of tacrolimus was set at 1.4mg/bid. The dosage of ribavirin was adjusted considering adverse reactions such as a skin rash on her back and a decrease in hemoglobin levels. The patient noticed the skin rash on her back on day 23 of TVR treatment, and her hemoglobin level decreased from 10.3g/dL to 9.1g/dL within 9 d. These adverse reactions were presumably caused by ribavirin; therefore, the dosage of ribavirin was decreased to 200mg/qod on day 29. The dosage of ribavirin was further decreased to 200mg every 3 d on day 43, 200mg every 4 d on day 57, and finally, she was withdrawn from ribavirin on day 70. No signs of rejection were observed over the course of 100 d of TVR administration.

In Case I, the average cyclosporine doses during 7 d before and after beginning administration of TVR were 157.1mg/bid and 46.4mg/qd, respectively. In the case of all patients, the dosage of cyclosporine decreased by about 60% after initiation of administration of TVR. The data of concentration/dose ratios (C/D ratio, (ng/mL)/mg) of cyclosporine from all study patients are shown in Fig. 5. When TVR therapy was initiated, the C/D ratio increased 3.04-fold from the -1st week to the 1st week. In addition, the C/D ratio of cyclosporine during the 2nd week significantly increased ($p < 0.0001$). On the other hand, after completion of TVR therapy, the C/D ratio decreased from 4.90 to 2.91.

DISCUSSION

Previously, the standard therapy for liver transplantation patients with chronic hepatitis C has been double combination therapy with PEG-IFN α and ribavirin.¹³⁻¹⁶ Recently, TVR is a new drug with strong efficacy against hepatitis C when administrated in combination with PEG-IFN and ribavirin.^{17,18} TVR has strong interactions with drugs metabolized by CYP3A4 and CYP3A5.^{5,6} Liver transplant patients have to take immunosuppressive agents such as tacrolimus and cyclosporine to avoid graft failure, and these agents are metabolized by CYP3A4 and CYP3A5. The blood concentrations of tacrolimus and cyclosporine increase with the administration of TVR. Therefore, to control the blood concentration of tacrolimus and cyclosporine, treatment with the new TVR therapy is important to prevent recurrence of hepatitis C in patients after liver transplantation. Garg *et al.* showed TVR increased the area under the curve of tacrolimus and cyclosporine to 70.3-fold and 4.11-fold, respectively.⁷ Therefore,

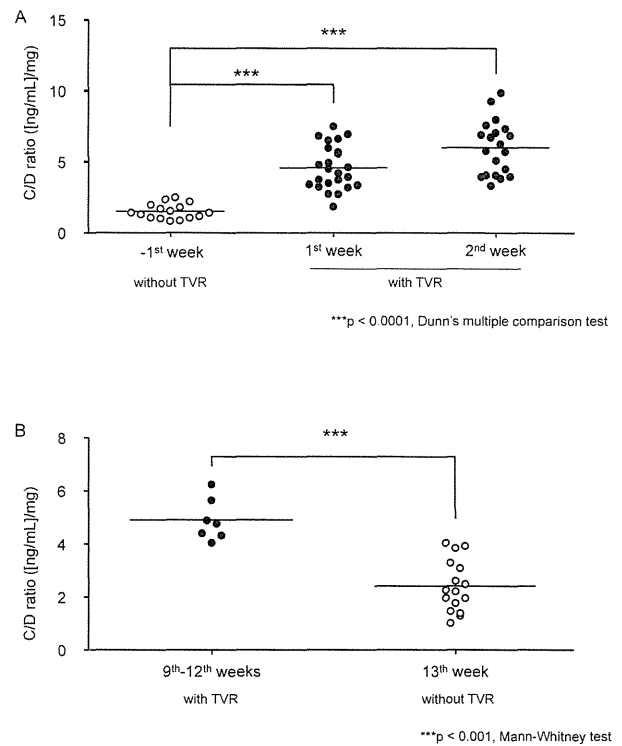


Fig. 5. Influence of Telaprevir (TVR) on C/D Ratio of Cyclosporine
 Concentration/dose (C/D) ratio of cyclosporine was documented within TVR combination therapy beginning (A) and TVR combination therapy ending (B) in this study. *** $p < 0.001$, significant difference between groups.

we switched the immunosuppressive agent from tacrolimus to cyclosporine in this study. On the basis of our predictions, the dosage of cyclosporine was decreased after initiation of TVR administration, and the blood concentration of cyclosporine was unstable. Moreover, the average dosage of cyclosporine decreased to 0.24–0.40-fold before initiation of TVR (data not shown). To maintain the target trough level of cyclosporine, we measured the blood concentration of cyclosporine 3 times a day during the 1st week of TVR administration. This was important to prevent graft rejection. In Case II, the peak blood concentration of cyclosporine was low and the trough level was difficult to decrease. To avoid liver graft rejection, the C_2 blood concentration was maintained at the target level.¹⁹ On the other hand, the trough level of cyclosporine was kept low to prevent adverse effects on the kidney.^{20,21} Therefore, we determined that the dosage of cyclosporine would not be 25mg/d, but rather 50mg/qod. Thus, we controlled not only the total dosage of cyclosporine but also the timing of administration.²⁰ The dosage adjustment of cyclosporine immediately after the end of TVR treatment is an important issue, because the rapid reduction of blood level of cyclosporine should lead the risk of acute rejection. In the present study, we found the rapid elimination of inhibitory effect of TVR on the disposition of cyclosporine in the all four cases (Fig. 5B). Based on these findings, rapid increase in the dosage of cyclosporine would be required to maintain the immunosuppressive effect throughout the anti HCV therapy with or without TVR.

Recently, we reported the drug interactions with tacrolimus in patients after living-donor liver transplantation.²²⁻²⁴ Uesugi *et al.* showed that the CYP3A5 genotype in the graft liver and native intestine had an effect on the blood concentration

Table 2. Transition of HCV RNA before and after the TVR Treatment

Case	Before (days before TVR treatment) ^{a)}	Time after TVR treatment (week)		
		1	2	4
		(log IU/mL)		
Case I	7.2 (7)	4.7	3.0	1.6
Case II	6.5 (12)	2.3	N.D. ^{b)}	N.D.
Case III	6.1 (6)	2.3	1.2>	N.D.
Case IV	4.5 (8)	1.2>	N.D.	N.D.

TVR, telaprevir; HCV, hepatitis C virus. a) The latest day before administration of TVR. b) N.D., HCV RNA was not detected by real-time PCR.

of tacrolimus.²⁵⁾ TVR inhibits not only CYP3A4 but also CYP3A5. We did not examine the CYP3A5 genotype in this study. However, the differences in the CYP3A5 genotype may affect the blood concentration of tacrolimus. Recently, Zheng *et al.* showed a correlation between CYP3A5 genotype and the risk of cyclosporine-induced nephrotoxicity.²⁶⁾ Therefore, the genotype of CYP3A5 may be important in implementing TVR therapy.

Almost all patients experienced HCV recurrence, and some underwent re-transplantation because of HCV-related liver cirrhosis or hepatocellular carcinoma.^{27,28)} The disease progression of hepatitis C is faster in graft liver than in healthy liver,^{8,9)} and the rate of SVR is lower in transplant patients than in patients who did not receive liver transplants.²⁹⁾ In this study, all patients completed the 12-week TVR triple therapy. In all patients, the HCV RNA levels immediately decreased to the baseline levels (Table 2). This indicated that PEG-IFN α -2b, ribavirin, and TVR therapy were effective against hepatitis C. Moreover, HCV RNA levels decreased and liver function markedly improved with TVR alone. However, SVR was detected 24 weeks after combination therapy with PEG-IFN α -2b, ribavirin, and TVR.^{4,17,30,31)} Therefore, these results did not suggest SVR, but these might be steps to SVR.

The dose of TVR had to be reduced in cases II, III, and IV because of severe adverse effects. TVR is known to elicit a severe rash. In Case IV, the level of hemoglobin decreased, and the dosage of ribavirin was gradually decreased. Cases II and IV showed skin rash, and Cases II and III experienced malaise or anorexia. The latter adverse effects were caused not only by TVR but also by PEG-IFN. Therefore, the adverse reactions might be a synergistic effect of triple therapy. To achieve successful outcome with the PEG-IFN, ribavirin, and TVR triple therapy, maintaining these adverse reactions become less bad may be key points to continuing this therapy. The difference between Case I and the others was the level of HCV RNA after administration of TVR. In Case I, the HCV RNA level rapidly decreased; however, these levels decreased almost immediately in Cases II–IV. In addition, the HCV RNA level in Case IV decreased to limits of detection with only TVR (Table 2). The connection between these adverse effects and therapeutic benefit of this therapy was difficult to determine. Small doses of TVR, for example 1000mg/d, might be beneficial to treat HCV and to avoid adverse effects in Cases II, III, and IV. Therefore, dose reduction from the standard dose (2250mg/d) is suitable for Japanese HCV-recurrence patients after liver transplantation.¹²⁾ In addition, the association between TVR blood level profile and its adverse reactions should be examined in future to individualized dosage adjustment of TVR.

In all patients, the serum creatinine levels were temporarily increased at the 1st week of TVR administration. However, in Case IV, during TVR treatment, the serum creatinine remained at a high level (1.41 ± 0.25 mg/dL). Cyclosporine or TVR might cause renal dysfunction; therefore, cyclosporine was replaced with tacrolimus immediately after TVR therapy. To treat avoid adverse effects of cyclosporine and the risk of re-control of cyclosporine, triple therapy should be administered with tacrolimus as the immunosuppressive agent.

In conclusion, we could treat patients with recurrence of hepatitis C after liver transplantation by TVR therapy to avoid liver graft rejection. Controlling the drug interaction between TVR and cyclosporine was the most important aspect to achieving both treatment of hepatitis C and prevention of liver graft rejection. We selected cyclosporine instead of tacrolimus as the immunosuppressive agent and carefully adjusted the dosage of cyclosporine by frequent measurement of blood concentration. It was risky to change the immunosuppressive agent from tacrolimus to cyclosporine for graft rejection. Therefore, in the future, we will need to control the blood concentration of tacrolimus, which has a strong interaction with TVR, to treat HCV with TVR triple therapy.

Acknowledgments This work was supported in part by a Grant-in-Aid for Scientific Research (KAKENHI) from the Ministry of Education, Culture, Sports, Science and Technology (MEXT) of Japan and by a Funding Program for Next Generation World-Leading Researchers (NEXT Program: LS073) initiated by the Council for Science and Technology Policy of the Japan Society for the Promotion of Science of Japan.

REFERENCES

- 1) Forestier N, Zeuzem S. Telaprevir for the treatment of hepatitis C. *Expert Opin. Pharmacother.*, **13**, 593–606 (2012).
- 2) Fowell AJ, Nash KL. Telaprevir: a new hope in the treatment of chronic hepatitis C? *Adv. Ther.*, **27**, 512–522 (2010).
- 3) Kim JJ, Culley CM, Mohammad RA. Telaprevir: an oral protease inhibitor for hepatitis C virus infection. *Am. J. Health Syst. Pharm.*, **69**, 19–33 (2012).
- 4) Kumada H, Toyota J, Okanoue T, Chayama K, Tsubouchi H, Hayaishi N. Telaprevir with peginterferon and ribavirin for treatment-naive patients chronically infected with HCV of genotype 1 in Japan. *J. Hepatol.*, **56**, 78–84 (2012).
- 5) Wilby KJ, Greanya ED, Ford JA, Yoshida EM, Partovi N. A review of drug interactions with boceprevir and telaprevir: implications for HIV and transplant patients. *Ann. Hepatol.*, **11**, 179–185 (2012).
- 6) Kiser JJ, Burton JR, Anderson PL, Everson GT. Review and management of drug interactions with boceprevir and telaprevir. *Hepa-*

- ology*, **55**, 1620–1628 (2012).
- 7) Garg V, van Heeswijk R, Lee JE, Alves K, Nadkarni P, Luo X. Effect of telaprevir on the pharmacokinetics of cyclosporine and tacrolimus. *Hepatology*, **54**, 20–27 (2011).
 - 8) Gane E. The natural history and outcome of liver transplantation in hepatitis C virus-infected recipients. *Liver Transpl.*, **9**, S28–S34 (2003).
 - 9) Sánchez-Fueyo A, Restrepo JC, Quinto L, Bruguera M, Grande L, Sanchez-Tapias JM, Rodes J, Rimola A. Impact of the recurrence of hepatitis C virus infection after liver transplantation on the long-term viability of the graft. *Transplantation*, **73**, 56–63 (2002).
 - 10) Tanaka K, Lake J, Villamil F, Levy G, Marotta P, Mies S, de Hemp-tinne B, Moench C. Comparison of cyclosporine microemulsion and tacrolimus in 39 recipients of living donor liver transplantation. *Liver Transpl.*, **11**, 1395–1402 (2005).
 - 11) Suzuki F, Suzuki Y, Sezaki H, Akuta N, Seko Y, Kawamura Y, Hosaka T, Kobayashi M, Saito S, Arase Y, Ikeda K, Mineta R, Watahiki S, Kobayashi M, Nakayasu Y, Tsuda H, Aoki K, Yamada I, Kumada H. Exploratory study on telaprevir given every 8 h at 500 mg or 750 mg with peginterferon-alpha-2b and ribavirin in hepatitis C patients. *Hepatology*, **43**, 691–701 (2013).
 - 12) Chayama K, Hayes CN, Ohishi W, Kawakami Y. Treatment of chronic hepatitis C virus infection in Japan: update on therapy and guidelines. *J. Gastroenterol.*, **48**, 1–12 (2013).
 - 13) Mukherjee S, Rogge J, Weaver L, Schafer DF. Pilot study of pegylated interferon alfa-2b and ribavirin for recurrent hepatitis C after liver transplantation. *Transplant. Proc.*, **35**, 3042–3044 (2003).
 - 14) Neff GW, delaGarza J, Shire N, Nishida S, O'Brien CB, Safdar K, Madariaga J, Schiff E, Ruiz P. The long-term effects of immune suppression on liver transplant recipients with recurrent hepatitis C viral infection. *Transplant. Proc.*, **36**, 3065–3067 (2004).
 - 15) Ueda Y, Takada Y, Marusawa H, Egawa H, Uemoto S, Chiba T. Individualized extension of pegylated interferon plus ribavirin therapy for recurrent hepatitis C genotype 1b after living-donor liver transplantation. *Transplantation*, **90**, 661–665 (2010).
 - 16) Castells L, Vargas V, Allende H, Bilbao I, Luis Lazaro J, Margarit C, Esteban R, Guardia J. Combined treatment with pegylated interferon (alpha-2b) and ribavirin in the acute phase of hepatitis C virus recurrence after liver transplantation. *J. Hepatol.*, **43**, 53–59 (2005).
 - 17) McHutchison JG, Everson GT, Gordon SC, Jacobson IM, Sulkowski M, Kauffman R, McNair L, Alam J, Muir AJ, PROVE1 Study Team. Telaprevir with peginterferon and ribavirin for chronic HCV genotype 1 infection. *N. Engl. J. Med.*, **360**, 1827–1838 (2009).
 - 18) Kieffer TL, De Meyer S, Bartels DJ, Sullivan JC, Zhang EZ, Tigges A, Dierynck I, Spanks J, Dorrian J, Jiang M, Adiwijaya B, Ghys A, Beumont M, Kauffman RS, Adda N, Jacobson IM, Sherman KE, Zeuzem S, Kwong AD, Picchio G. Hepatitis C viral evolution in genotype 1 treatment-naïve and treatment-experienced patients receiving telaprevir-based therapy in clinical trials. *PLoS ONE*, **7**, e34372 (2012).
 - 19) Treckmann J, Paul A, Ozcelik A, Saner F, Malago M, Nadalin S, Lang H, Malamutman E, Gerken G, Broelsch CE. Efficacy of C0 and C2 monitoring in adult liver transplant recipients treated with neoral, mycophenolate mofetil, and steroids. *Transplant. Proc.*, **39**, 3234–3236 (2007).
 - 20) Fukudo M, Yano I, Masuda S, Katsura T, Ogura Y, Oike F, Takada Y, Tanaka K, Inui K. Cyclosporine exposure and calcineurin phosphatase activity in living-donor liver transplant patients: twice daily vs. once daily dosing. *Liver Transpl.*, **12**, 292–300 (2006).
 - 21) Rodrigo E, Ruiz JC, Angeles de Cos M, Ruiz J, Gago M, Pinera C, Sanchez B, Gonzalez-Cotruello J, Gomez-Alamillo C, Arias M. Correlation of C0 and C2 levels with cyclosporine side effects in kidney transplantation. *Transplant. Proc.*, **41**, 2328–2331 (2009).
 - 22) Hosohata K, Masuda S, Katsura T, Takada Y, Kaido T, Ogura Y, Oike F, Egawa H, Uemoto S, Inui K. Impact of intestinal CYP2C19 genotypes on the interaction between tacrolimus and omeprazole, but not lansoprazole, in adult living-donor liver transplant patients. *Drug Metab. Dispos.*, **37**, 821–826 (2009).
 - 23) Hosohata K, Masuda S, Ogura Y, Oike F, Takada Y, Katsura T, Uemoto S, Inui K. Interaction between tacrolimus and lansoprazole, but not rabeprazole in living-donor liver transplant patients with defects of CYP2C19 and CYP3A5. *Drug Metab. Pharmacokin.*, **23**, 134–138 (2008).
 - 24) Hosohata K, Masuda S, Yonezawa A, Sugimoto M, Takada Y, Kaido T, Ogura Y, Oike F, Uemoto S, Inui K. Absence of influence of concomitant administration of rabeprazole on the pharmacokinetics of tacrolimus in adult living-donor liver transplant patients: a case-control study. *Drug Metab. Pharmacokin.*, **24**, 458–463 (2009).
 - 25) Uesugi M, Masuda S, Katsura T, Oike F, Takada Y, Inui K. Effect of intestinal CYP3A5 on postoperative tacrolimus trough levels in living-donor liver transplant recipients. *Pharmacogenet. Genomics*, **16**, 119–127 (2006).
 - 26) Zheng S, Tasnif Y, Hebert MF, Davis CL, Shitara Y, Calamia JC, Lin YS, Shen DD, Thummel KE. CYP3A5 gene variation influences cyclosporine A metabolite formation and renal cyclosporine disposition. *Transplantation*, **95**, 821–827 (2013).
 - 27) Brown RS. Hepatitis C and liver transplantation. *Nature*, **436**, 973–978 (2005).
 - 28) Berenguer M, Prieto M, Palau A, Rayon JM, Carrasco D, Juan FS, Lopez-Labrador FX, Moreno R, Mir J, Berenguer J. Severe recurrent hepatitis C after liver retransplantation for hepatitis C virus-related graft cirrhosis. *Liver Transpl.*, **9**, 228–235 (2003).
 - 29) Lavezzo B, Franchello A, Smedile A, David E, Barbui A, Torrani M, Ottobrelli A, Zamboni F, Fadda M, Bobbio A, Salizzoni M, Rizzetto M. Treatment of recurrent hepatitis C in liver transplants: efficacy of a six versus a twelve month course of interferon alfa 2b with ribavirin. *J. Hepatol.*, **37**, 247–252 (2002).
 - 30) Danta M. Telaprevir triple combination therapy, and dual peginterferon alpha-2a/ribavirin therapy for 24 weeks for those with rapid-early response is not inferior to 48 weeks of therapy for treatment-naïve patients with genotype 1 hepatitis C virus infection. *Evid. Based Med.*, **17**, 143–144 (2012).
 - 31) Ozeki I, Akaike J, Karino Y, Arakawa T, Kuwata Y, Ohmura T, Sato T, Kamiya N, Yamada I, Chayama K, Kumada H, Toyota J. Antiviral effects of peginterferon alpha-2b and ribavirin following 24-week monotherapy of telaprevir in Japanese hepatitis C patients. *J. Gastroenterol.*, **46**, 929–937 (2011).

Case Report

Plasma cell hepatitis induced by the termination of antiviral therapy for recurrent hepatitis C after living donor liver transplantation

Yoshihide Ueda,¹ Atsushi Yoshizawa,² Yasuhiro Ogura,² Aya Miyagawa-Hayashino,³ Hironori Haga,³ Tsutomu Chiba¹ and Shinji Uemoto²

Departments of ¹Gastroenterology and Hepatology, ²Surgery and ³Diagnostic Pathology, Graduate School of Medicine, Kyoto University, Kyoto, Japan

Plasma cell hepatitis (PCH) is an idiopathic disorder characterized by plasma cell infiltration in the allografts of patients who have undergone liver transplantation. Although an increasing number of cases of PCH have been reported in liver transplant recipients with hepatitis C recurrence treated with interferon, it is unclear whether PCH is induced by interferon itself. Here, we describe the cases of two patients who developed PCH just after the termination of antiviral therapy for recurrent hepatitis C after living donor liver transplantation. Liver dysfunction appeared at 1 month in one patient and 2 months in the other patient after pegylated interferon plus ribavirin therapy, and liver histology showed interface hepatitis with

plasma cell-rich lymphoid aggregates. Both patients recovered after steroid therapy and achieved sustained virological response. These cases suggest that PCH could be induced by the alteration of the immune condition resulting from the termination of antiviral therapy. PCH should be considered when the transaminase levels increase after antiviral therapy, and it should be carefully distinguished from hepatitis C relapse.

Key words: antiviral therapy, hepatitis C, liver transplantation, plasma cell hepatitis

INTRODUCTION

PLASMA CELL HEPATITIS (PCH), termed *de novo* autoimmune hepatitis (AIH), is an idiopathic disorder with the histological characteristics of AIH, showing interface hepatitis with a predominantly lymphoplasmacytic necroinflammatory infiltrate with or without lobular involvement and bridging necrosis in patients after undergoing liver transplantation for indications besides AIH.¹⁻⁴ Interestingly, an increasing number of PCH cases have been reported in liver transplant recipients infected with hepatitis C virus (HCV), including patients treated with interferon and ribavirin for recurrent hepatitis C.²⁻⁸ However, it is unclear whether PCH is induced by interferon itself because the

frequency of this disorder is low in a limited number of reports. Moreover, the histological features of PCH could not be completely distinguished from interface hepatitis because of HCV. Therefore, whether PCH is a real threat to the graft during antiviral therapy is controversial at present. Here, we describe the cases of two patients who developed PCH just after termination of antiviral therapy for recurrent hepatitis C after living donor liver transplantation (LDLT). As both patients achieved sustained virological response (SVR) and had no history of AIH, the termination of antiviral therapy was the likely trigger for PCH in these patients.

CASE REPORTS

Case 1

A 59-YEAR-OLD WOMAN underwent LDLT, with her son as the donor, for HCV-related cirrhosis. Six months after the LDLT, her liver biopsy showed HCV recurrence with mild necroinflammatory activity and mild fibrosis (METAVIR score, A1 F1) without acute cellular rejection (ACR). The HCV genotype was 1b and

Correspondence: Dr Yoshihide Ueda, Department of Gastroenterology and Hepatology, Graduate School of Medicine, Kyoto University, 54 Kawara-cho, Shogoin, Sakyo-ku, Kyoto 606-8507, Japan.

Email: yueda@kuhp.kyoto-u.ac.jp

Received 13 June 2013; revision 12 September 2013; accepted 13 September 2013.

the serum HCV RNA level was 3570 kIU/mL on an Amplicor HCV assay. The serum immunoglobulin (Ig)G level was 1260 mg/dL (reference range, 826–1840) and she was negative for antinuclear antibodies (ANA). She started antiviral therapy with 80 µg/week pegylated interferon-α-2b and 600 mg/day ribavirin, together with 2 mg/day tacrolimus and 1 g/day mycophenolate mofetil (Fig. 1a). HCV RNA was undetectable in serum 2 months after the initiation of the treatment, and antiviral therapy was continued for 14 months. The immunosuppressants administered were not changed during and after the antiviral therapy. Before the termination of treatment, her transaminase levels remained normal; however, 1 month later, her aspartate aminotransferase (AST) and alanine aminotransferase (ALT) levels reached 455 and 650 IU/L, respectively, IgG level increased to 2660 mg/dL, and she was positive for ANA at a titer of 1:40 with a speckled pattern. Type 1 liver-kidney microsomal antibodies (anti-LKM-1) was negative. Liver histology showed moderate necroinflammatory activity and moderate fibrosis (METAVIR score, A2 F2) with plasma cell-rich infiltration (Fig. 1b,c). As serum HCV RNA remained undetectable at that time; the International AIH Group score was 16, indicating definite AIH;⁹ and the total score in the histological scoring system for PCH⁶ was 11, we diagnosed the patient with PCH. Steroid therapy with methylprednisolone was initiated at a dose of 500 mg/day for 3 days, and then the dose was tapered from 250 mg/day on the fourth day to 62.5 mg/day on the sixth day. Then, the drug was switched to 50 mg prednisolone, which was tapered to 10 mg until the end of the sixth month. AST and ALT levels decreased immediately after the administration of steroid, and normalized during 2 months of the steroid therapy. Liver biopsy after 17 months of steroid therapy showed histological improvement. Serum HCV RNA was undetectable in serum at 24 weeks after the completion of antiviral therapy, and she was considered to have achieved SVR.

Case 2

A 63-year-old woman underwent LDLT, with her son as the donor, for HCV-related cirrhosis and hepatocellular carcinoma. Liver biopsy at 19 days after LDLT revealed mild ACR, but it resolved without any specific treatment. At 23 months after LDLT, she developed recurrent hepatitis C with mild activity and severe fibrosis on liver biopsy (METAVIR score, A1 F3). The HCV genotype was 2b and the serum HCV RNA level was 7.2 log IU/mL, as detected by a real-time polymerase chain reaction-based quantitation method. Antiviral therapy with 100 µg/

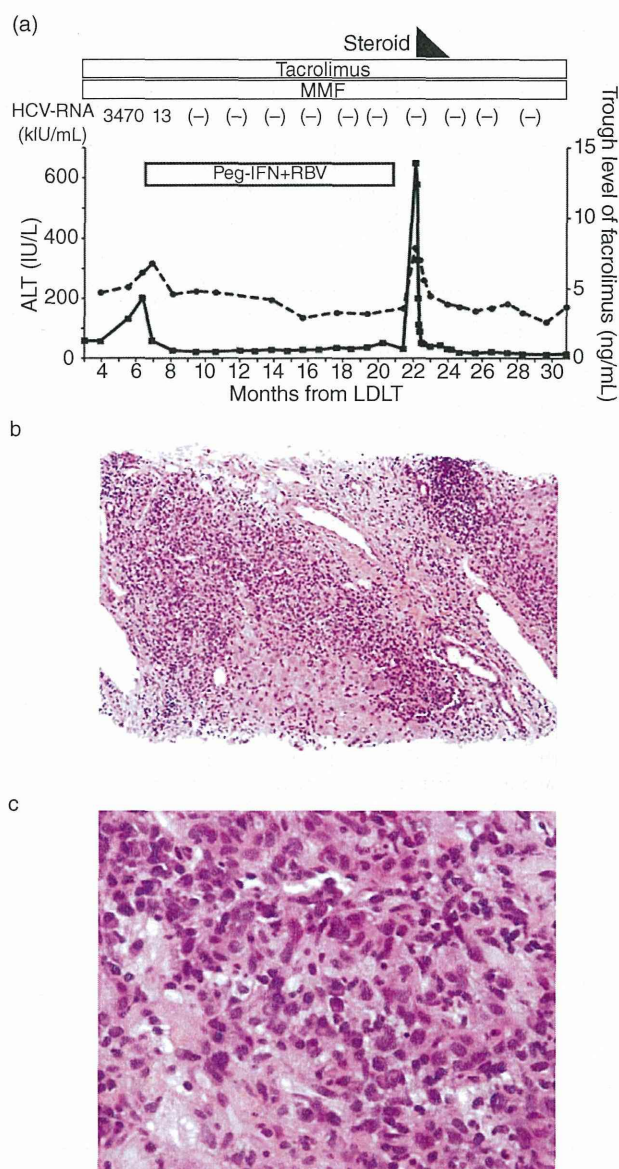


Figure 1 (a) Clinical course of patient 1, who developed plasma cell hepatitis induced by the termination of antiviral therapy for recurrent hepatitis C after living donor liver transplantation (LDLT). The fine lines indicate the alanine aminotransferase (ALT) level (IU/L), and the dotted lines represent the trough level of tacrolimus (ng/mL). Steroid administration is shown as a black box; treatments with tacrolimus, mycophenolate mofetil (MMF), and pegylated interferon plus ribavirin (peg-IFN + RBV) are indicated by open boxes. Serum hepatitis C virus (HCV) RNA levels (kIU/mL) are shown as values or (-), which means undetectable. (b,c) Liver allograft biopsy of patient 1 at 1 month after the termination of antiviral therapy, showing interface hepatitis with plasma cell-rich infiltration (hematoxylin-eosin, original magnifications: [b] ×200; [c] ×400).

week pegylated interferon- α -2b and 400 mg/day ribavirin was initiated (Fig. 2a). At that time, 50 mg/day cyclosporin and 15 mg/day prednisolone were used for immunosuppression. The prednisolone dose was reduced to 10 mg/day after 3 months of antiviral therapy. HCV RNA was undetectable in serum; however, treatment was discontinued after 21 weeks because of severe general fatigue. The transaminase levels were reduced and maintained within the reference range from 3 weeks to the end of antiviral therapy, but worsened 2 months after the termination of the treatment to an AST level of 136 IU/L and an ALT level of 152 IU/L. The serum IgG level increased to 1719 mg/dL, from 641 mg/dL before the antiviral therapy. She was negative for ANA and anti-LKM-1 throughout her clinical course. Liver biopsy revealed the features of AIH, including portal inflammation with plasma cell-rich lymphoid aggregates, interface hepatitis and centrilobular inflammation (Fig. 2b,c). As HCV RNA was undetectable in serum; the International AIH Group score was 14, suggesting AIH;⁹ and the total score on the histological scoring system for PCH was 10,⁶ the patient was diagnosed with PCH. Methylprednisolone was started at a dose of 500 mg/day for 3 days, and then the dose was tapered from 250 mg/day on the fourth day to 62.5 mg/day on the sixth day. The treatment was terminated on the seventh day, followed by the initiation of 10 mg/day prednisolone. The transaminase levels decreased and normalized after 2 months of steroid administration, and liver biopsy 19 months after the initiation of steroid therapy showed the remission of hepatitis. She was considered to have achieved SVR on the basis of a negative HCV RNA result at 24 weeks after the termination of antiviral therapy.

DISCUSSION

IN THIS REPORT, we demonstrated the cases of two patients who developed PCH just after the termination of antiviral therapy for recurrent hepatitis C after LDLT. The diagnosis of PCH in the present cases is definite because both patients achieved SVR and recovered after steroid therapy. Termination of antiviral therapy likely induced PCH in these patients, as both patients had no other trigger for PCH, such as reduction of immunosuppression.

At our institute, 125 HCV-infected liver transplant recipients were treated with standard interferon and/or pegylated interferon in combination with ribavirin for recurrent hepatitis C after LDLT between January 2001 and December 2012.^{10,11} Four of the 125 patients (3%),

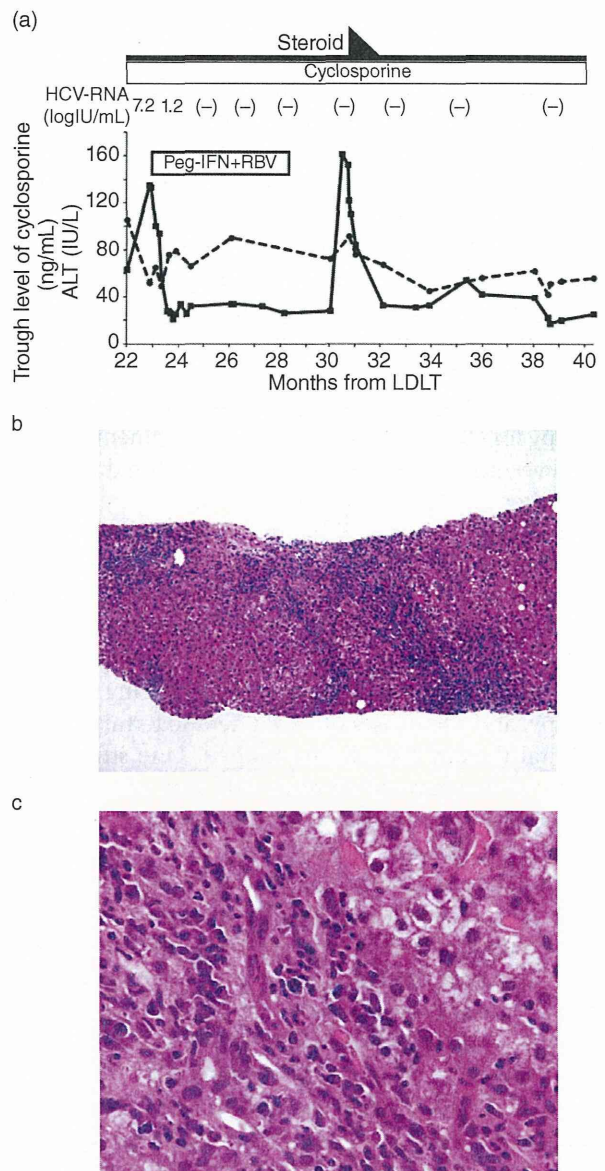


Figure 2 (a) Clinical course of patient 2, who developed plasma cell hepatitis after the termination of antiviral therapy for recurrent hepatitis C after living donor liver transplantation (LDLT). The fine lines indicate the alanine aminotransferase (ALT) level (IU/L), and the dotted lines represent the trough level of cyclosporin (ng/mL). Steroid administration is shown as black boxes; treatments with cyclosporin and pegylated interferon plus ribavirin (peg-IFN + RBV) are indicated by open boxes. Serum hepatitis C virus (HCV) RNA levels (logIU/mL) are shown as values or (-), which means undetectable. (b,c) Liver allograft biopsy of patient 2 at 2 months after the termination of antiviral therapy, showing interface hepatitis with lymphoplasmacytic necroinflammatory infiltration (hematoxylin-eosin, original magnifications: [b] $\times 100$; [c] $\times 400$).

including the two patients in this case report, developed PCH during or within 6 months after antiviral therapy. The other two patients who developed PCH during antiviral therapy showed interface hepatitis with moderate plasma cell infiltration in liver histology and high serum IgG levels. Clinical features of the two patients with PCH during antiviral therapy could not be distinguished from those of two patients who developed PCH after termination of antiviral therapy. The incidence of PCH in this study was similar to that in patients without antiviral therapy in our previous report, in which the incidence of PCH (de novo AIH) was 2.1% in 633 recipients.¹² Therefore, it is unknown whether antiviral therapy for HCV is involved in the development of PCH. However, in the present cases, PCH occurred immediately after the termination of antiviral therapy, indicating that the cessation of interferon may have induced the disease.

Several studies have shown an association between PCH (de novo AIH) and antiviral therapy for recurrent hepatitis C after liver transplantation.²⁻⁸ In these studies, most of the patients developed PCH during antiviral therapy, and a few cases of PCH after the termination of antiviral therapy have been reported. One study demonstrated two cases of de novo AIH that occurred after the end of antiviral therapy for recurrent hepatitis C after liver transplantation.¹³ Both patients developed de novo AIH at 1 month after the termination of pegylated interferon plus ribavirin therapy, but hepatitis caused by HCV recurrence was not completely excluded in both cases because the patients' sera tested positive for HCV RNA after termination of antiviral therapy. Berardi *et al.* reported nine liver transplant recipients with de novo AIH associated with antiviral treatment for hepatitis C recurrence.⁵ While eight patients of the nine in their report had de novo AIH during antiviral therapy, one patient who achieved SVR developed de novo AIH at 1 month after termination of antiviral therapy. Our present cases and these reported cases suggest that PCH can be induced by the termination of antiviral treatment.

It is important that PCH is considered in differential diagnoses along with relapse of HCV in patients developing liver dysfunction just after the termination of interferon therapy. The present cases showed elevation of transaminase levels at 1 and 2 months after the cessation of antiviral therapy when the relapse of HCV usually occurs. As it takes several days to obtain the results of serum HCV RNA examination, it would be initially difficult to distinguish HCV relapse from the other causes of liver dysfunction. Liver biopsy should be

immediately done and histological diagnosis using the scoring system for PCH is recommended to differentiate it from other causes of liver dysfunction, including hepatitis C relapse in this situation. PCH in the present cases could be diagnosed just after the elevation of transaminase levels, and received steroid therapy immediately after the diagnosis of PCH, resulting in good treatment response and good prognosis.

In conclusion, PCH could be induced by the alteration of the immune condition resulting from the termination of antiviral therapy. PCH should be considered when the transaminase levels increase after interferon therapy, and it should be carefully distinguished from hepatitis C relapse.

ACKNOWLEDGMENT

THIS WORK WAS supported by Health and Labor Sciences Research Grants for Research on Hepatitis from the Ministry of Health, Labor and Welfare, Japan.

REFERENCES

- 1 Czaja AJ. Diagnosis, pathogenesis, and treatment of autoimmune hepatitis after liver transplantation. *Dig Dis Sci* 2012; 57: 2248-66.
- 2 Guido M, Burra P. De novo autoimmune hepatitis after liver transplantation. *Semin Liver Dis* 2011; 31: 71-81.
- 3 O'Grady J. The immunoreactive patient: rejection and autoimmune disease. *Liver Transpl* 2011; 17 (Suppl 3): S29-33.
- 4 Selzner N, Guindi M, Renner EL, Berenguer M. Immune-mediated complications of the graft in interferon-treated hepatitis C positive liver transplant recipients. *J Hepatol* 2011; 55: 207-17.
- 5 Berardi S, Lodato F, Gramenzi A *et al.* High incidence of allograft dysfunction in liver transplanted patients treated with pegylated-interferon alpha-2b and ribavirin for hepatitis C recurrence: possible de novo autoimmune hepatitis? *Gut* 2007; 56: 237-42.
- 6 Fiel MI, Agarwal K, Stanca C *et al.* Posttransplant plasma cell hepatitis (de novo autoimmune hepatitis) is a variant of rejection and may lead to a negative outcome in patients with hepatitis C virus. *Liver Transpl* 2008; 14: 861-71.
- 7 Levitsky J, Fiel MI, Norvell JP *et al.* Risk for immune-mediated graft dysfunction in liver transplant recipients with recurrent HCV infection treated with pegylated interferon. *Gastroenterology* 2012; 142: 1132-9, e1.
- 8 Ward SC, Schiano TD, Thung SN, Fiel MI. Plasma cell hepatitis in hepatitis C virus patients post-liver transplantation: case-control study showing poor outcome and predictive features in the liver explant. *Liver Transpl* 2009; 15: 1826-33.

- 9 Alvarez F, Berg PA, Bianchi FB *et al.* International Autoimmune Hepatitis Group Report: review of criteria for diagnosis of autoimmune hepatitis. *J Hepatol* 1999; 31: 929–38.
- 10 Ueda Y, Takada Y, Haga H *et al.* Limited benefit of biochemical response to combination therapy for patients with recurrent hepatitis C after living-donor liver transplantation. *Transplantation* 2008; 85: 855–62.
- 11 Ueda Y, Takada Y, Marusawa H, Egawa H, Uemoto S, Chiba T. Individualized extension of pegylated interferon plus ribavirin therapy for recurrent hepatitis C genotype 1b after living-donor liver transplantation. *Transplantation* 2010; 90: 661–5.
- 12 Miyagawa-Hayashino A, Haga H, Egawa H *et al.* Outcome and risk factors of de novo autoimmune hepatitis in living-donor liver transplantation. *Transplantation* 2004; 78: 128–35.
- 13 Merli M, Gentili F, Giusto M *et al.* Immune-mediated liver dysfunction after antiviral treatment in liver transplanted patients with hepatitis C: allo or autoimmune de novo hepatitis? *Dig Liver Dis* 2009; 41: 345–9.

Accepted Manuscript

Reactivation from Occult HBV Carrier Status is Characterized by Low Genetic Heterogeneity with the Wild-type or G1896A Variant Prevalence

Tadashi Inuzuka, Yoshihide Ueda, Hiroki Morimura, Yosuke Fujii, Makoto Umeda, Tadayuki Kou, Yukio Osaki, Shinji Uemoto, Tsutomu Chiba, Hiroyuki Marusawa


PII: S0168-8278(14)00296-7
DOI: <http://dx.doi.org/10.1016/j.jhep.2014.04.033>
Reference: JHEPAT 5138

To appear in: *Journal of Hepatology*

Received Date: 10 December 2013
Revised Date: 7 April 2014
Accepted Date: 24 April 2014

Please cite this article as: Inuzuka, T., Ueda, Y., Morimura, H., Fujii, Y., Umeda, M., Kou, T., Osaki, Y., Uemoto, S., Chiba, T., Marusawa, H., Reactivation from Occult HBV Carrier Status is Characterized by Low Genetic Heterogeneity with the Wild-type or G1896A Variant Prevalence, *Journal of Hepatology* (2014), doi: <http://dx.doi.org/10.1016/j.jhep.2014.04.033>

This is a PDF file of an unedited manuscript that has been accepted for publication. As a service to our customers we are providing this early version of the manuscript. The manuscript will undergo copyediting, typesetting, and review of the resulting proof before it is published in its final form. Please note that during the production process errors may be discovered which could affect the content, and all legal disclaimers that apply to the journal pertain.



**Reactivation from Occult HBV Carrier Status is Characterized by Low Genetic Heterogeneity
with the Wild-type or G1896A Variant Prevalence**

**Tadashi Inuzuka¹, Yoshihide Ueda¹, Hiroki Morimura¹, Yosuke Fujii¹, Makoto Umeda²,
Tadayuki Kou³, Yukio Osaki⁴, Shinji Uemoto⁵, Tsutomu Chiba¹, and Hiroyuki Marusawa¹**

¹Department of Gastroenterology and Hepatology, Graduate School of Medicine,
Kyoto University, Kyoto, Japan

²Department of Gastroenterology and Hepatology, Hyogo Prefectural Amagasaki Hospital, Hyogo,
Japan

³Department of Gastroenterology and Hepatology, Kitano Hospital, Osaka, Japan

⁴Department of Gastroenterology and Hepatology, Osaka Red Cross Hospital, Osaka, Japan

⁵Department of Surgery, Graduate School of Medicine, Kyoto University, Kyoto, Japan

Corresponding & Reprint Author: Hiroyuki Marusawa at:

Department of Gastroenterology and Hepatology, Graduate School of Medicine,
Kyoto University, 54 Kawahara-cho, Shogoin, Sakyo-ku, Kyoto 606-8507, Japan
Phone; +81-75-751-4319, Fax; +81-75-751-4303
E-mail; maru@kuhp.kyoto-u.ac.jp

Electronic word count: 4999 words

Number of figures and tables: 3 figures, 4 tables

Abbreviations:

ALF, acute liver failure; ALT, alanine aminotransferase; anti-HBc, antibodies to hepatitis B core antigen; ETV, entecavir; HBeAg, hepatitis B e antigen; HBsAg, hepatitis B surface antigen; HBV, hepatitis B virus; PCR, polymerase chain reaction; pre-C, pre-core; T-bil, total bilirubin

Conflict of interest: All authors declare no conflicts of interests.