

# Intraocular Concentrations of Cytokines and Chemokines in Rhegmatogenous Retinal Detachment and the Effect of Intravitreal Triamcinolone Acetonide

HIROSHI KUNIKATA, MASAYUKI YASUDA, NAOKO AIZAWA, YUJI TANAKA, TOSHIAKI ABE, AND TORU NAKAZAWA

• **PURPOSE:** To investigate the role of intravitreal injection of triamcinolone acetonide (IVTA) in preventing photoreceptor apoptosis in eyes with rhegmatogenous retinal detachment (RRD) by measuring cytokine levels in the aqueous humor before and after IVTA.

• **DESIGN:** Prospective, nonrandomized, interventional case series.

• **METHODS:** SETTING: Institutional. PATIENTS: Nineteen eyes of 19 consecutive patients with RRD. INTERVENTION: All 19 eyes underwent IVTA 1 day before 25-gauge vitrectomy. Seventeen eyes free of retinal vascular disease served as controls. MAIN OUTCOME MEASURE: Both baseline and 1 day post-IVTA measurements were made of the relative concentrations of 15 soluble factors (3 cytokines, 7 chemokines, and 5 growth factors). The associations with clinical findings, including macular status, were then analyzed.

• **RESULTS:** Elevated monocyte chemotactic protein 1 (MCP-1), macrophage inflammatory protein 1 $\beta$  (MIP-1 $\beta$ ), and interferon  $\gamma$ -induced protein 10 (IP-10) in eyes with RRD were significantly reduced after IVTA. MCP-1 levels were significantly correlated with MIP-1 $\beta$  and IP-10 before and after IVTA. The decreases in MCP-1, MIP-1 $\beta$ , and IP-10 were also closely correlated to each other. Both before and after IVTA, MCP-1 was higher in eyes with macula-off RRD than in eyes with macula-on RRD.

• **CONCLUSIONS:** IVTA suppressed elevated levels of intraocular MCP-1, MIP-1 $\beta$ , and IP-10 in eyes with RRD. The decrease in the aqueous levels of each of these factors was significantly correlated with the others. In addition to MCP-1, MIP-1 $\beta$  and IP-10 might potentially be additional target molecules for RRD therapy. (Am J Ophthalmol 2013;155:1028–1037. © 2013 by Elsevier Inc. All rights reserved.)

**R**HEGMATOGENOUS RETINAL DETACHMENT (RRD) IS a common retinal disease that causes visual field defects and severe visual disturbance. Newly developed surgical interventions, particularly 25-gauge microincision vitrectomy surgery (25GMIVS), have led to a very high initial reattachment rate for eyes with RRD, currently about 95%.<sup>1–10</sup> Even after successful reattachment, however, degeneration of the photoreceptors in the detached area of the retina often prevents complete recovery of visual function.<sup>1,11</sup>

Vitreous samples from eyes with RRD have shown significantly elevated levels of monocyte chemotactic protein 1 (MCP-1) compared to controls.<sup>12,13</sup> Previous research by our team, performed with an experimental animal model, showed that MCP-1, along with tumor necrosis factor  $\alpha$  (TNF- $\alpha$ ), is implicated in the pathogenesis of photoreceptor degeneration and apoptosis following retinal detachment.<sup>14–16</sup> Furthermore, the administration of antibodies and corticosteroid suppressed photoreceptor degeneration and apoptosis in our animal model and lowered the intraocular expression of both MCP-1 and TNF- $\alpha$ . The current study examines the specific effects of corticosteroid in human subjects with RRD. Corticosteroid is already in wide use for a variety of ocular diseases, and triamcinolone acetonide (TA) in particular is well recognized for its anti-inflammatory properties. There are many reports on the successful use of intravitreal injection of triamcinolone acetonide (IVTA) as a treatment for exudative conditions of the posterior segment.<sup>17–25</sup>

In this prospective study, therefore, we hypothesized that in the preoperative period, IVTA would suppress inflammation and photoreceptor apoptosis in human eyes with RRD. To evaluate our hypothesis, we measured levels of intraocular mediators including chemokines and cytokines, such as MCP-1 and TNF- $\alpha$ , and analyzed their response to IVTA in eyes with RRD. Thus, the purpose of this report is to evaluate the effect of IVTA on the intraocular concentration of mediators in eyes with RRD.

## MATERIALS AND METHODS

• **SETTING AND DESIGN:** This was an institutional, prospective, nonrandomized, interventional case series.

Accepted for publication Jan 8, 2013.

From the Department of Ophthalmology (H.K., M.Y., N.A., Y.T., T.N.) and Division of Clinical Cell Therapy (T.A.), Tohoku University Graduate School of Medicine, Sendai, Japan.

Inquiries to Hiroshi Kunikata, Department of Ophthalmology, Tohoku University Graduate School of Medicine, 1-1 Seiryō-machi, Aoba-ku, Sendai 980-8574, Japan; e-mail: kunikata@oph.med.tohoku.ac.jp

**TABLE.** Aqueous Humor Levels of the Inflammatory Mediators Before and After Intravitreal Injection of Triamcinolone Acetonide

Groups	Mediators	Control (n = 17) (pg/mL)	RRD (n = 19)		P Value	
			Baseline (pg/mL)	After IVTA (pg/mL)	C vs B	B vs I
Cytokines	IL-6	21 ± 23	261 ± 674	277 ± 617	<.001 <sup>a</sup>	.27
	IFN-γ	5.4 ± 8.2	16.8 ± 12.7	22.9 ± 9.6	.003 <sup>a</sup>	.04 <sup>b</sup>
	TNF-α	4.0 ± 7.3	3.6 ± 2.9	4.9 ± 2.8	.02 <sup>a</sup>	.02 <sup>b</sup>
Chemokines	MCP-1	177 ± 26	1004 ± 667	591 ± 515	<.001 <sup>a</sup>	<.001 <sup>b</sup>
	MIP-1α	1.3 ± 2.9	0.14 ± 0.28	0.22 ± 0.28	.77	.21
	MIP-1β	11 ± 3.7	33.4 ± 16.7	22.2 ± 10.3	<.001 <sup>a</sup>	.004 <sup>b</sup>
	RANTES	2.8 ± 3.4	3.0 ± 2.4	5.9 ± 3.2	.48	.008 <sup>b</sup>
	Eotaxin	0.0 ± 0.0	22.6 ± 18.7	35.0 ± 21.0	<.001 <sup>a</sup>	.11
	IP-10	485 ± 491	2384 ± 2553	1936 ± 1856	<.001 <sup>a</sup>	.04 <sup>b</sup>
Growth factors	IL-8	4.5 ± 2.9	21.6 ± 11.6	26.7 ± 16.8	<.001 <sup>a</sup>	.20
	VEGF	61 ± 25	123 ± 67	206 ± 117	.003 <sup>a</sup>	<.001 <sup>b</sup>
	bFGF	9.5 ± 8.8	11.9 ± 11.5	20.3 ± 11.5	.35	.009 <sup>b</sup>
	G-CSF	1.9 ± 3.4	19.7 ± 38.9	97.2 ± 107.8	<.001 <sup>a</sup>	<.001 <sup>b</sup>
	GM-CSF	191 ± 37	212 ± 68	275 ± 59	.23	.001 <sup>b</sup>
	PDGF-BB	3.8 ± 5.3	5.3 ± 3.9	9.4 ± 4.1	.06	.007 <sup>b</sup>

B = RRD at baseline; bFGF = basic fibroblast growth factor; C = control; G-CSF = granulocyte colony-stimulating factor; GM-CSF = granulocyte-macrophage colony-stimulating factor; I = RRD after IVTA; IFN-γ = interferon γ; IL-6 = interleukin 6; IL-8 = interleukin 8; IP-10 = interferon gamma-induced protein 10; IVTA = intravitreal injection of triamcinolone acetonide; MCP-1 = monocyte chemoattractant protein 1; MIP-1α = macrophage inflammatory protein 1α; MIP-1β = macrophage inflammatory protein 1β; PDGF-BB = platelet-derived growth factor BB; RANTES = regulated on activation, normal T cell expressed and secreted; RRD = rhegmatogenous retinal detachment; TNF-α = tumor necrosis factor α; VEGF = vascular endothelial growth factor.

<sup>a</sup>Mann-Whitney *U* test.

<sup>b</sup>Wilcoxon signed rank test.

Subjects were recruited from patients referred to the Surgical Retina Service of Tohoku University Hospital. Surgical intervention and follow-up were both performed at this clinic. Informed consent for both the treatment and participation in the research for this prospective study (University Hospital Medical Information Network; UMIN Study ID N.: UMIN000009418) was approved by the institutional review board of Tohoku University Graduate School of Medicine (Prot. N.2006-262, November 20, 2006). Informed consent for both the treatment and participation in the research was obtained from each patient and the research was conducted according to the provisions of the Declaration of Helsinki, 1995 (as revised in Edinburgh, 2000).

• **PATIENTS:** All patients had RRD and were studied in the period before 25GMIVS. The inclusion criterion was clinically detectable RRD. The exclusion criteria were prior vitreous surgery or IVTA, intravitreal anti-vascular endothelial growth factor (VEGF), ocular inflammation, and vitreoretinal or optic nerve diseases. Clinical and demographic characteristics were collected, including age, macular status, extent of RRD, number of retinal breaks, preoperative best-corrected visual acuity (BCVA), 1-month-postoperative BCVA, 6-month-postoperative BCVA, 1-month-postoperative foveal thickness (FT), and 6-month-postoperative FT. BCVA was measured with the

Landolt C visual acuity chart, and the decimal acuities were converted to logarithms of the minimal angle of resolution (logMAR) units. The extent of the RRD was graded 1 to 4 according to the number of quadrants it covered.

• **INTERVENTION:** IVTA was performed in all patients 1 day before 25GMIVS. The TA (Kenacort-A; Bristol-Meyers Squibb, Tokyo, Japan) diluent was replaced with a balanced salt solution (BSS Plus; Alcon Laboratories, Fort Worth, Texas, USA) after Millipore filtration (Millex GS Filter Unit with MF-Millipore MCE Membrane, 0.22 μm; Merck Millipore Ltd., Tullagreen, Carrigtwohill, County Cork, Ireland), and the volume was adjusted so that 0.1 mL contained 4 mg TA. The TA was injected using a 27-gauge needle and a standard pars plana approach (3.5 mm posterior to the limbus). Before performing IVTA, samples of the aqueous humor were collected and the levels of mediators in the anterior chamber were measured. We next performed IVTA, and a day later collected a second aqueous humor sample, before beginning 25GMIVS. During 25GMIVS, we also collected samples of the vitreous. Patients undergoing 25GMIVS for epiretinal membrane (ERM) or macular hole (MH) served as controls.

• **MAIN OUTCOME MEASURE:** We investigated mediator levels in the pre- and post-IVTA aqueous humor, as well as the relationship between mediator levels and clinical findings

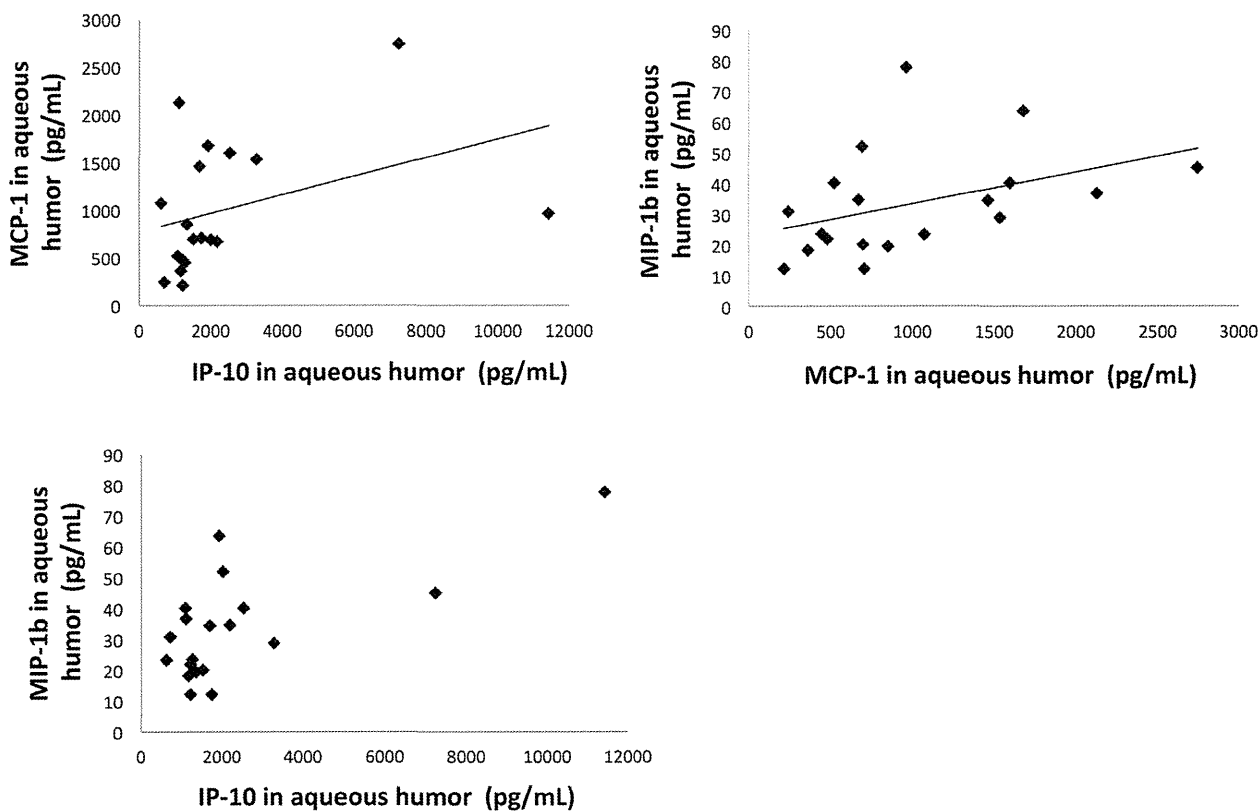


FIGURE 1. Relationship between chemokine levels in the aqueous humor before intravitreal injection of triamcinolone acetonide. (Top left) The aqueous humor level of monocyte chemotactic protein 1 (MCP-1) was significantly correlated with that of interferon  $\gamma$ -induced protein 10 (IP-10) ( $r = 0.48$ ,  $P = .04$ ). (Top right) In addition, the aqueous humor level of MCP-1 was significantly correlated with that of macrophage inflammatory protein 1 $\beta$  (MIP-1 $\beta$ ) ( $r = 0.50$ ,  $P = .03$ ). (Bottom) The aqueous humor level of IP-10 was likely correlated with that of MIP-1 $\beta$ , but not significantly ( $r = 0.44$ ,  $P = .06$ ).

including age, macular status, size of RRD, number of retinal tears, preoperative BCVA, 1-month-postoperative BCVA, 6-month-postoperative BCVA, 1-month-postoperative FT, and 6-month-postoperative FT. We also measured mediator levels in the post-IVTA vitreous.

• **MEASUREMENT OF INFLAMMATORY MEDIATORS:** We withdrew aqueous humor samples before IVTA with a 30-gauge needle, to prevent increasing intraocular pressure later on, after IVTA. We next collected aqueous humor samples 1 day after IVTA, just before 25GMIVS. Special care was taken to avoid touching intraocular tissues (ie, the cornea, the iris, and the lens) and to prevent mixing intraocular samples with other fluids. The samples of aqueous humor (about 100  $\mu$ L) were collected in sterile tubes and were immediately frozen at  $-80$  C. Control samples of the aqueous humor from eyes undergoing vitreous surgery for ERM or MH were collected as controls and were also immediately frozen. The inflammatory mediators we investigated fell into 3 groups: (1) 3 cytokines: interleukin 6 (IL-6), interferon  $\gamma$  (IFN- $\gamma$ ), and TNF- $\alpha$ ; (2) 7 chemokines: MCP-1/CCL2; macrophage inflammatory

protein 1 $\alpha$  (MIP-1 $\alpha$ )/CCL3; macrophage inflammatory protein 1 $\beta$  (MIP-1 $\beta$ )/CCL4; regulated on activation, normal T cell expressed and secreted (RANTES)/CCL5; eotaxin/CCL11; interferon  $\gamma$ -induced protein 10 (IP-10)/CXCL10; and IL-8/CXCL8; and (3) 5 growth factors: VEGF, basic fibroblast growth factor (bFGF), granulocyte colony-stimulating factor (G-CSF), granulocyte-macrophage colony-stimulating factor (GM-CSF), and platelet-derived growth factor BB (PDGF-BB). Samples were analyzed using a multiplex bead analysis system, the Bio-Plex system (Bio-Rad Laboratories, Hercules, California, USA). A custom-made kit (Bio-Plex Human Cytokine Assay; Bio-Rad Laboratories) was used to detect the mediators. For the experiment, aqueous humor and vitreous samples were diluted 4 times with sample diluent (Bio-Rad Laboratories). A total volume of 50  $\mu$ L from each sample was used for the assay. The kits were used according to the manufacturer's instructions.

• **STATISTICAL ANALYSES:** All analyses were performed with Ekuseru-Toukei 2006 software (Social Survey Research Information Co Ltd, Tokyo, Japan). The data

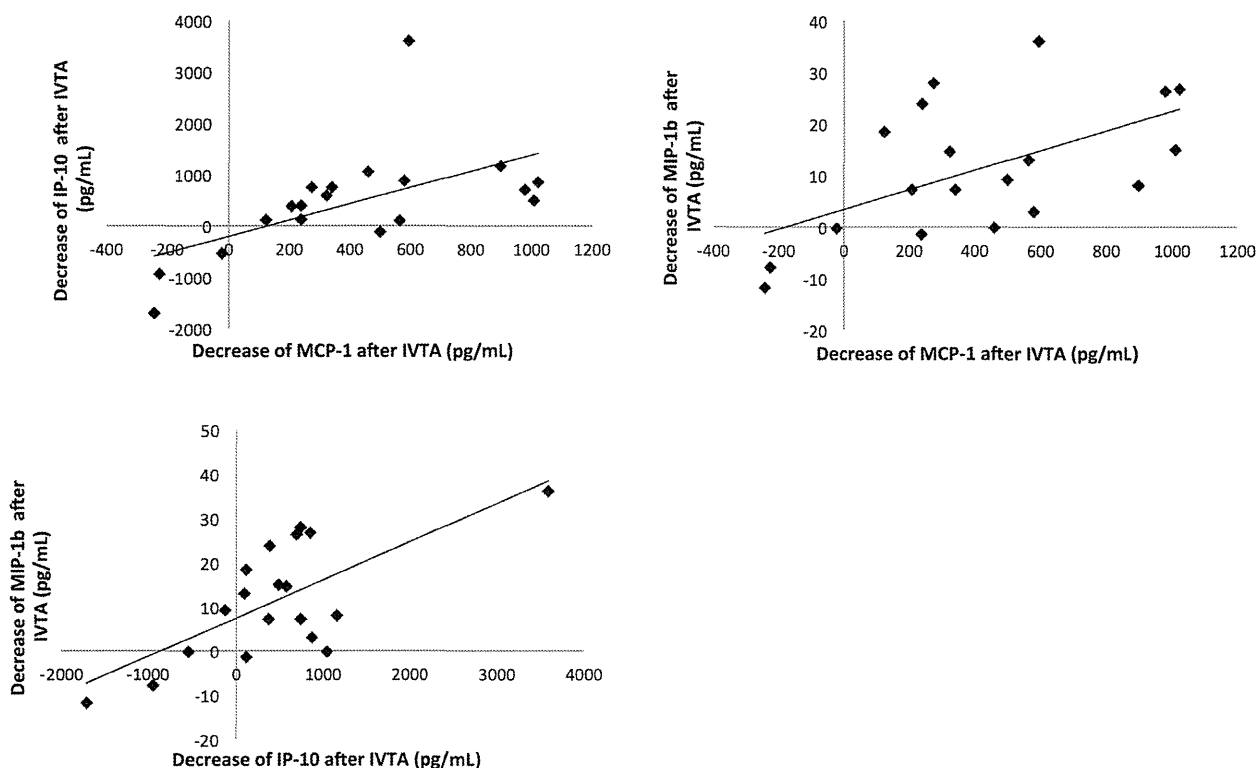


FIGURE 2. Alterations of levels of chemokines in the aqueous humor after intravitreal injection of triamcinolone acetonide. After intravitreal injection of triamcinolone acetonide (IVTA), the aqueous humor levels of monocyte chemoattractant protein 1 (MCP-1), macrophage inflammatory protein 1 $\beta$  (MIP-1 $\beta$ ), and interferon  $\gamma$ -induced protein 10 (IP-10) were significantly reduced ( $P < .001$ ,  $P = .004$ , and  $P = .04$ , respectively). Each mediator showed a correlated decrease with the others (Top left: MCP-1 and IP-10:  $r = 0.69$ ,  $P = .001$ ; Top right: MCP-1 and MIP-1 $\beta$ :  $r = 0.57$ ,  $P = .01$ ; Bottom: IP-10 and MIP-1 $\beta$ :  $r = 0.47$ ,  $P = .04$ ).

are presented as means  $\pm$  standard deviation. The significance of the difference between the pre- and post-IVTA data was assessed by the Wilcoxon signed rank test. The significance of the difference in the concentration of cytokines between eyes with an RRD and control subjects was assessed by the Mann-Whitney  $U$  test. The Spearman coefficient of correlation by rank was calculated to determine the correlation between aqueous humor and vitreous levels of the mediators. The Spearman coefficient of correlation by rank was also calculated to determine the correlation between the cytokine levels in the aqueous humor and clinical findings. The significance of the difference in the concentration of the cytokines between eyes with a macula-off RRD and macula-on RRD was assessed by the Mann-Whitney  $U$  test. A  $P$  value of less than .05 was considered to be statistically significant.

## RESULTS

NINETEEN EYES OF 19 PATIENTS (15 MEN AND 4 WOMEN) WITH RRD were included in this study. The ages of the patients

ranged from 40 to 71 years with a mean of  $56.9 \pm 8.0$  years. Preoperative BCVA was  $0.50 \pm 0.75$  logMAR units and ranged from  $-0.08$  to  $2.00$  logMAR units. One-month-postoperative BCVA was  $0.27 \pm 0.40$  logMAR units and ranged from  $-0.08$  to  $1.22$  logMAR units. Six-month-postoperative BCVA was  $0.11 \pm 0.23$  logMAR units and ranged from  $-0.08$  to  $0.70$  logMAR units. One-month-postoperative BCVA and 6-month-postoperative BCVA were better than preoperative BCVA ( $P = .06$  and  $P = .04$ , respectively). One-month-postoperative FT was  $232.7 \pm 42.4$   $\mu\text{m}$  and ranged from  $156$  to  $306$   $\mu\text{m}$ . Six-month-postoperative FT was  $246.1 \pm 37.1$   $\mu\text{m}$  and ranged from  $170$  to  $300$   $\mu\text{m}$ . The mean follow-up period was  $7.3 \pm 3.5$  months with a range of 2 to 13 months. There were 11 eyes with macula-off RRD and 8 eyes with macula-on RRD. The extent of the RRD was  $1.8 \pm 0.5$  and ranged from 1 to 3. The mean number of retinal tears was  $2.1 \pm 1.8$ . Complete reattachment was finally obtained in all 19 eyes with RRD after surgical intervention following IVTA. No severe adverse events such as endophthalmitis or any systemic side effects were observed in the study. Seventeen patients, including 9 with an ERM and 8 with an MH, were studied as controls.



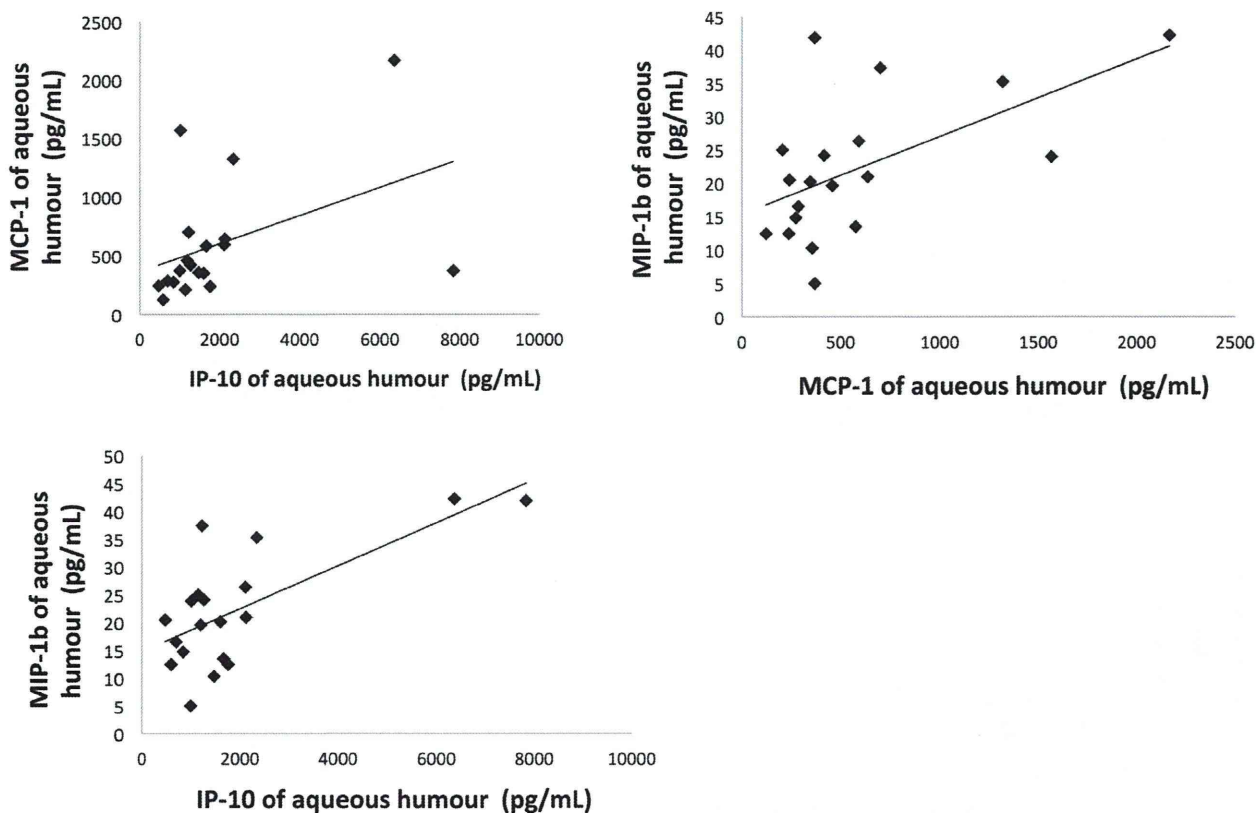


FIGURE 3. Relationship between chemokine levels in the aqueous humor after intravitreal injection of triamcinolone acetonide. (Top left) After intravitreal injection of triamcinolone acetonide, the aqueous humor level of monocyte chemoattractant protein 1 (MCP-1) was significantly correlated with that of interferon  $\gamma$ -induced protein 10 (IP-10) ( $r = 0.55$ ,  $P = .01$ ). (Top right) In addition, the aqueous humor level of MCP-1 was significantly correlated with that of macrophage inflammatory protein 1 $\beta$  (MIP-1 $\beta$ ) ( $r = 0.56$ ,  $P = .01$ ). (Bottom) The aqueous humor level of IP-10 was also significantly correlated with that of MIP-1 $\beta$  ( $r = 0.49$ ,  $P = .03$ ).

At baseline, IL-6, IFN- $\gamma$ , MCP-1, MIP-1 $\beta$ , eotaxin, IP-10, IL-8, VEGF, and G-CSF were detected in the aqueous and were significantly higher in eyes with an RRD than in controls ( $P < .001$ ,  $P = .003$ ,  $P < .001$ ,  $P < .001$ ,  $P < .001$ ,  $P < .001$ ,  $P = .003$ ,  $P < .001$ , respectively) (Table). Before IVTA, the aqueous humor level of MCP-1 was significantly correlated with that of IP-10 ( $r = 0.48$ ,  $P = .04$ ) (Figure 1, Top left). In addition, the aqueous humor level of MCP-1 was also significantly correlated with that of MIP-1 $\beta$  ( $r = 0.50$ ,  $P = .03$ ) (Figure 1, Top right). The aqueous humor level of IP-10 was likely correlated with that of MIP-1 $\beta$ , but not significantly ( $r = 0.44$ ,  $P = .06$ ) (Figure 1, Bottom). After IVTA, the levels of MCP-1, MIP-1 $\beta$ , and IP-10 were significantly reduced ( $P < .001$ ,  $P = .004$ , and  $P = .04$ , respectively) (Table). Each mediator showed a correlated decrease with the others, (MCP-1 and IP-10:  $r = 0.69$ ,  $P = .001$ ; MCP-1 and MIP-1 $\beta$ :  $r = 0.57$ ,  $P = .01$ ; IP-10 and MIP-1 $\beta$ :  $r = 0.47$ ,  $P = .04$ ) (Figure 2; Top left, Top right, and Bottom, respectively). After IVTA, the aqueous humor level of MCP-1 was significantly

correlated with that of IP-10 ( $r = 0.55$ ,  $P = .01$ ) (Figure 3, Top left). In addition, the aqueous humor level of MCP-1 was significantly correlated with that of MIP-1 $\beta$  ( $r = 0.56$ ,  $P = .01$ ) (Figure 3, Top right). The aqueous humor level of IP-10 was also significantly correlated with that of MIP-1 $\beta$  ( $r = 0.49$ ,  $P = .03$ ) (Figure 3, Bottom). After IVTA, the vitreous level of MCP-1 was significantly correlated with the aqueous humor level of MCP-1 ( $r = 0.52$ ,  $P = .03$ ) (Figure 4, Top left). In addition, the vitreous level of IP-10 was significantly correlated with the aqueous humor level of IP-10 ( $r = 0.78$ ,  $P < .001$ ) (Figure 4, Top right). The vitreous level of MIP-1 $\beta$  was significantly correlated with the aqueous humor level of MIP-1 $\beta$  ( $r = 0.86$ ,  $P < .001$ ) (Figure 4, Bottom). After IVTA, the vitreous level of MCP-1 was significantly correlated with that of IP-10 ( $r = 0.71$ ,  $P = .001$ ) (Figure 5, Top left). In addition, the vitreous level of IP-10 was significantly correlated with that of MIP-1 $\beta$  ( $r = 0.58$ ,  $P = .01$ ) (Figure 5, Top right). The vitreous level of MCP-1 was likely correlated with that of MIP-1 $\beta$ , but not significantly ( $r = 0.41$ ,  $P = .09$ ) (Figure 5, Bottom).

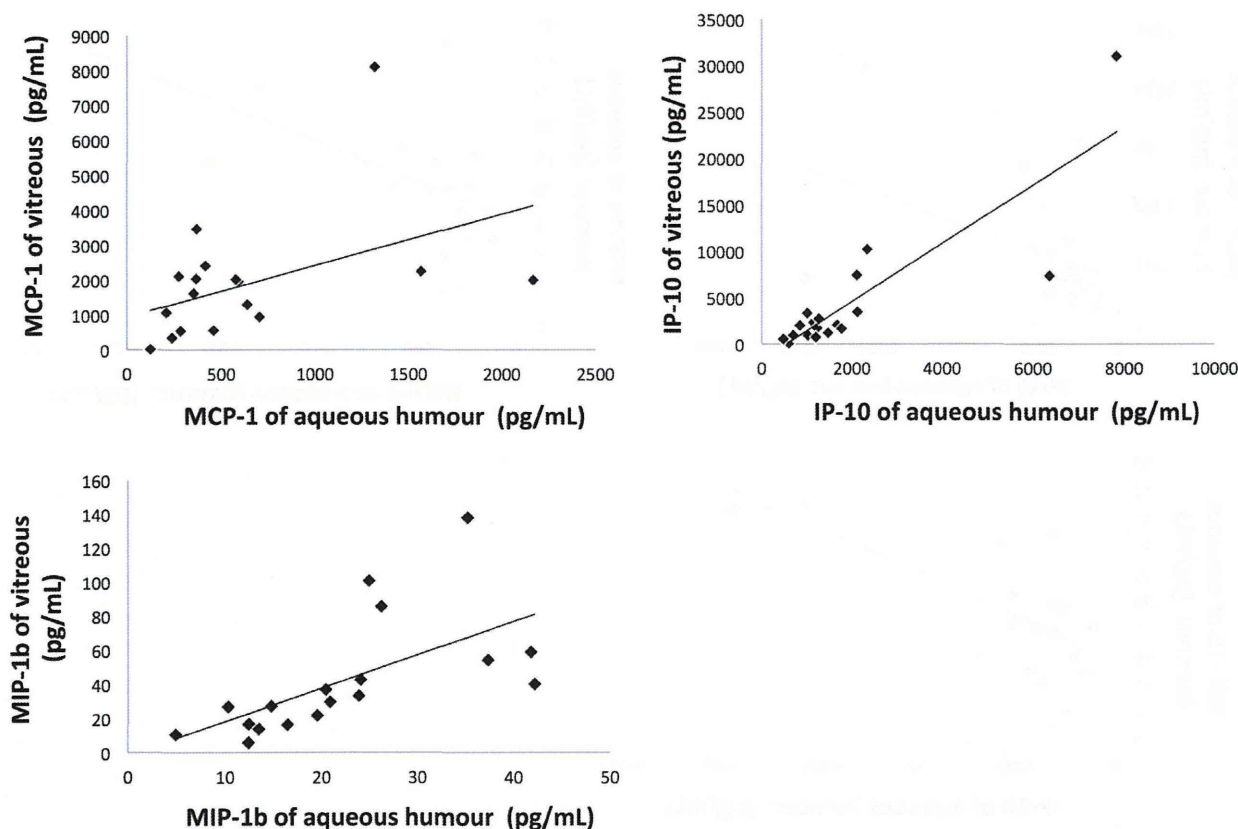


FIGURE 4. Relationship between chemokine levels in the aqueous humor and vitreous after intravitreal injection of triamcinolone acetonide. (Top left) After intravitreal injection of triamcinolone acetonide, the vitreous level of monocyte chemoattractant protein 1 (MCP-1) was significantly correlated with the aqueous humor level of MCP-1 ( $r = 0.52$ ,  $P = .03$ ). (Top right) In addition, the vitreous level of interferon  $\gamma$ -induced protein 10 (IP-10) was significantly correlated with the aqueous humor level of IP-10 ( $r = 0.78$ ,  $P < .001$ ). (Bottom) The vitreous level of macrophage inflammatory protein 1 $\beta$  (MIP-1 $\beta$ ) was significantly correlated with the aqueous humor level of MIP-1 $\beta$  ( $r = 0.86$ ,  $P < .001$ ).

Before IVTA, MCP-1 was higher in eyes with macula-off RRD ( $1337.2 \pm 776.9$  pg/mL) than in eyes with macula-on RRD ( $579.7 \pm 256.8$  pg/mL) ( $P = .03$ ). IL-8 was also higher in eyes with macula-off RRD ( $27.4 \pm 11.4$  pg/mL) than in eyes with macula-on RRD ( $13.7 \pm 7.4$  pg/mL) ( $P = .008$ ). Pre-IVTA eotaxin was significantly correlated with the extent of the RRD ( $r = -0.60$ ,  $P = .007$ ) and pre-IVTA VEGF was weakly correlated with the number of retinal tears ( $r = 0.47$ ,  $P = .04$ ). After IVTA, MCP-1 was higher in eyes with macula-off RRD ( $811.3 \pm 609.2$  pg/mL) than in eyes with macula-on RRD ( $288.5 \pm 101.2$  pg/mL) ( $P = .006$ ). Post-IVTA IFN- $\gamma$  and MIP-1 $\alpha$  were significantly correlated with 1-month-postoperative BCVA ( $r = 0.57$ ,  $P = .01$  and  $r = 0.66$ ,  $P = .002$ , respectively) and post-IVTA VEGF was also significantly correlated with the number of retinal tears ( $r = 0.57$ ,  $P = .01$ ). Post-IVTA bFGF was weakly correlated with 1-month-postoperative BCVA ( $r = 0.47$ ,  $P = .04$ ). Post-IVTA G-CSF was also weakly correlated with 6-month-postoperative FT ( $r = -0.50$ ,  $P = .049$ ).

## DISCUSSION

WE SET OUT TO EVALUATE THE EFFECT OF IVTA ON mediator levels in the aqueous humor of human eyes with RRD. Our baseline measurements showed that levels of IL-6, IFN- $\gamma$ , MCP-1, MIP-1 $\beta$ , eotaxin, IP-10, IL-8, VEGF, and G-CSF were significantly higher in eyes with RRD than in a control group. After IVTA, the levels of MCP-1, MIP-1 $\beta$ , and IP-10 decreased significantly; these decreases were closely correlated to each other. Thus, our study is the first to report IVTA's ability to suppress elevated levels of intraocular MCP-1, MIP-1 $\beta$ , and IP-10 in eyes with RRD (Figure 6). Our study additionally revealed that both before and after IVTA, MCP-1 was higher in eyes with macula-off RRD than in eyes with macula-on RRD.

Our finding that intraocular concentrations of MCP-1, IL-6, IL-8, and VEGF are significantly elevated in patients with RRD confirms existing research.<sup>26-28</sup> Our study also supports existing data showing that the intraocular concentration of TNF- $\alpha$  is not elevated in eyes with



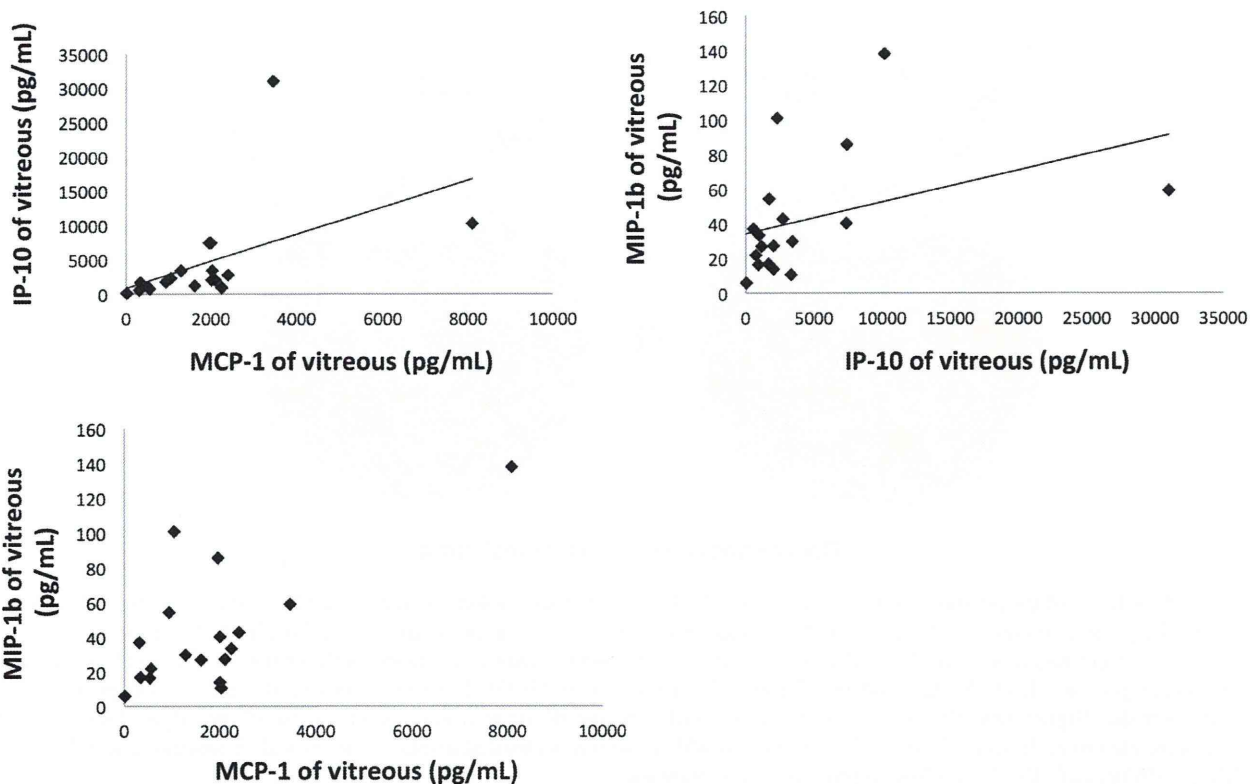


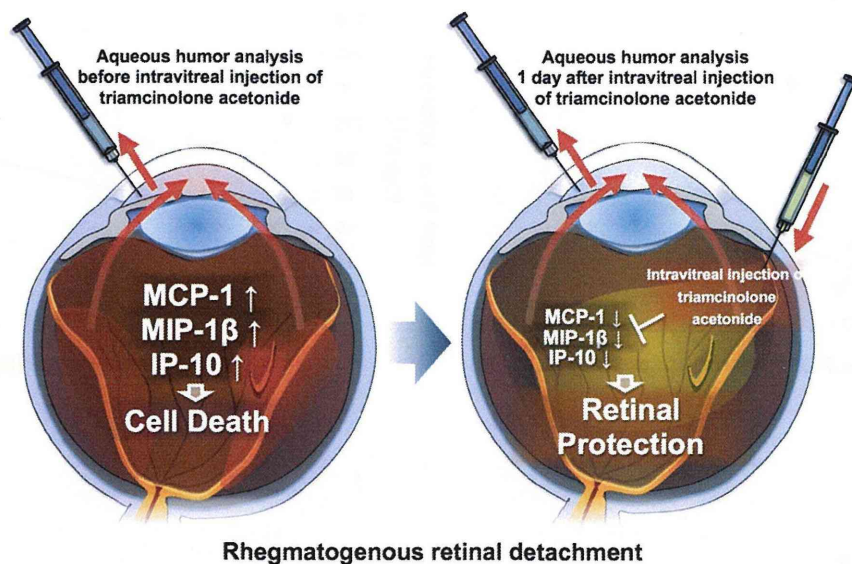
FIGURE 5. Relationship between chemokine levels in vitreous after intravitreal injection of triamcinolone acetonide. (Top left) After intravitreal injection of triamcinolone acetonide, the vitreous level of monocyte chemotactic protein 1 (MCP-1) was significantly correlated with that of interferon  $\gamma$ -induced protein 10 (IP-10) ( $r = 0.71$ ,  $P = .001$ ). (Top right) In addition, the vitreous level of IP-10 was significantly correlated with that of macrophage inflammatory protein 1 $\beta$  (MIP-1 $\beta$ ) ( $r = 0.58$ ,  $P = .01$ ). (Bottom) The vitreous level of MCP-1 was likely correlated with that of MIP-1 $\beta$ , but not significantly ( $r = 0.41$ ,  $P = .09$ ).

RRD.<sup>26</sup> Interestingly, however, our data showed that corticosteroid cannot suppress TNF- $\alpha$ , contradicting our earlier work with an animal model.<sup>14</sup> The exact reason for this is unclear, but there were many differences between the earlier study and the present one besides the use of, respectively, animal and human subjects. The type of intraocular sample also differed (retinal in the animal study vs aqueous humor in the present one), as did the length of corticosteroid intervention (3 days vs 1 day), delivery method for the medication (intraperitoneal vs intravitreal injection), and method of analysis (mRNA quantification with RT-PCR vs protein quantification by multiplex bead analysis system).<sup>14</sup> Furthermore, it is also possible that the chemokines differ in their rate of clearance from the anterior chamber, and TNF- $\alpha$  might clear more slowly from the anterior chamber than MCP-1, MIP-1 $\beta$ , or IP-10.

The use of IVTA to treat eyes with proliferative ocular disease was part of a series of pioneering achievements in ophthalmology in the 1980s. Researchers at that time used animal models to show IVTA's capacity to inhibit fibroblast growth and significantly reduce the rate of retinal detachment.<sup>29</sup> Since then, it has become widely used in clinical practice in eyes with a broad range of retinal

diseases, including uveitis, diabetic macular edema, retinal vein occlusion, and age-related macular degeneration.<sup>20,21,23-25</sup> Drug therapies in general have not yet been considered for eyes with RRD, as the priority has been improving methods for surgical reattachment. There are many patients, however, whose visual function does not recover completely, even after complete reattachment, because of retinal cell death in the time surrounding surgical intervention. Now that excellent surgical techniques, such as 25GMIVS, have established a very high reattachment rate,<sup>1-10</sup> the time has come to consider methods to address this gap in treatment.

We believe that IVTA, if performed promptly, can suppress photoreceptor apoptosis between RRD diagnosis and surgical intervention. The key to retinal protection during this period, as shown by initial studies using animal models, is control of the levels of several intraocular mediators, including MCP-1 and TNF- $\alpha$ .<sup>14-16</sup> These studies reported that the application of corticosteroid achieved this control for MCP-1, lowering its intraocular expression and suppressing photoreceptor death. We are the first to further demonstrate that the application of corticosteroid also reduces MCP-1 in human eyes with RRD. This is an



**FIGURE 6.** Schema of the protective effect of intravitreal injection of triamcinolone acetonide (IVTA) on retinal photoreceptors in eyes with rhegmatogenous retinal detachment. There was a relationship between intraocular chemokine levels before and after IVTA in eyes with rhegmatogenous retinal detachment. (Left) At the baseline, monocyte chemoattractant protein 1 (MCP-1), macrophage inflammatory protein 1 $\beta$  (MIP-1 $\beta$ ), and interferon  $\gamma$ -induced protein 10 (IP-10) were significantly higher in eyes with RRD than in controls. (Right) After IVTA, levels of MCP-1, MIP-1 $\beta$ , and IP-10 were significantly reduced, and these decreases were closely correlated to each other. Using IVTA, it was possible to suppress elevated levels of the critical intraocular chemokines (ie, MCP-1, MIP-1 $\beta$ , and IP-10) that lead to photoreceptor apoptosis.

important finding, because if the interval between RRD diagnosis and surgery is long, significant apoptosis can occur. This interval can vary depending on individual clinics, standards of care in different countries, and patients' lives.<sup>30,31</sup> Our results showed that MCP-1 levels were more elevated in eyes with macula-off RRD, a particularly relevant finding given that this type of RRD is known to lead to severe central visual disturbance postoperatively. The nature of IVTA means that it is especially appropriate if buckling is chosen as an RRD therapy, because that procedure keeps the entire vitreous intact in the eye. The injected corticosteroid can thus continue to suppress apoptosis even after surgery. In short, then, although it may not be possible to restore photoreceptors that have already undergone apoptosis, we believe that IVTA can help ensure the survival of the remaining photoreceptors.

The precise relationship between MCP-1, MIP-1 $\beta$ , and IP-10, and their role in apoptosis in eyes with RRD, remains unclear. As we have already reported, the first of these controllable mediators, MCP-1, exhibits increased expression in animal models in the Muller glia and macrophage/microglia.<sup>14-16</sup> MCP-1 can contribute to monocyte recruitment in areas where the outer retina has detached during the pathogenesis of RRD. The second mediator, MIP-1 $\beta$ , is a member of the C-C subfamily of chemokines, like MCP-1. Recent animal studies showed that MIP-1 $\beta$  is the most upregulated chemokine, and that it is involved in the recruitment of bone marrow-derived monocyte lineage

cells to the hypoxic retina.<sup>32,33</sup> Since RRD causes hypoxia in the detached area of the outer retina, it is thus understandable that MIP-1 $\beta$  levels rise. MIP-1 $\beta$  is also upregulated in human eyes with macular edema associated with branch retinal vein occlusion, and is significantly reduced after IVTA.<sup>34</sup> In this clinical study, a decrease in foveal thickness after IVTA was directly correlated with a decrease in MIP-1 $\beta$ .<sup>34</sup> Thus, it may not be surprising that MCP-1 and MIP-1 $\beta$  were expressed in eyes with RRD, as RRD leads to retinal ischemia and inflammation. The third mediator, IP-10, belongs to the group of  $\alpha$ -chemokines. It has been reported to be significantly associated with increased levels of MCP-1 in vitreous samples from patients with RRD and proliferative diabetic retinopathy.<sup>35</sup> The relationship between these 3 upregulated and controllable chemokines, however, remains unclear, and should be the subject of future research. If their antibodies were injected in animal eyes with RRD and the response analyzed, the chemokines' pathway and order of expression could be clarified. Although it may be impossible to detect caspase 3 activity in the aqueous humor or vitreous, it should be possible in the retina.<sup>36</sup> A more direct assay of apoptosis, therefore, such as an anti-cleaved caspase 3 test, might also demonstrate that retinal apoptosis is regulated after IVTA, clearly confirming our hypothesis.

Our study was thus limited by the lack of a direct assay of apoptosis, as well as a small sample size, an interval between administration of IVTA and analysis of its effects that was



necessarily short because of ethical considerations, and a lack of clinical, morphologic, and functional findings from a comparison between an IVTA group and a non-IVTA group. Nevertheless, we believe our results show that IVTA is currently the best way to suppress intraocular mediators and reduce photoreceptor death in eyes with RRD, at least until the antibodies for these mediators are ready for clinical use.

In conclusion, our findings show that elevated MCP-1, MIP-1 $\beta$ , and IP-10 in human eyes with RRD can be

controlled with the application of IVTA. The decreases after IVTA in MCP-1, MIP-1 $\beta$ , and IP-10 were closely correlated to each other. Preconditioning with IVTA suppressed levels of intraocular MCP-1, MIP-1 $\beta$ , and IP-10, chemokines that, when elevated, can lead to photoreceptor apoptosis in eyes with RRD. Further investigation is needed to evaluate the relationship between these chemokines and clinical findings of postoperative visual quality and complications to determine the efficacy of IVTA.

---

ALL AUTHORS HAVE COMPLETED AND SUBMITTED THE ICMJE FORM FOR DISCLOSURE OF POTENTIAL CONFLICTS OF INTEREST and none were reported. Publication of this article was supported in part by research grants from the Ministry of Education, Culture, Sports, Science and Technology, Tokyo, Japan (Grant-in-Aid for Young Scientists [B] 22791648). Contributions of authors: involved in design and conduct of the study (H.K., T.N.); collection, management, analysis, and interpretation of the data (H.K., M.Y., N.A., Y.T.); and preparation, review, or approval of the manuscript (T.A., T.N.).

---

## REFERENCES

1. Kunikata H, Abe T, Nishida K. Successful outcomes of 25- and 23-gauge vitrectomies for giant retinal tear detachments. *Ophthalmic Surg Lasers Imaging* 2011;42(6):487–492.
2. Kunikata H, Nishida K. Visual outcome and complications of 25-gauge vitrectomy for rhegmatogenous retinal detachment; 84 consecutive cases. *Eye (Lond)* 2010;24(6):1071–1077.
3. Kobayashi S, Sato S, Inoue M, et al. Comparison of 20- and 25-gauge vitrectomy for primary repair of rhegmatogenous retinal detachment. *Ophthalmic Surg Lasers Imaging* 2010; 41(5):550–554.
4. Carifi G. Outcomes and complications of rhegmatogenous retinal detachment repair with selective sutureless 25-gauge pars plana vitrectomy. *Am J Ophthalmol* 2010;150(5):757–758. author reply 758.
5. Bourla DH, Bor E, Axer-Siegel R, Mimouni K, Weinberger D. Outcomes and complications of rhegmatogenous retinal detachment repair with selective sutureless 25-gauge pars plana vitrectomy. *Am J Ophthalmol* 2010;149(4):630–634.e1.
6. Von Fricken MA, Kunjukunju N, Weber C, Ko G. 25-Gauge sutureless vitrectomy versus 20-gauge vitrectomy for the repair of primary rhegmatogenous retinal detachment. *Retina* 2009;29(4):444–450.
7. Mura M, Tan SH, De Smet MD. Use of 25-gauge vitrectomy in the management of primary rhegmatogenous retinal detachment. *Retina* 2009;29(9):1299–1304.
8. Miller DM, Riemann CD, Foster RE, Petersen MR. Primary repair of retinal detachment with 25-gauge pars plana vitrectomy. *Retina* 2008;28(7):931–936.
9. Lai MM, Ruby AJ, Sarrafzadeh R, et al. Repair of primary rhegmatogenous retinal detachment using 25-gauge transconjunctival sutureless vitrectomy. *Retina* 2008;28(5): 729–734.
10. Acar N, Kapran Z, Altan T, Unver YB, Yurtsever S, Kucuksumer Y. Primary 25-gauge sutureless vitrectomy with oblique sclerotomies in pseudophakic retinal detachment. *Retina* 2008;28(8):1068–1074.
11. Wakabayashi T, Oshima Y, Fujimoto H, et al. Foveal microstructure and visual acuity after retinal detachment repair: imaging analysis by Fourier-domain optical coherence tomography. *Ophthalmology* 2009;116(3):519–528.
12. Capeans C, De Rojas MV, Lojo S, Salorio MS. C-C chemokines in the vitreous of patients with proliferative vitreoretinopathy and proliferative diabetic retinopathy. *Retina* 1998;18(6):546–550.
13. Abu el-Asrar AM, Van Damme J, Put W, et al. Monocyte chemoattractant protein-1 in proliferative vitreoretinal disorders. *Am J Ophthalmol* 1997;123(5):599–606.
14. Nakazawa T, Kayama M, Ryu M, et al. Tumor necrosis factor- $\alpha$  mediates photoreceptor death in a rodent model of retinal detachment. *Invest Ophthalmol Vis Sci* 2011;52(3): 1384–1391.
15. Nakazawa T, Hisatomi T, Nakazawa C, et al. Monocyte chemoattractant protein 1 mediates retinal detachment-induced photoreceptor apoptosis. *Proc Natl Acad Sci U S A* 2007;104(7):2425–2430.
16. Nakazawa T, Matsubara A, Noda K, et al. Characterization of cytokine responses to retinal detachment in rats. *Mol Vis* 2006;12:867–878.
17. Soheilian M, Garfami KH, Ramezani A, Yaseri M, Peyman GA. Two-year results of a randomized trial of intravitreal bevacizumab alone or combined with triamcinolone versus laser in diabetic macular edema. *Retina* 2012; 32(2):314–321.
18. Noma H, Funatsu H, Mimura T, Shimada K. Macular sensitivity and morphology after intravitreal injection of triamcinolone acetonide for macular edema with branch retinal vein occlusion. *Retina* 2012;32(9):1844–1852.
19. Shimura M, Yasuda K, Nakazawa T, et al. Visual outcome after intravitreal triamcinolone acetonide depends on optical coherence tomographic patterns in patients with diffuse diabetic macular edema. *Retina* 2011;31(4):748–754.
20. Bae JH, Lee CS, Lee SC. Efficacy and safety of intravitreal bevacizumab compared with intravitreal and posterior sub-tenon triamcinolone acetonide for treatment of uveitic cystoid macular edema. *Retina* 2011;31(1):111–118.
21. Ahmadi H, Taei R, Riazi-Esfahani M, et al. Intravitreal bevacizumab versus combined intravitreal bevacizumab and triamcinolone for neovascular age-related macular

- degeneration: six-month results of a randomized clinical trial. *Retina* 2011;31(9):1819–1826.
22. Bergstrom CS, Hubbard GB 3rd. Combination intravitreal triamcinolone injection and cryotherapy for exudative retinal detachments in severe Coats disease. *Retina* 2008;28(3 Suppl): S33–S37.
  23. Park CH, Jaffe GJ, Fekrat S. Intravitreal triamcinolone acetate in eyes with cystoid macular edema associated with central retinal vein occlusion. *Am J Ophthalmol* 2003; 136(3):419–425.
  24. Martidis A, Duker JS, Greenberg PB, et al. Intravitreal triamcinolone for refractory diabetic macular edema. *Ophthalmology* 2002;109(5):920–927.
  25. Antcliff RJ, Spalton DJ, Stanford MR, Graham EM, ffytche TJ, Marshall J. Intravitreal triamcinolone for uveitic cystoid macular edema: an optical coherence tomography study. *Ophthalmology* 2001;108(4):765–772.
  26. Rasier R, Gormus U, Artunay O, Yuzbasioglu E, Oncel M, Bahcecioglu H. Vitreous levels of VEGF, IL-8, and TNF-alpha in retinal detachment. *Curr Eye Res* 2010;35(6): 505–509.
  27. Yoshimura T, Sonoda KH, Sugahara M, et al. Comprehensive analysis of inflammatory immune mediators in vitreoretinal diseases. *PLoS One* 2009;4(12):e8158.
  28. Mitamura Y, Takeuchi S, Yamamoto S, et al. Monocyte chemotactic protein-1 levels in the vitreous of patients with proliferative vitreoretinopathy. *Jpn J Ophthalmol* 2002; 46(2):218–221.
  29. Tano Y, Chandler D, Machemer R. Treatment of intraocular proliferation with intravitreal injection of triamcinolone acetate. *Am J Ophthalmol* 1980;90(6):810–816.
  30. Mitry D, Awan MA, Borooah S, et al. Long-term visual acuity and the duration of macular detachment: findings from a prospective population-based study. *Br J Ophthalmol* 2013;97(2):149–152.
  31. Ehrlich R, Niederer RL, Ahmad N, Polkinghorne P. Timing of acute macula-on rhegmatogenous retinal detachment repair. *Retina* 2013;33(1):105–110.
  32. Ishikawa K, Yoshida S, Nakao S, et al. Bone marrow-derived monocyte lineage cells recruited by MIP-1beta promote physiological revascularization in mouse model of oxygen-induced retinopathy. *Lab Invest* 2012;92(1):91–101.
  33. Ishikawa K, Yoshida S, Kadota K, et al. Gene expression profile of hyperoxic and hypoxic retinas in a mouse model of oxygen-induced retinopathy. *Invest Ophthalmol Vis Sci* 2010;51(8):4307–4319.
  34. Kunikata H, Shimura M, Nakazawa T, et al. Chemokines in aqueous humour before and after intravitreal triamcinolone acetate in eyes with macular oedema associated with branch retinal vein occlusion. *Acta Ophthalmol* 2010;90(2):162–167.
  35. Abu El-Asrar AM, Struyf S, Kangave D, Geboes K, Van Damme J. Chemokines in proliferative diabetic retinopathy and proliferative vitreoretinopathy. *Eur Cytokine Netw* 2006;17(3):155–165.
  36. Woo TT, Li SY, Lai WW, Wong D, Lo AC. Neuroprotective effects of lutein in a rat model of retinal detachment. *Graefes Arch Clin Exp Ophthalmol* 2013;251(1):41–51.