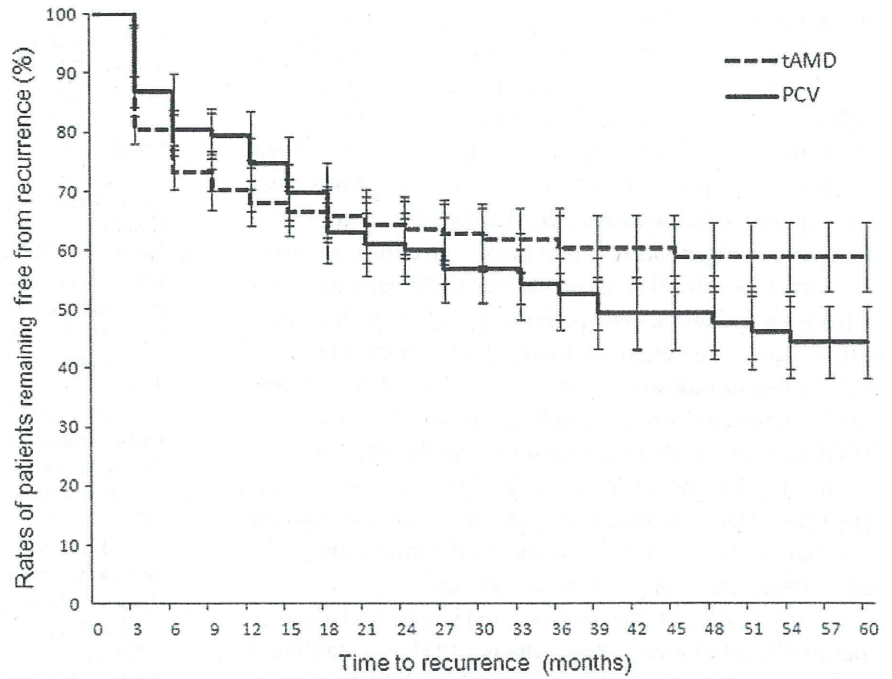


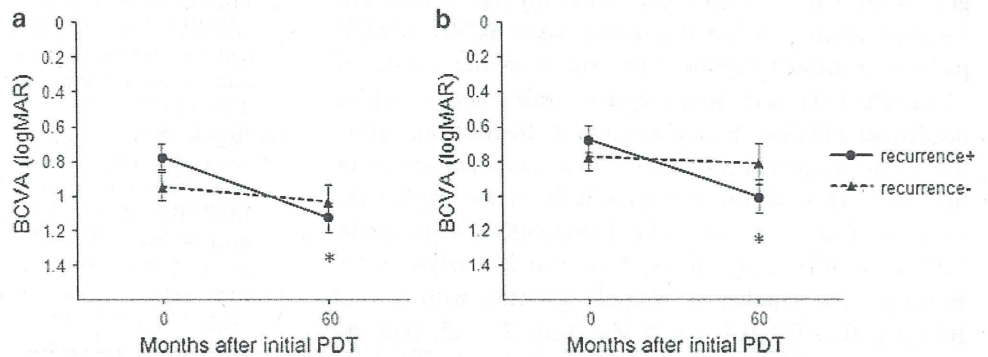
Fig. 3 Kaplan-Meier estimates of the rates (%) of patients remaining free from recurrence. The time to recurrence after complete resolution by PDT was measured. *Dashed line* tAMD; *solid line* PCV. Values are presented as means \pm SEMs



Sample sizes over time

tAMD	139	139	139	134	131	123	91	77	77	74	74
PCV	107	107	107	103	100	84	76	66	66	65	65

Fig. 4 Mean changes in BCVA between baseline and 60 months after the initial PDT in tAMD (a) and PCV (b) patients followed up for 60 months after initial PDT with/without the recurrence of the lesions. Triangle with *dashed line* recurrence -; circle with *solid line* recurrence +. Values are presented as means \pm SEMs. * $P < 0.005$ compared with baseline



findings, except for the lesion phenotype with a longer follow-up period. Since a better BCVA and a smaller GLD likely indicate a lower activity of the lesion, it is reasonable that the treatment for a lower activity lesion results in a better prognosis. We could not determine which lesion phenotype is a significant prognostic factor for visual outcome at 60 months after the initial PDT, probably owing to the influence of lesion recurrences after 12 months post-PDT. Notably, the number of treatments until 60 months of follow-up did not differ between the tAMD and PCV groups, although it was significantly less in the PCV group at 12 months of follow-up, as was also shown in our previous study [22]. These results indicate that the recurrence of PCV lesions occurred later than the recurrence of tAMD lesions after PDT. Figure 3 shows that the recurrence rate in the PCV group crossed over the line for the tAMD group at 15 months after the initial resolution of the lesions. This supports the importance of continuous long-term

observations after PDT, particularly for PCV patients, and suggests the necessity of some prevention strategies against the recurrence of these lesions because recurrent PCV may have lower susceptibility to PDT than naïve lesions. However, it is also true that PDT showed a significantly longer duration of attenuating the recurrences in PCV than in tAMD, which will be encouraging for Japanese AMD patients treated with PDT because PCV is a major phenotype of AMD in the Japanese population [8].

Recently, results of a multicenter study conducted to compare the effects of PDT and ranibizumab therapy in patients with PCV showed that both therapies as well as their combination (PDT + ranibizumab) therapy resulted in improvements in the patients' visual acuity at 6 months posttreatment [29]. In addition, PDT monotherapy and combination therapy achieved a significantly higher proportion of patients with complete polyp regression at 6 months than did ranibizumab monotherapy. However,

our results suggest that PDT monotherapy has a limitation in its effects against PCV at over 60 months. Since we do not have long-term data on anti-VEGF monotherapy or combination therapy for PCV lesions, whether PDT, anti-VEGF therapy, or combination therapy is more beneficial for visual outcome in PCV remains unknown. Since previous studies have demonstrated significantly better visual outcomes with monthly intravitreal injections of ranibizumab than with PDT in exudative AMD patients (most of them were likely tAMD patients) [12, 13], further study will be needed to determine the long-term effectiveness of each treatment modality against PCV. A number of recent studies conducted on the combination of PDT plus anti-VEGF therapy yielded better results than did PDT alone in treating tAMD and PCV [29–32]. However, data on the long-term effects of monotherapies for each phenotype are essential as the baseline outcome to determine the long-term effectiveness of combination therapy.

The limitation of the present study was its lack of a control (placebo) group; thus, whether PDT has significant effects in stabilizing vision in tAMD and PCV patients over 60 months of follow-up is unknown. Although the TAP and VIP studies showed that vision in the placebo groups was reduced over 2 years of follow-up [26, 33] and we have recently reported that the mean BCVA of PCV patients worsened significantly over a natural course of 12 months [34], data from long-term observations may be needed. In addition, those patients who dropped out during the follow-up period might have influenced the results of this study. This number of dropout patients may explain the relatively worse long-term visual outcome than that of the TAP Extension study in the time course analysis [24]. However, the number of dropout patients with a final BCVA ≤ 0.1 , 0.1–0.4, and ≥ 0.4 were 23, 25, and 20, respectively, which was evenly distributed and unlikely to have caused a significant difference in the results of the present study even after correction with the Last-Observation-Carried-Forward method. In addition, the findings of the present study will be useful for comparison of the long-term effects of PDT in tAMD and PCV patients.

In conclusion, PDT monotherapy may have benefits for the visual outcome of PCV patients as compared with tAMD until 12 months after the initial treatment. However, these advantages were not sustained after 5 years of follow-up in a Japanese population owing to recurrence of the lesions.

References

1. Cook HL, Patel PJ, Tufail A. Age-related macular degeneration: diagnosis and management. *Br Med Bull*. 2008;85:127–49.
2. Ding X, Patel M, Chan CC. Molecular pathology of age-related macular degeneration. *Prog Retin Eye Res*. 2009;28:1–18.
3. Yannuzzi LA, Sorenson J, Spaide RF, Lipson B. Idiopathic polypoidal choroidal vasculopathy (PCV). *Retina*. 1990;10:1–8.
4. Uyama M, Matsubara T, Fukushima I, Matsunaga H, Iwashita K, Nagai Y, et al. Idiopathic polypoidal choroidal vasculopathy in Japanese patients. *Arch Ophthalmol*. 1999;117:1035–42.
5. Yannuzzi LA, Ciardella A, Spaide RF, Rabb M, Freund KB, Orlock DA. The expanding clinical spectrum of idiopathic polypoidal choroidal vasculopathy. *Arch Ophthalmol*. 1997;115:478–85.
6. Spaide RF, Yannuzzi LA, Slakter JS, Sorenson J, Orlach DA. Indocyanine green videoangiography of idiopathic polypoidal choroidal vasculopathy. *Retina*. 1995;15:100–10.
7. Ciardella AP, Donsoff IM, Huang SJ, Costa DL, Yannuzzi LA. Polypoidal choroidal vasculopathy. *Surv Ophthalmol*. 2004;49:25–37.
8. Maruko I, Iida T, Saito M, Nagayama D, Saito K. Clinical characteristics of exudative age-related macular degeneration in Japanese patients. *Am J Ophthalmol*. 2007;144:15–22.
9. Yannuzzi LA, Negrao S, Iida T, Carvalho C, Rodriguez-Coleman H, Slakter J, et al. Retinal angiomatic proliferation in age-related macular degeneration. *Retina*. 2001;21:416–34.
10. Boscia F, Parodi MB, Furino C, Reibaldi M, Sborgia C. Photodynamic therapy with verteporfin for retinal angiomatic proliferation. *Graefes Arch Clin Exp Ophthalmol*. 2006;244:1224–32.
11. Krebs I, Krepler K, Stolba U, Goll A, Binder S. Retinal angiomatic proliferation: combined therapy of intravitreal triamcinolone acetonide and PDT versus PDT alone. *Graefes Arch Clin Exp Ophthalmol*. 2008;246:237–43.
12. Brown DM, Michels M, Kaiser PK, Heier JS, Sy JP, Janchulev T, ANCHOR Study Group. Ranibizumab versus verteporfin photodynamic therapy for neovascular age-related macular degeneration: two-year results of the ANCHOR study. *Ophthalmology*. 2009;116:57–65.
13. Bressler NM, Chang TS, Fine JT, Dolan CM, Ward J, Anti-VEGF Antibody for the Treatment of Predominantly Classic Choroidal Neovascularization in Age-Related Macular Degeneration (ANCHOR) Research Group. Improved vision-related function after ranibizumab vs photodynamic therapy: a randomized clinical trial. *Arch Ophthalmol*. 2009;127:13–21.
14. Matsumiya W, Honda S, Bessho H, Kusahara S, Tsukahara Y, Negi A. Early responses to intravitreal ranibizumab in typical neovascular age-related macular degeneration and polypoidal choroidal vasculopathy. *J Ophthalmol*. 2011;74:2020. doi:10.1155/2011/742020.
15. Tsujikawa A, Ooto S, Yamashiro K, Tamura H, Otani A, Yoshimura N. Treatment of polypoidal choroidal vasculopathy by intravitreal injection of bevacizumab. *Jpn J Ophthalmol*. 2010;54:310–9.
16. Gomi F, Sawa M, Sakaguchi H, Tsujikawa M, Oshima Y, Kamei M, et al. Efficacy of intravitreal bevacizumab for polypoidal choroidal vasculopathy. *Br J Ophthalmol*. 2008;92:70–3.
17. Stangos AN, Gandhi JS, Nair-Sahni J, Heimann H, Pournaras CJ, Harding SP. Polypoidal choroidal vasculopathy masquerading as neovascular age-related macular degeneration refractory to ranibizumab. *Am J Ophthalmol*. 2010;150:666–73.
18. Chan WM, Lam DS, Lai TY, Liu DT, Li KK, Yao Y, et al. Photodynamic therapy with verteporfin for symptomatic polypoidal choroidal vasculopathy. *Ophthalmology*. 2004;111:1576–84.
19. Akaza E, Yuzawa M, Matsumoto Y, Kashiwakura S, Fujita K, Mori R. Role of photodynamic therapy in polypoidal choroidal vasculopathy. *Jpn J Ophthalmol*. 2007;51:270–7.
20. Gomi F, Ohji M, Sayanagi K, Sawa M, Sakaguchi H, Oshima Y, et al. One-year outcomes of photodynamic therapy in age-related macular degeneration and polypoidal choroidal vasculopathy in Japanese patients. *Ophthalmology*. 2008;115:141–6.

21. Kurashige Y, Otani A, Sasahara M, Yodoi Y, Tamura H, Tsujikawa A, et al. Two-year results of photodynamic therapy for polypoidal choroidal vasculopathy. *Am J Ophthalmol.* 2008;146: 513–9.
22. Honda S, Imai H, Yamashiro K, Kurimoto Y, Kanamori-Matsui N, Kagotani Y, et al. Comparative assessment of photodynamic therapy for typical age-related macular degeneration and polypoidal choroidal vasculopathy: a multicenter study in Hyogo prefecture, Japan. *Ophthalmologica.* 2009;223:333–8.
23. Honda S, Kurimoto Y, Kagotani Y, Yamamoto H, Takagi H, Uenishi M, Hyogo Macular Disease Study Group. Photodynamic therapy for typical age-related macular degeneration and polypoidal choroidal vasculopathy: a 30-month multicenter study in Hyogo, Japan. *Jpn J Ophthalmol.* 2009;53:593–7.
24. Kaiser PK, Treatment of Age-Related Macular Degeneration with Photodynamic Therapy (TAP) Study Group. Verteporfin therapy of subfoveal choroidal neovascularization in age-related macular degeneration: 5-year results of two randomized clinical trials with an open-label extension: TAP report no. 8. *Graefes Arch Clin Exp Ophthalmol.* 2006;244:1132–42.
25. Treatment of Age-Related Macular Degeneration with Photodynamic Therapy (TAP) Study Group. Photodynamic therapy of subfoveal choroidal neovascularization in age-related macular degeneration with verteporfin. One-year results of 2 randomized clinical trials: TAP report 1. *Arch Ophthalmol.* 1999;117: 1329–45.
26. Verteporfin in Photodynamic Therapy Study Group. Verteporfin therapy of subfoveal choroidal neovascularization in age-related macular degeneration: two-year results of a randomized clinical trial including lesions with occult with no classic choroidal neovascularization: verteporfin in photodynamic therapy report 2. *Am J Ophthalmol.* 2001;131:541–60.
27. Fung AE, Lalwani GA, Rosenfeld PJ, Dubovy SR, Michels S, Feuer WJ, et al. An optical coherence tomography-guided, variable dosing regimen with intravitreal ranibizumab (Lucentis) for neovascular age-related macular degeneration. *Am J Ophthalmol.* 2007;143:566–83.
28. Potter MJ, Szabo SM. Recurrence of choroidal neovascularisation after photodynamic therapy in patients with age-related macular degeneration. *Br J Ophthalmol.* 2007;91:753–6.
29. Koh A, Lee WK, Chen LJ, Chen SJ, Hashad Y, Kim H, et al. EVEREST STUDY: efficacy and safety of verteporfin photodynamic therapy in combination with ranibizumab or alone versus ranibizumab monotherapy in patients with symptomatic macular polypoidal choroidal vasculopathy. *Retina.* 2012;32:1453–64.
30. Heier JS, Boyer DS, Ciulla TA, Ferrone PJ, Jumper JM, Gentile RC, FOCUS Study Group, et al. Ranibizumab combined with verteporfin photodynamic therapy in neovascular age-related macular degeneration: year 1 results of the FOCUS Study [published correction appears in *Arch Ophthalmol.* 2007;125:138]. *Arch Ophthalmol.* 2006;124:1532–42.
31. Antoszyk AN, Tuomi L, Chung CY, Singh A, FOCUS Study Group. Ranibizumab combined with verteporfin photodynamic therapy in neovascular age-related macular degeneration (FOCUS): year 2 results. *Am J Ophthalmol.* 2008;145:862–74.
32. Hara R, Kawaji T, Inomata Y, Tahara J, Sagara N, Fukushima M, et al. Photodynamic therapy alone versus combined with intravitreal bevacizumab for neovascular age-related macular degeneration without polypoidal choroidal vasculopathy in Japanese patients. *Graefes Arch Clin Exp Ophthalmol.* 2010;248:931–6.
33. Bressler NM, Treatment of Age-Related Macular Degeneration with Photodynamic Therapy (TAP) Study Group. Photodynamic therapy of subfoveal choroidal neovascularization in age-related macular degeneration with verteporfin: two-year results of 2 randomized clinical trials-tap report 2. *Arch Ophthalmol.* 2001; 119:198–207.
34. Bessho H, Honda S, Imai H, Negi A. Natural course and fundusoscopic findings of polypoidal choroidal vasculopathy in a Japanese population over 1 year of follow-up. *Retina.* 2011;31: 1598–602.

Five-year results of photodynamic therapy with verteporfin for Japanese patients with neovascular age-related macular degeneration

This article was published in the following Dove Press journal:
Clinical Ophthalmology
26 March 2013
Number of times this article has been viewed

Takashi Tsuchihashi
Keisuke Mori
Kazuhiro Ueyama
Shin Yoneya

Department of Ophthalmology,
Saitama Medical University, Iruma,
Saitama, Japan

Purpose: To describe the treatment outcome of photodynamic therapy (PDT) in Japanese patients with age-related macular degeneration (AMD) followed for 5 years.

Patients and methods: We retrospectively reviewed clinical charts of 51 patients with AMD. Thirty-one eyes of typical AMD (tAMD) and 20 eyes of polypoidal choroidal vasculopathy (PCV) were evaluated.

Results: The mean logarithm of the minimum angle of resolution (logMAR) vision of all AMD patients was 0.807 at the baseline examination and 0.937 at the 5 year examination. Mean visual acuity letter score loss is similar between patients with tAMD (-7.25) and with PCV (-5.36) at the month 60 examination. The patients with lesions of classic choroidal neovascularization (CNV) had 10.0 letters loss, but the patients with lesions of occult CNV had only 1.43 letters loss. The number of retreatments peaked in year 1 and declined immediately for patients with tAMD, but patients with PCV had significantly more frequent retreatments in the years 3 and 4 than patients with tAMD ($P = 1.48 \times 10^{-2}$, 5.96×10^{-3} , respectively).

Conclusion: Visual outcomes in patients with Japanese patients with AMD treated with PDT after 5-year follow up were worse than that in short-term follow up reported previously. In addition, the difference in visual prognosis between tAMD and PCV was not demonstrated after long-term follow-up.

Keywords: photodynamic therapy, age-related macular degeneration, polypoidal choroidal vasculopathy, visual outcomes

Introduction

Age-related macular degeneration (AMD) is the leading cause of severe visual loss in people over 50 years of age.¹ Photodynamic therapy (PDT) with verteporfin (Visudyne, Novartis Pharmaceutical Corporation, East Hanover, NJ, USA) is approved in more than 75 countries and commonly used to treat patients with subfoveal choroidal neovascularization (CNV) associated with AMD.²⁻⁴ Several clinical trials in the United States and European countries have reported the benefits of PDT.^{2,3,5-9} Guidelines for verteporfin therapy were based on the results of these trials in predominantly Caucasian populations. Although Treatment of Age-related Macular Degeneration with Photodynamic Therapy⁵ (TAP) investigation reported a benefit at 24 months with respect to reducing the risk of three or more lines of visual acuity (VA) loss compared with placebo controls, the Japanese Age-Related Macular Degeneration Trial (JAT) study group⁴ reported that PDT for CNV in. Sixty-four Japanese patients appeared to have better angiographic and visual outcomes than those of the Western trials.^{2,3,5-9}

Polypoidal choroidal vasculopathy (PCV) is a distinct form of AMD, which meets the late age-related maculopathy (ARM) criteria of the International ARM

Correspondence: Keisuke Mori
Department of Ophthalmology,
Saitama Medical University
38 Morohongo, Moroyama, Iruma,
Saitama, 350-0495, Japan
Tel +81 492 76 1250
Fax +81 492 95 8002
Email keisuke@saitama-med.ac.jp

Epidemiological Study Group,¹⁰ but the phenotypic characteristics differ from typical neovascular AMD (tAMD). Over the past decade, the spectrum of neovascular AMD has been expanded to include PCV.^{11–14} Patients with AMD in Japan have been reported to have PCV lesions more frequently than Caucasian patients^{15–18} and PDT provides favorable results in the treatment of PCV.^{19–23} Considering these outcomes of PDT treatments for PCV better outcomes are presumed for Japanese patients than Caucasian patients. Therefore, it is possible there may be a different response to PDT among different populations. Although TAP study provided the outcomes after PDT with AMD in the 5-year follow-up, JAT study⁴ and JAT extension²⁴ have described up to 2 years follow-up information.

The purpose of this study is to provide the long-term follow-up information (5 years) after PDT in Japanese patients, and to compare the results with those of Western studies. We also explored whether the effect of PDT is different between patients with PCV lesion and those without.

Materials and methods

Subjects, examination and diagnosis

This retrospective study was conducted at Saitama Medical University, Saitama, Japan. All study subjects were unrelated Japanese Asian. All participants underwent a comprehensive ocular examination, including slitlamp biomicroscopy, funduscopy, contact lens biomicroscopic examinations of the retina, fluorescein and indocyanine green angiography, and optical coherence tomography (OCT) observation (Cirrus and Stratus, Carl Zeiss Meditec AG, Jena, Germany) at baseline and every 3-month visit. Every patient had fluorescein angiography at baseline. Regarding indocyanine green angiography, there were five exceptions, with a history of allergy for iodide, a positive result on pre-injection test or a known systemic problem such as liver disease, ischemic heart disease, cardiac arrhythmia or cardiac pacemakers. The differential diagnosis of tAMD and PCV was conducted so that if the polypoidal structure of the choroidal vessels with or without abnormal vascular networks was observed on indocyanine green angiography at the corresponding lesion on fluorescein angiography, the eyes were diagnosed as having PCV. We referred to the five cases without indocyanine green angiography, funduscopic appearance of typical orange-like polypoidal structure and OCT findings to make an accurate diagnosis.

Fifty-one consecutive patients who underwent initially PDT with the diagnosis of AMD between July 2004 and June 2005,

with the completion of the month 60 examination, were recruited for this study. Inclusion criteria were as follows; (1) age of 50 years or older, (2) diagnosis of AMD in one or both eyes, (3) no association with other retinochoroidal diseases such as angioid streaks, high myopia (greater than 6D of myopic refractive error), central serous chorioretinopathy, presumed ocular histoplasmosis or retinal angiomatous proliferation (type 3 choroidal neovascularization). Excluded were the patients who had the treatments before and during the 5-year follow-ups with other methodologies; antivascular endothelial growth factor therapies, thermal laser photocoagulation, transpupillary thermotherapy, and/or vitreous surgery.

The main outcome of this study was best corrected visual acuity (BCVA) alteration during 5-year follow-up. We also analyzed the number of PDT retreatments. Recurrence of AMD was determined by a significant increase (20% or more compared with the lowest measurement at any previous scheduled visit) of the retinal thickness due to retinal edema and retinal detachment delineated by OCT measurement, increased or persistent fluorescein leakage from CNV or appearance of new retinal hemorrhage of one disc diameter or greater after 3 months or more. Additional retreatments were given if the CNV recurrence was observed as often as every 3 months during the 5-year follow-up.

Treatment procedures

The treatment protocol followed that used in the JAT study.⁴ Treatment involved a 10 minute intravenous infusion of verteporfin, 6 mg/m² body surface area, followed by light exposure 15 minutes after the start of the infusion. Light exposure was given with a diode laser beam (639 ± 3 nm), delivered at 600 mW/cm² for 83 seconds to produce 50 J/cm².

Statistical analysis

The BCVA was determined using the Landolt C chart, and was calculated and presented as the logarithm of the minimum angle of resolution (logMAR) for statistical analyses and for conversion to letter scores. The following calculations were used:

- logMAR value = log₁₀ (1/VA using Landolt C chart).
- Each 0.10 unit of logMAR difference = 5 letters.

The measured mean value of each group was compared using paired or unpaired *t*-test, chi-square test, and Bonferroni multiple comparison correction. *P* < 0.05 was considered to be statistically significant. All analysis was performed with commercially available software (SSRI version. 1.20, SSRI, Tokyo, Japan).

Results

Patient characteristics

Of the 51 exudative AMD patients, 31 patients (61%) were diagnosed with tAMD, and the remaining 20 patients (39%) were diagnosed with PCV. The baseline characteristics of study participants are summarized in Table 1. At baseline, the distribution of age, gender, great linear dimension (GLD), logMAR vision and central retinal thickness were not significantly different between tAMD and PCV ($P > 0.05$) patients. However, patients with tAMD had classic lesions more frequently than patients with PCV ($P = 7.81 \times 10^{-4}$).

Visual outcomes

The mean logMAR vision in all AMD patients was 0.807 (corresponding approximate VA score: 0.15) at the baseline examination and 0.937 (corresponding approximate visual acuity score: 0.11) at the month 60 examination. The logMAR vision gradually decreased throughout the follow-up period, but the difference between baseline and month 60 was not significant in each subset group (tAMD; $P = 0.110$, PCV; $P = 0.290$, all AMD; $P = 0.052$) (Figure 1).

Mean logMAR vision loss was similar between patients with tAMD and with PCV. The significant difference was not demonstrated in the change of logMAR vision from baseline between tAMD and PCV throughout the follow-up period ($P = 0.814$ at month 6, 0.957 at month 12, 0.544 at month 24 and 0.781 at month 60). LogMAR vision of patients with occult CNV improved from 0.822 ± 0.419 at baseline to 0.781 ± 0.516 at month 24 while logMAR vision of patients with classic CNV worsened from 0.796 ± 0.311 at baseline to 0.884 ± 0.473 at month 24. However, the significant difference was not seen between these patient groups throughout the follow up ($P = 0.097$ at month 6, $P = 0.518$ at month 12, $P = 0.595$ at month 24 and $P = 0.197$ at month 60).

Figure 2 demonstrates mean change in letters from baseline (logMAR vision converted to visual acuity letter scores) throughout 60-month follow up for all patients with AMD, tAMD and PCV (Figure 2A) and for 30 patients with classic CNV and 21 patients with occult CNV (Figure 2B). Mean visual acuity letter score decreased 6.51 in patients with all AMD, 7.25 in patients with tAMD and 5.36 in patients with PCV at the month 60 examination (Figure 2A). The patients with lesions of predominantly or minimally classic CNV had 10.0 letters loss, but the patients with lesions of occult with no classic CNV had only 1.43 letters loss (Figure 2B).

Number of retreatments

The mean number of retreatments per year during the follow up period is shown in Table 2. The number of retreatments peaked in year 1 and declined along the time course for patients with tAMD, but patients with PCV had significantly more frequent retreatments in the years 3 and 4 than patients with tAMD ($P = 1.48 \times 10^{-2}$, 5.96×10^{-3} , respectively).

Discussion

A previous randomized clinical trial for Japanese AMD (JAT study) provided 1-year results of PDT, demonstrating better angiographic and vision effects to those observed in Caucasian patients.⁴ JAT extension study showed similar favorable results through 2-year follow up. Mean visual acuity letter score in the study eye increased from 50.8 at baseline to 54.0 at month 24. In contrast to those reports, the mean logMAR vision in all AMD patients decreased from 0.807 (corresponding approximate visual acuity score: 0.15) at the baseline to 0.937 (corresponding approximate visual acuity score: 0.11) at the month 60 examination. Although many previous reports, with up to 12 months follow up results, described favorable results of PDT in treating PCV,^{19–23} our data did not show the significant

Table 1 Baseline characteristics of study participants

	tAMD	PCV	P
Number of patients	31	20	
Age (mean \pm SD)	70.3 \pm 7.2	69.5 \pm 7.5	0.686*
Sex (male/female)	24/7	16/4	0.826†
Angiographic classification (classic/occult)‡	24/7	6/14	7.81×10^{-4} †
GLD (μ m, mean \pm SD)	3172 \pm 1352	3550 \pm 1321	0.834*
Mean BCVA, logMAR vision (mean \pm SD)	0.85 \pm 0.33	0.73 \pm 0.40	0.141*
Mean BCVA, corresponding approximate decimal visual acuity	0.141	0.186	
Mean CRT (μ m, mean \pm SD)	489 \pm 143	541 \pm 195	0.815*

Notes: *Unpaired t-test; †Chi-square test; ‡fluorescein angiographic classification. classic indicates patients with lesions composed of predominantly or minimally classic CNV and occult indicates patients with lesions composed of occult with no classic choroidal neovascularization (CNV).

Abbreviations: tAMD, typical neovascular age-related macular degeneration; PCV, polypoidal choroidal vasculopathy; SD, standard deviation; GLD, greatest linear dimension; BCVA, best corrected visual acuity; logMAR, logarithm of minimum angular resolution; CRT, central retinal thickness.

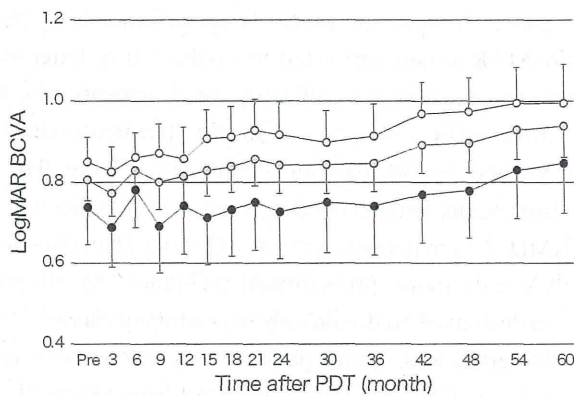


Figure 1 Best corrected visual acuity (BCVA) for all neovascular age-related macular degeneration (AMD), typical neovascular AMD (tAMD) and polypoidal choroidal vasculopathy (PCV) patients after photodynamic therapy (PDT) (open circles, tAMD; gray circles, all AMD; solid circles, PCV) over the 60 month follow-up period. **Notes:** The BCVA was determined using the Landolt C chart, and was calculated and presented as the logarithm of the minimum angle of resolution (logMAR). Values are presented as mean. (Error bar and standard error). **Abbreviation:** PDT, photodynamic therapy.

difference in visual prognosis between tAMD and PCV after long-term follow-up. Mean visual acuity letter score loss is similar between patients with tAMD and with PCV at the month 60 examination with no significant difference. These facts suggest that the better results in Japanese AMD patients and predominance of PCV in the visual outcome may be temporal during the first 2 years and may not last for more than 5 years.

Interestingly, this study demonstrated that the patients with lesions of classic CNV had 10.0 letters loss, while the patients with lesions of occult CNV had only 1.43 letters

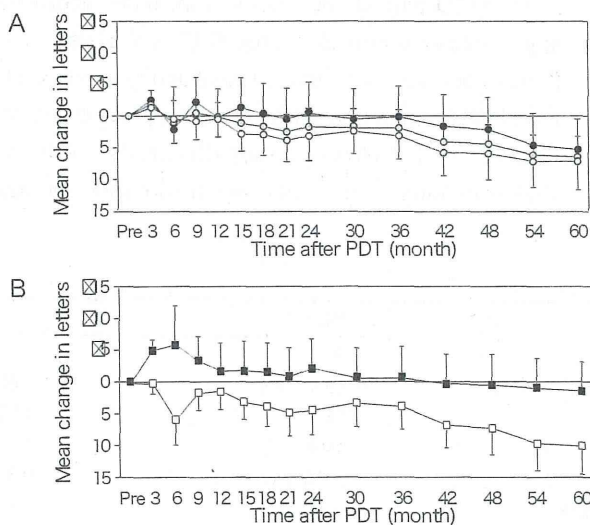


Figure 2 Mean change in letters from baseline for all long-term verteporfin treated patients: (A) open circles, tAMD; gray circles, all AMD; solid circles, PCV, (B) open squares, the patients with classic CNV; solid squares, the patients with occult CNV. **Note:** (Error bar and standard error). **Abbreviation:** PDT, photodynamic therapy; tAMD, typical neovascular; AMD, age-related macular degeneration; PCV, polypoidal choroidal vasculopathy; CNV, choroidal neovascularization.

Table 2 Mean number of retreatments

	Number of retreatments during each yearly period (mean ± SD)		
	tAMD	PCV	P
Year 1	0.55 ± 0.72	0.35 ± 0.48	0.286
Year 2	0.16 ± 0.37	0.25 ± 0.44	0.446
Year 3	0.10 ± 0.30	0.45 ± 0.68	1.48 × 10 ⁻² *
Year 4	0.03 ± 0.18	0.30 ± 0.47	5.96 × 10 ⁻³ *
Year 5	0.03 ± 0.18	0.10 ± 0.31	0.325

Note: *Significant (unpaired t-test).

Abbreviations: AMD, age-related macular degeneration; tAMD, typical neovascular AMD; PCV, polypoidal choroidal vasculopathy; SD, standard deviation.

loss in 5 years. Patients with occult CNV gained 5.81 letters at month 6 and 2.07 at month 24 while patients with classic CNV lost 5.96 letters at month 6 and 4.39 at month 24. However, the significant difference was not seen between these a patient groups throughout the follow up. Figure 3 provides a comparative summary of visual outcomes of our study and the TAP investigation.^{2,5,25} There were smaller proportions of patients who had at least a 15-letter loss in patients with occult CNV when compared to those with classic CNV.

The number of retreatments peaked in year 1 and declined along the time course for patients with tAMD, but patients with PCV had significantly more frequent retreatments in the years 3 and 4 than patients with tAMD ($P = 1.48 \times 10^{-2}$, $P = 5.96 \times 10^{-3}$, respectively). Honda et al also described 30-month results of PDT for Japanese patients with tAMD and PCV.²⁶ They found that recurrence of lesions in the PCV patients was more frequent than of that with the tAMD patients during the 12–30 months after initial PDT, while the recurrence rate was lower in the PCV group during the first 12 months. Our finding is consistent to this report. The higher incidence of recurrence in PCV patients in the years 3 and 4 may explain

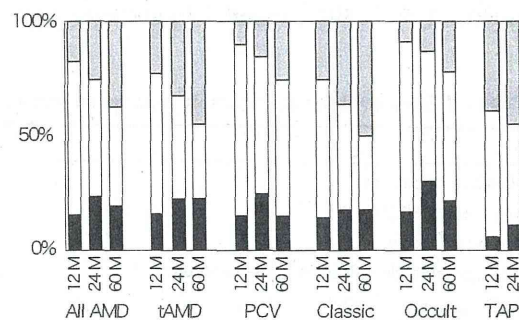


Figure 3 Comparison of visual outcomes for all patients at month 12, 24 and 60 with those of Treatment of Age-related Macular Degeneration with Photodynamic Therapy (TAP) Investigation.^{2,5,25}

Notes: Black bars: ≥15-letters increase; white bars: no change (±14 letters); gray bars: ≥15-letters decrease.

Abbreviations: AMD, age-related macular degeneration; tAMD, typical age-related macular degeneration; PCV, polypoidal choroidal vasculopathy; TAP, treatment of age-related macular degeneration with photodynamic therapy study.

predominance of PCV in the visual outcome is temporal during the initial 2 years and does not last for more than 5 years.

There are at least two limitations to this study. One is the small sample size, which may be associated with low statistical power, which may or may not be a reason of no significant change in VA from baseline or no significant difference in VA between tAMD and PCV detected at any time point over 5-years of follow-up. The second is that the retrospective nature of the study might exclude the patients with excellent or bad courses that could cause bias in the results. Since several anti-vascular endothelial growth factor drugs other than PDT are currently available and have become the first-choice treatment for AMD, it might be difficult to overcome these limitations with a single report. However, meta-analysis with an accumulation of similar data with multiple publications may be one alternative measure for these limitations, and is warranted.

Acknowledgement

This research was supported in part by an Institutional Grant (20-1-2-02) from the Medical Research Center, Saitama Medical University (KM), a grant from the Eye Research Foundation for the Aged (KM) and a grant-in-aid for scientific research (21592242) from the Ministry of Education, Culture and Science in Japan (KM).

The sponsor or funding organization had no role in the design or conduct of this research.

Disclosure

The authors report no conflicts of interest in this work.

References

- Vingerling LR, Diclemans IJ, Hofman A, et al. The prevalence of age related maculopathy in Rotterdam study. *Ophthalmology*. 1995;102:205–210.
- Treatment of age-related macular degeneration with photodynamic therapy (TAP) Study Group. Photodynamic therapy of subfoveal choroidal neovascularization in age-related macular degeneration with verteporfin: one-year results of 2 randomized clinical trials-TAP report. *Arch Ophthalmol*. 1999;117:1329–1345.
- Verteporfin in Photodynamic Therapy (VIP) Study Group. Verteporfin therapy of subfoveal choroidal neovascularization in age-related macular degeneration: two-year results of a randomized clinical trial including lesions with occult with no classic choroidal neovascularization-verteporfin in photodynamic therapy report 2. *Am J Ophthalmol*. 2001;131:541–560.
- Japanese Age-Related Macular Degeneration Trials (JAT) Study Group. Japanese age-related macular degeneration trial: 1-year results of photodynamic therapy with verteporfin in Japanese patients with subfoveal choroidal neovascularization secondary to age-related macular degeneration. *Am J Ophthalmol*. 2003;135:1049–1061.
- Treatment of age-related macular degeneration with photodynamic therapy (TAP) Study Group. Photodynamic therapy of subfoveal choroidal neovascularization in age-related macular degeneration with verteporfin: two-year results of 2 randomized clinical trials-TAP report 2. *Arch Ophthalmol*. 2001;119:198–207.
- Verteporfin in Photodynamic Therapy Study Group. Photodynamic therapy of subfoveal choroidal neovascularization in pathologic myopia with verteporfin. 1-year results of a randomized clinical trial-VIP report no 1. *Ophthalmology*. 2001;108:841–852.
- Blinder KJ, Bradley S, Bressler NM, et al. Treatment of Age-related Macular Degeneration with Photodynamic Therapy study group; Verteporfin in Photodynamic Therapy study group. Effect of lesion size, visual acuity, and lesion composition on visual acuity change with and without verteporfin therapy for choroidal neovascularization secondary to age-related macular degeneration: TAP and VIP report no 1. *Am J Ophthalmol*. 2003;136:407–418.
- Barbazetto I, Burdan A, Bressler NM, et al. Treatment of Age-Related Macular Degeneration with Photodynamic Therapy Study Group; Verteporfin in Photodynamic Therapy Study Group. Photodynamic therapy of subfoveal choroidal neovascularization with verteporfin: fluorescein angiographic guidelines for evaluation and treatment-TAP and VIP report no 2. *Arch Ophthalmol*. 2003;121:1253–1268.
- Arnold JJ, Blinder KJ, Bressler NM, et al. Treatment of Age-related Macular Degeneration with Photodynamic Therapy study group; Verteporfin in Photodynamic Therapy study group. Acute severe visual acuity decrease after photodynamic therapy with verteporfin: case reports from randomized clinical trials-TAP and VIP report no 3. *Am J Ophthalmol*. 2004;137:683–696.
- Bird AC, Bressler NM, Bressler SB, et al. An international classification and grading system for age-related macular degeneration. The International ARM Epidemiological Study Group. *Surv Ophthalmol*. 1995;39:367–374.
- Spaide RF, Yannuzzi LA, Slakter JS, Sorenson J, Orlock DA. Indocyanine green videoangiography of idiopathic polypoidal choroidal vasculopathy. *Retina*. 1995;15:100–110.
- Yannuzzi LA, Ciardella A, Spaide RF, Rabb M, Freund KB, Orlock DA. The expanding clinical spectrum of idiopathic polypoidal choroidal vasculopathy. *Arch Ophthalmol*. 1997;115:478–485.
- Yannuzzi LA, Wong DWK, Storzolini BS, et al. Polypoidal choroidal vasculopathy and neovascularized age-related macular degeneration. *Arch Ophthalmol*. 1999;117:1503–1510.
- Ciardella AP, Donsoff IM, Huang SJ, Costa DL, Yannuzzi LA. Polypoidal choroidal vasculopathy. *Surv Ophthalmol*. 2004;49:25–37.
- Sho K, Takahashi K, Yamada H, et al. Polypoidal choroidal vasculopathy: incidence, demographic features, and clinical characteristics. *Arch Ophthalmol*. 2003;121:1392–1396.
- Yuzawa M, Mori R, Kawamura A. The origins of polypoidal choroidal vasculopathy. *Br J Ophthalmol*. 2005;89:602–607.
- Maruko I, Iida T, Ssito M, Nagayama D, Saito K. Clinical characteristics of exudative age-related macular degeneration in Japanese patients. *Am J Ophthalmol*. 2005;144:15–22.
- Mori K, Horie-inoue K, Gerhlabach PL, et al. Phenotype and genotype characteristics of age-related macular degeneration in Japanese population. *Ophthalmology*. 2010;117:928–938.
- Spaide RF, Donsoff I, Lam DL, et al. Treatment of polypoidal choroidal vasculopathy with photodynamic therapy. *Retina*. 2002;22:529–535.
- Quaranta M, Maget-Faysse M, Coscas G. Exudative idiopathic polypoidal choroidal vasculopathy and photodynamic therapy with verteporfin. *Am J Ophthalmol*. 2002;134:277–280.
- Chan WM, Lam DS, Lai TY, et al. Photodynamic therapy with verteporfin for symptomatic polypoidal choroidal vasculopathy. One-year results of a prospective case series. *Ophthalmology*. 2004;111:1576–1584.
- Lee SC, Seong YS, Kim SS, Koh HJ, Kwon OW. Photodynamic therapy with verteporfin for polypoidal choroidal vasculopathy of the macula. *Ophthalmologica*. 2004;218:193–201.
- Silva Rm, Figueira J, Cachulo ML, Duarte L, Faria de Abreu JR, Cunha-Vaz JG. Polypoidal choroidal vasculopathy and photodynamic therapy with verteporfin. *Graefes Arch Clin Exp Ophthalmol*. 2005;243:973–979.

24. Japanese Age-Related Macular Degeneration Trials (JAT) Study Group. Photodynamic therapy with verteporfin in Japanese patients with subfoveal choroidal neovascularization secondary to age-related macular degeneration (AMD): results of the Japanese AMD Trial (JAT) extension. *Jpn J Ophthalmol.* 2008;52:99–107.
25. Treatment of Age-Related Macular Degeneration with Photodynamic therapy (TAP) Study Group. Verteporfin therapy for subfoveal choroidal neovascularization in age-related macular degeneration: 5-year results of an open-label extension of 2 randomized clinical trials-TAP report no 8. *Graefes Arch Clin Exp Ophthalmol.* 2006;244:1132–1142.
26. Honda S, Kurimoto Y, Kagotani Y, Yamamoto H, Takagi H, Uenishi M, Hyogo Macular Disease Study Group. Photodynamic therapy for typical age-related macular degeneration and polypoidal choroidal vasculopathy: a 30-month multicenter study in Hyogo, Japan. *Jpn J Ophthalmol.* 2009;53:593–597.

Clinical Ophthalmology

Publish your work in this journal

Clinical Ophthalmology is an international, peer-reviewed journal covering all subspecialties within ophthalmology. Key topics include: Optometry; Visual science; Pharmacology and drug therapy in eye diseases; Basic Sciences; Primary and Secondary eye care; Patient Safety and Quality of Care Improvements. This journal is indexed on

Submit your manuscript here: <http://www.dovepress.com/clinical-ophthalmology-journal>

Dovepress

PubMed Central and CAS, and is the official journal of The Society of Clinical Ophthalmology (SCO). The manuscript management system is completely online and includes a very quick and fair peer-review system, which is all easy to use. Visit <http://www.dovepress.com/testimonials.php> to read real quotes from published authors.

Longitudinal clinical course of three Japanese patients with Leber congenital amaurosis/early-onset retinal dystrophy with *RDH12* mutation

Kazuki Kuniyoshi · Hiroyuki Sakuramoto · Kazutoshi Yoshitake ·
Kosuke Abe · Kazuho Ikeo · Masaaki Furuno · Kazushige Tsunoda ·
Shunji Kusaka · Yoshikazu Shimomura · Takeshi Iwata

Received: 11 February 2014 / Accepted: 10 April 2014 / Published online: 22 April 2014
© Springer-Verlag Berlin Heidelberg 2014

Abstract

Purpose To report the longitudinal clinical course of three Japanese patients from two families with Leber congenital amaurosis/early-onset retinal dystrophy (LCA/EORD), and the results of next-generation DNA sequences on them.

Patients and methods The patients were three Japanese children: a 4-year-old girl, a 6-year-old boy, and a 3-year-old girl. Patients 1 and 2 were siblings, and patient 3 was from an unrelated family. Standard ophthalmic examinations including perimetry, electroretinography, optical coherence tomography, and ultrasonography were performed on each patient. The patients were

observed for 28, 16, and 10 years. Whole exomes of the patients and their non-symptomatic parents were analyzed using a next-generation sequence technique.

Results The decimal visual acuity varied between 0.07 and 0.6 at the initial visit and decreased to counting finger to hand motion in their teens. Funduscopy showed diffuse retinal and macular degeneration. During the follow-up period, a posterior staphyloma developed and the macular area became atrophic. Patient 1 developed cataracts in her early twenties. Genetic analysis revealed a homozygous A126V substitution in the *RDH12* gene in all patients.

Conclusions The three patients with LCA/EORD had a progressive decrease of their vision with the formation of a posterior staphyloma. This is the first report of Japanese patients with LCA/EORD with a *RDH12* mutation.

A part of this paper was presented at the 8th congress of Asia Pacific Vitreo-retina Society in Nagoya, Japan, on December 7, 2013.

K. Kuniyoshi (✉) · H. Sakuramoto · K. Abe ·
Y. Shimomura

Department of Ophthalmology, Kinki University Faculty
of Medicine, 377-2 Ohno-Higashi, Osaka-Sayama City,
Osaka 589-8511, Japan
e-mail: kuniyoshi-kazuki@umin.net

K. Yoshitake · K. Ikeo
Laboratory of DNA Data Analysis, National Institute of
Genetics, Shizuoka, Japan

M. Furuno
Transcriptome Technology Team, Life Science
Accelerator Technology Group, Division of Genomic
Technologies, RIKEN Center for Life Science
Technologies, Yokohama, Japan

K. Tsunoda
Laboratory of Visual Physiology, National Institute of
Sensory Organs, National Hospital Organization Tokyo
Medical Center, Tokyo, Japan

S. Kusaka
Department of Ophthalmology, Sakai Hospital, Kinki
University Faculty of Medicine, Sakai City, Osaka, Japan

T. Iwata
Division of Molecular and Cellular Biology, National
Institute of Sensory Organs, National Hospital
Organization Tokyo Medical Center, Tokyo, Japan