

An efficient diagnostic strategy for small, depressed early gastric cancer with magnifying narrow-band imaging: a post-hoc analysis of a prospective randomized controlled trial

Shinya Yamada, MD,¹ Hisashi Doyama, MD, PhD,¹ Kenshi Yao, MD, PhD,² Noriya Uedo, MD,³ Yasumasa Ezoe, MD, PhD,⁴ Ichiro Oda, MD,⁵ Kazuhiro Kaneko, MD, PhD,⁶ Yoshiro Kawahara, MD, PhD,⁷ Chizu Yokoi, MD, PhD,⁸ Yasushi Sugiura, MD,⁹ Hideki Ishikawa, MD, PhD,¹⁰ Yoji Takeuchi, MD,³ Yutaka Saito, MD, PhD,⁵ Manabu Muto, MD, PhD¹¹

Ishikawa, Fukuoka, Osaka, Kyoto, Tokyo, Chiba, Okayama, Japan

Background: We previously reported that magnifying narrow-band imaging (M-NBI) is a high-performance diagnostic tool for small, depressed gastric cancer. However, an efficient diagnostic strategy using endoscopic findings has not been fully elucidated.

Objective: To identify the endoscopic findings that contribute to accurate diagnosis of small, depressed gastric cancer and to propose the ideal diagnostic approach to such lesions.

Design: Post-hoc analysis of a prospective, randomized, controlled trial.

Setting: Nine hospitals.

Patients: Three hundred fifty-three patients with small, depressed gastric lesions.

Interventions: In the M-NBI group (n = 177), cancer diagnosis was made with diagnostic criteria including a demarcation line (DL) and an irregular microvascular pattern (IMVP). In the conventional white-light imaging (C-WLI) group (n = 176), diagnostic criteria were both an irregular margin and a spiny depressed area. In the C-WLI group, M-NBI was performed after C-WLI diagnosis.

Main Outcome Measurements: The diagnostic performance of each criterion in M-NBI alone, C-WLI, and M-NBI after C-WLI was investigated.

Results: M-NBI after C-WLI ultimately showed the best diagnostic performance in each diagnostic criterion. In M-NBI after C-WLI, evaluation of DL is technically easier than that of IMVP, and DL alone had a high sensitivity (95%) and negative predictive value (99%). The IMVP in M-NBI after C-WLI had a high sensitivity and specificity (95% and 96%, respectively) for diagnosis of cancer.

Limitations: Lesions were limited to the small, depressed type.

Conclusions: For a diagnosis using M-NBI after C-WLI, identification of DL is the first step, and subsequent inspection of IMVP diagnosed by DL is an efficient strategy. (Gastrointest Endosc 2014;79:55-63.)

Abbreviations: C-WLI, conventional white-light imaging; DL, demarcation line; ESD, endoscopic submucosal dissection; IM, irregular margin; IMVP, irregular microvascular pattern; M-NBI, magnifying narrow-band imaging; SDA, spiny depressed area.

DISCLOSURE: All authors disclosed no financial relationships relevant to this publication. Research support for this study was provided in part by a grant-in-aid for cancer research from the Ministry of Health (H21-009), Labor, and Welfare of Japan.

Copyright © 2014 by the American Society for Gastrointestinal Endoscopy
0016-5107/\$36.00

<http://dx.doi.org/10.1016/j.gie.2013.07.008>

Received March 19, 2013. Accepted July 7, 2013.

Current affiliations: Department of Gastroenterology, Ishikawa Prefectural Central Hospital, Ishikawa, Japan (1), Department of Endoscopy, Fukuoka University Chikushi Hospital, Fukuoka, Japan (2), Department of Gastrointestinal Oncology, Osaka Medical Cancer for Cancer and Cardiovascular Diseases, Osaka, Japan (3), Department of Multidisciplinary Cancer Treatment, Graduate School of Medicine, Kyoto University, Kyoto, Japan (4), Department of Gastroenterology, National Cancer

(footnotes continued on last page of article)

Gastric cancer is the second leading cause of cancer deaths worldwide.¹ Early detection and accurate diagnosis of depressed gastric mucosal cancer are effective ways to decrease mortality because the depressed type is the predominant morphology among gastric mucosal cancers.²⁻⁴ Moreover, detection of mucosal cancers ≤ 20 mm in diameter is ideal because they are curable with minimally invasive treatments such as EMR and endoscopic submucosal dissection (ESD).^{5,6} However, these approaches have proven difficult when using conventional white-light imaging (C-WLI) endoscopy because depressed-type cancer shows subtle morphologic changes. Accurate diagnosis is hampered by the lack of reliable diagnostic criteria. A novel endoscopic technology, magnifying narrow-band imaging (M-NBI), is a powerful tool for characterizing gastric mucosal lesions because it can visualize the microvascular architecture as well as morphology of such lesions.⁷

We performed a multicenter, prospective, randomized, controlled trial and reported that M-NBI was more useful than C-WLI in terms of the ability to diagnose small, depressed gastric cancerous lesions (UMIN-CTR 000001072).⁸ In this randomized controlled trial, 2 criteria,^{9,10} the presence of a demarcation line (DL) and an irregular microvascular pattern (IMVP), were used for the endoscopic evaluation of lesions using M-NBI, whereas the presence of an irregular margin (IM) and spiny depressed area (SDA) were used for C-WLI evaluation. However, the endoscopic findings that contribute to the accurate diagnosis of small, depressed gastric cancerous lesions have not been fully identified. Moreover, M-NBI still leads to misdiagnosis of some lesions, and the reasons for these misdiagnoses are unclear. Therefore, the aim of this study was to identify an efficient diagnostic strategy using the most reliable endoscopic findings to diagnose early gastric cancers and propose an ideal diagnostic approach to these cancers.

METHODS

Study design and endoscopic procedure

This study was conducted as a post-hoc analysis of data collected in our randomized controlled trial.⁸ The protocol of the trial was approved by the Ethics Committee of the Kyoto University Graduate School of Medicine on February 14, 2008. The UMIN Clinical Trials Registry identification number for this study is 000001072 on March 15, 2008. In the trial, 1353 patients with concomitant gastric cancer or a history of endoscopic resection of early gastric cancer were enrolled and underwent endoscopic screening with C-WLI between June 2008 and May 2010. The target lesions were "newly detected and undiagnosed" small, depressed gastric lesions ≤ 10 mm in diameter. Only the first lesion detected in each patient was selected for examination.

Among all patients 353 previously undiagnosed lesions were found in 362 patients that were randomly assigned to the M-NBI ($n = 177$) and C-WLI ($n = 176$) groups.

Take-home Message

- The diagnostic performance of magnifying narrowband imaging (M-NBI) after conventional white-light imaging (C-WLI) using a demarcation line (DL) and an irregular microvascular pattern (IMVP) was significantly high for small, depressed gastric lesions.
- In M-NBI after C-WLI, it is ideal to identify the DL first to diagnose small, depressed gastric cancer, and the subsequent IMVP inspection efficiently excludes false-positive lesions by the DL. The reasons for misdiagnoses include technical and cognitive factors; thus, training should involve both aspects.

The diagnosis for the target lesion was made on-site by 1 endoscopist according to predetermined diagnostic criteria for C-WLI and M-NBI, and the result was recorded on a case report form. For the C-WLI group, M-NBI examination was performed after completion of a diagnosis based on C-WLI (M-NBI after C-WLI) to evaluate the effect of using M-NBI in conjunction with C-WLI. At least 2 endoscopic images of the target lesion in each mode were captured and stored in a computer server during the diagnosis. After compilation of all endoscopic diagnoses, at least 1 biopsy specimen was obtained from the target lesion. Lesions diagnosed as cancer or suspicious for cancer were removed by EMR/ESD to obtain a final histologic diagnosis. The demographics of the study samples are summarized in Table 1.

The biopsy and EMR/ESD specimens were evaluated based on the revised Vienna classification. Category C4 (mucosal high-grade neoplasia) and C5 (submucosal invasion by neoplasia) were diagnosed as cancerous lesions, and C1 (negative for neoplasia), C2 (indefinite for neoplasia), and C3 (mucosal low-grade neoplasia) were diagnosed as noncancerous lesions. When indeterminate lesions were encountered, we consulted with a main expert pathologist as a central review system to obtain a final diagnosis. The lesions in the M-NBI group comprised 20 cancerous and 157 noncancerous lesions, and those in the C-WLI group comprised 20 cancerous and 156 noncancerous lesions (Fig. 1). The prevalence rate was almost identical in both groups (11.2% and 11.3%, respectively).

As described in the previous trial,⁸ this study was conducted according to the Standards for the Reporting of Diagnostic Accuracy Studies initiative¹¹ and the Declaration of Helsinki. Randomization and masking were strictly enforced. Thirty-one endoscopists from 9 institutions in Japan participated after being trained in the acquisition of C-WLI and M-NBI images of small, depressed lesions to minimize diagnostic variation among observers. Ethical concerns were fully addressed.

Endoscopy system and setting

The video endoscopy system used in this study comprised a video processor (EVIS LUCERA CV-260SL; Olympus Medical Systems, Tokyo, Japan) and a light source

TABLE 1. Demographics of the study sample

	C-WLI group (n = 176)	M-NBI group (n = 177)	P
Median age, y	69	69	.56
Gender			
Male	138	140	.79
Female	38	37	
Mean SDL size, mm	5.6	5.6	.97
SDL location (longitudinal)			
Upper third	39	27	.21
Middle third	40	49	
Lower third	97	101	
SDL location (circumferential)			
Anterior wall	29	32	
Lesser curvature	47	68	.06
Posterior wall	60	41	
Greater curvature	40	36	
Endoscope			
GIF-Q240Z	71	65	
GIF-FQ240Z	1	3	.83
GIF-H260Z	104	109	
Histology			
Noncancerous	156	157	1.00
Cancer	20	20	

SDL, Small, depressed lesion; M-NBI, magnifying narrow-band imaging; C-WLI, conventional white-light imaging.

(EVIS LUCERA Olympus CLV-260SL; Olympus Medical Systems) that worked in both the C-WLI and NBI modes. In the NBI mode, narrow-banded short-wavelength lights (400-430 nm and 525-555 nm) were used to contrast the microvascular architecture and mucosal surface of the superficial mucosa.¹²⁻¹⁴ High-resolution magnifying endoscopy with a capability of 80-fold optical magnification was used (GIF-Q240Z, GIF-H260Z, and GIF-FQ260Z; Olympus Medical Systems). A soft black hood (MB162 or MB46; Olympus Medical Systems) was attached at the tip of the endoscope. The structure enhancement of the endoscopic video processor was set to B-mode level 4 or 6 for C-WLI and to B-mode level 8 for M-NBI. The color mode was fixed at level 1.

Endoscopic criteria used to diagnose cancers

The 2 criteria^{9,10} used in the endoscopic evaluation of lesions using M-NBI were the presence of a DL and an

IMVP (Fig. 2). An IMVP refers to microvessels that differ in shape, take the shape of a closed or open loop, or are tortuous, branched, or bizarrely shaped. The vessels differ in both size and diameter, and the distribution of the microvessels is asymmetric with an irregular arrangement. The criteria used in the endoscopic evaluation of lesions using C-WLI were the presence of an IM and an SDA (Fig. 3). These findings were independently assessed and documented on a 3-point scale (present, absent, or indeterminate). Endoscopic diagnoses using both C-WLI and M-NBI were determined according to the combined visibility of the 2 findings. (1) If both findings were present, the diagnosis was cancer. (2) In the event of a combination other than pattern (1), the diagnosis was a noncancerous lesion.

Outcome measurements

Using the outlined criteria from C-WLI, M-NBI alone, and M-NBI after C-WLI, we compared the endoscopic diagnosis with the histologic diagnosis to determine the positive numbers of endoscopic findings in cancerous and noncancerous lesions, accuracy, sensitivity, specificity, positive predictive value, and negative predictive value. The diagnostic performance of each diagnostic criterion among C-WLI, M-NBI alone, and M-NBI after C-WLI was analyzed.

To clarify the reasons for incorrect diagnoses after reviewing the M-NBI findings and to extract the information that can be efficiently used in the training for M-NBI examination of early gastric cancers, the 2 experienced endoscopists who had analyzed more than 3000 endoscopic procedures using M-NBI reviewed the electronic images recorded in an image database for all facilities.

Statistical analysis

Demographics of the study samples between the C-WLI group and M-NBI group were compared using the Mann-Whitney U test for age and lesion size and the χ^2 test for gender, lesion location, endoscopy system, and histologic findings. Analyses of differences in the association between each endoscopic finding and cancer as well as analyses of differences in the diagnostic performance of the endoscopic findings provided by C-WLI, M-NBI alone, and M-NBI after C-WLI were compared using Pearson's χ^2 test and data from subjects with histopathologically confirmed diagnoses. Positive numbers of endoscopic findings in cancerous and noncancerous lesions were calculated with respect to relative risk.

In addition, all lesions diagnosed incorrectly using M-NBI were analyzed in terms of their endoscopic findings together with their histologic findings. The differences in the characteristics between correct and incorrect diagnoses were compared using the Mann-Whitney U test for lesion size and inspection time and using the χ^2 test for lesion location.

All P values were 2-sided and were not adjusted for multiple tests. $P < .05$ were considered statistically significant. All statistical analyses were performed using the Dr. SPSS II statistical software package (SPSS Japan Inc., Tokyo, Japan).

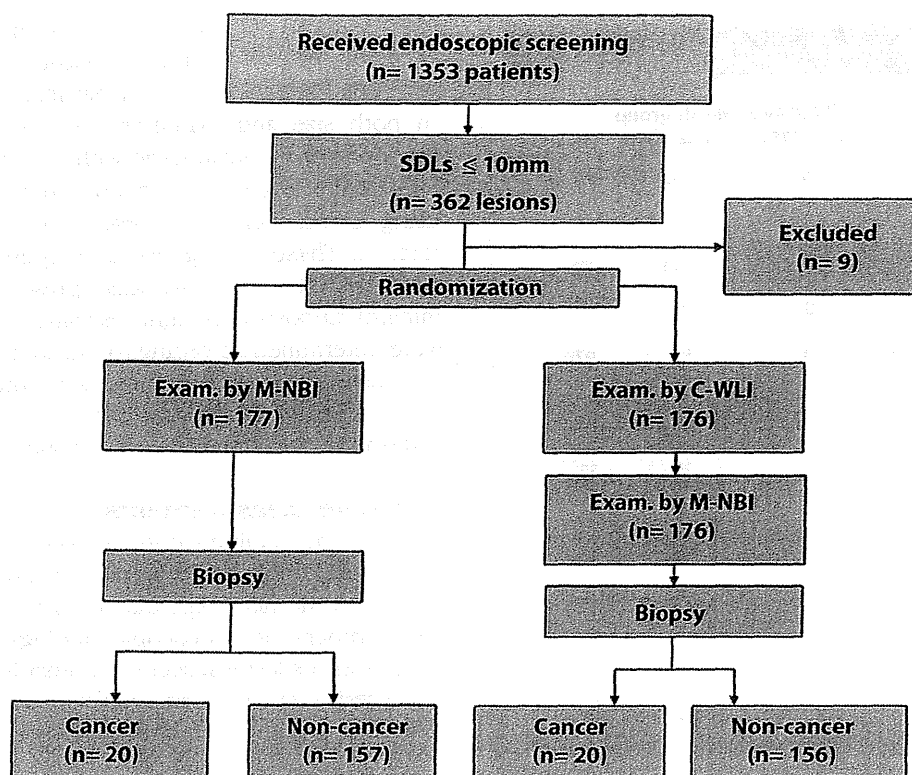


Figure 1. Trial profile, randomization, and examination. In this study, 1353 patients with concomitant gastric cancer or a history of endoscopic resection of early gastric cancer were enrolled and underwent endoscopic screening with C-WLI. Among these patients, 353 previously undiagnosed lesions were found in 362 patients that were randomly assigned to the M-NBI ($n = 177$) and C-WLI ($n = 176$) groups. *SDLs*, Small, depressed lesion; *M-NBI*, magnifying narrowband imaging; *C-WLI*, conventional white-light imaging.

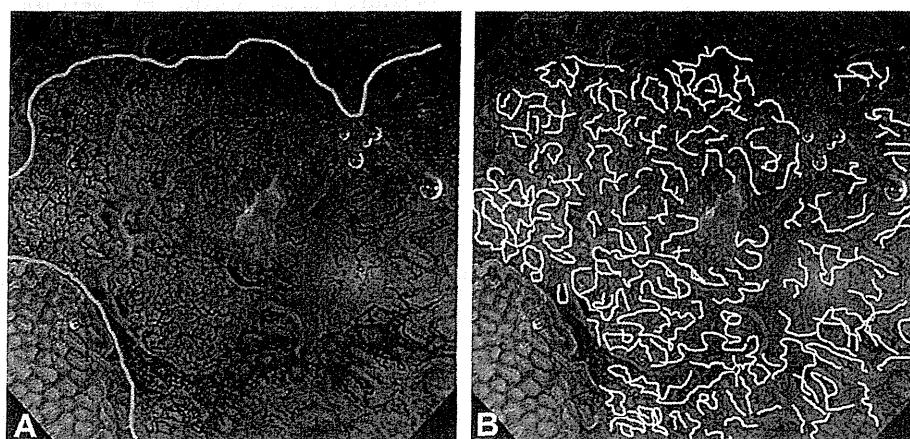

Figure 2. Endoscopic findings from magnifying narrowband imaging (M-NBI). **A**, A demarcation line (DL) is present between a depressed lesion and the surrounding mucosa (*yellow lines*). **B**, An irregular microvascular pattern (IMVP), is diagnosed if the vessels differ in shape or are a closed loop, open loop, tortuous, branched, or bizarrely shaped. The size of the vessels also varies, and their arrangement and distribution are irregular and asymmetric, respectively (*white lines*).

RESULTS

Association between each endoscopic finding and histologic result

Table 2 shows the association between each endoscopic finding in the cancerous and noncancerous lesions as diagnosed by C-WLI, M-NBI alone, and M-NBI after C-WLI.

All endoscopic findings in C-WLI showed no significant differences between cancerous and noncancerous lesions. However, all endoscopic findings (DL, IMVP, and both a DL and an IMVP) in both the M-NBI alone and M-NBI after C-WLI groups were significantly associated with the diagnosis of cancerous lesions ($P < .01$ for all). In particular, IMVP and both a DL and an IMVP had strong

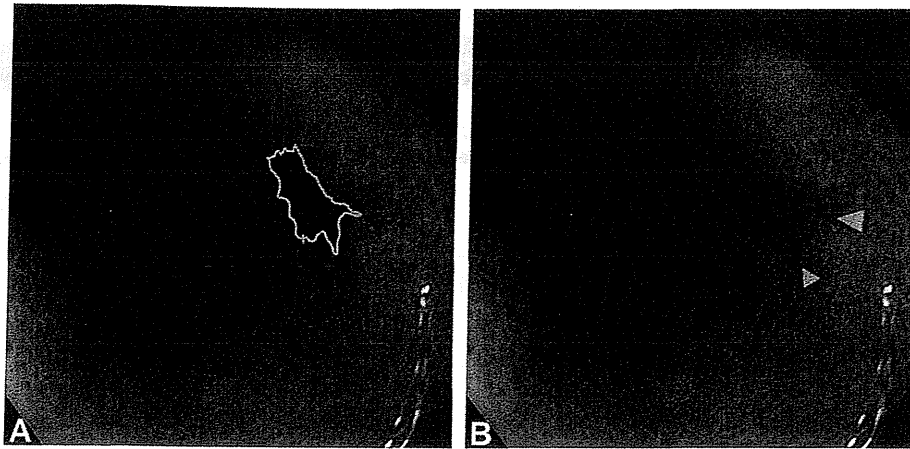


Figure 3. Endoscopic findings from conventional white-light imaging (C-WLI). **A**, An IM indicates the presence of an IM between a small, depressed lesion and the surrounding mucosa (yellow line). **B**, A spiny depressed area (SDA) indicates the presence of an SDA at the edge of a small, depressed lesion (yellow arrowheads).

associations with a cancer diagnosis (relative risks of 7.9 and 10.5 in M-NBI alone and 24.7 and 29.6 in M-NBI after C-WLI, respectively).

Diagnostic performance of each endoscopic finding

Table 3 shows the diagnostic performance according to each endoscopic finding from C-WLI, M-NBI alone, and M-NBI after C-WLI.

Accuracy. The accuracy of both M-NBI alone (90%; 95% confidence interval [CI], 85%-94%) and M-NBI after C-WLI (97%; 95% CI, 93%-99%) using a DL and an IMVP was significantly better than that of C-WLI using an IM and an SDA (65%; 95% CI, 57%-72%).

Sensitivity and specificity. Figure 4 shows the results of the comparison of the sensitivity and specificity of individual endoscopic findings provided by C-WLI, M-NBI alone, and M-NBI after C-WLI. The endoscopic findings of C-WLI were low in sensitivity (75% [95% CI, 51%-91%] for IM, 40% [95% CI, 19%-64%] for SDA, and 40% [95% CI, 19%-64%] for IM and SDA) and specificity (44% [95% CI, 36%-52%] for IM, 64% [95% CI, 56%-72%] for SDA, and 68% [95% CI, 60%-75%] for IM and SDA). The endoscopic diagnostic performance increased for C-WLI, followed by M-NBI alone; M-NBI after C-WLI ultimately showed the best diagnostic performance.

The sensitivity of an IMVP was low (60%; 95% CI, 36%-81%) in M-NBI alone, indicating that IMVP evaluation using M-NBI alone could lead to misdiagnosis of some cancers, and the sensitivity of an IMVP did not improve by combining it with evaluation of a DL (60%; 95% CI, 36%-81%). The sensitivity of an IMVP and both a DL and an IMVP in M-NBI alone significantly improved when they were evaluated after C-WLI (95% [95% CI, 75%-100%] and 95% [95% CI, 75%-100%]; $P = .02$ and $P = .02$, respectively). The specificity of an IMVP and both a DL and an IMVP was high in M-NBI alone (92% [95% CI, 87%-96%] and 94% [95% CI, 89%-97%], respectively) and M-NBI after

WLI (96% [95% CI, 92%-99%] and 97% [95% CI, 93%-100%], respectively), suggesting that the presence of an IMVP indicates a high probability of cancer.

The sensitivity of a DL in M-NBI alone and M-NBI after C-WLI was high (85% [95% CI, 62%-97%] and 95% [95% CI, 75%-100%], respectively), whereas the specificity of these findings (53% [95% CI, 45%-61%] and 49% [95% CI, 41%-58%], respectively) was significantly lower than that of an IMVP (92% [95% CI, 87%-96%] and 96% [95% CI, 92%-99%]; $P = .000$ and $P = .000$, respectively). The specificity of a DL in M-NBI alone and M-NBI after C-WLI improved significantly when evaluated in combination with an IMVP (94% [95% CI, 89%-97%] and 97% [95% CI, 93%-100%]; $P = .000$ and $P = .000$, respectively). This suggests that DL is a reliable finding for identification of cancer but it needs to be evaluated with C-WLI findings and the presence of an IMVP to exclude false-positive lesions.

Positive predictive value and negative predictive value. The positive predictive value of a DL in M-NBI alone and M-NBI after C-WLI were 19% (95% CI, 11%-28%) and 19% (95% CI, 13%-29%), respectively, and were similar to those in C-WLI (15% [95% CI, 8%-23%] for IM, 13% [95% CI, 6%-23%] for SDA, and 14% [95% CI, 6%-25%] for IM and SDA). The low positive predictive value of a DL in M-NBI alone and M-NBI after C-WLI improved significantly when evaluated with IMVP ($P < .01$ and $P < .01$, respectively).

The negative predictive value of all endoscopic findings of M-NBI alone exceeded 95% (97% [95% CI, 90%-98%] for DL, 95% [95% CI, 90%-98%] for IMVP, and 95% [95% CI, 90%-98%] for both DL and IMVP). The negative predictive value of all endoscopic findings of M-NBI after C-WLI was 99% (99% [95% CI, 93%-100%] for DL, 99% [95% CI, 96%-100%] for IMVP, and 99% [95% CI, 96%-100%] for both DL and IMVP). This indicates that M-NBI findings, especially when M-NBI is performed after C-WLI, could be good markers to exclude cancer from small, depressed gastric lesions that were detected with C-WLI.

TABLE 2. Association between each endoscopic finding and cancer

Method	Endoscopic findings	Pathologic diagnosis		RR [95% CI]	P
		Cancer	Noncancerous		
C-WLI	IM	15	88	1.3 [1.0-1.8]	.11
	SDA	8	56	1.1 [.6-2.0]	.72
	IM and SDA	8	50	1.3 [.7-2.2]	.48
M-NBI alone	DL	17	74	1.8 [1.4-2.3]	<.01
	IMVP	12	12	7.9 [4.1-15.1]	<.01
	DL and IMVP	12	9	10.5 [5.1-21.7]	<.01
M-NBI after C-WLI	DL	19	79	1.9 [1.6-2.3]	<.01
	IMVP	19	6	24.7 [11.2-54.5]	<.01
	DL and IMVP	19	5	29.6 [12.4-70.6]	<.01

M-NBI, Magnifying narrow-band imaging; C-WLI, conventional white-light imaging; DL, demarcation line; IMVP, irregular microvascular pattern; IM, irregular margin; SDA, spiny depressed area; RR, relative risk; CI, confidence interval.

TABLE 3. Diagnostic performance according to endoscopic findings

Method	Endoscopic finding	Accuracy (%)	Sensitivity (%)	Specificity (%)	PPV (%)	NPV (%)
C-WLI	IM	47	75	44	15	93
	SDA	61	40	64	13	89
	IM and SDA	65	40	68	14	90
M-NBI	DL	57	85	53	19	97
	IMVP	89	60	92	50	95
	DL and IMVP	90	60	94	57	95
M-NBI after C-WLI	DL	55	95	49	19	99
	IMVP	96	95	96	76	99
	DL and IMVP	97	95	97	79	99

M-NBI, Magnifying narrow-band imaging; C-WLI, conventional white-light imaging; DL, demarcation line; IMVP, irregular microvascular pattern; IM, irregular margin; SDA, spiny depressed area; PPV, positive predictive value; NPV, negative predictive value.

Analysis of lesions incorrectly diagnosed by M-NBI

We experienced 23 incorrect diagnoses (false positive, 14; false negative, 9) and 330 correct diagnoses for both M-NBI alone and M-NBI after C-WLI. There were no significant differences in characteristics (lesion size and location and time to establish diagnosis) between the correctly and incorrectly diagnosed lesions (Table 4). Two reviewers with experience in endoscopic diagnosis of more than 3000 cases using M-NBI reviewed the images of lesions that were misdiagnosed by M-NBI and identified the reasons for misdiagnosis as follows.

Technical factors. In 10 cases (5 false positives and 5 false negatives), the findings were judged to be indeterminate because the images were at a low magnification and/or out of focus.

Cognitive factors. Eleven cases had originally been misdiagnosed despite adequate examination. Eight cases were diagnosed as false positives, and 3 were diagnosed as false negatives. Reviewers correctly diagnosed lesions in 5 of the 8 false positives and 2 of the 3 false negatives. Thus, the reviewers posited that 1 reason for misdiagnosis was a lack of interpretive skill on the part of the endoscopist. The cases that were misdiagnosed despite adequate examination included 3 false positives and 1 false negative that the reviewers also misdiagnosed. This was presumably because of the limitations of the endoscopic criteria for diagnosing cancers used in this study.

Others. One diagnosis was mistakenly entered as a histologic noncancerous lesion on the case report form. One patient was misdiagnosed with a noncancerous lesion because of a sampling error as a result of forceps biopsy.

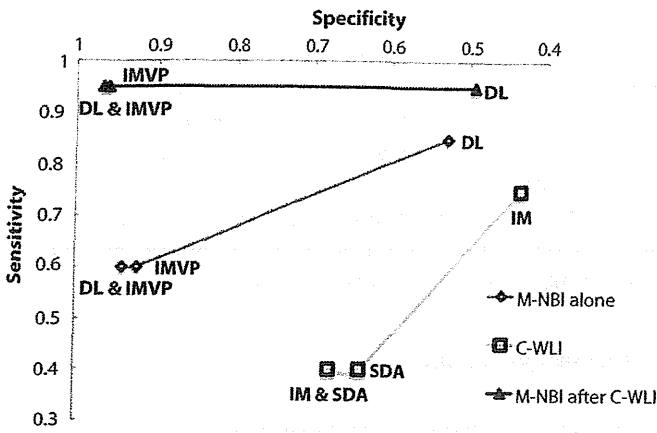


Figure 4. Comparison of the sensitivity and specificity of individual endoscopic findings in magnifying narrow-band imaging (M-NBI) alone, conventional white-light imaging (C-WLI), and M-NBI after C-WLI. Among all endoscopic findings, diagnostic performance improved significantly for C-WLI alone, followed by M-NBI alone, and then by M-NBI after C-WLI.

DISCUSSION

In this study, we found that the endoscopic diagnostic performance increased for C-WLI, followed by M-NBI alone; M-NBI after C-WLI ultimately showed the best diagnostic performance for each diagnostic criterion (Fig. 4). Therefore, M-NBI should generally be performed after evaluation of C-WLI findings. The combination of DL and IMVP characterized by M-NBI after C-WLI contributed to the most reliable diagnosis for small, depressed gastric lesions and can be an ideal, simple, standard diagnostic strategy for small, depressed gastric lesions.

Based on the current results, we herein propose an efficient endoscopic diagnostic strategy for small, depressed gastric lesions, as indicated in Figure 5. In the M-NBI after C-WLI technique, both a DL and an IMVP had a high negative predictive value (99% and 99%, respectively), indicating that both criteria were sufficiently sensitive for exclusion of noncancerous lesions. A DL is technically easier to identify than an IMVP.¹⁵ Therefore, the identification of a DL should be the first step in the diagnosis of gastric cancer because the absence of a DL alone allows for the exclusion of a noncancerous lesion. If a DL is absent, a noncancerous lesion can be diagnosed without any additional findings. Next, the presence of an IMVP is evaluated within a DL. If both a DL and IMVP are present, cancer is strongly suggested because an IMVP is sufficiently specific in the diagnosis of cancer (ie, it has a high positive predictive value) and an additional procedure with curative intent is indicated. If an IMVP is absent, the lesion can be diagnosed as a noncancerous lesion without a target biopsy sample because the negative predictive value of an IMVP is also very high. This strategy will provide a high level of accurate diagnosis for small, depressed gastric lesions. In particular, because the negative predictive value of both a DL and an IMVP is very high in

TABLE 4. Characteristics of correct and incorrect diagnosis by M-NBI

	Correct diagnosis (n = 330)	Incorrect diagnosis (n = 23)	P
Mean SDL size, mm	6	6	.67
SDL location (longitudinal)			
Upper third	61	5	
Middle third	82	7	.45
Lower third	187	11	
SDL location (circumferential)			
Anterior wall	57	4	.34
Lesser curvature	106	9	
Posterior wall	93	8	
Greater curvature	74	2	
Inspection time			
Average(s)	72	100	.15

M-NBI, Magnifying narrow-band imaging; SDL, small, depressed lesion.

M-NBI after C-WLI, the benefits of this strategy include reductions in the risk of hemorrhage, number of biopsy specimens for pathologic analysis, procedure time, and medical expenses, especially when a noncancerous lesion is diagnosed.

Analysis of lesions incorrectly diagnosed by M-NBI revealed reasons for misdiagnosis. The reasons for misdiagnosis included both technical and cognitive factors; thus, training should involve both aspects. Technical errors were mainly caused by difficulty in observation of a DL and an IMVP at maximum magnification. Attachment of a rubber cap is very helpful for capturing in-focus magnified images, but we failed to obtain sufficient images in some cases. To improve the performance of these techniques, 1 of the authors has published a book with a DVD¹⁶ explaining the techniques necessary to perform M-NBI at maximum magnification. The role of videos in transferring information relating to endoscopic technique will be more important than that of text from now on. Cognitive factors included the lack of interpretative skill on the part of the endoscopist. In their review of the images, the 2 reviewers revised the diagnosis in 7 cases, indicating a false-positive rate of 4.5% and false-negative rate of 22.5%. These numbers could have improved with better mastery of interpretative skill. An e-learning system was developed to improve interpretative skill using M-NBI, and a multicenter study, entitled "Learning curve with an e-learning system on magnifying narrow-band imaging in endoscopic diagnosis of gastric lesions: A randomized

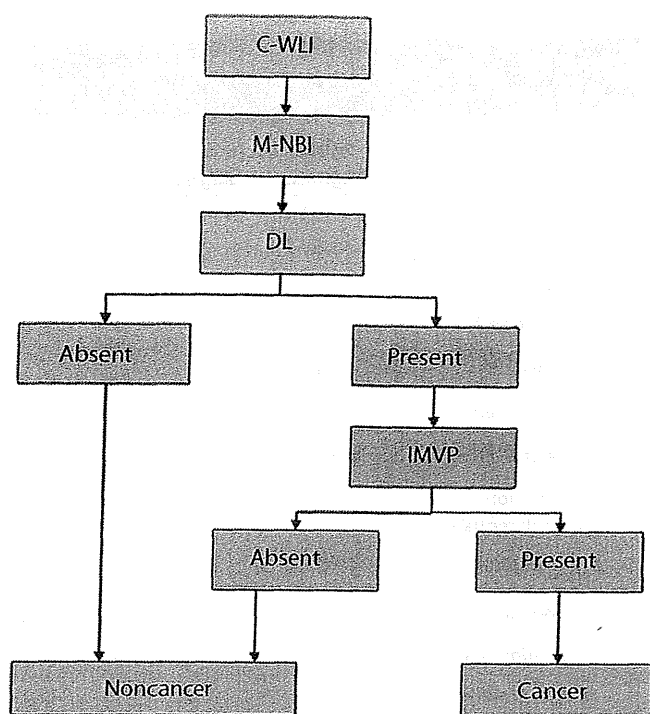


Figure 5. Strategy of using simplified criteria to make an endoscopic diagnosis of small, depressed lesions using magnifying narrowband imaging (M-NBI). When a small, depressed gastric lesion is detected by conventional white-light imaging (C-WLI), the presence or absence of a demarcation line (DL) should be the first step in diagnosing gastric cancer. If the DL is absent, a noncancerous lesion can be diagnosed. If the DL is present, the presence of an irregular microvascular pattern (IMVP) should be used for diagnosis. If an IMVP is absent, a noncancerous lesion can be diagnosed without a target biopsy sample and/or EMR/ESD. Finally, if both a DL and an IMVP are present, cancer is strongly suggested, and additional procedures are indicated.

study” (UMIN-CTR 000008569), was begun to examine the system’s usefulness. After the review of recorded images by the 2 experts, there were limits of diagnosing lesions with M-NBI in 4 cases. The lesions did not fulfill the endoscopic cancerous or noncancerous diagnostic criteria of a DL and an IMVP according to M-NBI. For these lesions, development of other diagnostic equipment or another method is required to further improve the diagnostic performance.

This study has limitations. The study samples were limited to ≤ 10 -mm depressed lesions. A diagnosis based on the microvascular pattern and a DL, but not the microsurface pattern, is not universally applicable to all macroscopic types of lesions. However, all small, depressed lesions in this study had a microvascular pattern that could be visualized, allowing the lesions to be diagnosed. Thus, the current authors are prospectively studying (UMIN-CTR 000004045) the ability of M-NBI to diagnose all macroscopic types of lesions using the vessel-plus-surface classification system put forth by Yao et al without size or macroscopic type limitation. The vessel-plus-surface classification system uses the microsurface pattern, microvascular pattern, and DL as indices.

In conclusion, the current study suggests that although M-NBI alone provided good diagnostic performance, it is important to conduct a C-WLI evaluation before M-NBI diagnosis. When using M-NBI, identification of a DL is the first step in the diagnosis of cancer, and the subsequent identification of an IMVP is useful for excluding noncancerous lesions among the lesions that were identified to have a DL. Training in both techniques and knowledge is important to improve M-NBI diagnosis.

ACKNOWLEDGMENTS

The study investigators in Japan were as follows: Noriya Uedo and Yoji Takeuchi (Osaka Medical Cancer for Cancer and Cardiovascular Diseases, Osaka); Hisashi Doyama, Yoshibumi Kaneko, Kenichi Takemura, Kazuhiro Miwa, and Shinya Yamada (Ishikawa Prefectural Central Hospital, Ishikawa); Yutaka Saito, Ichiro Oda, Shigetaka Yoshinaga, Satoru Nonaka, and Shusei Fukunaga (National Cancer Center Hospital, Tokyo); Manabu Muto, Yasumasa Ezoe, Shuko Morita, and Takahiro Horimatsu (Kyoto University, Kyoto); Kenshi Yao, Takashi Nagahama, Hiroshi Tanabe, Takahiro Beppu, Yoichiro Ono, and Masao Takeichi (Fukuoka University Chikushi Hospital, Fukuoka); Kazuhiro Kaneko, Tomonori Yano, Hiroaki Kon, and Shinya Tsuruta (National Cancer Center Hospital East, Chiba); Yoshiro Kawahara, Toshio Uraoka, Seiji Kawano, and Keisuke Hori (Okayama University Hospital, Okayama); Chizu Yokoi and Naoyoshi Nagata (National Center for Global Health and Medicine, Tokyo); Yasushi Sugiura (Kitano Hospital, Osaka); Hideki Ishikawa (Kyoto Prefectural University of Medicine, Kyoto); and Tomoko Aoyama (Medical Research Support, Osaka).

REFERENCES

1. Ferlay J, Shin HR, Bray F, et al. Estimates of worldwide burden of cancer in 2008: GLOBOCAN 2008. *Int J Cancer* 2010;127:2893-917.
2. Gotoda T, Yanagisawa A, Sasako M, et al. Incidence of lymph node metastasis from early gastric cancer: estimation with a large number of cases at two large centers. *Gastric Cancer* 2000;3:219-25.
3. Everett SM, Axon AT. Early gastric cancer in Europe. *Gut* 1997;41:142-50.
4. Hirasawa T, Gotoda T, Miyata S, et al. Incidence of lymph node metastasis and the feasibility of endoscopic resection for undifferentiated-type early gastric cancer. *Gastric Cancer* 2009;12:148-52.
5. Tada M, Murakami A, Karita M. Endoscopic resection of early gastric cancer. *Endoscopy* 1993;25:445-51.
6. Ono H, Kondo H, Gotoda T, et al. Endoscopic mucosal resection for treatment of early gastric cancer. *Gut* 2001;48:225-9.
7. Yao K, Anagnostopoulos GK, Ragunath K. Magnifying endoscopy for diagnosing and delineating early gastric cancer. *Endoscopy* 2009;41:462-7.
8. Ezoe Y, Muto M, Uedo N, et al. Magnifying narrowband imaging is more accurate than conventional white-light imaging in diagnosis of gastric mucosal cancer. *Gastroenterology* 2011;141:1017-25.
9. Yao K, Oishi T, Matsui T, et al. Novel magnified endoscopic findings of microvascular architecture in intramucosal gastric cancer. *Gastrointest Endosc* 2002;56:279-84.
10. Yao K, Nagahama T, So S, et al. Morphological correlation between ordinary and magnifying endoscopic findings with regard to small

- depressed-type gastric cancers [in Japanese with English abstract]. *Stomach and Intestine* (Tokyo) 2006;41:781-94.
11. Bossuyt PM, Reitsma JB, Bruns DE, et al. The STARD statement for reporting studies of diagnostic accuracy: explanation and elaboration. *Ann Intern Med* 2003;138:W1-12.
 12. Gono K, Yamazaki K, Doguchi N, et al. Endoscopic observation of tissue by narrow band illumination. *Opt Rev* 2003;10:211-5.
 13. Gono K, Obi T, Yamaguchi M, et al. Appearance of enhanced tissue feature in narrow-band endoscopic imaging. *J Biomed Opt* 2004;9:568-77.
 14. Muto M, Katada C, Sano Y, et al. Narrow band imaging: a new diagnostic approach to visualize angiogenesis in the superficial neoplasia. *Clin Gastroenterol Hepatol* 2005;3(Suppl 1):S16-20.
 15. Yao K, Iwashita A, Tanabe H, et al. Novel zoom endoscopy technique for diagnosis of small flat gastric cancer: a prospective, blind study. *Clin Gastroenterol Hepatol* 2007;7:869-78.
 16. Yao K. Zoom gastroscopy technique (with DVD). Tokyo: Nihon Medical Center; 2012.

Center Hospital, Tokyo, Japan (5), Division of Digestive Endoscopy and Gastrointestinal Oncology, National Cancer Center Hospital East, Chiba, Japan (6), Division of Endoscopy, Okayama University, Okayama, Japan (7), Endoscopy Division, National Center for Global Health and Medicine, Tokyo, Japan (8), Division of Gastroenterology and Hepatology, Kitano Hospital, Osaka, Japan (9), Department of Molecular-Targeting Cancer Prevention, Kyoto Prefectural University of Medicine, Kyoto, Japan (10), Department of Gastroenterology and Hepatology, Graduate school of Medicine, Kyoto University, Kyoto, Japan (11).

Reprint requests: Shinya Yamada, MD, Ishikawa Prefectural Central Hospital, 2-1 Kuratsukihigashi, Kanazawa, Ishikawa 920-8530, Japan.

Endoscopedia

GIE now has a blog! Keep up with GIE news by following us at www.endoscopedia.com.

Diagnostic performance and limitations of magnifying narrow-band imaging in screening endoscopy of early gastric cancer: a prospective multicenter feasibility study

Kenshi Yao · Hisashi Doyama · Takuji Gotoda · Hideki Ishikawa · Takashi Nagahama · Chizu Yokoi · Ichiro Oda · Hirohisa Machida · Kunihisa Uchita · Masahiko Tabuchi

Received: 22 August 2013 / Accepted: 16 December 2013

© The International Gastric Cancer Association and The Japanese Gastric Cancer Association 2014

Abstract

Background Curative treatment of patients with gastric cancer requires reliable detection of early gastric cancer. Magnifying endoscopy with narrow-band imaging (M-NBI) is useful for the accurate preoperative diagnosis of early gastric cancer. However, the role of M-NBI in screening endoscopy has not been established. The aims of this study were to determine the feasibility and limitations of M-NBI in screening endoscopy.

Methods We conducted a multicenter prospective uncontrolled trial of patients undergoing routine screening endoscopy patients. We determined the diagnostic accuracy, sensitivity and specificity of M-NBI according to the degree of certainty and need for biopsy, as assessed using the VS (vessel plus surface) classification system. We

analyzed the endoscopic and histopathological characteristics of both false negative and false positive high confidence M-NBI diagnoses. We then developed a provisional diagnostic strategy based on the diagnostic performance and limitations identified in this study.

Results A total of 1097 patients were enrolled in the study. We analyzed 371 detected lesions (20 cancers and 351 non-cancers). The accuracy, sensitivity and specificity of high confidence M-NBI diagnoses were 98.1, 85.7 and 99.4 %, respectively. The false negative case was a pale mucosal lesion with tissue diagnosis of signet-ring cell carcinoma. Exclusion of pale mucosal lesions increased the accuracy, sensitivity and specificity of high confidence M-NBI diagnoses to 99.4, 100 and 99.4 %, respectively. We therefore propose a practical strategy targeting non-pale mucosal lesions.

K. Yao (✉)

Department of Endoscopy, Central Research Institute for Endoscopy, Fukuoka University Chikushi Hospital, Fukuoka University, 1-1-1 Zokumyoin, Chikushino, Fukuoka 818-8502, Japan
e-mail: yao@fukuoka-u.ac.jp

H. Doyama

Department of Gastroenterology, Ishikawa Prefectural Central Hospital, Kanazawa, Japan

T. Gotoda

Department of Gastroenterology and Hepatology, Tokyo Medical University, Tokyo, Japan

H. Ishikawa

Department of Molecular-Targeting Cancer Prevention, Graduate School of Medical Science, Kyoto Prefectural University of Medicine, Kyoto, Japan

T. Nagahama

Department of Gastroenterology, Fukuoka University Chikushi Hospital, Chikushino, Japan

C. Yokoi

Department of Gastroenterology, National Center for Global Health and Medicine, Tokyo, Japan

I. Oda

Endoscopy Division, National Cancer Center Hospital, Tokyo, Japan

H. Machida

Department of Gastroenterology, Osaka City University Graduate School of Medicine, Osaka, Japan

K. Uchita

Department of Gastroenterology, Kochi Red Cross Hospital, Kochi, Japan

M. Tabuchi

Department of Gastroenterology, Izumiotsu Municipal Hospital, Izumiotsu, Japan

Conclusions With a refined strategy considering its limitations, M-NBI can act as an “optical biopsy” in screening endoscopies.

Keywords Gastric cancer · Magnifying endoscopy · Narrow-band imaging · Screening endoscopy · VS classification

Abbreviations

M-NBI	Magnifying endoscopy with narrow-band imaging
C-WLI	Conventional endoscopy with white-light imaging
STARD	Standards for the Reporting of Diagnostic Accuracy Studies
VS	Vessel plus surface
MV	Microvascular
MS	Microsurface
CI	Confidence interval
EGD	Esophagogastroduodenoscopy

Background

Gastric cancer is the second leading cause of cancer death worldwide [1]. Detection at an early stage is important in obtaining good outcomes for patients with gastric cancer. Magnifying endoscopy with narrow-band imaging (M-NBI) is a recently developed, powerful optical image enhanced endoscopic technique that has become commonplace in the field of gastrointestinal endoscopy [2]. We previously demonstrated excellent real time diagnostic performance in making an accurate endoscopic diagnosis of early gastric cancer, in a multicenter, prospective, randomized controlled trial in which we performed M-NBI following thorough examinations using conventional endoscopy with white light imaging (C-WLI) [3]. However, the conditions differed from those in screening endoscopy in actual clinical practice in the following ways. (1) We only included patients at high risk of developing gastric cancer. (2) The diameter of the target lesions was limited to ≤ 10 mm. (3) The macroscopic type of lesions was also limited to the superficial depressed type. The validity of the clinical application of M-NBI in routine screening endoscopy has therefore yet to be confirmed. In other words, no studies have reported the feasibility and limitations of M-NBI, irrespective of size or macroscopic type, in a prospective study. Furthermore, it is not clear how M-NBI can contribute to cost effectiveness, in other words how many endoscopic biopsies are required to diagnose one cancer.

Accordingly, the first aim of this study was to investigate the real time diagnostic performance of M-NBI in

screening endoscopy for circumscribed mucosal lesions of all macroscopic types and sizes. The next aims of this study were to identify the limitations of M-NBI (endoscopic and pathological characteristics of false negative and false positive cases), and to determine the number of biopsies for confirming the diagnosis of gastric cancer. Finally, we aimed to propose an efficient endoscopic diagnostic strategy for M-NBI in screening endoscopy.

Patients and methods

Study design and participants

This prospective uncontrolled multicenter feasibility study was conducted at 7 centers in Japan, in accordance with the Standards for the Reporting of Diagnostic Accuracy Studies (STARD) initiative [4], and the Declaration of Helsinki.

Consecutive patients who underwent screening upper gastrointestinal endoscopy at each center between October 2009 and November 2010 were considered for enrollment in this study. We included patients who gave informed consent before the endoscopic examinations. We excluded patients for whom endoscopic diagnoses had already been made, those in whom biopsies were not taken for cancer screening (e.g. for detection of *Helicobacter pylori*-associated gastritis), those patients who underwent gastrectomy, those taking medicine associated with bleeding tendency, and those with severe underlying diseases.

Written informed consent was obtained from each participant, and the study was approved by the institutional review board of each participating hospital. The clinical trial number of this study was UMIN 000004045.

Participating endoscopists

All endoscopic examinations were performed at 7 centers by 20 endoscopists accredited by the Japan Gastroenterological Endoscopy Society. The median (range) duration of experience of gastrointestinal endoscopy and upper gastrointestinal M-NBI were 10 (5–16) years and 3 (0.5–5) years, respectively. All participating endoscopists underwent instruction with the textbook entitled “Zoom gastroscopy: Magnifying endoscopy in the stomach [5]”, written by the lead researcher (K. Y.) before study commencement, in order to minimize diagnostic variation between participating endoscopists.

Endoscopy system and endoscopy procedures

The NBI system is an optical image-enhanced technology containing a narrow-band filter with central wavelengths of

415 and 540 nm. Since light with these wavelengths is well absorbed by hemoglobin and propagates shallowly within the mucosal tissue, the subepithelial microvascular architecture and the mucosal microsurface structure can be visualized in high contrast. Details of these principles have been described elsewhere [6, 7].

We used the electronic endoscopy system with NBI (Evis Lucera Spectrum System, Olympus Medical Systems, Tokyo, Japan), a high-resolution liquid crystal monitor (OEV191H; Olympus), and high-resolution optical magnifying endoscopes (GIF-Q240Z, GIF-H260Z; Olympus). The maximal resolution power of these scopes is 7.9 μm for the GIF-Q240Z, and 5.6 μm for the GIF-H260Z. To standardize the conditions under which magnified endoscopic images were obtained, before insertion of the scope we mounted a black soft hood attachment (MAJ-1988 for the GIF-Q240Z, MAJ-1989 for the GIF-H260Z; Olympus) on the tip of the scope, allowing the endoscopist to easily and consistently fix the distance between the tip of the scope and the target lesion at maximum magnification. The video processor was constantly set as follows: the structure enhancement function was set at the B6 level for C-WLI, and B8 for M-NBI, with the color mode fixed at level 1.

Endoscopic screenings were performed by a single endoscopist using C-WLI according to the systematic screening protocol for the stomach [8]. The patient's preparation was the same as for conventional endoscopy [9]. When a circumscribed mucosal lesion showing changes in surface or color [9, 10] was detected, the lesion was subsequently examined at maximal magnification using NBI. According to the predetermined criteria, the M-NBI examination was performed by the same endoscopist, without any consultation with other endoscopists, and the assisting physician immediately recorded the results on the uniform case record form. One target biopsy was then taken from each detected lesion. After the endoscopic examination was completed, the case record form was sent by fax to the data center at the Department of Molecular-Targeting Cancer Prevention, Graduate School of Medical Science, Kyoto Prefectural University of Medicine, within 3 days, without waiting for the histopathological diagnosis. A full description of the endoscopic procedures followed, and evaluations, has been published elsewhere [11–13].

M-NBI diagnostic criteria

We employed the established VS (vessel plus surface) classification system for the M-NBI diagnosis of early gastric cancer (Fig. 1) [11], the most commonly applied system in clinical practice [3, 12–25]. Briefly, when we detect a mucosal lesion using C-WLI, we analyze the subsequent M-NBI findings. Firstly, using M-NBI, we

determine whether a demarcation line is present between the mucosal lesion and the background surrounding mucosa. If the demarcation line is absent, a non-cancer diagnosis is made. If the demarcation line is present, we analyze the microvascular (MV) and microsurface (MS) patterns of the target lesion independently. The MV pattern is classified into 3 categories, namely a regular/irregular/absent MV pattern. Similarly, the MS pattern is classified into 3 categories, a regular/irregular/absent MS pattern. We then make the diagnosis of cancer according to the following criteria.

1. Presence of an irregular microvascular (MV) pattern with a demarcation line
2. Presence of an irregular microsurface (MS) pattern with a demarcation line

If either or both criteria are fulfilled, an endoscopic diagnosis of cancer can be made. Otherwise, an endoscopic diagnosis of non-cancer will be made. The details of the VS classification system have been reported elsewhere [9, 11].

Endoscopic diagnosis according to degree of certainty and need for biopsy

In order to determine how many biopsies are needed to diagnose one cancer, we set the grade of endoscopic diagnosis according to certainty and assessment of the need for biopsy.

Grade 1: non-cancer with high degree of confidence. The lesion can be diagnosed as non-cancer from the endoscopic findings alone. Biopsies of the lesion do not need to be taken under normal conditions.

Grade 2: non-cancer with low degree of confidence. The lesion has the appearance of non-cancer from the endoscopic findings. However, biopsies need to be taken from the lesion to confirm the diagnosis.

Grade 3: indeterminate. The lesion is indeterminate for non-cancer or cancer from the endoscopic findings alone. Therefore, biopsies need to be taken from the lesion to make a definitive diagnosis.

Grade 4: cancer with low degree of confidence. The lesion is suspicious for cancer from the endoscopic findings. However, biopsies need to be taken from the lesion to confirm the diagnosis.

Grade 5: cancer with high degree of confidence. The lesion can be diagnosed as cancer from the endoscopic findings alone. Biopsies of the lesion do not need to be taken under normal conditions.

For the purpose of this study, we reclassified Grades 1–3 as non-cancer and Grade 4 and Grade 5 as cancer, while Grade 1 and Grade 5 as “high confidence prediction” and Grades 2–4 as “low confidence prediction” [26, 27].

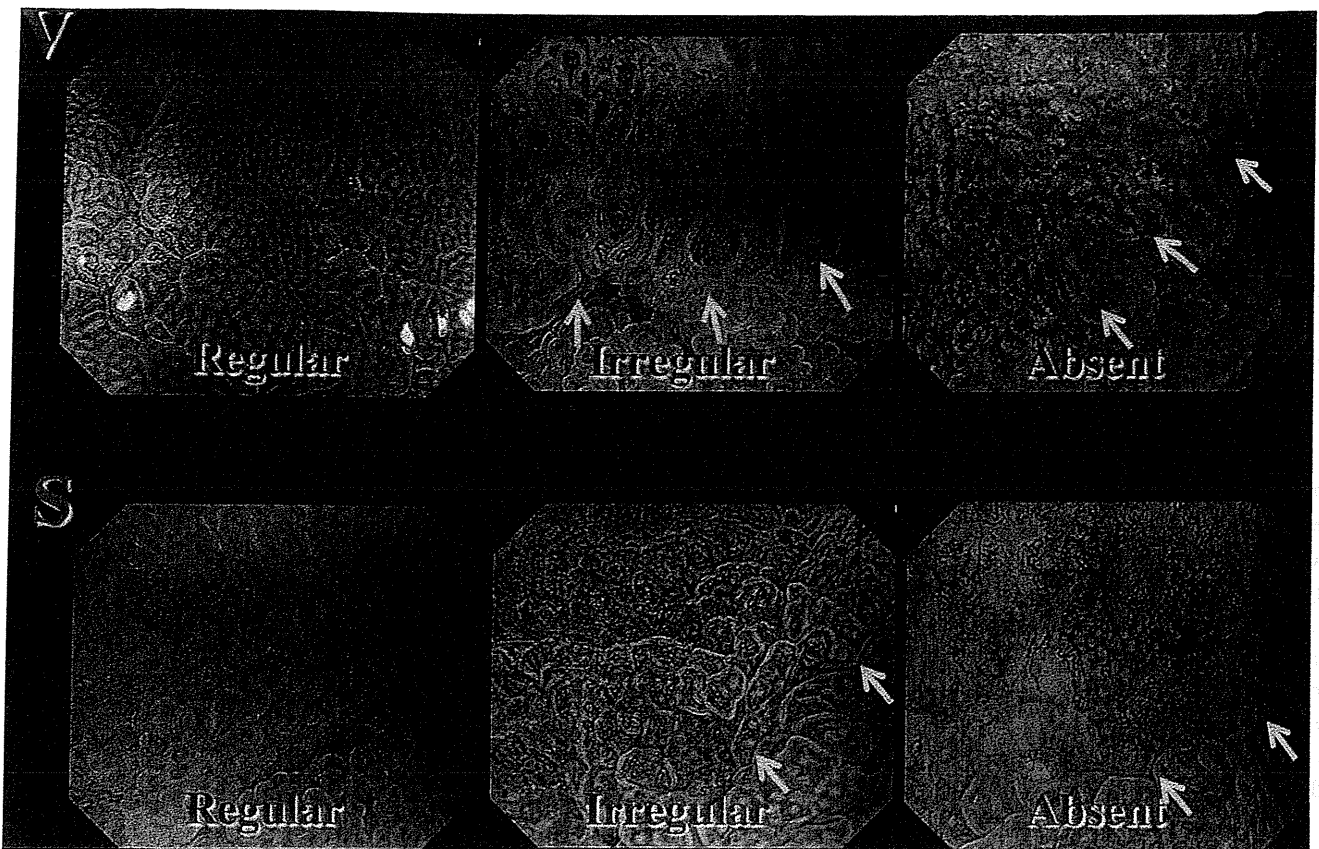
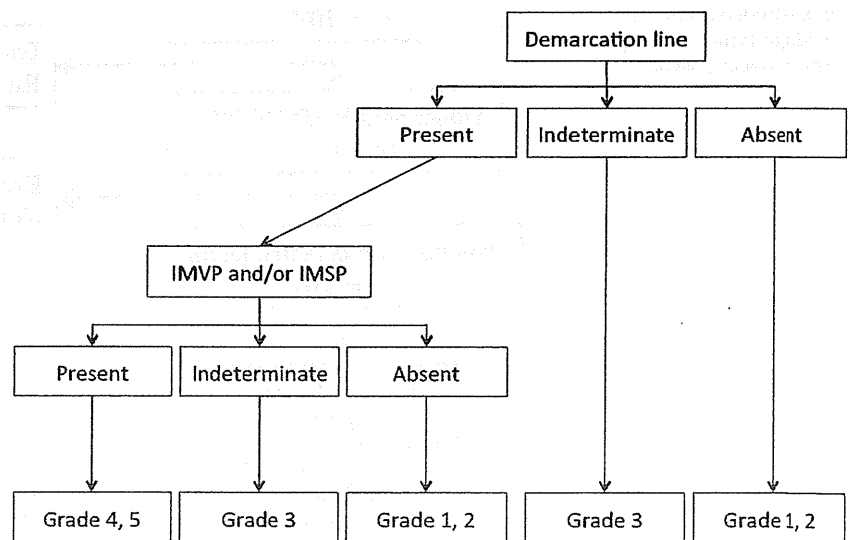


Fig. 1 VS classification using M-NBI (Reproduced with permission from Endoscopy 2009; 41:462–7 [11]). *V* microvascular pattern, classified as regular/irregular/absent. *S* microsurface pattern, classified as regular/irregular/absent

Fig. 2 Diagnostic flow diagram demonstrating the correlation between the VS (vessel plus surface) classification and Grades 1–5. *IMVP* irregular microvascular pattern, *IMSP* irregular microsurface pattern. Grade 1: non-cancer with high degree of confidence (no need for biopsies); Grade 2: non-cancer with low degree of confidence (biopsies required); Grade 3: indeterminate (biopsies required); Grade 4: cancer with low degree of confidence (biopsies required); Grade 5: cancer with high degree of confidence (no need for biopsies)



The diagnostic flow diagram shown in Fig. 2 demonstrates the correlation between the VS classification [28] and Grades 1–5. In this algorithm, when one of each finding is difficult for the endoscopist to determine whether it is present or absent, the finding is categorized as indeterminate.

Gold standard

Definitive diagnoses were made on the basis of histopathological examination of biopsy specimens or endoscopically resected specimens by highly experienced gastrointestinal pathologists in each institute, who were

blinded to the M-NBI findings. Histopathological diagnoses were made with reference to the revised Vienna classification [C1: negative for neoplasia; C2: indefinite for neoplasia; C3: mucosal low-grade neoplasia (low-grade dysplasia/adenoma); C4: mucosal high-grade neoplasia (4.1: high-grade dysplasia/adenoma; 4.2: noninvasive carcinoma (carcinoma in situ); 4.3: intramucosal carcinoma); and C5: submucosal invasion by tumor] [29, 30]. For the purpose of this study, C4 and C5 were grouped together into one category, known as cancer, and all other classifications as non-cancer [15].

End points

The primary aim of this feasibility study was to investigate the real time diagnostic performance (accuracy, sensitivity and specificity) of M-NBI, based on the degree of certainty (high or low confidence).

Another end point was the identification of the limitations of M-NBI in screening endoscopy when the endoscopist made a high confidence M-NBI diagnosis without biopsy. Limitations are defined as follows: (1) false negative cases with Grade 1 endoscopic diagnoses (non-cancer with high degree of confidence, no need for biopsies), but the pathological diagnosis was cancer, and (2) false positive cases with Grade 5 endoscopic diagnoses (cancer with

high degree of confidence, no need for biopsies), but the pathological diagnosis was non-cancer. The other end points were to investigate the diagnostic performance for the subgroup of lesions after exclusion of limited cases; to identify the number of biopsies needed to diagnose one cancer, and to propose a strategy for M-NBI in screening endoscopy with reference to the above results of this prospective study.

The estimated number of biopsies needed to detect one cancer was calculated as follows:

$$\text{Number of biopsies} = \frac{\text{number of lesions Grade 2}}{4/\text{number of detected cancers}}$$

Statistical analysis

Statistical analyses were performed using SPSS software version 10.5J for Windows (SPSS Inc., Chicago, IL, USA). Diagnostic accuracy, sensitivity, specificity are presented as percentages with 95 % confidence intervals (CI). Continuous variables are expressed as median with range. Comparisons of incidences between two groups were conducted using Pearson's Chi square test or Fisher's exact test. Analyses of the difference between two groups were

Fig. 3 Enrollment of patients and analysis of lesions. EGD esohagogastroduodenoscopy, M-NBI Magnifying endoscopy with narrow-band imaging

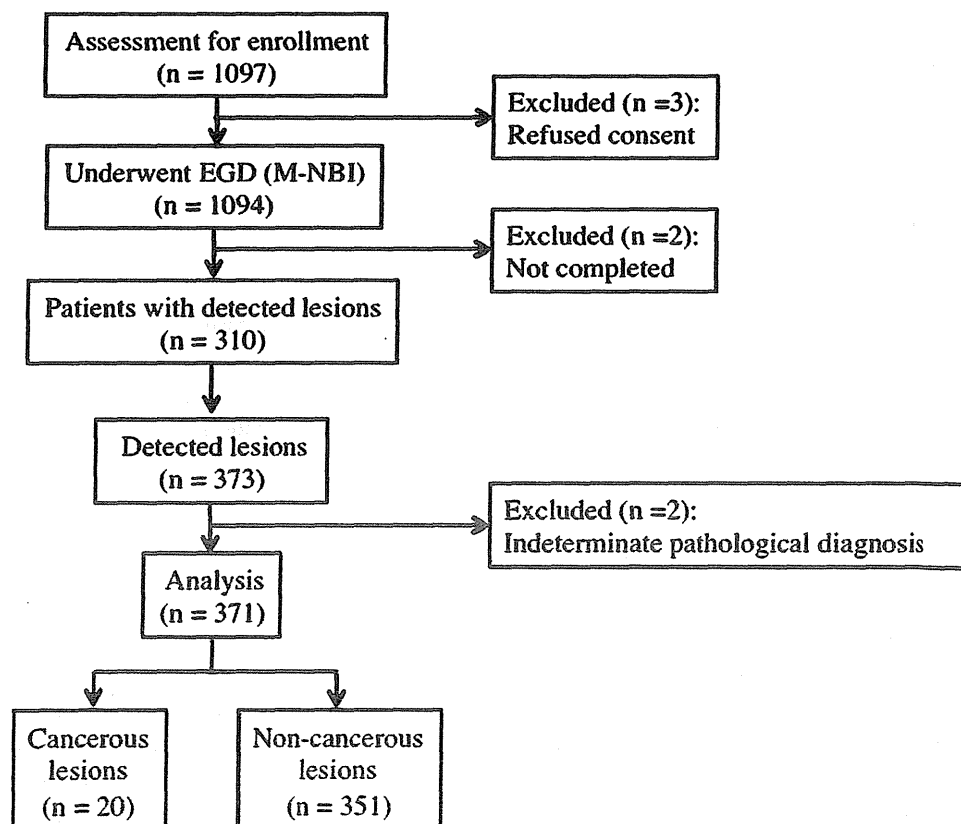


Table 1 Demographic characteristics of analyzed lesions according to histological diagnosis

	Cancer (<i>n</i> = 20)	Non-cancer (<i>n</i> = 351)	<i>P</i> value
Size (mm)			
Mean	18.8	7.3	0.002
SD	15.8	6.3	
Location			
Lower third	7	150	0.86
Middle third	8	137	
Upper third	5	64	
Macroscopic type ^a		0.39	
0 I	0	12	
0 IIa	2	61	
0 IIb	1	51	
0 IIc	14	217	
0 III	0	7	
Unclassified	3	3	
Endoscopic color			
Reddened	13	262	0.31
Same	5	50	
Pale	2	39	

^a Macroscopic types were determined using the Paris classification

Table 2 Endoscopic diagnoses using M-NBI for all lesions according to grade of certainty

Grade	Cancer	Non-cancer	Total
1	1	170	171
2	2	116	118
3	5	58	63
4	6	6	12
5	6	1	7
Total	20	351	371

M-NBI magnifying endoscopy with narrow-band imaging, *Grade 1* non-cancer with high degree of confidence (no need for biopsies), *Grade 2* non-cancer with low degree of confidence (biopsies required), *Grade 3* indeterminate (biopsies required), *Grade 4* cancer with low degree of confidence (biopsies required), *Grade 5* cancer with high degree of confidence (no need for biopsies)

Table 3 Diagnostic performance of M-NBI for all gastric lesions

	All lesions (95 % CI) (<i>n</i> = 371)	High confidence prediction (95 % CI) (<i>n</i> = 178)	Low confidence prediction (95 % CI) (<i>n</i> = 193)
Accuracy	96.1 (94.1–98.1)	98.1 (96.6–99.6)	93.3 (89.8–96.8)
Sensitivity	60.0 (38.5–81.5)	85.7 (59.8–100)	46.2 (19.1–73.3)
Specificity	98.0 (96.5–100)	99.4 (98.2–100)	96.7 (94.1–99.3)

M-NBI magnifying endoscopy with narrow-band imaging, *CI* confidence interval

made using Student's *t* test. *P* < 0.05 was considered significant.

Results

Between October 2009 and November 2010, 1097 patients were enrolled in the study. Three patients refused to participate. Accordingly, 1094 patients were registered and underwent endoscopic screening. The procedure was discontinued for 2 patients because of severe vomiting reflex. Endoscopic screening was completed for 1092 patients, with no reported adverse events.

A total of 373 lesions were detected from 310 patients screened using C-WLI followed by M-NBI. No definite pathological diagnosis was possible for 2 of the 373 lesions due to inadequate biopsy specimens, leaving 371 lesions suitable for the final analysis (Fig. 3). The median age (range) of the analyzed patients was 66 (30–90) years. The male: female ratio was 183:127. The demographic characteristics of the detected lesions is shown in Table 1. The final diagnosis was cancer in 20 of the 371 lesions, from histopathological examination of biopsy or resected specimens. The histological type of the detected cancers was differentiated (intestinal) in 14 lesions, and undifferentiated (diffuse) in 6. Fourteen cancers were resected using endoscopic submucosal dissection, and 6 were resected surgically.

Table 2 shows the endoscopic diagnoses for all lesions according to the degree of certainty. The diagnostic performance is shown in Table 3 when we regrouped Grades 1–3 as non-cancer, and Grade 4 and 5 as cancer, and when we regrouped Grade 1 and 5 as high confidence predictions, and Grades 2–4 as low confidence predictions. The accuracy and the specificity for all lesions exceeded 95 %, while the sensitivity was only 60 %. No significant differences were seen in accuracy, sensitivity or specificity between high and low confidence prediction groups.

Referring to Table 2, there was only one false negative case, with a Grade 1 endoscopic diagnosis (non-cancer with high degree of confidence, no need for biopsies), but a pathological diagnosis of cancer, as shown in Fig. 4. When we carefully reviewed the C-WLI and M-NBI findings

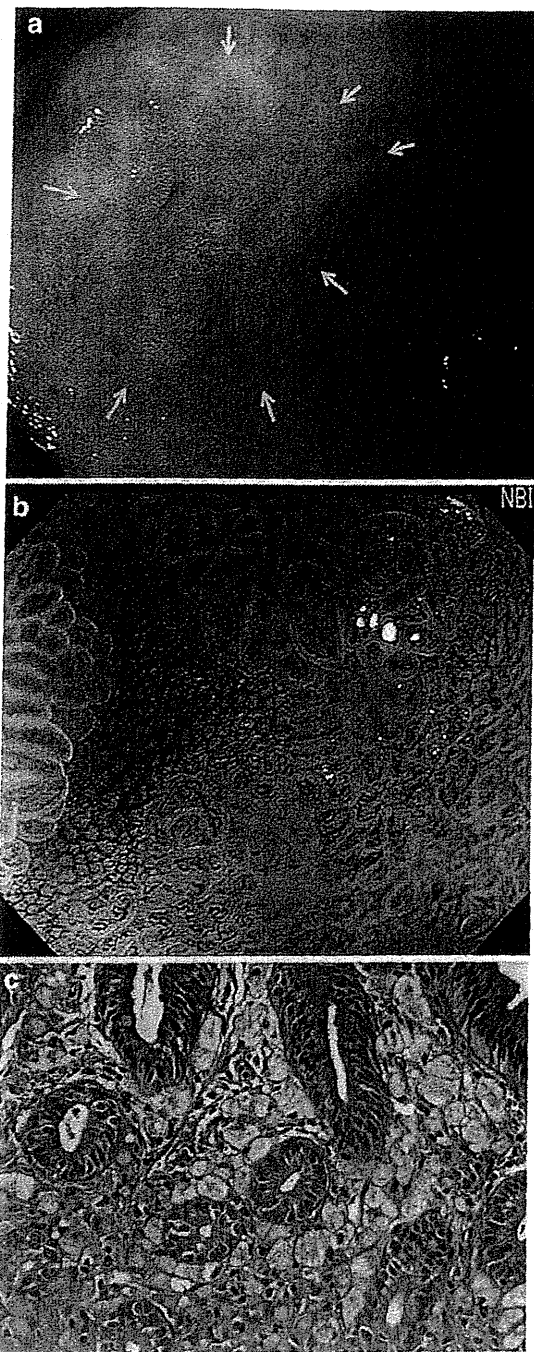


Fig. 4 A false negative case with high confidence M-NBI diagnosis (Grade 1). **a** Endoscopic findings using C-WLI. A pale mucosal lesion (arrows) was detected during screening endoscopy. The morphology of this lesion is slightly depressed and irregularly demarcated. **b** Endoscopic findings using M-NBI. The VS classification of this lesion was regular MV pattern and regular MS pattern without a demarcation line. Therefore the M-NBI diagnosis was “Grade 1: Non-cancer with high degree of confidence. The lesion can be diagnosed as non-cancer from the endoscopic findings alone. Biopsies of the lesion do not need to be taken under normal conditions.” **c** However, the histopathological findings of biopsy specimens taken from this lesion were of signet-ring cell carcinoma cells infiltrating beneath the surface epithelium showing intestinal metaplasia. The histopathological findings of the surgically resected specimen were showed a signet-ring cell carcinoma 18 mm in diameter, confined to the lamina propria mucosae. *M-NBI* Magnifying endoscopy with narrow-band imaging, *C-WLI* conventional endoscopy with white-light imaging, *VS classification* vessel plus surface classification, *MV* microvascular, *MS* microsurface

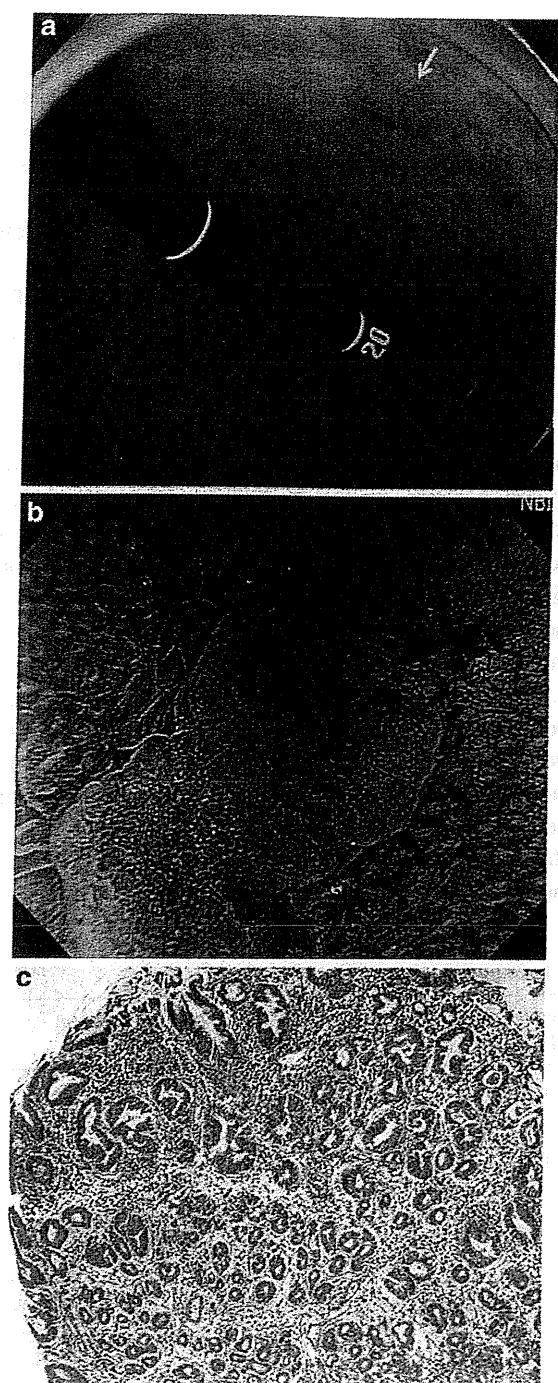
confidence, no need for biopsies), with a pathological diagnosis of non-cancer, as shown in Fig. 5. When we carefully reviewed the C-WLI and M-NBI findings together with the histopathological findings, C-WLI shows a reddened superficial elevated lesion, whereas M-NBI demonstrates a regular MV pattern plus regular MS pattern with a demarcation line, although the real time M-NBI findings were recorded as an irregular MV pattern plus irregular MS pattern. The reason for this false positive result was therefore considered to be an error of interpretation.

Analysis of the false negative and false positive cases, when we exclude the 41 lesions showed as pale color using C-WLI, interestingly, there were no Grade 1 false negative lesions in the subgroup comprising 330 reddened and same colored lesions, as shown in Table 4. In this subgroup, the diagnostic performance in the high confidence prediction group ($n = 161$) was remarkably high, with accuracy, sensitivity and specificity of 99.4, 100 and 99.4 %, respectively (Table 5). Accordingly, since the diagnostic performance is excellent in the subgroup comprising reddened and same colored lesions with high confidence predictions, the number of lesions with low confidence predictions requiring biopsies was in fact 169 (Table 5). In addition, the number of cancers detected in this subgroup was 18. The number of biopsies needed to diagnose one cancer was therefore calculated to be 9.4 (169/18) when we targeted mucosal lesions with reddened/same color.

Discussion

With regard to overall diagnostic performance, the accuracy and specificity of M-NBI were excellent at 96.1 and 98.0 %, respectively, while the sensitivity was low at only 60.0 %. Nevertheless, in the high confidence prediction group, the sensitivity was 85.7 %, comparable to that in an

together with the histopathological findings, C-WLI shows a pale superficial depressed lesion, whereas M-NBI demonstrates a regular MV pattern plus regular MS pattern without a demarcation line. Accordingly, even after an intensive review of the M-NBI findings, the endoscopic diagnosis was non-cancer with a high degree of confidence. The histopathological findings of both biopsied and surgically resected specimens revealed a signet-ring cell carcinoma 18 mm in diameter, limited to the mucosa (Fig. 4c). There was also one false positive case, with a Grade 5 endoscopic diagnosis (cancer with high degree of



◀Fig. 5 A false positive case with high confidence M-NBI diagnosis (Grade 5). **a** Endoscopic findings using C-WLI. A reddened mucosal lesion (*arrow*) was detected during screening endoscopy. The morphology of this lesion is superficial elevated. **b** Endoscopic findings using M-NBI. The VS classification of this lesion was irregular MV pattern and irregular MS pattern with a demarcation line. Therefore the real-time M-NBI diagnosis was “Grade 5: Cancer with high degree of confidence. The lesion can be diagnosed as cancer from the endoscopic findings alone. Biopsies of the lesion do not need to be taken under normal conditions.” Nevertheless, when we carefully reviewed the M-NBI findings, the VS classification of this lesion was revised to a regular MV pattern plus regular MS pattern with a demarcation line. In other words, the diagnosis was corrected to “non-cancer”. **c** Histopathological examination of biopsy specimens taken from this lesion revealed chronic active gastritis. *M-NBI* magnifying endoscopy with narrow-band imaging, *C-WLI* conventional endoscopy with white-light imaging, *VS classification* vessel plus surface classification, *MV* microvascular, *MS* microsurface

confirmed diagnosis. Accordingly, for Grade 1 and Grade 5 endoscopic diagnoses, biopsies were not taken. It is important for screening endoscopies to avoid false negative diagnoses. Taking into consideration the significant disadvantage, we determined the diagnostic performance after exclusion of lesions seen as pale colored using C-WLI. In this subgroup, the accuracy, sensitivity and specificity in the high confidence group were excellent at 99.4, 100 and 99.4 %, respectively. Therefore, we suggest that pale depressed lesions may be limitations of M-NBI, because early gastric cancers of the undifferentiated type/signet-ring cell type are often detected as pale flat/depressed lesions using C-WLI, and do not show any findings characteristic of cancer even with M-NBI, as we previously reported in retrospective studies [12, 27]. In other words, when we perform screening endoscopy, good indications for M-NBI are circumscribed lesions which show reddened or the same color as the background mucosa using C-WLI. Mucosal lesions seen as pale colored using C-WLI are not indications for M-NBI, but rather for taking biopsies from the target lesion.

Accordingly, from the results of this study, with consideration of the degree of diagnostic certainty and the need for biopsy, we devised a provisional strategy for screening endoscopy using M-NBI, as shown in Fig. 6. Briefly, a circumscribed mucosal lesion is detected using C-WLI. If the mucosal lesion is reddened or the same color as the background mucosa, M-NBI should be performed to make the diagnosis of either cancer or non-cancer. If the M-NBI diagnosis can be made with a high degree of confidence, this obviates the need for biopsy, but if the degree of confidence is low we need to take biopsies to obtain a histopathological diagnosis. When a mucosal lesion is pale colored, we take biopsies to make a definitive diagnosis.

When we limited the indication to mucosal lesions reddened or the same color using C-WLI, the estimated number of biopsies required to detect one cancer was 9.4.

earlier well-designed study targeting small superficial depressed lesions [3].

One of the most clinically relevant outcomes of this study is that we could identify false negative and false positive cases in a prospectively designed multicenter feasibility study including a large number of cases. In this study, we theoretically classified endoscopic diagnoses into 5 grades according to the degree of certainty and need for biopsy, in order to determine the limitations of M-NBI and the estimated number of biopsies required to make a

Table 4 Endoscopic diagnoses using M-NBI for reddened/same-colored mucosal lesions according to grade of certainty

Grade	Cancer	Non-cancer	Total
1	0	154	154
2	2	100	102
3	5	52	57
4	5	5	10
5	6	1	7
Total	18	312	330

M-NBI magnifying endoscopy with narrow-band imaging, *Grade 1* non-cancer with high degree of confidence (no need for biopsies), *Grade 2* non-cancer with low degree of confidence (biopsies required), *Grade 3* indeterminate (biopsies required), *Grade 4* cancer with low degree of confidence (biopsies required), *Grade 5* cancer with high degree of confidence (no need for biopsies)

Initially, we intended to compare the number of biopsies using C-WLI with a historical control. However, after completing the trials, the number of enrolled patients in the historical control over a certain period were in fact quite different from this prospective study. Therefore, since such unbalanced data sets are not suitable for analysis, we could not compare data from this prospective study with that from the historical control. In a retrospective study, the number of biopsies required to diagnose one cancer using C-WLI with chromoendoscopy was reported as 76 [31]. This suggests that M-NBI may contribute to reducing the

number of biopsies required to detect one cancer in screening endoscopy.

However, to provide further information for the selection of therapeutic strategy (e.g. endoscopic resection vs surgical resection), we need to take biopsies in Grade 5 cases, because endoscopic diagnosis using M-NBI has not been demonstrated to provide adequate diagnostic performance for predicting histological differentiation, i.e. differentiated vs undifferentiated type [9]. Therefore, clinicians should be aware of the necessity to take biopsies for the determination of histological type. On the other hand, we frequently encounter the situation where we are unable to take biopsies from a suspicious lesion in a patient on intensive antithrombotic therapy which can not be discontinued because of the high risk of thromboembolic events. In such cases, the proposed strategy may be applicable in deciding whether or not we should perform excisional biopsy after heparinization.

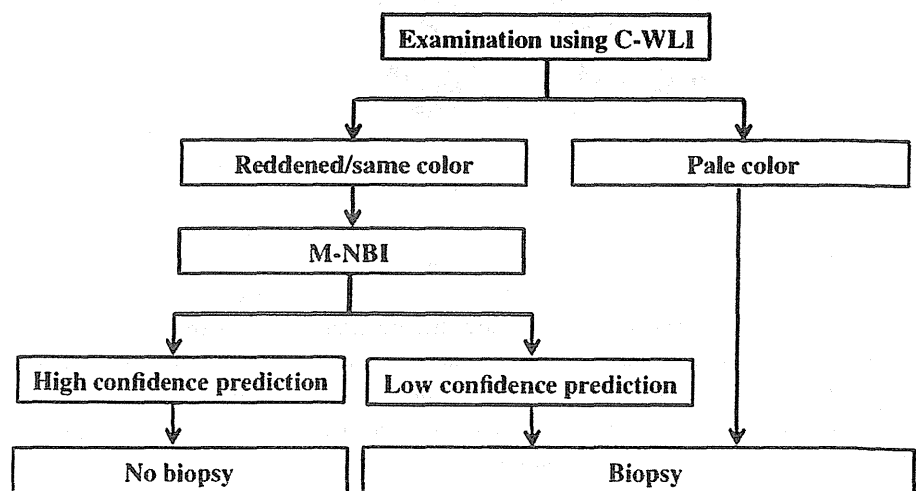
The limitations of this study are that this was an uncontrolled study, and the number of detected cancers was small. Therefore, in the near future we need to compare the diagnostic performance of M-NBI with other conventional endoscopy methods (e.g. chromoendoscopy) dealing with a substantial number of early gastric cancer cases. A system to ease the learning curve for M-NBI procedures has yet to be established. In order to overcome these problems, we are now developing a novel e-learning system for

Table 5 Diagnostic performance of M-NBI for reddened/same-colored mucosal lesions

	All lesions (95 % CI) (n = 330)		High confidence prediction (95 % CI) (n = 161)		Low confidence prediction (95 % CI) (n = 169)	
Accuracy	98.1	(96.6–99.6)	99.4	(98.2–100)	91.9	(87.8–96.0)
Sensitivity	69.2	(44.1–94.3)	100		41.7	(13.8–69.6)
Specificity	98.1	(98.2–100)	99.4	(98.2–100)	95.6	(94.2–98.8)

M-NBI magnifying endoscopy with narrow-band imaging, CI confidence interval

Fig. 6 A provisional strategy for M-NBI in screening gastroscopy



improving the diagnostic performance of M-NBI endoscopy (UMIN 00008569). Once it has been completed, we are planning a multicenter randomized controlled study. Once sufficient high-level evidence has been obtained that can support our provisional strategy, "optical biopsy" using M-NBI will be applied to clinical practice. The other limitations are that we have not tested the ability of NBI for detecting early gastric cancer because the image obtained by non-magnifying observation with NBI incorporated into the endoscopy system available in this study is too dark for endoscopists to detect a mucosal lesion. Recently, a new electronic endoscopy system with a bright NBI illumination (EVIS Lucera Elite, Olympus) has been launched. We are now planning a new trial to test whether NBI can detect more early gastric cancers than C-WLI. If we complete this study, it will become clear whether NBI can be helpful for detecting cancer invisible by C-WLI alone.

In conclusion, we demonstrated the high diagnostic performance and limitations of M-NBI in making a diagnosis of early gastric cancers of all macroscopic types in screening endoscopy in a multicenter prospective study, and we have proposed a provisional strategy for M-NBI in screening endoscopy for early gastric cancer that takes these limitations into consideration.

Acknowledgments This work was supported by a Multicenter Research Grant from the Japanese Foundation for Research and Promotion of Endoscopy. We would like to thank Dr. Mark Preston (Access Medical Communications) for correcting the English used in this manuscript.

Conflict of interest The authors have no potential conflicts of interest relevant to this article to declare.

References

1. Ferlay J, Shin HR, Bray F, et al. Estimates of worldwide burden of cancer in 2008: GLOBOCAN 2008. *Int J Cancer*. 2010;15(127):2893–917. doi:10.1002/ijc.25516 [published Online First: 17 June 2010].
2. Kaltenbach T, Sano Y, Friedland S, et al. American Gastroenterological Association (AGA) Institute technology assessment on image-enhanced endoscopy. *Gastroenterology*. 2008;134:327–40. doi:10.1053/j.gastro.2007.10.062 [published Online First: 30 October 2007].
3. Ezoe Y, Muto M, Uedo N, et al. Magnifying narrowband imaging is more accurate than conventional white-light imaging in diagnosis of gastric mucosal cancer. *Gastroenterology*. 2011;141:2017–25. doi:10.1053/j.gastro.2011.08.007 [published Online First: 19 August 2011].
4. Bossuyt PM, Reitsma JB, Bruns DE, et al. Towards complete and accurate reporting of studies of diagnostic accuracy: the STARD initiative. *BMJ*. 2003;4:41–4.
5. Yao K. I Kakudai Naishikyō. Tokyo: Nihon Medical Center; 2009. English edition: Yao K. Zoom gastroscopy: magnifying endoscopy in the stomach. Tokyo: Springer; 2013.
6. Gono K, Yamazaki K, Doguchi N, et al. Endoscopic observation of tissue by narrow band illumination. *Opt Rev*. 2003;10:211–5.
7. Gono K, Obi T, Yamaguchi M, et al. Appearance of enhanced tissue features in narrow-band endoscopic imaging. *J Biomed Opt*. 2004;9:568–77.
8. Yao K. The endoscopic diagnosis of early gastric cancer. *Ann Gastroenterol*. 2013;26:11–22.
9. Yao K, Nagahama T, Matsui T, et al. Detection and characterization of early gastric cancer for curative endoscopic submucosal dissection. *Dig Endosc*. 2013;25(Suppl 1):44–54. doi:10.1111/den.12004 [published Online First: January 24 2013].
10. Uedo N, Yao K, Ishihara R. Screening and treating intermediate lesions to prevent gastric cancer. *Gastroenterol Clin North Am* 2013; 42:317–335. doi:10.1016/j.gtc.2013.01.007.
11. Yao K, Anagnostopoulos GK, Ragnath K. Magnifying endoscopy for diagnosing and delineating early gastric cancer. *Endoscopy*. 2009;41:462–7. doi:10.1055/s-0029-1214594 [published Online First: 5 May 2009].
12. Yao K, Oishi T, Matsui T, et al. Novel magnified endoscopic findings of microvascular architecture in intramucosal gastric cancer. *Gastrointest Endosc*. 2002;56:279–84.
13. Yao K, Yao T, Iwashita A. Determining the horizontal extent of early gastric carcinoma: two modern techniques based of differences in the mucosal microvascular architecture and density between carcinomatous and non-carcinomatous mucosa. *Dig Endosc*. 2002;14:S83–7.
14. Yao K, Iwashita A, Kikuchi Y, et al. Novel zoom endoscopy technique for visualizing the microvascular architecture in gastric mucosa. *Clin Gastroenterol Hepatol*. 2005;3:S23–6.
15. Yao K, Iwashita A, Tanabe H, et al. Novel zoom endoscopy technique for diagnosis of small flat gastric cancer, a prospective, blind study. *Clin Gastroenterol Hepatol*. 2007;5:869–78.
16. Ezoe Y, Muto M, Horimatsu T, et al. Magnifying narrow-band imaging versus magnifying white-light imaging for the differential diagnosis of gastric small depressive lesions: a prospective study. *Gastrointest Endosc*. 2010;71:477–84. doi:10.1016/j.gie.2009.10.036.
17. Tsuji Y, Ohata K, Sekiguchi M, et al. Magnifying endoscopy with narrow-band imaging helps determine the management of gastric adenomas. *Gastric Cancer*. 2012;15:414–8. doi:10.1007/s10120-011-0133-2 [published Online First: 18 January 2012].
18. Miwa K, Doyama H, Ito R, et al. Can magnifying endoscopy with narrow band imaging be useful for low grade adenomas in pre-operative biopsy specimens? *Gastric Cancer*. 2012;15:170–8. doi:10.1007/s10120-011-0093-6 [published Online First 13 March 2012].
19. Maki S, Yao K, Nagahama T, et al. Magnifying endoscopy with narrow-band imaging is useful in the differential diagnosis between low-grade adenoma and early cancer of superficial elevated gastric lesions. *Gastric Cancer*. 2013;16:140–6. doi:10.1007/s10120-012-0160-7 [published Online First 17 May 2012].
20. Morita Y, Fujiwara S, Tanaka S, et al. A case of small early gastric cancer that was successfully detected by narrow band imaging magnifying endoscopy. *Dig Endosc*. 2011;23(Suppl 1):89–91. doi:10.1111/j.1443-1661.2011.01133.x.
21. Nagahama T, Yao K, Maki S, et al. Usefulness of magnifying endoscopy with narrow-band imaging for determining the horizontal extent of early gastric cancer when there is an unclear margin by chromoendoscopy (with video). *Gastrointest Endosc*. 2011;74:1259–67. doi:10.1007/s10120-012-0160-7 [published Online First: 17 May 2012].
22. Yao K, Iwashita A, Tanabe H, et al. White opaque substance within superficial elevated gastric neoplasia as visualized by magnification endoscopy with narrow-band imaging: a new optical sign for differentiating between adenoma and carcinoma. *Gastrointest Endosc*. 2008;68:574–80. doi:10.1016/j.gie.2008.04.011 [published Online First: 26 July 2008].

23. Yao K, Iwashita A, Nambu M, et al. Nature of white opaque substance in the gastric epithelial neoplasia as visualized by magnifying endoscopy with narrow-band imaging. *Dig Endosc.* 2012;24:419–25. doi:10.1111/j.1443-1661.2012.01314.x [published Online First: 12 April 2012].
24. Ueo T, Yonemasu H, Yada N, et al. White opaque substance represents an intracytoplasmic accumulation of lipid droplets: immunohistochemical and immunoelectron microscopic investigation of 26 cases. *Dig Endosc.* 2013;25:147–55. doi:10.1111/j.1443-1661.2012.01364.x [published Online First: 7 August 2012].
25. Tao G, Xing-Hua L, Ai-Ming Y, et al. Enhanced magnifying endoscopy for differential diagnosis of superficial gastric lesions identified with white-light endoscopy. *Gastric Cancer.* 2014;17:122–9. doi:10.1136/ard.2003.001234 [published Online First: 14 March 2013].
26. Hewett DG, Kaltenbach T, Sano Y, et al. Validation of a simple classification system for endoscopic diagnosis of small colorectal polyps using narrow-band imaging. *Gastroenterology.* 2012;143:599–607. doi:10.1053/j.gastro.2012.05.006 [published Online First: 15 May 2012].
27. Yao K, Fujiwara S, Nagahama T, et al. Diagnostic performance and limitations of magnifying narrow-band imaging for the diagnosis of minute gastric cancer (in Japanese with English abstract). *Stomach Intest (Tokyo).* 2013;48:843–56.
28. Yamada S, Doyama H, Yao K, et al. An efficient diagnostic strategy for small, depressed early gastric cancer with magnifying narrow-band imaging: a post hoc analysis of a prospective randomized controlled trial. *Gastrointest Endosc.* 2014;79:55–63. doi:10.1016/j.gie.2013.07.008 [published Online First: 7 Aug 2013].
29. Schlemper RJ, Riddell RH, Kato Y, et al. The Vienna classification of gastrointestinal epithelial neoplasia. *Gut.* 2000;47:251–5.
30. Schlemper RJ, Kato Y, Stolte M. Diagnostic criteria for gastrointestinal carcinoma in Japan and Western countries: proposal for a new classification system of gastrointestinal epithelial neoplasia. *J Gastroenterol Hepatol.* 2000;15(Suppl):C52–60.
31. Gotoda T, Shimoda T, Fujishiro M, et al. Macroscopic feature of “gastritis-like cancer” with little malignant appearance in early gastric cancer (in Japanese with English abstract). *Stomach Intest (Tokyo).* 1999;34:1495–503.