


53. Nakanishi K, Kawai T, Kumaki F, et al. Expression of human telomerase RNA component and telomerase reverse transcriptase mRNA in atypical adenomatous hyperplasia of the lung. *Hum Pathol*. 2002;33(7):697–702.
54. Seki N, Takasu T, Mandai K, et al. Expression of eukaryotic initiation factor 4E in atypical adenomatous hyperplasia and adenocarcinoma of the human peripheral lung. *Clin Cancer Res*. 2002;8(10):3046–3053.
55. Licchesi JD, Westra WH, Hooker CM, et al. Epigenetic alteration of Wnt pathway antagonists in progressive glandular neoplasia of the lung. *Carcinogenesis*. 2008;29(5):895–904.
56. Kerr KM, MacKenzie SJ, Ramasami S, et al. Expression of FHIT, cell adhesion molecules and matrix metalloproteinases in atypical adenomatous hyperplasia and pulmonary adenocarcinoma. *J Pathol*. 2004;203(2):638–644.
57. Maeshima AM, Tochigi N, Yoshida A, et al. Clinicopathologic analysis of multiple (five or more) atypical adenomatous hyperplasias (AAHs) of the lung: evidence for the AAH-adenocarcinoma sequence. *J Thorac Oncol*. 2010;5(4):466–471.
58. Mori M, Rao SK, Popper HH, Cagle PT, Fraire AE. Atypical adenomatous hyperplasia of the lung: a probable forerunner in the development of adenocarcinoma of the lung. *Mod Pathol*. 2001;14(2):72–84.
59. Kitamura H, Kameda Y, Ito T, Hayashi H. Atypical adenomatous hyperplasia of the lung. Implications for the pathogenesis of peripheral lung adenocarcinoma. *Am J Clin Pathol*. 1999;111(5):610–622.
60. Koga T, Hashimoto S, Sugio K, et al. Lung adenocarcinoma with bronchioloalveolar carcinoma component is frequently associated with foci of high-grade atypical adenomatous hyperplasia. *Am J Clin Pathol*. 2002;117(3):464–470.
61. Watanabe S, Watanabe T, Arai K, et al. Results of wedge resection for focal bronchioloalveolar carcinoma showing pure ground-glass attenuation on computed tomography. *Ann Thorac Surg*. 2002;73(4):1071–1075.
62. Sakurai H, Dobashi Y, Mizutani E, et al. Bronchioloalveolar carcinoma of the lung 3 centimeters or less in diameter: a prognostic assessment. *Ann Thorac Surg*. 2004;78(5):1728–1733.
63. Vazquez M, Carter D, Brambilla E, et al. Solitary and multiple resected adenocarcinomas after CT screening for lung cancer: histopathologic features and their prognostic implications. *Lung Cancer*. 2009;64(2):148–154.
64. Yoshida J, Nagai K, Yokose T, et al. Limited resection trial for pulmonary ground-glass opacity nodules: fifty-case experience. *J Thorac Cardiovasc Surg*. 2005;129(5):991–996.
65. Yamato Y, Tsuchida M, Watanabe T, et al. Early results of a prospective study of limited resection for bronchioloalveolar adenocarcinoma of the lung. *Ann Thorac Surg*. 2001;71(3):971–974.
66. Yamada S, Kohno T. Video-assisted thoracic surgery for pure ground-glass opacities 2 cm or less in diameter. *Ann Thorac Surg*. 2004;77(6):1911–1915.
67. Koike T, Togashi K, Shirato T, et al. Limited resection for noninvasive bronchioloalveolar carcinoma diagnosed by intraoperative pathologic examination. *Ann Thorac Surg*. 2009;88(4):1106–1111.
68. Maeshima AM, Tochigi N, Yoshida A, et al. Histological scoring for small lung adenocarcinomas 2 cm or less in diameter: a reliable prognostic indicator. *J Thorac Oncol*. 2010;5(3):333–339.
69. Lester SC, Bose S, Chen YY, et al. Protocol for the examination of specimens from patients with invasive carcinoma of the breast. *Arch Pathol Lab Med*. 2009;133(10):1515–1538.
70. Sakurai H, Maeshima A, Watanabe S, et al. Grade of stromal invasion in small adenocarcinoma of the lung: histopathologic minimal invasion and prognosis. *Am J Surg Pathol*. 2004;28(2):198–206.
71. Suzuki K, Asamura H, Kusumoto M, Kondo H, Tsuchiya R. “Early” peripheral lung cancer: prognostic significance of ground glass opacity on thin-section computed tomographic scan. *Ann Thorac Surg*. 2002;74(5):1635–1639.
72. Oka S, Hanagiri T, Uramoto H, et al. Surgical resection for patients with mucinous bronchioloalveolar carcinoma. *Asian J Surg*. 2010;33(2):89–93.
73. Hammond ME, Hayes DF, Dowsett M, et al. American Society of Clinical Oncology/College of American Pathologists guideline recommendations for immunohistochemical testing of estrogen and progesterone receptors in breast cancer (unabridged version). *Arch Pathol Lab Med*. 2010;134(7):e48–e72.
74. Lindeman N, Cagle P, Ladanyi M. CAP/IASLC/AMP lung cancer biomarkers guideline. *Arch Pathol Lab Med*. 2012. In press.
75. De Oliveira Duarte AR, Nikiforova MN, Yousem SA. Micropapillary lung adenocarcinoma: EGFR, K-ras, and BRAF mutational profile. *Am J Clin Pathol*. 2009;131(5):694–700.
76. Nakamura Y, Niki T, Goto A, et al. c-Met activation in lung adenocarcinoma tissues: an immunohistochemical analysis. *Cancer Sci*. 2007;98(7):1006–1013.
77. Yoshizawa A, Sumiyoshi S, Moreira AL, Travis WD. Validation of the IASLC/ATS/ERS lung adenocarcinoma (ADC) classification and use of comprehensive histologic subtyping (CHS) for architectural grading in 432 Japanese patients. *Mod Pathol*. 2011;24(15):429A.
78. Sica G, Yoshizawa A, Sima CS, et al. A grading system of lung adenocarcinomas based on histologic pattern is predictive of disease recurrence in stage I tumors. *Am J Surg Pathol*. 2010;34(8):1155–1162.
79. Ding L, Getz G, Wheeler DA, et al. Somatic mutations affect key pathways in lung adenocarcinoma. *Nature*. 2008;455(7216):1069–1075.
80. Shedden K, Taylor JM, Enkemann SA, et al. Gene expression-based survival prediction in lung adenocarcinoma: a multi-site, blinded validation study. *Nat Med*. 2008;14(8):822–827.
81. Sholl LM, Yeap BY, Iafrate AJ, et al. Lung adenocarcinoma with EGFR amplification has distinct clinicopathologic and molecular features in never-smokers. *Cancer Res*. 2009;69(21):8341–8348.
82. Dacic S, Shuai Y, Yousem S, Ohori P, Nikiforova M. Clinicopathological predictors of EGFR/KRAS mutational status in primary lung adenocarcinomas. *Mod Pathol*. 2010;23(2):159–168.
83. Kim YH, Ishii G, Goto K, et al. Dominant papillary subtype is a significant predictor of the response to gefitinib in adenocarcinoma of the lung. *Clin Cancer Res*. 2004;10(21):7311–7317.
84. Russell PA, Wainer Z, Wright GM, et al. Does lung adenocarcinoma subtype predict patient survival: a clinicopathologic study based on the new International Association for the Study of Lung Cancer/American Thoracic Society/European Respiratory Society international multidisciplinary lung adenocarcinoma classification. *J Thorac Oncol*. 2011;6(9):1496–1504.
85. Thunnissen FB, Beasley MB, Borczuk A, et al. Reproducibility of histopathological subtypes in pulmonary adenocarcinoma. *Mod Pathol*. 2012; 25:e pub ahead of print.
86. Warth A, Stenzinger A, von Brunneck A-C, et al. Interobserver variability in the application of the novel IASLC/ATS/ERS Classification. *Eur Resp J*. 2012. In press.
87. Kadota K, Suzuki K, D’Angelo SP, et al. Validation of the proposed IASLC/American Thoracic Society (ATS)/European Respiratory Society (ERS) international multidisciplinary classification of lung adenocarcinoma (ADC). *J Thorac Oncol*. 2011;6(6 suppl 2):S286.
88. Kadota K, Suzuki K, Yoshizawa A, et al. Clinicopathologic characteristics of adenocarcinoma in situ (AIS), minimally invasive adenocarcinoma (MIA) and lepidic predominant (LPD) adenocarcinoma of the lung (LAC): Memorial Sloan-Kettering Cancer Center Experience. *J Thorac Oncol*. 2011;6(6 suppl 2):S287.
89. Shim HS, Lee da H, Park EJ, Kim SH. Histopathologic characteristics of lung adenocarcinomas with epidermal growth factor receptor mutations in the International Association for the Study of Lung Cancer/American Thoracic Society/European Respiratory Society lung adenocarcinoma classification. *Arch Pathol Lab Med*. 2011;135(10):1329–1334.
90. Sterlacci W, Savić S, Schmid T, et al. Tissue-sparing application of the newly proposed IASLC/ATS/ERS classification of adenocarcinoma of the lung shows practical diagnostic and prognostic impact. *Am J Clin Pathol*. 2012;137(6):946–956.
91. Lee HY, Han J, Lee KS, et al. Lung adenocarcinoma as a solitary pulmonary nodule: prognostic determinants of CT, PET, and histopathologic findings. *Lung Cancer*. 2009;66(3):379–385.
92. Lin DM, Ma Y, Zheng S, et al. Prognostic value of bronchioloalveolar carcinoma component in lung adenocarcinoma. *Histol Histopathol*. 2006;21(6):627–632.
93. Yokose T, Suzuki K, Nagai K, et al. Favorable and unfavorable morphological prognostic factors in peripheral adenocarcinoma of the lung 3 cm or less in diameter. *Lung Cancer*. 2000;29(3):179–188.
94. Okudela K, Woo T, Mitsui H, et al. Proposal of an improved histological sub-typing system for lung adenocarcinoma—significant prognostic values for stage I disease. *Int J Clin Exp Pathol*. 2010;3(4):348–366.
95. Silver SA, Askin FB. True papillary carcinoma of the lung: a distinct clinicopathologic entity. *Am J Surg Pathol*. 1997;21(1):43–51.
96. Hoshi R, Tsuzuku M, Horai T, Ishikawa Y, Satoh Y. Micropapillary clusters in early-stage lung adenocarcinomas: a distinct cytologic sign of significantly poor prognosis. *Cancer*. 2004;102(2):81–86.
97. Kamiya K, Hayashi Y, Douguchi J, et al. Histopathological features and prognostic significance of the micropapillary pattern in lung adenocarcinoma. *Mod Pathol*. 2008;21(8):992–1001.
98. Kawakami T, Nabeshima K, Hamasaki M, et al. Small cluster invasion: a possible link between micropapillary pattern and lymph node metastasis in pT1 lung adenocarcinomas. *Virchows Arch*. 2009;454(1):61–70.
99. Kuroda N, Hamaguchi N, Takeuchi E, et al. Lung adenocarcinoma with a micropapillary pattern: a clinicopathological study of 25 cases. *APMIS*. 2006; 114(5):381–385.
100. Maeda R, Isowa N, Onuma H, et al. Lung adenocarcinomas with micropapillary components. *Gen Thorac Cardiovasc Surg*. 2009;57(10):534–539.
101. Makimoto Y, Nabeshima K, Iwasaki H, et al. Micropapillary pattern: a distinct pathological marker to subclassify tumours with a significantly poor prognosis within small peripheral lung adenocarcinoma ($\leq 20\text{ mm}$) with mixed bronchioloalveolar and invasive subtypes (Noguchi’s type C tumours). *Histopathology*. 2005;46(6):677–684.
102. Sanchez-Mora N, Presmanes MC, Monroy V, et al. Micropapillary lung adenocarcinoma: a distinctive histologic subtype with prognostic significance. Case series. *Hum Pathol*. 2008;39(3):324–330.
103. Tsutsumida H, Nomoto M, Goto M, et al. A micropapillary pattern is predictive of a poor prognosis in lung adenocarcinoma, and reduced surfactant apoprotein A expression in the micropapillary pattern is an excellent indicator of a poor prognosis. *Mod Pathol*. 2007;20(6):638–647.
104. Bishop JA, Teruya-Feldstein J, Westra WH, et al. p40 (DeltaNp63) is superior to p63 for the diagnosis of pulmonary squamous cell carcinoma. *Mod Pathol*. 2012;25(3):405–415.
105. Aways H, Takeshima Y, Yamasaki M, Inai K. Expression of MUC1, MUC2, MUC5AC, and MUC6 in atypical adenomatous hyperplasia, bronchioloalveolar carcinoma, adenocarcinoma with mixed subtypes, and mucinous bronchioloalveolar carcinoma of the lung. *Am J Clin Pathol*. 2004;121(5):644–653.

106. Casali C, Rossi G, Marchioni A, et al. A single institution-based retrospective study of surgically treated bronchioloalveolar adenocarcinoma of the lung: clinicopathologic analysis, molecular features, and possible pitfalls in routine practice. *J Thorac Oncol*. 2010;5(6):830–836.
107. Copin MC, Buisine MP, Leteurte E, et al. Mucinous bronchioloalveolar carcinomas display a specific pattern of mucin gene expression among primary lung adenocarcinomas. *Hum Pathol*. 2001;32(3):274–281.
108. Miyake H, Matsumoto A, Terada A, et al. Mucin-producing tumor of the lung: CT findings. *J Thorac Imaging*. 1995;10(2):96–98.
109. Sato K, Ueda Y, Shikata H, Katsuda S. Bronchioloalveolar carcinoma of mixed mucinous and nonmucinous type: immunohistochemical studies and mutation analysis of the p53 gene. *Pathol Res Pract*. 2006;202(10):751–756.
110. Gaeta M, Blandino A, Scribano E, et al. Mucinous cystadenocarcinoma of the lung: CT-pathologic correlation in three cases. *J Comput Assist Tomogr*. 1999;23(4):641–643.
111. Cohen PR, Yoshizawa A, Motoi N, et al. Signet ring cell features (SRCF) in lung adenocarcinoma: a cytologic feature or a histologic subtype? *Mod Pathol*. 2010;23(2):400A.
112. Deshpande CG, Yoshizawa A, Motoi N, et al. Clear cell change in lung adenocarcinoma: a cytologic change rather than a histologic variant. *Mod Pathol*. 2009;22(15):352A.
113. Rodig SJ, Mino-Kenudson M, Dacic S, et al. Unique clinicopathologic features characterize ALK-rearranged lung adenocarcinoma in the western population. *Clin Cancer Res*. 2009;15(16):5216–5213.
114. Inamura K, Satoh Y, Okumura S, et al. Pulmonary adenocarcinomas with enteric differentiation: histologic and immunohistochemical characteristics compared with metastatic colorectal cancers and usual pulmonary adenocarcinomas. *Am J Surg Pathol*. 2005;29(5):660–665.
115. Nakatani Y, Kitamura H, Inayama Y, et al. Pulmonary adenocarcinomas of the fetal lung type: a clinicopathologic study indicating differences in histology, epidemiology, and natural history of low-grade and high-grade forms. *Am J Surg Pathol*. 1998;22(4):399–411.
116. Nakatani Y, Masudo K, Miyagi Y, et al. Aberrant nuclear localization and gene mutation of beta-catenin in low-grade adenocarcinoma of fetal lung type: up-regulation of the Wnt signaling pathway may be a common denominator for the development of tumors that form morules. *Mod Pathol*. 2002;15(6):617–624.
117. Nakatani Y, Miyagi Y, Takemura T, et al. Aberrant nuclear/cytoplasmic localization and gene mutation of beta-catenin in classic pulmonary blastoma: beta-catenin immunostaining is useful for distinguishing between classic pulmonary blastoma and a blastomatoid variant of carcinosarcoma. *Am J Surg Pathol*. 2004;28(7):921–927.
118. Chu PG, Chung L, Weiss LM, Lau SK. Determining the site of origin of mucinous adenocarcinoma: an immunohistochemical study of 175 cases. *Am J Surg Pathol*. 2011;35(12):1830–1836.
119. Moran CA, Hochholzer L, Fishback N, Travis WD, Koss MN. Mucinous (so-called colloid) carcinomas of lung. *Mod Pathol*. 1992;5(6):634–638.
120. Rossi G, Murer B, Cavazza A, et al. Primary mucinous (so-called colloid) carcinomas of the lung: a clinicopathologic and immunohistochemical study with special reference to CDX-2 homeobox gene and MUC2 expression. *Am J Surg Pathol*. 2004;28(4):442–452.
121. Gao ZH, Urbanski SJ. The spectrum of pulmonary mucinous cystic neoplasia: a clinicopathologic and immunohistochemical study of ten cases and review of literature. *Am J Clin Pathol*. 2005;124(1):62–70.
122. Geisinger KR, Levine EA, Shen P, Bradley RF. Pleuropulmonary involvement in pseudomyxoma peritonei: morphologic assessment and literature review. *Am J Clin Pathol*. 2007;127(1):135–143.
123. Sekine S, Shibata T, Matsuno Y, et al. Beta-catenin mutations in pulmonary blastomas: association with morule formation. *J Pathol*. 2003;200(2):214–221.
124. Li HC, Schmidt L, Greenson JK, Chang AC, Myers JL. Primary pulmonary adenocarcinoma with intestinal differentiation mimicking metastatic colorectal carcinoma: case report and review of literature. *Am J Clin Pathol*. 2009;131(1):129–133.
125. Hatanaka K, Tsuta K, Watanabe K, Sugino K, Uekusa T. Primary pulmonary adenocarcinoma with enteric differentiation resembling metastatic colorectal carcinoma: a report of the second case negative for cytokeratin 7. *Pathol Res Pract*. 2011;207(3):188–191.
126. Hinoi T, Tani M, Lucas PC, et al. Loss of CDX2 expression and microsatellite instability are prominent features of large cell minimally differentiated carcinomas of the colon. *Am J Pathol*. 2001;159(6):2239–2248.
127. Shia J. Immunohistochemistry versus microsatellite instability testing for screening colorectal cancer patients at risk for hereditary nonpolyposis colorectal cancer syndrome, part I: the utility of immunohistochemistry. *J Mol Diagn*. 2008;10(4):293–300.
128. Yousem SA. Pulmonary intestinal-type adenocarcinoma does not show enteric differentiation by immunohistochemical study. *Mod Pathol*. 2005;18(6):816–821.
129. Barletta JA, Yeap BY, Chirieac LR. Prognostic significance of grading in lung adenocarcinoma. *Cancer*. 2010;116(3):659–669.
130. Nakazato Y, Minami Y, Kobayashi H, et al. Nuclear grading of primary pulmonary adenocarcinomas: correlation between nuclear size and prognosis. *Cancer*. 2010;116(8):2011–2019.
131. Petersen I, Koth WF, Friedrich KH, et al. Core classification of lung cancer: correlating nuclear size and mitoses with ploidy and clinicopathological parameters. *Lung Cancer*. 2009;65(3):312–318.
132. Kadota K, Suzuki K, Kachala SS, et al. Mitotic count is a predictor of recurrence in stage I lung adenocarcinoma generating a combined architectural and mitotic grading system. *Mod Pathol*. 2012;25(8):1117–1127.
133. Inamura K, Takeuchi K, Togashi Y, et al. EML4-ALK fusion is linked to histological characteristics in a subset of lung cancers. *J Thorac Oncol*. 2008;3(1):13–17.
134. Yoshida A, Tsuta K, Watanabe SI, et al. Frequent ALK rearrangement and TTF-1/p63 co-expression in lung adenocarcinoma with signet-ring cell component. *Lung Cancer*. 2010;72(3):309–315.
135. McLeer-Florin A, Moro-Sibilot D, Melis A, et al. Dual IHC and FISH Testing for ALK Gene Rearrangement in Lung Adenocarcinomas in a Routine Practice: A French Study. *J Thorac Oncol*. 2011;7(2):348–354.
136. Mino-Kenudson M, Chirieac LR, Law K, et al. A novel, highly sensitive antibody allows for the routine detection of ALK-rearranged lung adenocarcinomas by standard immunohistochemistry. *Clin Cancer Res*. 2010;16(5):1561–1571.
137. Yatabe Y. EGFR mutations and the terminal respiratory unit. *Cancer Metastasis Rev*. 2010;29(1):23–36.
138. Hayes DF, Allred C, Anderson BO, et al. Breast. In: AJCC Cancer Staging Manual 7th Edition, Edge SB, Byrd DR, Compton CC, et al, eds. New York, NY: Springer; 2009.
139. Girard N, Deshpande C, Azzoli CG, et al. Use of epidermal growth factor receptor/Kirsten rat sarcoma 2 viral oncogene homolog mutation testing to define clonal relationships among multiple lung adenocarcinomas: comparison with clinical guidelines. *Chest*. 2010;137(1):46–52.
140. Iwata T, Sugio K, Uramoto H, et al. Detection of EGFR and K-ras mutations for diagnosis of multiple lung adenocarcinomas. *Front Biosci*. 2011;17:2961–2969.
141. Chung JH, Choe G, Jheon S, et al. Epidermal growth factor receptor mutation and pathologic-radiologic correlation between multiple lung nodules with ground-glass opacity differentiates multicentric origin from intrapulmonary spread. *J Thorac Oncol*. 2009;4(12):1490–1495.
142. Yatabe Y, Mitsudomi T. Epidermal growth factor receptor mutations in lung cancers. *Pathol Int*. 2007;57(5):233–244.
143. Holst VA, Finkelstein S, Yousem SA. Bronchioloalveolar adenocarcinoma of lung: monoclonal origin for multifocal disease. *Am J Surg Pathol*. 1998;22(11):1343–1350.
144. Furak J, Trojan I, Szoke T, et al. Bronchioloalveolar lung cancer: occurrence, surgical treatment and survival. *Eur J Cardiothorac Surg*. 2003;23(5):818–823.
145. Akira M, Atagi S, Kawahara M, Iuchi K, Johkoh T. High-resolution CT findings of diffuse bronchioloalveolar carcinoma in 38 patients. *AJR Am J Roentgenol*. 1999;173(6):1623–1629.
146. Tateishi U, Muller NL, Johkoh T, et al. Mucin-producing adenocarcinoma of the lung: thin-section computed tomography findings in 48 patients and their effect on prognosis. *J Comput Assist Tomogr*. 2005;29(3):361–368.
147. Yabuuchi H, Murayama S, Murakami J, et al. High-resolution CT characteristics of poorly differentiated adenocarcinoma of the peripheral lung: comparison with well differentiated adenocarcinoma. *Radiat Med*. 2000;18(6):343–347.
148. Aoki T, Tomoda Y, Watanabe H, et al. Peripheral lung adenocarcinoma: correlation of thin-section CT findings with histologic prognostic factors and survival. *Radiology*. 2001;220(3):803–809.
149. Kodama K, Higashiyama M, Yokouchi H, et al. Natural history of pure ground-glass opacity after long-term follow-up of more than 2 years. *Ann Thorac Surg*. 2002;73(2):386–392.
150. Im JG, Han MC, Yu EJ, et al. Lobar bronchioloalveolar carcinoma: “angiogram sign” on CT scans. *Radiology*. 1990;176(3):749–753.
151. Nagao M, Murase K, Yasuhara Y, et al. Measurement of localized ground-glass attenuation on thin-section computed tomography images: correlation with the progression of bronchioloalveolar carcinoma of the lung. *Invest Radiol*. 2002;37(12):692–697.
152. Clayton F. The spectrum and significance of bronchioloalveolar carcinomas. *Pathol Annu*. 1988;23(pt 2):361–394.
153. Lau SK, Desrochers MJ, Luthringer DJ. Expression of thyroid transcription factor-1, cytokeratin 7, and cytokeratin 20 in bronchioloalveolar carcinomas: an immunohistochemical evaluation of 67 cases. *Mod Pathol*. 2002;15(5):538–542.
154. Sarantopoulos GP, Gui D, Shintaku P, et al. Immunohistochemical analysis of lung carcinomas with pure or partial bronchioloalveolar differentiation. *Arch Pathol Lab Med*. 2004;128(4):406–414.
155. Shah RN, Badve S, Papreddy K, et al. Expression of cytokeratin 20 in mucinous bronchioloalveolar carcinoma. *Hum Pathol*. 2002;33(9):915–920.
156. Simsir A, Wei XJ, Yee H, Moreira A, Cangiarella J. Differential expression of cytokeratins 7 and 20 and thyroid transcription factor-1 in bronchioloalveolar carcinoma: an immunohistochemical study in fine-needle aspiration biopsy specimens. *Am J Clin Pathol*. 2004;121(3):350–357.
157. Saad RS, Liu YL, Han H, Landreneau RJ, Silverman JF. Prognostic significance of thyroid transcription factor-1 expression in both early-stage conventional adenocarcinoma and bronchioloalveolar carcinoma of the lung. *Hum Pathol*. 2004;35(1):3–7.
158. Maeshima A, Sakamoto M, Hirohashi S. Mixed mucinous-type and non-mucinous-type adenocarcinoma of the lung: immunohistochemical examination and K-ras gene mutation. *Virchows Arch*. 2002;440(6):598–603.
159. Marchetti A, Buttitta F, Pellegrini S, et al. Bronchioloalveolar lung carcinomas: K-ras mutations are constant events in the mucinous subtype. *J Pathol*. 1996;179(3):254–259.

160. Sakuma Y, Matsukuma S, Yoshihara M, et al. Distinctive evaluation of nonmucinous and mucinous subtypes of bronchioloalveolar carcinomas in EGFR and K-ras gene-mutation analyses for Japanese lung adenocarcinomas: confirmation of the correlations with histologic subtypes and gene mutations. *Am J Clin Pathol*. 2007;128(1):100–108.
161. Tam IY, Chung LP, Suen WS, et al. Distinct epidermal growth factor receptor and KRAS mutation patterns in non-small cell lung cancer patients with different tobacco exposure and clinicopathologic features. *Clin Cancer Res*. 2006;12(5):1647–1653.
162. Marchetti A, Martella C, Felicioni L, et al. EGFR mutations in non-small-cell lung cancer: analysis of a large series of cases and development of a rapid and sensitive method for diagnostic screening with potential implications on pharmacologic treatment. *J Clin Oncol*. 2005;23(4):857–865.
163. Sonobe M, Manabe T, Wada H, Tanaka F. Mutations in the epidermal growth factor receptor gene are linked to smoking-independent, lung adenocarcinoma. *Br J Cancer*. 2005;93(3):355–363.
164. Ohtsuka T, Watanabe K, Kaji M, Naruke T, Suemasu K. A clinicopathological study of resected pulmonary nodules with focal pure ground-glass opacity. *Eur J Cardiothorac Surg*. 2006;30(1):160–163.
165. Takeuchi T, Tomida S, Yatabe Y, et al. Expression profile-defined classification of lung adenocarcinoma shows close relationship with underlying major genetic changes and clinicopathologic behaviors. *J Clin Oncol*. 2006;24(11):1679–1688.
166. Bryant CM, Albertus DL, Kim S, et al. Clinically relevant characterization of lung adenocarcinoma subtypes based on cellular pathways: an international validation study. *PLoS ONE*. 2010;5(7):1–13.
167. Conde E, Angulo B, Tang M, et al. Molecular context of the EGFR mutations: evidence for the activation of mTOR/S6K signaling. *Clin Cancer Res*. 2006;12(3 pt 1):710–717.
168. Ohtsuka K, Ohnishi H, Furuyashiki G, et al. Clinico-pathological and biological significance of tyrosine kinase domain gene mutations and overexpression of epidermal growth factor receptor for lung adenocarcinoma. *J Thorac Oncol*. 2006;1(8):787–795.
169. Soh J, Toyooka S, Ichihara S, et al. Sequential molecular changes during multistage pathogenesis of small peripheral adenocarcinomas of the lung. *J Thorac Oncol*. 2008;3(4):340–347.
170. Yousem SA, Nikiforova M, Nikiforov Y. The histopathology of BRAF-V600E-mutated lung adenocarcinoma. *Am J Surg Pathol*. 2008;32(9):1317–1321.
171. Ninomiya H, Hiramatsu M, Inamura K, et al. Correlation between morphology and EGFR mutations in lung adenocarcinomas: significance of the micropapillary pattern and the hobnail cell type. *Lung Cancer*. 2009;63(2):235–240.
172. Hirsch FR, Varella-Garcia M, McCoy J, et al. Increased epidermal growth factor receptor gene copy number detected by fluorescence in situ hybridization associates with increased sensitivity to gefitinib in patients with bronchioloalveolar carcinoma subtypes: a Southwest Oncology Group Study. *J Clin Oncol*. 2005;23(28):6838–6845.
173. Tang X, Shigematsu H, Bekele BN, et al. EGFR tyrosine kinase domain mutations are detected in histologically normal respiratory epithelium in lung cancer patients. *Cancer Res*. 2005;65(17):7568–7572.
174. Tanaka R, Horikoshi H, Nakazato Y, et al. Magnetic resonance imaging in peripheral lung adenocarcinoma: correlation with histopathologic features. *J Thorac Imaging*. 2009;24(1):4–9.
175. Stenhouse G, Fyfe N, King G, Chapman A, Kerr KM. Thyroid transcription factor 1 in pulmonary adenocarcinoma. *J Clin Pathol*. 2004;57(4):383–387.
176. Koga T, Hashimoto S, Sugio K, et al. Clinicopathological and molecular evidence indicating the independence of bronchioloalveolar components from other subtypes of human peripheral lung adenocarcinoma. *Clin Cancer Res*. 2001;7(6):1730–1738.
177. Kim YT, Kim TY, Lee DS, et al. Molecular changes of epidermal growth factor receptor (EGFR) and KRAS and their impact on the clinical outcomes in surgically resected adenocarcinoma of the lung. *Lung Cancer*. 2008;59(1):111–118.
178. Tsuta K, Ishii G, Nitadori J, et al. Comparison of the immunophenotypes of signet-ring cell carcinoma, solid adenocarcinoma with mucin production, and mucinous bronchioloalveolar carcinoma of the lung characterized by the presence of cytoplasmic mucin. *J Pathol*. 2006;209(1):78–87.
179. Ang DC, Zakowski MF, Ladanyi M, Moreira AL, Rekhtman N. Characteristic morphology and immunoprofile of lung adenocarcinoma with KRAS mutations: propensity for solid growth pattern and correlation with TTF-1 expression. *Mod Pathol*. 2010;23(suppl 2):396A.
180. Shrestha B, Ebihara Y, Osakabe Y, Kato H. Immunohistochemical, ultrastructural and molecular study of well differentiated adenocarcinomas of the lung predominantly composed of goblet cells. *Lung Cancer*. 1998;22(2):103–117.
181. Yatabe Y, Koga T, Mitsudomi T, Takahashi T. CK20 expression, CDX2 expression, K-ras mutation, and goblet cell morphology in a subset of lung adenocarcinomas. *J Pathol*. 2004;203(2):645–652.



OPEN

PRC2 overexpression and PRC2-target gene repression relating to poorer prognosis in small cell lung cancer

SUBJECT AREAS:

SMALL-CELL LUNG
CANCER

GENE SILENCING

EPIGENOMICS

TRANSLATIONAL RESEARCH

Teruyuki Sato^{1,2}, Atsushi Kaneda^{1,3,4}, Shingo Tsuji¹, Takayuki Isagawa¹, Shogo Yamamoto¹, Takanori Fujita¹, Ryota Yamanaka¹, Yukiko Tanaka¹, Toshihiro Nukiwa², Victor E. Marquez⁵, Yuichi Ishikawa⁶, Masakazu Ichinose² & Hiroyuki Aburatani¹

Received
25 February 2013

Accepted
14 May 2013

Published
29 May 2013

Correspondence and
requests for materials
should be addressed to
A.K. (kaneda@
genome.rcast.u-tokyo.
ac.jp)

¹Genome Science Division, Research Center for Advanced Science and Technology (RCAST), The University of Tokyo, Japan, ²Department of Respiratory Medicine, Graduate School of Medicine, Tohoku University, Japan, ³Department of Molecular Oncology, Graduate School of Medicine, Chiba University, Japan, ⁴CREST, Japan Science and Technology Agency (JST), ⁵Chemical Biology Laboratory, Frederick National Laboratory for Cancer Research, National Cancer Institute, USA, ⁶Division of Pathology, the Cancer Institute Hospital, Japanese Foundation for Cancer Research, Japan.

Small cell lung cancer (SCLC) is a subtype of lung cancer with poor prognosis. Expression array analysis of 23 SCLC cases and 42 normal tissues revealed that *EZH2* and other PRC2 members were highly expressed in SCLC. ChIP-seq for H3K27me3 suggested that genes with H3K27me3(+) in SCLC were extended not only to PRC2-target genes in ES cells but also to other target genes such as cellular adhesion-related genes. These H3K27me3(+) genes in SCLC were repressed significantly, and introduction of the most repressed gene *JUB* into SCLC cell line lead to growth inhibition. Shorter overall survival of clinical SCLC cases correlated to repression of *JUB* alone, or a set of four genes including H3K27me3(+) genes. Treatment with EZH2 inhibitors, DZNep and GSK126, resulted in growth repression of SCLC cell lines. High PRC2 expression was suggested to contribute to gene repression in SCLC, and may play a role in genesis of SCLC.

Lung cancer is the most leading cause of cancer-related deaths in the world, accounting for about 1.4 million deaths each year¹. Small cell lung cancer (SCLC) is a histologic subtype of lung cancer with a distinct clinical and biological feature, and represents approximately 15% of all the lung cancer cases^{2,3}. SCLC is strongly related to cigarette smoking, and approximately 90% of cases are reported to be smokers^{4,5}. The prognosis is poor mainly due to early dissemination and rapid growth^{6,7}. While SCLC shows high response to initial therapy, most cases relapse and become refractory to treatment. The 5-year survival is as poor as 15–25% for cases at limited stage, and <1% for cases at extensive stage^{6,8,9}.

Frequent mutation of *TP53* and *RB1* is reported in SCLC¹⁰. Sutherland *et al.* reported that cell type-restricted inactivation of *Trp53* and *Rb1* in mouse lung neuroendocrine cells and alveolar type 2 cells induced formation of lung tumors with extrapulmonary metastasis resembling SCLC¹¹. Whole genome sequencing of SCLC cell line NCI-H209 revealed >20,000 somatic substitutions including 134 of those in coding exons, and rearrangement of *CHD7*¹². Rudin *et al.* analyzed exome, transcriptome and copy number aberration of clinical SCLC samples, normal tissues, SCLC cell lines and normal cell lines, and identified 22 significantly mutated cancer-associated genes in SCLC, including *TP53* and *RB1*. Furthermore they found *SOX2* amplification and *RLF-MYCL1* fusion¹³. Peifer *et al.* also performed integrative analysis of exome/genome sequencing, transcriptome, and copy number aberrations in 29 SCLC. They reported *TP53* and *RB1* inactivation, mutations in *PTEN*, *SLIT2*, and *EPHA2*, and recurrent mutation of histone modifiers e.g. *CREBBP*, *EP300*, and *MLL*¹⁴.

Polycomb Repressive Complexes (PRCs) are known to modify epigenetic status and repress their target genes to establish and maintain the cell fates^{15,16}. EZH2 is a catalytic component of PRC2 and functions as a histone methyltransferase for H3 lysine 27 residue (H3K27), and its overexpression in cancer was reported first in prostate cancer, followed by breast cancer. EZH2 overexpression correlates to cancer progression and poorer prognosis^{17,18}. On the other hand, SWI/SNF antagonizes PRCs and activates PRC target genes and contributes to cell differentiation. Mutation in proteins in SWI/SNF complex leads to loss of antagonistic function to polycomb complex protein¹⁹. Those mutations or high expression of EZH2 may play a role in maintenance of cell stemness and thus carcinogenesis²⁰. As for lung cancer, 3-Deazaneplanocin A (DZNep), an inhibitor of PRC2, inhibits

growth of non-small cell lung cancer cells compared to non-cancerous bronchial epithelial and fibroblast cells²¹. Furthermore, immunohistochemical analysis suggested that elevated EZH2 expression is associated with non-small cell lung cancer progression and metastasis²².

Involvement of PRC2 in SCLC, however, has not been elucidated. Here we report high expression levels of *EZH2* and other PRC2 components in SCLC. Genes with H3K27me3(+) in SCLC cell lines but H3K27me3(-) in normal small airway epithelial cell (SAEC), (i) did not overlap with PRC2-target genes in ES cells, (ii) showed lower expression levels not only in SCLC cell lines but also in clinical SCLC samples, and (iii) showed significant enrichment of GO-terms e.g. immune response, cell adhesion, and plasma membrane. While *JUB* is the most repressed gene with such GO-terms and with H3K27me3 mark in all the three SCLC cell lines, *JUB* introduction lead to growth inhibition. Shorter overall survival of clinical SCLC cases correlated to repression of *JUB* alone, or a set of four genes including PRC target genes and marker genes of classic type SCLC^{23–25}. It is suggested that high expression of PRC2 contributes to gene repression in SCLC, and the gene repression may play a role in genesis of SCLC.

Results

Microarray expression analysis in SCLC and normal tissues. Gene expressions in 23 clinical SCLC samples and 42 normal tissues including the normal lung were analyzed on genome-wide scale using microarray, and average expression levels of SCLC were compared to those of normal tissues. Among 11,037 genes with Genechip score >200 in at least one sample, 71 genes showed higher expression in SCLC by >10-fold compared to normal tissues (Supplementary Table S1). The most highly expressed genes in SCLC samples included *GRP*, *INSM1* and *ASCL1*, which were reported to be highly expressed in classic type SCLC with neuroendocrine features^{23–25}, *TOP2A*, which encodes a DNA topoisomerase active in fast-growing tumors and is a target of chemotherapy in SCLC²⁶, and *EZH2*, a member of PRC2 and a methyltransferase for histone H3 lysine K27 (Fig. 1). Other PRC2 members, *SUZ12* and *EED*, were also highly expressed in SCLC compared to the normal tissues. The expression levels of PRC2 members in SCLC were also significantly higher than squamous cell carcinoma and adenocarcinoma of the lung (Supplementary Fig. S1).

Mapping of histone modification. We performed ChIP-seq for H3K27me3 mark in three SCLC cell lines and in SAEC, and obtained 9280, 9352, 15704 and 7589 peaks in Lu130, H209, DMS53, and SAEC, respectively (Fig. 2a). We then prepared ChIP samples by additionally performed ChIP experiments, and performed quantitative ChIP-PCR to validate ChIP-seq results (Fig. 2b). To confirm overlapping of H3K27me3(+) regions and PRC2-target regions, we also performed ChIP-seq for *SUZ12* in a SCLC cell line Lu130. *SUZ12*(+) regions were well-overlapped to H3K27me3(+) regions as reported^{27,28} (Supplementary Fig. S2).

Genes with and without H3K27me3 around promoter region (within \pm 2kb from transcription start site) were regarded as H3K27me3(+) and H3K27me3(-) genes, respectively. When expression levels of H3K27me3(+) genes were compared to H3K27me3(-) genes within each sample, H3K27me3(+) genes showed significant repression: 0.11-fold in SAEC, 0.27-fold in Lu130, 0.08-fold in H209, and 0.11-fold in DMS53 ($P < 1 \times 10^{-20}$, *t*-test), confirming that ChIP-seq analysis for H3K27me3 was properly performed (Fig. 2c).

These H3K27me3(+) genes were compared with reported PRC2-target genes in ES cells²⁸. Genes with H3K27me3 in SAEC only or genes with H3K27me3 in both SAEC and SCLC cell lines, showed significant overlap with PRC2-target genes in ES cells. Genes with

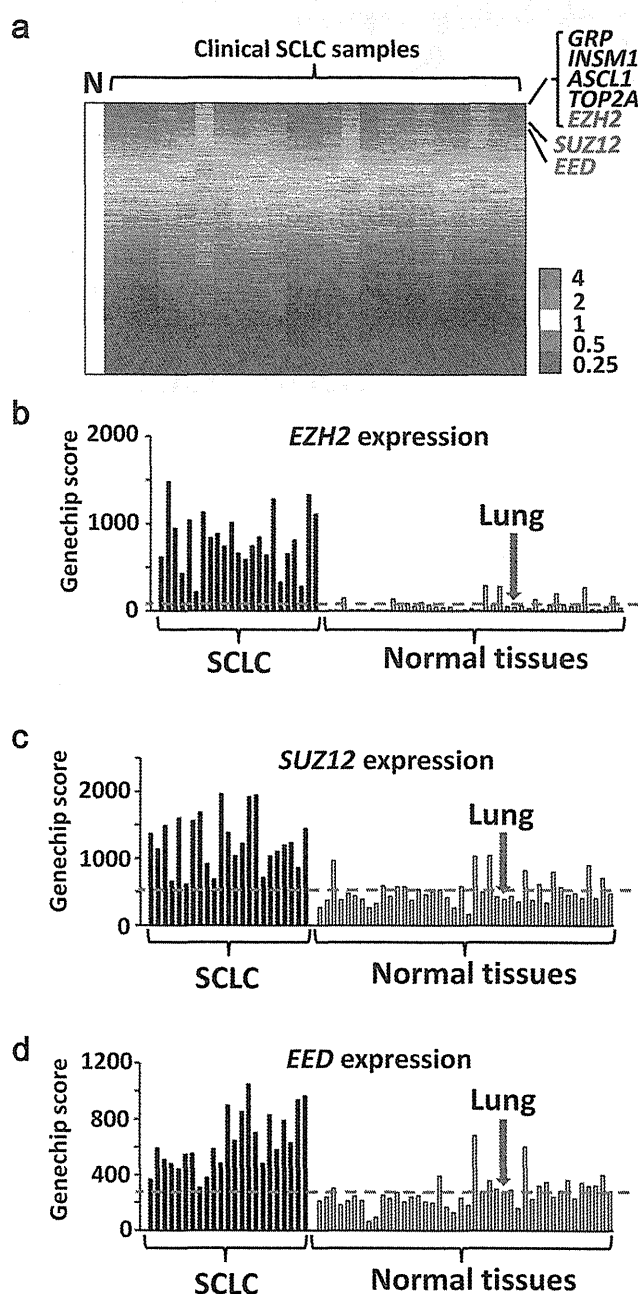


Figure 1 | Expression levels of PRC2 components in SCLC. Gene expression levels in 23 clinical SCLC samples were analyzed using expression arrays, and compared to 42 normal tissues including the lung. (a) Heatmap of gene expression in SCLC. Expression levels were shown by the ratio to the average expression level of all the normal samples (N), and genes were sorted by the descending order of average expression levels in SCLC samples. *Ezh2* was one of the most highly expressed genes. Expression levels of *EZH2* (b) and other PRC2 members, *SUZ12* (c) and *EED* (d), in SCLC samples were significantly higher than normal samples ($P = 3 \times 10^{-10}$, 7×10^{-9} , 1×10^{-8} , respectively, *t*-test). Red bar, the average expression level of the normal samples. Expression levels were shown by Genechip Score.

H3K27me3 in SCLC cell lines but not in SAEC, however, were not significantly overlapped with PRC2-target genes in ES cells (Fig. 2d).

Genes repressed with H3K27me3 in SCLC. The 8,654 genes showing H3K27me3(-) in 3 SCLC cell lines and also H3K27me3(-) in SAEC (SCLC(3)-SAEC(-) genes), showed similar

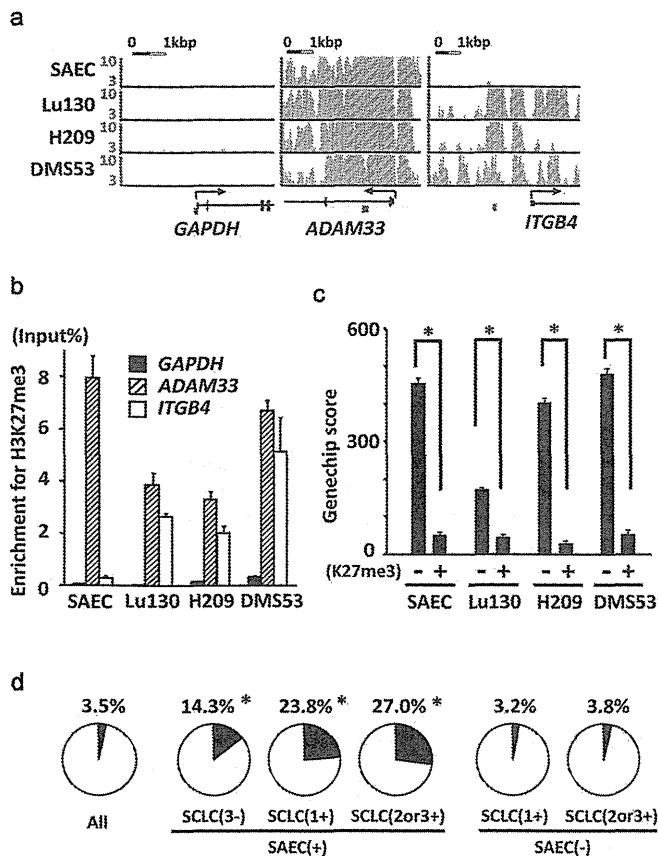


Figure 2 | Identification of genes modified with H3K27me3 in SCLC cell lines. (a) ChIP-seq of H3K27me3 in SAEC and SCLC cell lines. Genes not modified with H3K27me3 in either SAEC or SCLC cell lines (*GAPDH*), modified both in SAEC and SCLC cell lines (*ADAM33*), and not modified in SAEC but in SCLC cell lines (*ITGB4*), were representatively shown. *Brown bars*, regions for ChIP-PCR. (b) The results of ChIP-seq in *GAPDH*, *ADAM33* and *ITGB4* were validated by real-time PCR using ChIP samples that were obtained in additionally performed ChIP experiments. (c) Expression of H3K27me3(+) genes was significantly lower than H3K27me3(-) genes in each sample ($*P < 10^{-20}$, *t*-test). (d) PRC2-target genes in ES cells²⁸ occupied 3.5% among all the genes (*left*). Among genes with H3K27me3 in SAEC only, in SAEC and 1 SCLC cell line, and in SAEC and 2–3 SCLC cell lines (*center*), PRC2-target genes in ES cells occupied 14.3%, 23.8%, and 27.0%, respectively, indicating significant overlap ($*P < 10^{-30}$, $P < 10^{-30}$, $P < 10^{-30}$, Fisher's exact test.). Genes with H3K27me3 in 1 SCLC cell line or 2–3 SCLC cell lines but not in SAEC (*right*), however, were not significantly overlapped with PRC2-target genes in ES cells, 3.2% ($P = 0.66$) or 3.8% ($P = 0.65$), respectively.

expression levels among SAEC, 3 SCLC cell lines, the normal lung, other normal tissues, and clinical SCLC cases (Fig. 3a). But the 644 genes showing H3K27me3(+) in 1 of 3 SCLC cell lines but H3K27me3(-) in SAEC (SCLC(1+)SAEC(-) genes), showed lower expression levels in SCLC cell lines as well as clinical SCLC cases compared to the SCLC(3-)SAEC(-) genes. The 343 genes showing H3K27me3(+) in 2 or 3 SCLC cell lines but H3K27me3(-) in SAEC (SCLC(2or3+)SAEC(-) genes), showed further reduced expression levels in SCLC cell lines as well as clinical SCLC cases compared to the SCLC(3-)SAEC(-) genes. These data indicated that genes with H3K27me3(+) in SCLC cell lines were significantly repressed not only in the analyzed SCLC cell lines, but also in clinical SCLC samples (Fig. 3a).

When genes were sorted by fold expression level between SAEC and mean of 3 SCLC cell lines in descending order, the SCLC(2or3+)SAEC(-) genes were significantly enriched downward

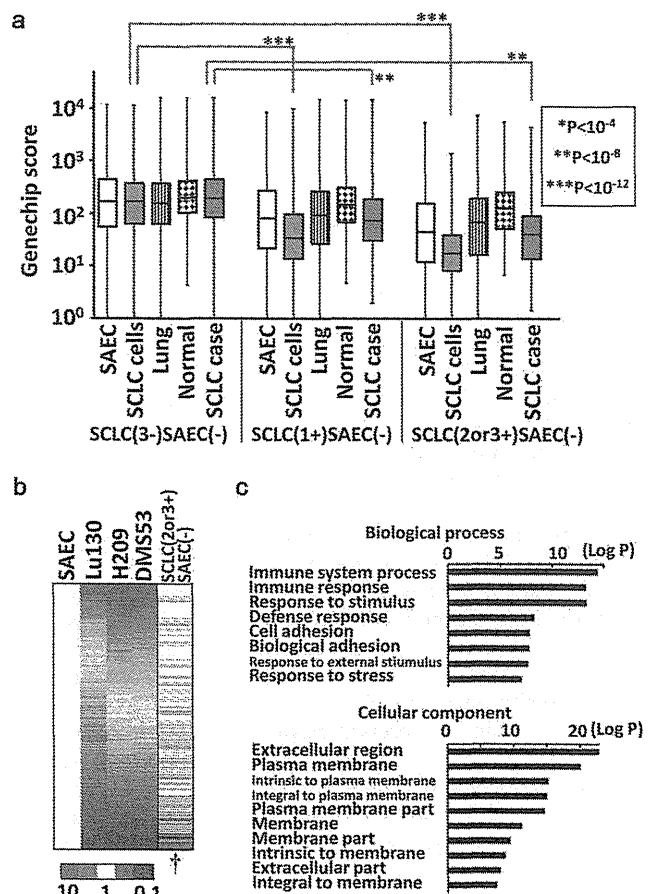


Figure 3 | Repression of genes with H3K27me3 in SCLC. (a) Gene expression in clinical samples. As for SCLC(3-)SAEC(-) genes showing H3K27me3(-) in all the three SCLC cell lines and H3K27me3(-) in SAEC (*left*), gene expression levels were similar among SAEC, SCLC cell lines, the lung, the normal other tissues, and clinical SCLC samples. As for SCLC(1+)SAEC(-) genes showing H3K27me3(+) in one SCLC cell line but H3K27me3(-) in SAEC (*middle*), expression levels were significantly lower in SCLC cell lines and clinical SCLC samples when compared between SCLC(3-)SAEC(-) and SCLC(1+)SAEC(-) categories. As for SCLC(2or3+)SAEC(-) genes showing H3K27me3(+) in two or three SCLC cell lines but H3K27me3(-) in SAEC (*right*), expression levels were even lower in SCLC cell lines and clinical SCLC samples when compared between SCLC(3-)SAEC(-) and SCLC(2or3+)SAEC(-) categories. (b) Significant repression of H3K27me3(+) genes in SCLC. Gene expression levels were shown by the ratio to those of SAEC, and all the genes were sorted by the descending order of average expression levels in SCLC cell lines. Genes in SCLC(2or3+)SAEC(-) category (*black bar* in the most right column) showed significant enrichment downward ($\dagger P < 10^{-15}$, Kolmogorov-Smirnov test), indicating that H3K27me3 modification at promoter regions correlated to gene repression. (c) GO-terms with significant enrichment. Immune response ($P = 5.1 \times 10^{-14}$), cell adhesion ($P = 1.7 \times 10^{-8}$), extracellular region ($P = 1.3 \times 10^{-23}$), plasma membrane ($P = 8.1 \times 10^{-21}$), and terms similar to these, showed significant enrichment in SCLC(2or3+)SAEC(-) genes.

($P < 1 \times 10^{-15}$, Kolmogorov-Smirnov test), i.e. were significantly repressed in SCLC cell lines (Fig. 3b). The 343 SCLC(2or3+)SAEC(-) genes showed significant enrichment of GO-terms e.g. immune response ($P = 5.1 \times 10^{-14}$), cell adhesion ($P = 1.7 \times 10^{-8}$) and other similar terms in Biological Process, which were different from GO-terms of PRC2-target genes in ES cells related to differentiation and development. Extracellular region ($P = 1.3 \times 10^{-23}$), plasma membrane ($P = 8.1 \times 10^{-21}$) and other similar GO-terms were enriched in Cellular Component (Fig. 3c).

Introduction of repressed genes in SCLC cell line. Genes possessing H3K27me3 mark in all the three SCLC cell lines, and relating to the four GO-terms of immune response, cell adhesion, extracellular region, or plasma membrane, were sorted by fold expression level between SAEC and mean of 3 SCLC cell lines in descending order (Fig. 4a). The most repressed genes were *JUB* and *PTRF*, which showed decreased expression to 0.01-fold in SCLC cell lines compared to SAEC, and H3K27me3 mark specifically in SCLC cell lines (Fig. 4b). These two genes were introduced in an SCLC cell line DMS53 using lentiviral system, and the protein expressions were confirmed by western blotting (Fig. 5a and Supplementary Fig. S3). *JUB* was distributed to the cellular membrane, while *PTRF* was localized in the cytoplasm (Fig. 5b). Introduction of *JUB* inhibited cellular growth, whereas introduction of *PTRF* did not affect cellular growth (Fig. 5c), suggesting that the most repressed gene related to cell adhesion, *JUB*, might function as a growth-suppressor in SCLC cells and its repression by PRC2 might contribute to genesis of SCLC.

***JUB* repression correlated to shorter survival.** Since gene repression by PRC2 was suggested to contribute to genesis of SCLC, we wanted to analyze whether the repression correlated to poorer prognosis of clinical SCLC or not. We therefore examined the dependency of overall survival time on *JUB* and other highly repressed PRC-target genes (*PTRF*, *DMKN*, *AXL*, *EPHB4*) (Fig. 4a) as well as highly expressed PRC2 complex genes (*EZH2*, *SUZ12*, *EED*) and also highly expressed classic type marker genes (*GRP*, *INSM1*, *ASCL1*) (Fig. 1a), using the Cox proportional-hazards regression. Repression of *JUB* or *EPHB4* showed strong correlation to shorter survival ($P = 0.002$ or $P = 0.007$, respectively), while high expression of classic type marker, *GRP*, also correlated to shorter

survival ($P = 0.02$) (Fig. 6a). The most relevant predictor variables were analyzed by the AIC based criteria, the stepAIC function of R software, and a set of four genes, *JUB*, *EPHB4*, *GRP* and *ASCL1*, was selected as the most relevant one ($P = 0.0001$) among all the possible combination of one through 11 genes. The K-means sample clustering with the four genes using Orange software²⁹ showed that the optimal cluster size was two, and the two groups of samples were shown by the multi dimensional scaling plot (Fig. 6b). The one group (namely Group-L) could be simply characterized with low *JUB* and high *GRP* expression, and the other one (namely Group-H), opposite (Fig. 6c). To analyze whether the classification into the two clusters reflect distinct prognosis, Kaplan-Meier survival analysis was also performed. Group-L showed shorter overall survival than Group-H ($P = 0.02$, log-rank test) (Fig. 6d).

To confirm the robustness of the set of four genes to classify SCLC, we analyzed reported RNA-seq data of SCLC¹⁴. The optimal cluster size was again two, revealed by the K-means sample clustering with the four genes using Orange²⁹, and the two groups of samples were shown by the multi dimensional scaling plot (Supplementary Fig. S4a). Again, the Group-L could be simply characterized with low *JUB* and high *GRP* expressions, and the Group-H, opposite (Supplementary Fig. S4b).

Treatment of SCLC cell lines with EZH2 inhibitors. To get insight into clinical application of EZH2 inhibitors on SCLC, we next analyzed effect of an EZH2 inhibitor, DZNep^{30,31}, on the three SCLC cell lines *in vitro*. When SCLC cell lines were treated with 5 μ M DZNep for 5–6 days, western blot analysis showed decrease of EZH2 protein level (Fig. 7a and Supplementary Fig. S5), which is consistent with the previous report³². WST-8 assay showed repression of cellular growth in the three SCLC cell lines,

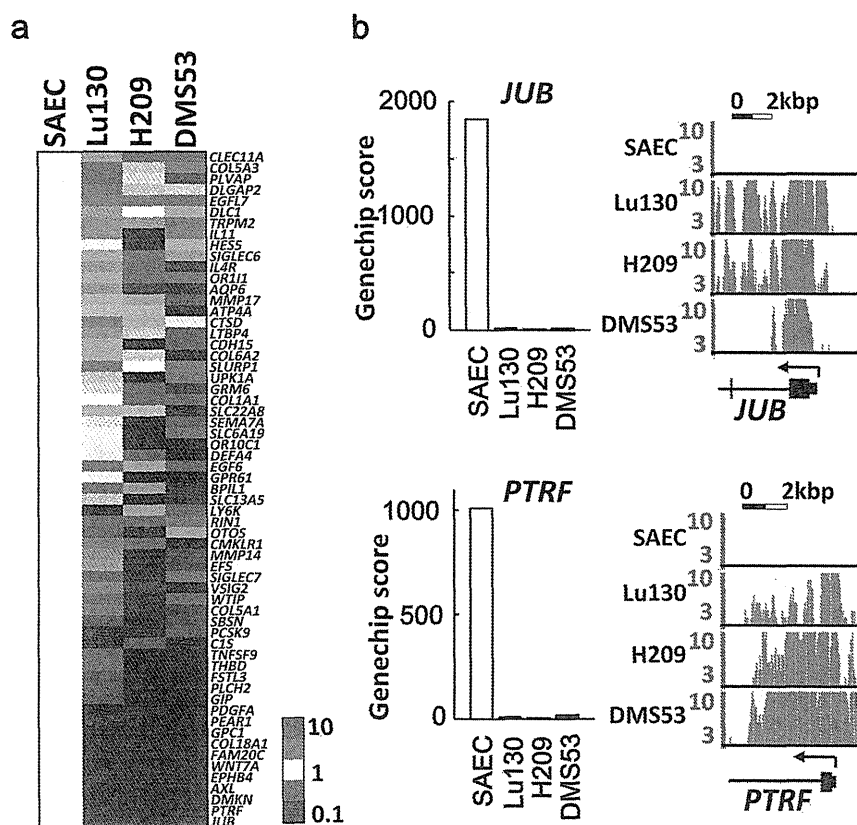


Figure 4 | Genes most repressed with H3K27me3 in SCLC. (a) Genes that showed H3K27me3 in all the three SCLC cell lines, and that were included in the four GO-terms of Immune response, cell adhesion, extracellular region, and plasma membrane. They were sorted by the descending order of average expression levels in SCLC cell lines, and the most repressed genes were *JUB* and *PTRF*. (b) SCLC cell lines showed low expression levels and H3K27me3 modifications of *JUB* and *PTRF*.

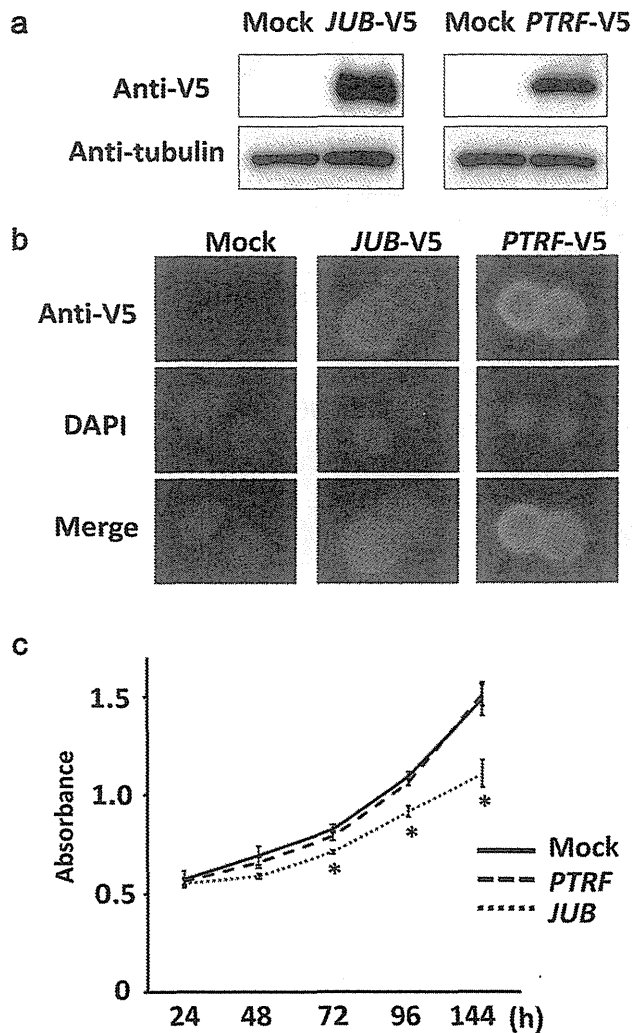


Figure 5 | Introduction of *JUB* and *PTRF* in SCLC cell line. *JUB* or *PTRF* cDNA with V5-tag was introduced in SCLC cell line DMS53 by lentivirus infection. (a) Expression was confirmed by western blotting. Blots were cropped in the figure, but the gels were run under the same experimental conditions, and full-length blots are presented in Supplementary Fig. S3. (b) *JUB* and *PTRF* expression by immunofluorescence. Introduced *JUB* was mainly observed at plasma membrane, and introduced *PTRF* was mainly observed in the cytoplasm. (c) Growth curve analyzed by WST-8 assay. *PTRF*-introduced cells showed similar growth to mock cells infected with empty lentivirus, whereas *JUB*-introduced cells showed suppressed growth significantly (* $P < 0.05$, *t*-test). Bars, standard deviation in triplicated analysis.

suggesting that *EZH2* inhibitors might be effective for therapy on SCLC.

SCLC cell lines were then treated with a selective *EZH2* inhibitor, GSK126, at different doses of 0.5, 2, and 8 μM (Fig. 7b). All the three cell lines showed substantial inhibition of cellular growth at high dose (8 μM). Although DMS53 was not sensitive to lower doses (0.5 μM and 2 μM), growth inhibition was observed in part at lower doses in Lu130 and H209.

Discussion

We here report high expression levels of *EZH2* and other PRC2 components in SCLC. Genes targeted by PRC2 in SCLC cell lines were shown to be repressed in SCLC cell lines and clinical SCLC samples. While *JUB* is the most repressed gene with H3K27me3 mark in all the three SCLC cell lines, *JUB* introduction lead to growth

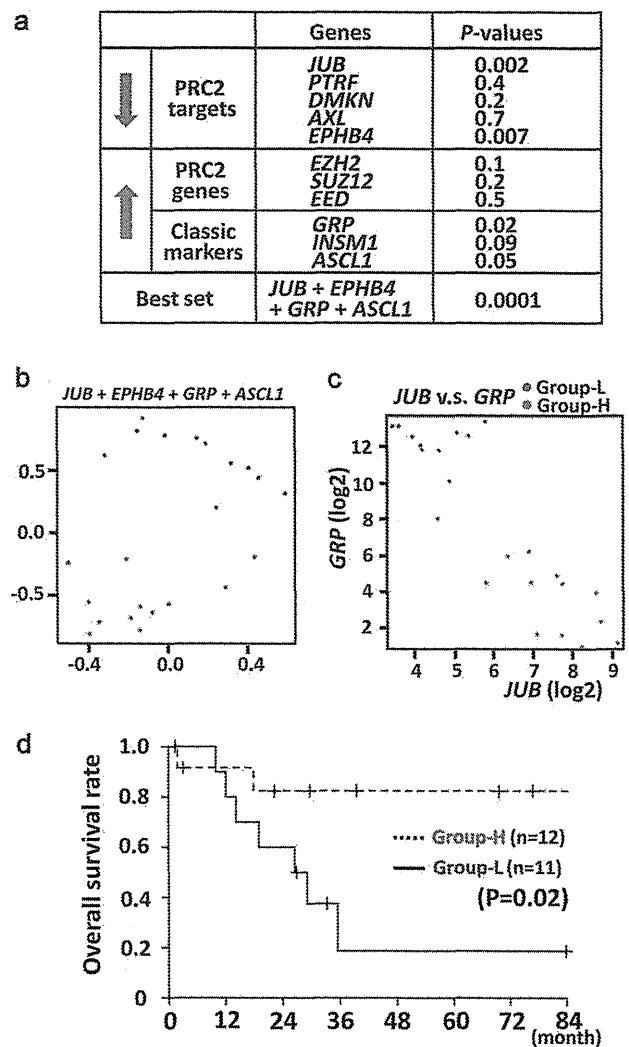


Figure 6 | Lower expression of *JUB* and poorer prognosis. (a) For five of repressed PRC-target genes (downward arrow) and six of highly expressed genes (upward arrow), the dependency of overall survival time of SCLC cases on each gene was analyzed using the Cox proportional-hazards regression, e.g. $P = 0.002$ for *JUB*. Among all the possible combination of one through 11 genes, the most relevant predictor variables were the set of the four genes, *JUB*, *EPHB4*, *GRP* and *ASCL1* (bottom, $P = 0.0001$). (b) The K-means sample clustering using the four genes showed that the optimal cluster size of SCLC cases was two, and the two groups of samples (blue and red spots) were shown by the multi dimensional scaling plot. (c) The one group (blue) could be simply characterized with low *JUB* and high *GRP* expression, and thus called Group-L. The other one (red) showed high *JUB* and low *GRP* expression, and thus called Group-H. (d) Group-L showed shorter recurrence-free survival than Group-H ($P = 0.02$, log-rank test).

inhibition of SCLC cells. Shorter overall survival of clinical SCLC cases significantly correlated to lower expression of *JUB* alone ($P = 0.002$), or a set of PRC2 target genes (*JUB*, *EPHB4*) and classic type marker genes (*GRP*, *ASCL1*) ($P = 0.0001$). Treatment of three SCLC cell lines with *EZH2* inhibitors, DZNep and GSK126, induced growth inhibition. These data suggested that high expression of PRC2 contributed to gene repression in SCLC, and the repression may play a role in worse prognosis of SCLC.

PRC2 complex has a histone methyltransferase activity and represses gene expression by methylation of H3K27 residue. PRC2-target genes in ES cells²⁸ show enrichment of genes related to development and differentiation, and repression of those genes in ES cells or adult tissue stem cells plays a role in maintenance of

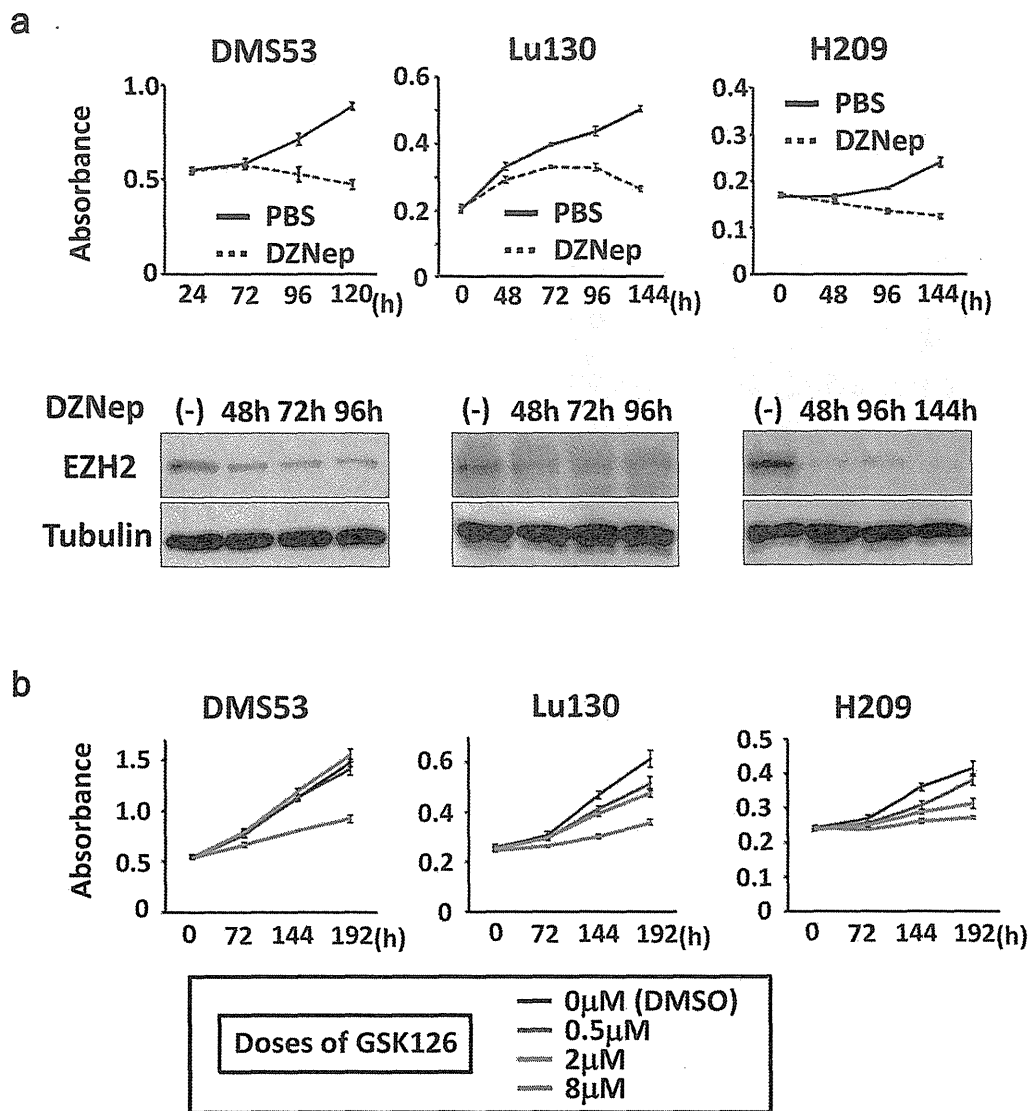


Figure 7 | Growth inhibition of SCLC cell lines by treatment with EZH2 inhibitors. (a) SCLC cell lines, Lu130, H209, and DMS53, were treated with 5 μ M DZNep, and growth curve was analyzed by WST-8 assay. Inhibition of cellular growth by DZNep treatment was observed in all the three cell lines, compared to vehicle (PBS) treatment. Protein levels of EZH2 were confirmed to be decreased by DZNep treatment, by western blot analysis. Blots were cropped in the figure, but the gels were run under the same conditions, except that 7% gel was used for EZH2 and 12% gel was used for α -tubulin in analyses of Lu130 and H209. Full-length blots are presented in Supplementary Fig. S5. (b) SCLC cell lines were treated with 0.5, 2, and 8 μ M GSK126, and growth curve was analyzed by WST-8 assay. Inhibition of cellular growth by GSK126 treatment was observed at 8 μ M in all the three cell lines, while Lu130 and H209 were more sensitive to GSK126, even at lower doses.

stemness³³. In this study, genes with H3K27me3 in SAEC only and genes with H3K27me3 both in SAEC and SCLC cells were significantly overlapped with PRC2-target genes in ES cells, and showed enrichment of GO-terms such as development and differentiation, similar to PRC2-target genes in ES cells. Genes with H3K27me3 in SCLC cells but not in SAEC, however, were not overlapped with PRC2-target genes in ES cells (Fig. 2d). It might be suggested that H3K27me3 marks in SCLC might be extended to not only PRC2-target genes in ES cells but also other target genes such as cellular adhesion-related genes, due to highly expressed PRC2 components.

It was reported that high expression levels of EZH2 in prostate cancer and breast cancer correlated to metastasis and invasion, and thus poorer prognosis^{17,18}. Inhibition of PRC2 by DZNep treatment resulted in growth inhibition of cancer cell lines with high expression of EZH2, compared to normal cell lines. *DAB21P* and *p21^{CDKN1A}* were reported to be PRC2 target genes and play a role in these cancers^{34–36}. In SCLC, high expression of EZH2 may extend PRC2-target genes

including *JUB*, and its repression in SCLC correlated to poorer prognosis. DZNep treatment of SCLC cell lines also resulted in growth inhibition, while DZNep is known as PRC2 inhibitor^{30,31}.

Recently, EZH2-specific inhibitors were reported to be developed and effective to diffuse large B-cell lymphoma cell lines^{37,38}. Although GSK126 induced loss of H3K27me3 independent of EZH2 mutation status, six of seven lymphoma cell lines sensitive to GSK126 treatment were *EZH2*-mutation(+), while only two of 11 lymphoma cell lines less sensitive to GSK126 were *EZH2*-mutation(+). It was suggested that lymphoma cell lines with mutant *EZH2* tend to be dependent on *EZH2* activity on cell growth³⁷. In our study, two of three SCLC cell lines showed growth inhibition in part at lower doses of GSK126. It might be suggested that elevated *EZH2* in SCLC could induce the dependence of cellular growth on *EZH2* activity, like the reported seven sensitive lymphoma cell lines (six *EZH2*-mutation(+) and one *EZH2*-mutation(-) cells), but that co-occurring alterations could perhaps weaken the dependency on *EZH2* in some

SCLC cells. PRC2-target medicine may become an important therapeutic strategy against cancer including SCLC, and application of EZH2-specific inhibitors should be further analyzed for SCLC.

While introduction of *JUB* showed growth suppression, introduction of *PTRF* had no effect. *PTRF* as well as *CAV1* is known as structural component of caveolae, 50–100 nm flask-shaped invaginations of plasma membrane involved in numerous signal transductions³⁹. Whereas *CAV1* was reported as a tumor suppressor^{40,41} and *PTRF* was required for premature senescence induction through interaction with *CAV1*⁴², *CAV1* was also strongly repressed in the three SCLC cell lines and clinical SCLC samples (Supplementary Fig. 6). Introduction of *PTRF* together with *CAV1* might be necessary to rule out tumor-suppressive function of *PTRF* in SCLC. Beside *JUB* and *PTRF*, genes with H3K27me3 in SCLC but not in SAEC included *EPHB4*, *WNT7A*, *COL18A1*, and *THBD* (Fig. 4). *EPHB4* was reported to be a tumor suppressor gene silenced by DNA hypermethylation in acute lymphoblastic leukemia, and transduction of *EPHB4* resulted in down-regulation of phosphorylated Akt⁴³. *WNT7A* was reported to be decreased in non-small cell lung cancer (NSCLC), and its transfection into NSCLC cell lines reversed malignant phenotype⁴⁴. *COL18A1* is cleaved to be Endostatin, an endogenous inhibitor of angiogenesis, and systemic administration of recombinant Endostatin inhibited growth of transplanted cancers⁴⁵. *THBD* was reported to be a tumor suppressor gene silenced by DNA hypermethylation in cancers^{46,47}, and its suppression correlated to tumor invasion and poor prognosis^{48,49}. Repression of these genes with H3K27me3 modification may also contribute to genesis of SCLC.

A cell adhesion-related protein *JUB* harbors LIM domain and is recruited to cadherin-dependent cell-cell adhesive complexes to form stable cell-cell junction⁵⁰. *JUB* was also reported to bind to PRMT5 and repress *SNAIL* target genes in the nucleus⁵¹, and accumulation of *JUB* in the nucleus of P19 embryonal cells resulted in growth inhibition and spontaneous endodermal differentiation⁵². In this study, introduction of *JUB* in an SCLC cell DMS53 resulted in growth repression, but the protein was distributed mainly to the cellular membrane, not in the nucleus. It is yet to be elucidated whether the protein distributed to cell-cell adhesive complexes functions as growth suppressor.

Classic type of SCLC with neuroendocrine feature is characterized with expression of *GRP* as well as L-dopa-decarboxylase, neuron specific enolase, and creatine kinase-BB isoenzyme⁵³. *ASCL1* is essential for development of neuroendocrine cells and also highly expressed in classic SCLC, and knock-down of *ASCL1* inhibited colony formation in soft agar and induced apoptosis in SCLC^{54,55}. Whereas *JUB* repression alone significantly correlated to shorter survival ($P = 0.002$), SCLC was classified into two groups with distinct prognosis using a set of PRC2 target genes (*JUB*, *EPHB4*) and classic type marker genes (*GRP*, *ASCL1*), and the group with poorer outcome could be simply characterized with low expression of *JUB* and high expression of *GRP* (Fig. 6c). Further study is necessary whether these expressions are independent phenomena or features of classic type SCLC include gene repression with H3K27me3.

In summary, PRC2 components were highly expressed in SCLC and contributed to gene repression, and the repression may play a role in genesis of SCLC.

Methods

Clinical samples and cell lines. Primary SCLC samples were obtained from patients undergoing pulmonary resection at Department of Surgery, Cancer Institute Hospital, with written informed consents. These samples were immediately frozen with liquid nitrogen and stored at -80°C . The frozen materials were microscopically examined by two independent pathologists, and were dissected to enrich cancer cells when necessary. Three SCLC cell lines with variable characteristics were prepared: a monolayer cell line DMS53 with wild type RB and missense mutation of p53, a floating cell line Lu130 with wild type RB and missense mutation of p53, and another floating cell line H209 with missense mutation of RB and splice site mutation of p53 (Supplementary Table S2). H209 and DMS53 were purchased from ATCC

(Manassas, VA), and Lu130 was from Riken BioResource Center Cell Bank (Tsukuba, Japan). SAEC was obtained from Lonza (Basel, Switzerland). Lu130 and H209 were cultured in RPMI1640 containing penicillin and streptomycin, supplemented with 10% fetal bovine serum at 37°C in 5% CO_2 . DMS53 was cultured in Dulbecco's modified Eagle's medium (DMEM) containing penicillin and streptomycin, supplemented with 10% fetal bovine serum at 37°C in 5% CO_2 . SAEC was cultured according to supplier's instruction using SAGM BulletKit and Reagent Pack (Lonza). This study was certified by Ethics Committee in The University of Tokyo and in the Cancer Institute.

RNA samples. Total RNA of 23 SCLC samples, three SCLC cell lines and SAEC was extracted using Trizol (Invitrogen). RNA samples of normal tissues to include variety of organs e.g. central nervous, respiratory, gastrointestinal, endocrine, immunological, skeletal, reproductive, urinary and circulatory systems, were purchased as follows: whole brain, cerebellum, adrenal gland, salivary gland, trachea, bone marrow, testis from Clontech (Mountain View, CA); cerebral cortex, pons, hippocampus, diencephalon, thalamus, tongue, esophagus, gallbladder, tonsil, artery, vein, adipose, lymph node, seminal vesicle from Biochain (Newark, CA); thymus, ovary, skeletal muscle, heart, small intestine, colon, pancreas, kidney, bladder, spleen, prostate from Ambion (Carlsbad, CA); skin, thyroid, breast, and uterus from Stratagene (Santa Clara, CA). The quality of RNA was controlled using Bioanalyzer 2100 (Agilent Technology, CA) and high quality RNA with RNA intensity number (RIN) ≥ 7.0 was used for array analysis.

Expression array analysis. For genome-wide transcription analysis, Affymetrix GeneChip Human Genome U133 plus 2.0 oligonucleotide arrays (Fremont, CA) was used. Data were collected and analyzed by GeneChip Scanner 3000 (Affymetrix). The GeneChip data were analyzed using the Affymetrix GeneChip Operating Software v1.3 by MAS5 algorithms, to obtain signal value (Genechip score) for each probe. For global normalization, the average signal in an array was made equal to 100. Expression array data is available at GEO datasets (GSE43346). Expression levels of squamous cell carcinoma and adenocarcinoma of the lung analyzed also using U133 plus 2.0 oligonucleotide arrays were collected from GEO datasets (GSE2199), and global normalization was done by the same manner.

Gene ontology analysis. Gene annotation enrichment analysis was done for Gene Ontology (biological process and cellular component) using the Functional Annotation tool at DAVID Bioinformatics Resources 6.7 (<http://david.abcc.ncifcrf.gov/>).

Chromatin immunoprecipitation (ChIP). Cells were cross-linked with 1% formaldehyde for 10 min at room temperature and were prepared for ChIP. ChIP using H3K27me3 (07-142, Upstate, rabbit polyclonal), or Suz12 (D39F6, Cell Signaling, rabbit monoclonal) antibody was performed as we previously reported⁵⁶. Briefly, cells were crosslinked with 1% formalin for 10 min, and crosslinked cell lysates underwent fragmentation by sonication and incubated with antibodies bound to protein A-sepharose beads (50% slurry) overnight at 4°C . The beads were washed several times and eluted with elution buffer (1% SDS, 0.1 M NaHCO_3). The eluates were treated with 1.5 μg of pronase 2 hr at 42°C then incubated at 65°C over night to reverse the crosslinks. The ChIP'ed DNA was purified by phenol/chloroform treatment and precipitated with LiCl and 70% ethanol.

ChIP-sequencing (ChIP-seq). Sample preparation for ChIP-seq was performed according to the manufacturer's instructions (Illumina), and sequencing was performed using Illumina Genome Analyzer IIX as we previously reported⁵⁶. Briefly, size fractionated DNA was extracted and a single adenosine was added using Klenow exo- (3' and 5' exo minus; Illumina). Illumina adaptors were then added and DNA was subjected to 20 cycles of PCR according to manufacturer's instructions. We then purified DNA and performed cluster generation and 36 cycles of sequencing on the Illumina cluster station and 1G Analyzer following the manufacturer's instructions. 36-bp single end reads were mapped to the NCBI Build #36 (UCSC hg18) reference human genome, using the Illumina pipeline software version 1.4. The numbers of uniquely mapped reads for SAEC, Lu130, H209 and DMS53 were 19,527,119 (SAEC), 7,543,376 (Lu130), 18,418,930 (H209) and 21,354,066 (DMS53) for H3K27me3, and 20,025,034 (Lu130) for Suz12. Distribution of immunoprecipitated DNA fragments was analyzed using Model-based Analysis for ChIP-Seq (MACS)⁵⁷, with a window of 600 bp. Regions with $p < 10^{-30}$ and $p < 10^{-10}$ were regarded as H3K27me3(+) and SUZ12(+) regions, respectively. ChIP-seq data is available at GEO datasets (GSE43346).

Quantitative real-time ChIP-PCR. ChIP samples were amplified by real-time PCR using SYBR Green and iCycler Thermal Cycler (Bio-Rad Laboratories) and quantified by drawing the standard curve using 20, 2, 0.2, and 0.02 ng/ μL sonicated genomic DNA of SAEC. The quantity of ChIP'ed DNA was shown as a ratio to Input DNA (Input %). The PCR primers and conditions are shown in Supplementary Table S3.

Lentiviral vectors. To introduce *JUB* and *PTRF* in SCLC cell, we constructed lentiviral vectors for *JUB* and *PTRF* by cloning full-length cDNAs by reverse-transcription PCR products from SAEC, into a CMV promoter driven expression vector pLentiV5 (Invitrogen, Carlsbad, CA) that contains puromycin resistance gene, and check the sequences. Lentivirus was prepared by transfection of pLentiV5 vector