

研究成果の刊行に関する一覧表

書籍

著者氏名	論文タイトル名	書籍全体の編集者名	書 籍 名	出版社名	出版地	出版年	ページ
なし							

雑誌

発表者氏名	論文タイトル名	発表誌名	巻号	ページ	出版年
D. Obata, Y. Morita, R. Kawaguchi, <b><u>K. Ishii,</u></b> <b><u>H. Hazama,</u></b> <b><u>K. Awazu,</u></b> H. Kutsumi, and T. Azuma	Endoscopic submucosal dissection using a carbon dioxide laser with submucosally injected laser absorber solution (porcine model)	Surg. Endosc.	27(11)	4241-4249	2013
D. Kusakari, <b><u>H. Hazama,</u></b> R. Kawaguchi, <b><u>K. Ishii,</u></b> and <b><u>K. Awazu</u></b>	Evaluation of the bending loss of the hollow optical fiber for application of the carbon dioxide laser to endoscopic therapy	Opt. Photon. J.	3(4A)	14-19	2013

#### IV. 研究成果の刊行物・別刷

## Endoscopic submucosal dissection using a carbon dioxide laser with submucosally injected laser absorber solution (porcine model)

Daisuke Obata · Yoshinori Morita · Rinna Kawaguchi · Katsunori Ishii · Hisanao Hazama · Kunio Awazu · Hiromu Kutsumi · Takeshi Azuma

Received: 28 December 2012 / Accepted: 10 May 2013 / Published online: 21 June 2013  
© Springer Science+Business Media New York 2013

### Abstract

**Background** Recently, endoscopic submucosal dissection (ESD) has been performed to treat early gastric cancer. The en bloc resection rate of ESD has been reported to be higher than that of conventional endoscopic mucosal resection (EMR), and ESD can resect larger lesions than EMR. However, ESD displays a higher complication rate than conventional EMR. Therefore, the development of devices that would increase the safety of ESD is desired. Lasers have been extensively studied as a possible alternative to electrosurgical tools. However, laser by itself easily resulted in perforation upon irradiation of the gastrointestinal tract. We hypothesized that performing ESD using a CO<sub>2</sub> laser with a submucosal laser absorber could be a safe and simple treatment for early gastric cancer. To provide proof of concept regarding the feasibility of ESD using a CO<sub>2</sub> laser with submucosally injected laser absorber solution, an experimental study in *ex vivo* and *in vivo* porcine models was performed.

**Methods** Five endoscopic experimental procedures using a carbon dioxide (CO<sub>2</sub>) laser were performed in a resected porcine stomach. In addition, three endoscopic experimental procedures using a CO<sub>2</sub> laser were performed in living pigs.

**Results** In the *ex vivo* study, en bloc resections were all achieved without perforation and muscular damage. In addition, histological evaluations could be performed in all of the resected specimens. In the *in vivo* study, en bloc resections were achieved without perforation and muscular damage, and uncontrollable hemorrhage did not occur during the procedures.

**Conclusions** Endoscopic submucosal dissection using a CO<sub>2</sub> laser with a submucosal laser absorber is a feasible and safe method for the treatment of early gastric cancer.

**Keywords** Endoscopic resection · Therapeutic upper gastrointestinal endoscopy · Laser · Laser absorbent

Gastric cancer is one of the most common cancers in the world. The development of endoscopic diagnostic techniques led to an increased number of early stage gastric cancers being detected. Subsequently, endoscopic mucosal resection (EMR) was established as a minimally invasive local treatment and is now performed for the treatment of early gastric cancer without lymph node metastasis [1]. The main advantages of the EMR method are that it does not involve laparotomy, the whole stomach is preserved, and it has a less negative impact on the patient's quality of life than laparotomy. Although the possibility of expanding the indications for EMR to resect larger lesions has recently been proposed, conventional EMR cannot be used to resect lesions larger than 20 mm en bloc because of technical limitations [2, 3]. Piecemeal resection does not enable sufficient histological evaluation of the tumor and displays a significantly higher local recurrence rate than en bloc resection [4–6]. Therefore, endoscopic submucosal dissection (ESD), a new EMR technique, was introduced by Hirao et al. [7] and has become widely accepted as a

---

D. Obata · Y. Morita · H. Kutsumi · T. Azuma (✉)  
Division of Gastroenterology, Department of Internal Medicine,  
Graduate School of Medicine, Kobe University, 7-5-2,  
Kusnoki-cho, Chuo-ku, Kobe, Hyogo, Japan  
e-mail: azumat@med.kobe-u.ac.jp

D. Obata  
e-mail: dobata@med.kobe-u.ac.jp

R. Kawaguchi · K. Ishii · H. Hazama · K. Awazu  
Division of Sustainable Energy and Environmental Engineering,  
Graduate School of Engineering, Osaka University,  
Suita, Osaka, Japan

standard procedure for early gastric cancer treatment. ESD allows larger lesions to be resected en-bloc. However, in comparison with EMR, ESD requires special skills and involves a long procedure. In addition, ESD carries a high risk of perforation and bleeding. Various devices, such as the insulated-tip knife (IT knife) [4], Flush knife [8], and hook knife [9] have been developed to reduce the complications rate of ESD. When dissection is performed using these devices, which cut using an electrosurgical current, the knife is in direct contact with the tissue. Submucosal dissection using an electrosurgical current requires a high level of skill and carries a risk of perforation because of unexpected incision of the muscularis propria. It was reported that the perforation rate of ESD for early gastric cancer using the IT knife was 5 % [4].

Lasers have been extensively studied as a possible alternative to electrosurgical tools. Various types of laser have been used as surgical tools to incise or excise tissues and achieve hemostasis. For example, potassium titanyl phosphate (KTP), neodymium-doped yttrium aluminium garnet (Nd:YAG), and diode lasers have all been used in endoscopic procedures for treating gastrointestinal tract cancer or precancerous lesions. These laser irradiation therapies vaporize the lesion and coagulate any hemorrhaging blood vessels. The main disadvantage of these therapies is that the lesion is vaporized; thus, pathological evaluations cannot be performed after the procedure. It is important to collect tissue samples from dissected lesions as it allows a precise pathological evaluation and aid decisions regarding additional treatment.

Lasers have various effects on living tissue. Recently, lasers have been widely used in clinical practice for making incisions, inducing coagulation and hemostasis, and vaporizing lesions. The laser energy absorbed by the target tissue is converted into other forms of energy, such as heat or shockwaves, or is used to induce chemical reactions. Lasers of different wavelengths have different scattering, penetration, and absorption profiles, and hence, have different effects on the target lesion depending on the amounts of energy absorbed by elements within tissue [10]. In the mid-infrared range, light scattering is negligible within soft tissue. The surgical performance of mid-infrared lasers generally depends on the light absorption characteristics of water and protein, the main components of soft tissue, at the laser's oscillating wavelength. The CO<sub>2</sub> laser is a gas laser that was originally developed in 1964 and has a wavelength of 10.6 μm [11]. It has been widely used in various surgical treatments in the otorhinolaryngology, dermatology, and oral surgery fields [12–14]. It is a mid-infrared laser, and its energy is strongly absorbed by water and protein, but hardly penetrates deeper tissues [15]. CO<sub>2</sub> lasers can cut tissue precisely whilst causing limited damage to the surrounding tissue [12–14]. Surgical procedures performed with CO<sub>2</sub>

lasers are mostly bloodless because the heat produced by the laser seals small vessels [16]. The reduced heat damage inflicted on the resected lesion allows precise pathological evaluations to be performed, and the low level of hemorrhaging increases visibility during the procedure, therefore making it safer. These features of the CO<sub>2</sub> laser are thought to be advantageous for ESD.

In clinical ESD procedures, a solution (usually saline or sodium hyaluronate) is injected into the submucosa to lift the target region of the mucosa, isolate the lesion, and protect the muscularis propria from thermal and mechanical injury, thereby decreasing the risk of perforation. Compared with most other lasers, a large amount of the energy produced by CO<sub>2</sub> lasers is absorbed by water [17]. Therefore, if there is enough water within the submucosa, it is hypothesized that the energy of the CO<sub>2</sub> laser will be absorbed by the water and will not be able to reach the muscularis propria. Thus, performing ESD using a CO<sub>2</sub> laser with saline as a submucosal laser absorbent could be a safe and simple treatment for early gastric cancer. There have been no previous reports of ESD of the stomach performed using a CO<sub>2</sub> laser because usual optical fibers cannot be used to deliver CO<sub>2</sub> laser due to very high internal absorption of the optical fibers. However, the hollow optical fiber that has recently been developed has enabled us flexible delivery of CO<sub>2</sub> laser. We examine whether performing gastric ESD with a CO<sub>2</sub> laser is feasible.

## Materials and methods

### Measurement of infrared absorption spectra

The infrared absorption spectra of the porcine stomach wall, saline, and 0.4 % sodium hyaluronate (MucoUp; Johnson and Johnson K.K., Tokyo, Japan) were measured using a Fourier transform infrared spectrometer (MB3000, ABB Ltd., Zurich, Switzerland) coupled with an infrared microscope (bi-μMAX, PIKE Technologies, WI, USA). When the absorption spectrum of the porcine stomach was measured, the absorption spectra of each layer; i.e., the mucosa, submucosa, and muscularis propria, were assessed.

### CO<sub>2</sub> laser

A CO<sub>2</sub> laser oscillation device (J. Morita Mfg. Corp., Kyoto, Japan) that had been remodeled to increase its output power was used for these experiments. The laser was used in continuous wave mode. The output power of the laser was measured using a laser power meter (30A, Ophir Optronics Solutions Ltd, Israel) and was set at predetermined values.

### Hollow optical fiber

A hollow optical fiber (J. Morita Mfg. Corp., Kyoto, Japan) optimized for the wavelength of the CO<sub>2</sub> laser was used in this study [18]. The inner diameter of the fiber was 700 μm, and it measured 2.65 m in length. The fiber was connected to a CO<sub>2</sub> laser oscillation device.

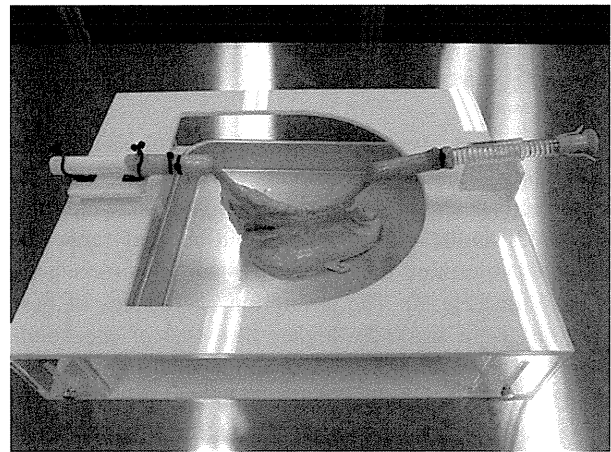
### Preliminary study

The speed of porcine gastric mucosal incisions made with electrosurgical knives was measured (data not shown), and it was found that the mean mucosal incision speed was about 1.0 mm/s. Porcine gastric wall samples were placed on an automatic moving table, and the speed of the table's movement was set at 0.5, 1, or 2 mm/s. In the absence of saline injection into the submucosa, the CO<sub>2</sub> laser irradiation was performed at output powers of 6, 8, and 10 W at a distance 2 mm from the mucosal surface. In the presence of saline injection into the submucosa, which was performed to increase the thickness of the submucosa to 5 mm, laser irradiation was performed at output powers of 6, 8, 10, and 12 W. The depth of incision was measured during each procedure.

### Ex vivo porcine stomach study

Porcine organs (the esophagus, stomach, and duodenum) were irrigated with water and Pronase MS 400 U/ml (Kaken Pharma, Tokyo, Japan). An overtube (MD-48518 Sumitomo Bakelite, Tokyo, Japan) was fixed onto a plastic box (Pentax Corporation, Tokyo, Japan). The esophagus of the resected specimen was then passed over the overtube, which formed a solid connection with the oral end of the esophagus. Then, the end of the duodenum was tightly attached to the plastic box using a plastic band (Fig. 1).

An upper gastrointestinal endoscope (GIF-Q260J, Olympus, Tokyo, Japan) was inserted into the stomach. To identify the margins of the hypothetical lesions, marking dots were made on the exterior of the target mucosa using a Flush knife (DK2618JN25, Fujifilm) and an electrical generator (vio200S; ERBE, Germany). The marking dots were placed so that the hypothetical lesions had diameters of 2 cm. Saline was injected into the submucosa under the hypothetical lesion with an endoscopic injection needle (01841; Top Corporation, Tokyo, Japan). A hollow optical fiber was passed through the scope channel, and circumferential mucosal cutting was performed using the continuous wave mode of the CO<sub>2</sub> laser at a power setting of 10.0 W. After an additional submucosal injection of saline, the submucosa below the hypothetical lesion was directly dissected using the same CO<sub>2</sub> laser mode. After cauterization, all of resected specimens and ESD sites were



**Fig. 1** A porcine stomach was subjected to CO<sub>2</sub> laser ESD using an endoscopy training system. A resected porcine stomach was subjected to CO<sub>2</sub> laser ESD using a training system for endoscopic procedures

collected and fixed in 4 % formalin, and then the diameter of the cauterized area was evaluated histologically.

### Living porcine study

LWD pigs weighing 18.5 kg were used in the study. This study was approved by ethical committee of the animal experimentation facility. The pigs were deprived of food for 24 h before the procedure. The pigs were placed under general anesthesia via the intramuscular injection of 10 mg/kg ketamine plus 2 mg/kg xylazine and endotracheal intubation. Anesthesia was maintained with isoflurane (2.0–3.0 %) and oxygen (2.0–3.0 L/min).

An upper gastrointestinal endoscope (GIF-Q260J, Olympus, Tokyo, Japan) was passed into the stomach with the assistance of an overtube (MD-48518 Sumitomo Bakelite, Tokyo, Japan). Marking dots were made around the exterior of a hypothetical lesion using a FlushKnife (DK2618JN25, Fujifilm) and an electrical generator (vio200S; ERBE, Germany) to identify its margins. Saline was then injected into the submucosa under the hypothetical lesion with an endoscopic injection needle (01841; Top Corporation, Tokyo, Japan). A hollow optical fiber was passed through the scope channel, and circumferential mucosal cutting was performed using the continuous wave mode of the CO<sub>2</sub> laser at a power setting of 10 W. After an additional submucosal injection of saline, the submucosa below the hypothetical lesion was directly dissected using the same CO<sub>2</sub> laser mode. After cauterization, necropsy was *immediately* performed, and all of the resected specimens and ESD sites were collected. The collected samples were fixed in 4 % formalin, and the diameter of the cauterized area was evaluated histologically.

## Results

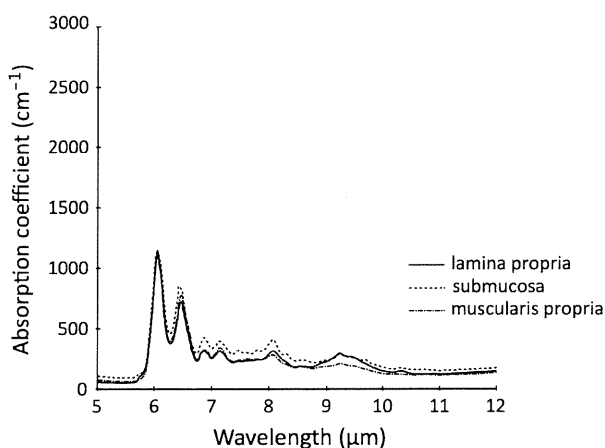
### Infrared absorption spectra

The absorption spectra of the mucosa, submucosa, and muscularis propria were almost identical (Fig. 2). The absorption spectra of saline and 0.4 % sodium hyaluronate displayed similar curves in the mid-infrared range and exhibited absorption values of  $\sim 850 \text{ cm}^{-1}$  at a wavelength of  $10.6 \mu\text{m}$  (Fig. 3). The absorption coefficients of these solutions were markedly higher than that of the lamina propria at a wavelength of  $10.6 \mu\text{m}$ , suggesting that laser absorbents, such as saline and sodium hyaluronate, absorb enough of the energy produced by  $\text{CO}_2$  lasers to protect the muscularis propria from damage caused by laser irradiation.

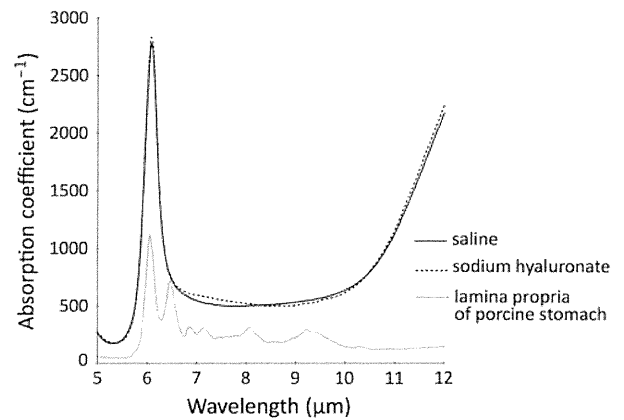
### Preliminary study

To investigate whether the submucosal injection of saline prevents the muscularis propria from being injured and to determine the optimal  $\text{CO}_2$  laser output power for ESD, a preliminary study was performed. In the absence of saline injection, at cutting speeds of 0.5 and 1.0 mm/s performing the  $\text{CO}_2$  laser irradiation at 6 W damaged the muscularis propria, and performing it at 10 W damaged the muscularis propria at all speeds (Fig. 4A, C). On the other hand, in the presence of saline, irradiation did not damage the muscularis propria at any speed or output power (Fig. 4B, D). Thus, the injection of saline prevented the laser's energy from passing through the submucosa, and hence, protected the muscularis propria from injury.

When sodium hyaluronate was injected into the submucosa, performing the  $\text{CO}_2$  laser irradiation at 12 W and 0.5 mm/s, which were the conditions that were found to be



**Fig. 2** Absorption spectra of the porcine stomach. The infrared absorption spectra of the lamina propria, submucosa, and muscularis propria are shown. These spectra were similar in the infrared region



**Fig. 3** Absorption spectra of saline and sodium hyaluronate. The infrared absorption spectra of saline, sodium hyaluronate, and the mucosa of the porcine stomach are shown. The spectra of saline and sodium hyaluronate were similar. The absorption coefficients of these solutions were higher than that of the lamina propria at a wavelength of  $10.6 \mu\text{m}$

most likely to induce injury in the saline experiment, laser irradiation did not damage the muscularis propria (data not shown).

These results showed that both saline and sodium hyaluronate stopped the energy of the  $\text{CO}_2$  laser from passing through the submucosa and prevented the muscularis propria from being injured.

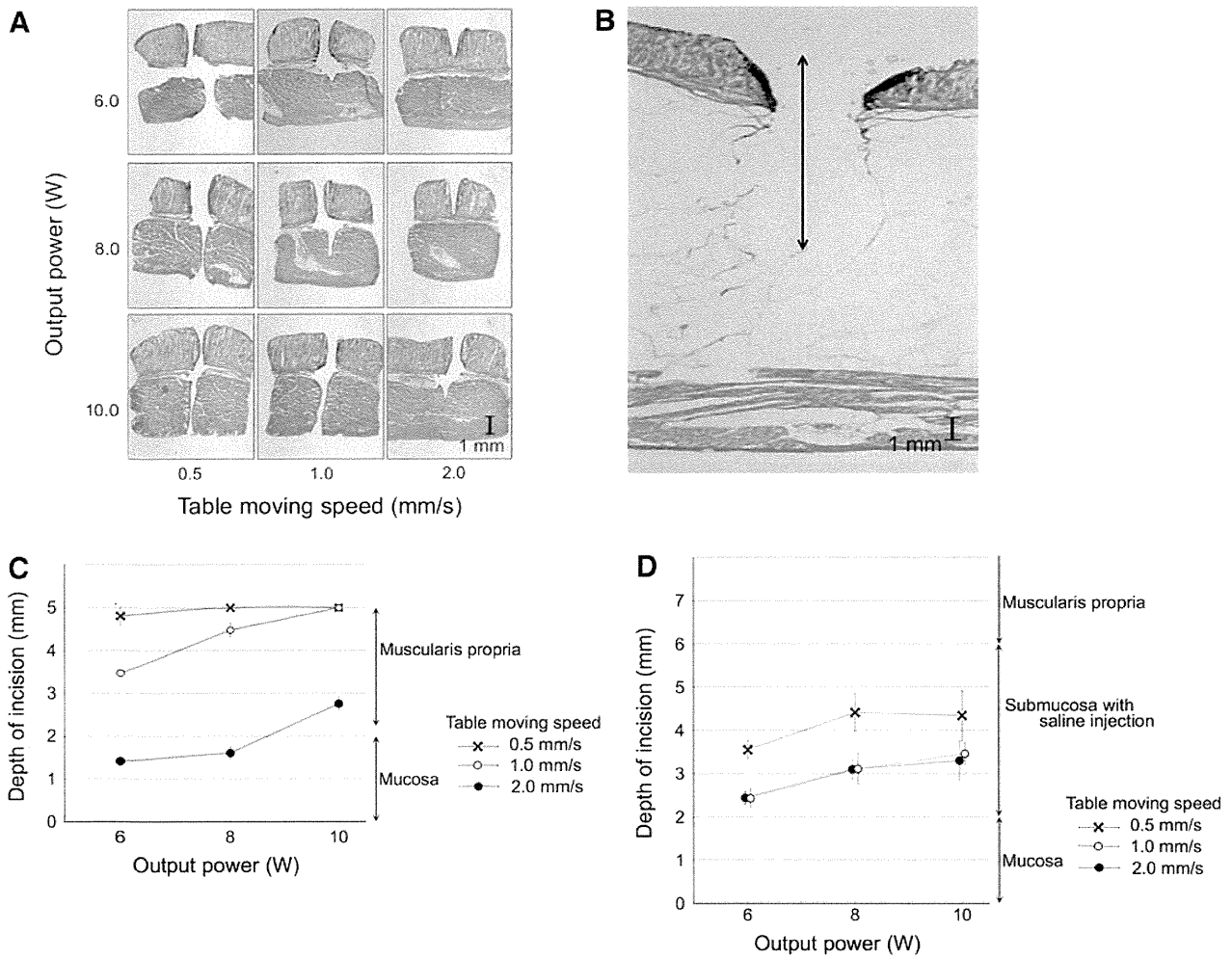
### *Ex vivo* porcine study

To investigate whether performing ESD using a  $\text{CO}_2$  laser with laser absorber is a safe and feasible method, an *ex vivo* study, in which a porcine gastric model was subjected to the procedure, was performed.

The procedure time was measured from the first submucosal injection to the end of the complete resection of the lesion. Grossly, all specimens included all of the markings caused by electrocautery, which formed the equivalent of a tumor-free resection margin. Hypothetical lesions were produced in the antrum, lower body, central body, and upper body. En bloc resections were achieved in all cases. The mean diameter of the resected specimen was 31.6 mm, and the mean procedure time was 26.2 min (Table 1).

The gastric wall resection sites were examined. However, no gastric wall perforation was encountered, and no muscular injuries were detected during histological examinations.

The resected specimens also were collected and histologically evaluated. The mucosae of the resected specimens were not damaged by the submucosal dissection, and histological evaluations could be performed in all of the resected specimens (Fig. 5A). The resection margins were very clear, and almost no burn effects were seen. In




**Fig. 4** Incision depth in various conditions. In the absence of saline injection, performing the CO<sub>2</sub> laser irradiation using an output power of 6 W damaged the muscular layer at incision speeds of 0.5 and 1.0 mm/s. Performing the CO<sub>2</sub> laser irradiation at an output power of 10 W damaged the muscular layer at all speeds (A). When the CO<sub>2</sub> laser incision was performed at an output power of 12 W and a speed

of 0.5 mm/s, it did not reach the muscular layer (B). These conditions were considered to produce the deepest incisions according to the findings obtained without saline injection. C Depth of the incisions produced in the absence of saline injections. D Depth of the incisions produced in the presence of saline injections

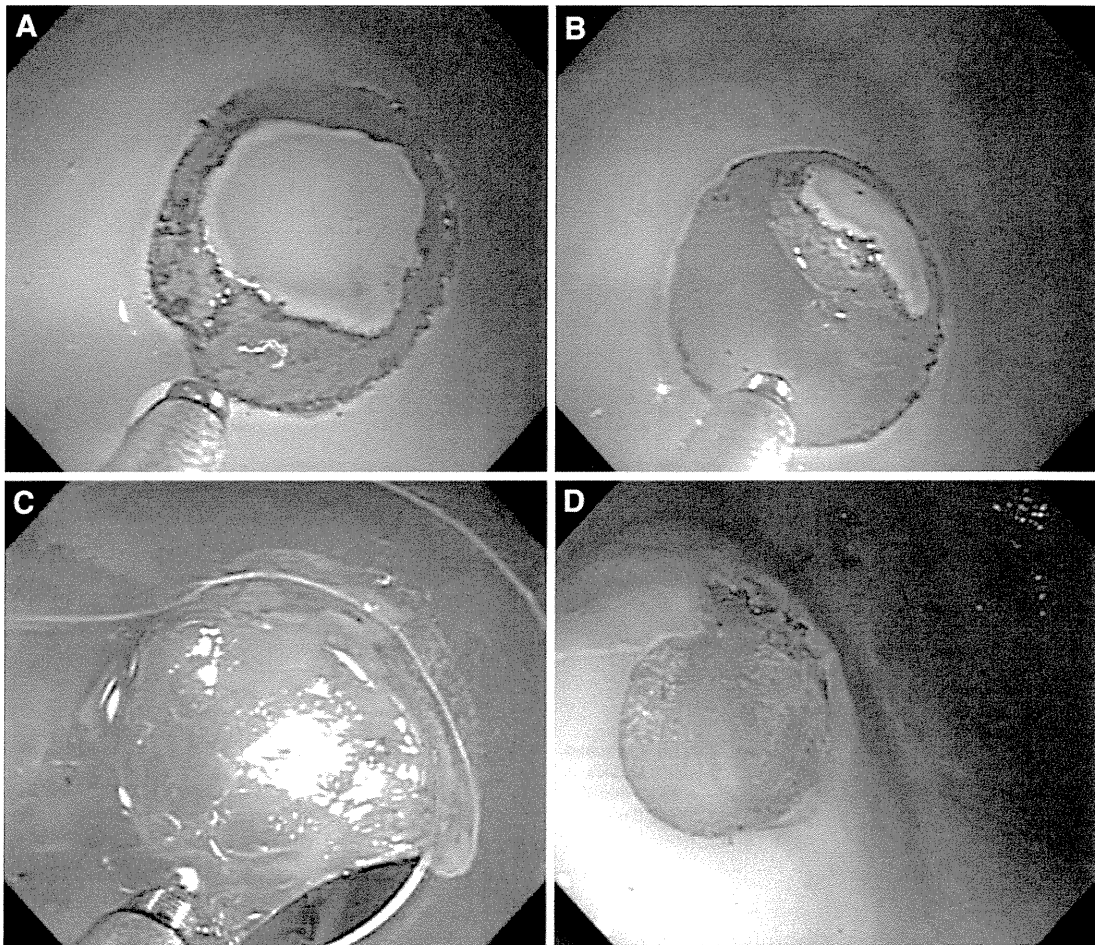
**Table 1** Results of CO<sub>2</sub> laser ESD in a resected porcine stomach

Case	Procedure time (min)	Major axis (mm)	Minor axis (mm)	Perforation
1	22.3	32.6	26.7	None
2	26.6	31.1	26.3	None
3	24.1	30.2	25.8	None
4	22.7	33.6	21.8	None
5	35.5	30.3	29.7	None
Mean	26.2	31.6	26.1	0
SD	5.5	1.5	2.8	0

ESD was performed using a CO<sub>2</sub> laser for five hypothetical lesions. The mean size of the resected specimens was 31.5 mm, and the mean procedure time was 26.2 min. No perforation occurred during the procedures



**Fig. 5** Histological findings of the resected lesion and resected site. A Histological findings of the resected lesion after laser ESD. Enough of the submucosa remained to allow submucosal invasion and lymphovascular invasion to be evaluated. B Histological findings of the laser ESD site. No muscular damage was seen



**Fig. 6** Endoscopic view of ESD using a CO<sub>2</sub> laser. **A** Circumferential mucosal incision. **B, C** Submucosal dissection. **D** Artificial ulcer produced by laser ESD

addition, no muscular damage was detected (Fig. 5B). These results suggest that ESD using a CO<sub>2</sub> laser is feasible.

#### Living porcine study

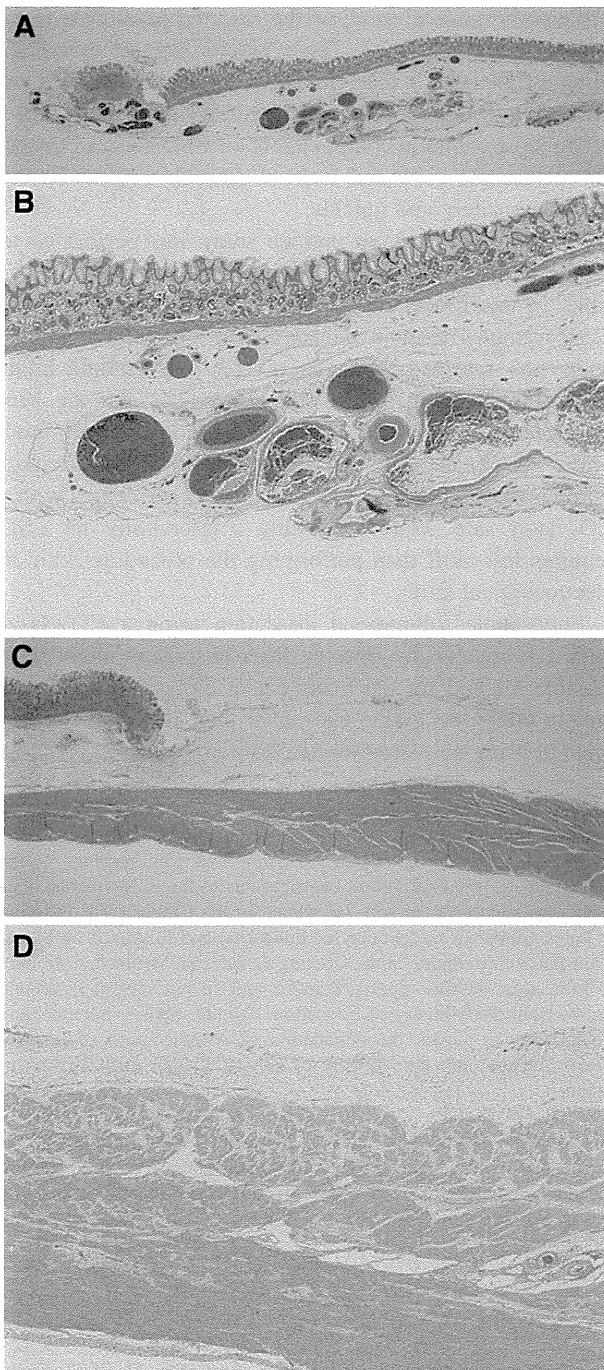
The *ex vivo* study suggested that ESD using a CO<sub>2</sub> laser is a feasible method. To verify the feasibility and safety of this method *in vivo*, a living porcine model study was performed (Fig. 6A–D). The median procedure time from the circumferential mucosal dissection to the end of the submucosal dissection was 22.3 min. Little hemorrhaging occurred during the circumferential mucosal dissection or submucosal dissection, and the hemorrhaging that did occur was arrested immediately with CO<sub>2</sub> laser irradiation. The procedures were accomplished without any complications, such as perforations or serious bleeding. During the circumferential mucosal dissection, smoke and fragment splattering temporarily reduced the endoscopist's visibility. However, the smoke and fragments were successfully

suctioned using an accessory channel, and the lens of the endoscope was cleaned, thereby recovering visibility. The incision edge was sharp and clear on the endoscopic view. During the submucosal dissection, no smoke or fragment splattering occurred. Specimens of the resected mucosa were collected, and the surface and edge of the ulcers produced by ESD were smooth. The heat damage caused by the incision and dissection was not extensive so it was possible to histologically evaluate the resected mucosa (Fig. 7A, B). The muscularis propria was not damaged by the laser irradiation (Fig. 7C, D). These findings indicate that ESD using a CO<sub>2</sub> laser is a feasible and safe method.

#### Discussion

Endoscopic submucosal dissection has been widely performed, not only for early gastric cancer, but also for superficial cancers in other parts of the gastrointestinal tract, such as esophageal cancer and colorectal cancer.





**Fig. 7** **A, B** Histological findings of the resected lesion and ESD resected site. **C, D** Histological findings of the laser ESD site. Enough of the submucosa remained free of heat damage to allow submucosal invasion and lymphovascular invasion to be evaluated (**A, B**). No muscular damage was detected at the ESD resection site (**C, D**)

However, ESD requires a great deal of endoscopic skill, and the procedure takes a long time. In addition, ESD carries a high risk of perforation and bleeding [4]. ESD is usually performed with an electro-surgical knife. It is

difficult to make incisions with electro-surgical knives without appropriate traction; therefore, skill is required to move the knife in the appropriate direction. Thus, to broaden ESD it is necessary to develop simple methods for mucosal incision and submucosal dissection. We hypothesized that laser irradiation might be a suitable alternative to using electro-surgical knives in ESD, because it can be used to make incisions and induce coagulation regardless of the skill of the operator. If the target can be directly viewed, then only the laser beam has to be in contact with the target, rather than the device itself, which is required for procedures performed with electro-surgical knives.

CO<sub>2</sub> lasers have been widely used in various surgical procedures in the otorhinolaryngology, dermatology, and oral surgery fields [12–14]. However, there have been few reports about CO<sub>2</sub> laser treatment involving the gastrointestinal tract, because the endoscopic use of CO<sub>2</sub> lasers in gastrointestinal procedures is limited by the lack of an efficient delivery system. Until recently, due to the wavelength characteristics of CO<sub>2</sub> lasers articulated arms with mirrors or lenses attached to them and optical fibers that were hard to pass through gastrointestinal endoscope channels were the only devices that could be used to perform CO<sub>2</sub> laser treatment in the gastrointestinal tract. However, flexible optical fibers that can be passed through gastrointestinal endoscope channels have since been developed for CO<sub>2</sub> lasers [18], so it has become possible to use CO<sub>2</sub> lasers for endoscopic procedures in the gastrointestinal tract. Anandasabapathy et al. [19] described the endoscopic ablation of the esophagus using a CO<sub>2</sub> laser in an *in vivo* porcine model. In this study, we have developed a safe ESD procedure involving the use of a CO<sub>2</sub> laser.

In standard ESD procedures, a solution is injected into the submucosa to lift it in order to ease its resection, to keep it a suitable distance from the muscularis propria, and to protect the muscularis propria from thermal and mechanical injury, thereby decreasing the risk of perforation. Compared with most other lasers, a large amount of the energy produced by CO<sub>2</sub> lasers is absorbed by water and soft tissue [17]. It was hypothesized that if a solution that could absorb the energy of CO<sub>2</sub> lasers could be injected into the submucosa, the energy of the CO<sub>2</sub> laser would be immediately absorbed, and hence, would not reach the muscularis propria. Previous studies have demonstrated that injecting a light absorbent solution into the submucosa and using a laser whose energy is specifically absorbed by the solution protects the muscularis propria from laser irradiation. In dogs that underwent laparotomy, Hayashi et al. [20] reported that when diode laser ablation was performed after the injection of indocyanine green (ICG) solution into the submucosa, the ablation did not extend beyond the proper muscularis propria of the gastric wall. In clinical practice, endoscopic laser treatment involving the injection of ICG

solution for early gastric cancer has been reported [21]. In these reports, an 805-nm laser and ICG solution were used. The energy of the 805-nm laser was strongly absorbed by the ICG solution, which has a specific absorption spectrum peak at a wavelength of 805 nm. CO<sub>2</sub> lasers are capable of precisely cutting tissue whilst causing limited injury to the surrounding tissue [12–14], because their energy is strongly absorbed by water and protein and hardly penetrates deeper tissues [15]; thus, CO<sub>2</sub> lasers are suitable for making sharp incisions. In this study, we used a CO<sub>2</sub> laser and saline, which is widely used in standard ESD procedures, as a CO<sub>2</sub> laser absorbent.

To provide proof of concept for CO<sub>2</sub> laser-based ESD, we performed an *ex vivo* study to investigate whether injecting a light absorbent solution into the submucosa would prevent the muscularis propria from being injured by laser irradiation. First, a preliminary study was performed to determine the optimal laser output power level for ESD. Then, to determine the appropriate incision speed, we measured the speed of the mucosal incisions produced during the resection of a porcine stomach with an electro-surgical knife. As a result, we found that the mean incision speed was ~1.0 mm/s (data not shown). Next, we performed a mucosal incision experiment in which a porcine stomach was resected using a CO<sub>2</sub> laser. Based on the abovementioned results, the mucosal incision speed was set to 0.5, 1.0, or 2.0 mm/s and the output power was set to 6.0, 8.0, or 10.0 W during this experiment. In the group in which no laser absorbent was injected into the submucosa, when an output power of 6.0 W was employed the ablation did not reach the submucosa at an incision speed of 2.0 mm/s (the fastest incision speed), but it did reach the muscularis propria when an incision speed of 1.0 mm/s was used, and the incision penetrated all of the layers at a speed of 0.5 mm/s (the slowest incision speed). On the other hand, in the group in which saline was injected into the submucosa, the ablation stopped in the submucosa when output powers of 6.0, 8.0, and 10.0 W were employed together with a 0.5 mm/s incision speed, and furthermore, the ablation did not reach the muscularis propria or injure the muscularis propria when an output level of 12 W was used. These results showed that the saline injected into the submucosa absorbed the energy of the laser and prevented the muscularis propria from being injured.

Next, to investigate whether CO<sub>2</sub> laser-based ESD is feasible, an *ex vivo* study was performed. A resected porcine stomach was subjected to five ESD procedures involving a CO<sub>2</sub> laser. Based on the results of the preliminary study, the output power of the laser was set at 10 W. All of the procedures were accomplished without perforation or damaging the muscularis propria, and visual evaluations of each resection site were performed after the procedure. The heat damage caused by the laser was

sufficiently minimal to allow the resected specimens to be histologically evaluated. These results suggest that ESD using a CO<sub>2</sub> laser is feasible. However, *ex vivo* studies are limited by the fact that no bleeding occurs. Bleeding is one of the most common complications of ESD and can distort the endoscopic view and make it difficult to perform the procedure safely and quickly.

Therefore, an *in vivo* porcine study was performed to further investigate whether ESD using a CO<sub>2</sub> laser is feasible. In this procedure, we were able to obtain mucosal tissue samples without damaging the muscularis propria under the resected area. There were no complications (including bleeding) during the procedure, and the heat damage caused by the incision and dissection was minimal. These results suggest that the submucosal injection of saline or sodium hyaluronate makes ESD performed with a CO<sub>2</sub> laser safe. Moreover, using a laser knife for ESD requires less skill than performing the procedure with an electro-surgical knife.

Endoscopic submucosal dissection using a CO<sub>2</sub> laser with a submucosally injected laser absorbent might be a feasible method for the treatment of early gastric cancer, and it might be easier and safer than the conventional method using an electro-surgical knife.

**Acknowledgments** The authors are grateful to Satoshi Watanabe and Keiichiro Yamada, Division of Sustainable Energy and Environmental Engineering, Graduate School of Engineering, Osaka University for their important contributions to the experiments. This work was supported, in part, by grants for the Global COE Program “Global Center of Excellence for Education and Research on Signal Transduction Medicine in the Coming Generation” from the Ministry of Education, Culture, Sports, Science, and Technology of Japan and grants from the Ministry of Education, Culture, Sports, Science, and Technology of Japan, the Foundation of Advancement of International Science, and the Ministry of Health, Labour and Welfare of Japan.

**Disclosures** Drs. Daisuke Obata, Yoshinori Morita, Rinna Kawaguchi, Katsunori Ishii, Hisanao Hazama, Kunio Awazu, Hiromu Kutsumi, and Takeshi Azuma have no conflicts of interest or financial ties to disclose.

## References

1. Soetikno R, Gotoda T, Nakanishi Y, Soehendra N (2003) Endoscopic mucosal resection. *Gastrointest Endosc* 57:567
2. Korenaga D, Haraguchi M, Tsujitani S, Okamura T, Tamada R, Sugimachi K (1986) Clinicopathological features of mucosal carcinoma of the stomach with lymph node metastasis in eleven patients. *Br J Surg* 73:431–433
3. Tanabe S, Koizumi W, Mitomi H, Nakai H, Murakami S, Nagaba S, Kida M, Oida M, Saigenji K (2002) Clinical outcome of endoscopic aspiration mucosectomy for early stage gastric cancer. *Gastrointest Endosc* 56:708–713
4. Ono H, Kondo H, Gotoda T, Shirao K, Yamaguchi H, Saito D, Hosokawa K, Shimoda T, Yoshida S (2001) Endoscopic mucosal resection for treatment of early gastric cancer. *Gut* 48:225

5. Ohkuwa M, Hosokawa K, Boku N, Ohtu A, Tajiri H, Yoshida S (2001) New endoscopic treatment for intramucosal gastric tumors using an insulated-tip diathermic knife. *Endoscopy* 33:221–226
6. Fujishiro M (2006) Endoscopic submucosal dissection for stomach neoplasms. *World J Gastroenterol* 12:5108
7. Hirao M, Masuda K, Asanuma T, Naka H, Noda K, Matsuura K, Yamaguchi O, Ueda N (1988) Endoscopic resection of early gastric cancer and other tumors with local injection of hypertonic saline-epinephrine. *Gastrointest Endosc* 34:264–269
8. Toyonaga T, Nishino E, Hirooka T, Dozaiku T, Sugiyama T, Iwata Y, Ono W, Ueda C, Tomita M (2005) Use of short needle knife for esophageal endoscopic submucosal dissection. *Dig Endosc* 17:246–252
9. Oyama T, Kikuchi Y (2002) Aggressive endoscopic mucosal resection in the upper GI tract-hook knife EMR method. *Minim Invasive Ther Allied Technol* 11:291–296
10. Strauss R, Fallon S (2004) Lasers in contemporary oral and maxillofacial surgery. *Dent Clin N Am* 48:861
11. Patel C (1964) Selective excitation through vibrational energy transfer and optical maser action in  $N_2-CO_2$ . *Phys Rev Lett* 13:617–619
12. Strong M, Jako G (1972) Laser surgery in the larynx. Early clinical experience with continuous  $CO_2$  laser. *Ann Otol Rhinol Laryngol* 81:791
13. Anderson R, Parrish J (1983) Selective photothermolysis: precise microsurgery by selective absorption of pulsed radiation. *Science* 220:524
14. Brugmans M, Kemper J, Gijsbers G, van der Meulen F, van Gemert M (1991) Temperature response of biological materials to pulsed non-ablative  $CO_2$  laser irradiation. *Lasers Surg Med* 11:587–594
15. Burke L, Rovin R, Cerullo L, Brown J (1985) Thermal effects of the Nd:YAG and carbon dioxide lasers on the central nervous system. *Lasers Surg Med* 5:67–71
16. Kotlow LA (2004) Lasers in pediatric dentistry. *Dent Clin N Am* 48:889–922
17. LeCarpentier G, Motamedi M, McMath L, Rastegar S, Welch A (1993) Continuous wave laser ablation of tissue: analysis of thermal and mechanical events. *IEEE Trans Biomed Eng* 40:188–200
18. Shi Y, Wang Y, Abe Y, Matsuura Y, Miyagi M, Sato S, Taniwaki M, Uyama H (1998) Cyclic olefin polymer-coated silver hollow glass waveguides for the infrared. *Appl Opt* 37:7758–7762
19. Anandasabapathy S, Maru D, Klumpp S, Uthamanthil R, Borne A, Bhutani M (2009) Novel endoscopic application of a new flexible-fiber  $CO_2$  laser for esophageal mucosal ablation in a porcine model. *Endoscopy* 41:138–142
20. Hayashi T, Arai T, Tajiri H, Niwa H (1997) Enhanced diode laser ablation using submucosal injection of indocyanine green solution: part II; irradiation to resected porcine gastric wall and canine gastric walls under laparotomy. *Gastroenterol Endosc* 39:1753–1765
21. Kawaguchi A, Nagao S, Takebayashi K, Higashiyama M, Komoto S, Hokari R, Miura S (2008) Long-term outcome of endoscopic semiconductive diode laser irradiation therapy with injection of indocyanine green for early gastric cancer. *J Gastroenterol Hepatol* 23:1193–1199

# Evaluation of the Bending Loss of the Hollow Optical Fiber for Application of the Carbon Dioxide Laser to Endoscopic Therapy

Daisuke Kusakari<sup>1</sup>, Hisanao Hazama<sup>1</sup>, Rinna Kawaguchi<sup>1</sup>, Katsunori Ishii<sup>1</sup>, Kunio Awazu<sup>1,2,3</sup>

<sup>1</sup>Graduate School of Engineering, Osaka University, Osaka, Japan

<sup>2</sup>Graduate School of Frontier Biosciences, Osaka University, Osaka, Japan

<sup>3</sup>The Center for Advanced Medical Engineering and Informatics, Osaka University, Osaka, Japan

Email: awazu@see.eng.osaka-u.ac.jp

Received April 29, 2013; revised June 30, 2013; accepted August 3, 2013

Copyright © 2013 Daisuke Kusakari *et al.* This is an open access article distributed under the Creative Commons Attribution License, which permits unrestricted use, distribution, and reproduction in any medium, provided the original work is properly cited.

## ABSTRACT

Since carbon dioxide laser is excellent for incision, hemostasis, coagulation, and vaporization of soft tissues, it has been widely applied in clinical treatments as the laser knife. In these days, flexible thin hollow optical fibers transmitting mid-infrared light have been developed, and the application of carbon dioxide laser to endoscopic therapy has become possible. However, it is expected that the irradiation effect is influenced by the change in the laser power at the tip of the hollow optical fiber due to the change in the transmittance by the bending loss. The purpose of this research is to quantitatively evaluate the change in the output power and therapeutic effect by bending the hollow optical fiber in a gastrointestinal endoscope. The change in the transmittance of the hollow optical fiber due to the insertion of the fiber into the endoscope and bending of the head of the endoscope was measured. Then, the relationship between the irradiated laser power and the incision depth for a porcine stomach was investigated. As the results, the most significant decrease in the transmittance of the hollow optical fiber was caused by the insertion of the fiber into the instrument channel of the endoscope, and bending of the head of the endoscope with the angle of 90° decreased the output laser power and incision depth by 10% and 25%, respectively. Therefore, it was confirmed that the bending loss of the hollow optical fiber due to the bending of the head of the endoscope had no significant influence on the endoscopic therapy using the carbon dioxide laser.

**Keywords:** Hollow Optical Fiber; Carbon Dioxide Laser; Bending Loss; Endoscopic Therapy

## 1. Introduction

Since carbon dioxide laser with the wavelength of 10.6  $\mu\text{m}$  is absorbed strongly by water, which is contained about 70% in biological soft tissues, it is excellent in incision, hemostasis, coagulation, and vaporization of the soft tissues [1,2]. In fact, carbon dioxide laser is widely efficient for medical field, e.g., plastic surgery, cosmetic surgery, otolaryngology, and dentistry. Even in the endoscopic surgery, carbon dioxide laser had various promising application, so that many researchers developed new techniques for clinical treatment [3,4]. At the same time, several kinds of optical fibers transmitting mid-infrared light have been developed. These optical fibers are classified broadly into three categories, *i.e.*, glasses composed of fluoride or oxide, special glasses such as chalcogenide, and polycrystalline materials such as metal halide [5]. However, these optical fibers have problems

in terms of the mechanical and chemical properties, toxicity, manufacturing cost, etc. Therefore, they could not be used for medical purposes. Recently, hollow optical fibers with a dielectric coating made of cyclic olefin polymer (COP) inside a cylindrical metal waveguide have been developed as shown in **Figure 1** [6]. Since the core of the hollow optical fibers is air or other gases with a high transmittance at the wavelength of the carbon dioxide laser, extremely low absorption loss could be obtained [7]. Because the reflection loss at the end surface of the fiber and related damage do not occur, the hollow optical fibers are suitable to transmit high-power lasers. In addition, the hollow optical fiber shown in **Figure 1** can simultaneously transmit carbon dioxide laser and visible aiming laser. Although it is possible to enhance the reflectance of the inner surface to nearly 100% by designing the COP layer thickness according to the wave-

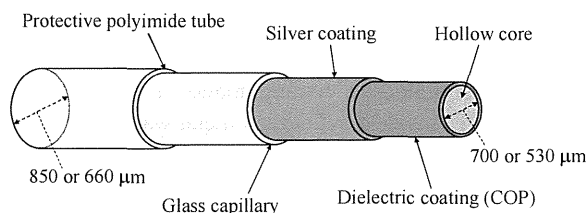
length of the transmitting laser light, the leaking loss to the outside of the fiber can not be eliminated in principle. Therefore, by bending the hollow optical fiber, the transmittance decreases due to the increase in the number of reflection per unit length and decrease in the reflectance in the fiber. When the hollow optical fiber is used in a clinical treatment with an endoscope, it is inferred that output laser power and therapeutic effect are changed due to the change in the transmittance of the hollow optical fiber caused by the bending of the endoscope. The purpose of this research is to quantitatively evaluate the change in the output laser power and therapeutic effect caused by bending the hollow optical fiber in a gastrointestinal endoscope.

## 2. Materials and Methods

### 2.1. Transmittance of the Hollow Optical Fiber with Bending of the Endoscope

In this research, a carbon dioxide laser system modified from a commercial laser system for dental treatment and so on (COM-2, J. Morita Manufacturing Corp., Kyoto, Japan) was used. The laser was operated in the continuous wave mode, and the maximum output power of the laser oscillator was 30 W. Two types of the hollow optical fiber (J. Morita Manufacturing Corp.) listed in **Table 1** were used to deliver the carbon dioxide laser through a gastrointestinal endoscope (GIF-2T200, Olympus Corp., Tokyo, Japan) shown in **Figure 2**. A laser power meter (30-A-BB-18, Ophir Optronics, Israel) was used to measure the laser power.

The carbon dioxide laser, the visible aiming laser with a wavelength of 650 nm, and air were simultaneously transmitted through the hollow optical fiber. Input and output powers of the hollow optical fibers were measured under four different conditions as shown in **Figure 3**, and each condition was described as follows:



**Figure 1.** Schematic of the hollow optical fiber used in this research.

**Table 1.** Specifications of the hollow optical fibers.

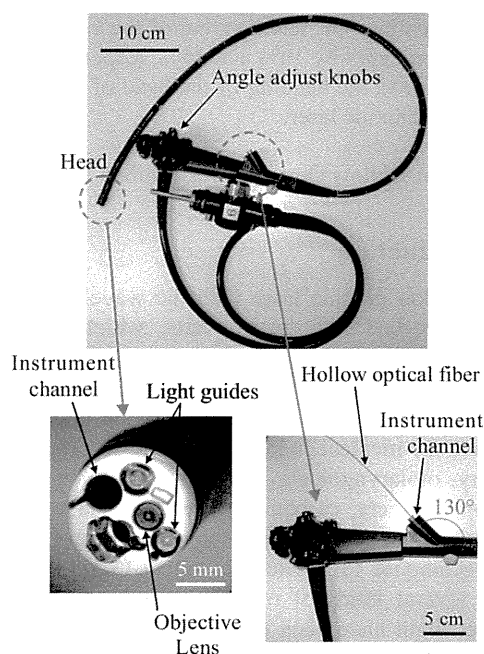
	Outer diameter ( $\mu\text{m}$ )	Inner diameter ( $\mu\text{m}$ )	Length $l$ (cm)
L-1	850	700	250
L-2	850	700	260
S-1	660	530	260

- I. The hollow optical fiber was kept straight without insertion to the endoscope.
- II. The hollow optical fiber was inserted into the endoscope, and endoscope was kept straight.
- III. In addition to the condition II, the middle part of the endoscope was gradually bent  $90^\circ$  with a radius  $r_1 = 50$  cm.
- IV. In addition to the condition III, the head of the endoscope was steeply bent  $90^\circ$  with a radius  $r_2 = 5$  cm.

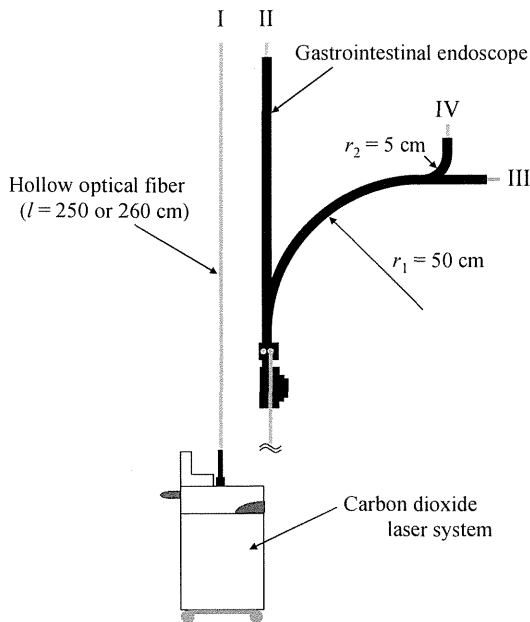
### 2.2. Dependence of the Output Laser Power and Incision Depth on the Bending of the Head of the Endoscope

By assuming the case where the endoscope is used in transoral surgery, the middle part of the endoscope was bent  $90^\circ$  with a radius  $r_1 = 50$  cm, and the tip of the hollow optical fiber L-1 was bent with various angles and radii  $r_2$  as listed in **Table 2**. To avoid the accidental damage to the endoscope due to the break of the hollow optical fiber during laser irradiation, the fiber was ejected about 15 cm from the head of the endoscope, and only the fiber was bent by using in-house guide plates made of foamed polystyrene in order to simulate the bending conditions of the head of the endoscope.

A segment of a porcine stomach was set on a motorized linear stage (SGSP20-20, SIGMA KOKI Co., Ltd., Tokyo, Japan) and moved at a constant speed of 1.0 mm/s during laser irradiation for a time of 20 s. The car-



**Figure 2.** The photographs of the endoscope and its head and instrument channel. The hollow optical fiber is steeply bent  $130^\circ$  just after the insertion to the instrument channel.



**Figure 3.** Schematics of the measurement of the transmittance of the hollow optical fibers for various bending conditions.

bon dioxide laser was irradiated vertically to the surface of the mucosa from a distance of 2 mm. The setting power of the carbon dioxide laser system was set at 3, 5, and 8 W, and laser power transmitted through the hollow optical fiber was measured under each condition. To simulate the *in vivo* environment, the sample surface was kept wet by pouring saline on the sample at a rate of 120 mL/h using a micro syringe pump (IC3100, AS ONE, Osaka, Japan). After laser irradiation, each sample was stored at  $-80^{\circ}\text{C}$  and was sliced to a thickness of 10  $\mu\text{m}$  by using a cryostat microtome (CM1850, Leica Microsystems, Wetzlar, Germany) at a temperature of  $-20^{\circ}\text{C}$ . Then, each sample section attached onto a glass slide was stained with hematoxylin and eosin (HE) staining and observed using a high-resolution slide scanner (NanoZoomer 2.0 RS, Hamamatsu Photonics K. K., Shizuoka, Japan).

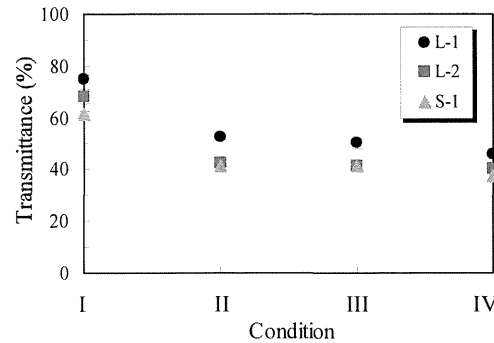
### 3. Results and Discussion

#### 3.1. Transmittance of the Hollow Optical Fiber with Bending of the Endoscope

Figure 4 shows the transmittance of the hollow optical fibers under each condition. When the hollow optical fiber was inserted into the instrument channel of the endoscope (from the condition I to II), the transmittance of the fiber L-1, L-2, and S-1 decreased by 29%, 28%, and 24%, respectively. On the other hand, the transmittance was not significantly decreased by the bending of the endo-

**Table 2.** Conditions for the measurement of the dependence of the output laser power and incision depth on the bending of the head of the endoscope.

Bending angle ( $^{\circ}$ )	0	30	60	90
Bending radius $r_2$ (cm)	-	11.0	7.0	5.0



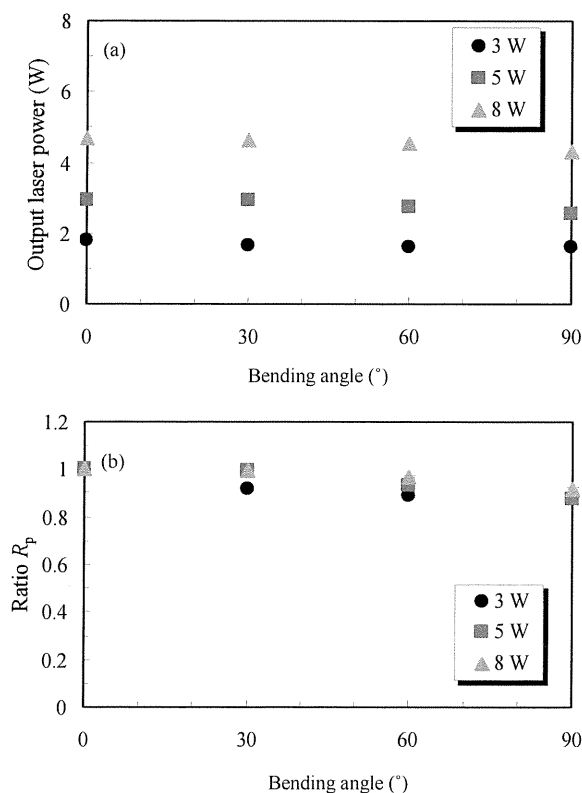
**Figure 4.** Transmittance of the hollow optical fibers under each condition.

scope. When the bending of the endoscope was changed from the condition II to IV, the transmittances of the fibers L-1, L-2, and S-1 decreased by 7, 3, and 4%, respectively. Therefore, it was found that the decrease in the transmittance of the hollow optical fiber due to the insertion into the instrument channel was the most dominant loss in the hollow optical fibers. It is suggested that these results are caused by the steep bending of  $130^{\circ}$  just after the insertion into the instrument channel as shown in Figure 2.

#### 3.2. Dependence of the Output Laser Power and Incision Depth on the Bending of the Head of the Endoscope

Figure 5 shows the relationships between the bending angle of the tip of the hollow optical fiber and the output laser power. The output laser power gradually decreased with the increase in the bending angle of the tip of the hollow optical fiber, and the output laser power at  $90^{\circ}$  was about 10% lower than that for  $0^{\circ}$ .

Figure 6 shows the photomicrographs of the cross sections of the HE stained porcine stomach samples after laser irradiation with each condition. Figure 7 shows the relationships between the bending angle of the tip of the hollow optical fiber and the incision depth measured from the photomicrographs of the sample shown in Figure 6. The incision depth under each condition decreased by up to 25% compared to that for  $0^{\circ}$  with an exception for the condition of 8 W at  $90^{\circ}$ . Therefore, it was confirmed that the bending loss of the hollow optical fiber due to the bending of the head of the endoscope had no significant influence on the endoscopic therapy using the carbon dioxide laser.

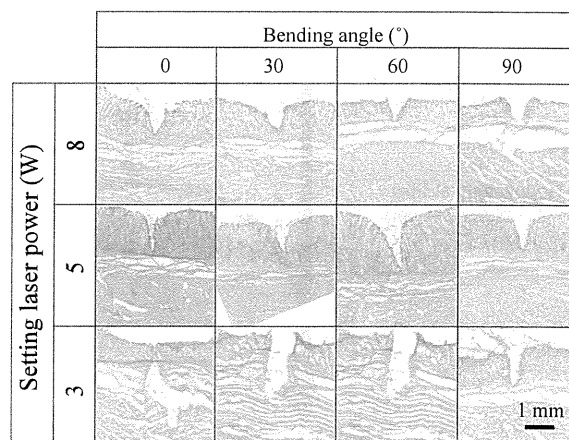


**Figure 5.** The relationships between (a) the bending angle of the head of the endoscope and the output laser power and (b) the bending angle and the ratio  $R_p$  of the output laser power to that for  $0^\circ$ .

The mechanism of the vaporization of the biological soft tissue by a laser knife is described as follows: When the biological soft tissue absorbs the laser, the temperature of the tissue quickly rises within a time of microseconds. Since the boiling point of water is  $100^\circ\text{C}$ , water in tissue is immediately vaporized and the volume is expanded by continuously making water in the tissue over  $100^\circ\text{C}$ . Then, cell membrane and organelle fragment are vaporized. In our experiment, laser was linearly scanned with a speed of  $1.0\text{ mm/s}$ , incision was performed using the vaporization. In order to describe the relationship between the irradiated laser energy density and the incision depth, the steady-state model has been proposed [8,9]. This model was developed for continuous ablation process using a continuous wave or pulsed laser with microseconds or longer pulse width. In the steady-state model, the relational expression between the incision depth  $\delta$  (mm) and the irradiated laser energy density  $\Phi_0$  ( $\text{J/mm}^2$ ) is given by

$$\delta = \frac{\Phi_0 - \Phi_{th}}{\rho h_{abl}}, \quad (1)$$

where  $\rho = 1.02 \times 10^{-3}\text{ g/mm}^3$  is the density of biological



**Figure 6.** Photomicrographs of the HE stained samples after laser irradiation with each condition.

soft tissue composed of water of 70%, and the ablation enthalpy  $h_{abl}$  (J/g) and the ablation threshold energy density  $\Phi_{th}$  ( $\text{J/mm}^2$ ) are defined as follows:

$$h_{abl} = C\Delta T + L,$$

$$\Phi_{th} = \frac{\rho h_{abl}}{\mu_a},$$

where  $C = 3.45\text{ J/(g}\cdot\text{K)}$  is the heat capacity,  $\Delta T = 63.0\text{ K}$  is the temperature rise to the boiling point of water,  $L = 2.58 \times 10^3\text{ J/g}$  is the heat of vaporization, and  $\mu_a = 6.15 \times 10^2\text{ mm}^{-1}$  is the absorption coefficient of the porcine mucosa at the wavelength of  $10.6\text{ }\mu\text{m}$  [10-12]. In **Figure 8**, the dots show the relationship between the irradiated laser energy density and the incision depth obtained from the results in **Figures 5** and **7**, and the solid line represents the theoretical values estimated using Equation (1). The laser beam diameter at the surface of the porcine stomach mucosa was measured for the fiber L-1 by using knife-edge method and was about 710, 712, 772, and  $740\text{ }\mu\text{m}$  at the bending angle of  $0^\circ$ ,  $30^\circ$ ,  $60^\circ$ , and  $90^\circ$ , respectively. The laser beam diameter was increased with the increase in the bending angle, because the beam spread angle from the exit of the hollow optical fiber was increased with the increase in the bending angle due to the conversion of the propagation mode from the low-order modes to the high-order modes in the hollow optical fiber.

From the results in **Figure 8**, it was found that both the experimental and theoretical values have similar correlations between the irradiated laser energy density and the incision depth. However, the theoretical values were about 1.5 times higher than the experimental values. It is inferred that the principal factor for this difference is the uncertainty in the physical values used in the model calculations, e.g., the density of biological soft tissue, ablation enthalpy, and the heat capacity. Since these values

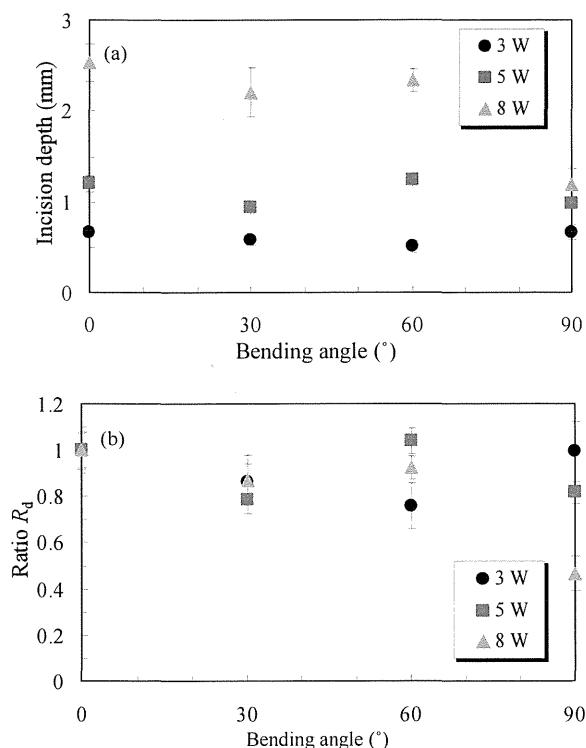


Figure 7. The relationships between (a) the bending angle of the tip of the hollow optical fiber and incision depth and (b) the bending angle and the ratio  $R_d$  of the incision depth to that for 0°.

were taken from the literatures, some values might not be suitable for the porcine stomach sample used in this research.

#### 4. Conclusion

The change in the output power of the carbon dioxide laser and therapeutic effect by bending the hollow optical fiber inserted in a gastrointestinal endoscope was quantitatively evaluated. The change in the transmittance of the hollow optical fiber due to the insertion of the fiber to the endoscope and bending of the head of the endoscope was measured. Then, the relationship between the irradiated laser power and the incision depth of a porcine stomach was investigated. As the result, the greatest decrease of the transmittance of the hollow optical fiber was caused by insertion of the fiber into the instrument channel of the endoscope, and bending of the head of the endoscope with the angle of 90° decreased the output laser power and incision depth by no more than 10% and less than 25%, respectively. Therefore, it was confirmed that the bending loss of the hollow optical fiber due to the bending of the head of the endoscope had no significant influence on the endoscopic therapy using the carbon dioxide laser.

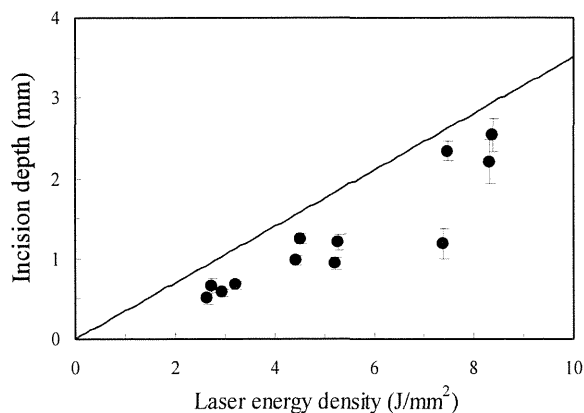


Figure 8. The relationships between the incision depth and irradiated laser energy density, where the solid line shows the theoretical values estimated with the steady-state model.

#### 5. Acknowledgements

We thank Haruhiko Murakami, Katsumi Hiyoshi, Akihito Hongo, and Yoshihide Okagami of J. Morita Manufacturing Corp. for their technical supports. This work was supported by Health Labour Science Research Grant of the Ministry of Health Labour and Welfare of Japan.

#### REFERENCES

- [1] J. T. Walsh and T. F. Deutsch, "Er:YAG Laser Ablation of Tissue: Measurement of Ablation Rates," *Lasers in Surgery and Medicine*, Vol. 9, No. 4, 1989, pp. 327-337. doi:10.1002/lsm.1900090404
- [2] J. T. Walsh, T. J. Flotte, R. R. Anderson and T. F. Deutsch, "Pulsed CO<sub>2</sub> Laser Tissue Ablation: Effect of Tissue Type and Pulse Duration on Thermal Damage," *Lasers in Surgery and Medicine*, Vol. 8, No. 2, 1988, pp. 108-118. doi:10.1002/lsm.1900080204
- [3] K. Ishii, S. Watanabe, D. Obata, H. Hazama, Y. Morita, Y. Matsuoka, H. Kutsumi, T. Azuma and K. Awazu, "Selective Mucosal Ablation Using CO<sub>2</sub> Laser for the Development of Novel Endoscopic Submucosal Dissection: Comparison of Continuous Wave and Nanosecond Pulsed Wave," *Proceedings of SPIE*, Vol. 7562, 2010, Article ID: 75620Q. doi:10.1117/12.842426
- [4] S. R. Browd, J. Zauberman, M. Karandikar, J. G. Ojemann, A. M. Avellino and R. G. Ellenbogen, "A New Fiber-Mediated Carbon Dioxide Laser Facilitates Pediatric Spinal Cord Detethering," *Journal of Neurosurgery: Pediatrics*, Vol. 4, No. 3, 2009, pp. 280-284. doi:10.3171/2009.4.PEDS08349
- [5] Y. Matsuura, "Basics of Optical Fibers for Medical Applications," *The Journal of Japan Society for Laser Surgery and Medicine*, Vol. 31, No. 4, 2011, pp. 407-412 (in Japanese).
- [6] Y. Abe, Y. W. Shi, Y. Matsuura and M. Miyagi, "Flexible Small-Bore Hollow Fibers with an Inner Polymer Coating," *Optics Letters*, Vol. 25, No. 3, 2000, pp. 150-152. doi:10.1364/OL.25.000150



- [7] Y. Matsuura, "Basics of Hollow Optical Fiber," *Medical Photonics*, No. 2, 2010, pp. 11-15 (in Japanese). doi:10.1002/lsm.1128
- [8] A. Vogel and V. Venugopalan, "Mechanisms of Pulsed Laser Ablation of Biological Tissues," *Chemical Reviews*, Vol. 103, No. 2, 2003, pp. 577-644. doi:10.1021/cr010379n
- [9] M. H. Niemz, "Laser-Tissue Interactions: Fundamentals and Applications," Springer, Berlin, 1996, pp. 58-87. doi:10.1007/978-3-662-03193-3
- [10] B. Choi and A. J. Welch, "Analysis of Thermal Relaxation during Laser Irradiation of Tissue," *Lasers in Surgery and Medicine*, Vol. 29, No. 4, 2001, pp. 351-359.
- [11] V. Venugopalan, N. S. Nishioka and B. B. Mikic, "Thermodynamic Response of Soft Biological Tissues to Pulsed Infrared-Laser Irradiation," *Biophysical Journal*, Vol. 70, No. 6, 1996, pp. 2981-2993. doi:10.1016/S0006-3495(96)79868-5
- [12] D. Obata, Y. Morita, R. Kawaguchi, K. Ishii, H. Hazama, K. Awazu, H. Kutsumi and T. Azuma, "Endoscopic Submucosal Dissection Using a Carbon Dioxide Laser with Submucosally Injected Laser Absorber Solution (Porcine Model)," *Surgical Endoscopy*, 2013, in Press. doi:10.1007/s00464-013-3029-x

