

天異常症候群第 2 版（下），日本臨牀社，
721-726, 2012.

2. 学会発表

古庄知己、清水健司、岡本伸彦、三宅紀子、大橋博文、松本直通、福嶋義光. D4ST1 欠損に基づく Ehlers-Danlos 症候群の診断基準および健康管理指針の構築. 第 35 回日本小児遺伝学会（平成 24 年 4 月 19 日 於 久留米大学筑水会館、久留米）.

古庄知己、福嶋義光、三宅紀子、松本直通、水本修二、菅原一幸、坂翔太、野村義宏、岳鳳鳴、佐々木克典、中山淳、岡田尚巳、武田伸一. デルマトン 4-O-硫酸基転移酵素-1 の欠損による新型 Ehlers-Danlos 症候群の発見、疾患概念の確立、遺伝子治療の開発. 第 110 回信州整形外科懇談会（平成 24 年 8 月 18 日 於 信州大学医学部附属病院）.

岳鳳鳴、古庄知己、滝澤 佐季子、吉江 進、増田 章子、森崎 美圭、横山 忠幸、友常 大八郎、佐々木 克典. Patient-specific iPSC cell-derived neurons of DD-EDS syndrome. 第 12 回日本再生医療学会総会（平成 24 年 3 月 21～23 日 於 パシフィコ横浜）.

Kosho T, Mizumoto S, Kobayashi M, Fujita Y, Nakayama J, Miyake N, Nomura Y, Hatamochi A, Fukushima Y, Sugahara K, Matsumoto N. Pathophysiological features of dermatan 4-O-sulfotransferase 1 (D4ST1)-deficient Ehlers-Danlos syndrome (DD-EDS). American Society of Human Genetics 62nd Annual Meeting, San Francisco, Nov 6-10, 2012.

招待講演「デルマトン硫酸 4-O-硫酸基転移酵素（D4ST-1）欠損による新型エーラスダンロス症候群の発見および疾患概念の確立～根治療法の開発をめざして～」古庄知己 国立精神・神経医療研究センター神経研究所 所内セミナー（平成 24 年 4 月 20 日 於 研究所 3 号館セミナールーム、小平）.

招待講演「整形外科疾患は遺伝性・先天性疾患

の宝庫～代表的疾患から古庄型 EDS まで～」古庄知己 信州大学医学部整形外科学教室・整形外科セミナー（平成 24 年 9 月 3 日 於 信州大学医学部附属病院）.

招待講演「デルマトン硫酸 4-O-硫酸基転移酵素（D4ST-1）欠損による新型エーラスダンロス症候群の発見および疾患概念の確立」古庄知己 第 36 回日本遺伝カウンセリング学会学術集会・市民公開シンポジウム（平成 24 年 6 月 9 日～10 日 於 信州大学医学部附属病院、松本）

招待講演「EDS の臨床～基本的なこと、新しいこと～」古庄知己 2012 年度 JEFA 総会（2012/6/30、於 横浜市浦舟地域ケアプラザ）

H. 知的財産権の出願・登録状況

なし

厚生労働科学研究費補助金（難治性疾患等克服研究事業）
大動脈疾患症例の実態解明・効果的な進行予防・治療を目的とした
全国的統一基盤システムの構築と研究
分担研究年度終了報告書

臨床研究協力体制の整備
JACVSD・NCDを基にした大動脈手術症例の前向き検討に向けて

研究分担者 澤城大悟 東京大学医学部附属病院循環器内科

研究要旨

動脈瘤・大動脈解離は発症すれば極めて死亡率が高く、またその死亡者数は増加傾向にあるにもかかわらずあまり注目されていない。非マルファン症候群症例における大動脈瘤・解離についてはその遺伝子異常、発症病態等についてほとんど情報が得られていないのが現実である。これら大動脈解離・大動脈瘤の中には遺伝的要素の強い家族集積性を認める大動脈瘤・大動脈解離の症例・家系があり、発症メカニズムのモデルとしてその遺伝子異常の解析や遺伝・発症形態の解析は多くの情報をもたらすことが予想される。さらに同疾患群には外科治療が最終治療手段となることも多い。しかしながら日本におけるそれら症例・家系についての解析は少数の限られた症例報告が多く遺伝形態の本態や治療に対する反応、予後についての情報は得られ難い状況となっている。また大動脈疾患による死亡率は8.5人/10万人程度であり各医療施設単体での年間集積症例数はそれ程多くはなく、本症候群の本態の把握には症例・家系の集積とその継続的な経過追跡・解析を行う為の共通基盤の整備が必須と考えられている。現在既に、平成23年度より当データベースを利用し、後ろ向き研究として結合織疾患合併症例の大動脈手術に対してのリスク要因としての解析を行い、マルファン症候群・非マルファン症候群それぞれの特徴等有用な解析結果を得ている。今後、同研究を基に東京近在の主要大動脈手術施行病院を参加施設として前向きな症例登録・追跡の開始及び評価項目の拡充が必要と考えられる。本研究においては、日本成人血管外科データベース（JACVSD）での登録症例（後ろ向き及び前向き検討）において結合織疾患（遺伝素因）を有する大動脈瘤・解離症例・家系の集積とその継続的な経過追跡・解析を行う為のレジストリー構築を目的とした。対象疾患群の最も侵襲的治療としての外科治療成績・術前周術期状態を分析し、本疾患群の大動脈手術のリスク要因としての解析を前向き、多施設共同検討を開始している。

A. 研究目的

動脈瘤・大動脈解離は発症すれば極めて死亡率が高く、またその死亡者数は増加傾向にあるにもかかわらずあまり注目されていない。結合織異常のマルファン症候群は大動脈瘤・解離を合併する代表的な疾患であるが、同疾患については遺伝的背景の解析

が進んでいるものの非マルファン症候群症例における大動脈瘤・解離についてはその遺伝子異常、発症病態等についてほとんど情報が得られていないのが現実である。これら大動脈解離・大動脈瘤の中には遺伝的要素の強い家族集積性を認める大動脈瘤・大動脈解離の症例・家系があり、発症メカ

ニズムのモデルとしてその遺伝子異常の解析や遺伝・発症形態の解析は多くの情報をもたらすことが予想される。さらに同疾患群には外科治療が最終治療手段となることも多い。しかしながら日本におけるそれら症例・家系についての解析は少数に限られた症例報告が多く遺伝形態の本態や治療に対する反応、予後についての情報は得られ難い状況となっている。また大動脈疾患による死亡率は8.5人/10万人程度であり各医療施設単体での年間集積症例数はそれ程多くはなく、本症候群の本態の把握には症例・家系の集積とその継続的な経過追跡・解析を行う為の共通基盤の整備が必須と考えられる。現在既に、平成23年度より当データベースを利用し、後ろ向き研究として結合織疾患合併症例の大動脈手術に対してのリスク要因としての解析を行い、マルファン症候群・非マルファン症候群それぞれの特徴等有用な解析結果を得ている。同研究を基に東京近在の主要大動脈手術施行病院を参加施設として前向きな症例登録・追跡の開始及び評価項目の拡充が必要と考え、分担研究員志水秀行先生より JACVSD への前向き登録申請を行って頂き、同機構より許諾を得た。2012年5月、また2013年1月の班会議を経て、前向き検討内容について検討を重ね、今後、症例登録・dataの蓄積・解析を行っていく予定としている。

長期的には論文発表を行い、さらには、結合織疾患（遺伝的素因）を背景とした大動脈瘤・大動脈解離の共通基盤を基にしたレジストリー構築を目標とし、将来的に日本における大動脈瘤・大動脈解離のレジストリーとして発展させる。本疾患の生命的危険に至る前での早期発見、効果的な外科

的また薬物治療の選択・開発、効果的な経過観察の方法の抽出またサロゲートマーカー等の評価等に継げる事を最終的な目標としている。

B. 研究方法

対象：日本成人心血管外科手術データベース（JACVSD）登録症例のうち、2004年1月1日より2010年12月31日までの大動脈

（弁・基部）置換術・修復術を施行した遺伝的素因を有する大動脈瘤・解離症例であるマルファン症候群だけでなく、周辺疾患群として大動脈炎・川崎病・Behcet・その他の膠原病（エーラスダンロス症候群・ロイツディーツ症候群等も含める。

解析項目：年齢・性別・家族歴・併存疾患・発症状況・症状経過・血行動態・診断・施行術式・急性期および慢性期の薬物療法、CT・MRI・エコー所見による大動脈径変化、および術後合併症の発症状況・予後（全死亡・大動脈関連死亡・再入院）、L/D：血清クレアチニン、CRP、Hb。

C. 研究結果・D. 考察、E. 結論

現在、倫理委員会等手続き中。

F. 健康危険情報

なし

G. 研究発表

1. 論文発表

- 1). Sawaki D, Suzuki T.
Targeting Transforming Growth Factor- β Signaling in Aortopathies in Marfan Syndrome.
Circ J. 2013 Mar 25;77(4):898-9.

- 2). Suzuki T, Bossone E, Sawaki D, János RA, Erbel R, Eagle K, Nagai R.
Biomarkers of aortic diseases.
Am Heart J, 2013, 165(1):15-25.
- 3). 澤城大悟、鈴木亨、
特集『バイオマーカーupdate —診断から治療評価へ—』 「急性大動脈解離」
「ICUとCCU」, 2013, vol 37(1) 19-26
- 4). 澤城大悟、鈴木亨、
特集「循環器病のバイオマーカー」 2.
循環器疾患診療ツールとしてのバイオマーカー f. 大動脈解離・大動脈瘤,
Heart View, 2012, vol.16 No12(増刊号), 72-78

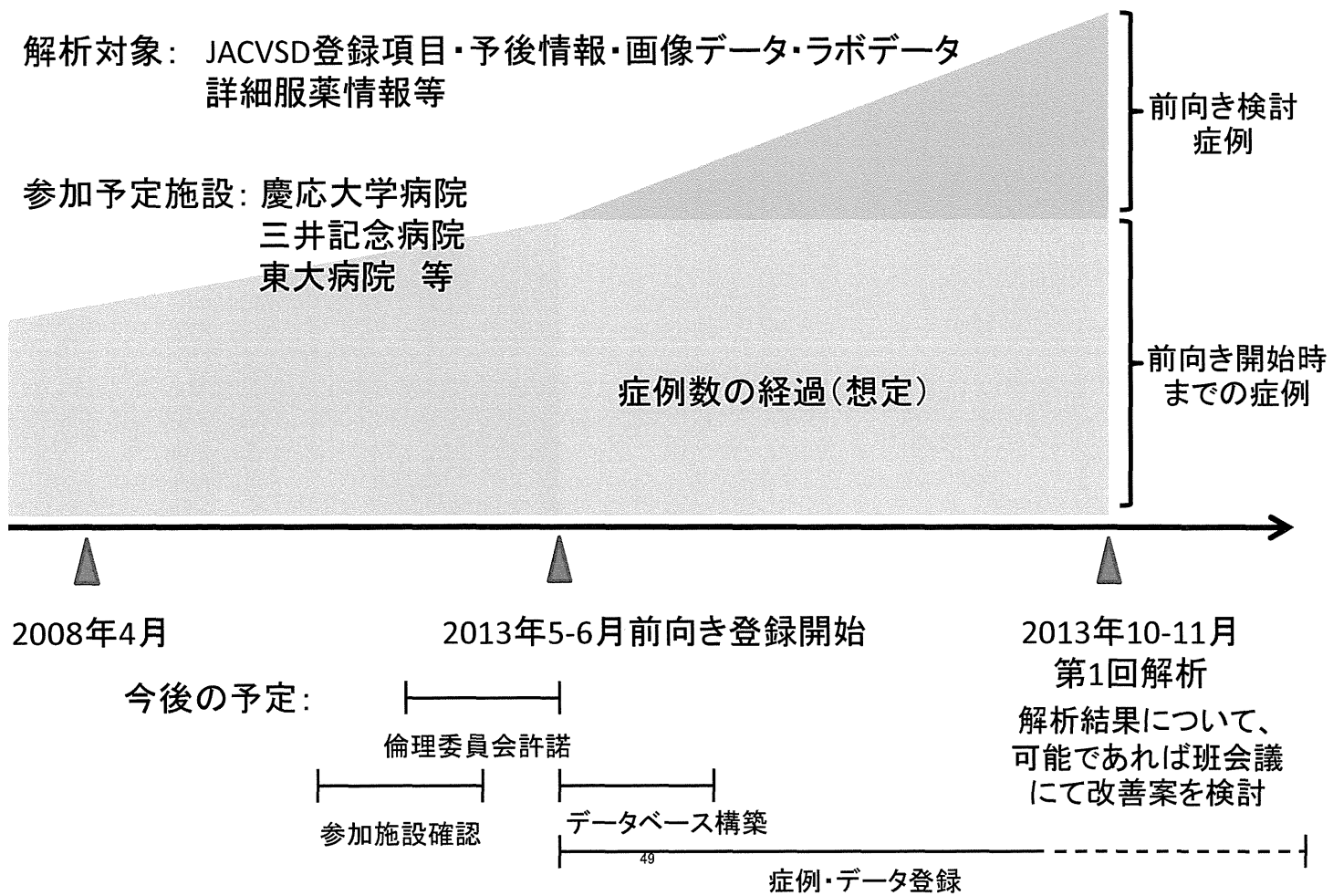
2. 学会発表
なし

H. 知的財産権の出願・登録状況

1. 特許取得
なし
2. 実用新案登録
なし
3. その他

なし

JACVSD・NCDを基にした大動脈手術症例の前向き検討(案)



研究成果の刊行に関する一覧表

書籍

著者氏名	論文タイトル名	書籍全体の編集者名	書籍名	出版社名	出版地	出版年	ページ
鈴木亨 澤城大悟、	特集『バイオマーカーupdate —診断から治療評価へ—』「急性大動脈解離」	清野精彦	「ICUとCCU」	医学図書出版	東京都	2013	19-26
鈴木亨 澤城大悟、	特集「循環器病のバイオマーカー」 2. 循環器疾患診療ツールとしてのバイオマーカー f. 大動脈解離・大動脈瘤、	井上晃男	Heart View	メジカルビュー	東京都	2012	72-78

雑誌

発表者氏名	論文タイトル名	発表誌名・刊号・ページ・出版年
Suzuki T, Sawaki D.	Targeting Transforming Growth Factor- β Signaling in Aortopathies in Marfan	<i>Circ J.</i> 2013 Mar 25;77(4):898-9.
Bossone E, Suzuki T, Eagle KA, Weinsaft JW.	Diagnosis of Acute Aortic Syndromes - Imaging and Beyond.	<i>Herz.</i> 2012 Dec 23. in press.
Suzuki T, Bossone E, Sawaki D, Jánosi RA, Erbel R, Eagle K, Nagai R.	Biomarkers of aortic diseases.	<i>Am Heart J.</i> 2013, 165(1):15-25.
Di Eusanio M, Trimarchi S, Patel HJ, Hutchison S, Suzuki T, Peterson MD, Di Bartolomeo R, Folesani G, Pyeritz RE, Braverman AC, Montgomery DG, Isselbacher EM, Nienaber CA, Eagle KA, Fattori R.	Clinical presentation, management, and short-term outcome of patients with type A acute dissection complicated by mesenteric malperfusion: Observations from the International Registry of Acute Aortic Dissection.	<i>J Thorac Cardiovasc Surg.</i> 2012, 145(2): 385-390.

Suzuki T, Isselbacher EM, Nietnaber CA, Pyeric tz RE, Eagle Knal A, Tsai TT, Coe per JV, Januzzi JL Jr, Braver man AC, Montg omery DG, Fatt ori R, Pape L, Harris KM, Boo her A, Oh J, P eterson M, Ram anath VS, Froe hlich JB.	Type-selective benefits of medica tions in treatment of acute aorti c dissection: (from the Internatio nal Registry of Acute Aortic Diss ection [IRAD]).	<i>Am J Cardiol</i> 109:122-127, 2012
Kawajiri H, Shimizu H, Yoshitake A, Yozu R	Hybrid repair of a Kommerell diverticulum associated with a right aortic arch and a left descending aorta	<i>J Vasc Surg.</i> 56(6) 1727-30, 2012
Inoue S, Mori A, Shimizu H, Yoshitake A, Tashiro R, Kabei N, Yozu R	Combined use of an epidural cooling catheter and systemic moderate hypothermia enhances spinal cord protection against ischemic injury in rabbits	<i>J Thorac Cardiovasc Surg.</i> in press
Kurihara T, Shimizu-Hirota R, Shimoda M, Adachi T, Shimizu H, Weiss SJ, Itoh H, Hori S, Aikawa N, Okada Y.	Neutrophil-derived matrix metalloproteinase 9 triggers acute aortic dissection	<i>Circulation.</i> 126(25) 3070-80, 2012
Shimizu H, Matayoshi T, Morita M, Ueda T, Yozu R	Total arch replacement under flow monitoring during selective cerebral perfusion using a single pump	<i>Ann Thorac Surg</i> 95(1) 29-34, 2013



Targeting Transforming Growth Factor- β Signaling in Aortopathies in Marfan Syndrome

Daigo Sawaki, MD; Toru Suzuki, MD

Marfan syndrome (MFS) is characterized by mutations in the fibrillin-1 gene and dysregulation of transforming growth factor- β (TGF β) signaling, which is phenotypically associated with gradual weakening of connective tissue throughout the body, including the lungs, bones and cardiovascular system.¹ A primary cause of mortality in MFS patients reaching adolescence or adulthood is aortic rupture or dissection. Surgery is generally performed to remove the affected portion of the aorta, but more than half of patients who have had their aortas repaired require additional surgery or manifest aortic rupture because of expansion of the unrepaired regions of the aorta over time.² At present, measures to identify patients exhibiting progressive expansion or re-expansion of the aorta after surgery is a topic of importance. On medical therapy, β -blockers have been historically used as the anchoring agent. The renin-angiotensin system (RAS) has also recently been implicated in the pathogenesis of Marfan aor-

topathy, with initial experiments showing prevention of aortic root expansion in a mouse model of MFS using RAS blockade,³ which was followed by studies in human patients that showed similar results.^{4,5} These findings were welcomed with enthusiasm as a pharmacological solution for MFS, and have prompted several human clinical trials, which are presently ongoing to determine the possible benefit of RAS blockade in aortopathy in MFS patients.⁶ TGF β signaling has also received attention as a key factor in the aortopathy of MFS patients, as not only the canonical regulatory pathway involving downstream Smad proteins but also a non-canonical pathway involving ERK and JNK kinases has been recently described as implicated in MFS pathology upon activation of the TGF β pathway.^{7,8} Moreover, circulating levels of TGF β have received attention because they are not only elevated in patients with MFS aortopathy but are also responsive to pharmacological treatment, thus suggesting their possible use as a sur-

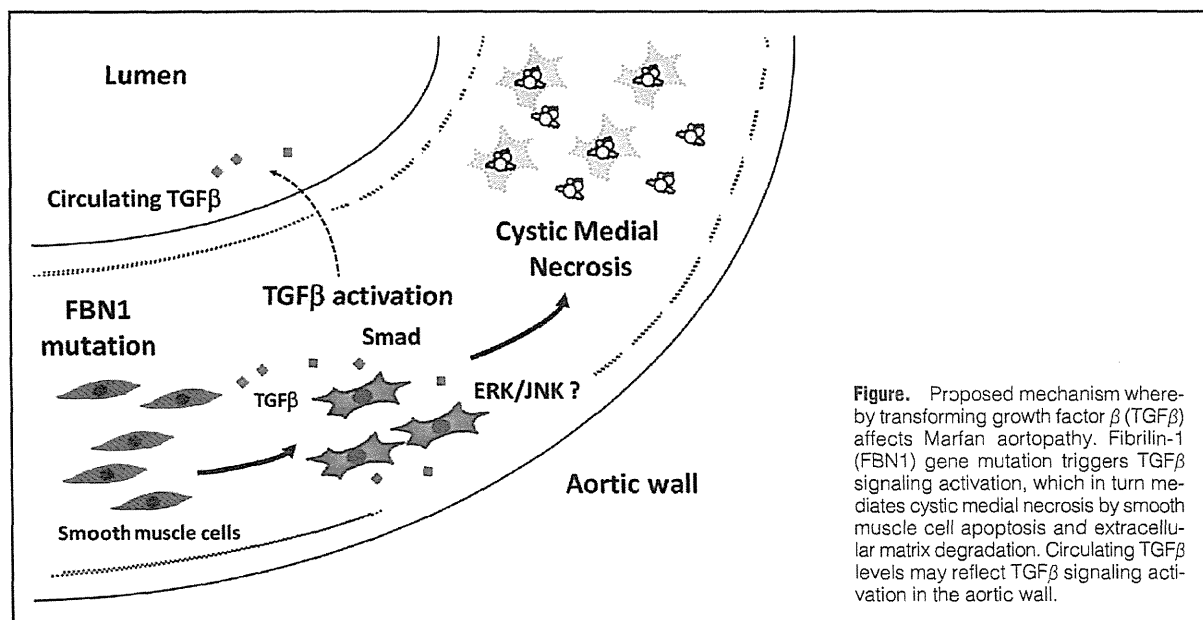


Figure. Proposed mechanism whereby transforming growth factor β (TGF β) affects Marfan aortopathy. Fibrillin-1 (FBN1) gene mutation triggers TGF β signaling activation, which in turn mediates cystic medial necrosis by smooth muscle cell apoptosis and extracellular matrix degradation. Circulating TGF β levels may reflect TGF β signaling activation in the aortic wall.

The opinions expressed in this article are not necessarily those of the editors or of the Japanese Circulation Society.

Received February 3, 2013; accepted February 3, 2013; released online February 14, 2013

Departments of Cardiovascular Medicine and Ubiquitous Preventive Medicine, The University of Tokyo, Tokyo, Japan

The authors contributed equally.

Mailing address: Toru Suzuki, MD, Department of Cardiovascular Medicine, Department of Ubiquitous Preventive Medicine, Graduate

School of Medicine, The University of Tokyo, 7-3-1 Hongo, Bunkyo-ku, Tokyo 113-8655, Japan. E-mail: torusuzu-tyk@umin.ac.jp

ISSN-1346-9843 doi:10.1253/circj.CJ-13-0183

All rights are reserved to the Japanese Circulation Society. For permissions, please e-mail: cj@j-circ.or.jp

rogate biomarker for the aortic remodeling process.⁹ However, there remains a paucity of data linking the severity of aortic wall destruction, histologically increased focal TGF β activation and elevated circulating TGF β levels in human cases of Marfan aortopathy.

Article p 952

In this issue of the Journal, Kim and colleagues¹⁰ report on their investigation of aortic tissue injury, such as cystic medial degeneration and cellular apoptosis, and Smad2 phosphorylation in MFS patients, in addition to TGF β levels in both the peripheral blood and aortic tissue. They demonstrate an association between circulating levels of active TGF β -1 and the severity of aortic remodeling (cystic medial degeneration and Smad2 phosphorylation in aneurysmal aortic layers) in MFS patients.

One of the noteworthy features of this study is that, for the first time, an association between pathologic aortic remodeling and both TGF β signaling in the aortic wall and circulating levels in MFS patients are shown (Figure). Activation of the Smad2 pathway had been previously reported as common to both syndromic and non-syndromic aneurysms of the human ascending aorta (including MFS as well as degenerative aneurysm and bicuspid aortic valve patients), but that previous study only reported pathologically increased Smad2 phosphorylation and expression levels of TGF β in the diseased aortic wall and did not determine the association between these phenomena and the degree of aortic wall remodeling/destruction or circulating TGF β levels.¹¹

Another feature of the present study is the patient cohort. Investigated patients had not been treated with antihypertensive drugs for more than 2 weeks, which provided the condition of minimal concomitant effects by the various drugs and agents used in this syndrome that may affect TGF β signaling and MFS pathogenesis. This, however, does imply that patients were basically medically untreated and thus points to an unconventional cohort for present standards of care. Further, the authors report on the degree and relationship between Smad phosphorylation and TGF β signaling at the histologic level in Asian subjects, as racial differences in MFS phenotype and circulating TGF β levels had been reported.¹² MFS patients with aortic dissection were also shown to exhibit more severe cystic medial degradation, and increased circulating or aortic TGF β levels. Although this finding is descriptive and not necessarily causal, it describes an association between the severity of aortic remodeling and circulating TGF β levels.

Several issues remain unanswered in the application, in the real world, of circulating TGF β levels as a surrogate biomarker to monitor disease activity or therapeutic efficacy in MFS or other aortopathic patients, in addition to the technical difficulties that lead to false-positive results (eg, method of blood sampling). One is that it is still unclear whether circulating TGF β levels are truly associated with dilation of the aorta, which is of clinical importance. The present study showed a

dilated aorta with an average width of 59 mm at the sinus of Valsalva regardless of circulating TGF β levels. Lack of correlation between the z value (an indicator of aortic root expansion) and circulating TGF β level, despite reduction in the level by pharmacological intervention, has also been reported.⁹ Another issue is the need to better understand the relative contribution of TGF β and its downstream signaling molecules in aneurysmal formation in the Marfan aorta.

Collectively, circulating TGF β levels may be associated with progression of aortic remodeling as reflected by activated Smad (phosphorylation) protein on histopathologic analysis. Importantly, however, other mechanisms, including Smad-independent pathways and/or inflammatory processes, might also contribute to clinical aneurysmal dilatation, rupture or dissection.¹³

References

1. Neptune ER, Frischmeyer PA, Arking DE, Myers L, Bunton TE, Gayraud B, et al. Dysregulation of TGF-beta activation contributes to pathogenesis in Marfan syndrome. *Nat Genet* 2003; **33**: 407–411.
2. Kimura N, Tanaka M, Kawahito K, Itoh S, Okamura H, Yamaguchi A, et al. Early- and long-term outcomes after surgery for acute type a aortic dissection in patients aged 45 years and younger. *Circ J* 2011; **75**: 2135–2143.
3. Habashi JP, Judge DP, Holm TM, Cohn RD, Loeys BL, Cooper TK, et al. Losartan, an AT1 antagonist, prevents aortic aneurysm in a mouse model of Marfan syndrome. *Science* 2006; **312**: 117–121.
4. Ahimastos AA, Aggarwal A, D'Orsa KM, Formosa MF, White AJ, Savarirayan R, et al. Effect of perindopril on large artery stiffness and aortic root diameter in patients with Marfan syndrome: A randomized controlled trial. *JAMA* 2007; **298**: 1539–1547.
5. Brooke BS, Habashi JP, Judge DP, Patel N, Loeys B, Dietz HC 3rd. Angiotensin II blockade and aortic-root dilation in Marfan's syndrome. *N Engl J Med* 2008; **358**: 2787–2795.
6. Lacro RV, Dietz HC, Wruck LM, Bradley TJ, Colan SD, Devereux RB, et al. Rationale and design of a randomized clinical trial of beta-blocker therapy (atenolol) versus angiotensin II receptor blocker therapy (losartan) in individuals with Marfan syndrome. *Am Heart J* 2007; **154**: 624–631.
7. Holm TM, Habashi JP, Doyle JJ, Bedja D, Chen Y, van Erp C, et al. Noncanonical TGFbeta signaling contributes to aortic aneurysm progression in Marfan syndrome mice. *Science* 2011; **332**: 358–361.
8. Habashi JP, Doyle JJ, Holm TM, Aziz H, Schoenhoff F, Bedja D, et al. Angiotensin II type 2 receptor signaling attenuates aortic aneurysm in mice through ERK antagonism. *Science* 2011; **332**: 361–365.
9. Matt P, Schoenhoff F, Habashi J, Holm T, Van Erp C, Loch D, et al. Circulating transforming growth factor-beta in Marfan syndrome. *Circulation* 2009; **120**: 526–532.
10. Kim KL, Yang JH, Song SH, Kim JY, Jang SY, Kim JM, et al. Positive correlation between the dysregulation of transforming growth factor- β 1 and aneurysmal pathological changes in patients with Marfan syndrome. *Circ J* 2013; **77**: 952–958.
11. Gomez D, Al Haj Zen A, Borges LF, Philippe M, Gutierrez PS, Jondeau G, et al. Syndromic and non-syndromic aneurysms of the human ascending aorta share activation of the Smad2 pathway. *J Pathol* 2009; **218**: 131–142.
12. Akutsu K, Morisaki H, Takeshita S, Ogino H, Higashi M, Okajima T, et al. Characteristics in phenotypic manifestations of genetically proved Marfan syndrome in a Japanese population. *Am J Cardiol* 2009; **103**: 1146–1148.
13. Radonic T, de Witte P, Groenink M, de Waard V, Lutter R, van Eijk M, et al. Inflammation aggravates disease severity in Marfan syndrome patients. *PLoS One* 2012; **7**: e32963.

Herz 2012 · 38:269–276
 DOI 10.1007/s00059-012-3710-1
 Received: 7. März 2012
 Revised: 4. September 2012
 Accepted: 2. Oktober 2012
 Published online: 23 December 2012
 © Urban & Vogel 2012

E. Bossone^{1,2} · T. Suzuki³ · K.A. Eagle⁴ · J.W. Weinsaft⁵

¹ Heart Department, University of Salerno, Salerno

² Cardiac Surgery Department, IRCCS Policlinico San Donato, San Donato Milanese, Milan

³ Department of Cardiovascular Medicine, Graduate School of Medicine, The University of Tokyo, Tokyo

⁴ University of Michigan Cardiovascular Center, Ann Arbor

⁵ Department of Medicine, Weill Cornell Medical College, New York

Diagnosis of acute aortic syndromes

Imaging and beyond

Introduction

Acute aortic syndromes encompass a spectrum of related conditions, ranging from aortic dissection (AoD) to intramural hematoma (IMH) and penetrating atherosclerotic ulcer (PAU). From a physiological standpoint, these conditions commonly result from disruption of the structural integrity of the aortic wall [1, 2, 3]. Beyond the typical presentation of rest-onset chest pain, patients with AoD may present with nonspecific symptoms, such as neurological deficits, syncope, or cramping abdominal pain [4]. Clinical variability can make diagnosis challenging, with symptomatic heterogeneity relating to distribution of aortic involvement. Failure to promptly recognize and treat acute aortic syndrome may result in progressive aortic injury, end-organ compromise, and hemodynamic instability, thereby, adding to the potential morbidity and mortality risks of these serious conditions [4, 5, 6].

This review provides an overview of established and emerging approaches for assessment of acute aortic syndromes, with focus on imaging and biomarkers. Diagnostic options are discussed in the context of consensus guidelines, including relative benefits offered by individual tests towards the goal of comprehensive evaluation and risk assessment of

patients with known or suspected acute aortic syndrome.

Imaging

Aortic dissection

AoD typically results from a tear in the aortic intima, an index event that causes blood extravasation with separation of the aortic wall layers (i.e., intima, media, and adventitia). AoD is generally classified as acute if presentation occurs within 2 weeks of symptom onset, subacute if it occurs within 2–6 weeks, and chronic if more than 6 weeks have elapsed [1, 2, 3, 4].

Anatomic location of AoD is a key determinant of clinical outcome and is widely used to guide management (Fig. 1a). The Stanford classification categorizes AoD involving the ascending aorta as *type A*, and AoD confined to the aortic arch or descending aorta (i.e., distal to the left subclavian artery) as *type B*. The DeBakey classification categorizes AoD based on site of origin of the intimal tear—*type I* originates in the ascending aorta and extends distally (i.e., aortic arch or beyond), *type II* is confined to the ascending aorta, and *type III* involves the descending aorta (i.e., distal to the left subclavian artery) [1, 2].

Tab. 1 Relative strengths of imaging modalities for acute aortic syndromes

	TTE	TEE	MRI	CT
Imaging factors				
Comprehensive aortic assessment	+	++	+++	+++
Tomographic (3D reconstruction)	–	–	+++	+++
Functional	+++	+++	++	+
Tissue characterization	–	–	+++	+++
Clinical factors				
Portability	+++	++	–	–
Patient access/monitoring	+++	+++	+	++
Rapidity	++	++	++	+++
Non-contrast	+++	+++	+	+
Radiation exposure	+++	+++	+++	+

3D three-dimensional, TTE transthoracic echocardiography, TEE transesophageal echocardiography, MRI magnetic resonance imaging, CT computed tomography.

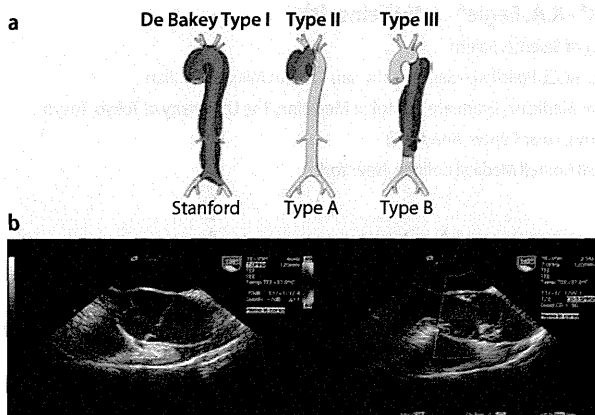


Fig. 1 ▲ Aortic Dissection. **a** DeBakey and Stanford classification systems. The DeBakey system (*top*) classifies AoD into three types based on site of origin and extent: type I originates in the ascending aorta and propagates at least to the aortic arch, type II originates and is confined to the ascending aorta, and type III originates in the descending aorta but occasionally extends in an antegrade or retrograde direction. The Stanford system (*bottom*) classifies AoD into two types: type A involves the ascending aorta, and type B is confined to the aortic arch or descending aorta. (Reproduced with permission. Modified from [42]). **b** Transesophageal echocardiography: Type A aortic dissection: intimal flap with entry tear close to the right anterior Valsalva sinus without (*left panel*) and with (*right panel*) color Doppler. (Courtesy of Rodolfo Citro, MD, Heart Department, University Hospital “San Giovanni di Dio e Ruggi d’Aragona”, Salerno, Italy)

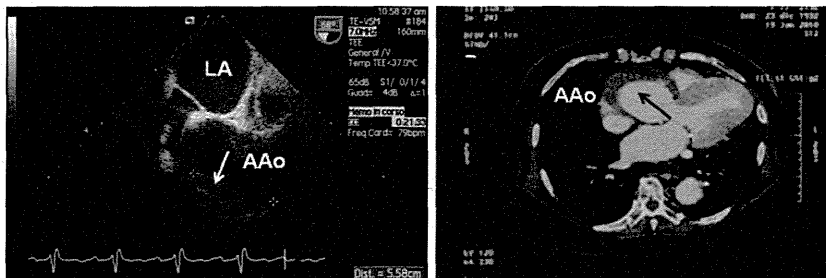


Fig. 2 ▲ Intramural hematoma. Transesophageal echocardiography (*left*) reveals ascending aortic aneurysm and aortic wall thickening (*arrow*) without accompanying dissection flap or false lumen. Contrast-enhanced computed tomography (*right*) demonstrates crescentic aortic wall thickening (*arrow*), a hallmark of intramural hematoma. (Courtesy of Rodolfo Citro, MD, Heart Department, University Hospital “San Giovanni di Dio e Ruggi d’Aragona”, Salerno, Italy). AAo ascending aorta, LA left atrium

Both the Stanford and DeBakey classification systems can readily be applied to imaging (■ Fig. 2). In consensus guidelines, there is a lack of agreement as to which system is better [1, 2]. Prompt surgical intervention is usually indicated for AoD involving the ascending aorta (Stanford type A, DeBakey types I or II), whereas medical management with β -blockade and adjunctive blood pressure control is reserved for AoD localized to the aortic arch or descending aorta (Stanford type B, DeBakey type II). Endovascular stenting is an alternative management strategy for

dissections involving the descending thoracic aorta. Patient-specific decisions regarding surgical/interventional vs. medical management are influenced by ancillary considerations, such as cardiovascular/hemodynamic stability and end-organ compromise [1, 2].

Diagnostic performance of imaging in AoD can vary depending on technology used, institutional expertise, and exam quality. Given the acute nature of AoD and the importance of early treatment, prospective randomized comparisons of imaging modalities are difficult.

In a recent meta-analysis, encompassing 1139 patients from 16 studies, pooled sensitivity (98–100%) and specificity (95–100%) were similar between transesophageal echocardiography (TEE), computed tomography (CT), and magnetic resonance imaging (MRI) [7]. Transthoracic echocardiography (TTE) has generally been reported to yield lower sensitivity for AoD diagnosis, with better performance for type A (78–87%) compared to type B (29–40%) AoD [1, 2, 8, 9]. According to data from the International Registry of Acute Aortic Dissection (IRAD), multimodality imaging is employed in approximately two thirds of patients being evaluated for AoD [5, 9], highlighting the importance of follow-up testing if clinical suspicion remains high despite an initially negative or equivocal diagnostic imaging result.

From an individual patient standpoint, decisions as to which modality should be used for AoD are influenced by imaging and clinical considerations. A comparison of the relative strengths of major noninvasive imaging modalities is shown in ■ Tab. 1. In addition to their general strengths, it is also important to recognize that test performance can vary between patients and institutions. Imaging expertise is critically important to optimize quality and maximize test performance. The common imaging challenges that may affect aortic assessment, as well as the strategies that can be employed to contend with them are outlined in ■ Tab. 2. As a general principle, multimodality imaging should be strongly considered when image quality is suboptimal or clinical suspicion for acute aortic syndrome persists after an initial negative test result.

The remainder of this section details key clinical and imaging considerations for imaging tests commonly used to assess AoD.

Echocardiography

TTE is widely used as a general screening test for patients with cardiovascular disease, including individuals with known or suspected AoD [10]. Major advantages include wide availability, bedside portability, absence of ionizing radiation, and no need for contrast administration (of particular

benefit in the context of AoD, a condition associated with impaired renal perfusion). TTE is well suited to assess cardiac complications of AoD, such as aortic regurgitation and pericardial effusion/tamponade [1, 2, 10].

TTE provides immediate and reliable assessment of cardiac structure and function, but its ability to comprehensively assess the aorta is limited. Quality can vary depending on patient body habitus and sonographer expertise. Imaging of the descending thoracic aorta is often challenging because of its relative distance from the sonographic probe, rendering TTE suboptimal for the assessment of AoD in this region.

TEE enables physician-guided imaging in close proximity to the thoracic aorta and provides high spatial and temporal resolution images in discrete aortic segments. Clinical advantages of TEE are counterbalanced by its invasive nature, which is dissatisfying for patients with low pretest probability for AoD, and may be contraindicated in patients with high pretest probability in whom hemodynamic instability prohibits sedation and endoscopy. Image artifacts due to reverberation may mimic AoD, appearing as a linear mobile density within the ascending aorta. Assessment of mobility (i.e., AoD manifests independent mobility from surrounding structures), location (i.e., AoD does not transect the aortic wall), and Doppler flow pattern (i.e., differential flow on either side of the dissection flap) are useful criteria for distinguishing AoD from an image artifact [1]. TEE may occasionally be suboptimal for imaging the distal ascending aorta/proximal arch because of interference by tracheal air shadowing, as well as the abdominal aorta because of the distance from the imaging probe, emphasizing the need for alternative imaging in some individuals [1, 2, 10].

Computed tomography and magnetic resonance imaging

Tomographic imaging—whether by CT or MRI—provides comprehensive assessment of the aorta and its branch vessels. Tomographic imaging also enables double oblique reformatting for identification of AoD origin and accurate assessment of

Herz 2012 · 38:269–276 DOI 10.1007/s00059-012-3710-1
© Urban & Vogel 2012

E. Bossone · T. Suzuki · K.A. Eagle · J.W. Weinsaft

Diagnosis of acute aortic syndromes. Imaging and beyond

Abstract

Acute aortic syndromes are fatal medical conditions including classic acute aortic dissection, intramural hematoma, and penetrating atherosclerotic ulcer. Given the nonspecific symptoms and signs, a high clinical index of suspicion followed by an imaging study, namely transesophageal echocardiography, computed tomography, and magnetic resonance imaging (sensitivity 98–100% and specificity 95–100%), is a *conditio sine qua non* for prompt diagnosis of acute aortic syndromes. This article provides an overview of

established and emerging approaches for the assessment of acute aortic syndromes, with focus on imaging and biomarkers. In this regard, D-dimer levels (cut-off: 500 ng/ml) may be useful to rule out aortic dissection, if used within the first 24 h after symptom onset.

Keywords

Acute aortic syndromes · Aortic dissection · Cardiac imaging techniques · D-dimer · Congenital abnormalities

Diagnose des akuten Aortensyndroms. Bildgebung und mehr

Zusammenfassung

Das akute Aortensyndrom ist eine letale Erkrankung und umfasst beispielsweise die klassische akute Aortendissektion, das intramurale Hämatom und das penetrierende atherosklerotische Ulkus. Angesichts der unspezifischen Symptome sind bei starkem klinischem Verdacht bildgebende Untersuchungen, also transösophageale Echokardiographie, Computertomographie und Magnetresonanztomographie (Sensitivität: 98–100%, Spezifität: 95–100%), eine *Conditio sine qua non* für die zügige Diagnose eines akuten Aortensyndroms. In der vorliegenden Übersichtsarbeit wird ein Überblick über

etablierte und neue Ansätze zur Beurteilung des akuten Aortensyndroms gegeben, dabei liegt der Schwerpunkt auf Bildgebung und Biomarkern. Diesbezüglich ist möglicherweise die Bestimmung des D-Dimer-Spiegels (Grenzwert: 500 ng/ml) zum Ausschluss einer Aortendissektion hilfreich, wenn sie innerhalb der ersten 24 h nach Symptombeginn durchgeführt wird.

Schlüsselwörter

Akutes Aortensyndrom · Aortendissektion · Kardiale Bildgebungsverfahren · D-Dimer · Kongenitale Anomalien

aortic size [11, 12], all major prognostic indices in patients with aortic disease. In addition to direct aortic assessment, both CT and MRI are well suited to assess complications of AoD, including pericardial or pleural effusions. Tomographic imaging is particularly useful for patients with prior aortic interventions, as it enables integrated visualization of both native aortic segments and prosthetic materials. Accelerated sampling methods have reduced test times for both CT and MRI, allowing rapid imaging of patients with known or suspected AoD. ECG gating techniques improve temporal resolution and reduce blurring of the aortic root, a relatively mobile region that can be difficult to assess on non-gated imaging.

Beyond their common advantages, it is important to consider the relative strengths of each tomographic im-

aging modality in the context of clinical considerations. MRI entails no radiation exposure and is well suited for serial assessment of at-risk patients. Using phase velocity encoded imaging techniques, MRI can directly measure aortic flow and thereby assess adjunctive complications such as aortic regurgitation. However, MRI is performed in a highly controlled setting, with most scanners employing closed bore systems that make rapid patient access difficult—a key disadvantage for unstable or claustrophobic patients. Additionally, MRI is prohibited in patients with ferromagnetic and/or magnetically activated implants (including most cardiac pacemakers and defibrillators), and image artifacts can interfere with assessment of vascular stents [13]. Gadolinium-based contrast agents are contraindicated in patients with advanced renal im-

Tab. 2 Imaging challenges in aortic assessment

Finding	Etiology	Typical location	Potential solutions
TTE Acoustic shadowing/impaired aortic visualization	Distance from sonographic probe	Aortic arch, descending aorta	Acquire images using suprasternal (for arch) or subcostal (for mid descending aorta) views
TEE Linear artifact mimicking dissection	Tracheal interference (air shadowing)	Distal arch, proximal descending aorta	Assess mobility pattern (artifact typically transects wall, demonstrates phasic mobility) Assess Doppler flow pattern (dissection typically manifests differential flow between true/false lumen, possible communication at dissection origin)
MRI Repetitive “ghosting” artifact obscuring aorta or mimicking dissection, blurred vessel contours	Respiratory motion Cardiovascular motion	Nonspecific (typically diffuse)	Accelerated data sampling (i.e., parallel or single shot imaging) Respiratory gating Integrated MR angiography interpretation with noncontrast (i.e., fast spin-echo, steady-state free precession) imaging
Impaired visualization of prosthetic material (i.e., aortic stents)	Susceptibility Radiofrequency shielding	Localized to prosthetic material (i.e., within or adjacent to stent)	Modify pulse sequence parameters (i.e., increase flip angle, decrease echo time) Alter pulse sequences used use of fast spin-echo pulse sequences (if feasible)
CT Impaired visualization of prosthetic material (i.e., stents)	Beam hardening artifact (blooming effect)	Localized to prosthetic material (i.e., within or adjacent to stent)	High resolution, multidetector CT scanners (i.e., for reduced voxel size) Modify scanning parameters (i.e., increase tube voltage) Modify data filtering (i.e., use edge enhancing [“sharp”] convolution kernels) Adjust workstation settings for stent interpretation (i.e., width ~1500 HU, center ~300 HU)

TTE transthoracic echocardiography, TEE transesophageal echocardiography, MRI magnetic resonance imaging, CT computed tomography.

pairment because of the risk for nephrogenic systemic fibrosis. Non-contrast MRI techniques, such as fast spin-echo and steady-state free precession, may be useful for aortic assessment of patients with renal dysfunction [14].

For CT angiography, both ionizing radiation and contrast-associated nephrotoxicity are substantial concerns, especially in patients requiring serial testing. Radiation dose reduction can be achieved through use of prospective ECG gating and dose modulation techniques [15]. CT offers several advantages that are especially pertinent to patients with known or suspected AoD. Relatively open scanner environments facilitate patient tolerance of the exam as well as rapid patient access, if necessary. Current generation multidetector CT can provide submillimeter spatial resolution—facilitating detailed assessment of aortic anatomy. Multidetector CT also enables coronary assessment, thereby, providing useful information for patients requiring coronary re-implantation in the context of aortic graft placement. Prosthetic material is well visualized on CT [13], enabling assessment of vessel integrity in patients with prior surgical interventions. These advantages may explain findings from the IRAD study, which re-

ported that CT was the most commonly used initial imaging test for suspected acute AoD (63%), followed by echocardiography (32%) and MRI (1%) [9].

Intramural hematoma

IMH, a potential precursor to AoD [16], reflects hemorrhage of the vasa vasorum into the aortic media, with resultant separation of the vessel wall (intima and media). Clinical differentiation between IMH and acute AoD can be challenging, emphasizing the need for reliable imaging to distinguish between these diagnoses.

Echo, CT, and MRI have all been used to diagnose IMH. An imaging hallmark is crescentic or circumferential aortic wall thickening in the absence of an identifiable dissection flap (Fig. 2). IMH location may vary, making comprehensive aortic imaging necessary when this diagnosis is being considered.

Tissue characterization imaging—as offered by CT and MRI—may also enable assessment of vascular properties beyond those discernable solely on the basis of IMH morphology. IMH typically manifests higher signal intensity than intraluminal blood on non-contrast CT and absence of enhancement (i.e., low signal in-

tensity) on contrast-enhanced imaging. Focal regions of intramural contrast uptake have been reported in some cases [17, 18], with variability possibly due to differences in IMH acuity or tissue composition. MRI tissue characterization can similarly demonstrate IMH, with delayed post-contrast (T1-weighted) imaging particularly useful for demonstrating thrombotic components [19, 20]. Complementary MRI approaches, such as T2*-weighted imaging, have been used to detect intramyocardial hemorrhage following acute myocardial infarction [21]. This approach also holds potential for assessing intravascular hemorrhage in the context of IMH. However, IMH may be small in size (i.e., focal), thereby, requiring high spatial resolution imaging to be detected. Aortic mobility imposes a further technical challenge, emphasizing the need for good temporal resolution, which may be difficult to achieve when counterbalanced with spatial resolution requirements. These imaging challenges may explain the limited application of tissue characterization approaches for diagnostic and prognostic assessment of IMH. Complementary MRI approaches include phase contrast and cine imaging, each of which may be helpful to exclude focal dis-

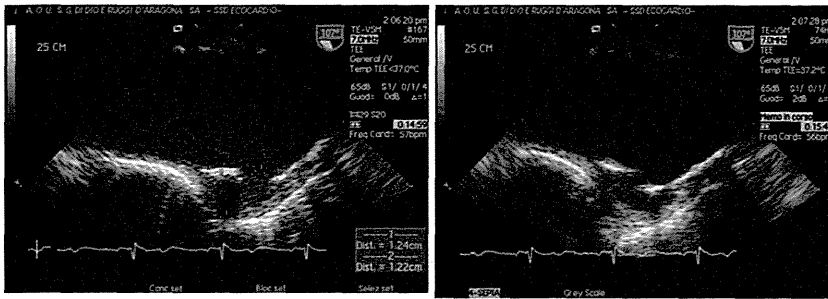


Fig. 3 ▲ Penetrating atherosclerotic ulcer. Transesophageal echocardiography: ulcer-like formation in the inferior wall of the aortic arch with disruption of the internal elastic lamina before (*left panel*) and after (*right panel*) contrast agent administration. (Courtesy of Rodolfo Citro, MD, Heart Department, University Hospital “San Giovanni di Dio e Ruggi d’Aragona”, Salerno, Italy)

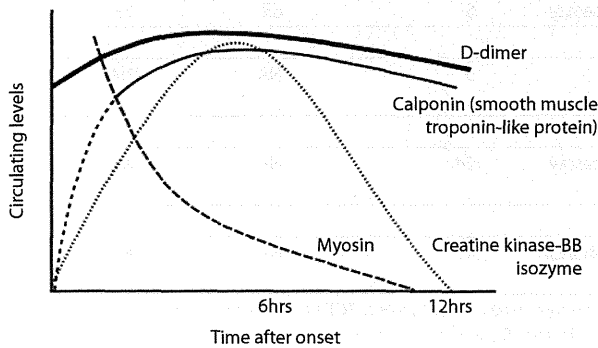


Fig. 4 ◀ Time course of biomarker elevation following acute aortic dissection. Note the rapid and prolonged elevation of D-dimer in relation to other potential biomarkers

section flap and absence of flow in association with IMH.

Penetrating atherosclerotic ulcer

PAU is identifiable by the presence of an ulcerated plaque that extends into the medial layer of the aortic wall. Exposure of the media to pulsatile blood flow may induce structural instability, with subsequent risk of PAU progression to AoD or IMH or even free rupture. Presenting symptoms can mimic IMH or AoD, emphasizing the role of noninvasive imaging for diagnostic assessment of acute aortic syndromes.

PAU typically appears as an *ulcer-like* formation on imaging (■ Fig. 3), with irregularly contoured luminal indentation. These features can be demonstrated on echo, as well as both CT and MRI. However, the latter two modalities offer several benefits of particular utility for PAU. First, both tomographic methods provide three-dimensional imaging—a feature particularly useful for demonstrating PAU in the presence of aortic tortuosity and associated altered geometry. Second, imaging is typically performed with administration

of intravascular contrast agents, which improve delineation of the luminal borders and facilitate assessment of plaque ulceration.

Some reports have suggested that MRI is superior to CT for the diagnosis of PAU [22]. However, these conclusions were derived from early imaging technology and can be questioned in the light of current generation multidetector CT, which can provide submillimeter spatial resolution. Similar to IMH, tissue characterization imaging by MRI and CT holds the potential to offer new insights into the pathophysiology of PAU. Both MRI and CT allow for tissue characterization of atherosclerotic plaques [23, 24], a feature that is particularly attractive for the assessment of aortic plaque composition in the context of PAU. However, as with IMH, *in vivo* application of tissue characterization imaging has been limited, possibly due to technical challenges related to both spatial and temporal resolution. Further advances in MRI and CT technologies may facilitate broader clinical application of tissue characterization approaches for the assessment of acute aortic syndromes.

Biomarkers

Smooth muscle

Smooth muscle is predominantly found in the aortic media, which is injured during onset and evolution of AoD, leading to circulatory release of cellular proteins. This phenomenon has led to investigation of several smooth muscle biomarkers for acute aortic syndromes.

Smooth muscle myosin heavy chain was among the first biomarkers found to be elevated in patients with AoD. Studies showed marked elevations in the setting of acute AoD, with a dynamic range of nearly 20-fold higher levels in patients presenting early after symptom onset [25]. Smooth muscle myosin offered favorable discrimination and diagnostic accuracy, but elevations were transient (i.e., 3–6 h) after AoD onset, similar to myoglobin in acute myocardial infarction [25, 26]. This phenomenon creates a narrow time window of use, a substantial limitation for use of this biomarker in routine clinical practice.

Creatine kinase, which includes both muscle (M-) and brain (B-) isozymes, has also been investigated as a biomarker for AoD. The MM-type isozyme is widely used for detection of skeletal muscle damage, as is the MB-isozyme for detection of ischemic heart disease. Studies measuring the BB-isozyme, which is selective for neurological and smooth muscle, showed marked elevations following AoD, with peak levels approximately 6 h after onset [27]. However, the short time course and lack of specificity of this biomarker are substantial limitations to clinical use.

Calponin, a troponin counterpart of smooth muscle, has also been investigated as a biomarker for AoD. Similar to troponin in the setting of myocardial infarction, a particular benefit of calponin concerns its prolonged elevation. In comparison to creatinine kinase-BB, calponin has a longer time course, remaining elevated throughout the first 24 h following AoD based on an initial assay [28]. The time course of calponin elevation in relation to other biomarkers for acute AoD is illustrated in ■ Fig. 4.

Tab. 3 Potential biomarkers for diagnosis of acute aortic dissection

Biomarker Author	Cases/Ctrl	Stanford A/B	Cut-off	Type of assay	Symptom onset (h)	Sensitivity (%)	Specificity (%)
D-dimer (µg/ml)							
Suzuki et al. [35]	87/133	64/23	>0.5	Immunoassay	24	96.6	46.6
Sbarouni et al. [36]	18/29	13/5	>0.7	ELISA	4–60	94	59
Ohlmann et al. [37]	94/94	67/27	>0.4	Turbidimetric	29	99	34
Hazui et al. [38]	29/49	29/0	>0.9	Latex agglutination	4	93.1	80
Akutsu et al. [39]	30/48	12/18	>0.5	Latex agglutination	4.5	100	54
Eggebrecht et al. [40]	16/48	6/10	>0.62	Latex agglutination	16	100	73
Weber et al. [41]	24/35	12/12	>0.5	Turbidimetric	24	100 ^a	69
SSMMHC (µg/l)							
Suzuki et al. [26]	95/131	45/50	2.5	Enzyme immunoassay	<3	90.0 ^b	98 ^c
Basic calponin (ng/ml)							
Suzuki et al. [28]	59/158	43/15	159 ^d	Immunoassay	6	63	73
MMP-9 (ng/ml)							
Sangiorgi et al. [31]	13/10	9/4	3-fold higher ^e	ELISA	3	NA	NA
TGF-β (ng/ml)							
Suzuki et al. [33]	28/–	20/8	5-fold higher ^f	Immunoassay	24	NA	NA
CK-BB isozyme (IU/l)							
Suzuki et al. [27]	10/20	–/–	17-fold higher ^g	Electrophoresis	12	NA	NA

CK creatine kinase, Ctrl controls, MMP matrix metalloproteinases, SSMMHC smooth-muscle myosin heavy-chain protein, TGF transforming growth factor, NA not available. ^aD-dimer values tended to be higher in more extended aortic dissection, ^bsensitivity 72.4% and 30.3% at <6 h and >6 h from symptom onset, respectively, ^cspecificity was 83% compared to patients with acute myocardial infarction, ^doptimal value determined from ROC curve analyses, ^e29.3±16.1 ng/ml for type A group and 16.7±2.1 ng/ml for type B group vs 7.74±1.6 ng/ml for ctrl, p<0.03, ^f24.5±12.9 ng/ml for aortic dissection patients (28.5±14.7 ng/ml for type A, 14.4±6.1 ng/ml for type B) vs 5.4±2.8 ng/ml for ctrl, ^g93.4 for aortic dissection patients vs 0.2 IU/l for ctrl

Taken together, these data demonstrate the potential of smooth muscle proteins as biomarkers of acute AoD. Further industrial developments are necessary for these assays to become clinically available.

Structural and inflammatory indices

Several markers of vascular integrity or systemic inflammation have been tested for AoD. Elastin, a structural vessel wall protein, has been shown to increase following AoD [29]. However, dynamic range is limited (i.e., less than a two-fold increase compared with normal controls), making reliable clinical use questionable. C-reactive protein, a nonspecific inflammatory marker, has also been shown to increase after acute AoD [30]. Re-elevation and retarded recovery of C-reactive protein levels may reflect instability of intramural thrombus or hematoma (defined as enlargement of localized contrast filling, transition to classic dissection, or expansion of hematoma in the aortic wall) and/or thrombosis within the false lumen

[25]. Matrix metalloproteinases (MMP), enzymes involved in aortic remodeling, are also elevated in acute AoD, namely the subunit MMP-9 [31]. Further research is needed to clarify their potential role in AoD.

Circulating transforming growth factor-beta (TGF-β) has received particular attention as it may serve as a biomarker for aortic remodeling in patients with Marfan syndrome [32]. Fibrillin-1, the protein that is defective in Marfan syndrome, regulates TGF-β activity. TGF-β is bound in a complex form to fibrillin-1, which is disrupted upon pathogenic insult. This causes release and activation of the TGF-β molecule, resulting in activation of vascular cell signaling cascades that induce aortic remodeling. Further study is needed to test the clinical utility of TGF-β in a broad range of aortopathies. However, circulating TGF-β levels have been shown to be markedly elevated in patients with acute AoD [33], suggesting that TGF-β may potentially serve as a biomarker for conditions other than Marfan syndrome.

D-dimer

At present, D-dimer is the only biomarker that is clinically available and adequately sensitive to detect AoD. D-dimer, a fibrin fragment released in coagulopathic disorders, is routinely used to diagnose pulmonary embolism (PE). As shown in **Fig. 4**, D-dimer elevation occurs early after AoD and is prolonged in relation to other biomarkers. This feature is of particular clinical utility as it provides an increased time frame during which D-dimer can be used to identify patients with AoD.

Several studies have shown D-dimer to be elevated in the setting of AoD (**Tab. 3**) [26, 27, 28, 31, 33, 34, 35, 36, 37, 38, 39, 40, 41]. Clinical utility has been tested in the IRAD substudy on biomarkers (IRAD-Bio) [35], which used suspicion of AoD as an entry criterion for both patients and controls, thereby, enabling D-dimer to be tested in a setting similar to routine clinical practice. IRAD-Bio encompassed 220 patients with clinical-

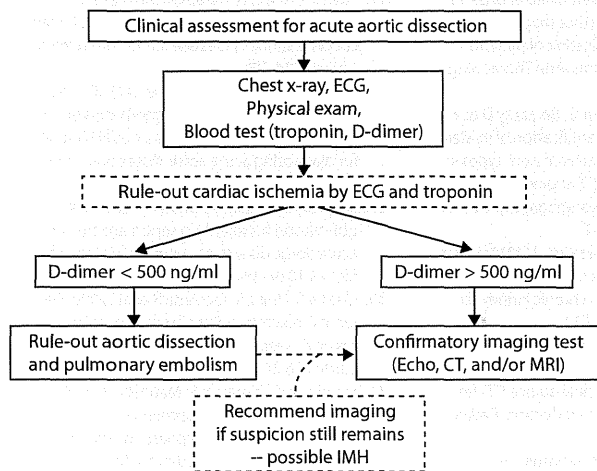


Fig. 5 ◀ Proposed diagnostic algorithm for patients with suspected aortic dissection. D-dimer testing is integrated with imaging and clinical evaluation. *CT* computed tomography, *IMH* intramural hematoma, *MRI* magnetic resonance imaging

ly suspected AoD. Results showed that, within the first 24 h of symptom onset, a D-dimer threshold of 500 ng/ml (commonly used for ruling out PE) can be used to discriminate between patients with and without confirmed AoD. Stratification based on D-dimer was maximal during the first 6 h after symptom onset, suggesting that AoD is associated with rapid and substantial D-dimer elevations. Not only was it possible to *rule out* AoD based on low D-dimer levels, but findings suggested that use of a higher threshold (1600 ng/ml) enabled AoD to be *ruled in*, thereby, supporting both the positive and negative predictive value of D-dimer. One caveat concerns the fact that IRAD-Bio included a small number of patients with PE, emphasizing the need for further study to test the utility of D-dimer among diverse patient cohorts. In summary, current data suggest that D-dimer may be helpful in assessing patients with suspected AoD. Since the same lower threshold can be applied to PE and AoD, this single test can be used to exclude both conditions in certain patients, a feature that is particularly advantageous from the standpoint of simplicity and cost-effectiveness. Notably, the IRAD-Bio study was comprised of patients with suspected AoD—caution is needed in extrapolating these data to patients with generalized chest pain. With the appropriate understanding in use and interpretation, D-dimer can be useful for evaluating chest pain syndromes in which marked elevations of this biomarker prompt consideration of further testing for acute AoD and/or PE.

Proposed algorithm for clinical decision-making

A proposed diagnostic algorithm that may be helpful in guiding evaluation of patients with suspected AoD is outlined in **Fig. 5**. While the algorithm integrates imaging and biomarker testing (D-dimer, troponin), clinical assessment assumes a primary role. To this end, clinical risk stratification using an “aortic dissection detection” (ADD) scoring tool has been included in recent US (ACC/AHA) consensus guidelines [1]. This tool has also been validated in patients with AoD: when tested in the IRAD registry, the ADD risk score yielded a diagnostic sensitivity of 95.7% for AoD. Among the 4.3% of patients with no clinical markers for AoD (ADD score = 0), nearly half (48.6%) that underwent chest X-ray had evidence of widened mediastinum—lending support to the concept that clinical history should be integrated with imaging or other testing when assessing for suspected AoD [5].

Regarding biomarkers, cardiac troponin and D-dimer can help to guide assessment. If possible, both indices should be checked with a point-of-care test that yields prompt results. Troponin, interpreted adjunctively with electrocardiography, can identify evidence of myocardial infarction/ischemia, which may constitute the primary cause of chest pain symptoms or occur as a secondary consequence of AoD (i.e., impaired coronary perfusion). In cases with D-dimer levels >500 ng/ml, an imaging test should

be performed promptly for further evaluation. In patients with D-dimer levels >1600 ng/ml, suspicion for AoD or PE should be high, with subsequent management guided by clinical findings and imaging results. In cases with D-dimer levels <500 ng/ml, imaging (i.e., CT, MRI, or TEE) should still be considered if clinical suspicion for AoD persists despite normal biomarker results. Indeed, normal D-dimer levels have been reported among patients with IMH or AoD with thrombosed false lumen [35], highlighting the importance of comprehensive evaluation for patients with suspected acute aortic syndromes.

Conclusion

The diagnosis of acute aortic syndrome can be made with similar accuracy using different imaging techniques such as TEE, CT or MRI depending on the availability of the technique, experience of the imaging staff, and clinical patient's condition. However, multimodality imaging should be strongly considered when image quality is suboptimal or clinical suspicion for acute aortic syndrome persists even after an initial negative test. The measurement of specific biomarkers is intriguing as an initial strategy for the diagnosis of acute aortic syndrome. D-dimer levels (cut-off: 500 ng/ml) may be useful to rule out AoD if used within the first 24 h after symptom onset. Further studies are necessary to test the comparative utility of variable imaging and biomarker-guided algorithms among large cohorts of patients with known or suspected acute aortic syndrome.

Corresponding address

Prof. E. Bossone
Via Pr. Amedeo, 36, 83023 Lauro (AV)
Italy
ebossone@hotmail.com

Acknowledgments. All authors participated in the writing of this manuscript and are responsible for its content. Eduardo Bossone assumes responsibility for the integrity of all contents of this manuscript.

Sources of funding. This work was supported by the National Institutes of Health (NIH/NHLBI US Federal Government Contract N-01-HV-68199 [National Registry of Genetically Triggered Thoracic Aortic Aneurysms and Cardiovascular Conditions]; JWW, KAE) (K23 HL102249-01; JWW).

Conflict of interest. On behalf of all authors, the corresponding author states that there are no conflicts of interest.

References

- Hiratzka LF, Bakris GL, Beckman JA et al (2010) 2010 ACCF/AHA/AATS/ACR/ASA/SCA/SCAI/SIR/STS/SVM guidelines for the diagnosis and management of patients with thoracic aortic disease: a report of the American College of Cardiology Foundation/American Heart Association Task Force on Practice Guidelines, American Association for Thoracic Surgery, American College of Radiology, American Stroke Association, Society of Cardiovascular Anesthesiologists, Society for Cardiovascular Angiography and Interventions, Society of Interventional Radiology, Society of Thoracic Surgeons, and Society for Vascular Medicine. *Circulation* 121:e266–e369
- Erbel R, Alfonso F, Boileau C et al (2001) Diagnosis and management of aortic dissection. *Eur Heart J* 22:1642–1681
- Booher AM, Eagle KA, Bossone E (2011) Acute aortic syndromes. *Herz* 36:480–487
- Hagan PG, Nienaber CA, Isselbacher EM et al (2000) The International Registry of Acute Aortic Dissection (IRAD): new insights into an old disease. *JAMA* 283:897–903
- Rogers AM, Hermann LK, Booher AM et al (2011) Sensitivity of the aortic dissection detection risk score, a novel guideline-based tool for identification of acute aortic dissection at initial presentation: results from the international registry of acute aortic dissection. *Circulation* 123:2213–2218
- Harris KM, Strauss CE, Eagle KA et al (2011) Correlates of delayed recognition and treatment of acute type A aortic dissection: the International Registry of Acute Aortic Dissection (IRAD). *Circulation* 124:1911–1918
- Shiga T, Wajima Z, Apfel CC et al (2006) Diagnostic accuracy of transesophageal echocardiography, helical computed tomography, and magnetic resonance imaging for suspected thoracic aortic dissection: systematic review and meta-analysis. *Arch Intern Med* 166:1350–1356
- Nienaber CA, Kodolitsch V von, Nicolas V et al (1993) The diagnosis of thoracic aortic dissection by noninvasive imaging procedures. *N Engl J Med* 328:1–9
- Moore AG, Eagle KA, Bruckman D et al (2002) Choice of computed tomography, transesophageal echocardiography, magnetic resonance imaging, and aortography in acute aortic dissection: International Registry of Acute Aortic Dissection (IRAD). *Am J Cardiol* 89:1235–1238
- Evangelista A, Flachskampf FA, Erbel R et al (2010) Echocardiography in aortic diseases: EAE recommendations for clinical practice. *Eur J Echocardiogr* 11:645–658
- Bireley WR II, Diniz LO, Groves EM et al (2007) Orthogonal measurement of thoracic aorta luminal diameter using ECG-gated high-resolution contrast-enhanced MR angiography. *J Magn Reson Imaging* 26:1480–1485
- Mendoza DD, Kochar M, Devoreux RB et al (2011) Impact of image analysis methodology on diagnostic and surgical classification of patients with thoracic aortic aneurysms. *Ann Thorac Surg* 92:904–912
- Scherthaner MB, Edelhauser G, Berzaczky D et al (2010) Perceptibility and quantification of in-stent stenosis with six peripheral arterial stent types in vitro: comparison of 16-MDCT angiography, 64-MDCT angiography, and MR angiography. *AJR Am J Roentgenol* 194:1346–1351
- Morita S, Masukawa A, Suzuki K et al (2011) Unenhanced MR angiography: techniques and clinical applications in patients with chronic kidney disease. *Radiographics* 31:E13–E33
- Blanke P, Bulla S, Baumann T et al (2010) Thoracic aorta: prospective electrocardiographically triggered CT angiography with dual-source CT—feasibility, image quality, and dose reduction. *Radiology* 255:207–217
- Evangelista A, Dominguez R, Sebastia C et al (2003) Long-term follow-up of aortic intramural hematoma: predictors of outcome. *Circulation* 108:583–589
- Park GM, Ahn JM, Kim DH et al (2011) Distal aortic intramural hematoma: clinical importance of focal contrast enhancement on CT images. *Radiology* 259:100–108
- Wu MT, Wang YC, Huang YL et al (2011) Intramural blood pools accompanying aortic intramural hematoma: CT appearance and natural course. *Radiology* 258:705–713
- Srichai MB, Junor C, Rodriguez LL et al (2006) Clinical, imaging, and pathological characteristics of left ventricular thrombus: a comparison of contrast-enhanced magnetic resonance imaging, transthoracic echocardiography, and transesophageal echocardiography with surgical or pathological validation. *Am Heart J* 152:75–84
- Weinsaft JW, Kim HW, Shah DJ et al (2008) Detection of left ventricular thrombus by delayed-enhancement cardiovascular magnetic resonance prevalence and markers in patients with systolic dysfunction. *J Am Coll Cardiol* 52:148–157
- Kumar A, Green JD, Sykes JM et al (2011) Detection and quantification of myocardial reperfusion hemorrhage using T2*-weighted CMR. *JACC Cardiovasc Imaging* 4:1274–1283
- Yucel EK, Steinberg FL, Eglin TK et al (1990) Penetrating aortic ulcers: diagnosis with MR imaging. *Radiology* 177:779–781
- Demarco JK, Ota H, Underhill HR et al (2010) MR carotid plaque imaging and contrast-enhanced MR angiography identifies lesions associated with recent ipsilateral thromboembolic symptoms: an in vivo study at 3T. *AJNR Am J Neuroradiol* 31:1395–1402
- Min JK, Edwardes M, Lin FY et al (2011) Relationship of coronary artery plaque composition to coronary artery stenosis severity: results from the prospective multicenter ACCURACY trial. *Atherosclerosis* 219:573–578
- Suzuki T, Katoh H, Watanabe M et al (1996) Novel biochemical diagnostic method for aortic dissection. Results of a prospective study using an immunoassay of smooth muscle myosin heavy chain. *Circulation* 93:1244–1249
- Suzuki T, Katoh H, Tsuchio Y et al (2000) Diagnostic implications of elevated levels of smooth-muscle myosin heavy-chain protein in acute aortic dissection. The smooth muscle myosin heavy chain study. *Ann Intern Med* 133:537–541
- Suzuki T, Katoh H, Kurabayashi M et al (1997) Biochemical diagnosis of aortic dissection by raised concentrations of creatine kinase BB-isozyme. *Lancet* 350:784–785
- Suzuki T, Distante A, Zizza A et al (2008) Preliminary experience with the smooth muscle tropinin-like protein, calponin, as a novel biomarker for diagnosing acute aortic dissection. *Eur Heart J* 29:1439–1445
- Shinohara T, Suzuki K, Okada M et al (2003) Soluble elastin fragments in serum are elevated in acute aortic dissection. *Arterioscler Thromb Vasc Biol* 23:1839–1844
- Makita S, Ohira A, Tachieda R et al (2000) Behavior of C-reactive protein levels in medically treated aortic dissection and intramural hematoma. *Am J Cardiol* 86:242–244
- Sangiorgi G, Trimarchi S, Mauriello A et al (2006) Plasma levels of metalloproteinases-9 and -2 in the acute and subacute phases of type A and type B aortic dissection. *J Cardiovasc Med* 7:307–315
- Matt P, Schoenhoff F, Habashi J et al (2009) Circulating transforming growth factor-beta in Marfan syndrome. *Circulation* 120:526–532
- Suzuki T, Trimarchi S, Sawaki D et al (2011) Circulating transforming growth factor-beta levels in acute aortic dissection. *J Am Coll Cardiol* 58:775
- Shimony A, Filion KB, Mottillo S et al (2011) Meta-analysis of usefulness of D-dimer to diagnose acute aortic dissection. *Am J Cardiol* 107:1227–1234
- Suzuki T, Distante A, Zizza A et al (2009) Diagnosis of acute aortic dissection by D-dimer: the International Registry of Acute Aortic Dissection Substudy on Biomarkers (IRAD-Bio) experience. *Circulation* 119:2702–2707
- Sbarouni E, Georgiadou P, Marathias A et al (2007) D-dimer and BNP levels in acute aortic dissection. *Int J Cardiol* 122:170–172
- Ohlmann P, Faure A, Morel O et al (2006) Diagnostic and prognostic value of circulating D-dimers in patients with acute aortic dissection. *Crit Care Med* 34:1358–1364
- Hazui H, Fukumoto H, Negoro N et al (2005) Simple and useful tests for discriminating between acute aortic dissection of the ascending aorta and acute myocardial infarction in the emergency setting. *Circ J* 69:677–682
- Akutsu K, Sato N, Yamamoto T et al (2005) A rapid bedside D-dimer assay (cardiac D-dimer) for screening of clinically suspected acute aortic dissection. *Circ J* 69:397–403
- Eggebrecht H, Naber CK, Bruch C et al (2004) Value of plasma fibrin D-dimers for detection of acute aortic dissection. *J Am Coll Cardiol* 44:804–809
- Weber T, Hogler S, Auer J et al (2003) D-dimer in acute aortic dissection. *Chest* 123:1375–1378
- Tsai TT, Nienaber CA, Eagle KA (2005) Acute aortic syndromes. 112: 3802–3813

Biomarkers of aortic diseases

Toru Suzuki, MD,^a Eduardo Bossone, MD,^{b,c} Daigo Sawaki, MD,^c Rolf Alexander János, MD,^d Raimund Erbel, MD,^c Kim Eagle, MD,^c and Ryozo Nagai, MD^a *Tokyo, Japan; Milan, and Salerno, Italy; Essen, Germany; and Ann Arbor, MI*

The development of diagnostic biomarkers of acute cardiovascular disease remains an important topic of interest given potential use to aid in early diagnosis. Cardiac biomarkers of ischemia and heart failure have already proven to be clinically useful. Biomarkers of aortic diseases are also needed, especially for life-threatening conditions such as aortic dissection. In this review, we discuss the present status of the development of biomarkers of aortic diseases. Although aortic dissection has been most vigorously pursued, there has also been notable recent progress in biomarkers of aneurysms and inflammatory aortic disease. (*Am Heart J* 2013;165:15-25.)

Approximately 150,000 studies have discussed thousands of potential clinically useful biomarkers, but currently, only about 100 biomarkers have been “translated” for use in the clinic.¹ These tremendously difficult odds of success (0.07%, or 1/1500) reflect the difficulties not only in discovering a new biomarker but also the additional effort that is necessary to validate findings in additional patient cohorts and then to pursue clinical trials for necessary administrative approval. Such development also requires industrial and financial support to create a platform for clinical use that often takes a decade or more. It is not surprising, therefore, that many potentially interesting biomarkers drop out along this process before becoming clinically available.

Cardiac biomarkers such as those for myocardial necrosis (eg, cardiac troponin) and heart failure (eg, natriuretic peptides) have proven successful.²⁻⁴ Aortic markers have also been pursued ranging from those for acute disease targeting aortic catastrophes to chronic markers for atherosclerotic disease (eg, aneurysms) and inflammatory markers (eg, aortitis). The present state of progress in this field will be discussed herein.

Aortic dissection

Acute aortic dissection (AAD) has been most pursued as a target for diagnostic biomarkers in the aorta and vasculature. This disease would benefit from biomarkers as an assistive tool because it still remains a challenge to diagnose.^{5,6} Variability in presentation and excessive early mortality makes early diagnosis both uncertain and critical. Dissection may present with symptoms that range from typical sudden-onset chest pain to an atypical neurologic deficit, cramping abdominal pain, or back pain.⁷ A clinical risk score for detecting AAD, the aortic dissection detection risk score, has been proposed by the American Heart Association/American College of Cardiology guideline committee to help identify patients at risk for this condition, and it has been confirmed to be highly sensitive for detection of the condition by the International Registry of Acute Aortic Dissection (IRAD) study group.^{8,9} The initial decision whether to obtain a definitive imaging test may also be limited by issues such as cost and/or availability. Delay in time to diagnosis for AAD is a recognized issue that needs to be improved upon because every minute until diagnosis counts in this condition with a high mortality of approximately 1%/h.¹⁰ A widely available and cost-effective measure such as a blood test that can rule in and/or rule out the disease would indeed aid in the diagnosis of the disease, benefiting patients and caregivers alike.^{8,11}

Benefits of biomarkers when used with standard imaging techniques

Acute aortic dissection has become more identifiable and treatable in the current era owing to recent advances in diagnostic methods, especially imaging modalities, as well as in management and therapeutic approaches. In a

From the ^aDepartment of Cardiovascular Medicine, The University of Tokyo, Tokyo, Japan, ^bDepartment of Cardiac Surgery, I.R.C.C.S. Policlinico San Donato, Milan, Italy, ^cDepartment of Cardiology and Cardiac Surgery, University Hospital “Scuola Medica, Salernitana,” Salerno, Italy, ^dDepartment of Cardiology, University of Duisburg-Essen, West-German Heart Center, Essen, Germany, and ^eDepartment of Cardiology, University of Michigan, Ann Arbor, MI.

Submitted June 12, 2012; accepted October 5, 2012.

Reprint requests: Toru Suzuki, MD, Department of Cardiovascular Medicine, Graduate School of Medicine, The University of Tokyo, 7-3-1 Hongo, Bunkyo-ku, Tokyo 113-8655, Japan.

E-mail: torusuzu-ky@umin.ac.jp

0002-8703/\$ - see front matter

© 2013, Mosby, Inc. All rights reserved.

<http://dx.doi.org/10.1016/j.ahj.2012.10.006>

recent meta-analysis that encompassed 119 patients from 16 studies, transesophageal echocardiography, computed tomography (CT), and magnetic resonance imaging showed comparable pooled sensitivity (98%-100%) and specificity (95%-98%).¹² According to observations from the IRAD study, two-thirds of patients suspected of AAD undergo multimodality imaging, thus highlighting the importance of follow-up imaging tests when there remains clinical suspicion even with an initial negative or equivocal result.¹³ Management of patients with AAD depends on identification of the anatomy (eg, site, extension) of the dissection in addition to complications (eg, end-organ involvement), which affects therapeutic approaches and prognosis. Imaging is thus the key diagnostic modality for this condition.

The most important role of diagnostic biomarkers of AAD lies in use in triaging patients to identify patients who should undergo rapid imaging, thus allowing for prompt initiation of treatment. As proposed in Figure 1, a simple diagnostic algorithm might be helpful in making an initial decision for patients with suspected AAD in which biomarker testing is used with other rapid tests. Biomarkers with high specificity will likely be useful to this extent. For instance, smooth muscle myosin with a specificity of 98% against healthy volunteers and 83% against patients with acute myocardial infarction as a disease with similar presentation of chest symptoms¹⁴ would be attractive as a "rule-in" test. Equally important is that biomarkers are potentially useful to "rule-out" AAD in suspicious patients. Because AAD has been the subject of litigation due to misdiagnosis,⁶ a blood test that can help rule out the disease would indeed be of use, such as use of D-dimer to rule out both AAD and pulmonary embolism (PE) in patients with chest pain, as will be discussed in detail hereafter. In this instance, biomarkers with a high sensitivity as is the case for D-dimer with a sensitivity of >95% for AAD would be ideal.¹⁵ An ideal biomarker would be one with both high specificity and high sensitivity and would thus be a "golden biomarker," but at this stage, there is yet to be one that is ideal for both, and thus, uses of biomarkers need to take into account their strengths and weaknesses in diagnostic properties or use a combination of such to provide for comprehensive testing.

The clinical setting and environment also play an important role in defining the usefulness of biomarker testing. In the setting in which imaging modalities such as CT are readily available in the emergency setting, biochemical testing will play a supplemental role. However, in community hospitals or clinics that do not have available advanced imaging methods, biochemical testing might be pivotal to aid in the initial diagnostic decision as to whether to send the patient home or refer to a tertiary center. Another point that should be made is that biomarkers reflect pathogenic activity and that they reflect whether the lesion is in

active or nonactive stages. For example, when examining an asymptomatic patient with an AAD on CT, which is not uncommon, biomarkers might help in the decision making in determining whether the lesion is of acute onset, which would require immediate attention (eg, admission and surgical consult).

Other important roles of biomarkers in AAD involve risk stratification or prognostic evaluation in subacute to chronic phases. Studies have shown that increased FDG uptake is a marker of active inflammation in the aortic wall and branches.¹⁶ Detection of increased inflammatory change by 18F-fluorodeoxy glucose (FDG)-positive positron emission tomography/CT may help to differentiate acute from chronic AAD.¹⁷ Vascular/aortic biomarkers that reflect remodeling (eg, transforming growth factor α [TGF- α]) might strengthen risk prediction when used in combination with these modalities, which can evaluate metabolic and inflammatory processes with precise anatomic localization.

Pathophysiology of aortic dissection and biomarkers

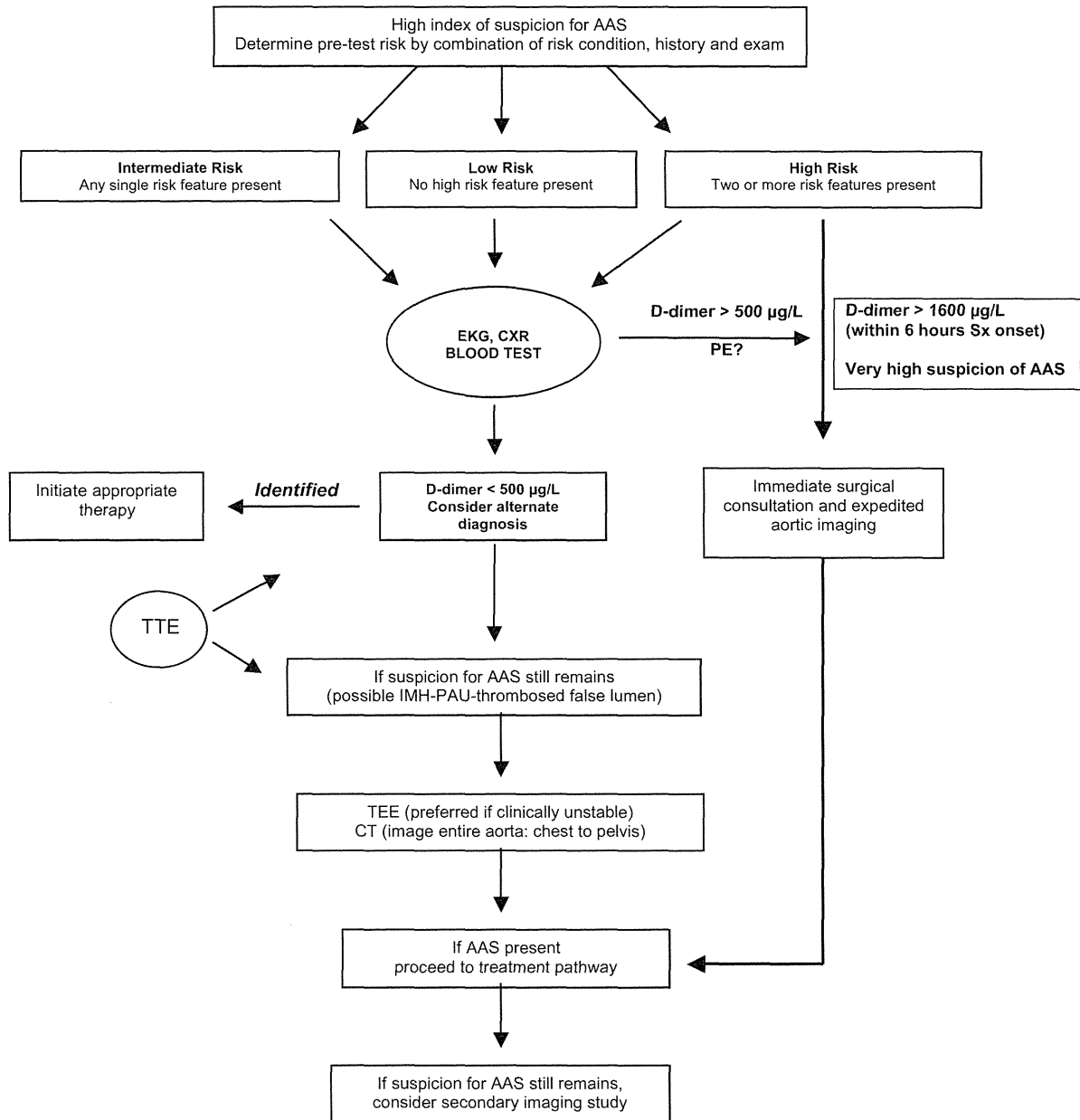
Acute aortic dissection is generally an age-related disease seen predominantly in the elderly, excluding patients with Marfan syndrome (MFS) who have a fragile aorta and are genetically predisposed to dissect in younger adolescent stages. The most common risk factor of elderly AAD is hypertension, which accompanies more than 70% of patients.⁷ About 50% of DeBakey type I/II and 80% of type III lesions have been reported to have a history of hypertension.¹⁸ A common histologic characteristic is cystic medial necrosis with elastic layer degradation and destruction, deposition of proteoglycans, and medial smooth muscle cell apoptosis. In these processes, inflammatory reactions play a role in pathogenic destruction of the media, which eventually leads to aortic dilatation, dissection, and, finally, rupture of the aortic wall. Fibrotic or fibrolytic biomarkers likely reflect these degradation processes. Once aortic dissection occurs, injury and destruction of the medial smooth muscle layer likely result in smooth muscle cell protein release and increased levels in circulating blood. False lumen thrombus formation/degradation, in turn, likely regulates thrombotic and thrombolytic markers. Acute aortic dissection is also associated with an inflammatory response, as evidenced by an accompanying elevation in inflammatory markers such as C-reactive protein (CRP).

Smooth muscle markers

Smooth muscle myosin heavy chain

Circulating smooth muscle myosin heavy chain (SM-MHC) shows marked elevations in patients with AAD (eg, dynamic range of approximately 20-fold higher levels in

Figure 1



Diagnostic algorithm of AAD using D-dimer and imaging. AAS, acute aortic syndrome; blood test: electrolytes, blood gases and H⁺, glucose, creatinine, amylase, CRP, hemoglobin, cardiac markers, brain-specific protein, D-dimer, and coagulation markers; CXR: chest x-ray; ECG, electrocardiogram; IMH, intramural hematoma; PAU, penetrating atherosclerotic ulcer; TTE, transthoracic echocardiogram; TEE, transesophageal echocardiogram. Modified from Hiratzka et al⁸.

dissected patients after onset as compared with baseline levels seen in chronic stages). Smooth muscle is predominantly found in the aortic medial layer, which, at onset and during the evolution of dissection, is injured, leading to release of cellular proteins into the circulation.

The time course of this marker showed elevations limited to the initial 3 to 6 hours after onset of symptoms similar to myoglobin in myocardial ischemia (aortic dissection 30.8 ± 13.9 ng/mL vs healthy controls 0.9 ± 0.1 ng/mL, cutoff value 2.5 ng/mL, sensitivity 90% and specificity