

厚生労働科学研究費補助金（難治性疾患克服研究事業）  
分担研究報告書

kenkou\_iryoyu/iyakuhin/kaihatsuyousei/list120  
423.html

(2013年2月2日アクセス)

- 3) FDA HP より、the Food and Drug  
Administration Safety and Innovation Act  
<http://www.gpo.gov/fdsys/pkg/PLAW-112publ144/pdf/PLAW-112publ144.pdf>

(2013年2月2日アクセス)


- 4) EMA HP より、Enpr-EMA  
[http://www.ema.europa.eu/ema/index.jsp?curl=pages/partners\\_and\\_networks/general/general\\_content\\_000303.jsp&mid=WC0b01ac05801df74a](http://www.ema.europa.eu/ema/index.jsp?curl=pages/partners_and_networks/general/general_content_000303.jsp&mid=WC0b01ac05801df74a)

(2013年2月2日アクセス)

- 5) 厚生労働省 HP より、革新的医薬品・医療機器・再生医療製品実用化促進事業について  
[http://www.mhlw.go.jp/seisakunitsuite/bunya/kenkou\\_iryoyu/iyakuhin/kakushin/](http://www.mhlw.go.jp/seisakunitsuite/bunya/kenkou_iryoyu/iyakuhin/kakushin/)

(2013年2月2日アクセス)

研究成果の刊行物・別刷り



## Effects of idursulfase enzyme replacement therapy for Mucopolysaccharidosis type II when started in early infancy: Comparison in two siblings

Go Tajima <sup>a</sup>, Nobuo Sakura <sup>a</sup>, Motomichi Kosuga <sup>b</sup>, Torayuki Okuyama <sup>b,\*</sup>, Masao Kobayashi <sup>a</sup>

<sup>a</sup> Department of Pediatrics, Hiroshima University Hospital, Hiroshima, Japan

<sup>b</sup> Center for Lysosomal Storage Diseases, National Center for Child Health and Development, Tokyo, Japan

### ARTICLE INFO

#### Article history:

Received 26 December 2012

Accepted 26 December 2012

Available online 9 January 2013

#### Keywords:

Mucopolysaccharidosis type II  
Enzyme replacement therapy

### ABSTRACT

Mucopolysaccharidosis type II (MPS II) is a lysosomal storage disorder that is progressive and involves multiple organs and tissues. While enzyme replacement therapy (ERT) with idursulfase has been shown to improve many somatic features of the disease, some such as dysostosis multiplex and cardiac valve disease appear irreversible once established, and little is known about the preventative effects of ERT in pre-symptomatic patients. We report on two siblings with severe MPS II caused by an inversion mutation with recombination breakpoints located within the *IDS* gene and its adjacent pseudogene, *IDS-2*. The siblings initiated treatment with idursulfase at 3.0 years (older brother) and 4 months (younger brother) of age, and we compared their outcomes following 2 years of treatment. At the start of treatment, the older brother showed typical features of MPS II, including intellectual disability. After 34 months of ERT, his somatic disease was stable or improved, but he continued to decline cognitively. By comparison, after 32 months of ERT his younger brother remained free from most of the somatic features that had already appeared in his brother at the same age, manifesting only exudative otitis media. Skeletal X-rays revealed characteristic signs of dysostosis multiplex in the older brother at the initiation of treatment that were unchanged two years later, whereas the younger brother showed only slight findings of dysostosis multiplex throughout the treatment period. The younger brother's developmental quotient trended downward over time to just below the normal range. These findings suggest that pre-symptomatic initiation of ERT may prevent or attenuate progression of the somatic features of MPS II. Follow-up in a larger number of patients is required to confirm the additive long-term benefits of ERT in pre-symptomatic patients.

© 2013 Elsevier Inc. All rights reserved.

### 1. Introduction

Mucopolysaccharidosis (MPS) type II (Hunter syndrome, OMIM #309900), is an inborn error of glycosaminoglycan (GAG) metabolism caused by deficient activity of lysosomal iduronate 2-sulfatase (IDS, EC 3.1.6.13). The responsible gene, *IDS*, is located on chromosome Xq28, and the disease shows classic X-linked recessive inheritance. Rarely, females may be affected as a result of biallelic mutations, skewed X-inactivation, uniparental isodisomy, or X-autosome translocations [1,2]. Dermatan sulfate and heparan sulfate, the substrates for IDS, accumulate in the lysosomes of various tissues and organs of affected patients, leading to the development of characteristic signs and symptoms of MPS II after the first year of life. (HOS reference). Somatic features include coarse facies, straw-like hair, rough and thickened skin, macrocephaly, disproportionate short stature due to dysostosis multiplex, decreased joint mobility, cardiac valve disease and left ventricular hypertrophy, hepatosplenomegaly, obstructive sleep apnea, and restrictive lung disease. Frequent otitis media and hernias

(inguinal and umbilical) may be the earliest presenting signs, but are non-specific. Patients with little to no IDS activity (severe form) exhibit progressive somatic disease, cognitive decline, and death during adolescence (HOS). Patients with some residual IDS activity (mild form) have largely somatic disease with normal intellectual development [3].

In recent years, enzyme replacement therapy (ERT) with recombinant human iduronate-2-sulfatase (idursulfase, Elaprase®, Genzyme, a Sanofi Company and Shire Human Genetic Therapies, Cambridge, MA) has been available for the treatment of MPS II. Weekly infusions of idursulfase have been shown to improve walking capacity, hepatosplenomegaly, and urinary GAG levels [4]. However, ERT appears to be less effective in correcting disease manifestations once developed in the skeletal system and heart valves [5,6]. Intravenously administered ERT has not been shown to slow or prevent the deterioration of the central nervous system in patients with the severe phenotype, most likely because it does not cross blood-brain barrier at the labeled dose [7]. Although idursulfase is approved for use only in patients who are at least 5 years of age, a recent report from the Hunter Outcome Survey (HOS) suggests that it can safely reduce urinary GAG levels and hepatomegaly in young children, some

\* Corresponding author. Fax: +81 3 3417 2238.

E-mail address: [tora@nch.go.jp](mailto:tora@nch.go.jp) (T. Okuyama).

of whom were below 1 year of age [8]. Recognizing that MPS II is a progressive disease that has some irreversible features, a panel of MPS II experts has recommended starting ERT as early as possible to achieve the best outcomes [9].

In this report, we describe our treatment experience in two Japanese brothers with the severe form of MPS II who started ERT at 4 months of age (pre-symptomatic) and 3 years of age (symptomatic). Our findings suggest that early, pre-symptomatic treatment is associated with a better clinical outcome as evidenced by the amelioration or prevention of certain somatic manifestations, e.g. dysostosis multiplex and cardiac valve disease, which once established, appear to be irreversible.

## 1.1. Case report

### 1.1.1. Patient 1 (older brother)

A 2 year 7 month old boy presented to our metabolism clinic with dysmorphic features, cardiac and skeletal disease, and severe developmental delay. He was the first child born to non-consanguineous Japanese parents. Following an uneventful pregnancy and neonatal period, he was noted to have a small ventricular septal defect during a febrile illness at 3 months of age. At 9 months of age, the ventricular septal defect had closed but mild mitral valve regurgitation was present. His parents noticed a gibbus deformity at approximately 1 year of age, and by age 2 he had developed stiffness in his elbow and fingers. His psychomotor development was moderately delayed: he walked at 1.5 years and was still non-verbal. Other past medical history was notable for a febrile seizure, umbilical hernia, enlarged adenoids, and bilateral otitis media. On physical examination, the boy had a coarse facies and disproportionately short limbs. His was above average in height (92.2 cm, +0.6 SD), overweight (17.0 kg, +3.2 SD), and had macrocephaly (50 cm, +0.5 SD). He had marked hepatomegaly and a nonpalpable spleen. Urinary GAG analysis revealed an elevated uronic acid level of 254 mg/g creatinine (normal mean  $\pm$  SD, 30.0  $\pm$  12.8) with increased amounts of dermatan sulfate (63%) and heparan sulfate (12%) relative to chondroitin sulfate (25%), consistent with MPS I or II. The diagnosis of MPS II was confirmed by the absence of detectable IDS activity in leukocytes.

No potential disease-causing mutation was found by sequencing all 9 exons of the IDS gene and their intron-exon junctions by conventional PCR-based methods [10]. To detect a recombination mutation between IDS and its adjacent putative pseudogene, IDS-2, that leads to an inversion and non-functional IDS gene, we performed a simple and rapid assay involving two PCR reactions. The first reaction selectively amplifies a 2.8 kb DNA fragment from the recombinant gene but not the wild type IDS gene, while the second reaction selectively amplifies a 3.5 kb DNA fragment from the wild type IDS gene but not the recombinant gene (Fig 1a) [11]. Genetic testing of the patient revealed an abnormal banding pattern indicative of recombination between the IDS gene and the IDS-2 pseudogene (Fig 1b).

### 1.1.2. Patient 2 (younger brother)

The younger brother was born just after his older brother was diagnosed with MPS II. Birth weight (2.966 kg) and length (47 cm) were normal for his gestational age of 39 weeks. There were no abnormal findings on initial physical examination, but the urinary uronic acid level was elevated at 423 mg/g creatinine (normal mean  $\pm$  SD, 43.4  $\pm$  12.9), and urinary GAG analysis showed increased amounts of dermatan sulfate (55%) and heparan sulfate (11%) relative to chondroitin sulfate (34%). IDS activity in leukocytes was below the detectable limit. As expected, Patient 2 had the same recombination mutation as his older brother.

**1.1.2.1. Enzyme replacement therapy.** Treatment with intravenous recombinant idursulfase was started at 3.0 years of age for Patient 1 and 4 months of age for Patient 2. Although the recommended dose of idursulfase is 0.5 mg/kg/week, Patient 1 received only

0.3–0.4 mg/kg/week for the first 1.5 years until his weight reached 20 kg (4.5 years of age) because of a restriction by the health insurance system; subsequently, he received 0.5 mg/kg/week of idursulfase. The dose for Patient 2 was 0.5 mg/kg/week from the start of treatment. As of December 2012, Patients 1 and 2 had received ERT for 34 and 32 months, respectively. Both patients have tolerated ERT well with only mild and intermittent urticaria.

## 2. Results

### 2.1. Urinary GAG

The uronic acid in urine was measured at several time points after initiation of ERT using the carbazole reaction method (SRL Medisearch, Tokyo, Japan). Fig. 2 shows the changes observed in both patients over time. In Patient 1, the uronic acid level decreased to approximately half of the baseline level after 3 months and then plateaued at 130–180 mg/g creatinine (29–49% reduction from baseline) (Fig. 2a). The uronic acid level in Patient 2 showed a continuous decrease to below 100 mg/g creatinine (76% reduction from baseline), but remains above the normal range (Fig. 2b).

### 2.2. Liver and spleen size

The liver edge of Patient 1 extended 4 cm below the right costal margin at baseline, and it rapidly became non-palpable after the initiation of ERT. The spleen was not palpable at any time, and by ultrasound, it was at the upper limit of normal size for age and remained stable during the first 28 months of ERT. Patient 2's liver and spleen were normal in size before and during ERT.

### 2.3. Cardiac function

At baseline, Patient 1's echocardiogram revealed moderate mitral valve regurgitation and a mildly distorted left ventricular wall, although the ejection fraction was normal at 69%. These findings showed little change after 22 months of ERT. In Patient 2, no abnormalities were detected by echocardiography before and after 11 months of ERT.

### 2.4. Respiratory and Hearing

Patient 1 had bilateral exudative otitis media and adenoid hypertrophy at baseline that did not respond well to ERT. Although an adenoidectomy was performed at 3.5 years of age, exudative otitis media and hearing impairment persisted. Patient 2 also had exudative otitis media during the ERT period. Neither patient developed sleep apnea.

### 2.5. Skeletal X-rays

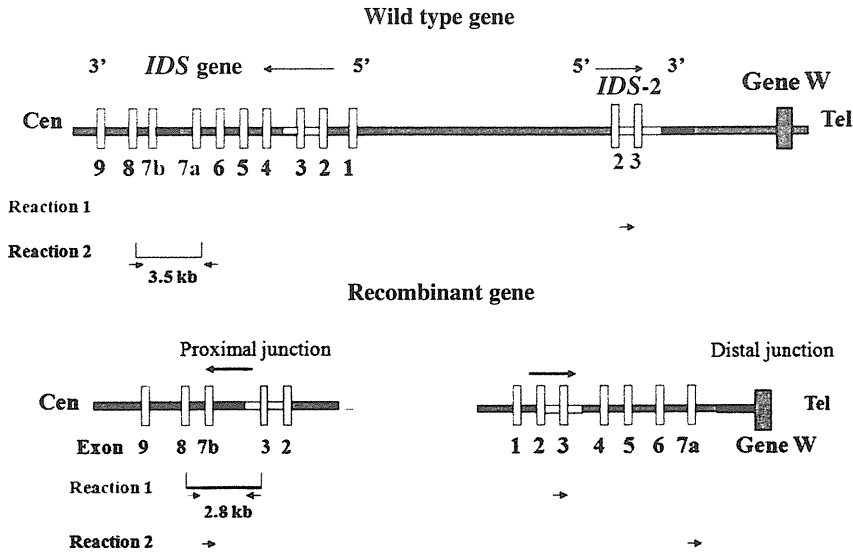
At baseline, dysostosis multiplex was already apparent in Patient 1. The most prominent findings were hypoplastic changes of the vertebral bodies giving rise to a characteristic protrusion of the antero-inferior surface, the so-called inferior tongue. Other mild signs of dysostosis multiplex included oar-like ribs, bullet-shaped phalanges, and iliac flaring. After 27 months of ERT, these findings showed little change. Similar, but milder findings of oar-like ribs and bullet-shaped phalanges were present in Patient 2 at 3 months of age. After 25 months of ERT, "inferior tongue" had become notable and oar-like ribs had progressed (data not shown).

### 2.6. Joints

Patient 1 had stiffness in multiple joints of his extremities at baseline. There was no obvious change with ERT, although accurate


**a**

**Recombination of *IDS* and *IDS-2***



**b**

**Recombination of *IDS* gene and *IDS2* gene (PCR amplification)**



	Wild type	Recombinant
<b>Reaction 1 (<i>IDS-IDS2</i>)</b>	(-)	2.8 kb
<b>Reaction 2 (exon7F-8Rv)</b>	3.5 kb	(-)

M Marker  
 Lane1 Patient 1  
 Lane2 Confirmed patient  
 Lane3 Heterozygous carrier  
 Lane4 Normal control  
 Lane5 NTC

**Fig. 1.** Genetic diagnosis of MPS II by detecting recombination of the *IDS* and *IDS-2* genes. The pseudogene *IDS-2*, which consists of sequences that are homologous to exons 2 and 3 and intron 7 of the *IDS* gene, is located ~20 kb telomeric to *IDS* in Xq27.3–q28. In the recombinant gene, exons 1, 4, 5, 6, 7a are translocated to the *IDS-2* locus, thereby grossly altering the structure of the *IDS* gene. PCR reaction 1 amplified a 2.8 kb fragment of the recombinant gene in Patients 1 and 2 and the heterozygous carrier, but not in the normal control. PCR reaction 2 amplified a 3.5 kb fragment of the wild-type *IDS* gene in the heterozygous carrier and normal control, but not in the two patients.

measurement was difficult. Patient 2 had normal joint mobility that was maintained during ERT.

**3. Magnetic resonance imaging of the central nervous system**

By MRI, Patient 1 had dilated perivascular spaces in the cerebral white matter both at baseline and after 22 months of ERT, and at

the latter timepoint, mild dilatation of the lateral ventricles also was apparent. At baseline, Patient 2's MRI showed only subtle changes in the corpus callosum that were suggestive of dilated perivascular spaces. After 14 months ERT, the dilated perivascular spaces became more typical and resembled those of his brother. Patient 2 did not show any evidence of hydrocephalus or cerebral atrophy (Data not shown).

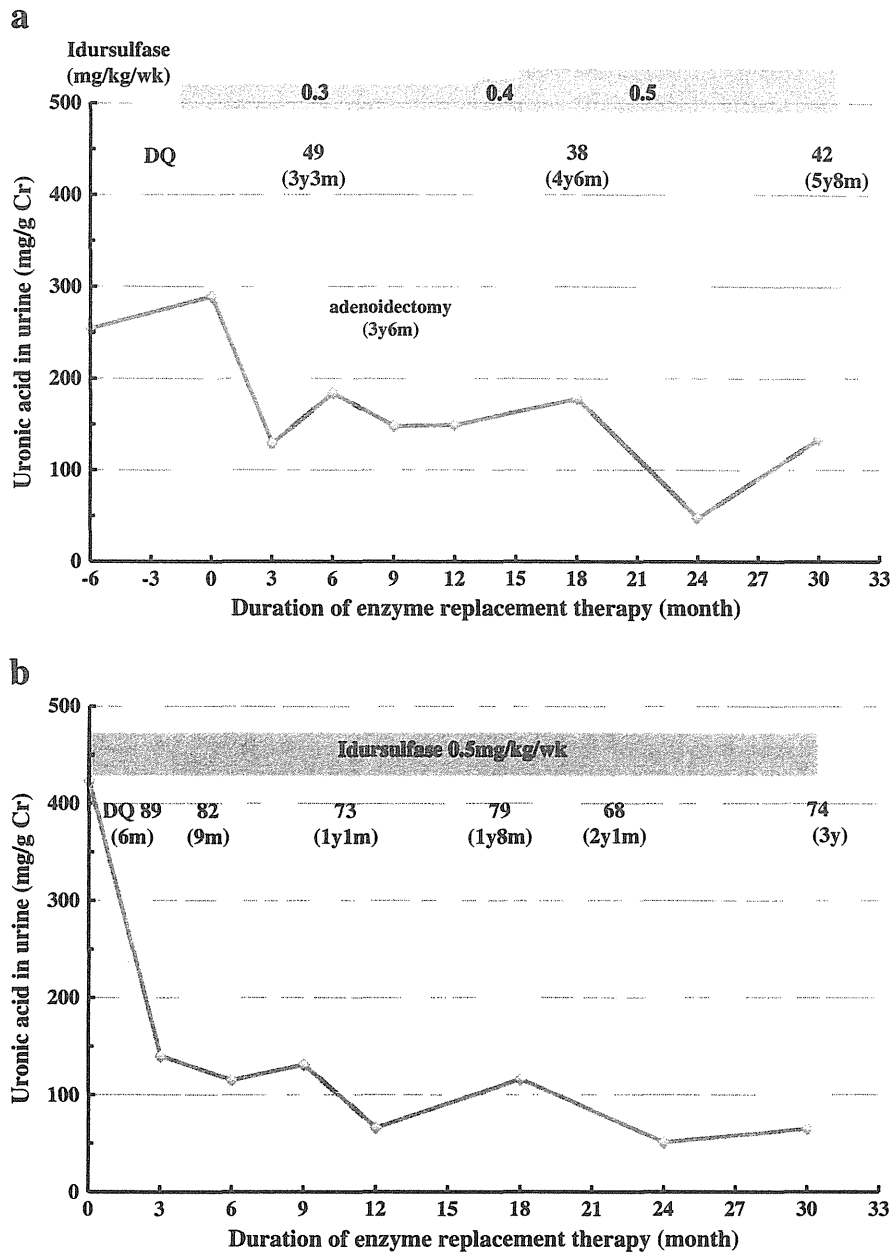


Fig. 2. Uronic acid level in urine and developmental quotient (DQ) during ERT for (a) Patient 1 and (b) Patient 2. Idursulfase was administered to Patient 1 at a reduced dose for more than 1 year because of a restriction from the health insurance system.

### 3.1. Psychomotor development

The developmental quotient (DQ) score of Patient 1 was already low at baseline (DQ=49), and it declined further after 34 months of ERT (DQ=42). He barely acquired any words, and behavioral problems, such as hyperactivity, were becoming significant. The DQ score of Patient 2 was initially normal, but then fell to just below the normal range during ERT. His DQ scores at 6, 9, 13, 18, 21 and 34 months of age were 89, 82, 73, 79, 68 and 74 respectively. He recently learned to walk, but he does not yet speak any words.

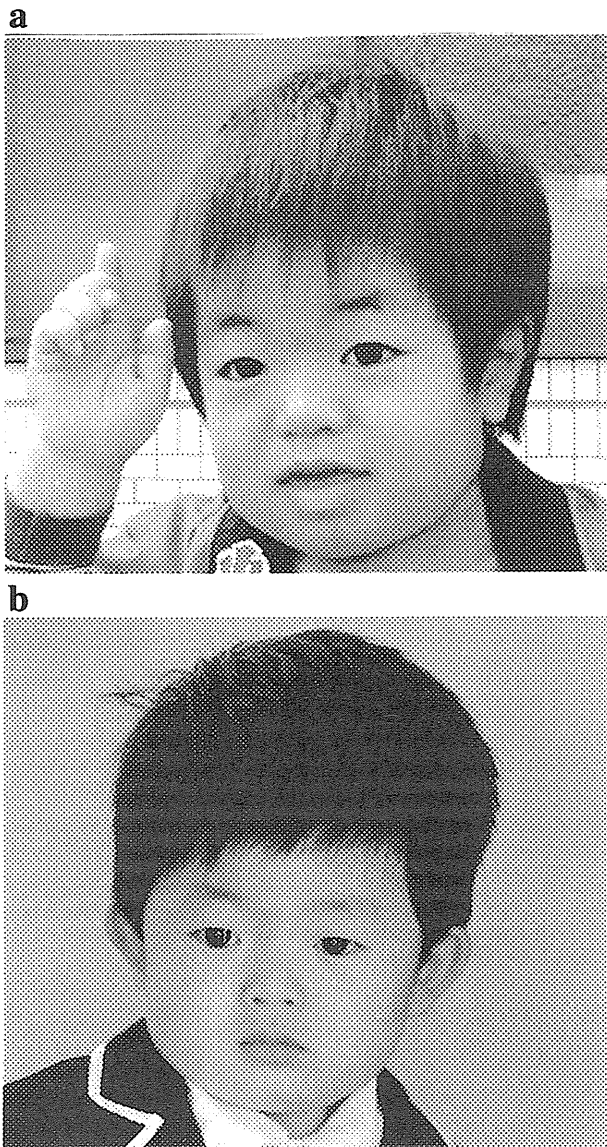
These observations are summarized in Table 1.

### 3.2. Facial appearance

The preventative effects of ERT on facial appearance were evident in Patient 2 (Fig. 3b; 2 years and 10 months old) compared with

Table 1  
Clinical features of the patients.

	Patient 1 (elder brother)		Patient 2 (younger brother)	
Start of ERT	3y0m		0y4m	
Duration of ERT	34 m		32 m	
Clinical symptoms	before ERT (3y0m)	after ERT (5y10m)	before ERT (0y4m)	after ERT (3y0m)
Coarse features of face	yes	stable	no	no
Thick and coarse skin	yes	improved	no	no
Hepatosplenomegaly	yes	improved	no	no
Cardiac dysfunction	yes	stable	no	no
Problems in joints	yes	stable	no	no
Dysostosis multiplex	yes	slowly progressive	mild	slowly progressive
Exudative otitis media	yes	persistent	no	yes
Developmental quotation	49	42	89	74



**Fig. 3.** Facial appearances of the brothers. (a) Patient 1 at the age of 2 years and 9 months, before initiation of ERT. (b) Patient 2 at the age of 2 years and 10 months, after 31 months of ERT.

Patient 1 (Fig. 3a; 2 years and 9 months old). Patient 1 had coarse features affecting his nose, lips, and tongue, whereas Patient 2 did not show any MPS II-related facial features.

#### 4. Discussion

Since idursulfase ERT for MPS II became commercially available (2006 in the US; 2007 in the European Union and Japan), there has been an increasing number of reports on its clinical effects. Idursulfase has been shown to improve walking capacity while reducing hepatosplenomegaly and urinary GAG levels. The most common adverse events have been infusion-related reactions, including some reports of anaphylactic reactions [5]. However, most of the treatment effects described to date have been in patients above age 5 who manifested typical symptoms of MPS II before initiation of ERT [12,13]. The results suggest that once established, pathological changes in certain organs and tissues, e.g. the bones, joints, heart valves, and central nervous system are difficult to correct [9]. A recent analysis of the effects of ERT in patients younger than 6 years old enrolled in the Hunter Outcome Survey (HOS) has shown a similar

safety profile and reduction in hepatomegaly as in older patients [8]. Of these 124 children treated ERT, 11 initiated treatment during the first year of life, and the youngest treated was 1 month of age. However, no individual outcome data have been reported.

There is limited information on the ability of idursulfase to prevent the occurrence of disease manifestations in pre-symptomatic MPS II patients. MPS II is difficult to diagnose in early infancy before the development of typical signs and symptoms due to the insidious progression of disease [14,15]. The few patients that have been diagnosed early usually had a previously affected relative that prompted pre-symptomatic testing, as was the case for our siblings. Only one recent case report has described the effects of idursulfase ERT initiated in an asymptomatic infant with MPS II [16]. This boy was diagnosed at 14 days of life on the basis of an older affected sister, who interestingly, was found to have low IDS activity and be heterozygous for a missense mutation, p.Tyr523Cys/c.1568A>G in exon 9, with almost totally skewed X-inactivation of the normal *IDS* gene. Idursulfase (0.5 mg/kg/wk) was initiated at 3 months of life and 3-year follow-up was provided. The affected boy did not develop coarse facial features, joint disease, or organomegaly, and his cardiac function remained normal; the only abnormal finding was a mild deformity of one vertebrae. In contrast, the older sister showed typical clinical features of MPS II when she was diagnosed at age 3, including severe intellectual disability (IQ = 50) that worsened over time (IQ = 24 at age 10) despite 5 years of ERT. Considering her severe phenotype, it is surprising that her affected brother has maintained a normal IQ of 98 at 3 years of age. An earlier report had described this mutation as mild [17]. It is possible that the sister had other unknown central nervous system complications or effects of skewed X-inactivation that affected her cognitive status, or that the original assignment as a mild mutation was incorrect. Another possibility is that ERT started in early infancy had a protective effect on the central nervous system, but animal data suggest that intravenously administered idursulfase is unable to cross the blood–brain barrier at this dose.

Our experience has been similar to this recent case report, with a better outcome observed when treatment was initiated at 4 months of age instead of at 3 years of age, a difference of 2.7 years. The reduced dose that the older brother received for the initial 15 months of treatment may have contributed to some of the differences in outcomes. Nevertheless, somatic symptoms were present in Patient 1 before 2 years of age, but none were seen in Patient 2 at the same age except for possibly exudative otitis media. The only other somatic finding has been slight signs of dysostosis multiplex by X-ray. The prognosis for his mental development seems less promising, given the gradual decline in DQ from normal to slightly below normal. Although hearing problems due to chronic exudative otitis media may have contributed to the apparent decline in DQ, it has been reported that speech development is less affected in patients with mild compared to severe MPS II despite similar otological findings [18]. The inversion mutation is predicted to be a severe mutation that leads to a non-functional *IDS* gene, and in one series it was present in 13% of boys with MPS II [19]. Treatment options to prevent further deterioration of his intellectual abilities appear limited at this time. Previous reports on the therapeutic effects of hematopoietic stem cell transplantation (HSCT) in MPS II patients have generally been negative, but most patients had pre-existing CNS disease and little clinical data exists on the use of this procedure as a preventative measure in patients with normal cognitive function [20]. According to a recent report, donor-derived cells were detected in the brain of a transplanted MPS II patient [21]. To determine whether HSCT may be beneficial to MPS II patients at risk for CNS involvement, additional data must be collected on cases in which HSCT is performed as early as possible. Intrathecal delivery of ERT to treat MPS II-related CNS disease is currently being investigated in an ongoing Phase 1 clinical trial, and the results have not yet been published.


In summary, this is the second detailed case report of idursulfase ERT started in early infancy in a patient with MPS II. In contrast to

the older brother who had typical features of MPS II at the initiation of ERT that did not completely resolve after 2 years of treatment, we believe that the near absence of somatic findings in the younger brother after 2 years of treatment is attributable to early ERT administered in the pre-symptomatic state. The effect of early ERT on the younger brother's intellectual development is less clear. Long-term observation of these and other similar cases should help to clarify the extent of the preventative effects of ERT on the somatic and CNS aspects of MPS II as well as to define the optimal timing of treatment to achieve the best possible outcomes.

## References

- [1] K. Tuschl, A. Gal, E. Paschke, S. Kircher, O.A. Bodamer, Mucopolysaccharidosis type II in females: case report and review of literature, *Pediatr. Neurol.* 32 (2005) 270–272.
- [2] L.L. Pinto, T.A. Vieira, R. Giugliani, I.V. Schwartz, Expression of the disease on female carriers of X-linked lysosomal disorders: a brief review, *Orphanet J. Rare Dis.* 5 (2010) 14–23.
- [3] J.B. Holt, M.D. Poe, M.L. Escolar, Natural progression of neurological disease in mucopolysaccharidosis type II, *Pediatrics* 127 (2011) 1258–1265.
- [4] J. Muenzer, J.E. Wraith, M. Beck, R. Giugliani, P. Harmatz, C.M. Eng, A. Vellodi, R. Martin, U. Ramaswami, M. Gucsavas-Calikoglu, S. Vijayaraghavan, S. Wendt, A.C. Puga, B. Ulbrich, M. Shinawi, M. Cleary, D. Piper, A.M. Conway, A. Kimura, A phase II/III clinical study of enzyme replacement therapy with idursulfase in mucopolysaccharidosis II (Hunter syndrome), *Genet. Med.* 8 (2006) 465–473.
- [5] L.A. Clarke, Idursulfase for the treatment of mucopolysaccharidosis II, *Expert Opin. Pharmacother.* 9 (2008) 311–317.
- [6] J. Muenzer, M. Beck, C.M. Eng, R. Giugliani, P. Harmatz, R. Martin, U. Ramaswami, A. Vellodi, J.E. Wraith, M. Cleary, M. Gucsavas-Calikoglu, A.C. Puga, M. Shinawi, B. Ulbrich, S. Vijayaraghavan, S. Wendt, A.M. Conway, A. Rossi, D.A. Whiteman, A. Kimura, Long-term, open-labeled extension study of idursulfase in the treatment of Hunter syndrome, *Genet. Med.* 13 (2011) 95–101.
- [7] S.A. Sawaf, E. Mayatepek, B. Hoffmann, Neurological findings in Hunter disease: pathology and possible therapeutic effects reviewed, *J. Inher. Metab. Dis.* 31 (2008) 473–480.
- [8] J. Muenzer, M. Beck, R. Giugliani, Y. Suzuki, A. Tylki-Szymanska, V. Valayannopoulos, A. Vellodi, J.E. Wraith, Idursulfase treatment of Hunter syndrome in children younger than 6 years: results from the Hunter Outcome Survey, *Genet. Med.* 13 (2011) 102–109.
- [9] J.E. Wraith, M. Scarpa, M. Beck, O.A. Bodamer, L. De Meirleir, N. Guffon, A. Meldgaard Lund, G. Malm, A.T. Van der Ploeg, J. Zeman, Mucopolysaccharidosis type II (Hunter syndrome): a clinical review and recommendations for treatment in the era of enzyme replacement therapy, *Eur. J. Pediatr.* 167 (2008) 267–277.
- [10] J.J. Hopwood, S. Bunge, C.P. Morris, P.J. Wilson, C. Steglich, M. Beck, E. Schwinger, A. Gal, Molecular basis of mucopolysaccharidosis type II: mutation in the iduronate-2-sulfatase gene, *Hum. Mutat.* 2 (1993) 435–442.
- [11] K. Lagerstedt, S.L. Karsten, B.M. Carlberg, W.J. Kleijer, T. Tønnesen, U. Pettersson, M.L. Bondeson, Double-strand breaks may initiate the inversion mutation causing the Hunter syndrome, *Hum. Mol. Genet.* 6 (1997) 627–633.
- [12] J. Muenzer, M. Gucsavas-Calikoglu, S.E. McCandless, T.J. Schuetz, A. Kimura, A phase I/II clinical trial of enzyme replacement therapy in mucopolysaccharidosis II (Hunter syndrome), *Mol. Genet. Metab.* 90 (2007) 329–337.
- [13] T. Okuyama, A. Tanaka, Y. Suzuki, H. Ida, T. Tanaka, G.F. Cox, Y. Eto, T. Orii, Japan Elaprase® Treatment (JET) study: idursulfase enzyme replacement therapy in adult patients with attenuated Hunter syndrome (Mucopolysaccharidosis II, MPS II), *Mol. Genet. Metab.* 99 (2010) 18–25.
- [14] E. Glamuzina, Fettes e, Bainbridge K, Crook V, Finnegan N, Abulhoul L, Vellodi A: Treatment of mucopolysaccharidosis type II (Hunter syndrome) with idursulfase: the relevance of clinical trial end points, *J. Inher. Metab. Dis.* 34 (2011) 749–754.
- [15] C. Alcalde-Martín, J.M. Muro-Tudelilla, R. Cancho-Candela, L.G. Gutiérrez-Solana, G. Pintos-Morell, M. Martí-Herrero, P. Munguira-Aguado, E. Galán-Gómez, First experience of enzyme replacement therapy with idursulfase in Spanish patients with Hunter syndrome under 5 years of age: Case observations from the Hunter Outcome Survey (HOS), *Eur. J. Med. Genet.* 53 (2010) 371–377.
- [16] A. Tylki-Szymanska, A. Jurecka, Z. Zuber, A. Rozdzyńska, J. Marucha, B. Czartoryska, Enzyme replacement therapy for mucopolysaccharidosis II from 3 months of age: a 3-year follow-up, *Acta Paediatr.* 101 (2012) 42–47.
- [17] J.J. Jonsson, E.L. Aronovich, S.E. Braun, C.B. Whitley, Molecular diagnosis of mucopolysaccharidosis type II (Hunter syndrome) by automated sequencing and computer-assisted interpretation: toward mutation mapping of the iduronate-2-sulfatase gene, *Am. J. Hum. Genet.* 56 (1995) 597–607.
- [18] Y.S. Cho, J.H. Kim, T.W. Kim, S.C. Chung, S.A. Chang, D.K. Jin, Otolologic manifestations of Hunter syndrome and their relationship with speech development, *Audiol. Neurootol.* 13 (2008) 206–212.
- [19] M.L. Bondeson, N. Dahl, H. Malmgren, W.J. Kleijer, T. Tønnesen, B.M. Carlberg, U. Pettersson, Inversion of the IDS gene resulting from recombination with IDS-related sequences is a common cause of the Hunter syndrome, *Hum. Mol. Genet.* 4 (1995) 615–621.
- [20] N. Guffon, Y. Bertrand, I. Forest, A. Fouilhoux, R. Froissart, Bone marrow transplantation in children with Hunter syndrome: Outcome after 7 to 17 years, *J. Pediatr.* 154 (2009) 733–737.
- [21] K. Araya, N. Sakai, I. Mohri, K. Kagitani-Shimono, T. Okinaga, Y. Hashii, H. Ohta, I. Nakamichi, K. Aozasa, M. Taniike, K. Ozono, Localized donor cells in brain of a Hunter disease patient after cord blood stem cell transplantation, *Mol. Genet. Metab.* 98 (2009) 255–263.





## Long-term efficacy of hematopoietic stem cell transplantation on brain involvement in patients with mucopolysaccharidosis type II: A nationwide survey in Japan

Akemi Tanaka <sup>a,\*</sup>, Torayuki Okuyama <sup>b</sup>, Yasuyuki Suzuki <sup>c</sup>, Norio Sakai <sup>d</sup>, Hiromitsu Takakura <sup>e,f</sup>, Tomo Sawada <sup>m</sup>, Toju Tanaka <sup>b</sup>, Takanobu Otomo <sup>d</sup>, Toya Ohashi <sup>g</sup>, Mika Ishige-Wada <sup>h</sup>, Hiromasa Yabe <sup>e,f</sup>, Toshihiro Ohura <sup>i</sup>, Nobuhiro Suzuki <sup>j</sup>, Koji Kato <sup>k</sup>, Souichi Adachi <sup>l</sup>, Ryoji Kobayashi <sup>m</sup>, Hideo Mugishima <sup>h</sup>, Shunichi Kato <sup>e,f</sup>

<sup>a</sup> Department of Pediatrics, Osaka City University Graduate School of Medicine, Osaka, Japan

<sup>b</sup> Department of Clinical Laboratory Medicine, National Center for Child Health and Development, Tokyo, Japan

<sup>c</sup> Medical Education Department Center, Gifu University School of Medicine, Gifu, Japan

<sup>d</sup> Department of Pediatrics, Osaka University Graduate School of Medicine, Osaka, Japan

<sup>e</sup> Department of Cell Transplantation, Tokai University School of Medicine, Isehara, Japan

<sup>f</sup> Department of Pediatrics, Tokai University School of Medicine, Isehara, Japan

<sup>g</sup> Department of Gene Therapy, Institute of DNA Medicine, The Jikei University School of Medicine, Tokyo, Japan

<sup>h</sup> Department of Pediatrics and Child Health, Nihon University School of Medicine, Tokyo, Japan

<sup>i</sup> Department of Pediatrics, Sendai City Hospital, Sendai, Japan

<sup>j</sup> Department of Pediatrics, Sapporo Medical University Hospital, Sapporo, Japan

<sup>k</sup> Division of Hematology/Oncology, Children's Medical Center, Japanese Red Cross Nagoya Daiichi Hospital, Nagoya, Japan

<sup>l</sup> Department of Human Health Sciences, Kyoto University Graduate School of Medicine, Kyoto, Japan

<sup>m</sup> Department of Pediatrics, Sapporo Kitanire Hospital, Sapporo, Japan

### ARTICLE INFO

#### Article history:

Received 1 September 2012

Accepted 1 September 2012

Available online 7 September 2012

#### Keywords:

Hematopoietic stem cell transplantation

Mucopolysaccharidosis type II

Brain efficacy

Survey

### ABSTRACT

Hematopoietic stem cell transplantation (HSCT) has not been indicated for patients with mucopolysaccharidosis II (MPS II, Hunter syndrome), while it is indicated for mucopolysaccharidosis I (MPS I) patients <2 years of age and an intelligence quotient (IQ) of  $\geq 70$ . Even after the approval of enzyme replacement therapy for both of MPS I and II, HSCT is still indicated for patients with MPS I severe form (Hurler syndrome). To evaluate the efficacy and benefit of HSCT in MPS II patients, we carried out a nationwide retrospective study in Japan. Activities of daily living (ADL), IQ, brain magnetic resonance image (MRI) lesions, cardiac valvular regurgitation, and urinary glycosaminoglycan (GAG) were analyzed at baseline and at the most recent visit. We also performed a questionnaire analysis about ADL for an HSCT-treated cohort and an untreated cohort (natural history). Records of 21 patients were collected from eight hospitals. The follow-up period in the retrospective study was  $9.6 \pm 3.5$  years. ADL was maintained around baseline levels. Cribriform changes and ventricular dilatation on brain MRI were improved in 9/17 and 4/17 patients, respectively. Stabilization of brain atrophy was shown in 11/17 patients. Cardiac valvular regurgitation was diminished in 20/63 valves. Urinary GAG concentration was remarkably lower in HSCT-treated patients than age-matched untreated patients. In the questionnaire analysis, speech deterioration was observed in 12/19 patients in the untreated cohort and 1/7 patient in HSCT-treated cohort. HSCT showed effectiveness towards brain or heart involvement, when performed before signs of brain atrophy or valvular regurgitation appear. We consider HSCT is worthwhile in early stages of the disease for patients with MPS II.

© 2012 Elsevier Inc. All rights reserved.

**Abbreviations:** ADL, activities of daily living; DQ, development quotient; ERT, enzyme replacement therapy; FIM, functional independence measure; GAG, glycosaminoglycan; HSCT, hematopoietic stem cell transplantation; IQ, intelligence quotient; JSPH, Japanese Society for Pediatric Hematology; MPS, mucopolysaccharidosis; MRI, magnetic resonance imaging; SD, standard deviation.

\* Corresponding author at: Department of Pediatrics, Osaka City University Graduate School of Medicine, 1-4-3 Asahi-machi, Abeno-ku, Osaka 545-8585, Japan. Fax: +81 6 6636 8737.

E-mail address: [akemi-chan@med.osaka-cu.ac.jp](mailto:akemi-chan@med.osaka-cu.ac.jp) (A. Tanaka).

### 1. Introduction

Hematopoietic stem cell transplantation (HSCT) is a standard therapy for young patients with mucopolysaccharidosis I (MPS I, Hurler syndrome, OMIM 607014) [1–4]. HSCT is indicated when MPS I patients are <2 years of age and show an intelligence quotient (IQ) of  $\geq 70$ . However, HSCT has not been indicated for patients with mucopolysaccharidosis II (MPS II, Hunter syndrome, OMIM 309900) as no obvious efficacy has been shown on the brain involvement of MPS II patients [5–8].

Enzyme replacement therapy (ERT) for MPS II was approved in the USA and Europe in 2006, and in Japan in 2007. Its efficacy has been demonstrated for visceral organ and soft connective tissue involvement [9,10], but poor or no efficacy was observed for brain involvement [11,12] because of poor penetration across the blood–brain barrier. Poor efficacy has also been speculated towards hard connective tissues such as bone and heart valves because of poor vascularity. Moreover, weekly injection can prove inconvenient to patients and their families, and the high cost of treatment is another issue to be taken into consideration.

MPS II is the most frequent type of MPS in Asian patients, accounting for 60% of all MPS types in Japan. Before the approval of ERT, HSCT was indicated for MPS II as a standard therapy in Japan. The efficacy of HSCT on visceral organs was clear and similar to that of ERT [13]. However, efficacy on the brain or heart valves has not been clearly evaluated for either ERT or HSCT.

We present the results of a retrospective evaluation of the efficacy of HSCT on MPS II by collecting the clinical records of the patients with MPS II who received HSCT from 1990 to 2003. We also analyzed the answers to a questionnaire given to two cohorts: HSCT-treated and HSCT-untreated (natural history) MPS II patients.

## 2. Methods

### 2.1. MPS II classification

Disease severity was evaluated in all patients into four types (A–D) on the basis of chronological development, history of disease onset, initial symptoms, and clinical records before transplantation. Because of the wide spectrum of clinical phenotypes in MPS II, it is important to compare patients within the same type of disease for the evaluation of efficacy. Types A and B are attenuated forms with normal intelligence, while Types C and D are severe forms with mental impairment. MPS II was classified as follows:

- Type A is the most attenuated form. Onset is at school age with joint stiffness. Patients show normal intelligence, can go to and learn at a normal school, and work.
- Type B shows onset before school age with joint stiffness and/or abdominal distension. They show normal intelligence in primary school but hearing and physical impairments may impact development to a low degree in high school.
- Type C is a severe form. The abnormality is noted at  $\geq 2$  years of age. They start to speak words at 12–18 months of age and speak sentences at 2–3 years of age. Developmental delay and abnormal features become obvious after 3 years of age.
- Type D is a most severe form. The abnormality is noted at  $< 2$  years of age. Abnormal features are obvious around 1 year of age. Speech is definitely delayed. They start to speak words at  $\geq 2$  years of age (or may not speak), but sentences are never spoken.

### 2.2. Retrospective study from transplanted patients' records

This study was approved by the HSCT committee the Japanese Society of Pediatric Hematology (JSPH) and the ethics committees of the participating institutes.

A questionnaire was sent to 12 transplant centers in Japan to ask whether they had any type of MPS patients who had received HSCT and were surviving with donor cell engraftment and complete or incomplete chimera. We then mailed the physicians in charge of the patients with MPS II to obtain informed consent from the patients and/or their guardians so that data could be collected from their clinical records.

School status, movement and daily activities, conversation, and toileting were graded into Levels A (independent), B (assisted occasionally), C (assisted in every event), and D (bedridden, lack of communication,

or wholly assisted) for each item from questionnaires and/or clinical records. Data on intelligence quotient (IQ) and development quotient (DQ) were also collected from clinical records. Functional independence measure (FIM) score was also analyzed and compared with the natural history of the disease as described in a previous report [14].

Brain magnetic resonance imaging (MRI) abnormalities were classified into four distinct types (Categories I–IV) and graded by scores according to a previous report [15]. The score was judged by two pediatricians and one radiologist. The categories were as follows:

- Category I. Cystic or cribriform lesions were graded from T1-weighted MRI as follows: 0 = none; 1 = mild ( $\leq 10$  cystic lesions  $< 3$  mm); 2 = moderate ( $> 10$  small cystic lesions of  $< 3$  mm); and 3 = severe (many cystic lesions including those  $> 3$  mm).
- Category II. White matter signal changes observed on T2-weighted MRI were graded as follows: 0 = none; 1 = mild (a few limited to the periventricular area); and 2 = severe (in most parts of the periventricular area and other white matter areas).
- Category III. Ventricular enlargement was graded as follows: 0 = none; 1 = mild ( $< 3$  mm widening of the third ventricle without temporal horn dilatation); 2 = moderate ( $> 5$ – $10$  mm widening of the third ventricle); and 3 = severe ( $> 10$  mm dilatation of the third ventricle with bulbous configuration).
- Category IV. Brain atrophy was graded as follows: 0 = none, 1 = mild (mild widening of Sylvian and interhemispheric fissures by  $< 3$  mm, but not all of the sulci are involved); 2 = moderate (widening of all fissures and sulci by 3–5 mm); and 3 = severe (widening of all fissures and sulci by  $> 5$  mm with definite loss of cortex and white matter).

Cardiac valvular regurgitations were analyzed by color Doppler echocardiogram with each valve graded according to severity into four levels (I–IV) by the Sellers' classification [16].

Urinary glycosaminoglycan (GAG) was analyzed as the amount of uronic acid. These data were compared with the values in HSCT-untreated MPS II patients and also with those in ERT-treated MPS II patients.

### 2.3. Family questionnaire analysis

We sent a questionnaire to each of the 60 families with 66 MPS II patients registered with “the Japanese MPS Family Society”. Information was collected about chronological development and course of deterioration for both HSCT-treated and HSCT-untreated (natural history) patients. Patients were first classified according to MPS II Types A–D on the basis of information on chronological development, before HSCT if performed, and at disease onset. Data were compared between HSCT-treated and HSCT-untreated patients for MPS II Type C or D patients.

## 3. Results

### 3.1. Retrospective study from transplanted patient records

Among transplanted patients with MPS, 63% (26/41) had MPS II. The 5-year survival rate after treatment of MPS II was 88.5% during the period from 1990 to 2003. Clinical records were collected for the 21 surviving patients (81% from eight hospitals: Type A (n = 1), Type B (n = 6), Type C (n = 7), and Type D (n = 7) [Tables 1 and 2]. Donor state, transplantation protocol, and chimeric status are also summarized in Table 2. Two patients with Type B disease (patients 10-3 and 10-5) received total body irradiation (TBI) in the transplantation protocol. The donors for patients 10-7 and 7-6 were carrier siblings: patient 10-7 showed extremely low iduronate 2-sulfatase activity (25% of normal) even though complete chimera was obtained, while iduronate 2-sulfatase activity was normal in patient 7-6. Chimeric status was determined by short tandem repeats analysis in all patients except for four patients (patients 10-7, 7-8, 7-1, and 1-1) where sex chromosome was

**Table 1**  
Patient numbers for each MPS II type and the results of HSCT effectiveness.

	No. of patients			
	Type A	Type B	Type C	Type D
Retrospective study from transplant patient records (n = 21)	1	6	7	7
ADL (see Table 2)				
Patients analyzed (n = 13)	1	3	5	4
Patients stabilized/improved from baseline	1	2	3	4
IQ/DQ (see Table 2)				
Patients analyzed (n = 11)	0	2	4	5
Patients stabilized/improved from baseline	0	2	1	0
FIM (see Table 2)				
Patients analyzed (n = 11)	1	1	6	3
Patients stabilized/improved from baseline	1	1	2	1
Brain MRI (see Tables 2 and 3)				
Patients analyzed (n = 17)	1	6	5	5
Patients stabilized/improved from baseline (see Tables 2 and 3)	0	5	4	2
Cardiac valvular regurgitation (see Tables 2 and 4)				
Patients analyzed (n = 21)	1	6	7	7
Patients stabilized/improved from baseline	1	4	5	6
Family questionnaire analysis (n = 60)	7	13	26	14
			(see Table 5)	
HSCT (+) (n = 17); [no. rejected]	3 [1]	3 [1]	7	4
HSCT (-) (n = 43)	4	10	19	10

Abbreviations: ADL, activities of daily living; DQ, development quotient; FIM, functional independence measure; IQ, intelligence quotient; MRI, magnetic resonance imaging.

analyzed. The activity of iduronate 2-sulfatase in patient 1-3 showed the lower limit of normal activity, probably because of incomplete chimera. All other patients showed activity within the mean  $\pm 1$  SD of normal. Age at transplantation was  $64.2 \pm 30.2$  months. The mean follow-up period was  $115.7 \pm 41.4$  months. Patient numbers for each MPS II type and a brief summary of results for HSCT effectiveness are shown in Table 1.

Clinical background and outcome among HSCT-treated MPS II patients are detailed in Table 2. Not every patient underwent all clinical examinations. Answers to the questionnaire were obtained for the analysis of ADL (school status, movement and daily activities, conversation, and toileting) from 13 patients: Type A (n = 1), Type B (n = 3), Type C (n = 5), and Type D (n = 4). Two patients with attenuated forms of the disease (patients 1-3 and 7-3) maintained a normal level of ADL (Level A) for each item throughout the observation period. None of the patients with severe forms of the disease except two Type C patients (patients 5-1 and 1-1) showed deterioration from baseline status.

IQ/DQ data were available for 11 patients: Type B (n = 2), Type C (n = 4), and Type D (n = 5). Two Type B patients (7-3 and 7-2) showed an IQ within the normal range both at baseline and at the most recent assessment. Deterioration was observed in two Type C patients (5-2 and 7-6) and two Type D patients (7-4 and 12-1). One Type C (patient 5-1) and one Type D (patient 8-2) showed such severe deterioration at baseline that evaluation of change was not possible. One Type C patient (7-1) and two Type D patients (7-5 and 9-1), whose IQ/DQ were  $> 70$  at baseline, maintained their developmental status without deterioration, while DQ decreased with increasing age (Table 2).

FIM score was available in 11 patients: Type A (n = 1), Type B (n = 1), Type C (n = 6), and Type D (n = 3). Patients with Type A/B disease maintained scores in the normal range. Three Type C/D patients (7-8, 7-1, and 4-1) showed disease attenuation in FIM score when compared with the natural history described in a previous report [14]. One Type C (patient 7-8) and one Type D (patient 4-1) showed disease attenuation in FIM score for motor function, while the score for cognition did not differ from untreated patients. One Type C (patient 7-1) showed disease attenuation in FIM scores for both motor function and cognition. Other

patients with severe forms of the disease (4 Type C and 2 Type D) showed no difference as compared to the previously reported untreated patients [14]. The results are summarized in Table 2.

IQ/DQ and FIM scores were both obtained in seven patients: one Type B (patient 7-2), four Type C (patients 5-2, 7-6, 7-1, and 5-1), and two Type D (9-1 and 12-1). Among these patients with Type C/D disease and brain involvement, only one patient (7-1) showed disease attenuation in both FIM score and developmental status. The remaining three Type C patients showed no difference in FIM score as compared to natural history. While developmental status and ADL improved in patient 9-1, no efficacy in FIM score was shown as compared to natural history.

Brain MRI data were analyzed in 17 patients: Type A (n = 1), Type B (n = 6), Type C (n = 5), and Type D (n = 5) [Table 2]. Improvements in Categories I and III lesions were shown in nine (4 Type B, 2 Type C, and 3 Type D) and four patients (2 Type C and 2 Type D), respectively. Eight out of 17 patients (59%) had an improvement in total score. All of the six patients who showed an increase in total score had deterioration in Category IV lesions (brain atrophy). Three of these six patients had Type D disease (patients 7-4, 8-2, and 10-1). Two patients (7-1 and 4-1) who showed disease attenuation in FIM score also showed improvement in brain MRI abnormality scores. There was no difference in the effectiveness between the attenuated forms (Type A/B) and severe forms (Type C/D) of the disease or any correlation between the effectiveness of HSCT and age at HSCT, as summarized in Table 3.

Valvular regurgitation was analyzed for mitral, aortic, and tricuspid valves. Pulmonary valves showed insufficient lesions to warrant analysis. Twenty-one patients were analyzed: Type A (n = 1), Type B (n = 6), Type C (n = 7), and Type D (n = 7), i.e. a total of 63 valves. Results are summarized in Tables 2 and 4. Valvular regurgitation improved in 32% and stabilized in 56% of valves. There was no difference in efficacy between patients with the attenuated (Type A/B) and severe forms (Type C/D) of MPS II (data not shown). However, valvular regurgitation deteriorated more frequently in the patients transplanted at  $\geq 6$  years of age (5 valves out of 8 patients), as shown in Table 4.

The amount of urinary GAG was analyzed from urinary uronic acid concentrations. Mean urinary uronic acid concentrations in children ages 7–16 years were  $18.0 \pm 5.5$  (n = 24) and  $165.5 \pm 77.9$  (n = 9) mg/g creatinine for normal children and among untreated Types A–D MPS II patients, respectively. Urinary GAG in HSCT-treated MPS II patients was  $24.8 \pm 9.8$  mg/g creatinine (n = 7, ages 9–17 years). Urinary GAG in ERT-treated patients with MPS II at Osaka City University Hospital was  $37.6 \pm 14.3$  mg/g creatinine (n = 6, age 7–16 years).

### 3.2. Family questionnaire analysis

Answers to the questionnaire were collected for 60 patients with MPS II from 55 families. The numbers of HSCT-treated and HSCT-untreated patients were 17 and 43, respectively. As the questionnaire sheet was anonymous, we could not identify the patients analyzed in the clinical study described above. The patients were divided into Types A–D clinical forms (Table 1), as previously described. Six out of 20 Type A/B patients were treated by HSCT and two of them (one each with Types A and B) underwent rejection. Four of 14 Type D patients received HSCT. However, they showed deterioration before transplantation. We analyzed the efficacy of HSCT in 26 Type C patients with respect to disease progression by age at onset of speech deterioration, walking disability, and convulsion (Table 5). The numbers of patients in the HSCT-treated and HSCT-untreated cohorts were 7 and 19, respectively. Mean ages of these cohorts were  $145.7 \pm 67.8$  and  $142.7 \pm 88.6$  months, respectively.

Seven Type C patients underwent HSCT at a mean age of  $65.9 \pm 22.1$  months (range, 44–111 months). Before HSCT treatment, the seven patients showed no difference in developmental milestones as compared to the 19 HSCT-untreated patients. At the time of survey, 12 out of 19 (63%) HSCT-untreated patients showed deterioration of

**Table 2**  
Clinical background and outcome among HSCT-treated MPS II patients (n = 21).

Patient no.	Disease type	Age at HSCT	Donor	Protocol	Chimeric status	GVHD	Follow-up	ADL (pre/post), [n = 13]				IQ/DQ (developmental age)	
								School status	Movement and daily activities	Conversation	Toileting	Pre	Post
1-3	A	19 y 8 m	Unrelated BM	CY + BU + ATG	50	No	6 y 7 m	(A/A)	(A/A)	(A/A)	(A/A)	NA	
10-3	B	4 y 11 m	Unrelated CB	CY + TBI	100	No	7 y 1 m	NA	NA	NA	NA	NA	
7-3	B	5 y 5 m	Normal sibling	CY + BU + ATG	100	No	8 y 7 m	(A/A)	(B/A)	(A/A)	(A/A)	114 (normal)	102 (normal)
7-2	B	6 y 0 m	Normal sibling	BU + ATG	Mixed	No	10 y 11 m	NA	NA	NA	NA	99 (normal)	91 (normal)
8-1	B	9 y 5 m	Normal sibling	CY + BU	100	No	12 y 7 m	(E/E)	(E/E)	(B/B)	(E/E)	NA	
10-7	B	7 y 9 m	Carrier sibling	CY + BU + ATG	100	No	11 y 3 m	(A/A)	(A/A)	(A/A)	(A/A)	NA	
10-5	B	11 y 6 m	Unrelated BM	CY + TBI	90	Yes	6 y 6 m	(A/D)*	(B/B)	(A/A)	(A/A)	NA	
5-2	C	3 y 4 m	Normal sibling	CY + BU	100	No	7 y 4 m	(B/B)	(C/B)	(B/B)	(D/B)	53 (3 y 11 m)	NA
7-8	C	4 y 3 m	Unrelated BM	CY + BU + ATG	100	No	7 y 4 m	NA	NA	NA	NA	NA	
7-7	C	5 y 5 m	Unrelated CB	CY + BU + ATG	100	No	7 y 7 m	NA	NA	NA	NA	NA	
7-6	C	5 y 9 m	Carrier sibling	CY + BU + ATG	100	No	6 y 11 m	(B/B)	(C/C)	(D/C)	(D/B)	25 (1 y 8 m)	NA
7-1	C	7 y 0 m	Normal sibling	CY + BU	100	Yes	16 y 3 m	(B/B)	(B/A)	(B/A)	(E/E)	78 (5 y 6 m)	65 (9 y 6 m)
5-1	C	7 y 3 m	Normal sibling	CY + BU	100	No	10 y 5 m	(B/B)	(C/D)*	(C/C)	(B/C)*	NA	NA
1-1	C	9 y 4 m	Normal sibling	CY + BU	100	No	16 y	(C/D)*	(C/D)*	(C/D)*	(C/D)*	NA	
7-4	D	2 y 0 m	Unrelated BM	CY + BU + ATG	100	Yes	9 y 11 m	NA	NA	NA	NA	50 (1 y 0 m)	NA
7-5	D	2 y 2 m	Normal sibling	CY + BU + ATG	96	No	8 y 8 m	NA	NA	NA	NA	70 (1 y 6 m)	29 (2 y 2 m)
9-1	D	2 y 2 m	Unrelated BM	CY + BU + ATG	100	No	12 y	(E/B)	(C/A)	(B/A)	(C/A)	100 (2 y 2 m)	40 (5 y 6 m)
12-1	D	2 y 6 m	Normal sibling	CY + BU	100	No	8 y 3 m	(E/B)	(C/C)	(C/C)	(D/D)	66 (5 y 6 m)	30 (1 y 10 m)
8-2	D	2 y 9 m	Normal sibling	CY + BU	100	No	12 y 3 m	(D/B)	(D/D)	(D/D)	(D/D)	NA	NA
4-1	D	4 y 2 m	Unrelated BM	CY + BU + ATG	100	No	5 y 5 m	(B/B)	(A/A)	(C/B)	(D/B)	NA	
10-1	D	5 y 4 m	Normal sibling	CY + BU + ATG	100	No	7 y 8 m	NA	NA	NA	NA	NA	

Abbreviations: ADL, activities of daily living; ATG, antithymocyte globulin; BM, bone marrow; BU, busulfan; CB, cord blood; CY, cyclophosphamide; DQ, development quotient; FIM, functional independence measure; HSCT, hematopoietic stem cell transplantation; IQ, intelligence quotient; m, month; MPS, mucopolysaccharidosis; MRI, magnetic resonance imaging; NA, not available (not found, not examined, and/or not measurable); TBI, total body irradiation; y, year.

\* Regression of level or score.

Table 2 (continued)

Patient no.	FIM Difference from natural history	Brain MRI abnormality (pre/post) [n = 17]				Valvular regurgitation (pre/post) [n = 21]		
		Category I (cribriform change)	Category II (white matter signal change)	Category III (ventricular enlargement)	Category IV (brain atrophy)	Mitral	Aortic	Tricuspid
1-3	Normal range	(2/2)	(1/2) <sup>a</sup>	(2/2)	(1/2) <sup>a</sup>	II-III/IV	II/I	II-III/IV
10-3	Normal range	(1.5/0.5)	(0/0)	(1/1)	(0/0)	III/(-)	(-)/(-)	(-)/(-)
7-3	NA	(1/0.5)	(0/0)	(0/0)	(0/0)	I-II/(-)	II/(-)	(-)/(-)
7-2	Normal range	(1/0)	(0/0)	(0/0)	(0/0)	I-II/I-II	(-)/II <sup>a</sup>	I/(-)
8-1	NA	(1/1)	(2/2)	(1/1)	(0/0)	I/I	(-)/II <sup>a</sup>	I/I
10-7	NA	(3/2)	(0/0)	(0/0)	(0/0)	II/I	(-)/(-)	(-)/(-)
10-5	NA	(1/2) <sup>a</sup>	(0/0)	(0/1)	(0.5/1.5) <sup>a</sup>	I/I	II/II	(-)/(-)
5-2	No difference	NA	NA	NA	NA	(-)/(-)	(-)/(-)	(-)/(-)
7-8	Attenuation	(1/1)	(0/0)	(0/0)	(0/0)	I/I	(-)/(-)	I/I
7-7	NA	(1/0)	(1/0)	(1/0)	(0/0)	III/II-III	(-)/II <sup>a</sup>	I/(-)
7-6	No difference	(1/1)	(0/0)	(2/2)	(1/1.5) <sup>a</sup>	(-)/(-)	II/(-)	II/(-)
7-1	Attenuation	(1/0)	(0/0)	(2/1.5)	(1/1)	I/I	I/(-)	(-)/(-)
5-1	No difference	NA	NA	NA	NA	(-)/I <sup>a</sup>	II/I	(-)/(-)
1-1	No difference	(2/2)	(2/2)	(2/2)	(3/3)	I/II <sup>a</sup>	II/I	(-)/(-)
7-4	NA	(0.5/0)	(0/0)	(0/1) <sup>a</sup>	(0/1) <sup>a</sup>	II/I	II/I	I/(-)
7-5	NA	(1/0)	(0/0)	(0.5/0)	(0/0)	II/II	(-)/(-)	(-)/(-)
9-1	No difference	NA	NA	NA	NA	(-)/II <sup>a</sup>	I/I	(-)/(-)
12-1	No difference	NA	NA	NA	NA	(-)/(-)	(-)/(-)	(-)/(-)
8-2	NA	(2/2)	(1/1)	(1/2) <sup>a</sup>	(2/3) <sup>a</sup>	(-)/(-)	(-)/II <sup>a</sup>	I/(-)
4-1	Attenuation	(1/0.5)	(0/0)	(1/0.5)	(0/0)	(-)/(-)	I/I	(-)/(-)
10-1	NA	(0.5/0.5)	(0/0)	(3/3)	(2/3) <sup>a</sup>	(-)/(-)	(-)/(-)	(-)/(-)

**Table 3**

Effectiveness of HSCT on brain MRI lesions among MPS II patients according to age at transplantation or MPS II clinical classification.

	No. of patients				MPS II classification	
	Age at HSCT				Type A/B (n = 7)	Type C/D (n = 10)
	<4 y (n = 3)	4–5 y (n = 3)	5–6 y (n = 5)	>6 y (n = 6)		
Improved (n = 8)	1	2	3	2	4	4
Stable (n = 3)	0	1	1	2	1	2
Deteriorated (n = 6)	2	0	2	2	2	4

Abbreviations: HSCT, hematopoietic stem cell transplantation; MPS, mucopolysaccharidosis, y, year.

speech, nine (47%) spoke no words, six (32%) had convulsions, and six (32%) did not walk. All but one of the HSCT-treated Type C patients showed no speech deterioration, loss of speech, or convulsions.

#### 4. Discussion

We performed a retrospective study on the long-term efficacy of HSCT in MPS II patients. Efficacy was noted, to some extent, even with respect to brain involvement as long as HSCT was carried out before developmental delay became clinically manifest, without brain atrophy on MRI. The study of ADL from transplanted patient records showed that HSCT-treated patients maintained almost the same levels of speech ability and gait as at baseline or an improvement in most patients (Table 2). The questionnaire study among Type C patients of HSCT-treated and HSCT-untreated cohorts showed no deterioration in all except one Type C patient in the HSCT-treated cohort, which is different from the natural history of the disease (HSCT-untreated cohort) [Table 5]. However, no difference was shown in FIM score when compared to the natural history of the disease except for three patients (7–8, 7–1, and 4–1). Moreover, two patients with Type D disease (patients 7–5 and 9–1) with baseline DQ of 70 and 100, respectively, showed severe deterioration and no difference was shown with respect to the natural history of the disease for patient 9–1 with respect to FIM score. Thus, HSCT may not be effective with respect to brain involvement for Type D MPS II patients.

The effectiveness of HSCT on brain MRI was distinctive. Improvement in Categories I and III lesions was clearly shown. Category I lesions involve enlargement of perivascular spaces where GAG-loaded

**Table 4**

Changes in cardiac valve involvement according to age at HSCT among MPS II patients.

	No. of patients with cardiac valvular regurgitation (n = 21)				
	Age at HSCT				
	<4 y (n = 6)	4–5 y (n = 3)	5–6 y (n = 4)	≥6 y (n = 8)	Total (n = 21)
Mitral valve (n = 21)					
Diminished	1	1	2	3	7 (33%)
Stable	4 [3 <sup>a</sup> ]	2 [1 <sup>a</sup> ]	2 [2 <sup>a</sup> ]	3 [0 <sup>a</sup> ]	11 [6 <sup>a</sup> ] (52%)
Increased	1	0	0	2	3 (14%)
Aortic valve (n = 21)					
Diminished	1	0	2	4	7 (33%)
Stable	4 [3 <sup>a</sup> ]	3 [2 <sup>a</sup> ]	1 [1 <sup>a</sup> ]	1 [0 <sup>a</sup> ]	9 [6 <sup>a</sup> ] (43%)
Increased	1	0	1	3	5 (24%)
Tricuspid valve (n = 21)					
Diminished	2	0	2	2	6 (29%)
Stable	4 [4 <sup>a</sup> ]	3 [2 <sup>a</sup> ]	2 [2 <sup>a</sup> ]	6 [5 <sup>a</sup> ]	15 [13 <sup>a</sup> ] (71%)
Increased	0	0	0	0	0 (0%)
Total (n = 63)					
Diminished	4	1	6	9	20 (32%)
Stable	12 [10 <sup>a</sup> ]	8 [5 <sup>a</sup> ]	5 [5 <sup>a</sup> ]	12 [6 <sup>a</sup> ]	35 [25 <sup>a</sup> ] (56%)
Increased	2	0	1	5	8 (13%)

Abbreviations: HSCT, hematopoietic stem cell transplantation; MPS, mucopolysaccharidosis, y, year.

<sup>a</sup> Number with absence of regurgitation at HSCT (baseline).

**Table 5**

Clinical course of HSCT-untreated and HSCT-treated Type C MPS II patients in questionnaire analysis.

	Pre-treatment in HSCT-treated cohort (n = 7)		HSCT-untreated cohort (n = 19)	
Mean ± SD age at developmental milestones (m)				
Speak words	17.1 ± 4.1		18.0 ± 6.3	
Speak sentences	32.0 ± 9.2		40.1 ± 14.2	
Age when noticed developmental delay (m)	26.4 ± 16.6		34.2 ± 12.5	
Mean ± SD age at HSCT (m)	65.9 ± 22.1		–	
Mean ± SD age at survey (m)	145.7 ± 67.8		142.7 ± 88.6	
Disease progression	Post-treatment in HSCT-treated cohort		HSCT-untreated cohort	
	No. of affected (%)	Age when noticed (m)	No. of affected (%)	Mean ± SD age when noticed (m)
Speech deterioration	1 <sup>*</sup> /7 (14%)	42	12/19 (63%)	113.5 ± 40.4
Loss of speech	1 <sup>*</sup> /7 (14%)	72	9/19 (47%)	150.4 ± 55.1
Convulsions	1 <sup>*</sup> /7 (14%)	125	6/19 (32%)	186.0 ± 71.2
Unable to walk	0/7 (0%)	–	6/19 (32%)	186.5 ± 52.9

1<sup>\*</sup>. The same patient.

Abbreviations: HSCT, hematopoietic stem cell transplantation; m, month; MPS, mucopolysaccharidosis; NA, not applicable; SD, standard deviation.

cells are accumulated and Category III lesions occur from insufficient cerebrospinal fluid absorption or secondarily from brain atrophy. It is speculated that engrafted cells migrate into perivascular and sub-arachnoid spaces and secrete the deficient enzyme responsible for diminishing GAG storage, thereby improving lesions. On the other hand, for Category IV lesions, which results from neuronal cell loss, deterioration was observed in six patients and none improved. It may be that engrafted cells are not located to deep brain tissue. Of these six patients, three were Type D patients and two of them showed a worsening of Category III lesions, which probably resulted from the progression of Category IV lesions (brain atrophy). Thus, the efficacy of HSCT is not shown in Type D patients from the brain MRI study.

Two patients with Type C/D disease (patients 7–1 and 4–1) showed effectiveness in both intellectual (ADL, IQ/DQ, and FIM) and imaging analysis (brain MRI), while three patients (patients 7–6, 7–4, and 8–2) showed deterioration in both. These three patients already had severe intellectual deterioration at baseline with low IQ/DQ. However, no clear correlation between the effectiveness on brain MRI lesions and on intellectual scores was shown in other Type C/D patients because of insufficient data.

The most serious cardiac consequence in MPS II is valvular insufficiency. Thickening of heart valves by GAG accumulation and fibrosis results in valvular stenosis and regurgitation, culminating in heart failure, which is one of the most frequent causes of death in MPS II patients in our experience. Mitral valves and aortic valves were those primarily affected in our patients. In particular, the aortic perivalvular area was enlarged in older patients and caused regurgitation. Eighty-eight percent of valves showed improvement (32%) or stabilization (56%) with respect to regurgitation. A deterioration of valvular regurgitation was frequently observed in older patients who received HSCT, who already had regurgitation on baseline examination prior to engraftment. We have experience with different patients in a family with Type B MPS II who received and did not receive HSCT in this study. An uncle did not receive any therapy, could not walk at 17 years, and died at 20 years from heart failure. His nephew was 18 years at survey (patient 10–7) and underwent HSCT at 7 years and 9 months old. Although he had mitral valve regurgitation, he remained relatively well and was practicing kendo in high school. The efficacy of HSCT on the respiratory system probably reduced his cardiac stress.

It is known that the efficacy of HSCT is affected by the transplantation condition. TBI can sometimes result in brain atrophy or dementia after many years delay. Since none of the Type C/D patients received TBI as part of their transplantation protocol, their deterioration must have resulted from the disease itself and not a consequence of TBI. It has been recently reported that lower enzyme activity after HSCT results in lower efficacy in the patients with MPS I severe form (Hurler syndrome) in a multicenter survey study of 197 patients [17]. In our study, two patients showed extremely low enzyme activity after HSCT. However, it is unclear whether they had poor efficacy from HSCT.

ERT has recently become available in Japan. It has demonstrated clear efficacy with respect to visceral organ involvement and urinary GAG secretion [9,10]. ERT is superior to HSCT in terms of safety and availability. However, ERT requires weekly injection, its cost is high, and antibody development is another problem. Moreover, the efficacy of ERT has not been clearly demonstrated with respect to brain [11,12] or heart valve involvement.

In patients who received HSCT, urinary GAG concentration was definitely decreased after engraftment. Values became almost the same as those of normal children. In ERT-treated MPS II patients, however, urinary GAG concentration was slightly higher than that in HSCT-treated patients. Similar results have been previously reported in patients with MPS I [4]. It is possible that engrafted cells provide the deficient enzyme more efficiently to the affected cells and organs than by systemic ERT administration.

In contrast to the efficacy of HSCT with respect to MRI findings, our personal experience with ERT of six patients aged 1–12 years with severe MPS II showed a 4%–12% brain volume reduction following 2 years' treatment (data not shown). Moreover, none of them showed any improvement in any MRI lesion category. However, Wang et al. [18] reported that ERT reduced or stabilized brain MRI abnormalities. Longer observation periods are necessary to evaluate the efficacy of ERT on ADL, and heart and brain involvement.

Our study showed an improvement of brain MRI findings in HSCT-treated patients. We speculate that the efficacy is due to migrated microglial cells derived from donor cells. In 2009, Araya et al. [19] reported the localization of donor cells in the brain of a patient with MPS II after cord blood cell transplantation. Several studies have shown the migration of transplanted bone marrow cells into brain tissue [20,21]. In a recent report, autologous cord blood infusion showed some efficacy in children with acquired neurologic disorders [22]. It is known that HSCT shows efficacy on brain involvement in patients with genetic leukodystrophies including adrenoleukodystrophy, metachromatic leukodystrophy, and globoid cell leukodystrophy [23], and HSCT is a standard therapy for these patients in early stages of the disease. HSCT combined with gene therapy (ex vivo gene therapy) using a lentiviral vector has recently been shown to be successful in two patients with adrenoleukodystrophy [24]. It is speculated that stem cells can migrate across the blood–brain barrier in some situations such as the environment induced by disease.

On the other hand, the efficacy of HSCT on IQ/DQ was unclear in patients with MPS II. However, it can be concluded that the disease of lesser severity and an earlier time of transplantation will lead to better efficacy on IQ/DQ.

The disadvantages of HSCT are the mortality (11.5% in 1990–2003) and morbidity associated with the transplantation procedure [25]. Suitable donors may not be found easily and quickly. However, once engraftment has been established, the quality of life of patients will be better than in patients receiving weekly ERT treatment. Moreover, the expense of HSCT is less than that for ERT. HSCT also improves morbidity in patients with MPS II, particularly when performed early in the course of the disease. Exogenous ERT is unable to correct cognitive and CNS disease because of its inability to cross the blood–brain barrier. In contrast, HSCT allows donor-derived, enzyme-producing cells to migrate into the brain and other organs, thereby providing a permanent form

of enzyme replacement [26,27]. The utility of HSCT should therefore be re-evaluated in the treatment for MPS II. HSCT is a worthwhile treatment for MPS II when it is performed before signs of brain atrophy appear on MRI and before heart valvular regurgitation appear. Therefore, neonatal screening for MPS II may result in improving of the prognosis. In the future, genetically engineered bone marrow cells, autologous cord blood cells, or other cells may become good sources for cell transplantation, or other novel intervention for genetic diseases may be developed.

### Conflict of interest

Each author declares no potential conflict of interest, real or perceived.

### Acknowledgments

We indebted to the patients and families of the members in The Japanese MPS Family Society for providing answers to the questionnaire. We thank Ms. Miho Tabe in SRL Clinical Laboratory Inc. for providing the data on uronic acid concentrations in HSCT-treated patients. We also thank Drs. Toru Yorifuji, Hiraku Doi, and Takeo Kato, Department of Pediatrics, Kyoto University Graduate School of Medicine, for collecting data from historic clinical records and Dr. Yukio Miiki, Department of Radiology, Osaka City University Graduate School of Medicine, for expert advice on evaluating MRI lesions.


This study was supported by grant H20-Clinical Study General-011, and the matching fund subsidy of "Research on Measures for Intractable Diseases" project from the Ministry, of Health, Labour and Welfare, Japan.

### References

- [1] J.R. Hobbs, K. Hugh-Jones, A.J. Barrett, N. Byrom, D. Chambers, K. Henry, D.C. James, C.F. Lucas, T.R. Rogers, P.F. Benson, L.R. Tansley, A.D. Patrick, J. Mossman, E.P. Young, Reversal of clinical features of Hurler's disease and biochemical improvement after treatment by bone-marrow transplantation, *Lancet* 2 (1981) 709–712.
- [2] S.L. Staba, M.L. Escolar, M. Poe, Y. Kim, P.L. Martin, P. Szabolcs, J. Allison-Thacker, S. Wood, D.A. Wenger, P. Rubinstein, J.J. Hopwood, W. Krivit, J. Kurtzberg, Cord-blood transplants from unrelated donors in patients with Hurler's syndrome, *N. Engl. J. Med.* 350 (2004) 1960–1969.
- [3] J.J. Boelens, R.F. Wynn, A. O'Maera, P. Veys, Y. Bertrand, G. Souillet, J.E. Wraith, A. Fischer, M. Cavazzana-Caivo, K.W. Sykora, P. Sedlacek, A. Rovelli, C.S. Uiterwaal, N. Wulffraat, Outcomes of hematopoietic stem cell transplantation for Hurler's syndrome in Europe: a risk factor analysis for graft failure, *Bone Marrow Transplant.* 40 (2007) 225–233.
- [4] J. Muenzer, J.E. Wraith, L.A. Clarke, Mucopolysaccharidosis I: management and treatment guidelines, *Pediatrics* 123 (2009) 19–29.
- [5] N. Guffon, Y. Bertrand, I. Forest, A. Fouilhoux, R. Froissart, Bone marrow transplantation in children with Hunter Syndrome: outcome after 7 to 17 years, *J. Pediatr.* 154 (2009) 733–737.
- [6] E.J. McKinnis, S. Sulzbacher, J.C. Rutledge, J. Sanders, C.R. Scott, Bone marrow transplantation in Hunter syndrome, *J. Pediatr.* 129 (1996) 145–148.
- [7] A. Vellodi, E. Young, A. Cooper, V. Lidchi, B. Winchester, J.E. Wraith, Long-term follow-up following marrow transplantation for Hunter disease, *J. Inher. Metab. Dis.* 22 (1999) 638–648.
- [8] C. Peters, W. Krivit, Hematopoietic cell transplantation for mucopolysaccharidosis IIB (Hunter syndrome), *Bone Marrow Transplant.* 25 (2000) 1097–1099.
- [9] J.E. Wraith, M. Scarpa, M. Beck, O.A. Bodamer, L. De Meirleir, N. Guffon, A. Meldgaard Lund, G. Malm, A.T. Van der Ploeg, J. Zeman, Mucopolysaccharidosis type II (Hunter syndrome): a clinical review and recommendations for treatment in the era of enzyme replacement therapy, *Eur. J. Pediatr.* 167 (2008) 267–277.
- [10] T. Okuyama, A. Tanaka, Y. Suzuki, H. Ida, T. Tanaka, G.F. Cox, Y. Eto, T. Orii, Japan Elaprase Treatment (JET) study: idursulfase enzyme replacement therapy in adult patients with attenuated Hunter syndrome (mucopolysaccharidosis II, MPS II), *Mol. Genet. Metab.* 99 (2010) 18–25.
- [11] F. Papadia, M.S. Lozupone, A. Gaeta, D. Capodiferno, G. Licalandola, Long-term enzyme replacement therapy in a severe case of mucopolysaccharidosis type II (Hunter syndrome), *Eur. Rev. Med. Pharmacol. Sci.* 15 (2011) 253–258.
- [12] R. Manara, E. Priante, M. Grimaldi, L. Santoro, L. Astarita, R. Barone, D. Concolino, M. Di Rocco, M.A. Donati, S. Fecarotta, A. Ficcidenti, A. Fiumara, F. Furlan, I. Giovannini, F. Lilliu, R. Mardari, G. Polonara, E. Procopio, A. Rampazzo, A. Rossi, G. Sanna, R. Parini, M. Scarpa, Brain and spine MRI features of Hunter disease: frequency, natural evolution and response to therapy, *J. Inher. Metab. Dis.* 34 (2011) 763–780.

- [13] M. Imaizumi, K. Gushi, I. Kurobane, S. Inoue, J. Suzuki, Y. Koizumi, H. Suzuki, A. Sato, Y. Gotoh, K. Haginoya, M. Kikuchi, J. Aikawa, K. Narisawa, A. Ohnuma, K. Ohmura, H. Shintaku, A. Tanaka, K. Tada, Long-term effects of bone marrow transplantation for inborn errors of metabolism: a study of four patients with lysosomal storage disease, *Acta Paediatr. Jpn.* 36 (1994) 30–36.
- [14] T. Kato, Z. Kato, I. Kuratsubo, T. Ota, T. Orii, N. Kondo, Y. Suzuki, Evaluation of ADL in patients with Hunter disease using FIM score, *Brain Dev.* 29 (2007) 298–305.
- [15] T. Seto, K. Kono, K. Morimoto, Y. Inoue, H. Shintaku, H. Hattori, O. Matsuoka, T. Yamano, A. Tanaka, Brain magnetic resonance imaging in 23 patients with mucopolysaccharidosis and the effect of bone marrow transplantation, *Ann. Neurol.* 50 (2001) 79–92.
- [16] R.D. Sellers, M.J. Levy, K. Amplatz, C.W. Lillehei, Left retrograde cardioangiography in acquired cardiac disease: technique, indication and interpretations in 700 cases, *Am. J. Cardiol.* 14 (1964) 437–447.
- [17] J. Boelens, M. Aldenhoven, M.L. Escolar, M.D. Poe, R.F. Wynn, A.O. Maera, A. Rovel, P. Veys, P. Orchard, J. Kurtzberg, J. Boelens, international multicenter study to identify predictors of long term outcome of Hurler syndrome patients after successful hematopoietic stem cell transplantation, in: Abstract S08.7 presented at the 12th International Symposium on MPS and Related Diseases, Noodwijkerhout, The Netherlands, Jun 28–Jul 1 2012.
- [18] R.Y. Wang, E.J. Cambray-Forker, K. Ohanian, D.S. Karlin, K.K. Covault, P.H. Schwartz, J.E. Abdenur, Treatment reduces or stabilizes brain imaging abnormalities in patients with MPS I and II, *Mol. Genet. Metab.* 98 (2009) 406–411.
- [19] K. Araya, N. Sakai, I. Mohri, K. Kagitani-Shimono, T. Okinaga, Y. Hashii, H. Ohta, I. Nakamichi, K. Aozasa, M. Taniike, K. Ozono, Localized donor cells in brain of a Hunter disease patient after cord blood stem cell transplantation, *Mol. Genet. Metab.* 98 (2009) 255–263.
- [20] D.W. Kennedy, J.L. Abkowitz, Kinetics of central nervous system microglia and macrophage engraftment: analysis using a transgenic bone marrow transplantation model, *Blood* 90 (1997) 986–993.
- [21] P. Sano, A. Tessitore, A. Ingrassia, A. d'Azzo, Chemokine-induced recruitment of genetically modified bone marrow cells into the CNS of GM1-gangliosidosis mice corrects neuronal pathology, *Blood* 106 (2005) 2259–2268.
- [22] J. Sun, J. Allison, C. McLaughlin, L. Sledge, B. Waters-Pick, S. Wease, J. Kurtzberg, Differences in quality between privately and publicly banked umbilical cord blood units: a pilot study of autologous cord blood infusion in children with acquired neurologic disorders, *Transfusion* 50 (2010) 1980–1987.
- [23] A. Gassas, J. Raiman, L. White, T. Schechter, J. Clarke, J. Doyle, Long-term adaptive functioning outcomes of children with inherited metabolic and genetic diseases treated with hematopoietic stem cell transplantation in a single large pediatric center: parents' perspective, *J. Pediatr. Hematol. Oncol.* 33 (2011) 216–220.
- [24] N. Cartier, S. Hacein-Bey-Abina, C.C. Bartholomae, P. Bougnères, M. Schmidt, C.V. Kalle, A. Fischer, M. Cavazzana-Calvo, P. Aubourg, Hematopoietic stem cell gene therapy with a lentiviral vector in X-linked adrenoleukodystrophy, *Science* 326 (2009) 818–823.
- [25] V.K. Prasad, A. Mendizabal, S.H. Parikh, P. Szabolcs, T.A. Driscoll, K. Page, S. Lakshminarayanan, J. Allison, S. Wood, D. Semmel, M.L. Escolar, P.L. Martin, S. Carter, J. Kurtzberg, Unrelated donor umbilical cord blood for inherited metabolic disorders in 159 pediatric patients from a single center: influence of cellular composition of the graft on transplantation outcomes, *Blood* 112 (2008) 2979–2989.
- [26] V.K. Prasad, J. Kurtzberg, Emerging trends in transplantation of inherited metabolic diseases, *Bone Marrow Transplant.* 4 (2008) 99–108.
- [27] V.K. Prasad, J. Kurtzberg, Cord blood and bone marrow transplantation in inherited metabolic diseases: scientific basis, current status and future directions, *Br. J. Haematol.* 148 (2010) 356–372.





## Identification of mutations in the prostaglandin transporter gene *SLCO2A1* and its phenotype-genotype correlation in Japanese patients with pachydermoperiostosis

Takashi Sasaki<sup>a,b,1</sup>, Hironori Niizeki<sup>c,1,\*</sup>, Atsushi Shimizu<sup>d</sup>, Aiko Shiohama<sup>e</sup>, Asami Hirakiyama<sup>c,f</sup>, Torayuki Okuyama<sup>f</sup>, Atsuhito Seki<sup>g</sup>, Kenji Kabashima<sup>h</sup>, Atsushi Otsuka<sup>h</sup>, Akira Ishiko<sup>i</sup>, Keiji Tanese<sup>j</sup>, Shun-ichi Miyakawa<sup>j</sup>, Jun-ichi Sakabe<sup>k</sup>, Masamitsu Kuwahara<sup>l</sup>, Masayuki Amagai<sup>b</sup>, Hideyuki Okano<sup>m</sup>, Makoto Suematsu<sup>n</sup>, Jun Kudoh<sup>e,\*</sup>

<sup>a</sup> Center for Integrated Medical Research, Keio University School of Medicine, Shinjuku-ku, Tokyo, Japan

<sup>b</sup> Department of Dermatology, Keio University School of Medicine, Shinjuku-ku, Tokyo, Japan

<sup>c</sup> Department of Dermatology, National Center for Child Health and Development, Setagaya-ku, Tokyo, Japan

<sup>d</sup> Department of Molecular Biology, Keio University School of Medicine, Shinjuku-ku, Tokyo, Japan

<sup>e</sup> Laboratory of Gene Medicine, Keio University School of Medicine, Shinjuku-ku, Tokyo, Japan

<sup>f</sup> Department of Laboratory Medicine, National Center for Child Health and Development, Setagaya-ku, Tokyo, Japan

<sup>g</sup> Department of Orthopedics, National Center for Child Health and Development, Setagaya-ku, Tokyo, Japan

<sup>h</sup> Department of Dermatology, Kyoto University Graduate School of Medicine, Kyoto, Japan

<sup>i</sup> First Department of Dermatology, School of Medicine, Toho University, Ota-ku, Tokyo, Japan

<sup>j</sup> Division of Dermatology, Kawasaki Municipal Hospital, Kawasaki, Kanagawa, Japan

<sup>k</sup> Department of Dermatology, Hamamatsu University School of Medicine, Hamamatsu, Shizuoka, Japan

<sup>l</sup> Division of Plastic Surgery, Nara Medical University, Kashihara, Nara, Japan

<sup>m</sup> Department of Physiology, Keio University School of Medicine, Shinjuku-ku, Tokyo, Japan

<sup>n</sup> Department of Biochemistry, Keio University School of Medicine, Shinjuku-ku, Tokyo, Japan

### ARTICLE INFO

#### Article history:

Received 24 April 2012

Received in revised form 12 July 2012

Accepted 19 July 2012

#### Keywords:

PDP

Whole exome sequencing

Mutation analysis

*SLCO2A1*

Prostaglandin transporter

### ABSTRACT

**Background:** Pachydermoperiostosis (PDP) is a rare genetic disorder characterized by 3 major symptoms: pachydermia including cutis verticis gyrata (CVG), periostosis, and finger clubbing. Recently, a homozygous mutation in the gene *HPGD*, which encodes 15-hydroxyprostaglandin dehydrogenase (15-PGDH), was found to be associated with PDP. However, mutations in *HPGD* have not been identified in Japanese PDP patients.

**Objective:** We aimed to identify a novel responsible gene for PDP using whole exome sequencing by next-generation DNA sequencer (NGS).

**Methods:** Five patients, including 2 patient-parent trios were enrolled in this study. Entire coding regions were sequenced by NGS to identify candidate mutations associated with PDP. The candidate mutations were subsequently sequenced using the Sanger method. To determine clinical characteristics, we analyzed histological samples, as well as serum and urinary prostaglandin E2 (PGE2) levels for each of the 5 PDP patients, and 1 additional patient with idiopathic CVG.

**Results:** From initial analyses of whole exome sequencing data, we identified mutations in the solute carrier organic anion transporter family, member 2A1 (*SLCO2A1*) gene, encoding prostaglandin transporter, in 3 of the PDP patients. Follow-up Sanger sequencing showed 5 different *SLCO2A1* mutations (c.940+1G>A, p.E427\_P430del, p.G104\*, p.T347I, p.Q556H) in 4 unrelated PDP patients. In addition, the splice-site mutation c.940+1G>A identified in 3 of 4 PDP patients was determined to be a

**Abbreviations:** CVG, cutis verticisgyrata; NGS, next-generation DNA sequencer; PDP, pachydermoperiostosis; *SLCO2A1*, solute carrier organic anion transporter family member 2A1; PGT, prostaglandin transporter; SNP, single nucleotide polymorphism.

\* Corresponding author at: Department of Dermatology, National Center for Child Health and Development, 2-10-1 Okura, Setagaya-ku, Tokyo 157-8535, Japan.

Tel.: +81 3 3416 0181; fax: +81 3 5494 7909.

\*\* Corresponding author at: Laboratory of Gene Medicine, Keio University School of Medicine, 35 Shinanomachi, Shinjuku-ku, Tokyo 160-8582, Japan.

Tel.: +81 3 5363 3755; fax: +81 3 5843 6085.

E-mail addresses: niizeki-h@ncchd.go.jp (H. Niizeki), jkudoh@dmb.med.keio.ac.jp (J. Kudoh).

<sup>1</sup> These authors contributed equally to this work.

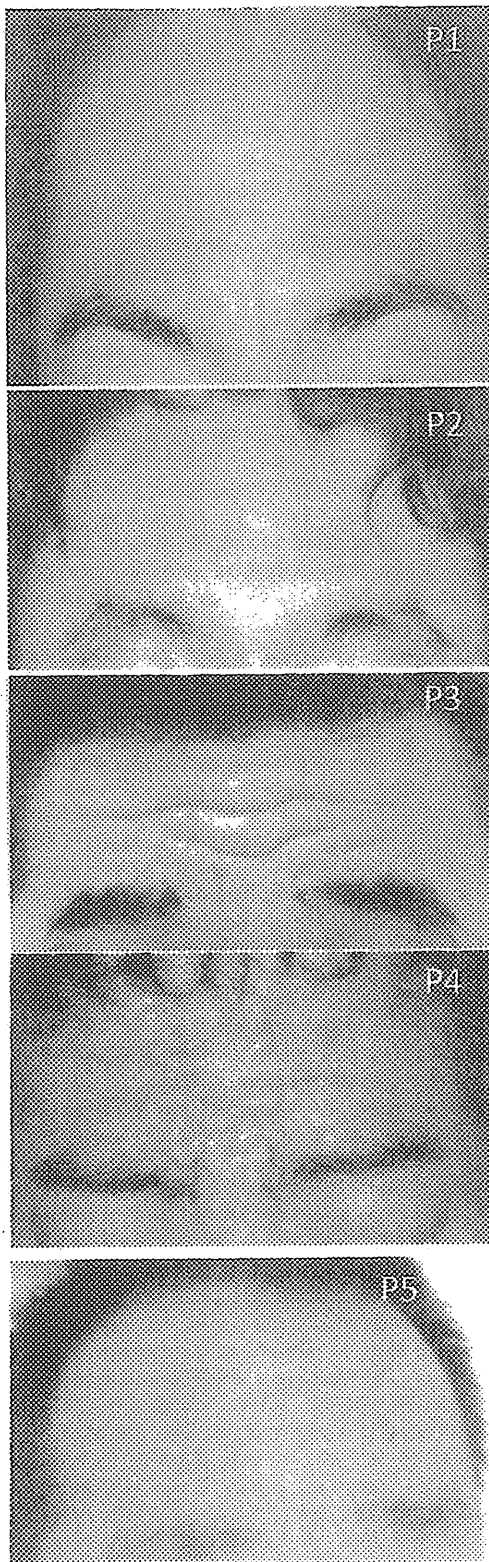


Fig. 1. Variation in forehead furrowing is associated with clinical forms of pachydermoperiostosis (PDP). Forehead furrows are apparent in the complete form of PDP, but less pronounced in the incomplete form. Greasiness of the skin was also evident in the complete form but not in the incomplete form of PDP.

hyperhidrosis of palms and soles. Pachydermia was prominent in the frontal, parietal, and occipital regions of the scalp as well as in the cheek and forehead skin (Fig. 1, P4). Endocrinological examinations showed no notable findings. Radiological

examination showed periostosis of the diaphysis of the radius, ulna, tibia, and fibula. Arthropathy was not evident. A skin biopsy specimen (Supplementary Fig. 1) taken from the scalp and forehead showed thickening of the dermis. Thick and interwoven collagen bundles, sebaceous and sweat gland enlargement, and mucin deposits in the dermis were also prominent. These findings met the diagnostic criteria of the complete form of PDP. His familial history was noncontributory. The patient refused the examination after being informed.

#### 2.1.5. Patient 5 (P5)

The case of this patient has been considered in another study [14]. Briefly, a 53-year-old man was referred to one of the authors. He had a 30-year history of digital clubbing and symmetric arthralgia of the knees. Physical examination showed transverse forehead furrows (Fig. 1, P5), but other skin manifestations, including seborrhea, acne, or hyperhidrosis were not evident. All laboratory tests, including thyroid function and serum levels of growth hormone, were within normal ranges, which ruled out thyroid acropathy and acromegaly. Magnetic resonance imaging of the brain showed CVG. Radiographic examination of the knee region showed periostosis with cortical thickening and ectopic ossification. Histological examination of the forehead skin showed acanthosis in the epidermis, sebaceous and sweat gland enlargement, and mucin deposits in the dermis. These findings met the diagnostic criteria of the complete form of PDP. His familial history was noncontributory.

#### 2.1.6. Patient 6 (P6)

This patient was 52 years old when referred to one of the authors. He presented with furrows in the occipital region of the scalp that he had noticed since the age of 17. At the age of 30, he underwent plastic surgery to lift these furrows. He had swelling and pain of the joints with unsymmetrical manner. The patient had been treated for pain in his right acromioclavicular joint, which had been persisted for 3 years. Physical examination showed no digital clubbing or thickening of the forehead skin. No biopsy specimen was available. Folliculitis was evident in the occipital region of the scalp. He also showed hypertrophic gingiva in the lower jaw. Radiological examination showed no apparent periostosis of the diaphysis of the radius and ulna. The patient was diagnosed with idiopathic CVG. His familial history was noncontributory.

#### 2.2. Measurement of prostaglandin E2 (PGE2) level in urine and serum

We examined serum and urinary levels of PGE2 using a commercial enzyme immunoassay kit (Cayman, Cayman Biochemical, Ann Arbor, MI, USA). Urinary and serum samples were stored in complete darkness at  $-30^{\circ}\text{C}$  until use.

#### 2.3. Extraction of genomic DNA and total RNA

Genomic DNA was isolated from peripheral blood samples obtained from the patients and their parents using the QIAamp DNA Blood Maxi Kit (QIAGEN KK, Tokyo, Japan).

For reverse transcriptase (RT)-PCR analysis, total RNA was isolated from a skin sample of P3 using a commercial extraction kit (RNeasy Mini Kit; QIAGEN KK, Tokyo, Japan).

#### 2.4. Whole exome sequencing

DNA fragments derived from exon regions were enriched using the SureSelect Human All Exon v4, according to the manufacturer's instructions (Agilent Technologies, Japan). The enriched DNA fragments were sequenced with the Illumina Genome Analyzer II according to the manufacturer's instructions, for 75 bp paired-end reads (Illumina, Japan). The raw image files were processed with

**Table 1**  
Summary of clinical phenotype, genotype and PGE2 contents.

Case	P1	P2	P3	P4	P5	P6
Current age (years)	24	25	45	37	53	52
Onset age (years)	13	12	17	10 <sup>§</sup>	20	17
Clinical form	Incomplete	Incomplete	Complete	Complete	Complete	Unclassified <sup>*</sup>
HPGD	ND	ND	ND	NA	ND	ND
SLCO2A1 allele 1	c.940+1G>A p.R288Gfs*7	c.310G>A p.G104 <sup>*</sup>	c.940+1G>A p.R288Gfs*7	NA	c.940+1G>A p.R288Gfs*7	ND
SLCO2A1 allele 2	c.1279_1290del12 p.E427_P430del	c.1040C>T p.T347I	c.940+1G>A p.R288Gfs*7	NA	c.1668G>C p.Q556H	ND
Serum PGE2 (pg/ml) <sup>**</sup>	30	83	3880	NA	1762	647.4
Urinary PGE2 (pg/ml)	650	2940	68,160	NA	414.7	172.5
<i>Triad</i>						
Digital clubbing	+	+	+	+	+	–
Periostosis	+	+	+	+	+	–
Pachydermia	+	+	+	+	+	+
Cutis verticis gyrata	–	–	+	+	+	+
<i>Skin</i>						
Palmar and plantar hyperhidrosis	+	+	–	–	–	–
Acne	+	+	–	+	–	+
Seborrhoea and eczema	+	+	+	+	–	–
Sebaceous hyperplasia with fibrotic change surrounding space <sup>⊗</sup>	+/- <sup>⊗</sup>	NA	+	++	+/-	NA
<i>Skeletal</i>						
History of bone fractures	–	–	–	+	–	–
Swelling of large joints	+	+	–	+	+	–
Painful joints on exercise	+	+	–	–	+ <sup>#</sup>	+ <sup>#</sup>
Hydrarthrosis	+	–	–	–	+ <sup>##</sup>	–
<i>Others</i>						
Anemia	–	–	–	+	–	–
Peptic ulcers of the stomach and duodenum	–	–	–	+ <sup>§</sup>	–	–
General fatigue	–	–	–	–	–	+
References	[11]	Present study	[12]	[13]	[14]	Present study

NA, not available; +, positive; –, negative or unknown; ND, (tested but) not detected.

<sup>§</sup> Treated with vagotomy at the age of 10.

<sup>\*</sup> Having idiopathic cutis verticis gyrata (CVG).

<sup>\*\*</sup> Normal range: 25–200 pg/mL.

<sup>⊗</sup> On histologic examination: ++, prominent; +, obvious; +/-, subtle.

<sup>⊗</sup> Fibrotic change was observed only in superficial dermis.

<sup>#</sup> Active stage at current age.

<sup>##</sup> Arthroscopy revealed diffuse osteosclerosis and ectopic ossification.

**Table 2**  
Variation summary statistics for whole exome sequencing of four PDP patients.

	Total variation	SS-NSVs	Known variation		Unknown variation					
			dbSNPs135	Other <sup>a</sup>	SS	NS	SL	SG	FS	MS
P1	38,746	10,484	9943	384	2	6	1	0	12	136
P2	36,392	10,342	9837	358	4	8	1	1	9	124
P5	40,539	11,037	10,492	389	2	6	1	2	10	135
P6	41,957	11,222	10,614	427	1	4	0	4	15	157

<sup>a</sup> 1K genome, JPN exome.

We also analyzed whole exome sequencing data of 100 Japanese individuals generated by the 1000 Genomes Project to ascertain the frequencies of these *SLCO2A1* mutations in the Japanese population. Although we found 6 known SNPs and 1 novel synonymous mutation in the *SLCO2A1* coding region, none of the *SLCO2A1* mutations identified in the PDP patients were found in the 200 Japanese control alleles (data not shown).

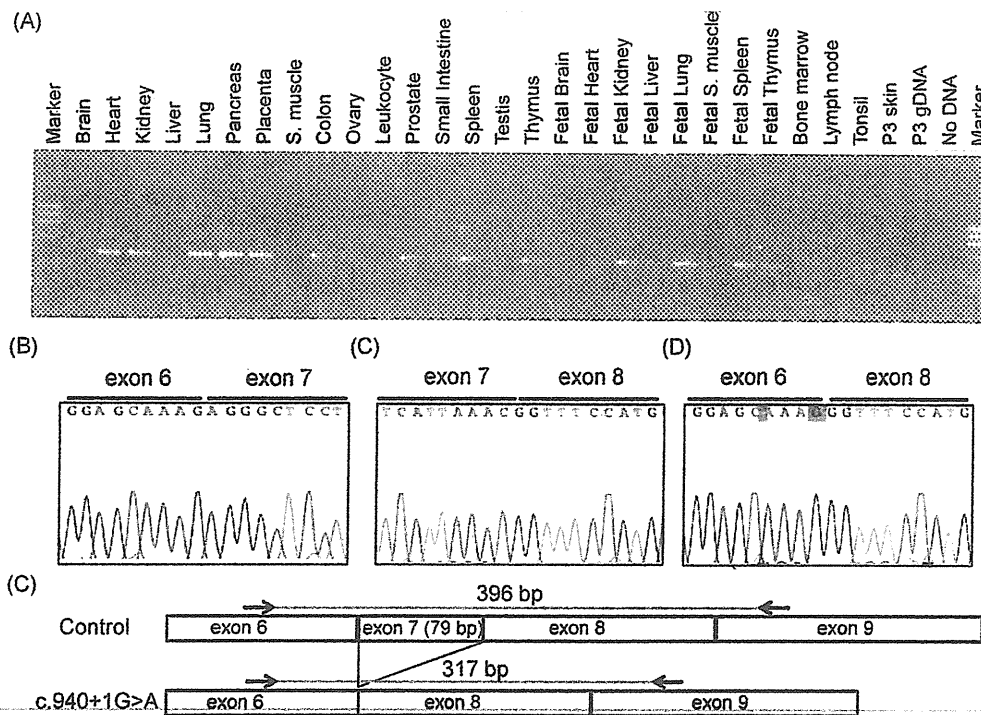
In summary, we identified *SLCO2A1* compound heterozygous mutations in 3 PDP patients, and *SLCO2A1* homozygous mutations in 1 PDP patient; no *SLCO2A1* mutation was found in P6, who shows only CVG in 3 major symptoms of PDP (Table 1).

To exclude the possibility that the c.217delA mutation in the *ZNF98* gene is a causative or a modifier mutation, we sequenced the coding region of *ZNF98* in 4 PDP patients as well as in the parents of P1 and P2. We found a single heterozygous c.217delA mutation in 2 of the PDP patients and one of the parents. However, c.217delA was not found in the other 2 PDP patients. Phenotypic comparisons

indicated that no specific phenotype was associated with the c.217delA mutation. Therefore, we deduced that the c.217delA mutation of *ZNF98* does not have a modifier effect on PDP.

### 3.3. Haplotype and a founder mutation analysis of *SLCO2A1*

In this study, we characterized 4 alleles in 3 PDP patients with the c.940+1G>A SS mutation. In order to determine whether this mutation was a founder mutation, we analyzed SNPs in the *SLCO2A1* gene. On the basis of the analysis of 9 SNPs, we identified 6 haplotypes in the 46-kb region of the *SLCO2A1* gene (Table 3). Among the 4 alleles with the c.940+1G>A SS mutation, 8 of 9 SNPs are identical and only one SNP is different in one of 4 alleles. This SNP (rs10935090) is located in the most upstream region of *SLCO2A1* in exon1 among these 9 SNPs. In addition, we found that SNP (rs10935090) is localized different LD block compared with other 8 SNPs in Japanese HapMap data. These results suggest that



**Fig. 3.** Splice site mutation c.940+1G>A causes loss of exon 7 in *SLCO2A1* mRNA. (A) RT-PCR product amplified between exon 6 and exon 9 in *SLCO2A1*. Although *SLCO2A1* mRNA of the expected size is expressed in a wide variety of human tissues, only a smaller PCR product was obtained from the skin biopsy specimen taken from P3 who was homozygous for the c.940+1G>A SS mutation. (B–D) Sequence analysis of the PCR products generated between exon 6 and exon 9. The exon 7 region was detected in the exon boundaries of RT-PCR products from lung tissues (B, C). No exon 7 sequence was detected in the PCR product derived from skin mRNA of P3 (D). (E) Schematic representation of the exon 7 skipping. The *SLCO2A1* c.940+1G>A SS mutation located in the splice donor site of intron 7, which results in the loss of exon 7 and a truncation of PGT.

gene would cause the failure of PGE re-uptake, resulting in high PGE2 levels in the skin tissue, serum, and urine.

Of the 4 PDP patients screened, 1 carried a homozygous mutation, where as the other 3 carried compound heterozygous mutations in the *SLCO2A1* gene. All 4 PDP patients who possessed *SLCO2A1* mutations showed typical PDP phenotypes which are classified into the complete or incomplete forms. However, no significant mutations in the *SLCO2A1* gene were identified in the sole patient with CVG. Among the 8 alleles of *SLCO2A1* identified in this study, 4 (50%) included the same SS mutation (c.940+1G>A), which would be derived from a single founder allele. The other 4 *SLCO2A1* mutations were found in one of mutations in compound heterozygotes (summarized in Table 1). Analysis of *SLCO2A1* transcripts in P3, who was homozygous for the c.940+1G>A SS mutation, showed that the mutation resulted in the loss of exon 7 and a truncation of the PGT protein.

Among the 5 types of *SLCO2A1* mutations we identified, the NS mutation p.G104\* and the c.940+1G>A SS mutation are considered to be severe mutations, as they result in truncations of the PGT protein. The p.Q556H mutation is located in the highly conserved 11th transmembrane domain adjacent to 1 of 3 critical amino acid residues (Glu78, Arg561, or Lys614) for PG transport activity [18] (Fig. 4). No information has been reported in previous investigations of PGT with regard to the potential functional impacts of the 2 mutations p.T347I and p.E427-P430del. Thr-347 is located in the extracellular region between the 7th and 8th transmembrane domains and is highly conserved in human, mouse, chicken, frog, and zebrafish (Fig. 4). The amino acid sequence containing the p.E427-P430del mutation (EVYP) is located in the extracellular region between the 9th and 10th transmembrane domains. The amino acid sequence (V/I)YP is conserved in human, mouse, chicken, and zebrafish, but not in frog (Fig. 4). Therefore, it is possible that the amino acid deletion mutation p.E427-P430del could have a less severe effect on PG transport activity.

Collectively, we deduced that the homozygous status of the c.940+1G>A SS mutation observed in P3, would have the most severe impact on PGT function. Compound heterozygotes with an c.940+1G>A SS mutation and a p.Q556H mutation, for example P5, would also be expected to have hindered PGT function, although to a lesser extent than c.940+1G>A homozygotes.

For *ZNF98*, we found a single heterozygous c.217delA mutation in 2 of the 4 PDP patients in one of their parents who did not have PDP. Phenotypic comparison indicated that no specific phenotype was associated with PDP patients who possess a single heterozygous c.217delA mutation. Therefore, we deduced that the c.217delA mutation of *ZNF98* does not have a modifier effect on PDP.

#### 4.2. Genotype–phenotype correlation in PDP

*SLCO2A1* mutations and clinical phenotypes of 6 patients are summarized in Table 1. Interestingly, P3, diagnosed with the complete form of PDP, was homozygous for the severe c.940+1G>A SS mutation, whereas P1, P2, and P5 were all found to be compound heterozygotes for *SLCO2A1* mutations represented both the incomplete form (P1, P2) and the complete form (P5) of PDP, carrying a severe mutation (either c.940+1G>A SS mutation or NS mutation) and another *SLCO2A1* mutation. The severity of pachydermia and associated histological changes was also correlated with *SLCO2A1* genotypes (Fig. 1 and Table 1). In addition, serum and urinary PGE2 levels in P3 were much higher than those observed for other PDP patients. Together, clinical data and genetic analyses showed that *SLCO2A1* genotypes in PDP patients were closely associated with serum PGE2 levels, suggesting that *SLCO2A1* mutations contribute to the severity of clinical phenotypes in PDP.

It was previously reported that transgenic mice with the K5 promoter – PTGS2 (also known as Cox2) transgene, exhibit high