

CLINICAL CHARACTERISTICS OF OCCULT MACULAR DYSTROPHY IN FAMILY WITH MUTATION OF *RP1L1* GENE

KAZUSHIGE TSUNODA, MD, PhD,* TOMOAKI USUI, MD, PhD,†‡ TETSUHISA HATASE, MD, PhD,† SATOSHI YAMAI, MD,§ KAORU FUJINAMI, MD,* GEN HANAZONO, MD, PhD,* KEI SHINODA, MD, PhD,*¶ HISAO OHDE, MD, PhD,** MASAKAZU AKAHORI, PhD,* TAKESHI IWATA, PhD,* YOZO MIYAKE, MD, PhD*††

Purpose: To report the clinical characteristics of occult macular dystrophy (OMD) in members of one family with a mutation of the *RP1L1* gene.

Methods: Fourteen members with a p.Arg45Trp mutation in the *RP1L1* gene were examined. The visual acuity, visual fields, fundus photographs, fluorescein angiograms, full-field electroretinograms, multifocal electroretinograms, and optical coherence tomographic images were examined. The clinical symptoms and signs and course of the disease were documented.

Results: All the members with the *RP1L1* mutation except one woman had ocular symptoms and signs of OMD. The fundus was normal in all the patients during the entire follow-up period except in one patient with diabetic retinopathy. Optical coherence tomography detected the early morphologic abnormalities both in the photoreceptor inner/outer segment line and cone outer segment tip line. However, the multifocal electroretinograms were more reliable in detecting minimal macular dysfunction at an early stage of OMD.

Conclusion: The abnormalities in the multifocal electroretinograms and optical coherence tomography observed in the OMD patients of different durations strongly support the contribution of *RP1L1* mutation to the presence of this disease.

RETINA 32:1135–1147, 2012

Occult macular dystrophy (OMD) was first described by Miyake et al¹ to be a hereditary macular dystrophy without visible fundus abnormalities. Patients with OMD are characterized by a progressive decrease of visual acuity with normal-appearing fundus and normal fluorescein angiograms (FA). The important signs of OMD are normal full-field electroretinograms (ERGs) but abnormal focal macular ERGs and mul-

tifocal electroretinograms (mfERGs) also exist. These findings indicated that the retinal dysfunction was confined to the macula.^{1–5} Optical coherence tomography (OCT) showed structural changes in the outer nuclear and photoreceptor layers.^{6–11}

Recently, we found that dominant mutations in the *RP1L1* gene were responsible for OMD.¹² The *RP1L1* gene was originally cloned as a gene derived from common ancestors as a retinitis pigmentosa 1 (*RPI*) gene, which is responsible for 5–10% of autosomal dominant retinitis pigmentosa worldwide, on the same Chromosome 8.^{13–17} A number of attempts have been made to identify mutations in *RP1L1* in various retinitis pigmentosa patients with no success. An immunohistochemical study on cynomolgus monkeys showed that *RP1L1* was expressed in rod and cone photoreceptors, and *RP1L1* is thought to play important roles in the morphogenesis of the photoreceptors.^{13,18} Heterozygous *RP1L1* knockout mice were reported to be normal, whereas homozygous knockout mice develop subtle retinal degeneration.¹⁸ However, the *RP1L1* protein has a very low degree of overall sequence

From the *Laboratory of Visual Physiology, National Institute of Sensory Organs, Tokyo, Japan; †Division of Ophthalmology and Visual Science, Graduate School of Medical and Dental Sciences, Niigata University, Niigata, Japan; ‡Akiba Eye Clinic, Niigata, Japan; §Department of Ophthalmology, Sado General Hospital, Niigata, Japan; ¶Department of Ophthalmology, School of Medicine, Teikyo University, Tokyo, Japan; **Department of Ophthalmology, School of Medicine, Keio University, Tokyo, Japan; and ††Aichi Medical University, Aichi, Japan.

The authors have no financial interest or conflicts of interest.

Supported in part by research grants from the Ministry of Health, Labor and Welfare, Japan and Japan Society for the Promotion of Science, Japan.

Reprint requests: Kazushige Tsunoda, Laboratory of Visual Physiology, National Institute of Sensory Organs, 2-5-1 Higashigaoka, Meguro-ku, Tokyo 152-8902, Japan; e-mail: tsunodakazushige@kankakuki.go.jp

identity (39%) between humans and mice compared with the average values of sequence similarity observed between humans and mice proteins. The results of linkage studies have strongly supported the contribution of *RP11* mutations to the presence of this disease,¹² but the function of *RP11* in the human retina has not been completely determined.

A large number of cases of OMD have been reported^{7,10,19}; however, we did not always find the same mutations in sporadic cases or in small families, which had less than three affected members. This led us to hypothesize that several independent mutations can lead to the phenotype of OMD, that is, OMD is not a single disease caused by a specific gene mutation, but may represent different diseases with similar retinal dysfunctions.

Thus, the aim of this study was to determine the characteristics of OMD by investigating the phenotypes of patients with the *RP11* mutation from a single Japanese family.

Patients and Methods

We investigated 19 members from a single Japanese family. A homozygous mutation, p.Arg45Trp in the *RP11* gene, was confirmed in 14 members,¹² and 13 of the 14 were diagnosed with OMD. Among the 14 members with a mutation in the *RP11* gene, 11 were followed-up at the Niigata University in Niigata, Japan. The other three were examined at the National Institute of Sensory Organs in Tokyo, Japan. Each member had a complete ophthalmic examination including best-corrected visual acuity (BCVA), refraction, perimetry, fundus photography, FA, full-field ERGs,²⁰ mfERGs,²¹ and OCT. The visual fields were determined by Goldmann perimetry or by Humphrey Visual Field Analyzer (Model 750i; Carl Zeiss Meditec, Inc, Dublin, CA). The SITA Standard strategy was used with the 30-2 program or the 10-2 program for the Humphrey Visual Field Analyzer.

Electroretinograms were used to assess the retinal function under both scotopic and photopic conditions.²² Full-field ERGs were recorded using the International Society of Clinical Electrophysiology and Vision standard protocol. Multifactorial electroretinograms were recorded with the Visual Evoked Response Imaging System (VERIS science 4.1; EDI, San Mateo, CA). A Burian–Allen bipolar contact lens electrode was used to record the mfERGs. The visual stimuli consisted of 61 or 103 hexagonal elements with an overall subtense of approximately 60°. The luminance of each hexagon was independently modulated between black (3.5 cd/m²) and white (138.0 cd/m²) according to

a binary m-sequence at 75 Hz. The surround luminance was 70.8 cd/m².

The OCT images were obtained with a spectral-domain OCT (HD-OCT; Carl Zeiss Meditec or a 3D-OCT-1000, Mark II; Topcon) from 21 eyes of 12 cases in the same pedigree.

The procedures used adhered to the tenets of the Declaration of Helsinki and were approved by the Medical Ethics Committee of both the Niigata University and National Institute of Sensory Organs. An informed consent was received from all the subjects for the tests.

Results

The findings of 5 generations of 1 family with OMD are shown in Figure 1. The numbered family members had the same mutation in *RP11* (p.Arg45Trp), and family members designated with the filled squares or filled circles were phenotypically diagnosed with OMD by routine examinations including visual field tests, FA, mfERGs, and Fourier-domain OCT. Only Patient 5 (age 60 years) had normal phenotype, although she had the *RP11* mutation.

The clinical characteristics and the results of ocular examinations of all the 14 family members with the *RP11* mutation (p.Arg45Trp) are listed in Tables 1 and 2. Family Member #5 was diagnosed as normal because she had normal mfERGs.

Among the 13 OMD patients (average age at the final examination, 57.2 ± 22.1 years), 12 complained of disturbances of central vision and 4 complained of photophobia (Table 1). Patient 1 did not report any visual disturbances in the right eye as did Patient 6 for both eyes. The visual dysfunction in these eyes was confirmed by mfERGs. For 13 patients, the age at the onset of visual difficulties varied from 6 years to 50 years with a mean of 27.3 ± 15.1 years.

All the patients were affected in both eyes, and the onset was the same in the 2 eyes except for Patients 1, 11, 12, and 14. Patient 1 first noticed a decrease in her visual acuity in her left eye at age 50 years, and she still did not have any subjective visual disturbances in her right eye 30 years later. However, a clear decrease in the mfERGs in the macular area was detected in both eyes. Patient 11 first noticed a decrease in the visual acuity in her right eye at age 47 years when the BCVA was 0.2 in the right eye and 1.2 in the left eye (Figure 2). Seven years later at age 54 years, she noticed a decrease in the vision in her left eye. Similarly, Patients 12 and 14 did not report any visual disturbances in their right eyes until 2 (Patient 12) or 8 (Patient 14) years after the onset in their left eyes.

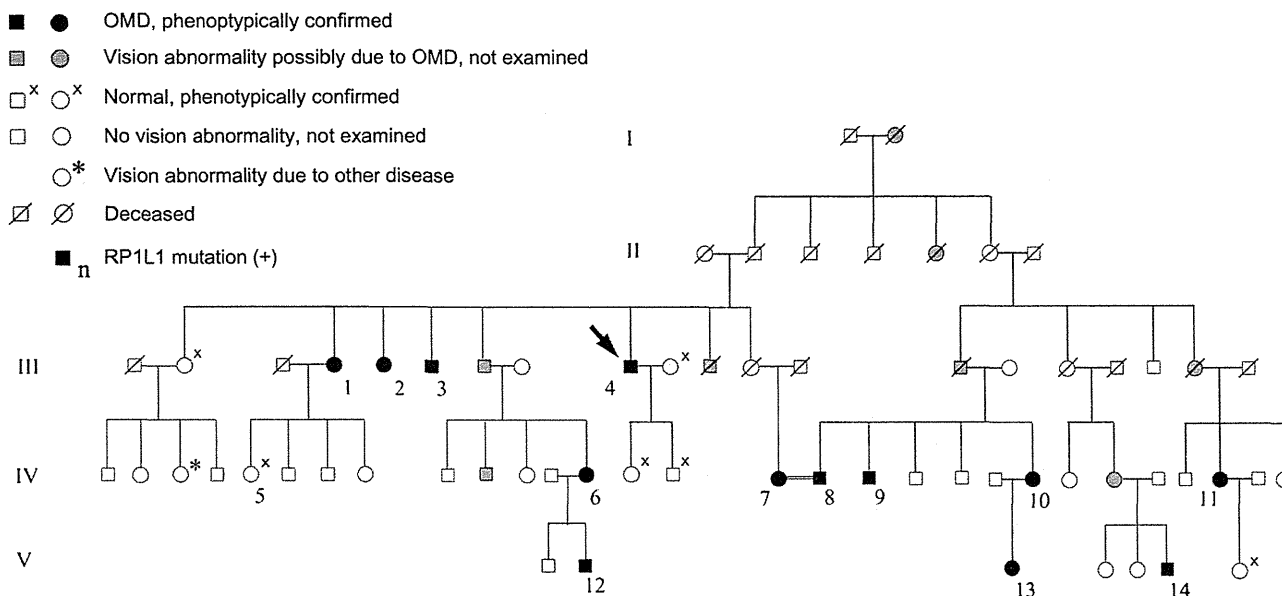


Fig. 1. Pedigree of a family with OMD. The identification number of the patients is marked beside the symbols. The proband is indicated by an arrow. The open squares and circles with crosses are the relatives whose visual function was confirmed to be normal by routine examinations including Humphrey visual field tests, mfERGs, and Fourier-domain OCT. Those designated by hatched squares or circles were reported to have poor vision with similar severity and onset as the other genetically confirmed OMD patients. One relative marked by an asterisk had unilateral optic atrophy because of retrobulbar neuritis.

The duration of the continuous decrease in the BCVA varied from 10 years to 30 years (mean, 15.6 ± 7.7 years) in 16 eyes of 9 adult patients. After this period, these patients reported that their vision did not decrease. Patients 2, 3, 8, and 14 complained of photophobia, and the degree of photophobia remained unchanged after the visual acuity stopped decreasing. Patients 1, 2, 4, 7, and 9 had additional disturbances of vision because of senile cataracts, and Patients 2 and 4 had bilateral cataract surgery. The visual disturbances because of the OMD were still progressing at the last examination in the left eye of Patient 11 (age 57 years), and both eyes of Patient 12 (age 20 years), Patient 13 (age 18 years), and Patient 14 (age 28 years).

Different systemic disorders were found in some of the patients; however, there did not seem to be a specific disorder, which was common to all of them (Table 1).

In the 16 eyes of 9 patients whose BCVA had stopped decreasing, the BCVA varied from 0.07 to 0.5 (Table 2). The BCVA of the left eye of Patient 6 was 0.07 because of an untreated senile cataract. If this eye is excluded, the final BCVAs of all the stationary eyes range from 0.1 to 0.5. Patient 2 had photophobia, and her BCVA measured by manually presenting Landolt rings on separate cards under room light was 0.4 in the right eye and 0.5 in the left eye, which was better than that measured by a Landolt chart of 0.3 in the right eye and 0.3 in the left eye with background illumination.

For the 13 patients whose original refractions were confirmed, 11 of 26 eyes were essentially emmetropic

($< \pm 0.5$ diopters). Both eyes of Patients 1, 3, 4, 6, and 8 and the left eye of Patient 5 were hyperopic (+0.675 to +4.625 diopters). The right eye of Patient 7, the left eye of Patient 12, and both eyes of Patient 13 were moderately myopic (-0.625 to -2.75 diopters). These results indicate that there is no specific refraction associated with OMD patients in this family.

The visual fields were determined by Goldmann perimetry or Humphrey Visual Field Analyzer. All the patients had a relative central scotoma in both eyes except for Patient 1 whose right eye was normal by Goldmann perimetry. In all cases, no other visual field abnormalities were detected during the entire course of the disease. In the patients examined shortly after the onset, a relative central scotoma was not detected by Goldman perimetry and was confirmed by static perimetry.

The fundus of all except one eye was normal. The left eye of Patient 9 had background diabetic retinopathy. At the first consultation at age 46 years, Patient 9 did not have diabetes, and the fundoscopic examination and FA revealed no macular abnormalities. At the age 66 years, there were few microaneurysms in the left macula away from the fovea; however, OCT did not show any diabetic changes such as macular edema. The OMD was still the main cause of visual acuity reduction in this patient.

Six patients consented to FA, and no abnormality was detected in the entire posterior pole of the eye. It is noteworthy that both the fundus and FA of Patient 4 were normal at the age 73 years, which was >50 years

Table 1. Clinical Characteristics of the Family Members With RP1L1 Mutation (p.Arg45Trp)

Case	Age and Gender	Chief Complaint	Affected Eye	Age at Onset (Years)	Duration of Continuous Decrease in BCVA (Years)	Duration After the Onset (Years)	
1	81, F	Decreased visual acuity	Bilateral*	50	20	31	Hypertens
2	71, F	Decreased visual acuity and photophobia	Bilateral	25	25	46	Diabetes
3	74, M	Decreased visual acuity and photophobia	Bilateral	30	10	44	Hyperlipid
4	83, M	Decreased visual acuity	Bilateral	20	10	63	Hypertens infarcti
5	60, F	None	—†	—	—	—	
6	50, F	None	Bilateral*	Unknown	Unknown	Unknown	
7	69, F	Decreased visual acuity	Bilateral	50	10	19	
8	69, M	Decreased visual acuity and photophobia	Bilateral	28	10	41	Hypertens for ossi of the p ligamen
9	66, M	Decreased visual acuity	Bilateral	30	15	36	Diabetes
10	58, F	Decreased visual acuity	Bilateral	10	30	48	Rheumatc of age, 43 year
11	57, F	Decreased visual acuity	Bilateral ‡	47	OD, 10, OS, still progressing	10	
12	20, M	Decreased visual acuity	Bilateral§	14	Still progressing	6	Atopic de
13	18, F	Decreased visual acuity	Bilateral	6	Still progressing	12	
14	28, M	Decreased visual acuity and photophobia	Bilateral¶	18	Still progressing	10	

*Patient 1 has subjective visual disturbance only in the left eye, and Patient 6 does not have any subjective visual disturbances in both eyes. †mfERG.

†This woman has a mutation in RP1L1, but her visual function was confirmed normal after routine examinations including mfERG.

‡This patient noticed visual disturbance only in the right eye at 47 years of age. The visual disturbance in the left eye was first noticed at

§This patient noticed visual disturbance only in the left eye at 14 years of age. The visual disturbance in the right eye was first noticed at

¶This patient noticed visual disturbance only in the left eye at 18 years of age. The visual disturbance in OD was first noticed at 26 years of age.

Table 2. Results of Ocular Examinations of the Family Members With RP1L1 Mutation

Case	Age and Gender	BCVA at Final Visit		Refraction (D)*		Visual Field	Fundus Appearance	FA	Full-Field ERG
		OD	OS	OD	OS				
1	81, F	1.2	0.1	+4.25	+4.625	Relative central scotoma, OS	Normal, OU	Normal, OU	NE
2	71, F	0.4	0.5	Unknown‡	Unknown‡	Relative central scotoma, OU	Normal, OU	NE	NE
3	74, M	0.2	0.3	+2.875	+3.375	Relative central scotoma, OU	Normal, OU	NE	NE
4	83, M	0.2	0.2	+1.0	+1.625	Relative central scotoma, OU	Normal, OU	Normal, OU	Normal ISCEV standard protocol ERG, OU
5	60, F	1.2	1.2	-0.25	+0.875	Normal, OU	Normal, OU	NE	NE
6	50, F	1.2	1.2	+1.0	+1.0	Relative central scotoma, OU	Normal, OU	NE	NE
7	69, F	0.1§	0.07§	-0.625	+0.25	Relative central scotoma, OU	Normal, OU	NE	Normal ISCEV standard protocol ERG, OU
8	69, M	0.1	0.1	+1.125	+0.675	Relative central scotoma, OU	Normal, OU	NE	Normal ISCEV standard protocol ERG, OU

Table 2. (Continued)

Case	Age and Gender	BCVA at Final Visit		Refraction (D)*		Visual Field	Fundus Appearance	FA	Full-Field ERG
		OD	OS	OD	OS				
9	66, M	0.2	0.3	+0.125	+0.125	Relative central scotoma, OU	Normal, OD Background diabetic retinopathy with microaneurysm, OS	Normal, OU	Normal mixed rod-cone responses, OU
10	58, F	0.1	0.1	+0.5	+0.375	Relative central scotoma, OU	Normal, OU	NE	Normal cone responses, OU
11	57, F	0.1	0.4	+0.5	0.0	Relative central scotoma, OU	Normal, OU	Normal, OU	Normal ISCEV standard protocol ERG, OU
12	20, M	0.3	0.3	-0.375	-0.75	Relative central scotoma, OU	Normal, OU	Normal, OU	Normal ISCEV standard protocol ERG, OU
13	18, F	0.2	0.15	-1.625¶	-2.75¶	Relative central scotoma, OU	Normal, OU	Normal, OU	Normal ISCEV standard protocol ERG, OU
14	28, M	1.0	0.6	-0.25	-0.25	Relative central scotoma, OU	Normal, OU	NE	Normal ISCEV standard protocol ERG, OU

D, diopter; ISCEV, International Society of Clinical Electrophysiology and Vision; NE, not examined.

*Spherical equivalents at the initial visit.

†The responses of Ring 1 were extinguished and the N1-P1 amplitudes were not measurable in Cases 2, 3, 4, 7, 10, 11, and 13.

‡This patient had already undergone cataract surgeries for both eyes at the initial visit, and no data could be obtained about the original

§This patient's visual acuity was reduced also by senile cataract.

¶The refraction of this patient was measured after instillation of cycloplegics.

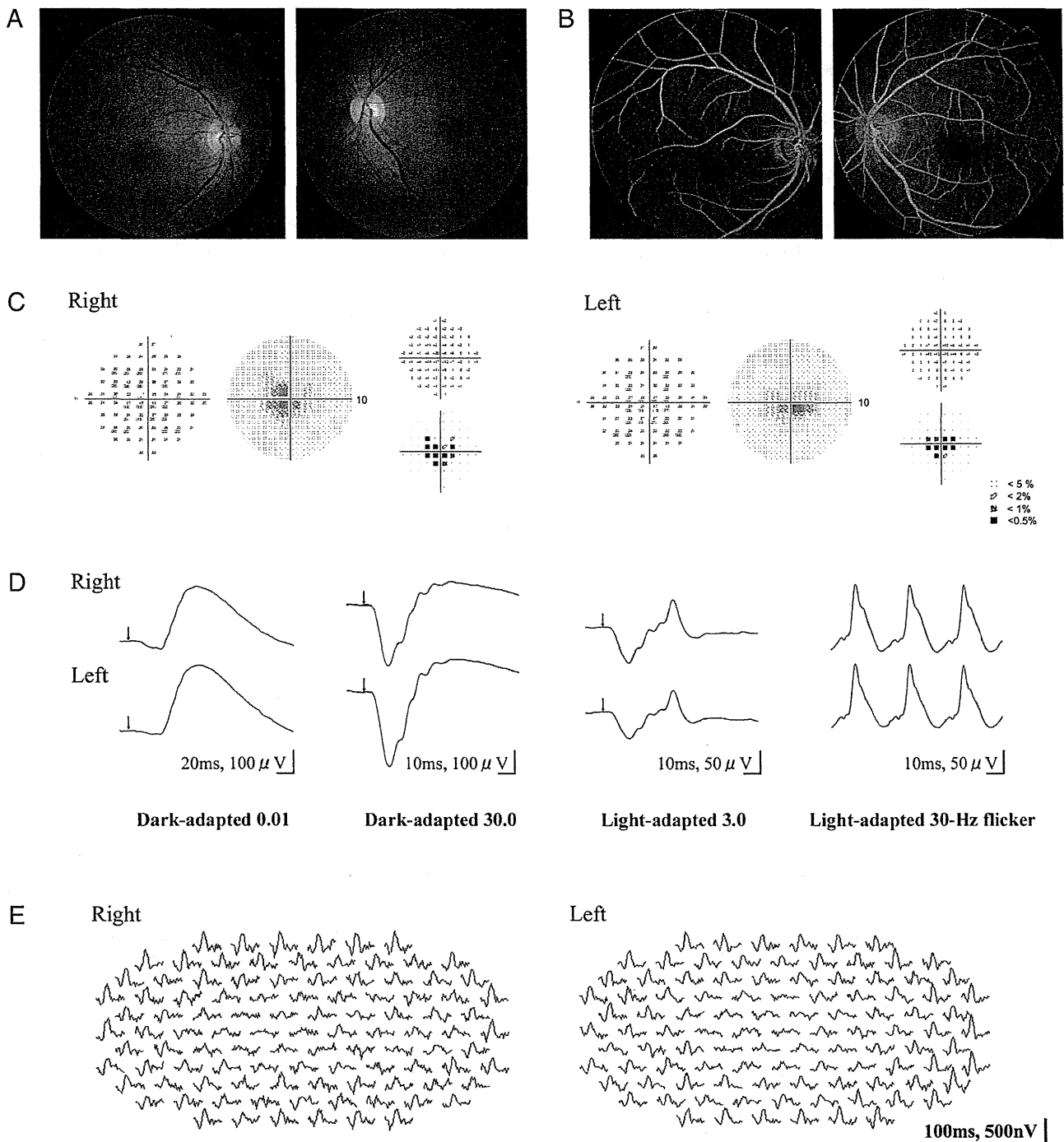


Fig. 2. Results of ocular examination of Patient 11. The data in (A) to (E) were collected 3 years after the onset of the visual disturbance at age 50 years. At this time, the patient had not noticed a decrease in the visual acuity in her left eye. The BCVA was 0.1 in the right eye and 1.2 in the right eye. A, and B. Fundus photographs and FAs showing no abnormal findings. C. Static visual field test (Humphrey Visual Field Analyzer, 10-2) showing relative central scotoma in both eyes. D. Full-field rod, mixed rod-cone, cone ERGs, and 30-Hz flicker responses. All the responses are normal in both eyes. E. Trace arrays of mfERGs tested with 103 hexagonal stimuli shown without spatial averaging. The responses of the central locus are extinguished in both eyes.

after the onset. This patient first noticed visual disturbances at age 20 years and was diagnosed with OMD at age 73 years. The appearance of the macula and optic disk at age 83 years was still normal >60 years after the onset of the symptoms.

Rod, mixed rod-cone, and cone full-field ERGs were recorded from 7 patients using the International Society of Clinical Electrophysiology and Vision standard protocol, and all of them showed normal rod and cone responses as in the representative case shown in

Figure 2. Only the mixed rod–cone responses were recorded from Patient 9, and only the cone responses were recorded from Patient 10, and these responses were also normal.

The amplitudes of the mfERGs were reduced in the central region of both eyes in all the 13 patients. We quantified the relative mfERG responses at the fovea by dividing the N1–P1 amplitudes of the central ring (Ring 1) by those in the outermost eccentric ring (Ring 5 in cases of 61 stimuli and Ring 6 in cases of 103 stimuli) in 13 OMD patients and 1 normal family member (Case 5) with the *RP1L1* mutation (Table 2).⁴ Among the 26 eyes of the 13 OMD patients, the N1–P1 amplitudes of the central locus were measurable in 12 eyes in 6 cases tested with the 61 stimuli. The ratio of the amplitudes of Ring 1/Ring 5 in these OMD patients ranged from 0.60 to 2.74 (average of normals: 4.34 ± 0.67 , $n = 20$). In 6 eyes tested with 61 stimuli and all the 8 eyes tested with 103 stimuli, the responses in the central locus were extinguished and the amplitudes were not measurable (see examples in Figure 2E). The ratio of the amplitudes of Ring 1/Ring 5 in a normal family member (Case 5, right eye) was 4.24, which was within the normal range.

The results of routine ocular examinations in Patient 11 at the age 50 years, when she did not have any visual disturbances in her left eye, are shown in Figure 2. The BCVA was 0.1 in the right eye and 1.2 in the left eye. The fundus and FA were normal in both eyes. Humphrey visual field tests (SITA Standard and pattern deviation 10-2) showed a relative central scotoma in both eyes. The full-field rod, mixed rod–cone, cone, and 30-Hz flicker ERGs were normal in both eyes. The mfERGs were reduced in and around the region of the central scotoma in both eyes. The Humphrey visual field test (30-2) did not detect a central scotoma in either eye (data not shown). The findings in the left eye of this patient are typical of the early stage of the OMD, where the dysfunction of the foveal region could be clearly detected in the mfERGs even though the subjective visual disturbance was almost undetectable.

Spectral-domain OCT images were recorded from 11 family members with the *RP1L1* mutation. The outer retinal structure was considered to be normal when the external limiting membrane, photoreceptor inner/outer segment (IS/OS) line, cone outer segment tip (COST) line, and retinal pigment epithelium (RPE) were clearly detected in the OCT images (Figure 3A).^{11,23}

The OCT images of 5 representative OMD patients are aligned in the order of years after the onset in Figure 3B. The right eye of Case 1, which had electrophysiologically confirmed macular dysfunction but did not have subjective visual disturbances, showed a normal IS/OS line and COST line but only at the

foveal center (asterisk in Figure 3B, ①). However, in the parafoveal region, the IS/OS line was blurred and the COST line could not be observed (arrowheads in Figure 3B, ①).

In the right eye of Case 11, the OCT images which were taken 10 years after the onset showed that the IS/OS line at the fovea was very blurred and thick but not disrupted. The COST line could not be observed in the macular area. In the perimacular region that had normal visual function, all the outer retinal structures were seen to be normal (Figure 3B, ②). Similar findings were observed in the left eye of Case 1 and the right eye of Case 8 (Figure 3B, ③ and ④).

In the right eye of Case 4, which was examined 63 years after the onset, the IS/OS line was disrupted at the fovea. The COST line could not be observed in the macula but was still visible in the perimacular region. The external limiting membrane and RPE could be observed to be normal over the entire region (Figure 3B, ⑤).

The OCT images of 2 sporadic cases of OMD without the *RP1L1* mutation are shown in Figure 3C. Both patients had a progressive central scotoma with normal-appearing fundus and normal FA. The full-field ERGs were normal but the focal macular ERGs elicited with a 10° spot were not recordable. Their OCT images, however, were not similar to those in patients with *RP1L1* mutation; the IS/OS line could be clearly observed at the fovea (Figure 3C, ① and ②), and the COST line could also be observed at the fovea, although it was slightly more blurred than in the normal cases. There was a minute disruption of the IS/OS line at the foveola in 1 case (asterisk in Figure 3C, ①).

The OCT findings in 21 eyes of 11 cases with the *RP1L1* mutation are summarized in Table 3. The examined eyes are listed in the order of years after the onset. Case 5, who was diagnosed as not having the typical characteristics of OMD, had completely normal retinal structures. In the case of OMD without subjective visual disturbances, the COST line and IS/OS line were normally observed only at the very center of the fovea (Case 1, right eye, Figure 3B, ①). In other affected cases, the COST line was not present and the IS/OS line appeared blurred in the entire fovea (Cases 14, right eye to 8). In patients with longer duration OMD, the IS/OS line was disrupted or not present as in Cases 2 and 4.

The retinal thickness at the foveola was measured as the distance from the internal limiting membrane to the inner border of the RPE. Considering the variation in the thickness in normals, we classified that the retina at the foveola was abnormally thin when the thickness was $<160 \mu\text{m}$. All the affected eyes with disease duration ≤ 12 years had normal foveal thickness (right

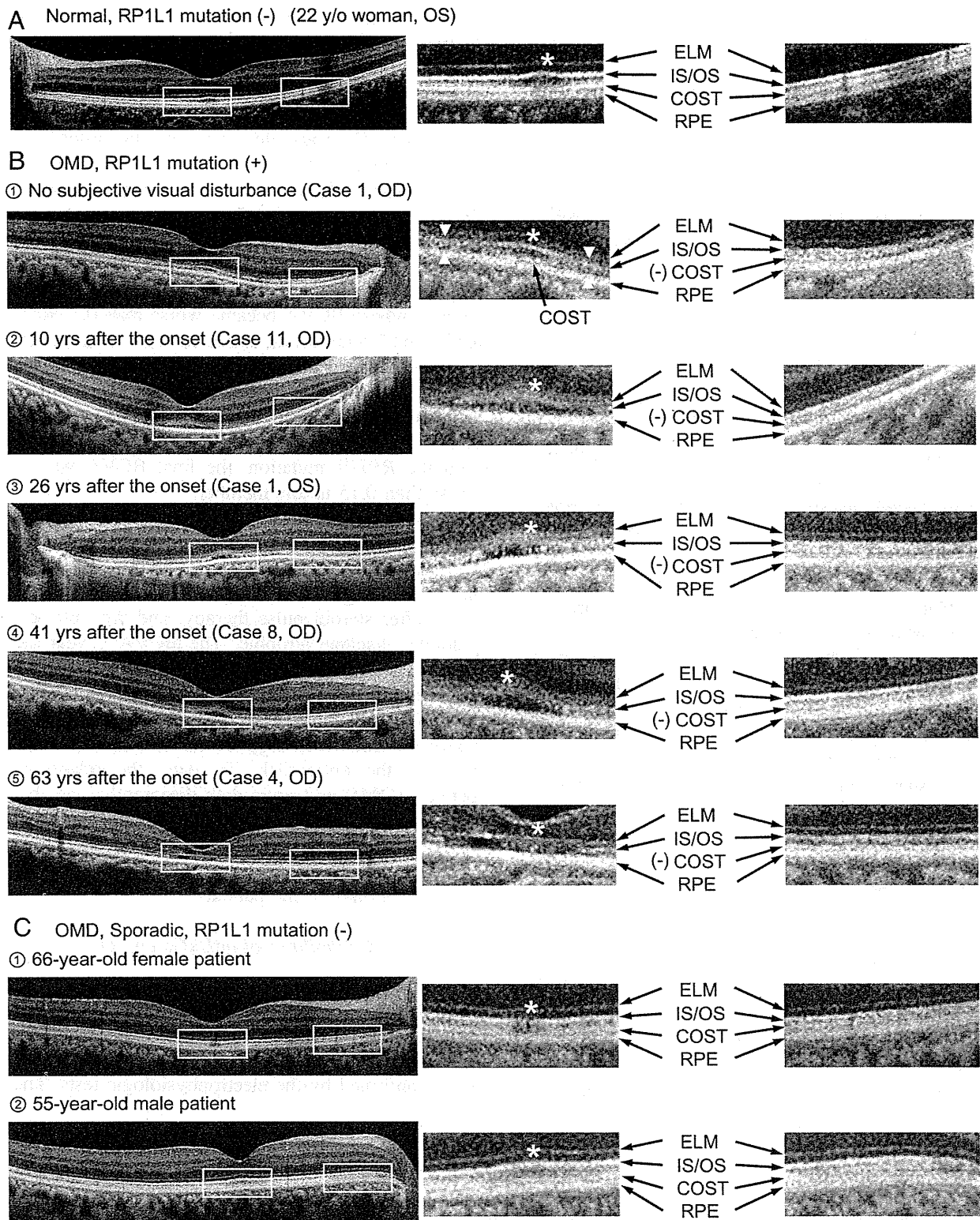


Fig. 3. Optical coherence tomography images horizontally profiled along the foveola (left) and magnified images in the fovea and the perimacular region (right). Outer retinal structures, such as external limiting membrane (ELM), photoreceptor IS/OS line, COST line, and RPE, are indicated by arrows. The foveal center is indicated by an asterisk. All the OCT images were taken with the HD-OCT (Carl Zeiss). **A.** Optical coherence tomography image of a normal control without the *RP1L1* mutation (22-year-old woman). All the outer retinal structures, for example, external limiting membrane, IS/OS line, COST line, and RPE, are clearly observed both in the fovea and the perimacular region. **B.** Optical coherence tomography images of patients affected by OMD with the *RP1L1* mutation. ①. Optical coherence tomography image of the right eye of Case 1, which did not have subjective visual disturbances. The COST line is present in the foveal center (black arrow), but not in the parafoveal region (arrowheads). The IS/OS line is clearly

eye of Cases 1 to Case 13), whereas the fovea of all the affected eyes with durations ≥ 20 years were classified as thin (Case 7 to Case 4).

To determine whether a significant correlation existed between the results of mfERGs and OCT, the relative amplitudes of the mfERGs at the fovea (Ring 1/Ring 5 or 6) are listed in Table 3. In cases where the disease durations was ≥ 3 years, the relative amplitude at the fovea was approximately 1.0 or nonrecordable because the responses of the central locus were extinguished. Only cases with very short durations had mildly reduced mfERGs in the fovea (2.34 in the right eye of Case 1 and 1.63 in the right eye of Case 14).

Discussion

Course of OMD Patients with *RP1L1* Mutation

Our results confirmed that all the patients with the *RP1L1* mutation had similar phenotypes; slowly progressive visual disturbances of both eyes, normal-appearing fundus, normal FA and full-field ERGs during the entire course of the disease, selective dysfunction at the macula detected by focal macular ERGs and mfERGs, selective abnormality of the photoreceptor layer in the macula revealed by OCT, and a final BCVA not poorer than 0.1. The age at the onset of OMD was, however, very variable among the family members and varied from 6 years to 50 years.

Our study also confirmed that there are patients with OMD who have normal visual acuity and no subjective visual disturbances until the disease progressed to a more advanced stage. Similar findings have been reported for other patients with OMD,^{1,2,24} although the etiology of these patients was not confirmed by genetic analyses. For such patients, the function of the small region in the foveola of these eyes has probably been spared so that the BCVA was normal. This was morphologically confirmed by the OCT; in the right eye of Case 1, the BCVA of which was 1.2, the OCT image showed that photoreceptor structures were spared only at the foveal center.

Among the 14 family members with the *RP1L1* mutation, only Case 5 (60-year-old woman) did not

show any signs of macular dysfunction in both subjective and objective tests. Thus, this woman may be a carrier of a mutated gene, but we cannot exclude the possibility that macular dysfunction may appear later. In our genetic study of 4 other OMD families, 2 brothers (58 and 55 years old) were not diagnosed with OMD, although both had the *RP1L1* mutation (p.Arg45Trp).¹² In all the OMD patients with the *RP1L1* mutation, the visual dysfunction was detected no later than 50 years of age.¹²

Occluded macular dystrophy has been reported to be a slowly progressive disease; however, there were no patients whose BCVA became worse than 0.1 except for Patient 7 who had an untreated senile cataract. Our results confirmed that once the BCVA is reduced to 0.1 to 0.2, the disease becomes stationary and both the subjective and objective visual functions do not deteriorate thereafter. Similarly, in 3 other families with the *RP1L1* mutation, the final BCVA was not worse than 0.15 in any member.¹²

There was 1 family member (asterisk, Figure 1) who had a sudden decrease of vision in the left eye at age 49 years, but she was diagnosed with retrobulbar neuritis at the Niigata University. Her vision did not recover after steroid pulse therapy, and the optic disk gradually became atrophic. The BCVA 1 year later was 1.2 in the right eye and 0.07 in the left eye. We concluded that the vision reduction was not related to the OMD. Nakamura et al²⁵ reported a case of OMD that had normal-tension glaucoma with abnormal cupping of the optic disk. To date, the relationship between OMD and optic disk diseases has not been determined. In our family, the optic disks of all the OMD patients appeared normal, and OCT did not show any thinning of the nerve fiber layer or ganglion cell layer in any of the patients.

Diagnostic Reliabilities of mfERGs and OCT

There were patients, such as Case 6 (both eyes), Case 1 (right eye), and Case 11 (left eye), with OMD from an *RP1L1* mutation who did not have any subjective visual disturbances and whose diagnosis were only confirmed by the electrophysiologic tests. These

Figure 3. (continued) observed at the foveal center (asterisk) but appears blurred in the parafoveal region (arrowheads). ②, ③, and ④. Optical coherence tomography image of the right eye of Case 11, the left eye of Case 1, and the right eye of Case 8, which show typical signs of OMD. The COST line is not present over the entire macula but is present in the perimacular regions. The IS/OS line is blurred and thick in the fovea. ⑤. Optical coherence tomography image (vertical section) of the right eye of Case 4. This image was obtained 63 years after the onset of visual symptoms. The IS/OS line is disrupted at the fovea. The COST line cannot be seen in the macula but is still visible in the perimacular region. There is an apparent thinning of the photoreceptor layer at the fovea. C. Optical coherence tomography images of sporadic cases of OMD without the *RP1L1* mutation. ① and ②. Both patients had progressive central scotoma with normal-appearing fundus and normal FA. The full-field ERGs were normal but focal macular ERGs elicited by a 10° spot were not recordable. The IS/OS line could be clearly observed at the fovea in both cases, except in minute disruption at the foveola in ① (asterisk). The COST line could be observed at the fovea in both cases, although slightly more blurred than in the normal case.

Table 3. Optical Coherence Tomography Findings in 21 Eyes of 11 Family Members with RP1L1 Mutation in the Ord

Years After the Onset (Years)	Case	OD/OS	BCVA	Relative Amplitude in mfERG at fovea (Ring 1/Ring 5 or 6)	OCT Findings at Fovea			
					Disappearance of COST at fovea	Blurring of IS/OS Junction at Fovea	Abnormality of RPE	Thinning of Fovea (Thickness <160 μ m)
None	5	OD	1.2	4.24	-	-	-	-(217)
Unknown	1	OD	1.2	2.34	\pm^*	\pm^*	-	-(200)
2	14	OD	1.0	1.63	+	+	-	-(160)
3	11	OS	0.4	Not measurable	+	+	-	-(168)
6	12	OD	0.3	0.98	+	+	-	-(174)
		OS	0.3	1.03	+	+	-	-(168)
10	14	OS	0.6	0.66	+	+	-	-(160)
10	11	OD	0.1	Not measurable	+	+	-	-(164)
12	13	OD	0.2	Not measurable	+	+	-	-(181)
		OS	0.15	Not measurable	+	+	-	-(177)
20	7	OD	0.1	Not measurable	+	+	-	+(134)
		OS	0.07	Not measurable	+	+	-	+(142)
31	1	OS	0.1	0.60	+	+	-	+(150)
38	10	OD	0.1	Not measurable	+	+	-	+(150)
		OS	0.1	Not measurable	+	+	-	+(153)
41	8	OD	0.1	1.01	+	+	-	+(148)
		OS	0.1	1.30	+	+	-	+(148)
46	2	OD	0.4	Not measurable	+	+\uparrow	-	+(156)
		OS	0.5	Not measurable	+	+\uparrow	-	+(154)
63	4	OD	0.2	Not measurable	+	+\uparrow	-	+(77)
		OS	0.2	Not measurable	+	+\uparrow	-	+(76)

*The COST and IS/OS junction were normal only at the foveal center. In the parafovea, the COST could not be observed and the IS/OS junction was disrupted at the fovea.
 \uparrow The IS/OS junction was disrupted at the fovea.

findings indicate that mfERGs or focal macular ERGs are sensitive enough to detect very early macular dysfunction in OMD.

Similarly, OCT could be another sensitive tool for the detection of early OMD because an abnormality of the COST line and the IO/OS line in the macula was observed in all the affected cases. However, we believe that the mfERG is more sensitive than OCT in detecting early dysfunctions of the macula in eyes with OMD. For example, Case 14 was a 28-year-old man whose BCVA was 1.0 (right eye) and 0.6 (left eye), but his fundus and visual field tests did not show any differences between the 2 eyes. He did notice a visual disturbance in his left eye 8 years before the onset in his right eye. In the OCT images, both the COST line and the IS/OS line were similarly affected for both eyes at the fovea, and the retinal thickness at the fovea was 160 μm in both eyes (Table 3). The mfERGs, on the other hand, were different in the 2 eyes; the relative amplitude of mfERG at the fovea (Ring 1/Ring 5) was 1.63 (38.2/23.5) in his right eye and 0.66 (15.8/23.8) in his left eye (Table 3). Thus, we believe that both the mfERGs and OCT can be useful in the diagnosis of OMD, but mfERGs are more reliable in detecting and evaluating minimal macular dysfunction at the early stage of the disease. The abnormalities in the OCT, however, progress slowly and continuously until the late stage, and thus they may be more useful for following the long-term progression of OMD.

Roles of RPILI Gene and Occurrence of OMD

Our study confirmed that all the affected patients with *RPILI* mutation had abnormalities of the photoreceptor structures; the IS/OS line was very blurred and thick and the COST line could not be observed in the macula (Figure 2). But in the perimacular region, which had normal visual function, all the outer retinal structures were seen to be normal. During the whole disease process, neither the external limiting membrane nor the RPE had any significant changes and remained normal. In some of sporadic cases of the OMD, similar abnormalities in the OCT could not be observed, although localized macular dysfunction was confirmed electrophysiologically (Figure 3C).

The location of COST line coincided with the location where the outer segment disks are renewed in the cones.^{23,26} The disappearance of the COST line indicates an early stage of dysfunction of the cone photoreceptors as has been found in acute zonal occult outer retinopathy.¹¹ Recently, ultrahigh-resolution OCT with adaptive optics has revealed that the IS/OS line corresponds to the ellipsoids of the photoreceptor inner segments, which are rich in mitochondria and play important roles in cellular metabolism.²⁷

Immunohistochemistry for the *RPILI* gene in retinal section of cynomolgus monkeys showed that it was expressed in both the inner and outer segments of the rod and cone photoreceptors, although the exact site within the photoreceptor has not been confirmed.¹² *RPILI* is believed to play important roles in the morphogenesis of photoreceptors, and once the function of *RPILI* is disrupted by a mutation, both the electrophysiologic responses and structures of the photoreceptor can be altered. Cellular dysfunction because of an *RPILI* mutation affects either the inner or outer segment, or both, of the photoreceptors, which first becomes apparent as an abnormality of both the COST line and IS/OS line in the OCT images.

Considering that the OCT abnormalities in sporadic cases did not show similar pattern as patients with the *RPILI* mutation, the phenotypically confirmed OMD surely consists of diseases caused by several independent etiologies. In any case, the abnormalities in the mfERGs and OCT observed in OMD in this family strongly support the contribution of *RPILI* mutation to the presence of this disease.

There are still some important questions of the disease process in OMD that are unsolved. First, why is only the macular region affected while the perimacular region remains intact both functionally and morphologically even at a very advanced stage? Second, why do OMD patients have normal fundus appearance until the end stage, and why does the RPE remain intact until the end stage when the photoreceptor structures are markedly damaged (Figure 3B, ⑤)? Fujinami et al²⁸ demonstrated that the fundus autofluorescence images in the macula of OMD patients are normal, indicating that the RPE is normal. Third, why does the disease progression stop when the BCVA decreases to 0.1 to 0.2?

These characteristics in the disease process are peculiar to the OMD and not observed in other macular dystrophies. More detailed investigations on the function of *RPILI* should provide information to answer these questions.

We suggest that OMD is not a single disease caused by a specific gene mutation, *RPILI*, but may represent different disease entities with similar retinal dysfunctions. Considering all our findings on OMD, we can phenotypically define the OMD as a slowly progressing bilateral dysfunction of the photoreceptors located in the macula, not accompanied by either vascular or RPE damage. The etiology of OMD cases without the *RPILI* mutation is now under investigation with large number of cases and some of them might be found to be because of other autosomal recessive mutations.

Key words: electroretinography, focal macular ERG, multifocal ERG, occult macular dystrophy, optical coherence tomography, *RP1L1*.

References

- Miyake Y, Ichikawa K, Shiose Y, Kawase Y. Hereditary macular dystrophy without visible fundus abnormality. *Am J Ophthalmol* 1989;108:292–299.
- Miyake Y, Horiguchi M, Tomita N, et al. Occult macular dystrophy. *Am J Ophthalmol* 1996;122:644–653.
- Fujii S, Escano MF, Ishibashi K, et al. Multifocal electroretinography in patients with occult macular dystrophy. *Br J Ophthalmol* 1999;83:879–880.
- Piao CH, Kondo M, Tanikawa A, et al. Multifocal electroretinogram in occult macular dystrophy. *Invest Ophthalmol Vis Sci* 2000;41:513–517.
- Wildberger H, Niemeyer G, Junghardt A. Multifocal electroretinogram (mfERG) in a family with occult macular dystrophy (OMD). *Klin Monatsbl Augenheilkd* 2003;220:111–115.
- Kondo M, Ito Y, Ueno S, et al. Foveal thickness in occult macular dystrophy. *Am J Ophthalmol* 2003;135:725–728.
- Brockhurst RJ, Sandberg MA. Optical coherence tomography findings in occult macular dystrophy. *Am J Ophthalmol* 2007;143:516–518.
- Koizumi H, Maguire JJ, Spaide RF. Spectral domain optical coherence tomographic findings of occult macular dystrophy. *Ophthalmic Surg Lasers Imaging* 2009;40:174–176.
- Lubinski W, Goslawski W, Penkala K, et al. A 43-year-old man with reduced visual acuity and normal fundus: occult macular dystrophy—case report. *Doc Ophthalmol* 2008;116:111–118.
- Park SJ, Woo SJ, Park KH, et al. Morphologic photoreceptor abnormality in occult macular dystrophy on spectral-domain optical coherence tomography. *Invest Ophthalmol Vis Sci* 2010;51:3673–3679.
- Tsunoda K, Fujinami K, Miyake Y. Selective abnormality of cone outer segment tip line in acute zonal occult outer retinopathy as observed by Spectral domain optical coherence tomography. *Arch Ophthalmol* 2011;129:1099–1101.
- Akahori M, Tsunoda K, Miyake Y, et al. Dominant mutations in *RP1L1* are responsible for occult macular dystrophy. *Am J Hum Genet* 2010;87:424–429.
- Conte I, Lestingi M, den Hollander A, et al. Identification and characterisation of the retinitis pigmentosa 1-like1 gene (*RP1L1*): a novel candidate for retinal degenerations. *Eur J Hum Genet* 2003;11:155–162.
- Bowne SJ, Daiger SP, Malone KA, et al. Characterization of *RP1L1*, a highly polymorphic paralog of the retinitis pigmentosa 1 (*RP1*) gene. *Mol Vis* 2003;9:129–137.
- Pierce EA, Quinn T, Meehan T, et al. Mutations in a gene encoding a new oxygen-regulated photoreceptor protein cause dominant retinitis pigmentosa. *Nat Genet* 1999;22:248–254.
- Sullivan LS, Heckenlively JR, Bowne SJ, et al. Mutations in a novel retina-specific gene cause autosomal dominant retinitis pigmentosa. *Nat Genet* 1999;22:255–259.
- Jacobson SG, Cideciyan AV, Iannaccone A, et al. Disease expression of *RP1* mutations causing autosomal dominant retinitis pigmentosa. *Invest Ophthalmol Vis Sci* 2000;41:1898–1908.
- Yamashita T, Liu J, Gao J, et al. Essential and synergistic roles of *RP1* and *RP1L1* in rod photoreceptor axoneme and retinitis pigmentosa. *J Neurosci* 2009;29:9748–9760.
- Lyons JS. Non-familial occult macular dystrophy. *Doc Ophthalmol* 2005;111:49–56.
- Marmor MF, Fulton AB, Holder GE, et al. ISCEV Standard for full-field clinical electroretinography (2008 update). *Documenta Ophthalmologica* 2009;118:69–77.
- Hood DC, Bach M, Brigell M, et al. ISCEV guidelines for clinical multifocal electroretinography (2007 edition). *Documenta Ophthalmologica* 2008;116:1–11.
- Usui T, Tanimoto N, Ueki S, et al. ERG rod a-wave in Oguchi disease. *Vision Research* 2004;44:535–540.
- Srinivasan VJ, Monson BK, Wojtkowski M, et al. Characterization of outer retinal morphology with high-speed, ultra-high-resolution optical coherence tomography. *Invest Ophthalmol Vis Sci* 2008;49:1571–1579.
- Miyake Y. *Electrodiagnosis of Retinal Diseases*. Tokyo, Japan: Springer-Verlag; 2006.
- Nakamura M, Kanamori A, Seya R, et al. A case of occult macular dystrophy accompanying normal-tension glaucoma. *Am J Ophthalmol* 2003;135:715–717.
- Anderson DH, Fisher SK, Steinberg RH. Mammalian cones—disk shedding, phagocytosis, and renewal. *Invest Ophthalmol Vis Sci* 1978;17:117–133.
- Fernandez EJ, Hermann B, Povazay B, et al. Ultrahigh resolution optical coherence tomography and pancorrection for cellular imaging of the living human retina. *Opt Express* 2008;16:11083–11094.
- Fujinami K, Tsunoda K, Hanazono G, et al. Fundus autofluorescence in autosomal dominant occult macular dystrophy. *Arch Ophthalmol* 2011;129:579–602.

