

of resected polyps increases (11–15), but there have been no previously published reports that describe the risk factors for delayed bleeding specifically with respect to large colorectal tumors. The aim of the present study was to evaluate and clarify the risk factors for delayed bleeding after ER for colorectal tumors ≥ 20 mm in diameter.

PATIENTS AND METHODS

PATIENTS

ER procedures (PO, *en bloc* EMR and EPMR) were performed on 403 colorectal tumors ≥ 20 mm in diameter in 375 consecutive patients at the National Cancer Center Hospital in Tokyo from January 2003 to December 2006. Patients with inflammatory bowel diseases, thrombocytopenia and non-epithelial neoplasms were excluded from this study as were patients who received an endoscopic submucosal dissection (ESD) because electrocoagulations were usually performed on all visible vessels after the ESD procedure and the rate of delayed bleeding in ESD cases is very low (2%) according to a published report on colorectal ESDs performed in our hospital (16).

We analyzed a prospectively completed database and reviewed patient medical records pertaining to these large colorectal tumors and retrospectively assessed patient age, gender, hypertension and current use of anticoagulant (warfarin) or antiplatelet drugs (e.g. aspirin, ticlopidine) as well as tumor location, size, macroscopic type, histopathological findings, resection method and whether or not placement of prophylactic clips was performed during the ER in an effort to determine the risk factors for delayed bleeding. Delayed bleeding was defined as clinical evidence of bleeding manifested by melena or hematochezia from 0 to 14 days after the procedure that required endoscopic hemostasis. Written informed consent was obtained from all patients before ER in accordance with the Declaration of Helsinki.

INDICATIONS FOR ENDOSCOPIC RESECTION

After observation of a lesion was conducted by conventional endoscopic examination, 0.4% indigo-carmin dye was sprayed over the lesion to enhance its surface detail. High-magnification observation (PCF-240ZI or CF-H260AZI; Olympus Optical Co., Ltd, Tokyo, Japan) with 0.05% crystal-violet stain was then used whenever necessary to evaluate the surface character for pit patterns to differentiate an invasive pattern from a non-invasive pattern. An invasive pattern is characterized by irregular and distorted epithelial crypts observed in a demarcated area, suggesting that submucosal (s.m.) invasion is >1000 μm (17–20). Existence of a non-invasive pattern determined by chromomagnification colonoscopy was the minimum requirement for all ER candidates.

ENDOSCOPIC PROCEDURES

When anticoagulant and/or antiplatelet drugs were prescribed for non-critical problems, patients were instructed to discontinue the use of such drugs beginning 7 days before their ERs. All ER procedures were performed using an Olympus PCF-Q240ZI or CF-H260AZI video endoscope. PO was performed by snaring without s.m. injection, while the inject and cut technique described in previous reports was used for both EMR and EPMR procedures (1–3,6,8). EPMR was distinguished from EMR whenever a lesion was resected in more than two pieces.

The lesion was first elevated by injecting glycerol into the s.m. layer using a standard 23 G injection needle (Olympus). Glycerol was used as the s.m. injection solution because as we previously reported, a 10% glycerol solution is superior to normal saline for colorectal EMR (21). The lifted lesion was then resected with a round or oval snare in 120 W endocut (effect 3) and 50 W forced coagulation mode (effect 3) using a high-frequency electrical generator (ICC200; ERBE Elektromedizin GmbH, Tübingen, Germany). For purposes of this study, the method of resection was categorized as being either an *en bloc* (PO or EMR) or a piecemeal (EPMR) resection. All resected materials were retrieved for histopathological examination. We subsequently advised all ER patients to refrain from alcohol consumption and heavy exercise for 1 week and to call our hospital immediately if they had any bloody feces.

PROPHYLACTIC CLIP PLACEMENT

We leave the decision on whether clipping is necessary or not after ER to the doctors. When the following situations are a concern, the doctors determine that clipping is necessary: an acute bleeding occurs when a lesion is resected, and blood vessels are suspected to be exposed on the mucosal defect; as tissue coagulation is not sufficient when a lesion is resected, blood vessels are not sufficiently coagulated; a mucosal defect is deep, the muscle layers and serosa are exposed and there is a risk of perforation. Such technique was used solely for the purpose of stopping acute bleeding and not to prevent tumor implantation in those cases in which a lesion was resected in more than five pieces. Approximation of the mucosa at the edge of the post-ER ulcer was performed using hemoclips (HX-600 or HX-610 series; Olympus or Resolution Clip Device; Boston Scientific, Natick, MA, USA) (Fig. 1A–C). When complete closure of a large mucosal defect proved difficult using just hemoclips, clipping of only exposed vessels or complete closure using the endoloop/metallic clip method was performed with a double-channel colonoscope (22).

TUMOR-RELATED FACTORS

The size of each polyp was measured in relation to an open standard PO snare and the macroscopic type was categorized

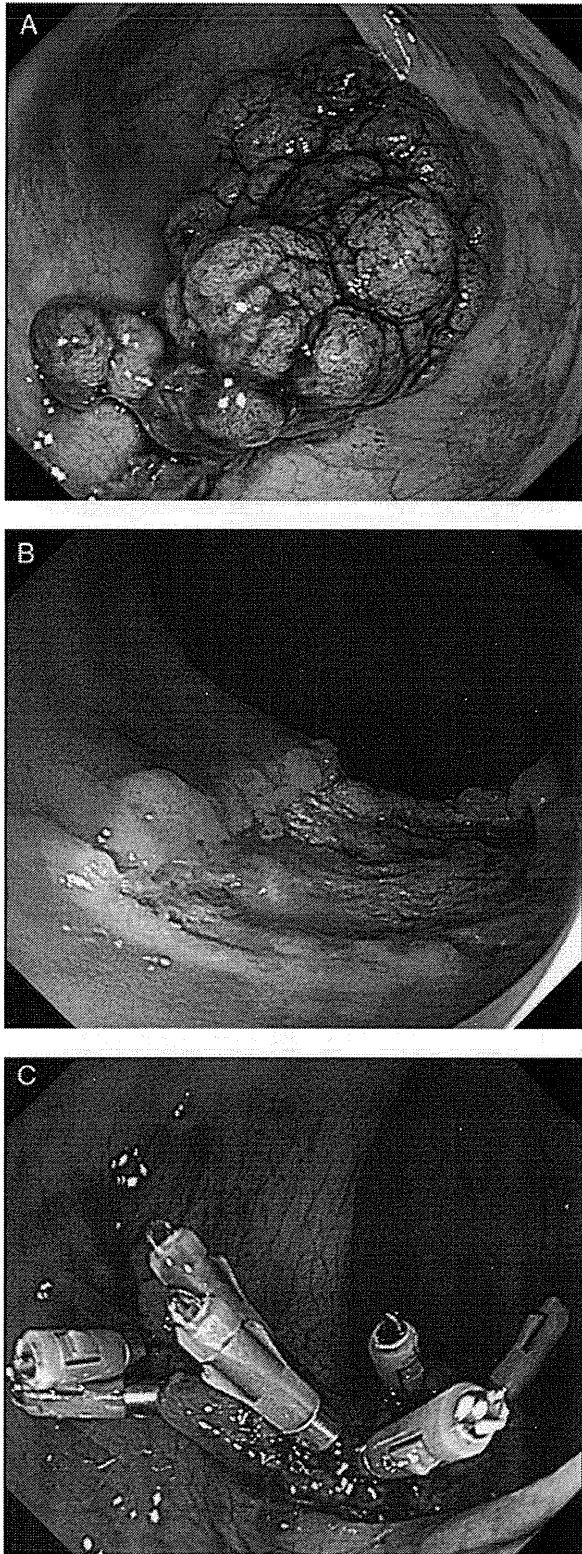


Figure 1. (A) Chromoendoscopic view after indigo-carmin dye spraying showing 50 mm, uneven polypoid lesion (Ip) in the rectum. (B) Endoscopic view after endoscopic mucosal resection showing mucosal defect without any residual tumor. (C) Mucosa at the edge of mucosal defect was approximated using hemoclips thus preventing delayed bleeding.

as being either sessile or other (flat, depressed or recurrent). All specimens were evaluated after being cut into 2 mm slices and examined histopathologically with diagnoses based on the Japanese classification of cancer of the colon and rectum (23) and the Vienna classification (24).

PATIENT-RELATED FACTORS

Patient information was based on a review of available medical records. Hypertension was defined as a patient either having systolic blood pressure of at least 140 mmHg or undergoing antihypertensive therapy. The current use of anticoagulant or antiplatelet drugs was defined as the use of such drugs within 7 days of ER. Only one patient using both anticoagulant and antiplatelet drugs was included in the anti-coagulant group.

STATISTICAL ANALYSIS

Data were reported as mean \pm standard deviation (SD) and median (range) for quantitative variables having normal and skewed distributions, respectively. In comparing baseline characteristics between the two groups of patients with and without delayed bleeding, we used a *t*-test for continuous variables and a Fisher exact test or χ^2 test for dichotomous variables. All statistical analyses were performed using SAS version 8.0 (SAS Institute Inc., Cary, NC, USA) and the *P* value was two-sided with <0.05 used to determine statistical significance.

RESULTS

CLINICOPATHOLOGICAL CHARACTERISTICS

A total of 403 colorectal tumors ≥ 20 mm in diameter were treated by ER in 375 consecutive patients. The mean patient age \pm SD was 63 ± 12 years (range, 22–92 years) and the mean lesion size was 27.1 ± 9.6 mm (range, 20–95 mm).

DELAYED BLEEDING

All delayed bleeding cases are summarized in Table 1. The total number of delayed bleeding cases amounted to 17 lesions (4.2%) in 17 patients (4.5%) and the median interval between ER and the onset of delayed bleeding was 2 days (range, 1–14 days). All delayed bleeding cases were successfully managed by endoscopic hemostasis involving clipping and/or electrocoagulation without the necessity of any surgical interventions or blood transfusions.

PATIENT-RELATED FACTORS AND DELAYED BLEEDING

A complete comparison of patients with and without delayed bleeding is summarized in Table 2. In terms of patient-related factors, our comparison of the incidence of delayed bleeding included the following results: gender (male/female), 6.3/

Table 1. Clinicopathological characteristics of delayed bleeding cases

No.	Age	Gender	Resection method	Prophylactic clip	Interval ^a (days)	Location	Lesion size (mm)	Macroscopic type	Histopathology
1	61	F	EMR	Used	1	Transverse	25	Other	Carcinoma
2	56	M	EMR	Not	7	Ascending	25	Other	Carcinoma
3	80	M	EPMR	Not	1	Rectum	20	Other	Adenoma
4	70	M	EPMR	Not	10	Sigmoid	30	Other	Adenoma
5	71	M	EPMR	Not	7	Sigmoid	60	Other	Carcinoma
6	79	M	EPMR	Not	1	Sigmoid	20	Other	Adenoma
7	74	M	EPMR	Not	1	Cecum	50	Sessile	Adenoma
8	68	M	EPMR	Not	2	Cecum	40	Other	Carcinoma
9	59	M	EPMR	Not	1	Transverse	25	Other	Carcinoma
10	65	M	EPMR	Not	3	Transverse	30	Other	Carcinoma
11	61	M	EPMR	Not	3	Ascending	35	Other	Carcinoma
12	65	M	EPMR	Not	5	Rectum	25	Other	Carcinoma
13	52	F	PO	Not	1	Ascending	50	Other	Carcinoma
14	49	M	PO	Used	14	Sigmoid	28	Sessile	Carcinoma
15	64	M	EMR	Used	2	Transverse	40	Sessile	Carcinoma
16	54	M	EPMR	Not	7	Descending	20	Sessile	Adenoma
17	45	M	EMR	Not	2	Rectum	20	Sessile	Carcinoma

^aBetween ER and the onset of delayed bleeding.

Table 2. Comparison of patients with and without delayed bleeding

	Total	Delayed bleeding		P value
		Yes	No	
Number of patients	375	17	358	
Age, years (mean ± SD)	63.3 ± 12.3	63.3 ± 10.0	63.3 ± 12.4	NS
Gender (male/female)	240/135	15/2	225/133	0.04
Hypertension (+/-)	83/292	6/11	77/281	NS
Current use of anticoagulant drugs (+/-)	6/369	1/16	5/353	NS
Current use of antiplatelet drugs (+/-)	10/365	0/17	10/348	NS

NS, not significant.

1.5% ($P = 0.04$); hypertension (+/-), 7.2/3.8% ($P = 0.18$); current use of anticoagulant (+/-), 16.7/4.3% ($P = 0.24$); and current use of antiplatelet (+/-), 0/4.9% ($P = 0.53$). There was no delayed bleeding in one patient using both anti-coagulant and antiplatelet drugs. There was virtually no difference between the two groups of patients with and without delayed bleeding in terms of mean age, but the delayed bleeding rate in males was significantly higher than in females.

TUMOR-RELATED FACTORS AND DELAYED BLEEDING

A complete comparison of lesions with and without delayed bleeding is summarized in Table 3. As for

tumor-related factors, our comparison of the incidence of delayed bleeding included the following results: tumor location (colon/rectum), 3.9/5.2% ($P = 0.81$); macroscopic type (sessile/other), 2.7/5.4% ($P = 0.59$); histopathological findings (adenoma/carcinoma), 3.8/4.4% ($P = 0.76$); resection method (*en bloc* resection/piece-meal resection), 3.1/5.3% ($P = 0.29$); and placement of prophylactic clips (used/not used), 1.7/6.1% ($P = 0.04$). There were no statistically significant differences between lesions with and without delayed bleeding except that the delayed bleeding rate was significantly higher in those cases without prophylactic clip placement.

Table 3. Comparison of lesions with and without delayed bleeding

	Total	Delayed bleeding		P value
		Yes	No	
Number of lesions	403	17	386	
Location (colon/rectum)	306/97	12/5	262/124	NS
Lesion size, mm (mean \pm SD)	27.1 \pm 9.6	31.9 \pm 12.2	26.8 \pm 9.5	NS
Macroscopic type (sessile/other ^a)	182/221	5/12	177/209	NS
Histopathology (adenoma/carcinoma)	132/271	5/12	127/259	NS
Resection method (<i>en bloc</i> /piecemeal)	194/209	6/11	188/198	NS
Prophylactic clip placement (used/not used)	174/229	3/14	171/215	0.04

NS, not significant.

^aFlat, depressed or recurrent.

DISCUSSION

In this study, the risk factors for delayed bleeding after ER were assessed in a group of patients specifically with large colorectal tumors which differed from previous reports. The delayed bleeding rate in male patients and those patients who did not receive prophylactic clip placement was significantly higher ($P = 0.04$).

A number of studies have attempted to identify the factors involved in the occurrence of delayed bleeding after ER, and various factors such as large size, sessile type, right-side location, hypertension and prior anticoagulation therapy have been proposed as being associated with an increased risk of delayed bleeding (15,25–31). This is the first large-scale study to assess these contributing factors in patients specifically with large colorectal tumors.

Delayed bleeding after ER is a clinically serious problem because it can lead to emergency endoscopic hemostasis, intensive patient care monitoring and/or the need for blood transfusions (12,15). Various studies have reported delayed bleeding in 0.3–6.1% of POs (12,15,28,32). In one recent investigation of 6617 POs by Watabe et al. (25), the rate of post-PO bleeding was 0.57%, but the mean size of polyps was only 5.6 mm. Our overall rate of delayed bleeding was higher undoubtedly because the mean size in this study was considerably larger at 27.1 \pm 9.6 mm. The results of other studies have also indicated that polyp size was an important risk factor for bleeding both during and after a procedure (15,25–27,33,34), although there was no significant difference between cases with and without delayed bleeding for tumors ≥ 20 mm according to the results of our study.

In terms of patient-related factors, the delayed bleeding rate was significantly higher in males than females ($P = 0.04$). We could not elucidate from their medical records a possible reason why there was a gender-based difference in patients with delayed bleeding, however, because there was no available evidence regarding any lifestyle differences between male and female patients with delayed bleeding. Watabe et al.

(25) concluded that hypertension was a significant risk factor for delayed bleeding, but there was no correlation between hypertension and delayed bleeding in our study. Neither could we find a correlation between the current use of anticoagulant and/or antiplatelet drugs and delayed bleeding.

In contrast, the delayed bleeding rate was significantly lower in the group of patients with prophylactic clip placement ($P = 0.04$). Application of hemostatic clips has been proven safe and effective for managing delayed bleeding following ER (35–37). Hachisu reported on 29 patients treated with prophylactic clipping following PO and delayed bleeding was not detected in any of them (38). A recent study indicated that prophylactic clip placement for the closure of mucosal defects in cases of gastric EMR reduced delayed bleeding (39), but it is still unclear whether or not such clip placement decreases the occurrence of delayed bleeding after ER for colorectal tumors. Although the study by Shioji et al. (12) indicated that clipping did not decrease the occurrence of delayed bleeding, we believe that their study population ($n = 413$) was too small to justify such a conclusion as 76.9% of the polyps were < 10 mm (mean size, 7.8 mm). As a result, the efficacy of prophylactic clip placement for the prevention of delayed bleeding in large colorectal tumors remains uncertain and should be determined by analyzing a high-risk group.

The study by Friedland and Soetikno (40) reported that there were no bleeding episodes after resection of 41 polyps up to 10 mm in size followed immediately by prophylactic application in 21 patients receiving the long-term anticoagulation drug warfarin. Although it was a small single-center retrospective study, their findings indicated that prophylactic clip placement in a high-risk group of patients on anticoagulation medication could be effective against delayed bleeding. Our study group also involved high-risk patients because of the large mean size of the resected tumors. Hemoclips were applied to cases of immediate bleeding in our study and we were unable to separate such cases from the prophylactic clip placement cases. Although cases with

immediate bleeding would logically be expected to have a higher risk of delayed bleeding, the rate of delayed bleeding in the entire group in which clipping was performed was significantly lower. This is the first study demonstrating the efficacy of prophylactic clipping in preventing delayed bleeding for colorectal tumors ≥ 20 mm.

The fact that this also was a single-center retrospective study like the earlier Friedland and Soetikno study is the most notable limitation. A second limitation is that we cannot exclude the possibility of inter-endoscopist bias as to whether or not prophylactic clip placement was performed in individual cases.

The other significant risk factor for delayed bleeding involved male patients in our study compared with female patients. Particularly, in male patients, the delayed bleeding rate in patients without prophylactic clip placement was significantly higher (8.9%) compared with patients with prophylactic clip placement (1.8%) ($P = 0.03$). As indicated above, a recommendation from this study might be that prophylactic clipping should be performed in male patients. In contrast, however, other previously published studies have reported different risk factors for delayed bleeding including sessile type, right-side location, patient hypertension and prior or long-term anticoagulation therapy. In the future, investigation may demonstrate the effectiveness of prophylactic clip placement for patients having such risk factors. We would also have to consider the relationship if any between delayed bleeding and different clipping techniques involving complete closure or exposed vessel clipping. Consequently, the effectiveness of prophylactic clip placement after ER for large colorectal tumors needs to be confirmed in a prospective randomized multicenter trial.

In conclusion, the results of this study indicated that prophylactic clip placement may be an effective method for preventing delayed bleeding after ER for large colorectal tumors.

Authors' Contributions

S.F. and Y.S. conceived study concept and design. S.F. co-wrote the paper and analyzed the data together with T.S. and T.N. and T.M. All authors contributed to endoscopic technical support and discussed the results and commented on the manuscript.

Acknowledgements

The authors wish to thank Christopher Dix for his assistance in editing this manuscript.

Conflict of interest statement

None declared.

References

- Ahmad NA, Kochman ML, Long WB, et al. Efficacy, safety, and clinical outcomes of endoscopic mucosal resection: a study of 101 cases. *Gastrointest Endosc* 2002;55:390–96.
- Yokota T, Sugihara K, Yoshida S. Endoscopic mucosal resection for colorectal neoplastic lesions. *Dis Colon Rectum* 1994;37:1108–11.
- Soetikno RM, Gotoda T, Nakanishi Y, et al. Endoscopic mucosal resection. *Gastrointest Endosc* 2003;57:567–79.
- Deyle P, Largiader F, Jenny S, et al. A method for endoscopic electrosection of sessile colonic polyp. *Endoscopy* 1973;5:38–40.
- Kudo S. Endoscopic mucosal resection of flat and depressed type of early colorectal cancer. *Endoscopy* 1993;25:455–61.
- Su MY, Hsu CM, Lin CJ, et al. Endoscopic treatment of colorectal neoplasms: a simple and safe procedure to lower the incidence of colorectal cancers. *Dig Dis Sci* 2008;53:1297–302.
- Saito Y, Fujii T, Kondo H, et al. Endoscopic treatment for laterally spreading tumors in the colon. *Endoscopy* 2001;33:682–86.
- Tanaka S, Haruma K, Oka S, et al. Clinicopathologic features and endoscopic treatment of superficially spreading colorectal neoplasms larger than 20 mm. *Gastrointest Endosc* 2001;54:62–6.
- Kudo S, Kashida H, Tamura T, et al. Colonoscopic diagnosis and management of nonpolypoid early colorectal cancer. *World J Surg* 2000;24:1081–90.
- Uraoka T, Saito Y, Matsuda T, et al. Endoscopic indications for endoscopic mucosal resection of laterally spreading tumors in the colorectum. *Gut* 2006;55:1592–7.
- American Society for Gastrointestinal Endoscopy. Complications of colonoscopy. *Gastrointest Endosc* 2003;57:441–5.
- Shioji K, Suzuki Y, Kobayashi M, et al. Prophylactic clip application does not decrease delayed bleeding after colonoscopic polypectomy. *Gastrointest Endosc* 2003;57:691–4.
- Heldwein W, Dollhopf M, Rösch T, et al. The Munich Polypectomy Study (MUPS): prospective analysis of complications and risk factors in 4000 colonic snare polypectomies. *Endoscopy* 2005;37:1116–22.
- Taku K, Sano Y, Fu KI, et al. Iatrogenic perforation at therapeutic colonoscopy: should the endoscopist attempt closure using endoclips or transfer immediately to surgery. *Endoscopy* 2006;38:428.
- Sawhney MS, Salfiti N, Nelson DB, et al. Risk factors for severe delayed postpolypectomy bleeding. *Endoscopy* 2008;40:115–9.
- Saito Y, Uraoka T, Matsuda T, et al. Endoscopic treatment of large superficial colorectal tumors: a case series of 200 endoscopic submucosal dissections (with video). *Gastrointest Endosc* 2007;65:537–42.
- Fujii T, Hasegawa RT, Saitoh Y, et al. Chromoscopy during colonoscopy. *Endoscopy* 2001;33:1036–41.
- Fu KI, Sano Y, Kato S, et al. Chromoendoscopy using indigo carmine dye spraying with magnifying observation is the most reliable method for differential diagnosis between non-neoplastic and neoplastic colorectal lesions: a prospective study. *Endoscopy* 2004;36:1089–93.
- Saito Y, Emura F, Matsuda T, et al. Invasive pattern is an indication for surgical treatment. *Gut* 2004. <http://gut.bmjournals.com/cgi/eletters/53/2/284>.
- Matsuda T, Fujii T, Saito Y, et al. Efficacy of the invasive/non-invasive pattern by magnifying chromoendoscopy to estimate the depth of invasion of early colorectal neoplasms. *Am J Gastroenterol* 2008;103:2700–6.
- Uraoka T, Fujii T, Saito Y, et al. Effectiveness of glycerol as a submucosal injection for EMR. *Gastrointest Endosc* 2005;61:736–40.
- Matsuda T, Fujii T, Emura F, et al. Complete closure of a large defect after EMR of a lateral spreading colorectal tumor when using a two-channel colonoscope. *Gastrointest Endosc* 2004;60:836–9.
- Japanese Society for Cancer of the Colon and Rectum. *Japanese Classification of Colorectal Carcinoma*. Tokyo: Kanehawa 1997.
- Schlemper RJ, Riddell RH, Kato Y, et al. The Vienna classification of gastrointestinal epithelial neoplasia. *Gut* 2000;47:251–5.
- Watabe H, Yamaji Y, Okamoto M, et al. Risk assessment for delayed hemorrhagic complication of colonic polypectomy: polyp-related factors and patient-related factors. *Gastrointest Endosc* 2006;64:73–8.
- Sorbi D, Norton I, Conio M, et al. Postpolypectomy lower GI bleeding: Descriptive analysis. *Gastrointest Endosc* 2000;51:690–6.
- Dafnis G, Ekblom A, Pahlman L, et al. Complications of diagnostic and therapeutic colonoscopy within a defined population in Sweden. *Gastrointest Endosc* 2001;54:302–9.

28. Hui AJ, Wong RM, Ching JY, et al. Risk of colonoscopic polypectomy bleeding with anticoagulants and antiplatelet agents: analysis of 1657 cases. *Gastrointest Endosc* 2004;59:44–8.
29. Rosen L, Bub DS, Reed JF, 3rd, et al. Hemorrhage following colonoscopic polypectomy. *Dis Colon Rectum* 1993;36:1126–31.
30. Gibbs DH, Opelka FG, Beck DE, et al. Postpolypectomy colonic hemorrhage. *Dis Colon Rectum* 1996;39:806–10.
31. Rex DK, Lewis BS, Waye JD. Colonoscopy and endoscopic therapy for delayed post-polypectomy hemorrhage. *Gastrointest Endosc* 1992;38:127.
32. Stergiou N, Riphaut A, Lange P, et al. Endoscopic snare resection of large colonic polyps: how far can we go? *Int J Colorectal Dis* 2003;18:131–5.
33. Macrae FA, Tan KG, Williams CB. Towards safer colonoscopy: a report on the complications of 5000 diagnostic or therapeutic colonoscopies. *Gut* 1983;24:376–83.
34. Consolo P, Luigiano C, Strangio G, et al. Efficacy, risk factors and complications of endoscopic polypectomy: ten year experience at a single center. *World J Gastroenterol* 2008;14:2364–9.
35. Parra-Blanco A, Kaminaga N, Kojima T, et al. Hemoclipping for postpolypectomy and postbiopsy colonic bleeding. *Gastrointest Endosc* 2000;51:37–41.
36. Binmoeller KF, Thonke F, Soehendra N. Endoscopic hemoclip treatment for gastrointestinal bleeding. *Endoscopy* 1993;25:167–70.
37. American Society for Gastrointestinal Endoscopy. Technology status evaluation report. Endoscopic clip application devices. *Gastrointest Endosc* 2006;63:746–50.
38. Hachisu T. Evaluation of endoscopic hemostasis using an improved clipping apparatus. *Surg Endosc* 1988;2:13–7.
39. Choi KD, Jung HY, Lee GH, et al. Application of metal hemoclips for closure of endoscopic mucosal resection-induced ulcers of the stomach to prevent delayed bleeding. *Surg Endosc* 2008;22:1882–6.
40. Friedland S, Soetikno R. Colonoscopy with polypectomy in anticoagulated patients. *Gastrointest Endosc* 2006;64:98–100.

Safety and efficacy of colorectal endoscopic submucosal dissection in elders: clinical and follow-up outcomes

Naoto Tamai · Yutaka Saito · Taku Sakamoto ·
Takeshi Nakajima · Takahisa Matsuda · Hisao Tajiri

Accepted: 25 May 2012 / Published online: 7 June 2012
© Springer-Verlag 2012

Abstract

Purpose Endoscopic submucosal dissection (ESD) has recently been applied to treatment of colorectal neoplasia; however, its safety and efficacy in terms of follow-up outcomes in elders have not been thoroughly examined. The aim of this study is to describe the clinical outcomes of colorectal ESD in elderly patients.

Methods Two groups of patients, elderly (≥ 75 years of age) and non-elderly (< 75 years of age), who underwent colorectal ESD at the National Cancer Center Hospital from February 1998 to December 2010 were retrospectively compared on the following measures: tumor size, procedure time, complication rates, en bloc resection rates, and curative resection rates. We also investigated the follow-up outcomes in non-curative resection cases.

Results Of 614 consecutive patients treated by colorectal ESD, 125 (20.4 %) comprised the elderly group, and 489 patients (79.6 %) comprised the non-elderly group. No significant differences were observed between the two groups in terms of tumor size, procedure time, complication rates, en bloc resection rates, and curative resection rates. Of the patients who underwent non-curative resection, 7/19

(36.8 %) and 47/63 (74.6 %) in the elderly and non-elderly group, respectively, underwent additional treatment. Among the elderly patients who were followed up without additional treatment, no case of local recurrence, residual lesions, or distant metastases was observed during the observation period. **Conclusion** Treatment outcomes of colorectal ESD were equivalent in both groups. However, many of the non-curative cases in the elderly patients were followed up without additional treatment. Future studies should focus on the outcome in such patients to confirm the feasibility of colorectal ESD in elderly patients.

Keywords Endoscopic submucosal dissection (ESD) · Colorectal neoplasia · Elderly patients · Colon · Rectum · Laterally spreading tumor (LST)

Introduction

Colorectal carcinoma is one of the most common cancers worldwide, and its prevalence is steadily increasing in Japan [1]. The increased life expectancy of elderly patients has created a demand for minimally invasive treatments for colorectal cancer in elderly patients [2, 3]. Endoscopic submucosal dissection (ESD), initially developed for early gastric cancer, enables the resection of large superficial tumors en bloc [4, 5]. The advantage of ESD over conventional endoscopic mucosal resection (EMR) is its ability to remove tumors en bloc, regardless of tumor size. Although recent studies have described the effective use of ESD for the treatment of superficial colorectal neoplasia, technical difficulties owing to its thinner wall, tortuous structure, and higher perforation rate in comparison with conventional EMR have been indicated [6–12], and reports on the safety of colorectal ESD in elderly patients are still

N. Tamai (✉) · Y. Saito · T. Sakamoto · T. Nakajima · T. Matsuda
Endoscopy Division, National Cancer Center Hospital,
5-1-1 Tsukiji, Chuo-ku,
Tokyo 104-0045, Japan
e-mail: tamai-naoto@jikei.ac.jp

N. Tamai · H. Tajiri
Department of Endoscopy,
The Jikei University School of Medicine,
Tokyo, Japan

H. Tajiri
Division of Gastroenterology and Hepatology, Department of
Internal Medicine, The Jikei University School of Medicine,
Tokyo, Japan

limited [13]. In addition, the effectiveness of colorectal ESD, especially follow-up outcomes in elderly patients with non-curative resection, has not been thoroughly examined. Performing additional treatments in elderly patients who have undergone non-curative resection is sometimes difficult due to their general condition. Therefore, the aim of this study is to describe the short-term and follow-up outcomes of non-curative colorectal ESD in elderly patients.

Materials and methods

A total of 614 consecutive patients with 635 colorectal lesions treated by ESD at the National Cancer Center Hospital from February 1998 to August 2010 were retrospectively reviewed. Written informed consent to participate was obtained from all patients who underwent colorectal ESD. We divided them into two groups: an elderly group consisting of patients ≥ 75 years of age and a non-elderly group consisting of patients < 75 years of age. We compared the tumor size (measured by the pathologist after formalin fixation), procedure time, complication rate (perforation and delayed bleeding), en bloc resection rate, and curative resection rate between these two groups. We also investigated the follow-up outcomes of non-curative resection cases.

Inclusion criteria for ESD

For inclusion, the depth of invasion was limited to the mucosa or submucosal superficial (less than 1,000 μm from the muscularis mucosa) as estimated endoscopically as well as by magnification chromoendoscopy. The existence of a non-invasive pattern as determined by magnification chromoendoscopy was helpful in the diagnosis of tumor depth of invasion [14]. Based on extensive clinicopathological analyses, we defined the indications for colorectal ESD as nongranular type laterally spreading tumors (LSTs) larger than 20 mm and granular type LSTs larger than 30 mm because both have a higher submucosal invasion rate and are difficult to treat even by piecemeal EMR [15]. Patients with large villous tumors as well as intramucosal lesions, recurrent lesions, and residual mucosal lesions that showed a non-lifting sign after EMR were also potential candidates for ESD.

Exclusion criteria for ESD

Exclusion criteria included the existence of an invasive pattern [14], as determined by magnification chromoendoscopy, and other invasive cancers and circumferential tumors treated by surgery.

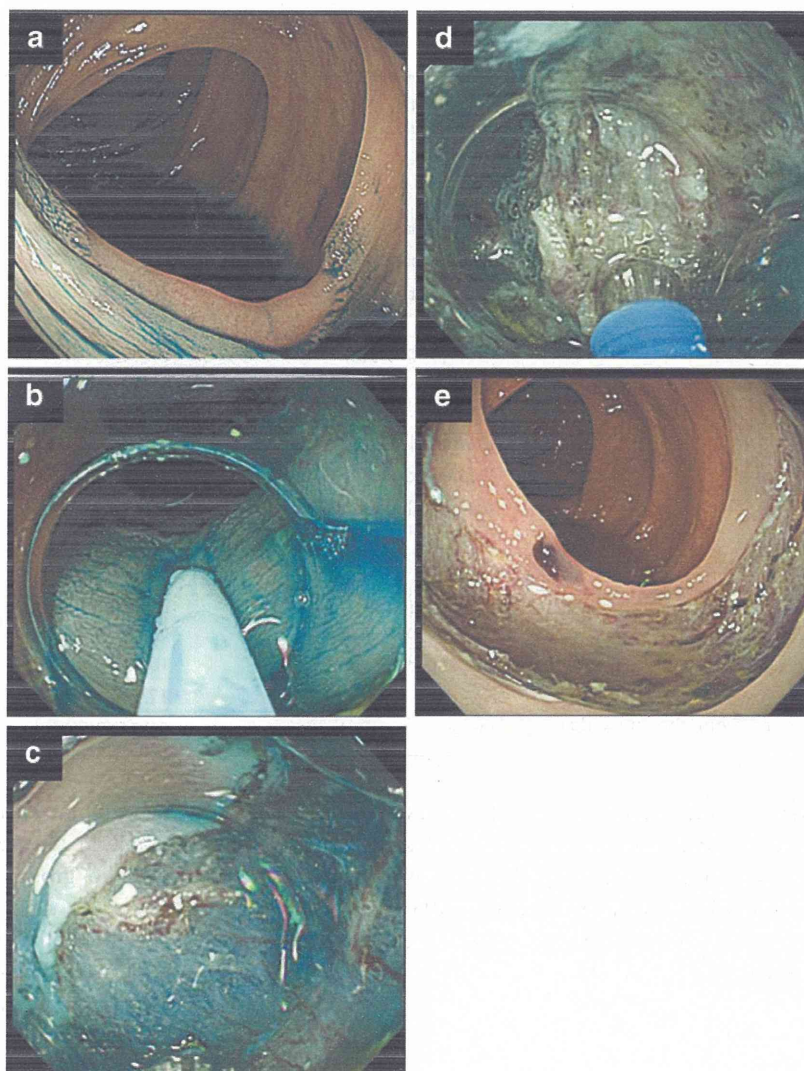
ESD methods

All patients underwent total bowel irrigation with 2–3 L of polyethylene glycol solution the morning of the procedure. Additional polyethylene glycol was administered as necessary. ESD was generally carried out using a single-channel colonoscope with a water-jet system (PCFQ260JI, Olympus Medical Systems, Tokyo, Japan). The margins of the lesions were delineated before ESD using 0.4 % indigo carmine spray dye. For submucosal injection, a mixture of two solutions was prepared before the procedure to create a longer-lasting submucosal fluid cushion. Solution 1 was indigo carmine dye (2 mL of 1 %) and epinephrine (1 mL of 0.1 %) mixed with 200 mL of 10 % glycerol and 5 % fructose in normal saline solution (glycerol; Chugai Pharmaceutical Co, Tokyo, Japan) in a container with the resulting solution. Solution 2 was sodium hyaluronate acid (Mucoup; Johnson & Johnson, Tokyo, Japan) with a smaller amount of indigo carmine dye and epinephrine. During ESD, a small amount of solution 1 was injected into the submucosal layer first to confirm the appropriate submucosal layer elevation. Solution 2 was then injected into the properly elevated submucosal layer, after which a partial marginal incision was performed with a bipolar needle knife (B-knife; Xeon Medical Co, Tokyo, Japan) from the oral side using the endoscope's retroflex position. Using the B-knife reduced the risk of perforation because of its bipolar current electric system. Following the partial marginal incision, a partial submucosal dissection was made using the B-knife. Once again, the solution was injected into the submucosal layer to lift up both the lesion and the submucosal layer from the muscle layer for a safe colorectal ESD. A series of partial marginal incisions followed by partial submucosal dissection was then performed until the lesion was resected completely. An insulation-tipped knife (Olympus Co, Tokyo, Japan) was used after the lesion had rolled up, and the submucosal layer could be directly visualized for safer and faster dissection. We also used a distal attachment that enables fine visualization of the submucosal layer and allows for counter-traction of the submucosal tissue (Fig. 1). The electrosurgical unit used was the ICC 200 (Erbe Elektromedizin, Tübingen, Germany). Intravenous midazolam (2 mg) and pentazocine (15 mg) were administered during all ESD procedures. An additional 2 mg of midazolam was administered whenever indicated based on the judgment of the colonoscopist. Hemo Stat-Y (Pentax, Tokyo, Japan) was used for hemostasis. Carbon dioxide insufflation was used instead of air insufflation to reduce patient discomfort.

Histological assessment

All specimens were fixed in 10 % buffered formalin and cut into 2-mm slices. Specimens were then examined

Fig. 1 **a** Nongranular type LST (40 mm in size) located in the ascending colon. **b** Injection of glycerol solution (10 % glycerol and 5 % fructose in normal saline solution) and sodium hyaluronate acid solution into SM layer. **c** Blue-colored submucosal layer clearly visualized using indigo carmine dye and distal attachment for counter-traction. **d** Submucosal dissection using a bipolar needle knife after partial circumferential incision. **e** Ulcer bed after successful en bloc resection



microscopically for depth of invasion, and their histological types and lateral and vertical resection margins were determined. A resection was considered tumor-free when both the lateral and vertical margins of the specimen were negative for tumor cells, irrespective of the histological features of the tumor. A resection was considered to be curative when the following criteria were met: the lateral and vertical margins of the specimen were free of cancer; submucosal invasion was less than 1,000 μm from the muscularis mucosae; and no lymphatic invasion, vascular involvement, or poorly differentiated components were detected. Histological diagnoses were based on the Japanese classification system for cancer of the colon and rectum and the Vienna classification system.

Follow-up

Endoscopic examinations were conducted for individuals with non-curative resections, who were followed up without

additional treatment. Piecemeal resection cases were scheduled at 6 months after ESD, and en bloc resection cases were scheduled at 12 months after ESD [16]. After the first endoscopic examination, annual follow-up endoscopic examinations were scheduled. Contrast-enhanced computed tomography (CT) was also performed annually for patients with non-curative resections, who were followed up without additional treatment. The following information was retrospectively collected from medical records: date of the most recent endoscopy; date of the most recent CT scan; and the presence of residual tumors, local recurrence, or distant metastasis.

Statistical analysis

All variables in this study are described as mean \pm standard deviation (SD). For comparing baseline characteristics between the two groups, we used a *t* test for continuous

Table 1 Patient and tumor characteristics

	Elderly patients	Non-elderly patients	<i>p</i> value
Patients (<i>n</i>)	125 (20.4 %)	489 (79.6 %)	<0.0001
Lesions (<i>n</i>)	134	501	
Age (years), mean±SD	78.3±3.0	61.8±8.6	
Sex ratio			
Male/female	71:54	287:202	0.71
Tumor location			
Cecum or colon	104/134 (77.6 %)	363/501 (72.5 %)	0.21
Rectum	30/134 (22.4 %)	138/501 (27.5 %)	
Macroscopic type			
LST-NG	53/134 (39.6 %)	187/501 (37.3 %)	0.82
LST-G	59/134 (44 %)	238/501 (47.5 %)	
Protruded	7/134 (5.2 %)	31/501 (6.2 %)	
Depressed	4/134 (3.0 %)	11/501 (2.2 %)	
Residual/local recurrence	11/134 (8.2 %)	30/501 (6.0 %)	
SMT	0/134 (0 %)	4/501 (0.8 %)	
Histology			
Adenoma	33/134 (24.6 %)	100/501 (20 %)	0.35
Intramucosal cancer ^a	69/134 (51.5 %)	283/501 (56.5 %)	
SM superficial cancer ^b	15/134 (11.2 %)	53/501 (10.6 %)	
SM deep cancer	17/134 (12.7 %)	54/501 (10.8 %)	
Others	0/134 (0 %)	10/501 (2.0 %)	

^aSubmucosal invasion less than 1,000 μm from the muscularis mucosae

^bSubmucosal invasion 1,000 μm or more from the muscularis mucosae

variables, a chi-square test and Fisher exact tests as appropriate for dichotomous variables. All statistical analyses were performed using SPSS for Windows (SPSS, Release 6.0; SPSS Inc., Chicago, IL, USA, 1993). The *p* values are two sided, and *p*<0.05 was used to determine statistical significance.

Results

A total of 614 consecutive patients with 635 colorectal lesions were treated by colorectal ESD. Of these patients, 125 (20.4 %) were in the elderly group and 489 (79.6 %) were in the non-elderly group. There were no significant differences between the two groups with respect to gender

ratio, tumor location, macroscopic tumor type, or histology (Table 1). No significant differences were observed between the two groups with respect to resected specimen size, procedure time, complication rate, en bloc resection rate, or non-curative resection rate (Table 2). Of the patients who underwent non-curative resection, 7/19 (36.8 %) in the elderly group and 47/63 (74.6 %) in the non-elderly group underwent additional treatment. Significantly fewer people in the elderly group underwent additional treatment. Among the 12 patients in the elderly group and the 16 in the non-elderly group who were followed up without surgery for a median of 46 and 27.5 months, respectively, there was no case of local recurrence, residual lesions, or distant metastasis observed during the study period. Among the seven elderly patients who underwent additional surgery

Table 2 Clinical outcomes of colorectal ESD

	Elderly patients	Non-elderly patients	<i>p</i> value
Tumor size			
Long axis (mm), mean±SD	35.2±17.4	36.3±18.5	0.54
Short axis (mm), mean±SD	30.9±15.6	29.5±15.4	0.34
Procedure time (min), mean±SD	104.7±77.0	102.7±72.2	0.79
Complication rate	3.7 % (5/134)	4.2 % (21/501)	0.19
Perforation rate	2.2 % (3/134)	2.6 % (13/501)	0.24
Postoperative bleeding rate	1.5 % (2/134)	1.6 % (7/501)	0.30
En bloc resection rate	93.3 % (125/134)	88.1 % (443/501)	0.085
Non-curative resection rate	14.2 % (19/134)	12.6 % (63/501)	0.62

Table 3 Outcomes of additional surgical treatment

	Elderly patients	Non-elderly patients
Additional surgical treatment [patients (<i>n</i>)/lesions (<i>n</i>)]	7/7	42/42
Residual lesions (%)	0/7 (0)	6/42 (14.3)
Lymph node metastases (%)	0/7 (0)	2/42 (4.8)
Distant metastases (%)	0/7 (0)	2/42 (4.8)

for non-curative lesions, no residual lesions or lymph node metastases were observed in the resected specimens. In contrast, of the 42 non-elderly patients who underwent additional surgery for non-curative lesions at the National Cancer Center Hospital, 6 (14.3 %) had residual tumors and 2 (4.8 %) had lymph node metastases in the resected specimens; distant metastases were confirmed in two patients (4.8 %; Table 3).

Discussion

The results of our study show that the short-term outcome of colorectal ESD in elderly patients was comparable to that in non-elderly patients, suggesting that

colorectal ESD is technically feasible in both groups of patients. In this study, many of the non-curative cases in elderly patients were followed up without additional treatment; the most common reason for which was request for the same by the patient and family (Table 4). The evaluation of risk as determined by histological assessment of resected specimens, mostly en bloc, might have influenced patient and family choice. In the non-curative cases followed up without additional treatment, local recurrences, residual lesions, or distant metastases were not observed in either group during the study period. Considering that the mortality rates for surgical treatment have been reported as 1.7–10.1 % in elderly patients [17–20], it seems acceptable to follow-up non-curative cases in the elderly group without additional treatment. Nevertheless, the follow-up periods are still limited. According to a previous report, the mean post-operative hospital stay for laparoscopic colorectal resection was 7.2 days [21], while that for colorectal ESD in the patients of this study was 4.0 days. The short hospitalization period is a significant advantage of ESD, not only cost-wise but also in terms of avoiding functional decline in elderly patients [22]. Of the elderly patients who underwent additional surgery, no residual lesions, lymph node metastases, or distant metastases were observed upon follow-up. However, of the non-elderly patients who

Table 4 Non-curative cases followed up without additional treatment in elderly patients

Case	Age (years)	Sex	Tumor location	Macroscopic type	Reasons for non-curative treatment	Reasons for follow-up without additional treatment	Follow-up duration (M)	Vital status
Case 1	78	M	Rectum	Is	pSM 7,000 μ m	Underlying disease (Parkinson's disease)	108	Living
Case 2	76	M	Rectum	Ila+Ilc (LST-NG)	pSM 3,700 μ m	Request of patient and family	7	Deceased (chronic heart failure)
Case 3	76	M	Ascending colon	Ila+Ilc (LST-NG)	pSM 3,000 μ m	Request of patient and family	57	Living
Case 4	75	F	Transverse colon	Ila+Ilc (LST-NG)	pSM 500 μ m poorly differentiated component	Request of patient and family	59	Living
Case 5	77	M	Sigmoid colon	Ila+Ilc (LST-NG)	pSM 1,000 μ m	Request of patient and family	76	Living
Case 6	75	F	Ascending colon	Ila+Ilc (LST-NG)	pSM 1,300 μ m	Request of patient and family	61	Living
Case 7	76	M	Rectum	Ila+Ilc (LST-NG)	pSM 2,300 μ m	Request of patient and family	60	Living
Case 8	75	F	Ascending colon	Is+Ila (LST-G)	pSM 2,000 μ m	Request of patient and family	59	Living
Case 9	79	M	Rectosigmoid colon	Ila+Ilc (LST-NG)	pSM 2,500 μ m	Underlying disease (leukemia)	12	Deceased (leukemia)
Case 10	81	M	Rectum	Ila (LST-NG)	pSM 1,750 μ m	Request of patient and family	42	Living
Case 11	77	M	Rectum	Is+Ila (LST-G)	pSM 6,000 μ m	Underlying disease (depression)	46	Living
Case 12	76	M	Cecum	Is+Ila (LST-G)	pSM 1,300 μ m	Request of patient and family	8	Living

underwent additional surgery, residual tumors were found in 14.3 %, lymph node metastases in 4.8 %, and distant metastases in 4.8 %. This discrepancy between elderly and non-elderly patients might indicate differences in the clinicopathological characteristics of colorectal cancer between young and elderly patients. Chou et al. reported that younger patients with colorectal cancer have more aggressive histopathological characteristics and poorer prognoses compared to older patients [18]. By collecting more data on the follow-up outcomes of non-curative cases, it may become possible to propose different strategies for elderly and non-elderly patients. In the current study, there was no significant difference between these two groups with respect to perforation rates, a finding discordant with other reports [23, 24]. All cases of perforation were successfully managed endoscopically, with no occurrence of panperitonitis in elderly patients. It can be assumed that mortality for panperitonitis is higher in elderly than non-elderly patients [25]. Even though we have reported less experience performing ESDs, fewer than 50 cases had independent risk factors for complications [6]. It is therefore feasible to perform colorectal ESD at high-volume centers, even in elderly patients.

Limitations of the present study include its single-center design, small number of patients followed up without additional treatment, and a short follow-up period. At this point, it is difficult to recommend a strategy for treating non-curative cases of colorectal ESD in elderly patients who have a higher risk of surgery-associated complications. Further follow-up studies that focus on mortality and complication rates are necessary to confirm the feasibility of colorectal ESD in elderly patients.

Conclusion

Treatment outcomes for colorectal ESD in elderly patients were equivalent to those in non-elderly patients. However, many of the non-curative cases in elderly patients were followed up without additional treatment. Thus, future studies should collect more information on treatment outcomes in such patients in order to confirm the feasibility of colorectal ESD in elderly patients.

Conflicts of interest All authors have no conflicts of interest or financial ties to disclose.

References

- Matsuda T, Marugame T, Kamo K et al (2008) Cancer incidence and incidence rates in Japan in 2002: based on data from 11 population-based cancer registries. *Jpn J Clin Oncol* 38:641–648
- McKenna RJ Sr (1994) Clinical aspects of cancer in the elderly. Treatment decisions, treatment choices, and follow-up. *Cancer* 74:2107–2017
- Matsushita I, Hanai H, Kajimura M et al (2002) Should gastric cancer patients more than 80 years of age undergo surgery? Comparison with patients not treated surgically concerning prognosis and quality of life. *J Clin Gastroenterol* 35:29–34
- Ohkuwa M, Hosokawa K, Boku N et al (2001) New endoscopic treatment for intramucosal gastric tumors using an insulated-tip diathermic knife. *Endoscopy* 33:221–216
- Ono H, Kondo H, Gotoda T et al (2001) Endoscopic mucosal resection for treatment of early gastric cancer. *Gut* 48:225–229
- Saito Y, Uraoka T, Yamaguchi Y et al (2010) A prospective, multicenter study of 1111 colorectal endoscopic submucosal dissections (with video). *Gastrointest Endosc* 72:1217–1225
- Fujishiro M, Yahagi N, Kakushima N et al (2007) Outcomes of endoscopic submucosal dissection for colorectal epithelial neoplasms in 200 consecutive cases. *Clin Gastroenterol Hepatol* 5:678–683, quiz 645
- Saito Y, Uraoka T, Matsuda T et al (2007) Endoscopic treatment of large superficial colorectal tumors: a case series of 200 endoscopic submucosal dissections (with video). *Gastrointest Endosc* 66:966–973
- Yamamoto H, Kawata H, Sunada K et al (2002) Success rate of curative endoscopic mucosal resection with circumferential mucosal incision assisted by submucosal injection of sodium hyaluronate. *Gastrointest Endosc* 56:507–512
- Antillon MR, Bartalos CR, Miller ML et al (2008) En bloc endoscopic submucosal dissection of a 14-cm laterally spreading adenoma of the rectum with involvement to the anal canal: expanding the frontiers of endoscopic surgery (with video). *Gastrointest Endosc* 67:332–337
- Hurlstone DP, Atkinson R, Sanders DS et al (2007) Achieving R0 resection in the colorectum using endoscopic submucosal dissection. *Br J Surg* 94:1536–1542
- Saito Y, Fukuzawa M, Matsuda T et al (2010) Clinical outcome of endoscopic submucosal dissection versus endoscopic mucosal resection of large colorectal tumors as determined by curative resection. *Surg Endosc* 24:343–352
- Uraoka T, Higashi R, Kato J et al (2011) Colorectal endoscopic submucosal dissection for elderly patients at least 80 years of age. *Surg Endosc* 25:3000–3007
- Matsuda T, Fujii T, Saito Y et al (2008) Efficacy of the invasive/non-invasive pattern by magnifying chromoendoscopy to estimate the depth of invasion of early colorectal neoplasms. *Am J Gastroenterol* 103:2700–2706
- Uraoka T, Saito Y, Matsuda T et al (2006) Endoscopic indications for endoscopic mucosal resection of laterally spreading tumours in the colorectum. *Gut* 55:1592–1597
- Hotta K, Fujii T, Saito Y et al (2009) Local recurrence after endoscopic resection of colorectal tumors. *Int J Colorectal Dis* 24:225–230
- Roscio F, Bertoglio C, De Luca A et al (2011) Outcomes of laparoscopic surgery for colorectal cancer in elderly patients. *JSL* 15:315–321
- Chou CL, Chang SC, Lin TC et al (2011) Differences in clinicopathological characteristics of colorectal cancer between younger and elderly patients: an analysis of 322 patients from a single institution. *Am J Surg* 202:574–582
- Arenal-Vera JJ, Tinoco-Carrasco C, del-Villar-Negro A et al (2011) Colorectal cancer in the elderly: characteristics and short term results. *Rev Esp Enferm Dig* 103:408–415

20. Symeonidis D, Christodoulidis G, Koukoulis G et al (2011) Colorectal cancer surgery in the elderly: limitations and drawbacks. *Tech Coloproctol* 15:47–50
21. Degiuli M, Mineccia M, Bertone A et al (2004) Outcome of laparoscopic colorectal resection. *Surg Endosc* 18:427–432
22. Maziere S, Laniece I, Hadri N et al (2011) Predictors of functional decline of older persons after an hospitalisation in an acute care for elder unit: importance of recent functional evolution. *Presse Med* 40:e101–110
23. Tanaka S, Oka S, Kaneko I et al (2007) Endoscopic submucosal dissection for colorectal neoplasia: possibility of standardization. *Gastrointest Endosc* 66:100–107
24. Zhou PH, Yao LQ, Qin XY (2009) Endoscopic submucosal dissection for colorectal epithelial neoplasm. *Surg Endosc* 23:1546–1551
25. Tan KK, Hong CC, Zhang J et al (2011) Predictors of outcome following surgery in colonic perforation: an institution's experience over 6 years. *J Gastrointest Surg* 15:277–284

Solitary Metastatic Colon Cancer Showing a Small Depressed Configuration

Hidetsugu Yamagishi, Taku Sakamoto, Takahisa Matsuda, Takeshi Nakajima and Yutaka Saito

Abstract

We herein present a case of IIC-like metastatic lung cancer that was detected early. A 65-year-old man presented with diarrhea and difficulty walking. Colonoscopy demonstrated a depressed lesion in the descending colon. However, the appearance of the lesion by endoscopy with a magnifying objective was not compatible with early colon cancer. Therefore, we performed diagnostic endoscopic mucosal resection to allow for an examination of the whole lesion. A histological examination demonstrated lung cancer metastasis to the colon. Only 1.6% of lung cancers metastasize to the large intestine, and metastatic colorectal cancer is not usually detected at an early stage. In the present case, however, endoscopy and a histological examination revealed alterations in the mucosal configuration of the lesion, which were unusual for early colon cancer.

Key words: colonoscopy, metastatic colon cancer

(Intern Med 51: 2321-2324, 2012)

(DOI: 10.2169/internalmedicine.51.7559)

Introduction

Gastrointestinal tract metastasis from a malignant tumor is rare, and the large intestine, in particular, is thought to be comparatively less prone to metastasis. Metastatic gastrointestinal tumors account for 1.9% of all metastatic alimentary canal tumors and 0.1-1.0% of malignant colorectal tumors (1). Among gastrointestinal tract tumors, metastasis from primary lung cancer accounts for only 0.19% of all cases (2). Such metastases are commonly detected in the small intestine (3) and have a higher predilection for occurrence in the jejunum than in the ileum. In addition, multiple (rather than solitary) lesions tend to occur in such metastases. Gastrointestinal tract metastasis is generally manifested by ileus or gastrointestinal bleeding at an advanced stage. We herein present a case of IIC-like colon metastasis from lung cancer that was detected at an early stage.

Case Report

A 65-year-old man presented with diarrhea, numbness, pain in both lower extremities, and difficulty walking. A barium enema examination indicated transverse colon steno-

sis, and computed tomography (CT) revealed nodular shadows in the liver. Both advanced colon cancer and metastatic liver cancer were diagnosed.

Colonoscopy showed no lesions in the transverse colon, but it did reveal a depressed lesion (3 mm) in the descending colon (Fig. 1). After indigo carmine dye spraying, the tumor and its margin became clearer (Fig. 2), and macroscopic type 0-IIc cancer was identified. Narrow-band imaging revealed slightly irregular and loose microcapillary vessels (Fig. 3). Crystal violet staining showed a small round pit pattern of Kudo's Type IIIs (Fig. 4). The endoscopic diagnosis was early colon cancer. We performed an endoscopic mucosal resection of the lesion.

A histological evaluation revealed a poorly differentiated adenocarcinoma in the submucosa (Fig. 5). The neoplastic cells appeared to have invaded the lamina propria stroma; the duct epithelium was unaffected. Vascular invasion was confirmed (Fig. 6 and 7). We suspected a metastatic rather than primary tumor based on the histology of the tumor and the fact that the tumor cells were negative for caudal-type homeobox-2, prostate-specific antigen and chromogranin A, and positive for thyroid transcription factor-1 (Fig. 8). We strongly suspected metastasis from lung cancer.

The presence of lung cancer was confirmed by CT, which

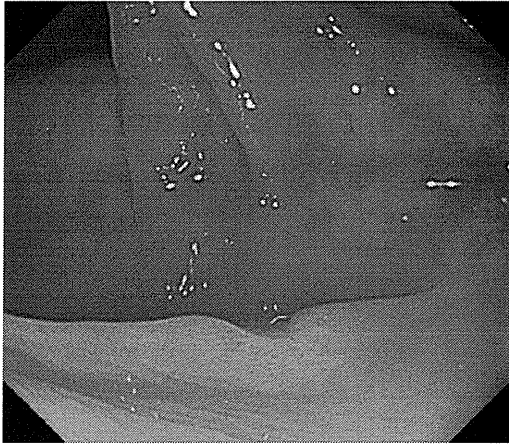


Figure 1. Colonoscopy showed a depressed lesion in the descending colon.

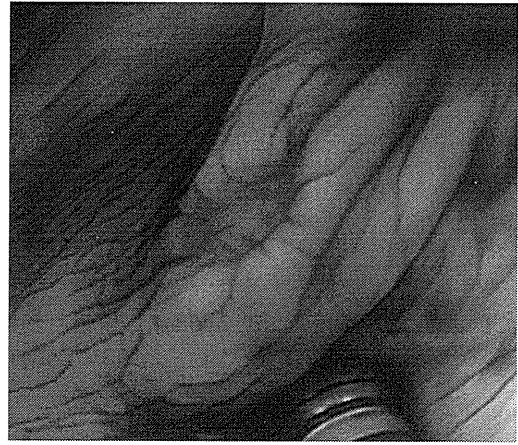


Figure 2. Indigo carmine dye spraying.

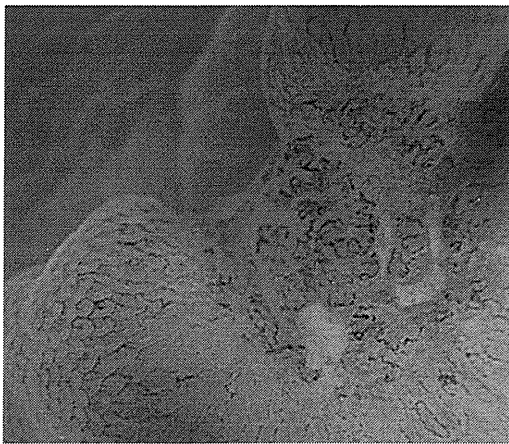

Figure 3. Narrow-band imaging (NBI) showed normal vessels around the depressed area. There were slightly irregular vessels and loose microcapillary vessels in the depressed area.

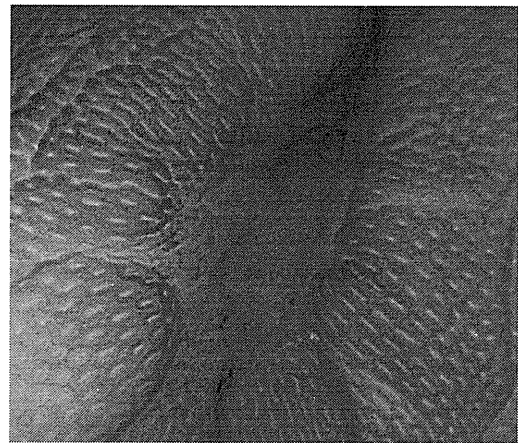


Figure 4. Crystal violet staining revealed a normal pit pattern around the depressed area. The depressed area consisted of small irregular pits.

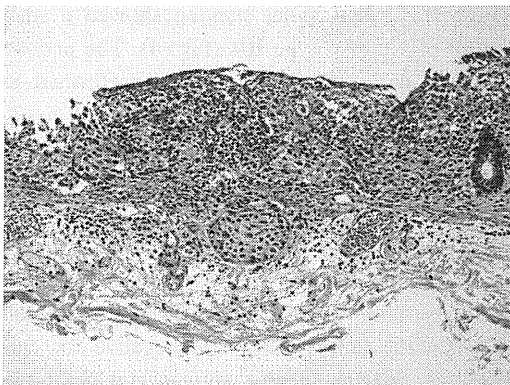


Figure 5. Histology of the resected specimen showed poorly differentiated adenocarcinoma in the submucosa (Hematoxylin and Eosin staining, $\times 100$).

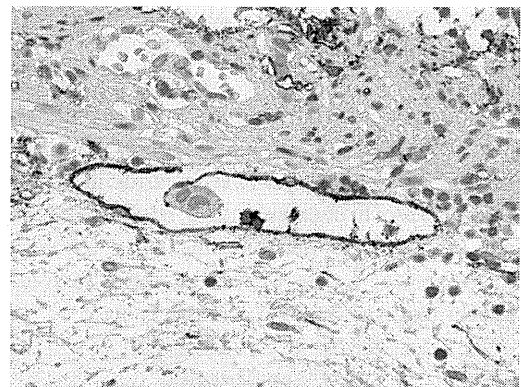

Figure 6. Lymphatic invasion (D2-40, $\times 400$).

also revealed liver and bone metastases (Fig. 9 and 10). We diagnosed the patient with primary lung cancer based on the

pathological examination and CT. The patient was transferred to the terminal care unit for the prophylactic control of pain and symptoms.

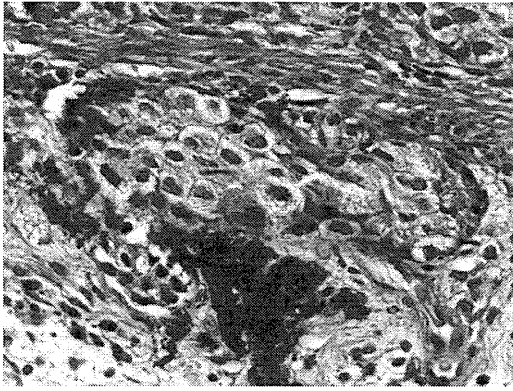


Figure 7. Venous invasion (Victoria blue-Hematoxylin and Eosin staining, $\times 400$).

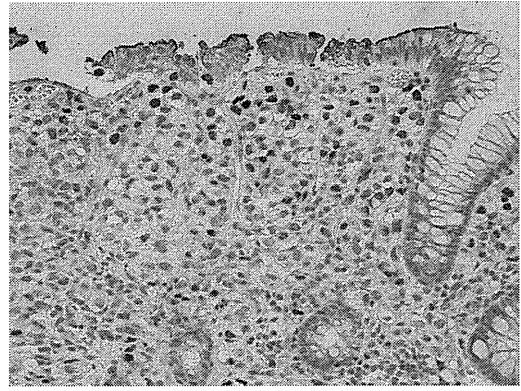


Figure 8. Thyroid transcription factor-1-positive tumor cells ($\times 200$).

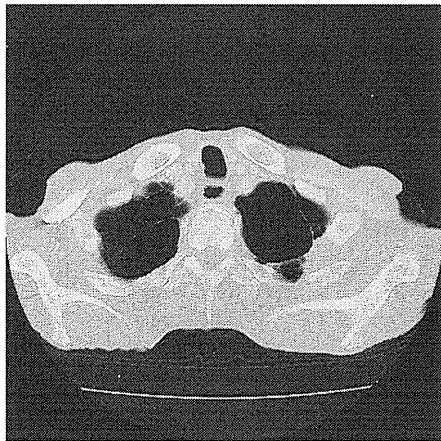


Figure 9. CT scan revealed the lung mass.

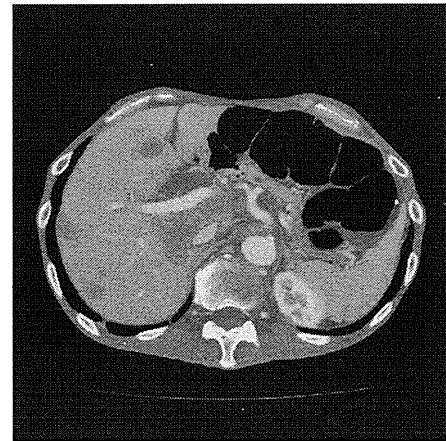


Figure 10. CT scan revealed the presence of multiple hepatic metastases and bone metastasis.

Discussion

The prevalence of lung cancer metastases to the large intestine is 1.6% in autopsy cases in Japan (4). Metastatic colorectal cancer is usually not detected at an early stage. This is probably because gastrointestinal tract metastases do not produce clinical symptoms, such as apoplexy, perforation, or intestinal atresia until the lesion becomes enlarged.

In the current case, our initial diagnosis was early primary colon cancer, which was based on the macroscopic appearance of the lesion during colonoscopy, and a metastatic tumor was not suspected. However, a retrospective analysis and confirmatory endoscopy showed alterations in the mucosal pattern in the lesion, which is not a common feature of early colon cancer. More typical images are seen for Narrow-band imaging (NBI) and pit patterns in cases of early colorectal cancer, but in the present case, the pits in the depressions were considered to correspond to atypical type III cancer. We therefore considered that in the initial lesion, there was little morphological change at the mucosal surface, and that such change was submucosal, because the tumor cells that had infiltrated into the submucosal layer

had proliferated towards the epithelial side, thereby causing retraction of the normal non-malignant glandular tubules and making the pits appear small and round.

Furthermore, it was also considered that tumor cell proliferation towards the mucosal surface had led to ulceration, thereby producing 0-IIc-like changes with central depressions. Lung cancer metastasis to the large intestine mainly involves hematogenous spread (5), wherein the tumor cells initially spread to the submucosa and muscularis propria and then subsequently proliferate. Such tumors generally have diffuse infiltrating-type and submucosal tumor-like patterns.

Histopathologically, the neoplastic cells show a medullary proliferation pattern, accompanied by a fibrous stroma. Therefore, it is important to differentiate between endocrine cell carcinoma and metastasis from various organs. We considered that the metastasis might have originated from prostate cancer, but staining for prostate specific antigen (PSA) was negative. Subsequently, we considered metastasis from lung cancer and performed thyroid transcription factor-1 (TTF-1) staining, which is useful for making a differential diagnosis. TTF-1, discovered by Civitareale, shows high organ specificity and it is positive in both squamous cell carci-

noma (5-11%) and adenocarcinoma (62.5-72%) of the lung (6, 7). TTF-1 has also been reported to be expressed in 80-97% of small cell cancers. Therefore, to rule out small cell cancer in the present case, we performed chromogranin A staining, and negative results were obtained.

On the basis of these findings, we diagnosed the patient with lung cancer metastasis to the colon. This case of a Ilc-like metastatic lesion from lung cancer is very rare, and the endoscopic appearance and pathological findings reported herein should therefore be important for the differential diagnosis of similar cases.

The authors state that they have no Conflict of Interest (COI).

References

1. Balthazar EJ, Rosenberg HD, Davidian MM. Primary and metastatic scirrhous carcinoma of the rectum. *AJR* **132**: 711-715, 1979.
2. Kim MS, Kook EH, Ahn SH, et al. Gastrointestinal metastasis of lung cancer with special emphasis on a long-term survivor after operation. *J Cancer Res Clin Oncol* **135**: 297-301, 2009.
3. Garwood RA, Sawyer MD, Ledesma EJ, et al. A case and review of bowel perforation secondary to metastatic lung cancer. *Am Surg* **71**: 110-116, 2005.
4. Naka H, Kou M, Shinichirou O, et al. Clinicopathological study on cancer involvement of gastrointestinal tract observed in 1,755 autopsies. *Kitasato Med* **19**: 254-257, 1989.
5. Morris DM, Deitch EA. Clinical significant intestinal metastasis from a primary bronchogenic carcinoma. *J Surg Oncol* **23**: 93-94, 1983.
6. Di Loreto C, Di Lauro V, Puglisi F, et al. Immunocytochemical expression of tissue specific transcription factor-1 lung cancer. *J Clin Pathol* **50**: 30-32, 1997.
7. Pelosi G, Frassetto F, Pasini F, et al. Immunoreactivity for thyroid transcription factor-1 in stage I non-small cell cancer of the lung. *Am J Surg Pathol* **25**: 363-372, 2001.

The use of computed tomographic colonography in predicting the difficulty of endoscopic treatment for large protruding neoplasms

Taku Sakamoto · Mototaka Miyake ·
Takeshi Nakajima · Takahisa Matsuda ·
Hirokazu Taniguchi · Yutaka Saito · Gen Inuma

Accepted: 1 December 2011 / Published online: 14 December 2011
© Springer-Verlag 2011

Dear Editor:

Submucosal fibrosis is considered a major hurdle in endoscopic submucosal dissection (ESD), which is an effective technique for treating colorectal neoplasms. Although it is relatively easy to predict the difficulty of endoscopic resection for laterally spreading tumors (LST), it is more difficult in the case of large protruding lesions (Paris type 0-Is, >20 mm in diameter) such as villous tumors, which are often eventually removed by multiple piecemeal resection. However, considering the high incidence of recurrent or residual tumors and the difficulty of precise histopathological evaluation, piecemeal endoscopic mucosal resection (EMR) should be avoided. Instead, when endoscopic resection is predicted to be difficult, laparoscopic assisted colectomy is a viable treatment option; therefore, the objective evaluation of fibrotic changes in the submucosal layer is important. Although this evaluation may be accomplished using endoscopic miniprobe ultrasonography (mEUS), which is effective in assessing the depth of invasion in both gastric cancer and colorectal neoplasms as well as that of submucosal fibrosis for flat or depressed lesions, its limited depth of penetration is a disadvantage in assessing protruding lesions. Moreover, the observation of lesions located on

the oral side of folds using mEUS is also considered difficult, and a different method may be more suitable for identifying these cases.

Computed tomographic colonography (CTC) is currently an established technique for colorectal imaging that allows the evaluation of both endoluminal and transluminal features and has good diagnostic performance in T staging of colorectal cancer. Using CTC, images can be reconstructed in almost any plane and can be used to create three-dimensional images while maintaining diagnostic image resolution and without influencing the location of the lesion. It can also be used to evaluate both lesion morphology and intratumoral features, including those of protruding lesions and lesions located on the oral side of folds. Moreover, several studies have shown that the degree of fibrosis contributes to an enhancement pattern in contrast-enhanced CTC (CE-CTC). Thus, CE-CTC may potentially be used for evaluating the shape and morphological changes of the bowel wall, including the degree of fibrotic changes in the submucosal layer. In this letter, we describe the use of CTC in the identification of patients with intramucosal protruded-type neoplasm predicted to present endoscopic difficulties.

All patients who had undergone preoperative colonoscopy and same day CE-CTC at our institution from January 2006 to December 2008 were identified through retrospective analysis. After pretreatment colonoscopy and standard preparation, patients underwent CE-CTC examination for staging using a 64-multidetector row CT scanner (Aquilion; Toshiba Medical Systems, Tokyo, Japan). The scan range was from the abdomen to the pelvis, with the following parameters: 120 kV; 200–400 mA with automatic exposure control; 64 rows×0.5 mm collimation; and helical pitch, 53 (pitch factor, 0.828). Anticholinergic drugs were injected intravenously immediately before each examination, and gas insufflation was performed via the anus with an

T. Sakamoto (✉) · T. Nakajima · T. Matsuda · Y. Saito
Endoscopy Division, National Cancer Center Hospital,
5-1-1 Tsukiji,
Chuo-ku, Tokyo 104-0045, Japan
e-mail: tasakamo@ncc.go.jp

M. Miyake · G. Inuma
Department of Diagnostic Radiology, National Cancer Center Hospital,
Chuo-ku, Tokyo, Japan

H. Taniguchi
Pathology Division, National Cancer Center Hospital,
Chuo-ku, Tokyo, Japan

automated CO₂ insufflator (Protocol; E-Z-EM, New York). For TNM staging, all patients were administered a total of 150 mL of contrast medium [Omnipaque (300 mg/mL); Daiichi-Sankyo Pharmaceuticals, Tokyo, Japan] intravenously with an autoinjector at a rate of 3.0 mL/s. The scan delays were set at 50 s (early phase) and 90 s (delayed phase) after the injection of the contrast medium. CE-CTC images were acquired for each patient in prone and supine positions and reviewed by an experienced radiologist for identifying “bundle-like low-density areas (BLDA)” in the submucosa, which were characterized as a lower density area than that of protruding intramucosal neoplasms in the early phase.

Patients with protruding intramucosal neoplasms larger than 20 mm in diameter were included in our study, whereas those with LSTs as per the endoscopic data were excluded. The 11 patients that met these criteria were divided into two groups according to the outcome of the endoscopic treatment: 6 cases of patients were included in group A, which comprised the difficult resections that had a piecemeal resected specimen with more than 10 pieces and/or a procedure time longer than 180 min, while group B included the remaining 5 cases. En bloc resection was achieved in 36% cases (4 out of 11), and the median duration of the procedure time was 95 min (interquartile range, 80–200 min). In group A, the median size of the lesions was 52.5 mm (range, 40–60), with 83% lesions located in the colon and 17% in the rectum. In group B, the lesions had a median size of 40 mm (range, 30–50 mm), and 80% was located in the rectum. No significant differences in the size or location of lesions were observed between the two groups ($P=0.113$ and $P=0.067$, respectively); however, the duration of the procedure was significantly longer in group A than group B (median time, 200 vs. 70 min; $P=0.008$). The rate of positive findings for BLDAs was 83% (five out of six) in group A and 20% (one out of five) in group B. Histopathological examination showed that the presence of BLDA corresponded to the presence of submucosal fibrosis.

Regarding clinical outcomes, en bloc resection was achieved in only 36% of the cases in this study. Although ESD was planned in nine cases, the procedure was abandoned and converted to piecemeal EMR in 56% (five out of nine) of

these cases because of technical difficulties associated with submucosal fibrosis. As a previous Japanese multicenter study has reported that the en bloc resection rate of ESD for treatment of colorectal neoplasms was 88%, it appears that endoscopic treatment for large protruding lesions is more difficult than that for other colorectal neoplasms. Additionally, confounding factors other than submucosal fibrosis, such as location and lesion size, may have potentially contributed to the lack of success of endoscopic treatment in our study. In particular, group A included a greater number of colonic lesions; colonic lesion ESD is known to be technically more difficult to treat than rectal ESD. However, as there was no significant difference in lesion size between groups, submucosal fibrosis seemed to be the most important factor determining the difficulty of endoscopic treatment.

Our study has certain limitations. First, we reviewed only intramucosal neoplastic lesions that were treated endoscopically. Although the presence of submucosal fibrosis could be confirmed, precise correspondence between histological and CTC findings may be difficult to conclude in cases where patients require piecemeal resection. Comparing histological and CTC findings in surgically resected intramucosal neoplasms would enhance the accuracy and acceptance of preoperative BLDA assessment by CTC. Second, only a single experienced radiologist evaluated the presence of BLDA in our study, and our findings require validation by studies involving multiple radiologists. Third, our study was a pilot study with a small sample size; a prospective multicenter trial would provide further clarity regarding the utility of CTC in predicting difficulties in endoscopic resection. Despite these limitations, our study suggests that the presence of BLDA corresponds well with the presence of fibrosis in the submucosal layer and that CTC may be an effective tool for preoperatively estimating the difficulty of the endoscopic resection of large protruding tumors in the colon.

Financial disclosures No funding was provided for this study, and the authors have no relevant financial relationships to report.

The impact of narrow band imaging for colon polyp detection: a multicenter randomized controlled trial by tandem colonoscopy

Hiroaki Ikematsu · Yutaka Saito · Shinji Tanaka · Toshio Uraoka ·
Yasushi Sano · Takahiro Horimatsu · Takahisa Matsuda · Shiro Oka ·
Reiji Higashi · Hideki Ishikawa · Kazuhiro Kaneko

Received: 8 December 2011 / Accepted: 24 February 2012 / Published online: 24 March 2012
© Springer 2012

Abstract

Background Previous studies have yielded conflicting results on the adenoma detection rate with narrow band imaging (NBI) compared with white light imaging (WLI). To overcome the confounding factors of these studies, we aimed to evaluate the colonic adenoma detection rate with primary NBI versus that with primary WLI by using consistent NBI system, endoscope, and imaging settings, and experienced colonoscopists.

Methods In this multicenter prospective trial, 813 patients were randomized to undergo high-definition, tandem

colonoscopy in the right colon with either NBI followed by WLI (NBI–WLI group) or WLI followed by NBI (WLI–NBI group). The NBI settings were fixed at surface structure enhancement level A-5 and adaptive index of hemoglobin color enhancement level 3. All detected polyps were resected or biopsied for histopathological analysis. The primary and secondary outcome measures were the adenoma detection rates and miss rates, respectively, with primary imaging.

Results The NBI–WLI and WLI–NBI groups comprised 389 and 393 patients, respectively, who met the inclusion criteria. The groups did not differ significantly in age, gender, institution, indication for colonoscopy, bowel preparation, or observation time. The adenoma detection rates of primary NBI and WLI were 42.3 and 42.5 %, respectively [difference not significant (NS)]. The adenoma miss rate was significantly less with primary NBI than with primary WLI (21.3 vs. 27.8 %; $p = 0.03$).

Conclusions NBI does not improve the adenoma detection rate during primary colonoscopy; however, it has a lower miss rate for adenoma lesions in the proximal colon than WLI.

H. Ikematsu (✉) · K. Kaneko
Department of Gastroenterology and Gastrointestinal Oncology,
National Cancer Center Hospital East, 6-5-1 Kashiwanoha,
Kashiwa, Chiba 277-8577, Japan
e-mail: hikemats@east.ncc.go.jp

Y. Saito · T. Matsuda
Endoscopy Division, National Cancer Center Hospital,
Tokyo, Japan

S. Tanaka · S. Oka
Department of Endoscopy, Hiroshima University,
Hiroshima, Japan

T. Uraoka · R. Higashi
Department of Endoscopy, Okayama University Hospital,
Okayama, Japan

Y. Sano
Gastrointestinal Center, Sano Hospital, Kobe, Japan

T. Horimatsu
Department of Gastroenterology and Hepatology,
Kyoto University, Kyoto, Japan

H. Ishikawa
Department of Molecular-Targeting Cancer Prevention,
Kyoto Prefectural University of Medicine, Osaka, Japan

Keywords Adenoma detection rate · Colonoscopy · Screening

Introduction

Early detection and removal of colorectal adenoma lesions by screening colonoscopy are the most effective means of colorectal cancer prevention [1–3]. The adenoma detection rate is an important quality indicator for colonoscopy; moreover, this detection rate is an independent predictor of the risk of colorectal cancer after screening colonoscopy