

tribution to this study. We also thank Tse Yee Kit, MPhil, of the Department of Medicine and Therapeutics, The Chinese University of Hong Kong for performing data processing and statistical calculations for this study.

REFERENCES

- Sung JY, Lau JYW, Goh KL, et al, for the Asia Pacific Working Group on Colorectal Cancer. Increasing incidence of colorectal cancer in Asia. *Lancet Oncol* 2005;6:871-6.
- Center MM, Jemal A, Smith RA, et al. Worldwide variations in colorectal cancer. *CA Cancer J Clin* 2009;59:366-78.
- Curado MP, Edwards B, Shin HR, et al, editors. Cancer incidence in five continents, vol. IX. IARC Scientific Publications No. 160, Lyon (France): IARC; 2007.
- Hardcastle JD, Chamberlain JO, Robinson MH, et al. Randomised controlled trial of faecal-occult-blood screening for colorectal cancer. *Lancet* 1996;348:1472-7.
- Mandel JS, Bond JH, Church TR, et al. Reducing mortality from colorectal cancer by screening for fecal occult blood. *N Engl J Med* 1993;328:1365-71.
- Chien C, Morimoto LM, Tom J, et al. Differences in colorectal cancer stage and survival by race and ethnicity. *Cancer* 2005;104:629-39.
- Janz NK, Wren PA, Schottenfeld D, et al. Colorectal cancer screening attitudes and behavior: a population-based study. *Prev Med* 2003;37:627-34.
- Koo JH, Wong SKC, Jalaludin B, et al. Clinical and pathological outcomes of colorectal cancer in a multi-ethnic population. *Clin Gastroenterol Hepatol* 2008;6:1016-21.
- Seeff LC, Nadel MR, Klabunde CN, et al. Patterns and predictors of colorectal cancer test use in the adult U.S. population. *Cancer* 2004;100:2093-103.
- Lieberman DA. Screening for colorectal cancer. *N Engl J Med* 2009;361:1179-87.
- Sung JY, Lau JYW, Young GP, et al. Asia Pacific consensus recommendations for colorectal cancer screening. *Gut* 2008;57:1166-76.
- Byeon J-S, Yang S-K, Kim TI, et al, for the Asia Pacific Working Group for Colorectal Cancer. Colorectal neoplasm in asymptomatic Asians: a prospective multinational multicenter colonoscopy survey. *Gastrointest Endosc* 2007;65:1015-22.
- Leung WK, Ho KY, Kim W-H, et al, for the Asia Pacific Working Group on Colorectal Cancer. Colorectal neoplasia in Asia: a multicenter colonoscopy survey in symptomatic patients. *Gastrointest Endosc* 2006;64:751-9.
- Sung JY, Choi SYP, Chan FKL, et al. Obstacles to colorectal cancer screening in Chinese: a study based on the Health Belief Model. *Am J Gastroenterol* 2008;103:974-81.
- Koo JH, Arasaratnam MM, Liu K, et al. Knowledge, perception and practices of colorectal cancer in an ethnically diverse population. *Cancer Epidemiol* 2010;34:604-10.
- Weber MF, Banks E, Ward R, et al. Population characteristics related to colorectal cancer testing in New South Wales, Australia: results from the 45 and Up Study cohort. *J Med Screen* 2008;15:137-42.
- Brawarsky P, Brooks DR, Mucci LA, et al. Effects of physician recommendation and patient adherence on rates of colorectal cancer testing. *Cancer Detect Prev* 2004;28:260-8.
- Wong NY, Nenny S, Guy RJ, et al. Adults in a high-risk area are unaware of the importance of colorectal cancer: a telephone and mail survey. *Dis Col Rectum* 2002;45:946-54.
- Goh KL, Quek KF, Yeo et al. Colorectal cancer in Asians: a demographic and anatomic survey in Malaysian patients undergoing colonoscopy. *Aliment Pharmacol Ther* 2005;22:859-64.
- Hilmi I, Hartono JL, Goh KL. Challenges in colorectal cancer screening in an urban Asian population. *Asian Pacific J Cancer Prev* 2011;11:815-22.
- Ngelangel CA, Wang EHM. Cancer and the Philippine Cancer Control Program. *Jpn J Clin Oncol* 2002;32(Suppl 1):S52-61.
- Price J, Campbell C, Sells J, et al. Impact of UK Colorectal Cancer Screening Pilot on hospital diagnostic services. *J Public Health (Oxf)* 2005;27:246-53.
- Yeoh KG, Ho KY, Chiu HM, et al; Asia-Pacific Working Group on Colorectal Cancer. The Asia-Pacific Colorectal Screening score: a validated tool that stratifies risk for colorectal advanced neoplasia in asymptomatic Asian subjects. *Gut* 2011;60:1236-41.
- Subramaniam S, Klosterman M, Amonkar MM, et al. Adherence with colorectal cancer screening guidelines: a review. *Prev Med* 2004;38:536-50.
- Robb KA, Power E, Atkin W, et al. Ethnic differences in participation in flexible sigmoidoscopy screening in the UK. *J Med Screen* 2008;15:130-6.
- Choi KS, Jun JK, Lee H-Y, et al. Increasing uptake of colorectal cancer screening in Korea: a population-based study. *BMC Public Health* 2010;10:265-73.
- McCaffery K, Wardle J, Waller J. Knowledge, attitudes, and behavioral intentions in relation to the early detection of colorectal cancer in the United Kingdom. *Prev Med* 2003;36:525-35.
- Ford JS, Coups EJ, Hay JL. Knowledge of colon cancer screening in a national probability sample in the United States. *J Health Commun* 2006;11:19-35.
- Chong VH, Abdullah MS, Telisinghe PU, et al. Colorectal cancer: incidence and trend in Brunei Darussalam. *Singapore Med J* 2009;50:1085-9.
- Furnham A. Response bias, social desirability and dissimulation. *Pers Indiv Differ* 1986;7:385-400.

of Singapore, Singapore, Department of Gastroenterology (4), Kaohsiung Medical University, Kaohsiung, Taiwan, Cipto Mangunkusumo Hospital (5), University of Indonesia, Jakarta, Indonesia, Department of Gastroenterology (6), Shanghai Hospital, Center for Clinical Epidemiology, Second Military Medical University, Shanghai, People's Republic of China, Department of Internal Medicine (7), National Taiwan University Hospital, Taipei, Taiwan, Raja Isteri Pengiran Anak Saleha (RIPAS) Hospital (8), Bandar Seri Begawan, Brunei, Division of Gastroenterology (9), Chulalongkorn University, Bangkok, Thailand, Department of Gastroenterology and Hepatology (10), University of Malaya, Kuala Lumpur, Malaysia, Department of Gastroenterology (11), University of Ulsan, Seoul, Korea, Patel Hospital (12), Karachi, Pakistan, Department of Gastroenterology (13), Xijing Hospital, Fourth Military Medical University, Xi'an, People's Republic of China, Endoscopy Division (14), National Cancer Center Hospital, Tokyo, Japan, Department of Gastroenterology and Human Nutrition (15), All India Institute of Medical Sciences, Delhi, India, Department of Gastroenterology (16), University of Santo Tomas, Manila, Philippines, Department of Gastroenterology (17), Yonsei University, Seoul, Korea.

Reprint requests: Jenn H. Koo, FRACP, Department of Gastroenterology, Liverpool Hospital, Locked Bag 7103, Liverpool BC, NSW 1871, Australia.

If you would like to chat with an author of this article, you may contact Dr Koo at kenjhkoo@yahoo.com.au.

LETTERS, TECHNIQUES AND IMAGES

Impact of endoscopic submucosal dissection knife on risk of perforation with an animal model-monopolar needle knife and with a bipolar needle knife




Fig. 1. (a) Bipolar needle knife (B knife). (b) Ball-tip B knife (BB knife). (c) Monopolar needle knife.

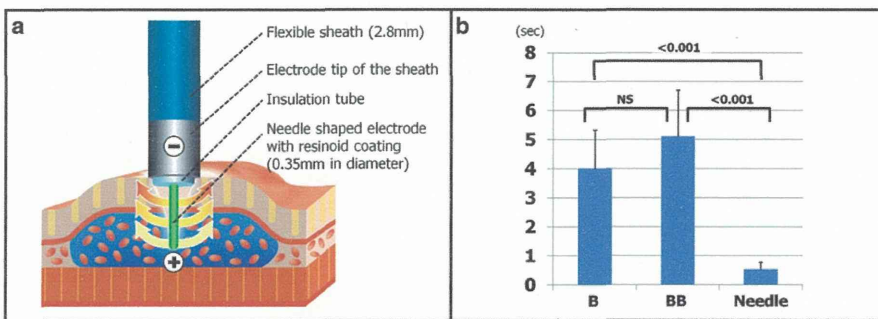


Fig. 2. (a) Schematic view showing flow route of high-frequency electric current from knife to sheath tip. (b) Results of bipolar needle knife (B knife), ball-tip B knife (BB knife) and monopolar needle knife showing time to perforation (s) on a resected porcine esophagus. NS, not significant.

The bipolar needle knife (B knife; XEMEX Co, Tokyo, Japan) was developed to reduce the risk of perforation during endoscopic submucosal dissection compared to monopolar instruments (Fig. 1a).¹ It was designed so high-frequency electricity flows from the knife to the sheath tip, reducing the amount of current sent to the muscle layer (Fig. 2a).² Subsequently, the ball-tip B knife (BB knife; XEMEX) was designed with a ball-shaped needle end, to further reduce the risk of perforation (Fig 1b). The objective of this animal experiment was to confirm and compare the actual risk of perforation with these different knives.

A resected porcine esophagus was cut open along the long axis to expose the lumen, which was fixed to a tray with stable tension. The end of each endoscopic submucosal dissection knife attached to a stick was designed to perpendicularly contact the mucosa. A 200 g fixed weight attached to the stick created a constant pressure for each application. A 40 W forced coagulation current (ICC200; ERBE, Tübingen, Germany) was applied with a needle knife (Olympus Optical Co., Ltd, Tokyo, Japan) (Fig. 1c), B knife and BB knife, and perforation time was measured. This procedure was repeated 10 times for each knife.

The time to perforation (mean ± SD) with the needle knife, B knife and BB knife was 0.5 ± 0.2, 4.0 ± 1.3 and

5.1 ± 1.6 s, respectively (needle vs B, $P < 0.001$; B vs BB, not significant; needle vs BB, $P < 0.001$) (Fig. 2b). The B and BB knives had significantly longer times to perforation than the needle knife.

Bipolar instruments are considered safer because of their perceived reduced risk of perforation, particularly the BB knife with its ball-tipped design. Our study reaffirmed that bipolar knives are better for performing endoscopic submucosal dissection of the esophagus and colorectum, which have thinner walls than the stomach.

Satoru Nonaka, Yutaka Saito, Shusei Fukunaga, Taku Sakamoto, Takeshi Nakajima and Takahisa Matsuda
Endoscopy Division, National Cancer Center Hospital, Tokyo, Japan

REFERENCES

- Saito Y, Uraoka T, Matsuda T *et al.* Endoscopic treatment of large superficial colorectal tumors: A case series of 200 endoscopic submucosal dissections (with video). *Gastrointest. Endosc.* 2007; **66**: 966–73.
- Sano Y, Fu KI, Saito Y *et al.* A newly developed bipolar-current needle-knife for endoscopic submucosal dissection of large colorectal tumors. *Endoscopy* 2006; **38** (Suppl 2): E95.

GASTROENTEROLOGY

Matched case-control study comparing endoscopic submucosal dissection and endoscopic mucosal resection for colorectal tumorsNozomu Kobayashi,^{*,5} Naoto Yoshitake,^{*} Yoshitaka Hirahara,^{*} Jun Konishi,^{*} Yutaka Saito,[†] Takahisa Matsuda,[†] Tsutomu Ishikawa,[‡] Ryuzo Sekiguchi^{*} and Takahiro Fujimori⁵^{*}Department of Diagnostic Imaging, Tochigi Cancer Center, Utsunomiya, Tochigi, [†]Endoscopy Division, National Cancer Center Hospital, Tokyo, and [‡]Departments of Radiology and [§]Surgical and Molecular Pathology, Dokkyo University School of Medicine, Tochigi, Japan**Key words**

colorectal neoplasia, endoscopic mucosal resection, endoscopic submucosal dissection, perforation, local recurrence.

Accepted for publication 18 September 2011.

Correspondence

Dr Nozomu Kobayashi, Department of Diagnostic Imaging, Tochigi Cancer Center, Yonan 4-9-13, Utsunomiya, Tochigi 320-0834, Japan. Email: nkobayas@tcc.pref.tochigi.lg.jp

Abstract**Background and Aim:** For large colorectal tumors, the en bloc resection rate achieved by endoscopic mucosal resection (EMR) is insufficient, and this leads to a high rate of local recurrence. As endoscopic submucosal dissection (ESD) has been reported to achieve a higher rate of en bloc resection and a lower rate of local recurrence in the short-term, it is expected to overcome the limitations of EMR. We conducted a matched case-control study between ESD and EMR to clarify the effectiveness of ESD for colorectal tumors.**Methods:** Between April 2005 and February 2009, a total of 28 colorectal tumors in 28 patients were resected by ESD and were followed up by colonoscopy at least once. As a control group, 56 EMR cases from our prospectively completed database were matched. En bloc resection, complication and recurrence rates were compared between the two groups.**Results:** The mean sizes of the lesions were 27.1 mm in the ESD group and 25.0 mm in the EMR group. The en bloc resection rate was significantly higher in the ESD group (92.9% vs 37.5% with ESD vs EMR), and the rate of perforation was also significantly higher (10.7% vs 0%). All cases of perforation were managed conservatively. No recurrence was observed in the ESD group, whereas local recurrences were detected in 12 EMR cases (21.4%). Eleven of the 12 recurrences (91.7%) were managed endoscopically, and one required surgical resection.**Conclusions:** Endoscopic submucosal dissection is a promising technique for the treatment of colorectal tumors, giving an excellent outcome in comparison with EMR.**Introduction**

Endoscopic submucosal dissection (ESD) was originally developed in 1995 to achieve en bloc resection of large early gastric cancers, and thereafter was applied to colorectal tumors.^{1,2} Originally, endoscopic mucosal resection (EMR) was the standard treatment for early-stage colorectal tumors because of its convenience and lower invasiveness.^{3,4} However, for large superficial colorectal tumors measuring ≥ 20 mm, the en bloc resection rate achieved by EMR is insufficient, and this leads to a high rate of local recurrence.⁵⁻⁷ As ESD has been reported to achieve a higher rate of en bloc resection and a lower rate of local recurrence in the short-term, it is expected to overcome the limitations of EMR and offer better outcomes. On the other hand, the technical difficulty and high complication rate of ESD has delayed the standardization of this technique, and currently colorectal ESD can be performed only by experienced endoscopists.⁸⁻¹²

The target lesions for ESD and EMR are similar but different. For example, lesions with a positive nonlifting sign or large can-

cerous lesions that must be removed en bloc for accurate histopathological examination can be resected only by ESD. Before the introduction of ESD, such lesions were treated by surgery.¹³ This difference in the target lesions between the two techniques explains the difficulty in performing a well designed comparative study to examine the merits and drawbacks of ESD and EMR. Therefore, the present matched case-control study was performed to clarify whether ESD is more effective than EMR for treatment of colorectal tumors.

Methods

Between May 2005 and February 2009, a total of 45 colorectal tumors in 45 patients were resected by ESD at Tochigi Cancer Center, and the data for these cases were accumulated on a prospectively completed database. Four recurrent tumors, one carcinoma and one gastrointestinal stromal tumor were excluded from the present study, and one case that required additional surgery after ESD because of noncurative resection was also

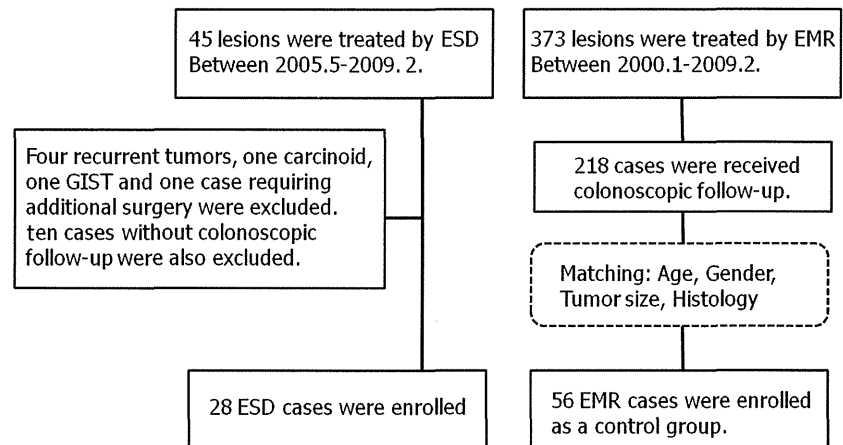


Figure 1 Flow chart. (EMR, endoscopic mucosal resection; ESD, endoscopic submucosal dissection; GIST, gastrointestinal stromal tumor).

excluded. Twenty-eight (73.7%) of the 38 remaining patients who underwent at least one follow-up colonoscopy examination were included in this matched case-control study. As a control group, two controls who had undergone EMR between January 2000 and December 2009 were matched with each studied ESD patient for age (± 5 years), gender (male/female), lesion size (± 5 mm) and histology (adenoma/early cancer) (Fig. 1).

The rates of en bloc resection, complication and recurrence were evaluated for both groups. We defined en bloc resection as a one-piece resection of the whole lesion, as observed endoscopically. Informed consent was obtained from all patients for use of their data.

Endoscopic procedure

For colonic preparation, we used 2–3 L polyethylene glycol-electrolyte solution on the day of the procedure. All the patients received scopolamine butylbromide 20 mg intravenously unless this was contraindicated, and sedation (for example with midazolam or diazepam) if required. All the investigators in this study had performed more than 500 colonoscopic procedures, and Olympus (Tokyo, Japan) video scopes (CF-Q240I, CF-Q240ZI, PCF-Q240ZI and CF-H260AZI. GIF-Q260J only for ESD cases) were used for each procedure.

Indication criteria for ESD

Colorectal ESD was officially introduced to Tochigi Cancer Center in May 2005, and our therapeutic strategy for colorectal tumors was changed at this point.

In the period before the introduction of colorectal ESD, EMR using a snare with submucosal injection had been the first choice. When a lesion was considered a possible invasive cancer and was too large, especially exceeding 30 mm in size, or showing a positive non-lifting sign, we recommended surgical resection.

In May 2005, we started to perform ESD mainly for laterally spreading tumors (LSTs), defined as lesions with a low vertical axis extending laterally along the interior luminal wall, and classified into two subtypes based on endoscopic findings.¹⁴ The granular (LST-G) type was defined as a lesion with even or uneven

nodules on the surface, and the non-granular (LST-NG) type as a lesion with a smooth surface. LST-NG type tumors ≥ 20 mm in size and LST-G type tumors ≥ 30 mm in size were usually treated by ESD because these lesions have a higher invasion rate and en bloc resection is necessary for adequate evaluation of the resected specimen. Lesions not lifted by submucosal injection were also good candidates for ESD, as were recurrent tumors and certain submucosal tumors. However, we also performed conventional EMR for selected lesions that were relatively small and well lifted by submucosal injection.

Adenomas, intramucosal cancers and submucosal minutely invasive cancers (submucosal invasion present, but less than 1 mm below the muscularis mucosae) without lymphovascular involvement or a poorly differentiated component are rarely considered to have lymph node metastasis, and therefore we judged such cases to have been curatively resected and did not recommend additional therapy.¹⁵

EMR and ESD procedure

Endoscopic mucosal resection was performed by seven staff endoscopists using the inject and cut technique. Normal saline or 0.2% sodium hyaluronate solution was injected into the submucosa of the lesion with a 23-gauge needle, and then the lifted lesion was resected using a monopolar oval snare (SD-210L-25; Olympus).

Endoscopic submucosal dissection was performed by a single experienced endoscopist using a monopolar needle knife (Flush knife; Fujinon [Tokyo, Japan] or Dual knife; Olympus) with submucosal injection of 0.4% sodium hyaluronate solution. Although several lesions were finally resected using a snare after circumferential incision, they were regarded as ESD cases. Carbon dioxide insufflation and sedation using midazolam were used routinely during ESD.¹⁶

Tumor size was estimated by measuring the resected specimen after retrieval for en bloc resected specimens and by comparing the endoscopic observation with the snare size for piecemeal resected specimens.

Both procedures were basically performed in an inpatient setting, and the length of the hospital stay was 3 or 4 days for EMR and 5 days for ESD, if no complications occurred.

Table 1 Clinicopathological characteristics of patients

	ESD group (n = 28)	EMR group (n = 56)	P-value
Age (mean [SD])	65.1 (9.7)	65.9 (9.9)	NS
Gender (M/F)	19/9	38/18	
Tumor size (mm) (mean [SD])	27.1 (10.1)	25 (9.0)	NS
Location (%)			
Proximal	14 (50.0)	26 (46.4)	
Distal	6 (21.4)	15 (26.8)	
Rectum	8 (28.6)	15 (26.8)	
Macroscopic type (%)			
LST-G	6 (21.4)	22 (39.3)	NS
LST-NG	20 (71.4)	22 (39.3)	0.005
Depressed	2 (7.1)	0	0.043
Protruded	0	12 (21.4)	0.008
Histopathology (%)			
Adenoma	8 (28.6)	16 (28.6)	
M-Ca	10 (35.7)	26 (46.4)	
SM-Ca	10 (35.7)	14 (25.0)	

Distal, descending and sigmoid colon; EMR, endoscopic mucosal resection; ESD, endoscopic submucosal dissection; LST-G, laterally spreading tumor granular type; LST-NG, laterally spreading tumor non-granular type; M-Ca, intramucosal cancer; NS, not significant; Proximal, cecum to splenic flexure; SD, standard deviation; SM-Ca, submucosal cancer.

Histopathologic analysis

All the resected specimens were fixed in 10% buffered formalin solution and stained with hematoxylin and eosin. Histopathological diagnosis was based on the Japanese classification of cancer of the colon and rectum, and submucosal cancers are subclassified into minute and deep (≥ 1 mm from the muscularis mucosae to the deepest point of invasion).¹⁷

Follow-up

We usually recommended that initial follow-up colonoscopy be performed at 6–12 months after endoscopic treatment for en bloc resection cases and at 3–6 months for cases that had been resected piecemeal. In cases without local recurrence, we performed repeat colonoscopy at intervals of 12 months or more.

Statistical analysis

All values are reported as mean \pm standard deviation when applicable. Comparisons were made using χ^2 test, Fisher's exact test, and *t*-test. Differences at $P < 0.05$ were considered to be statistically significant. All calculations were conducted using the SPSS statistical software package (SPSS, Chicago, IL, USA).

Results

The clinicopathological characteristics of the patients in the two groups are shown in Table 1. The mean sizes of the lesions were 27.1 mm in the ESD group and 25.0 mm in the EMR group. The incidence of LST-NG type lesions was significantly higher in the ESD group, whereas protruded lesions were included only in the EMR group.

Table 2 Clinical outcomes

	ESD group (n = 28)	EMR group (n = 56)	P-value
En bloc resection (%)	27 (92.9)	21 (37.5)	< 0.001
Complications			
Perforation (%)	3 (10.7)	0	0.013
Delayed bleeding (%)	2 (7.1)	1 (1.8)	0.2
Procedure time (min, median)	140 (45–400)	11 (2–280)	
Local recurrence (%) (en bloc/piecemeal)	0	12 (21.4) 1/11	0.008

EMR, endoscopic mucosal resection; ESD, endoscopic submucosal dissection.

En bloc resection was achieved for 27 (92.9%) of the 28 lesions in the ESD group and for 21 (37.5%) of the 56 lesions in the EMR group ($P < 0.001$) (Table 2). The median procedure time for ESD was 140 min (45–400 min), compared with 11 min (2–280 min) for EMR. As complications, perforation occurred in three (10.7%) of the 28 patients in the ESD group and in none of the patients in the EMR group ($p = 0.013$). All of these complications were managed conservatively by endoscopic closure using endoclips, and no emergency operation was needed (Table 3). Delayed bleeding occurred in two (7.1%) of the patients in the ESD group and in one (1.8%) of the patients in the EMR group. All three of these cases were also managed endoscopically using endoclips or hemostatic forceps, and no blood transfusions were necessary.

No local recurrence was detected in the ESD group during a median endoscopic follow-up period of 596 days (range 192–1319 days). In contrast, 12 local recurrences (21.4%) occurred in the EMR group during a median endoscopic follow-up period of 1141 days (range 84–3374 days). All the recurrent lesions except one (91.7%) were resected piecemeal. The median period after the procedure until detection of recurrence was 238 days (range 51–1498 days), and 10 of the 12 recurrences were detected at the first colonoscopic follow-up examination. Eleven (91.7%) of the 12 recurrences were managed endoscopically, and one case required surgical resection because of intramural recurrence mimicking a submucosal tumor (Table 4, Fig. 2).

Discussion

In this matched case-control study comparing ESD with EMR, ESD achieved a high en bloc resection rate and a low recurrence rate in the short term. Although the complication rate was higher in the ESD group, all of the complications were manageable conservatively.

Before the introduction of ESD, conventional EMR was the only endoscopic treatment for early-stage colorectal tumors,^{3,4} and surgery was also performed for large lesions or lesions with a positive non-lifting sign because of the technical difficulty involved.¹³ EMR for large lesions sometimes resulted in piecemeal resection, and this led to a high rate of local recurrence.^{5–7} For lesions measuring ≥ 20 mm, the rates of local recurrence have been reported to range from 7.7% to 21.9%, and from 25% to 50%

Table 3 Description of three perforated cases

No.	Age/gender	Tumor size (mm)	Location	Macroscopic type	Treatment for perforation	Hospitalization stay (day)
1	71/M	40	Ascending	Ila (LST-NG)	Endoscopic closure by endoclips	13
2	67/F	30	Sigmoid	Ila (LST-NG)	Endoscopic closure by endoclips and endoloop	17
3	57/M	30	Ascending	Ila + IIc (LST-NG)	Endoscopic closure by endoclips	9

LST-NG, laterally spreading tumor non-granular type.

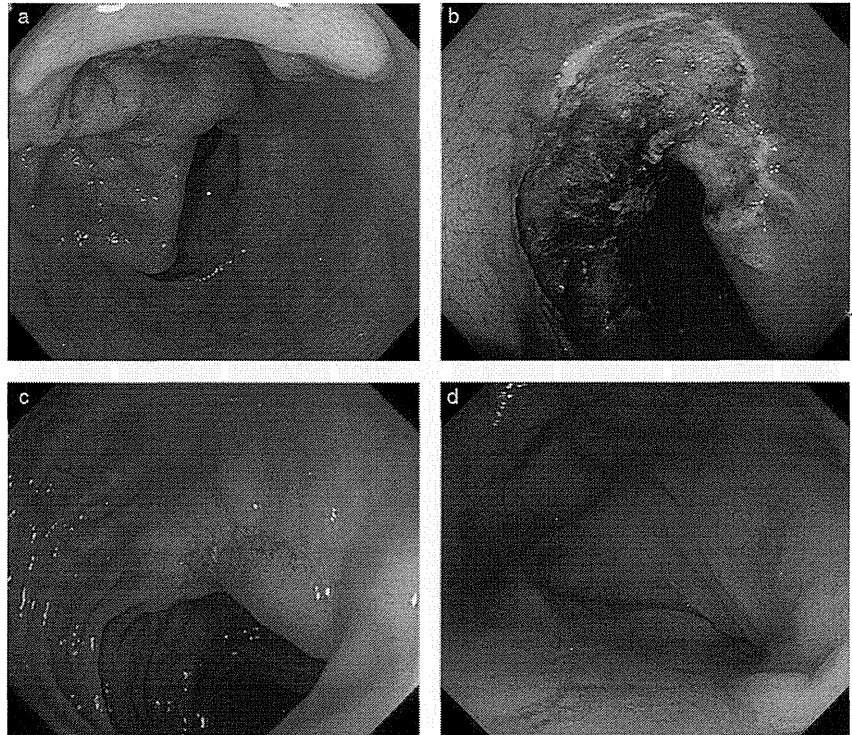


Figure 2 (a) Large laterally spreading tumor non-granular type (LST-NG) lesion was located in the sigmoid colon. (b) Piecemeal resection was performed. (c) First follow-up colonoscopy after 6 months revealed local recurrence, and salvage endoscopic mucosal resection (EMR) was performed. (d) Third follow-up colonoscopy was performed at 19 months after initial EMR and revealed intramural recurrence mimicking submucosal tumor.

for cases resected piecemeal.^{18–20} In the present study, there were 12 cases (21.4%) of local recurrence in the EMR group, and all except one were resected piecemeal. Therefore our data accorded with these previous reports.

On the other hand, the en bloc resection rate achieved by ESD has been reported to be extremely high, ranging from 80.0% to 98.4%, and no case of local recurrence has been reported in ESD cases for which en bloc resection was achieved.^{8–11} Therefore, local recurrence in ESD cases is rare, with a maximum rate of 2%.²¹ In this study, no local recurrence was observed in the ESD group, and ESD was proved to be an effective treatment for colorectal tumors in terms of curability.

Saito *et al.* reported the first comparison between colorectal ESD and EMR including a mid-term follow-up.²¹ The authors assessed large samples of 145 ESD and 228 EMR cases, and concluded that ESD achieved higher rates of en bloc resection and curative resection than EMR. Although their study was not randomized or matched, they also suggested that ESD was superior in terms of outcome, despite its longer procedure time and higher perforation rate.

With regard to complications, the perforation rate was significantly higher in the ESD group. However, the need for urgent surgery because of unsuccessful endoscopic closure is reportedly low, most cases of perforation being manageable conservatively with endoscopic closure using endoclips.^{22,23} All three cases of perforation in the present series were also treated endoscopically and the patients recovered with conservative management, with a mean 8-day extension of hospitalization. In addition, although we matched the size and histopathology of the lesions to minimize the difference of the target lesions in each group, macroscopic type could not be adjusted. The incidence of LST-NG was significantly higher in the ESD group and we previously reported that 20% of LST-NG required surgical treatment before the introduction of ESD due to technical difficulty with EMR.¹³ This means that the target lesions for ESD were more difficult to remove endoscopically in comparison with those for EMR, and therefore the higher perforation rate associated with ESD was perhaps not surprising. Although examination of the long-term outcomes of cases in which perforation occurs will be needed in order to clarify the validity of this strategy, we consider that the perforation rate

Table 4 Description of 12 recurrent cases

No.	Age/ gender	Tumor size (mm)	Location	Macroscopic type	Histology of primary lesion	No. resected specimens	Duration of recurrence detection (day)	No. colonoscopy for recurrence detection	Additional treatment	Histology of recurrent lesion
1	57/F	20	Transversers	Ila (LST-NG)	M-Ca	Multiple	51	1	Endoscopic resection	Adenoma
2	73/M	20	Rectum	Ila (LST-G)	M-Ca	Multiple	1498	4	Endoscopic resection	M-Ca
3	81/M	35	Sigmoid	Isp	SM-Ca	En bloc	234	1	Endoscopic resection	Adenoma
4	61/F	30	Sigmoid	Is + Ila (LST-G)	M-Ca	Multiple	114	1	Endoscopic resection	Adenoma
5	66/F	40	Ascending	Ila (LST-NG)	Adenoma	Multiple	196	1	Endoscopic resection	Adenoma
6	64/F	25	Ascending	Ila (LST-G)	SM-Ca	Multiple	378	2	Endoscopic resection	Adenoma
7	70/M	25	Rectum	Is + Ila (LST-G)	Adenoma	Multiple	185	1	Endoscopic resection	Adenoma
8	66/M	20	Transverse	Ila (LST-NG)	M-Ca	Multiple	271	1	Endoscopic resection	M-Ca
9	55/M	35	Ascending	Is + Ila (LST-G)	M-Ca	Multiple	446	1	Endoscopic resection	Adenoma
10	64/M	35	Transverse	Ila (LST-G)	Adenoma	Multiple	621	1	Endoscopic resection	Adenoma
11	76/M	40	Sigmoid	Ila (LST-NG)	SM-Ca	Multiple	166	1	Surgical resection	Invasive cancer
12	37/M	40	Rectum	Is + Ila (LST-G)	Adenoma	Multiple	241	1	Endoscopic resection	M-Ca

LST-G, laterally spreading tumor granular type; LST-NG, laterally spreading tumor non-granular type; M-Ca, intramucosal cancer; SM-Ca, submucosal cancer.

associated with ESD and the feasibility of conservative management is acceptable.

We usually recommend that initial follow-up colonoscopy be performed at 6–12 months after endoscopic treatment for en bloc resection cases and at 3–6 months for those resected piecemeal. Although the durations of follow-up colonoscopy varied in this series because of its retrospective design, all of the 12 recurrent lesions except one were detected and removed endoscopically with appropriate timing. The case requiring surgical resection involved intramural recurrence, even though the follow-up interval had been adequate. In this case, follow-up colonoscopy examinations at 6 and 12 months after piecemeal resection detected recurrent lesions, and these were removed endoscopically on both occasions. However, at 19 months after EMR, intramural recurrence mimicking a submucosal tumor was observed, and this required surgery. Although such cases may be rare, they should be borne in mind, especially when piecemeal resection has to be performed.

This study had some limitations. First, because it was a retrospective cohort study based on historical controls treated during a different period, lead-time and selection biases may have occurred. Therefore, we used a matching method to minimize such influences. Second, despite the usage of matching method, polyp characteristics in two groups still differed in terms of macroscopic type and presence or absence of non-lifting sign. These factors could affect the results of treatment. Third, a quarter of eligible ESD cases at our institution were excluded because of a lack of follow-up data. These cases were followed up at other hospitals, or follow-up colonoscopy had not been performed. Fourth, the number of patients included in this study and the duration of follow-up were limited. Finally, we were unable to assess the cost effectiveness of the two procedures. Although ESD devices are more expensive, the cost of additional treatment for recurrent cases should be considered as the total cost of EMR. A further study to prospectively assess the long-term outcome and cost effectiveness of ESD will be necessary in order to overcome these limitations.

In conclusion, this matched case-control study has shown that ESD achieves a higher en bloc resection rate than EMR. Although the procedure time will need to be shortened and the rate of perforation reduced, all of the perforation cases were manageable conservatively by endoscopic closure with endoclips. In addition, no local recurrence was detected in the ESD group, whereas piecemeal resection in the EMR group led to a high rate of local recurrence, and one case that recurred as invasive cancer required surgical resection. The results of our retrospective study suggest that ESD can be a promising technique for the treatment of colorectal tumors, offering an excellent outcome in comparison with EMR.

Acknowledgments

This work was supported in part by a Grant-in-aid for Cancer Research (21S-2) from the Ministry of Health, Labour and Welfare.

References

- 1 Hosokawa K, Yoshida S. Recent advances in endoscopic mucosal resection for early gastric cancer. *Gan to Kagaku Ryoho* 1998; **25**: 476–83.

- 2 Gotoda T, Kondo H, Ono H *et al.* A new endoscopic resection procedure using an insulation-tipped electrosurgical knife for rectal flat lesions: report of two cases. *Gastrointest. Endosc.* 1999; **50**: 560–3.
- 3 Deyle P, Largiader F, Jenny S *et al.* A method for endoscopic electroresection of sessile colonic polyp. *Endoscopy* 1973; **5**: 38–40.
- 4 Kudo S. Endoscopic mucosal resection of flat and depressed type of early colorectal cancer. *Endoscopy* 1993; **25**: 455–61.
- 5 Tamura S, Nakajo K, Yokoyama Y *et al.* Evaluation of endoscopic mucosal resection for laterally spreading rectal tumors. *Endoscopy* 2004; **36**: 306–12.
- 6 Saito Y, Fujii T, Kondo H *et al.* Endoscopic treatment for laterally spreading tumors in the colon. *Endoscopy* 2001; **33**: 682–6.
- 7 Hurlstone DP, Cross SS, Brown S *et al.* A prospective evaluation of high-magnification chromoscopic colonoscopy in predicting completeness of EMR. *Gastrointest. Endosc.* 2004; **59**: 642–50.
- 8 Saito Y, Uraoka T, Matsuda T *et al.* Endoscopic treatment of large superficial colorectal tumors: a case series of 200 endoscopic submucosal dissections (with video). *Gastrointest. Endosc.* 2007; **66**: 966–73.
- 9 Tanaka S, Oka S, Kaneko I *et al.* Endoscopic submucosal dissection for colorectal neoplasia: possibility of standardization. *Gastrointest. Endosc.* 2007; **66**: 100–7.
- 10 Fujishiro M, Yahagi N, Kakushima N *et al.* Outcomes of endoscopic submucosal dissection for colorectal epithelial neoplasms in 200 consecutive cases. *Clin. Gastroenterol. Hepatol.* 2007; **5**: 678–83.
- 11 Tamegai Y, Saito Y, Masaki N *et al.* Endoscopic submucosal dissection: a safe technique for colorectal tumors. *Endoscopy* 2007; **39**: 418–22.
- 12 Yamamoto H, Kawata H, Sunada K *et al.* Successful en-bloc resection of large superficial tumors in the stomach and colon using sodium hyaluronate and small-caliber-tip transparent hood. *Endoscopy* 2003; **35**: 690–4.
- 13 Kobayashi N, Saito Y, Uraoka T *et al.* Treatment strategy for laterally spreading tumors in Japan: before and after the introduction of endoscopic submucosal dissection. *J. Gastroenterol. Hepatol.* 2009; **24**: 1387–92.
- 14 Uraoka T, Saito Y, Matsuda T *et al.* Endoscopic indications for endoscopic mucosal resection of laterally spreading tumours in the colorectum. *Gut* 2006; **55**: 1592–97.
- 15 Kitajima K, Fujimori T, Fujii S *et al.* Correlations between lymph node metastasis and depth of submucosal invasion in submucosal invasive colorectal carcinoma: a Japanese collaborative study. *J. Gastroenterol.* 2004; **39**: 534–43.
- 16 Saito Y, Uraoka T, Matsuda T *et al.* A pilot study to assess safety and efficacy of carbon dioxide insufflation during colorectal endoscopic submucosal dissection under conscious sedation. *Gastrointest. Endosc.* 2007; **65**: 537–42.
- 17 Japanese Research Society for Cancer of the Colon and Rectum. *General Rules for Clinical and Pathological Studies on Cancer of the Colon, Rectum and Anus: Histopathological Classification*, 6th edn. Tokyo: Kanehara Syuppan, 1998; 60–90.
- 18 Conio M, Repici A, Demarquay JF *et al.* EMR of large sessile colorectal polyps. *Colorectal Dis.* 2006; **8**: 497–500.
- 19 Hotta K, Fujii T, Saito Y *et al.* Local recurrence after endoscopic resection of colorectal tumors. *Int. J. Colorectal Dis.* 2009; **24**: 225–30.
- 20 Tanaka S, Haruma K, Oka S *et al.* Clinicopathologic features and endoscopic treatment of superficially spreading colorectal neoplasms larger than 20 mm. *Gastrointest. Endosc.* 2001; **54**: 62–6.
- 21 Saito Y, Fukuzawa M, Matsuda T *et al.* Clinical outcome of endoscopic submucosal dissection versus endoscopic mucosal resection of large colorectal tumors as determined by curative resection. *Surg. Endosc.* 2010; **24**: 343–52.
- 22 Taku K, Sano Y, Fu KI *et al.* Iatrogenic perforation associated with therapeutic colonoscopy: a multicenter study in Japan. *J. Gastroenterol. Hepatol.* 2007; **22**: 1409–14.
- 23 Fujishiro M, Yahagi N, Kakushima N *et al.* Successful nonsurgical management of perforation complicating endoscopic submucosal dissection of gastrointestinal epithelial neoplasms. *Endoscopy* 2006; **38**: 1001–6.

New closure technique for large mucosal defects after endoscopic submucosal dissection of colorectal tumors (with video)

Yosuke Otake, MD,¹ Yutaka Saito, MD, PhD,¹ Taku Sakamoto, MD, PhD,¹ Takaya Aoki, MD,¹ Takeshi Nakajima, MD, PhD,¹ Naoya Toyoshima, MD,¹ Takahisa Matsuda, MD, PhD,¹ Hiroyuki Ono, MD, PhD²

Tokyo, Japan

Background: Certain large colorectal tumors satisfy expanded indications for endoscopic submucosal dissection (ESD); however, the resulting large mucosal defects may contribute to complications such as delayed bleeding and perforation. Various closure devices and methods have been developed for large mucosal defects to prevent such complications.

Objective: To demonstrate the feasibility of a new and simple technique for closing large mucosal defects after colorectal ESD.

Design: Pilot feasibility study.

Setting: Single center.

Patients: Ten patients with 10 tumors half circumferential or less in size with sufficient muscle layer exposure after ESD were selected and treated by using the closure technique between July 2009 and June 2010.

Intervention: Small mucosal incisions were made around the mucosal defect by the same needle-knife used during ESD. These incisions provided a better grip for conventional clips, which then facilitated lifting the surrounding mucosa across the defect without slipping, thereby making it considerably easier to reduce the size of the defect and place additional clips.

Main Outcome Measurements: Patient characteristics and tumor clinicopathologic features were assessed as well as closure completion rate, closure procedure time, and closure-related complications.

Results: All 10 tumors were successfully treated by ESD. Mean lesion size was 26.8 mm (range 8-50 mm). All mucosal defects were completely closed by using the new closure technique, without complications. Mean closure procedure time was 15 minutes (range 8-35 minutes).

Limitations: Small sample size with specifically selected patients.

Conclusion: Large mucosal defects resulting from colorectal ESD can be completely closed with small mucosal incisions by using conventional clips.

Endoscopic submucosal dissection (ESD) is now accepted as an effective endoscopic treatment for colorectal neoplasms. ESD can result in en bloc resection of larger lesions,¹⁻⁴ so certain large colorectal laterally spreading tu-

mors (LSTs) satisfy expanded indications for endoscopic treatment.⁵ Various treatment strategies have been developed for each LST subtype, based on size, morphology, and histopathology.⁶⁻¹⁰

Abbreviations: ESD, endoscopic submucosal dissection; LST, laterally spreading tumor.

DISCLOSURE: Y. Saito received funding support from the Japanese Foundation for Research and Promotion of Endoscopy. No other financial relationships relevant to this publication were disclosed.

Copyright © 2012 by the American Society for Gastrointestinal Endoscopy 0016-5107/\$36.00
doi:10.1016/j.gie.2011.10.037

Received July 21, 2011. Accepted October 26, 2011.

Current affiliations: Endoscopy Division (1), National Cancer Center Hospital, Tokyo, Department of Endoscopy and Gastrointestinal Oncology (2), Shizuoka Cancer Center Hospital, Shizuoka, Japan.

Reprint requests: Yutaka Saito, MD, PhD, Chief Endoscopy Division, National Cancer Center Hospital, 5-1-1 Tsukiji, Chuo-ku, Tokyo, 104-0045, Japan.

If you would like to chat with an author of this article, you may contact Dr Saito at ytsaito@ncc.go.jp.

Although ESD is considered an acceptable treatment method in Japan,⁶ resulting large mucosal defects may contribute to complications including delayed bleeding and perforation. Various closure devices and methods have been reported,¹¹⁻¹³ but they involve greater technical difficulty, so we wanted to develop a simpler and easier closure technique. Our idea was inspired by Ono's closure technique for gastric perforation during ESD (unpublished data; H.O. 2007). We describe herein a simplified technique that uses small mucosal incisions and report the results of a pilot study demonstrating its feasibility.

METHODS

Study protocol was approved by our institutional review board, and 98 patients were recruited who provided informed written consent and had large colorectal tumors treated by ESD between July 2009 and June 2010. We specifically excluded patients who had colorectal tumors that were more than half circumferential and then prospectively selected only those 10 patients with sufficient muscle layer exposure after ESD. Closure completion rate, closure procedure time, and closure-related complications were evaluated, including patient reactions such as abdominal pain and increases in white blood cell count, C-reactive protein levels, and body temperature.

The closure technique, which uses conventional clips (EZ Clip; Olympus Co Tokyo, Japan), is quite simple (Fig. 1). First, small incisions 2 to 3 mm in length were made from the mucosa to the muscularis mucosae around the mucosal defect with the same bipolar needle-knife (B-knife; Zeon Medical Co, Tokyo, Japan) and electro-surgical unit (ICC 200; Erbe Elektromedizin, Tübingen, Germany) in the 50-W Endocut mode used during ESD. The number of incisions depended on the size of the mucosal defect. At least 3 incisions were placed on both the oral and anal sides of the defect, with approximately 1 cm between incisions. This provided a better grip for the clip, which could then be lifted easily across the defect without slipping, thereby making it easier to reduce the size of the defect and place additional clips as necessary (Fig. 2).

Although each case was evaluated individually, we recommend closure starting from the verge and proceeding to the center of the mucosal defect because it usually is easier. We normally used a 0.4% sodium hyaluronate acid solution for submucosal injection during colorectal ESDs, and the resultant long-lasting cushion may have made our closure technique easier and safer. We considered it unnecessary to use additional submucosal injection solution before performing the closure technique, but such injection may be advisable in certain circumstances.

RESULTS

Ten patients (6 men/4 women) with a mean age of 66.8 years (range 58-84 years), having a total of 10 colorectal

Take-home Message

- Large mucosal defects resulting from endoscopic submucosal dissection of large colorectal tumors may contribute to complications such as delayed bleeding and perforation.
- The authors have developed a novel closure technique for such large mucosal defects that is simpler and easier than previously reported closure methods and can be performed with conventional instruments and devices.

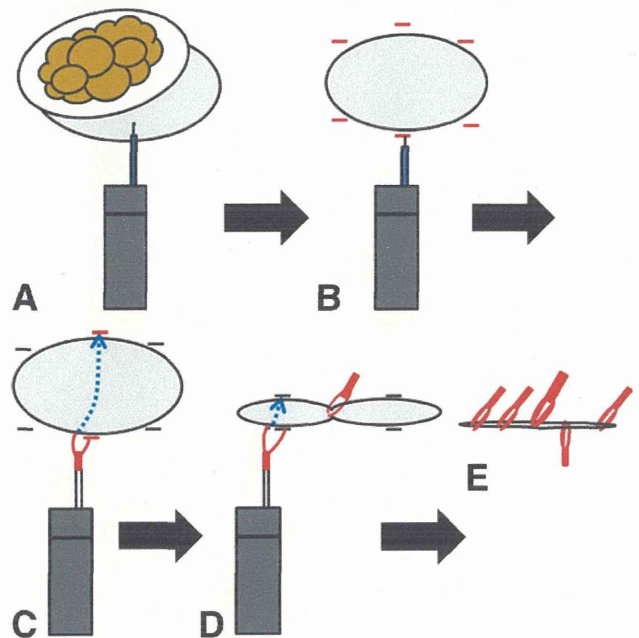


Figure 1. Diagram of an endoscopic closure technique for a large mucosal defect by using small incisions and conventional clips. **A**, Completion of colorectal endoscopic submucosal dissection by using a bipolar knife (B-knife; Zeon Medical Co, Tokyo, Japan). **B**, Small incisions (red) of 2 to 3 mm were made completely around the mucosal defect by using the same bipolar knife. **C**, The first open conventional clip (red) attached at the center anal incision (red), lifted across the mucosal defect (blue dotted line and arrow), and attached at the center oral incision (red). **D**, The second open clip (red) attached and lifted at the anal incision (blue dotted line with arrow) and attached at the oral incision to further reduce the size of the mucosal defect. **E**, Complete closure of the mucosal defect achieved by using conventional clips (red).

tumors, underwent this closure technique after ESD. Mean tumor size was 26.8 mm (range 8-50 mm). All 10 lesions successfully resulted in en bloc resections without complications. Patient characteristics and tumor clinicopathologic features are summarized in Table 1. The simplified closure technique was successfully completed in all 10 cases without any closure-related complications. On average, 6.8 small incisions were placed around each mucosal defect by using an average of 8.1 conventional clips. Mean closure procedure time was 15 minutes (range 8-35 minutes) (Table 2). No delayed complications such as bleed-

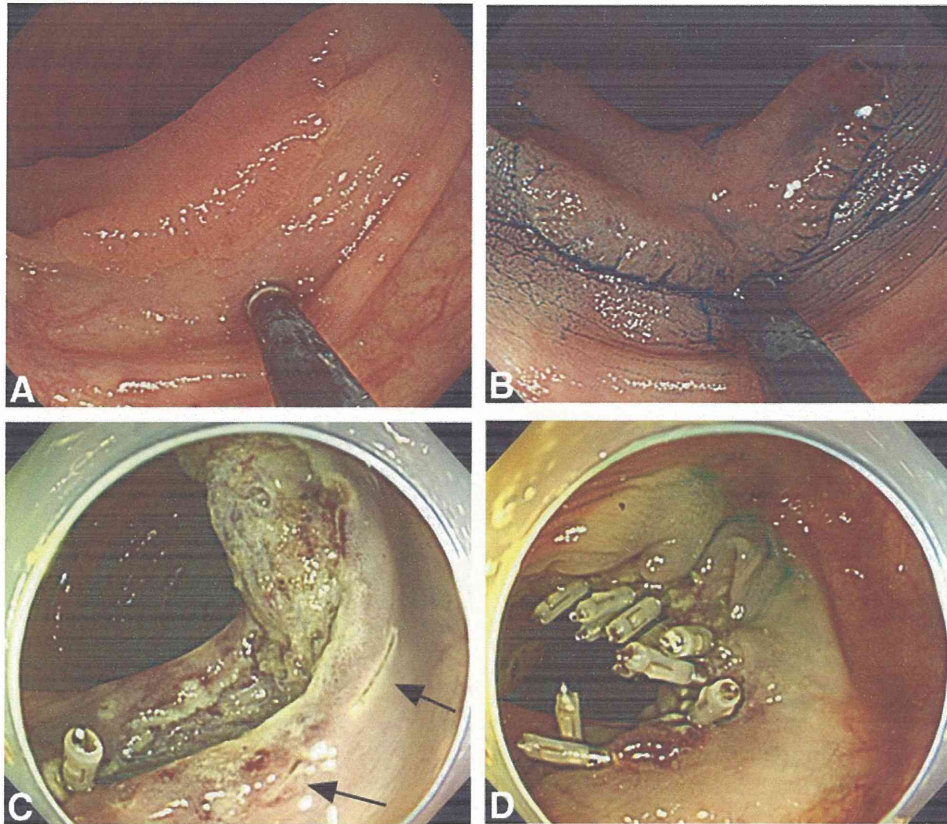


Figure 2. ESD of a large colorectal tumor resulting in a large mucosal defect. **A**, A large nongranular type laterally spreading tumor measuring 30 mm in diameter located in the ascending colon and treated by ESD. **B**, Lesion margins delineated by using a 0.4% indigo-carmin dye spray. **C**, A large mucosal defect resulted from ESD, so small mucosal incisions of 2 to 3 mm in length were made with a bipolar needle-knife completely around the defect as indicated by arrows. **D**, Complete closure was successfully performed for a large mucosal defect by using conventional clips. Video 1 shows ESD and the closure technique briefly (Video available online at www.giejournal.org). ESD, endoscopic submucosal dissection.

ing or perforation occurred postoperatively. Mean white blood cell count recorded the first day after ESD was $7260/\text{mm}^3$ ($3900\text{--}10,000/\text{mm}^3$) (normal $3900\text{--}6300/\text{mm}^3$), and the mean C-reactive protein level was 0.4 mg/dL ($0.04\text{--}1.4$ mg/dL) (normal $0\text{--}0.1$ mg/dL) (Table 3). Body temperature readings were regularly recorded for all patients during hospitalization, and none of the 10 patients developed a serious fever. All 10 patients were administered oral intake 1 day after ESD and were hospitalized for 4 days, both figures representing 1 day less than for typical colorectal ESD patients.

DISCUSSION

We successfully demonstrated our simplified technique for closure of large mucosal defects after colorectal ESDs by using small incisions around the defect, without complications.

ESD for treating early gastric cancer was developed in Japan in the 1990s,^{14,15} and a similar treatment for colorectal tumors is now accepted in Japan based on our previously reported multicenter evaluation of over 1111 colorectal ESDs.³ The term *laterally spreading tumor* was

proposed by Kudo for colorectal neoplasms that tend to grow laterally but are unlikely to involve deep invasion, and this tumor type is now a well-accepted designation among colorectal tumors.⁵ Treatment strategy today for such lesions (ie, the necessity of en bloc resection) is based on the precise subtype identified by pathologic evaluation. En bloc resection is considered necessary for granular type LSTs with large nodules as well as the nongranular type.⁷⁻⁸ ESD is the recommended method for en bloc resection of such lesions >20 mm in size.

Although rare, delayed complications such as bleeding and perforation can occur at the site of mucosal defects after endoscopic resection of colorectal tumors. Saito et al³ reported that the delayed bleeding rate in colorectal ESD cases was 1.5% (17/1111), whereas the delayed perforation rate was 0.4% (4/1111). Among other recently determined causes, such complications are considered to be caused by transmural electrocautery injury and larger resection size.¹⁶⁻¹⁷ In addition, residual tumors can appear after piecemeal EMR, necessitating further endoscopic treatment that is more difficult because the residual tumor is often buried beneath scar tissue.^{1,18} The incidence of residual tumors after ESD, however, is low because of en

TABLE 1. Patient characteristics and tumor clinicopathologic features

Characteristic	Value
Patient	
Age, mean (range), y	66.8 (58-84)
Sex, male/female	6/4
Tumor	
Size, mean (range), mm	26.8 (8-50)
Location, no.	
Cecum	1
Ascending colon	2
Transverse colon	3
Upper rectum	2
Lower rectum	2
Macroscopic type, no.	
Granular type laterally spreading	3
Nongranular type laterally spreading	4
Recurrent tumor	3
Pathology, no.	
Low-grade adenoma	1
Noninvasive cancer	9

TABLE 2. Closure technique results

Technique	Result
Closure completion rate, no. (%)	10/10 (100)
Closure procedure time, mean (range), min	15 (8-35)
Small incisions, no. (range)	6.8 (6-8)
Clips, no. (range)	8.1 (5-12)
Complications, no. (%)	
Perforation	0/10 (0)
Bleeding	0/10 (0)

TABLE 3. Patient responses and measurements

Finding	Value
Abdominal pain, no. (%)	0/10 (0)
White blood cell count, mean (range)	7260/mm ³ (3900-10,000/mm ³)
C-reactive protein level, mean (range)	0.4 mg/dL (0.04-1.4 mg/dL)
Maximum body temperature, mean (range)	36.8°C (35.8-37.6°C)

tific, Natick, Mass) that could be closed and released as necessary before final attachment. Sakamoto et al¹³ developed a loop clip consisting of a metallic clip attached to a nylon string loop for complete closure without using a 2-channel colonoscope. All 3 techniques are rather complex and require specially designed devices. In contrast, our closure technique is simple and uses conventional devices/methods. We simply make mucosal incisions with the same bipolar needle-knife used during ESD, usually without additional submucosal injection. In all 10 cases, complete closure of the mucosal defect was successfully performed without complications. Although not indicated in previous closure technique reports, our mean closure time was 15 minutes, which we regard as reasonable.

In summary, we demonstrated the feasibility of a simplified technique that uses small mucosal incisions for closure of large mucosal defects after colorectal ESD. This technique has the potential of reducing hospitalization for some ESD patients, thereby facilitating possible single-day treatment. Small patient sample size and the fact that the 10 participating patients were specifically selected certainly are limiting factors. We believe the promising results, however, warrant further evaluation in prospective studies involving larger numbers of patients.

Conclusion

Large mucosal defects resulting from colorectal ESDs were successfully closed by using small mucosal incisions and conventional clips within a reasonably short procedure time with the added potential benefit of a reduction in delayed complications.

REFERENCES

1. Saito Y, Fukuzawa M, Matsuda T, et al. Clinical outcome of endoscopic submucosal dissection versus endoscopic mucosal resection of large colorectal tumors as determined by curative resection. *Surg Endosc* 2010;24:343-52.
2. Isomoto H, Nishiyama H, Yamaguchi N, et al. Clinicopathological factors associated with clinical outcomes of endoscopic submucosal dissection for colorectal epithelial neoplasms. *Endoscopy* 2009;41:679-83.

bloc resection¹; therefore, complete closure of mucosal defects is considered reasonable and useful in ESD cases.

Three reports have been published describing techniques for closure of mucosal defects after endoscopic treatment of colorectal tumors. Matsuda et al¹¹ described complete closure by using a 2-channel colonoscope, an endoloop snare, and a conventional metallic clip. Fujii et al¹² used an 8 ring (small metallic figure 8-shaped ring) and a special clip (Resolution Clip Device; Boston Scien-

3. Saito Y, Uraoka T, Yamaguchi Y, et al. A prospective, multicenter study of 1111 colorectal endoscopic submucosal dissections (with video). *Gastrointest Endosc* 2010;72:1217-25.
4. Niimi K, Fujishiro M, Kodashima S, et al. Long-term outcomes of endoscopic submucosal dissection for colorectal epithelial neoplasms. *Endoscopy* 2010;42:723-9.
5. Kudo S. Endoscopic mucosal resection of flat and depressed types of early colorectal cancer. *Endoscopy* 1993;25:455-61.
6. Saito Y, Fujii T, Kondo H, et al. Endoscopic treatment for laterally spreading tumors in the colon. *Endoscopy* 2001;33:682-6.
7. Uraoka T, Saito Y, Matsuda T, et al. Endoscopic indications for endoscopic mucosal resection of laterally spreading tumours in the colorectum. *Gut* 2006;55:1592-7.
8. Oka S, Tanaka S, Kanao H, et al. Therapeutic strategy for colorectal laterally spreading tumor. *Dig Endosc* 2009;(21 suppl 1):S43-6.
9. Huang Y, Liu S, Gong W, et al. Clinicopathologic features and endoscopic mucosal resection of laterally spreading tumors: experience from China. *Int J Colorectal Dis* 2009;24:1441-50.
10. Kobayashi N, Saito Y, Uraoka T, et al. Treatment strategy for laterally spreading tumors in Japan: before and after the introduction of endoscopic submucosal dissection. *J Gastroenterol Hepatol* 2009;24:1387-92.
11. Matsuda T, Fujii T, Emura F, et al. Complete closure of a large defect after EMR of a lateral spreading colorectal tumor when using a two-channel colonoscope. *Gastrointest Endosc* 2004;60:836-8.
12. Fujii T, Ono A, Fu KI. A novel endoscopic suturing technique using a specially designed so-called "8-ring" in combination with resolution clips (with videos). *Gastrointest Endosc* 2007;66:1215-20.
13. Sakamoto N, Beppu K, Matsumoto K, et al. "Loop Clip," a new closure device for large mucosal defects after EMR and ESD. *Endoscopy* 2008;(40 suppl 2):E97-8.
14. Ono H, Kondo H, Gotoda T, et al. Endoscopic mucosal resection for treatment of early gastric cancer. *Gut* 2001;48:225-9.
15. Gotoda T, Yamamoto H, Soetikno RM. Endoscopic submucosal dissection of early gastric cancer. *J Gastroenterol* 2006;41:929-42.
16. Anderson ML, Pasha TM, Leighton JA. Endoscopic perforation of the colon: lessons from a 10-year study. *Am J Gastroenterol* 2000;95:3418-22.
17. Onogi F, Araki H, Ibuka T, et al. "Transmural air leak": a computed tomographic finding following endoscopic submucosal dissection of gastric tumors. *Endoscopy* 2010;42:441-7.
18. Hotta K, Fujii T, Saito Y, et al. Local recurrence after endoscopic resection of colorectal tumors. *Int J Colorectal Dis* 2009;24:225-30.

Availability of Journal back issues

As a service to our subscribers, copies of back issues of *Gastrointestinal Endoscopy* for the preceding 5 years are maintained and are available for purchase from Elsevier until inventory is depleted. Please write to Elsevier Inc., Subscription Customer Service, 3251 Riverport Lane, Maryland Heights, MO 63043 or call 800-654-2452 or 314-447-8871 for information on availability of particular issues and prices.

Predictive factors of local recurrence after endoscopic piecemeal mucosal resection

Taku Sakamoto · Takahisa Matsuda ·
Yosuke Otake · Takeshi Nakajima ·
Yutaka Saito

Received: 21 September 2011 / Accepted: 30 November 2011 / Published online: 6 January 2012
© Springer 2011

Abstract

Background Endoscopic piecemeal mucosal resection (EPMR) is a widely accepted treatment for colorectal tumefaction. However, as it is associated with a significant recurrence rate, the technique remains controversial. The purpose of our study was to evaluate the risk factors for the local recurrence of colorectal neoplasms after EPMR.

Methods The study population of our retrospective evaluation comprised 222 patients who had undergone EPMR from January 2002 to July 2007 and who had had at least 1 surveillance colonoscopy 3–6 months after the initial treatment.

Results Local recurrence was detected in 42 patients (19%) between 6 and 15 months after EPMR. Our multivariate analysis revealed that the resection of 5 or more neoplasm specimens, compared with fewer than 5, was 3 times more likely to result in local recurrence ($P = 0.005$). No statistically significant correlation of local recurrence with lesion size, location, macroscopic type, or histology was detected.

Conclusion The removal of 5 or more neoplasm specimens is an independent risk factor for local recurrence after EPMR. Careful colonoscopic surveillance should be performed after multiple piecemeal resection.

Keywords Colorectal neoplasm · Endoscopic piecemeal mucosal resection (EPMR) · Local recurrence · Retrospective analysis

Introduction

The introduction of endoscopic submucosal dissection (ESD), enabling the en-bloc resection of large lesions, has recently diversified the strategy of endoscopic treatment for colorectal neoplasms [1–3]. However, its technical difficulty and a high complication rate preclude the standardization of this novel procedure [2, 3]. Conventional endoscopic mucosal resection (EMR), including piecemeal resection, remains, therefore, the most widely acknowledged general treatment for colorectal tumors [4–6].

Nevertheless, endoscopic piecemeal mucosal resection (EPMR) is not free of controversy, as it is associated with a high incidence of local recurrence or residual lesions, and it entails intensive colonoscopic surveillance, with recommendations of repeated examination at 3–6 months [7–10]. We previously reported that the recurrent or residual lesions did not show increased levels of histological atypia; they were mainly recognized as adenomas, even when the patients had been initially diagnosed with intramucosal carcinoma [11]. Thus, the efficacy of EPMR for certain types of lesions was confirmed. As regards the post-EPMR colonoscopic surveillance, reducing the number of recommended examinations, resulting in improved patient compliance, is highly desirable, and could be facilitated by the systematized stratification of risk factors for locally recurring or residual lesions. Unfortunately, very few studies have provided detailed long-term follow-up analyses of relevance.

Herein, we describe post-EPMR clinical outcomes and evaluate the risks of local recurrence in search of therapeutically relevant predictive factors.

T. Sakamoto (✉) · T. Matsuda · Y. Otake ·
T. Nakajima · Y. Saito
Endoscopy Division, National Cancer Center Hospital,
5-1-1 Tsukiji, Chuo-ku, Tokyo, Japan
e-mail: tasakamo@ncc.go.jp

Methods

All patients who had undergone EPMR from January 2002 to July 2007 and who had had at least 1 surveillance colonoscopy 3–6 months after the initial resection at the National Cancer Center Hospital (NCCH), Tokyo, were considered for inclusion in this retrospective study. The patients were identified by reviewing the endoscopic database at our division. The study was conducted in accordance with the guidelines of our institutional review board, who approved it without the need for the subjects' informed consent; however, all of the patients had provided written informed consent for the colonoscopy and endoscopic treatment.

A total of 311 lesions in 292 patients were removed by EPMR in the analyzed period. Exclusion criteria included the following: familial adenomatous polyposis, ulcerative colitis, no surveillance after the initial resection, and inability to verify the treatment site on surveillance colonoscopy. Patients who were diagnosed with invasive cancer (implying increased odds of lymph node metastasis), who underwent additional surgical resection, were also excluded. Finally, 222 lesions in 222 patients were eligible for consideration in this study (Fig. 1).

Endoscopic procedure and follow-up

All endoscopic procedures were performed by staff doctors or senior residents of NCCH with endoscopic experience involving approximately 500 colonoscopies with conventional EMR. Olympus video-endoscopes (PCF-Q240Z, CF-H260AZI; Olympus, Tokyo, Japan) were used in all procedures. Once the lesion was identified, further characterization was performed by pit pattern analysis using magnifying chromoendoscopy in all cases. Patients with lesions displaying non-invasive patterns underwent endoscopic treatment. The EPMR technique applied was based on a well-recognized general method using a Spiral Snare (20 mm), and/or Snare Master (10, 25 mm) (Olympus).

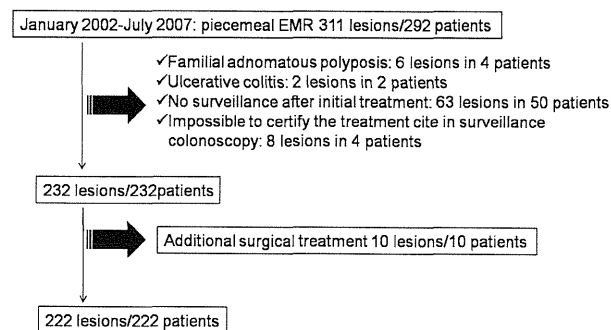


Fig. 1 Flowchart showing the inclusion of cases in the present study. EMR endoscopic mucosal resection

The electric current used for resection was set to endocut mode (effect 3, output: 120 W) or forced coagulation mode with 50- output (ICC-200; ERBE, Tuebingen, Germany). Submucosal injection using normal saline or glycerol combined with a small amount of 0.2% indigocarmine was used in all cases to lift the lesions. After resection with the snares, coagulation, using hot biopsy forceps, was also performed if there was a suspicion of small residual tumors in the resection plane.

The first follow-up colonoscopy was performed 3–6 months after the initial resection in all patients, and the second, after 1 year. Upon the detection of recurrent or residual tumors, a second round of surveillance colonoscopy was performed 6 months after the first one, with additional endoscopic treatment.

Pathological evaluation

All collected specimens were fixed in 10% formalin and cut into 2-mm slices. Microscopic evaluation of histological type, depth of invasion, lymphovascular invasion, and cut margins was analyzed.

Statistical analysis

Data were entered manually and statistically assessed using STATA version 10.0 (StataCorp, College Station, TX, USA). The odds ratios (ORs) and 95% confidence intervals (95% CI) were evaluated at each setting of the categorical variable for the predictors of recurrence, including size of lesion, site of polyp, number of resected specimens, morphological type, and histology (adenoma or carcinoma); multivariate logistic regression was completed to assess the associations between the factors. A two-tailed *P* value below 0.05 was considered statistically significant. To categorize the lesions for statistical analysis, their locations in the colon and the rectum were considered, with regard to the technical difficulty of resection. The cut-off lesion size was determined by median size, and the number of resected specimens was categorized as ≥ 5 or < 5 . The morphological appearance of polyps was reclassified as per the updated Paris classification of superficial neoplastic lesions in the digestive tract [12], and we divided all lesions into polypoid or non-polypoid groups. In the Paris classification, 0-Is + IIa, granular-type laterally spreading tumors, are categorized as non-polypoid. However, endoscopic resection for simple protruded lesions (0-Is, Isp, and Is + IIa) is generally considered to be easier than that for the flat elevated and depressed lesion types (0-IIa, IIa + IIc, IIc). Considering the endoscopic difficulty, in this study we categorized Is + IIa as polypoid type for descriptive purposes.

Results

The clinical and pathological features of the study cohort are summarized in Table 1. Of the 222 patients, 138 (62%) were male, and the mean age was 66 years. Forty-eight lesions were located in the rectum, and 174 in the colon (cecum, 37; ascending colon, 49; transverse colon, 43; descending colon, 12; sigmoid colon, 33). Morphologically, 108 lesions were polypoid (0-Is, Is + IIa) and 114 were non-polypoid (0-IIa, IIa + IIc, IIc). The histological examination showed adenoma in 69, and intramucosal or submucosal-superficial carcinoma in 153 cases.

Complications

No perforations were observed. Four patients developed bleeding requiring endoscopic confirmation and hemostasis >24 h after EPMP. All the bleeding episodes were successfully treated using endoclips or coagulation without blood transfusion.

Incidence of recurrence

The median follow-up period was 32 months (interquartile range [IQR] 11–53). Local recurrence was detected in 42 treatment sites between 6 and 15 months (IQR) after the initial treatment, and 39 of these lesions were treated by additional EMR or coagulation and achieved complete remission. These lesions were histologically diagnosed as adenoma or intramucosal carcinoma. Additional surgical resection was performed in 3 patients (1.4%). The lesions in 2 of these 3 patients were diagnosed as invasive cancer

(recurrence at 7 and 18 months with submucosal tumor-like configuration). The clinical stages (International Union Against Cancer [UICC]-TNM classification) of these two lesions were evaluated as follows: T3N0M0, IIIB and T3N1aM0, IIIA. The third surgical patient showed recurrence at the initial treatment site at 6 months (additional EMR was performed) and repeated (4 times) local recurrence on surveillance colonoscopy. Finally, endoscopic treatment was relinquished for this patient because of technical difficulties: the lesion was located in the cecum, close to the appendix orifice and multiple diverticuli.

Predictive factors of recurrence

The resection of 5 or more pieces and lesion size (more than 30 mm) were found to be the significant risk factors for local recurrence after piecemeal resection in the univariate analysis, with ORs of 4.14 (95% CI 1.91–8.92) and 2.76 (1.31–5.98). Multivariate analysis revealed that only the number of pieces resected was a significant risk factor for local recurrence, with the resection of 5 or more pieces compared with fewer than 5 pieces being 3 times more likely to result in local recurrence ($P = 0.005$). No statistically significant correlation of local recurrence with lesion size, location, macroscopic type, or histology was detected, as shown in Table 2.

Discussion

The main focus of the present study was to identify predictors of local recurrence after EPMP. The number of pieces resected proved to be the sole significant risk factor. It stands to reason that the number of resected specimens might be associated with an increased lesion size, making lesion size an important alternative predictor of post-EPMP recurrence. However, we did not detect high multicollinearity between these two investigated factors by statistical analysis, and only the number of resected specimens remained an independent risk factor for local recurrence. Moreover, this result does not necessarily prove that the lesion size determines the number of resected pieces. Actually, the lesions that were easy to lift up by submucosal injection during the endoscopic procedure commonly did not require multiple resection. In contrast, the ones characterized by fibrosis in the submucosal layer necessitated removal in several fractions, even if they were only moderately sized. Similarly, laterally spreading tumors of non-granular type are considered difficult to resect en bloc by conventional EMR [13]. Thus, the morphological features of the malignant tumor constitute an important element in the decision on whether or not to implement EPMP for the tumor treatment.

Table 1 Clinicopathological characteristics of all eligible patients

Age, years (mean \pm SD)	65.5 \pm 11.4
Gender (male/female)	138/84 (62.2/37.8)
Lesion size, mm (mean \pm SD)	28.2 \pm 12.5
Location (%)	
Colon	174 (78)
Rectum	48 (22)
Macroscopic type (%)	
Polypoid (0-Is, Isp, Is + IIa)	108 (49)
Non-polypoid (0-IIa, IIa + IIc, IIc)	114 (51)
Histology (%)	
Adenoma	69 (31)
M–SM superficial cancer	153 (69)
Complications (%)	
Perforation	0 (0)
Delayed bleeding	4 (2)
Follow-up period (months), median (IQR)	32 (11–53)

M mucosal, SM submucosal, IQR interquartile range

Table 2 Results of analyses of the risk factors for local neoplasm recurrence or residual lesions

Variable	Recurrence (±)	Univariate			Multivariate		
		Odds ratio	95% CI	<i>P</i> value	Odds ratio	95% CI	<i>P</i> value
Lesion size							
<30 mm	15/109	1.000	1.307–5.980	0.004	1.000	0.793–4.287	0.156
≥30 mm	27/71	2.763			1.843		
Macroscopic type							
Polypoid	21/87	1.000	0.481–1.819	0.846	1.000	0.250–1.246	0.155
Non-polypoid	21/93	0.935			0.559		
Location							
Colon	29/145	1.000	0.886–3.903	0.103	1.000	0.771–4.047	0.178
Rectum	13/35	1.857			1.767		
No. of resected specimens							
2–4	21/145	1.000	1.909–8.919	<0.001	1.000	1.412–6.917	0.0005
≥5	21/35	4.143			3.126		
Histology							
Adenoma	9/60	1.000	0.791–4.634	0.133	1.000	0.535–3.250	0.548
Adenocarcinoma	33/120	1.833			1.319		

CI Confidence interval

Some previous reports have indicated that conventional en-bloc EMR techniques were limited to the removal of lesions that were 20–30 mm in size [14–16]. Therefore, most follow-up studies that investigated local recurrence after EMR aimed at the eradication of malignancies of dimensions exceeding 20 mm [13, 17, 18]. However, 72 cases of smaller lesions included in our study warranted the implementation of EPMR for the following reasons: existence of fibrosis due to biopsy prior to endoscopic resection, inadequate visibility, and poor procedure conditions (e.g., bowel movements). In view of these findings, we concede that lesions of less than 20 mm in size should not be excluded from recurrence studies.

Recently, ESD has been introduced as an alternative therapeutic technique for the treatment of gastrointestinal neoplasms [1, 2]. Because it is typically performed as an en-bloc resection, the procedure provides a complete specimen for precise histopathological evaluation. However, owing to its technical difficulty and the increased risk of perforation, ESD is not as widely used in the treatment of colorectal as of gastric neoplasms. In contrast, EPMR has gained wide acceptance due to its simplicity, rapidity, and low complication rates. However, it should be well recognized that EPMR is not free of disadvantages, including a high incidence of local recurrence and the possibility of inaccurate pathological evaluation. Regarding local recurrence, current guidelines published by the American Cancer Society recommend repeated examination 3–6 months after piecemeal resection for large or sessile polyps [10]. While previous studies concerning the risks of residual tumors reported an 0–50% incidence of the

phenomenon [19], our findings regarding local neoplasm recurrence showed an incidence of 18.9%. Controversially, in our study, about 80% of the patients who underwent EPMR did not require intensive colonoscopic surveillance, while most of the residual lesions were resected by additional endoscopic treatment, achieving complete remission. Therefore, considering low patient compliance for colonoscopy and desirable cost-minimalization, the systematized stratification of risk factors for local neoplasm recurrence might prove highly useful.

Nevertheless, the probability of invasive recurrence should not be dismissed; in the present study, 2 such cases were recorded. Several previous reports assumed that residual tumor cells acquired greater malignancy after resection, and the development of residual cancer after EMR or polypectomy has been described [20–24]. Interestingly, the histological evaluation in the initial treatment of our 2 patients who had invasive recurrence was “intramucosal carcinoma without lymphovascular infiltration,” which has little possibility of lymph node metastasis, and the clinically recommended treatment is curative resection [25]. It is likely, however, that submucosal or lymphovascular invasion in some parts of these lesions was difficult to evaluate perfectly due to the application of piecemeal EMR. In fact, the 2 malignancies were resected by fractionation into more than 5 pieces, and collecting all the resected specimens was problematic. Therefore, preoperative diagnosis for depth of invasion seemed crucial and in this study was evaluated by means of magnifying chromoendoscopy; this technique, as well as endoscopic ultrasonography, has shown good diagnostic efficacy in

early colorectal cancer [26, 27]. However, the diagnostic performance proved inferior for the protruded type of lesions as opposed to the flat or depressed types. Moreover, our retrospective study showed a higher rate of submucosal invasion with increasing size in early colorectal cancer [28, 29]. Therefore, lesions showing potential for submucosal invasion in preoperative examination should be resected through appropriate endoscopic procedures aiming at en-bloc removal or fractionation into only a few pieces. If the aforementioned endoscopic techniques should prove unfeasible, surgical laparoscopy would be an appropriate alternative treatment strategy.

Some limitations of our study warrant mention. Firstly, this was a retrospective study conducted at a single institution. Diverse therapeutic instruments (e.g., solutions for submucosal injection, snare devices) and endoscopic observations (with or without chromomagnification) applied in individual institutions would contribute to increased variability. Secondly, some patients presenting with no local recurrence at first surveillance colonoscopy did not proceed to further follow-up examinations, as their background (e.g., age, place of residence) precluded multiple visits to our hospital. Moreover, patients diagnosed with small lesions (<20 mm) warranting piecemeal resection in only a few fractions were also largely monitored only through the first surveillance round. Consequently, the actual recurrence rate might prove higher than the one estimated herein. Therefore, the validity of our results for recurrent or residual tumors requires confirmation in multicenter trials. Third, there might be some predictive factors for local recurrence after piecemeal EMR; for example, differences in endoscopists' skill levels, the presence or absence of coagulation of the resection plane, and observation of the resected margin with magnifying endoscopy. However, these factors were not analyzed because of the retrospective nature of the present study, and the data were collected using medical records in a single referral center. Further, analysis of the influence of the number of pieces resected would be possible by conducting a prospective study where the precise number of pieces resected could be recorded.

In conclusion, the removal of 5 or more pieces constitutes an independent risk factor for local recurrence after EPMR, and careful surveillance colonoscopy is needed after multiple piecemeal EMR. Taking heed of invasive recurrence in particular, endoscopists should avoid multiple resections and should consider alternative treatment strategies according to the morphological features, size, and location of the lesion, as well as their skills.

Conflict of interest None.

References

1. Saito Y, Fukuzawa M, Matsuda T, Fukunaga S, Sakamoto T, Uraoka T, et al. Clinical outcome of endoscopic submucosal dissection versus endoscopic mucosal resection of large colorectal tumors as determined by curative resection. *Surg Endosc.* 2010;24(2):343–52.
2. Saito Y, Uraoka T, Yamaguchi Y, Hotta K, Sakamoto N, Ikematsu H, et al. A prospective, multicenter study of 1111 colorectal endoscopic submucosal dissections (with video). *Gastrointest Endosc.* 2010;72(6):1217–25.
3. Tanaka S, Tamegai Y, Tsuda S, Saito Y, Yahagi N, Yamano HO. Multicenter questionnaire survey on the current situation of colorectal endoscopic submucosal dissection in Japan. *Dig Endosc.* 2010;22(Suppl 1):S2–8.
4. Ahmad NA, Kochman ML, Long WB, Furth EE, Ginsberg GG. Efficacy, safety, and clinical outcomes of endoscopic mucosal resection: a study of 101 cases. *Gastrointest Endosc.* 2002;55(3):390–6.
5. Hurlstone DP, Sanders DS, Cross SS, Adam I, Shorthouse AJ, Brown S, et al. Colonoscopic resection of lateral spreading tumours: a prospective analysis of endoscopic mucosal resection. *Gut.* 2004;53(9):1334–9.
6. Kiesslich R, Neurath MF. Endoscopic mucosal resection: an evolving therapeutic strategy for non-polypoid colorectal neoplasia. *Gut.* 2004;53(9):1222–4.
7. Walsh RM, Ackroyd FW, Shellito PC. Endoscopic resection of large sessile colorectal polyps. *Gastrointest Endosc.* 1992;38(3):303–9.
8. Hotta K, Fujii T, Saito Y, Matsuda T. Local recurrence after endoscopic resection of colorectal tumors. *Int J Colorectal Dis.* 2009;24(2):225–30.
9. Tanaka S, Oka S, Chayama K. Colorectal endoscopic submucosal dissection: present status and future perspective, including its differentiation from endoscopic mucosal resection. *J Gastroenterol.* 2008;43(9):641–51.
10. Winawer SJ, Zauber AG, Fletcher RH, Stillman JS, O'Brien MJ, Levin B, et al.; US Multi-Society Task Force on Colorectal Cancer; American Cancer Society. Guidelines for colonoscopy surveillance after polypectomy: a consensus update by the US Multi-Society Task Force on Colorectal Cancer and the American Cancer Society. *Gastroenterology.* 2006;130(6):1872–85.
11. Sakamoto T, Saito Y, Matsuda T, Fukunaga S, Nakajima T, Fujii T. Treatment strategy for recurrent or residual colorectal tumors after endoscopic resection. *Surg Endosc.* 2011;25(1):255–60.
12. The Paris endoscopic classification of superficial neoplastic lesions: esophagus, stomach, and colon. *Gastrointest Endosc.* 2003;58(6 Suppl):S3–43.
13. Luigiano C, Consolo P, Scaffidi MG, Strangio G, Giacobbe G, Alibrandi A, et al. Endoscopic mucosal resection for large and giant sessile and flat colorectal polyps: a single-center experience with long-term follow-up. *Endoscopy.* 2009;41(10):829–35.
14. Soetikno RM, Inoue H, Chang KJ. Endoscopic mucosal resection. Current concepts. *Gastrointest Endosc Clin N Am.* 2000;10(4):595–617, vi.
15. Tanaka S, Haruma K, Oka S, Takahashi R, Kunihiro M, Kitadai Y, et al. Clinicopathologic features and endoscopic treatment of superficially spreading colorectal neoplasms larger than 20 mm. *Gastrointest Endosc.* 2001;54(1):62–6.
16. Tamura S, Nakajo K, Yokoyama Y, Ohkawauchi K, Yamada T, Higashidani Y, et al. Evaluation of endoscopic mucosal resection for laterally spreading rectal tumors. *Endoscopy.* 2004;36(4):306–12.

17. Arebi N, Swain D, Suzuki N, Fraser C, Price A, Saunders BP. Endoscopic mucosal resection of 161 cases of large sessile or flat colorectal polyps. *Scand J Gastroenterol.* 2007;42(7):859–66.
18. Khashab M, Eid E, Rusche M, Rex DK. Incidence and predictors of “late” recurrence after endoscopic piecemeal resection of large sessile adenomas. *Gastrointest Endosc.* 2009;70(2):344–9.
19. Tanaka S, Oka S, Chayama K. Colorectal endoscopic submucosal dissection: present status and future perspective, including its differentiation from endoscopic resection. *J Gastroenterol.* 2008;43(9):641–51.
20. Pollard CW, Nivatvongs S, Rojanasakul A, Reiman HM, Dozois RR. The fate of patients following polypectomy alone for polyps containing invasive carcinoma. *Dis Colon Rectum.* 1992;35(10):933–7.
21. Ishikawa T, Ushio K, Miyagawa K, Nakashima H, Yokota T, Ono H, et al. Morphological features of local recurrent adenomas and carcinomas of the colon and rectum after polypectomy (in Japanese with English abstract). *I Chou.* 1993;28:511–22.
22. Matsuda K, Masaki T, Abo Y, Uchida H, Watanabe T, Muto T. Rapid growth of residual colonic tumor after incomplete mucosal resection. *J Gastroenterol.* 1999;34(2):260–3.
23. Tsunada S, Mannen K, Yamaguchi K, Aoki S, Uchihashi K, Toda S, et al. A case of advanced colonic cancer that developed from residual laterally spreading tumor treated by piecemeal endoscopic mucosal resection. *Clin J Gastroenterol.* 2008;1(1):18–22.
24. Kunihiro M, Tanaka S, Haruma K, Kitadai Y, Yoshihara M, Sumii K, et al. Electrocautery snare resection stimulates cellular proliferation of residual colorectal tumor: an increasing gene expression related to tumor growth. *Dis Colon Rectum.* 2000;43(8):1107–15.
25. Kitajima K, Fujimori T, Fujii S, Takeda J, Ohkura Y, Kawamata H, et al. Correlations between lymph node metastasis and depth of submucosal invasion in submucosal invasive colorectal carcinoma: a Japanese collaborative study. *J Gastroenterol.* 2004;39(6):534–43.
26. Matsuda T, Fujii T, Saito Y, Nakajima T, Uraoka T, Kobayashi N, et al. Efficacy of the invasive/non-invasive pattern by magnifying chromoendoscopy to estimate the depth of invasion of early colorectal neoplasms. *Am J Gastroenterol.* 2008;103(11):2700–6.
27. Fu KI, Kato S, Sano Y, Onuma EK, Saito Y, Matsuda T, et al. Staging of early colorectal cancers: magnifying colonoscopy versus endoscopic ultrasonography for estimation of depth of invasion. *Dig Dis Sci.* 2008;53(7):1886–92.
28. Uraoka T, Saito Y, Matsuda T, Ikehara H, Gotoda T, Saito D, Fujii T. Endoscopic indications for endoscopic mucosal resection of laterally spreading tumours in the colorectum. *Gut.* 2006;55(11):1592–7.
29. Saito Y, Uraoka T, Matsuda T, Emura F, Ikehara H, Mashimo Y, et al. Endoscopic treatment of large superficial colorectal tumors: a case series of 200 endoscopic submucosal dissections (with video). *Gastrointest Endosc.* 2007;66(5):966–73.

Risk Factors for Delayed Bleeding After Endoscopic Resection for Large Colorectal Tumors

Minori Matsumoto¹, Shusei Fukunaga^{1,2}, Yutaka Saito^{1,*}, Takahisa Matsuda¹, Takeshi Nakajima¹, Taku Sakamoto¹, Naoto Tamai^{1,3} and Tsuyoshi Kikuchi¹

¹Endoscopy Division, National Cancer Center Hospital, Tokyo, ²Department of Gastroenterology, Osaka City University Graduate School of Medicine, Osaka and ³Department of Endoscopy, The Jikei University School of Medicine, Tokyo, Japan

*For reprints and all correspondence: Yutaka Saito, Endoscopy Division, National Cancer Center Hospital, 5-1-1 Tsukiji, Chuo-ku, Tokyo 104-0045, Japan. E-mail: ytsaito@ncc.go.jp

Received March 7, 2012; accepted July 26, 2012

Objective: Endoscopic resection techniques for treating colorectal tumors have advanced recently so that large colorectal tumors can now be treated endoscopically, although some patients experience delayed bleeding after endoscopic resection. Our aim was to clarify the risk factors for delayed bleeding after endoscopic resection for colorectal tumors ≥ 20 mm in diameter. Endoscopic submucosal dissection cases were excluded because of the low incidence of delayed bleeding after such procedures.

Methods: This was a retrospective study using a prospectively completed database and patient medical records at a single, national cancer institution. A total of 403 colorectal endoscopic resections were performed on 375 consecutive patients. We analyzed the database and retrospectively assessed patient age, gender, hypertension and current use of anticoagulant (warfarin) or antiplatelet drugs (e.g. aspirin, ticlopidine) as well as tumor location, size, macroscopic type, histopathological findings, resection method and whether or not placement of prophylactic clips was performed during the endoscopic resection.

Results: The overall rate of delayed bleeding was 4.2% (17/403) and the median interval between endoscopic resection and the onset of delayed bleeding was 2 days (range, 1–14 days). All delayed bleeding cases were successfully controlled by endoscopic hemostasis involving clipping and/or electrocoagulation without the need for surgical interventions or blood transfusions. Based on our univariate analysis, the delayed bleeding rate was significantly higher in both males ($P = 0.04$) and those patients without prophylactic clip placement ($P = 0.04$).

Conclusions: Our study results indicated that prophylactic clip placement may be an effective method for preventing delayed bleeding after endoscopic resection for large colorectal tumors.

Key words: colorectal tumors – endoscopic resection – delayed bleeding

INTRODUCTION

Endoscopic resection (ER) techniques used in the treatment of colorectal tumors have progressed to the point that they have become well established recently because ER is associated with minimal invasiveness and excellent results (1–6). In addition to polypectomy (PO), endoscopic mucosal resection (EMR) and endoscopic piecemeal mucosal resection (EPMR) are now widely accepted in the

treatment of large colorectal tumors and laterally spreading tumors (7–10). There is always a risk of complications with ER, however, despite the best preventative efforts and delayed bleeding, which can occur up to 2 weeks after ER, is one of the more frequent complications (11). Although delayed bleeding is clinically serious, it is difficult to accurately predict the risk of such delayed bleeding (12). The risk of delayed bleeding has been reported to increase as the size