

Research Center for Cancer Prevention and Screening, National Cancer Center, which followed all subjects given a TCS as a primary screening from February 2004 to August 2010. A total of 15,348 cases had a colonoscopy performed as a primary screening. This data was used to calculate the cost associated with identifying a patient with CRC using the cost of TCS as 15,500 JPY, based on Japanese national reimbursement tables.

**2.2. Strategy 2: FIT as a Primary Screening.** We retrospectively analyzed the Japanese nationwide survey of CRC screening in 2008 [11]. A total of 5,267,443 cases were included. This data was used to calculate the cost associated with identifying a patient with CRC using the cost of FIT as 1,600 JPY and TCS as 15,500 JPY, respectively.

### 3. Results

Clinical characteristics of examinees in strategies 1 and 2 are listed in Table 1. Both groups predominantly comprised examinees in their 50s and 60s, and there was a higher male-to-female ratio in strategy 2 than in strategy 1. However, there was no statistical significance between two groups.

The number of CRC cases identified and the cost to find one case of CRC in both groups are listed in Table 2. In strategy 1, there were 112 cases of CRC among 15,348 TCS examinees (0.73%), with a calculated cost of finding one CRC case of 2,124,000 JPY. In group 2, 5,267,443 underwent FIT, with 319,846 cases testing positive, (6.1%). All examinees with a positive FIT were recommended for a further TCS. However, only 174,914 examinees (54.7%) underwent TCS, and 6,838 cases of CRC were found. The calculated cost to find one patient with CRC was 1,629,000 JPY in this group. If all of the 319,846 cases with a positive FIT had undergone TCS, the number of CRC cases would have increased, reducing the cost of identifying CRC. Assuming that the rate of CRC cases among the TCS examinees was the same as that in the strategy 2 group (3.9%; 6,838/174,914), it was calculated that there would be 12,504 CRC patients, each costing 1,090,000 JPY to be identified.

The staging of CRC at diagnosis (Japanese Classification of Colorectal Carcinoma) and initial treatment for CRC are summarized in Table 2. The rate of stage 0 and endoscopic resection were higher in strategy 1 than in strategy 2.

### 4. Discussion

Several previous studies have shown that CRC screening including FIT and TCS is cost-effective. However, in Japan, only a few cost-effective analyses have been reported, with the cost-effectiveness of TCS as primary screening still unclear.

In this analysis, we compared the cost of identifying a patient with CRC using two screening strategies, using TCS as a primary screening, or using FIT as a primary screening with TCS then performed in cases with a positive FIT test. The results demonstrated that it cost more to identify CRC when TCS was used as a primary screening strategy compared to the FIT screening strategy (2,124,000 JPY versus 1,629,000

TABLE 1: Clinical characteristics of examinees in strategies 1 and 2.

	Strategy 1 (n = 15,348)	Strategy 2 (n = 5,267,443)
Screening strategy	TCS as a primary screening	FIT as a primary screening
Sex		
Male	5,892 (38.4%)	2,174,604 (41.3%)
Female	9,456 (61.6%)	2,006,926 (38.1%)
Unknown	0	1,085,913 (20.6%)
Age group (yr)		
<40	15 (0.1%)	370,750 (7.0%)
40–49	1,918 (12.5%)	870,134 (16.5%)
50–59	4,864 (31.7%)	1,050,813 (19.9%)
60–69	6,521 (42.5%)	1,044,313 (19.8%)
≥70	2,030 (13.2%)	845,520 (16.1%)
Unknown	0	1,085,913 (20.6%)
Mean (range)	60.1 (40–89)	Unknown

JPY). It is assumed that this difference would have become even larger if all FIT-positive subjects had then chosen to have a TCS (2,124,000 JPY versus 1,090,000 JPY). However, the higher cost associated with the TCS only strategy does not necessarily deny the cost-effectiveness of this approach for primary screening. This is because TCS, used as a primary screening strategy, was able to identify CRC at an earlier stage as demonstrated in Table 2, possibly resulting in a decreased cost of CRC treatment and followup. The clinical course of the cases of CRC detected in strategy 1 at our institution is shown in Figure 1. Among the 112 CRC cases identified, 109 cases followed a clear clinical course, with approximately 80% cured with a single endoscopic treatment. Only one case has had recurrent disease following treatment. Such a clinical course indicates that earlier detection of CRC can lead to cure with less invasive treatment, resulting in a shorter period of followup and decreased cost of CRC care. From this perspective, it is possible to postulate that the difference in the cost of identifying CRC in the two strategies is not as great and that TCS may be a cost-effective primary screening strategy. Additionally, we probably underestimated the cost-effectiveness of TCS because we did not include the possibility to reduce CRC incidence with TCS in this study. Previous studies have demonstrated the effect of colonic polypectomy in reducing CRC incidence [12, 13]. Not only when using TCS as a primary screening strategy but also when using FIT as a primary screening, reduction in CRC incidence is expected [14]. However, taking into account the higher detection rate for colorectal polyps with TCS and the low rate of undergoing TCS among examinees with a positive FIT, reduction in CRC incidence is expected more when using TCS as a primary screening. If we consider this effect of TCS, TCS may be a more acceptable choice as a primary screening. Furthermore, considering that using TCS as a primary screening can lead to better quality of life (QOL) after CRC diagnosis due to the earlier detection of disease, it is worth performing TCS as a primary screening of CRC.

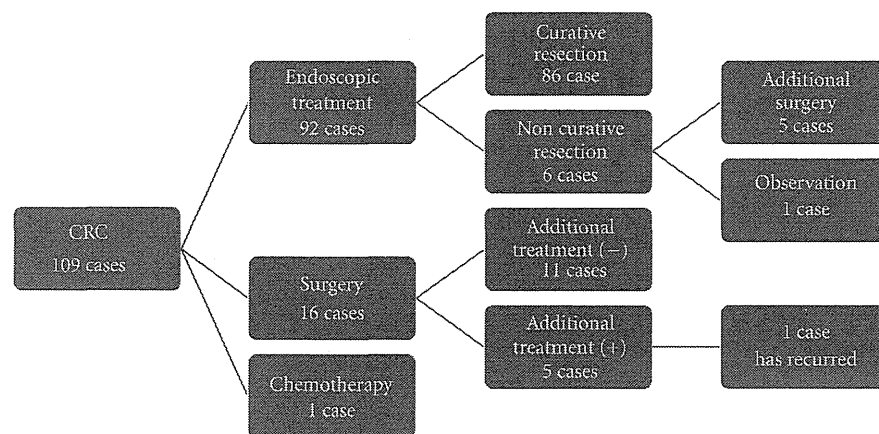


FIGURE 1: The clinical course of CRC cases detected in strategy 1.

TABLE 2: Number of CRC cases, the cost to find one CRC case, staging of CRC at diagnosis, and initial treatment for CRC in both strategies.

	Strategy 1 (n = 15,348)	Strategy 2 (n = 5,267,443)
Number of cases of CRC	112 (0.73%)	6,838 (0.13%)
Cost to find a case of CRC	2,124,000 JPY	1,629,000 JPY
Staging of CRC at diagnosis		
0	81 (72.3%)	1,713 (25.1%)
I	16 (14.3%)	1,043 (15.3%)
II	7 (6.3%)	552 (8.1%)
III a	3 (2.7%)	418 (6.1%)
III b	1 (0.9%)	187 (2.7%)
IV	1 (0.9%)	116 (1.7%)
Unknown	3 (2.7%)	2,809 (41.1%)
Initial treatment for CRC		
Endoscopic treatment	93 (83.0%)	2,267 (33.2%)
Surgery	16 (14.3%)	2,466 (36.1%)
No treatment	0	19 (0.3%)
Others	0	67 (1.0%)
Unknown	3 (2.7%)	2,019 (29.5%)

## 5. Conclusions

The cost associated with identifying one case of CRC is higher when using TCS as a primary screening strategy compared to using the FIT as a primary screening. However, taking into account the earlier detection of CRC using TCS, it is possible to postulate that the final cost difference may be reduced and that TCS may provide a cost-effective primary screening strategy. Additionally, considering the effect of TCS on CRC incidence and a better QOL after earlier detection of CRC with TCS, TCS is worth using as a primary screening of CRC.

## References

- [1] T. Matsuda, T. Marugame, K.-I. Kamo, K. Katanoda, W. Ajiki, and T. Sobue, "Cancer incidence and incidence rates in Japan in 2005: based on data from 12 population-based cancer registries in the monitoring of cancer incidence in Japan (MCJ) project," *Japanese Journal of Clinical Oncology*, vol. 41, no. 1, pp. 139–147, 2011.
- [2] A. L. Frazier, G. A. Colditz, C. S. Fuchs, and K. M. Kuntz, "Cost-effectiveness of screening for colorectal cancer in the general population," *JAMA*, vol. 284, no. 15, pp. 1954–1961, 2000.
- [3] A. Sonnenberg, F. Delcò, and J. M. Inadomi, "Cost-effectiveness of colonoscopy in screening for colorectal cancer," *Annals of Internal Medicine*, vol. 133, no. 8, pp. 573–584, 2000.
- [4] M. Pignone, S. Saha, T. Hoerger, and J. Mandelblatt, "Cost-effectiveness analyses of colorectal cancer screening: a systematic review for the U.S. Preventive Services Task Force," *Annals of Internal Medicine*, vol. 137, no. 2, pp. 96–104, 2002.
- [5] K. Song, A. M. Fendrick, and U. Ladabaum, "Fecal DNA testing compared with conventional colorectal cancer screening methods: a decision analysis," *Gastroenterology*, vol. 126, no. 5, pp. 1270–1279, 2004.
- [6] S. Vijan, I. Hwang, J. Inadomi et al., "The cost-effectiveness of CT colonography in screening for colorectal neoplasia,"

- American Journal of Gastroenterology*, vol. 102, no. 2, pp. 380–390, 2007.
- [7] K. K. F. Tsoi, S. S. M. Ng, M. C. M. Leung, and J. J. Y. sung, “Cost-effectiveness analysis on screening for colorectal neoplasm and management of colorectal cancer in Asia,” *Alimentary Pharmacology and Therapeutics*, vol. 28, no. 3, pp. 353–363, 2008.
- [8] I. Lansdorp-Vogelaar, A. B. Knudsen, and H. Brenner, “Cost-effectiveness of colorectal cancer screening,” *Epidemiologic Reviews*, vol. 33, pp. 88–100, 2011.
- [9] I. Tsuji, A. Fukao, T. Shoji, I. Kuwajima, N. Sugawara, and S. Hisamichi, “Cost-effectiveness analysis of screening for colorectal cancer in Japan,” *Tohoku Journal of Experimental Medicine*, vol. 164, no. 4, pp. 269–278, 1991.
- [10] T. Shimbo, H. A. Glick, and J. M. Eisenberg, “Cost-effectiveness analysis of strategies for colorectal cancer screening in Japan,” *International Journal of Technology Assessment in Health Care*, vol. 10, no. 3, pp. 359–375, 1994.
- [11] “Nationwide Survey Committee of Mass Screening for Digestive Organs of the Japanese Society of Gastroenterological Cancer Screening: annual report 2008 of the nationwide survey on mass screening for digestive organs,” *Journal of Gastroenterol Cancer Screening*, vol. 49, pp. 73–112, 2011.
- [12] S. J. Winawer, A. G. Zauber, May Nah Ho et al., “Prevention of colorectal cancer by colonoscopic polypectomy,” *The New England Journal of Medicine*, vol. 329, no. 27, pp. 1977–1981, 1993.
- [13] F. Citarda, G. Tomaselli, R. Capocaccia, S. Barcherini, and M. Crespi, “Efficacy in standard clinical practice of colonoscopic polypectomy in reducing colorectal cancer incidence,” *Gut*, vol. 48, no. 6, pp. 812–815, 2001.
- [14] J. S. Mandel, T. R. Church, J. H. Bond et al., “The effect of fecal occult-blood screening on the incidence of colorectal cancer,” *The New England Journal of Medicine*, vol. 343, no. 22, pp. 1603–1607, 2000.

## Clinical Study

# Detectability of Colon Polyp Using Computed Virtual Chromoendoscopy with Flexible Spectral Imaging Color Enhancement

Shinsuke Kiriyama,<sup>1,2,3</sup> Takahisa Matsuda,<sup>3</sup> Takeshi Nakajima,<sup>3</sup>  
Taku Sakamoto,<sup>3</sup> Yutaka Saito,<sup>3</sup> and Hiroyuki Kuwano<sup>2</sup>

<sup>1</sup>Department of Surgery, Gunma Chuo General Hospital, Maebashi, Gunma 371-0025, Japan

<sup>2</sup>Department of General Surgical Science, Graduate School of Medicine, Gunma University, Maebashi, Gunma 371-8511, Japan

<sup>3</sup>Endoscopy Division, National Cancer Center Hospital, Tokyo 104-0045, Japan

Correspondence should be addressed to Shinsuke Kiriyama, drkiriyama@yahoo.co.jp

Received 9 August 2011; Accepted 19 December 2011

Academic Editor: C. M. Wilcox

Copyright © 2012 Shinsuke Kiriyama et al. This is an open access article distributed under the Creative Commons Attribution License, which permits unrestricted use, distribution, and reproduction in any medium, provided the original work is properly cited.

The aim of this pilot study was to assess the feasibility of using computed virtual chromoendoscopy with the flexible spectral imaging color enhancement (FICE) for colon neoplasia screening. A modified back-to-back colonoscopy using FICE and white light in the right-sided colon was conducted prospectively for the consecutive patients attending for the postoperative (sigmoidectomy or anterior resection) follow-up colonoscopy. Histopathology of detected lesions was confirmed by evaluation of endoscopic resection or biopsy specimens. One-hundred and two patients were enrolled, and 100 patients (61 males and mean age 63 years) were finally analyzed. The total number of polyps detected by FICE and white light colonoscopy was 65 and 45, respectively. The miss rate for all polyps with FICE (24%) was significantly less than that with white light (46%) ( $P = 0.03$ ). Colonoscopy using FICE could beneficially enhance the detection of neoplastic lesions in the right-sided colon compared to white light colonoscopy.

## 1. Introduction

Colonoscopy is the accepted gold standard for the detection of colorectal lesions including colorectal cancers and adenomas. Early detection and removal of colorectal adenomas have been shown to be the most effective way of colorectal cancer prevention, however, polyps can be missed with conventional white light (WL) colonoscopy [1, 2]. Unfortunately, at standard WL colonoscopy, classification of lesions is often difficult and a substantial percentage of adenomas are missed during the procedure. According to the results of back-to-back colonoscopies by Rex et al., the miss rate for adenomas  $\geq 1$  cm was 6%, for adenomas 6–9 mm was 13%, and for adenomas  $\leq 5$  mm was 27%, respectively [3]. Furthermore, there was a trend toward right-sided colorectal adenomas being missed more often than left-sided ones (27% versus 21%). As missing adenomas or cancers during

colonoscopy would result in increasing the need of surgery and death from colorectal cancers, attempts to reduce this kind of miss rate include pancolonial dye spraying, wide angle colonoscopy, or cap-fitted colonoscopy [4–8].

On the other hand, computed virtual chromoendoscopy with the flexible spectral imaging color enhancement (FICE) has been developed as a new dye-less imaging technique, which might allow higher rate of colon polyp detection [9–13]. FICE is based on a computed spectral estimation technology that arithmetically processes the reflected photons to reconstitute virtual images for a choice of different wavelengths. Due to its variable setting functions, it is possible to select flexibly the most suitable wavelengths required for examination. Based on technical considerations, it is conceivable that advanced virtual imaging techniques might highlight adenomas during colonoscopy, however, its effectiveness, measured as frequency of detection of colorectal

polyps in comparison to conventional WL colonoscopy, has not been investigated enough. We therefore conducted this pilot study to assess the feasibility of using FICE for colon neoplastic lesions screening.

## 2. Methods

**2.1. Study Design.** From August 2008 to March 2009 in National Cancer Center Hospital, Japan, a modified back-to-back colonoscopy using FICE and WL was conducted for 102 patients in the right-sided colon including cecum, ascending and transverse colon. This study was conducted prospectively, and written informed consent for examination and treatment was obtained from all of the studied patients prior to the procedures. The consecutive patients attending for the postoperative (sigmoidectomy or rectal anterior resection) follow-up colonoscopy were randomized to undergo the colonoscopy with either FICE or WL (group A: WL-FICE, group B: FICE-WL). After randomization, the scope was inserted into the cecum using white light. Patients with known inflammatory bowel disease, overt bleeding, and polyposis syndrome and patients receiving anticoagulant medication were excluded from the study.

**2.2. Flexible Spectral Imaging Color Enhancement (FICE).** All examinations were performed with high-resolution zoom endoscopes (EC 590 ZW, Fujifilm medical, Tokyo, Japan). However, the zoom function of the device was not utilized for this study. The system was equipped with the EPX 4400 processor (Fujifilm medical) that provides the FICE technology.

Based on preliminary experience of the participating endoscopists, FICE set 7 (R 540 nm, G 490 nm and B 420 nm) was favored over other FICE sets for application in the colon and was therefore exclusively used in this study. In the FICE turn, withdrawal was performed with activated FICE set 7. Switching back to conventional imaging was allowed at the discretion of the endoscopist only for polypectomies.

**2.3. Endoscopic Procedure.** All patients were prepared for colonoscopy by ingesting 2-3 liters of polyethylene glycolelectrolyte solution on the same-day morning. Scopolamine butylbromide (10 mg) was administered intravenously to avoid bowel movement prior to examination for the patients with no contraindication to the use of this agent. Basically all colonoscopies were performed without sedation, by one of three experienced colonoscopists (more than 1000 colonoscopies). Only when patients felt abdominal pain, midazolam (2 mg) was administered intravenously during procedure. Quality of bowel preparation was assessed by the examiner as follows: (a) excellent (near 100% mucosal visualization following suction of fluid residue), (b) good (near 90% mucosal visualization), and (c) fair (less than 90% mucosal visualization). Examinations were performed in a modified back-to-back fashion, using FICE and WL in the right-sided colon including cecum, ascending colon, and transverse colon. The time needed for both insertion and examination for withdrawal and all lesions detected in the right-sided

colon was recorded. Each patient was randomized in one of the following two groups with a computer-generated random number list; group A: after cecal insertion by WL, the colonoscope was withdrawn from the cecum to the splenic flexure with WL mode and then rewithdraw in the colonoscope with FICE from the cecum to the splenic flexure after reinsertion of the scope to the cecum by WL (WL-FICE); group B: withdrawing the colonoscope in the inverse order of group A (first FICE and then WL; FICE-WL). All lesions detected during either examination of FICE or WL were removed by endoscopic resection or biopsy specimens and sent for histological evaluation without exception. All lesions identified on the second examination were considered as lesions missed by the first examination. The location of each lesion was defined according to landmarks including hepatic flexure and splenic flexure. The size of the lesions was estimated using open endoscopic biopsy forceps.

**2.4. Histopathological Evaluation.** Resected specimens were immediately fixed in 10% buffered formalin solution and subsequently stained with hematoxylin-eosin. Experienced gastrointestinal pathologists who were completely blinded to each endoscopic diagnosis evaluated all pathological specimens. Histological diagnoses were determined according to the World Health Organization (WHO) criteria [14].

**2.5. Statistical Analysis.** This study was mainly designed to demonstrate that the colonoscope with FICE has a different reliability than with WL for polyp detection. No sample sizes were calculated, as this was a pilot study. The design of the study included two independent groups; group A underwent colonoscopy with FICE after colonoscopy with WL, and group B underwent colonoscopy with WL after colonoscopy with FICE. Categorical variables are expressed with frequencies and percentages. Continuous variables are expressed with means and standard deviations. Statistical differences were analyzed by  $\chi^2$  test of independence, the Mann-Whitney *U* tests, and Fisher's exact test. A *P* value of less than 0.05 was considered statistically significant. Statistical analysis was conducted with SPSS V. (Chicago, IL), Stat X act v. 5.0.3 (Cytel Co., MA), and Statistica v. 5.5 (Tulsa, OK).

## 3. Results

A total of 102 patients were enrolled in this study. Fifty-one were randomized to group A and B. According to the protocol, two cases were excluded from the final analysis because of impossible insertion cases to cecum bottom: one bowel adhesion case after operation in group A and one local recurrence of anastomosis in group B. A total of 100 cases were finally evaluated. The 100 patients included 61 (61%) men, and the mean age and standard deviation were  $63 \pm 12$  years. The indications for colonoscopy were postoperative surveillance of anterior resection ( $N = 65$ ) and sigmoidectomy ( $N = 35$ ). The bowel preparation was described as excellent or good in 82 cases (82%) and fair in 18 (18%), respectively (Table 1).

There were no statistically significant differences between the FICE and WL with respect to withdrawal time, lesion

TABLE 1: Patient characteristics.

	Group A (WL-FICE)	Group B (FICE-WL)
Cases	50	50
Male	30	31
Female	20	19
Mean age (yr)	62.7	63.3
Operation history		
Anterior resection	36	29
Sigmoidectomy	14	21
Bowel preparation		
Excellent	23	17
Good	19	23
Fair	8	10

TABLE 2: Comparison FICE with white light.

	FICE	WL
Withdrawal time (sec.)	213	193
(Range)	(90–490)	(79–600)
Detected lesions		
All	65	45
Neoplastic	59 (91%)	38 (84%)
Macroscopic finding		
Flat elevated	53 (90%)	33 (87%)
Polypoid	6 (10%)	5 (13%)
Tumor size		
<5 mm	33 (56%)	24 (63%)
≥5 mm	26 (44%)	14 (37%)

detection, macroscopic finding, and tumor size. Total numbers of detected and removed lesions by FICE and WL colonoscopy were 65 and 45, respectively. Characteristics of the detected neoplastic lesions by FICE and WL colonoscopy were flat elevated: 53 (90%) and 33 (87%) and small (<5 mm): 33 (56%) and 24 (63%), respectively (Table 2).

The miss rate for all polyps with FICE (24%) was significantly less than that with WL (46%) ( $P = 0.03$ ). Among all detected polyps, the number of neoplastic lesions detected by FICE and WL colonoscopy was 59 and 38, respectively. Among 45 neoplastic lesions, which were diagnosed in group B, 34 (76%) lesions were detected at the first FICE withdrawal technique (Table 3). In contrast, in group A (among 52 neoplastic lesions), only 27 (52%) lesions were recognized at the first WL withdrawal technique, and 25 (48%) lesions were detected by the second FICE examination. Significantly more neoplastic lesions were missed by WL compared with FICE system ( $P = 0.02$ ).

#### 4. Discussion

Detection of adenomas is essential at screening colonoscopy, however, the miss rate especially for small and flat lesions remains unacceptably high. According to several reports,

10 to 15% of lesions remains undiagnosed at colonoscopy, even by experienced practitioners. In this pilot study, we investigated the utility of a FICE system on miss rates during colonoscopy and the efficiency of colonoscopy withdrawal. Based on the results of our study, FICE system may be useful for the detection of colorectal adenomas in the right-sided colon compared to WL conventional colonoscopy under high-quality bowel preparation.

The largest advantage of this system may prove to be the ability to perform faster and more efficient examination without the need for additional attachments to the endoscope and without dye spraying or infusion. According to the National Polyp Study (NPS), the incidence of colorectal cancer was decreased by endoscopic intervention. In brief, polypectomy during routine colonoscopy has been shown to prevent the development of colorectal cancer, compared with the incidence of it in reference groups. Therefore, colonoscopy is considered as a gold standard for detection and treatment of colorectal adenomas, however, the conventional colonoscopy technique during withdrawal, even if very careful, cannot detect all lesions, especially flat and small depressed ones. Potential explanations for failure at colonoscopy include poor bowel preparation or inadequately short withdrawal times [15, 16]. Moreover, an important technical factor that determines the detection of lesions is the level of mucosal contrast provided by the imaging method. Low contrast might contribute to the miss rate of small and flat lesions that show only subtle changes in mucosal topography, focal pallor, and marginal irregularity [17, 18].

Endoscopic imaging techniques aimed at early detection of colorectal cancer and its precursors have been developed over the last decade. Techniques that improve the detection of mucosal irregularities, such as pancolonic chromoendoscopy, narrow band imaging (NBI), high-resolution imaging, autofluorescence imaging, and FICE have been applied in a variety of clinical situations to enhance the detection of flat and depressed lesions or to enable histological diagnosis. Many authors have reported that chromoendoscopy is helpful for the detection and detailed morphological assessment of flat and depressed colorectal lesions [19–28]. Pancolonic chromoendoscopy using an indigocarmine diffusion during withdrawal from the cecum, which highlighted subtle mucosal irregularities, has been reported to significantly increase the detection of diminutive, flat neoplastic lesions in the right colon. However, the withdrawal time for the indigocarmine dye spray group was almost twice as long as for the control group.

Computed virtual chromoendoscopy with FICE is a novel optical approach to enhance mucosal contrast [29]. This technique enhances the bandwidth of light components, resulting in dye-less contrast enhancement of mucosal and vascular details. To overcome the problems of conventional chromoendoscopy, another chromoendoscopic techniques FICE and NBI were recently developed. Both techniques are safe, rapid, and easy to apply, and several preliminary studies reported enhancement of vascular and mucosal contrast. The NBI system has been shown to be helpful in visualizing such lesions by improving contrast and is considered to be a new type of optical/digital chromoendoscopy [30, 31].

TABLE 3: Detected lesions in group A and B.

	A (WL-FICE) ( <i>n</i> = 50)	B (FICE-WL) ( <i>n</i> = 50)	<i>P</i> value
Total number of lesions (%)			
First	WL 33 (54)	FICE 37 (76)	<i>P</i> = 0.03
Second	FICE 28 (46)	WL 12 (24)	
Total number of neoplastic lesions (%)			
First	WL 27 (52)	FICE 34 (76)	<i>P</i> = 0.02
Second	FICE 25 (48)	WL 11 (24)	

In particular, magnification using NBI colonoscopy for the observation of the presence of “meshed brown capillary vessels” is extremely useful for distinguishing between neoplastic and nonneoplastic lesions without any dye solution. Regarding polyp detection, however, it is controversial at this moment [32]. Furthermore, during NBI colonoscopy examinations, intestinal fluid was seen as being reddish in color similar to blood. Therefore, proper bowel preparation is one of the limitations when using this system.

In 1989, Miyake et al. [9] developed and reported a new optimal band imaging system, and endoscopic examinations with this optimal band imaging system were developed as FICE after these essential reports. Images acquired by this new system provided better brightness than old fiberscopic images. Preliminary reports showed that in the esophagus, the detection rate for neoplasm of FICE and NBI appears similar to that of conventional chromoendoscopy [33, 34]. In other reports, FICE with high-definition endoscope in colonoscopy or upper GI endoscopy was useful for diagnosis between neoplastic and nonneoplastic lesions [35–37]. Pohl et al. reported that FICE was superior to standard colonoscopy and equivalent to conventional chromoendoscopy for distinguishing neoplastic from nonneoplastic lesions and adenoma detection rate was not improved by FICE compared to WL with targeted indigocarmine spraying [38, 39]. However, there are few prospective studies that have attempted to clarify the usefulness of the adenoma detection rate using FICE system [40].

In this study, a total of 110 lesions from 100 patients were detected and removed endoscopically. Among these lesions, the number of neoplastic lesion detected by FICE and WL was 59 (91%) and 38 (84%), respectively. In contrast, the number of nonneoplastic lesions recognized as a polyp and removed by FICE and WL colonoscopy was only 6 (9%) and 7 (16%), respectively. The lesions we diagnosed and resected in this study with FICE and WL systems were mostly neoplastic ones. However, we consider further investigation is necessary to evaluate the efficiency for differential diagnosis with FICE system. Diminutive flat elevated lesions are thought to be of little clinical significance because such lesions, especially less than 5 mm polyps, are low-grade dysplasia in most cases. Meanwhile, depressed lesions are considered to have a high malignant potential compared to polypoid ones in similar size [41–43]. In this present study, all detected lesions’ macroscopic type was flat elevated or polypoid. Because of low incidence, there were no depressed lesions in this study. However, significantly more

small and/or flat neoplastic lesions were detected by FICE compared with WL colonoscopy. Additionally, the brightness of the image during FICE colonoscopy is sufficient to ensure a good overview in large luminal diameter sections of the bowel. Therefore, FICE colonoscopy is considered to be a promising modality to detect small depressed lesions.

Bowel preparation rate of excellent or good in our study was described more than 80 percent in both group. Negative advocacy piece to improvement in detectability of colorectal polyps using FICE was described in the past report with lower bowel preparation rate of excellent or good less than 75 percent [44]. It is suggested that proper bowel preparation is indispensable to achieve success to detect small colorectal lesions, so we think quality of bowel preparation is very important for full effectiveness of FICE colonoscopy.

There are several limitations in our study. First, this study was performed at a single institute as a pilot study. Our data are precise but it is uncertain whether it would be available for all examiners. Therefore, additional multicenter studies are necessary to clarify the usefulness of FICE system.

Another point worth mentioning is that our study was conducted within the limits of the right colon, which mean withdrawal time were more than three minutes. We selected modified back-to-back colonoscopy in right-side colon. Complete back-to-back colonoscopy may be painful for patients under no sedation and longer procedures because many colonoscopies without sedation are usually performed in Japan. The higher prevalence of flat and diminutive lesions diagnosed in the right colon may be consistent with past descriptions [45, 46]. Furthermore, a higher miss rate of detection has been reported in the right colon compared to the left colon. Therefore, we defined the area from the cecum to the splenic flexure as the target area in our prospective study. We think that it is necessary to evaluate the total colonoscopy using FICE from cecum to rectum as further estimation.

In conclusion, colonoscopy using FICE could beneficially enhance the detection of neoplastic lesions in the right-sided colon, especially flat and/or diminutive adenomatous lesions compared to conventional WL colonoscopy under proper bowel preparation.

## Disclosure

All authors have no financial relationships with a commercial entity producing health-care-related product and/or services relevant to this paper. The part of this study was presented at Asia Pacific Digestive Week 2010 in Kuala Lumpur, Malaysia.

## References

- [1] S. J. Winawer, A. G. Zauber, M. J. O'Brien et al., "Randomized comparison of surveillance intervals after colonoscopic removal of newly diagnosed adenomatous polyps," *New England Journal of Medicine*, vol. 328, no. 13, pp. 901–906, 1993.
- [2] S. J. Winawer, A. G. Zauber, M. N. Ho et al., "Prevention of colorectal cancer by colonoscopic polypectomy," *New England Journal of Medicine*, vol. 329, no. 27, pp. 1977–1981, 1993.
- [3] D. K. Rex, C. S. Cutler, G. T. Lemmel et al., "Colonoscopic miss rates of adenomas determined by back-to-back colonoscopies," *Gastroenterology*, vol. 112, no. 1, pp. 24–28, 1997.
- [4] J. C. Brooker, B. P. Saunders, S. G. Shah et al., "Total colonic dye-spray increases the detection of diminutive adenomas during routine colonoscopy: a randomized controlled trial," *Gastrointestinal Endoscopy*, vol. 56, no. 3, pp. 333–338, 2002.
- [5] D. P. Hurlstone, S. S. Cross, R. Slater, D. S. Sanders, and S. Brown, "Detecting diminutive colorectal lesions at colonoscopy: a randomised controlled trial of pan-colonic versus targeted chromoscopy," *Gut*, vol. 53, no. 3, pp. 376–380, 2004.
- [6] D. K. Rex, V. Chadalawada, and D. J. Helper, "Wide angle colonoscopy with a prototype instrument: impact on miss rates and efficiency as determined by back-to-back colonoscopies," *American Journal of Gastroenterology*, vol. 98, no. 9, pp. 2000–2005, 2003.
- [7] V. P. Deenadayalu, V. Chadalawada, and D. K. Rex, "170 degrees Wide-angle colonoscope: effect on efficiency and miss rates," *American Journal of Gastroenterology*, vol. 99, no. 11, pp. 2138–2142, 2004.
- [8] M. Matsushita, K. Hajiro, K. Okazaki, H. Takakuwa, and M. Tominaga, "Efficacy of total colonoscopy with a transparent cap in comparison with colonoscopy without the cap," *Endoscopy*, vol. 30, no. 5, pp. 444–447, 1998.
- [9] Y. Miyake, T. Sekiya, S. Kubo et al., "A new spectrophotometer for measuring the spectral reflectance of gastric mucous membrane," *Imaging Science Journal*, vol. 37, pp. 134–138, 1989.
- [10] T. Shiobara, S. Zhou, H. Haneishi, N. Tsumura, and Y. Miyake, "Improved color reproduction of electronic endoscopes," *Journal of Imaging Science and Technology*, vol. 40, no. 6, pp. 494–501, 1996.
- [11] N. Tsumura, T. Tanaka, H. Haneishi, and Y. Miyake, "Optimal design of mosaic color filters for the improvement of image quality in electronic endoscopes," *Optics Communications*, vol. 145, no. 1–6, pp. 27–32, 1998.
- [12] T. Shiobara, N. Haneishi, and Y. Miyake, "Color correction for colorimetric color reproduction in an electronic endoscope," *Optics Communications*, vol. 114, no. 1–2, pp. 57–63, 1995.
- [13] T. Sakama, "Fundamental examination that image processing of the stomach mucous membrane which applies the presumption of spectrum reflectance," *Gastrointestinal Endoscopy*, vol. 47, p. 773, 2005.
- [14] "World Health Organization classification of tumours: pathology and genetics of tumours of the digestive system," S. R. Hamilton and L. A. Aaltonen, Eds., pp. 104–119, IARC Press, Lyon, France, 2000.
- [15] R. L. Barclay, J. J. Vicari, A. S. Doughty, J. F. Johanson, and R. L. Greenlaw, "Colonoscopic withdrawal times and adenoma detection during screening colonoscopy," *New England Journal of Medicine*, vol. 355, no. 24, pp. 2533–2541, 2006.
- [16] D. T. Simmons, G. C. Harewood, T. H. Baron et al., "Impact of endoscopist withdrawal speed on polyp yield: implications for optimal colonoscopy withdrawal time," *Alimentary Pharmacology and Therapeutics*, vol. 24, no. 6, pp. 965–971, 2006.
- [17] S. Kudo, H. Kashida, T. Tamura et al., "Colonoscopic diagnosis and management of nonpolypoid early colorectal cancer," *World Journal of Surgery*, vol. 24, no. 9, pp. 1081–1090, 2000.
- [18] D. P. Hurlstone, T. Fujii, and A. J. Lobo, "Early detection of colorectal cancer using high-magnification chromoscopic colonoscopy," *British Journal of Surgery*, vol. 89, no. 3, pp. 272–282, 2002.
- [19] T. Fujii, R. T. Hasegawa, Y. Saitoh et al., "Chromoscopy during colonoscopy," *Endoscopy*, vol. 33, no. 12, pp. 1036–1041, 2001.
- [20] S. Kudo, S. Tamura, T. Nakajima et al., "Diagnosis of colorectal tumorous lesions by magnifying endoscopy," *Gastrointestinal Endoscopy*, vol. 44, pp. 8–14, 1996.
- [21] D. P. Hurlstone, S. S. Cross, I. Adam et al., "A prospective clinicopathological and endoscopic evaluation of flat and depressed colorectal lesions in the United Kingdom," *American Journal of Gastroenterology*, vol. 98, no. 11, pp. 2543–2549, 2003.
- [22] M. Adachi, K. Okinaga, and T. Muto, "Flat adenoma of the large bowel: re-evaluation with special reference to central depression," *Diseases of the Colon and Rectum*, vol. 43, no. 6, pp. 782–787, 2000.
- [23] S. Tanaka, K. Haruma, M. Ito et al., "Detailed colonoscopy for detecting early superficial carcinoma: recent developments," *Journal of Gastroenterology*, vol. 35, no. 12, pp. 121–125, 2000.
- [24] R. Kiesslich, M. Von Bergh, M. Hahn, G. Hermann, and M. Jung, "Chromoendoscopy with indigocarmine improves the detection of adenomatous and nonadenomatous lesions in the colon," *Endoscopy*, vol. 33, no. 12, pp. 1001–1006, 2001.
- [25] M. G. Lapalus, T. Helbert, B. Napoleon, J. F. Rey, P. Houcke, and T. Ponchon, "Does chromoendoscopy with structure enhancement improve the colonoscopic adenoma detection rate?" *Endoscopy*, vol. 38, no. 5, pp. 444–448, 2006.
- [26] B. J. Rembacken, T. Fujii, A. Cairns et al., "Flat and depressed colonic neoplasms: a prospective study of 1000 colonoscopies in the UK," *Lancet*, vol. 355, no. 9211, pp. 1211–1214, 2000.
- [27] T. Matsuda, Y. Saito, K. I. Fu et al., "Does autofluorescence imaging videoendoscopy system improve the colonoscopic polyp detection rate? A pilot study," *American Journal of Gastroenterology*, vol. 103, no. 8, pp. 1926–1932, 2008.
- [28] T. Uraoka, Y. Saito, T. Matsuda et al., "Detectability of colorectal neoplastic lesions using a narrow-band imaging system: a pilot study," *Journal of Gastroenterology and Hepatology*, vol. 23, no. 12, pp. 1810–1815, 2008.
- [29] J. Pohl, A. May, T. Rabenstein, O. Pech, and C. Ell, "Computed virtual chromoendoscopy: a new tool for enhancing tissue surface structures," *Endoscopy*, vol. 39, no. 1, pp. 80–83, 2007.
- [30] Y. Sano, M. Muto, H. Tajiri, A. Ohtsu, and S. Yoshida, "Optical/digital chromoendoscopy during colonoscopy using narrow-band imaging system," *Digestive Endoscopy*, vol. 17, pp. S43–S48, 2005.
- [31] H. M. Chiu, C. Y. Chang, C. C. Chen et al., "A prospective comparative study of narrow-band imaging, chromoendoscopy, and conventional colonoscopy in the diagnosis of colorectal neoplasia," *Gut*, vol. 56, no. 3, pp. 373–379, 2007.
- [32] D. K. Rex and C. C. Helbig, "High yields of small and flat adenomas with high-definition colonoscopes using either white light or narrow band imaging," *Gastroenterology*, vol. 133, no. 1, pp. 42–47, 2007.
- [33] J. Pohl, A. May, T. Rabenstein et al., "Comparison of computed virtual chromoendoscopy and conventional chromoendoscopy with acetic acid for detection of neoplasia in Barrett's esophagus," *Endoscopy*, vol. 39, no. 7, pp. 594–598, 2007.
- [34] M. A. Kara, F. P. Peters, W. D. Rosmolen et al., "High-resolution endoscopy plus chromoendoscopy or narrow-band

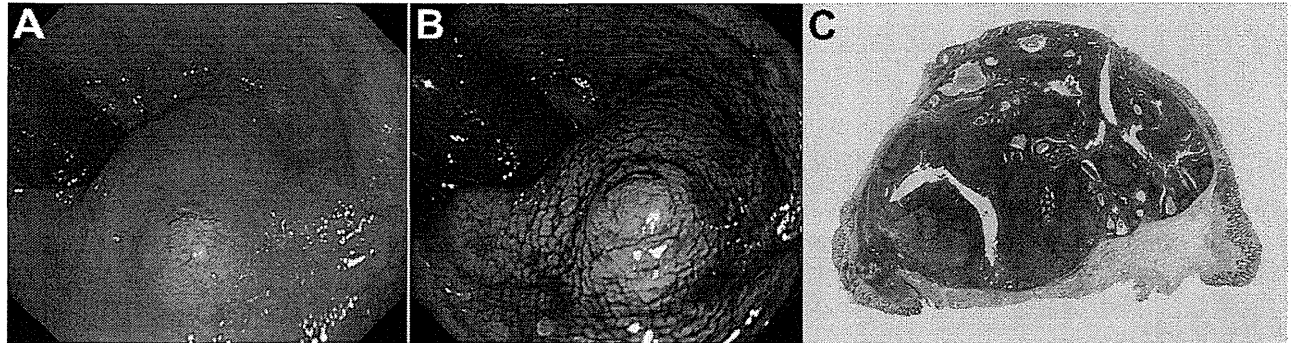


- imaging in Barrett's esophagus: a prospective randomized crossover study," *Endoscopy*, vol. 37, no. 10, pp. 929–936, 2005.
- [35] A. Parra-Blanco, A. Jiménez, B. Rembacken et al., "Validation of Fujinon intelligent chromoendoscopy with high definition endoscopes in colonoscopy," *World Journal of Gastroenterology*, vol. 15, no. 42, pp. 5266–5273, 2009.
- [36] H. Osawa, M. Yoshizawa, H. Yamamoto et al., "Optimal band imaging system can facilitate detection of changes in depressed-type early gastric cancer," *Gastrointestinal Endoscopy*, vol. 67, no. 2, pp. 226–234, 2008.
- [37] R. Mouri, S. Yoshida, S. Tanaka, S. Oka, M. Yoshihara, and K. Chayama, "Evaluation and validation of computed virtual chromoendoscopy in early gastric cancer," *Gastrointestinal Endoscopy*, vol. 69, no. 6, pp. 1052–1058, 2009.
- [38] J. Pohl, M. Nguyen-Tat, O. Pech, A. May, T. Rabenstein, and C. Ell, "Computed virtual chromoendoscopy for classification of small colorectal lesions: a prospective comparative study," *American Journal of Gastroenterology*, vol. 103, no. 3, pp. 562–569, 2008.
- [39] J. Pohl, E. Lotterer, C. Balzer et al., "Computed virtual chromoendoscopy versus standard colonoscopy with targeted indigocarmine chromoscopy: a randomised multicentre trial," *Gut*, vol. 58, no. 1, pp. 73–78, 2009.
- [40] J. M. Cha, J. I. Lee, K. R. Joo, S. W. Jung, and H. P. Shin, "A prospective randomized study on computed virtual chromoendoscopy versus conventional colonoscopy for the detection of small colorectal adenomas," *Digestive Diseases and Sciences*, vol. 55, no. 8, pp. 2357–2364, 2010.
- [41] Y. Saitoh, I. Waxman, A. B. West et al., "Prevalence and distinctive biologic features of flat colorectal adenomas in a North American population," *Gastroenterology*, vol. 120, no. 7, pp. 1657–1665, 2001.
- [42] S. Tsuda, B. Veress, E. Tóth, and F. T. Fork, "Flat and depressed colorectal tumours in a southern Swedish population: a prospective chromoendoscopic and histopathological study," *Gut*, vol. 51, no. 4, pp. 550–555, 2002.
- [43] R. Soetikno, S. Friedland, T. Kaltenbach, K. Chayama, and S. Tanaka, "Nonpolypoid (flat and depressed) colorectal neoplasms," *Gastroenterology*, vol. 130, no. 2, pp. 566–576, 2006.
- [44] S. J. Chung, D. Kim, J. H. Song et al., "Efficacy of computed virtual chromoendoscopy on colorectal cancer screening: a prospective, randomized, back-to-back trial of Fuji Intelligent Color Enhancement versus conventional colonoscopy to compare adenoma miss rates," *Gastrointestinal Endoscopy*, vol. 72, no. 1, pp. 136–142, 2010.
- [45] I. K. Woolfson, G. J. Eckholdt, C. R. Wetzel et al., "Usefulness of performing colonoscopy one year after endoscopic polypectomy," *Diseases of the Colon and Rectum*, vol. 33, no. 5, pp. 389–393, 1990.
- [46] B. Hofstad, M. Vatn, S. Larsen, and M. Osnes, "Growth of colorectal polyps: recovery and evaluation of unresected polyps of less than 10 mm, 1 year after detection," *Scandinavian Journal of Gastroenterology*, vol. 29, no. 7, pp. 640–645, 1994.

## Dome-Type Carcinoma of the Colon Masquerading a Submucosal Tumor

MASAYOSHI YAMADA,\* SHIGEKI SEKINE,† and TAKAHISA MATSUDA\*

\*Endoscopy Division, National Cancer Center Hospital, †Molecular Pathology Division, National Cancer Center Research Institute, Tokyo, Japan



A 76-year-old woman was referred for treatment of a rectal submucosal tumor (SMT). Endoscopy revealed a broad-based elevated lesion, 10 mm in diameter in the lower rectum (Figure A). This lesion appeared to be covered entirely with non-neoplastic mucosa showing mild discoloration (Figure B). A tiny whitish exudate was observed on the top of the lesion. Based on these endoscopic findings, we diagnosed an SMT and completely removed the lesion by endoscopic submucosal resection with a ligation device.<sup>1</sup>

Histologically, the resected specimen was a well-differentiated adenocarcinoma associated with a dense lymphocytic infiltration (Figure C). The tumor showed expansive growth and no desmoplastic stroma was observed. There were well-developed germinal centers in the lymphoid stroma. Consistent with the endoscopic findings, the tumor was covered mostly with non-neoplastic mucosa. The tumor was exposed to the surface in only a narrow area of 2 mm. Because desmin staining showed muscularis mucosae just below the lymphoid stroma, this tumor was diagnosed as intramucosal cancer and the patient had no additional treatment besides regular endoscopic surveillance. This patient remained disease free 4 years after the endoscopic submucosal resection with a ligation device.

Lymphoid stroma generally is known as a feature of cancers with microsatellite instability and those related to Epstein-Barr virus (EBV) infection. However, an immunohistochemical analysis showed retained expression of 4 mismatch repair proteins (MLH1, PMS2, MSH2, and MSH6) and *in situ* hybridization for EBV-encoded small RNA-1 was negative. These findings indicate the tumor was microsatellite stable and was unrelated to EBV infection.

These histologic features are consistent with those of dome-type carcinoma (DC), which first was reported by Jass et al<sup>2</sup> in 2000 as a rare variant of colorectal adenocarcinoma characterized by a dense lymphoid stroma and expansive growth. Because of the intimate relationship between the neoplastic glands and lymphoid tissue, it has been suggested that DC exhibits a differentiation to dome epithelium of gut-associated lymphoid tissue.

From previous reports, DC also has been known to show characteristic endoscopic findings.<sup>3</sup> The common endoscopic appearances are plaque-like, sessile polyp, and SMT. Two of 10 cases previously reported were described as an SMT.<sup>4,5</sup>

Because of their expansive growth pattern, DCs may present as SMT-like lesions.<sup>4</sup> However, DCs mostly have a component of mucosal dysplasia on their surface, which allows an endoscopic diagnosis of an epithelial neoplasm.<sup>5</sup> The present case indicates that it may be difficult to discriminate DC from SMT when the area of mucosal dysplasia is small and indistinct.

## References

1. Ono A, Fujii T, Saito Y, et al. Endoscopic submucosal resection of rectal carcinoid tumors with a ligation device. *Gastrointest Endosc* 2003;57:583–587.
2. Jass JR, Constable L, Sutherland R, et al. Adenocarcinoma of colon differentiating as dome epithelium of gut-associated lymphoid tissue. *Histopathology* 2000;36:116–120.
3. Coyne JD. Dome-type colorectal carcinoma: a case report and review of the literature. *Colorectal Dis* 2012;14:e360–e362.
4. De Petris G, Lev R, Quirk DM, et al. Lymphoepithelioma-like carcinoma of the colon in a patient with hereditary nonpolyposis colorectal cancer. *Arch Pathol Lab Med* 1999;123:720–724.
5. Yamada M, Sekine S, Matsuda T, et al. Dome-type carcinoma of the colon; a rare variant of adenocarcinoma resembling a submucosal tumor: a case report. *BMC Gastroenterol* 2012;12:21.

## Acknowledgments

The authors thank Dr Patrick B. Allen (Consultant Gastroenterologist, Ulster Hospital, Belfast, NI, UK) for editing this manuscript.

## Conflicts of interest

The authors disclose no conflicts.

© 2013 by the AGA Institute

1542-3565/\$36.00

<http://dx.doi.org/10.1016/j.cogh.2012.11.009>

CASE REPORT

Open Access

# Dome-type carcinoma of the colon; a rare variant of adenocarcinoma resembling a submucosal tumor: a case report

Masayoshi Yamada<sup>1,3</sup>, Shigeki Sekine<sup>2</sup>, Takahisa Matsuda<sup>3,5\*</sup>, Masayuki Yoshida<sup>1</sup>, Hirokazu Taniguchi<sup>1</sup>, Ryoji Kushima<sup>1</sup>, Taku Sakamoto<sup>3</sup>, Takeshi Nakajima<sup>3</sup>, Yutaka Saito<sup>3</sup> and Takayuki Akasu<sup>4</sup>

## Abstract

**Background:** Dome-type carcinoma (DC) is a distinct variant of colorectal adenocarcinoma and less than 10 cases have been described in the literature. Most of the previously reported cases were early lesions and no endoscopic observations have been described so far. We herein report a case of a DC invading the subserosal layer, including endoscopic findings.

**Case presentation:** A highly elevated lesion in the transverse colon was diagnosed by colonoscopy in a 77-year-old man. The tumor appeared to be similar to a submucosal tumor (SMT), however, a demarcated area of reddish and irregular mucosa was observed at the top of the tumor. There were no erosions or ulcers. Laparoscopic-assisted right hemicolectomy was performed and pathological examination revealed a well-circumscribed tumor invading the subserosal layer. The tumor was a well-differentiated adenocarcinoma associated with a dense lymphocytic infiltration and showed expansive growth. The overlying mucosal layer showed high-grade dysplasia.

**Conclusion:** The present lesion was diagnosed as a DC of the colon invading the subserosal layer. Because the association of mucosal dysplasia is common in DCs, the detection of dysplastic epithelium would be important to discriminate DCs from SMTs.

**Keywords:** Colorectal carcinoma, Gut-associated lymphoid tissue, Dome-type carcinoma

## Background

Dome-type carcinoma (DC) is a rare variant of colorectal adenocarcinoma that is characterized by well or moderately differentiated histology, expansive growth, and dense lymphoid stroma [1]. Since Jass *et al.* [1,2] reported this lesion as a distinct variant of adenocarcinoma, less than 10 cases have been reported and most of them are early lesions limited to the submucosal layer [3,4]. Based on the phenotypical features of DCs, including the intimate association with lymphoid tissue, the presence of intraepithelial B-lymphocytes and the lack of goblet cells, DC has been suggested to derive from M-cells of the gut-associated lymphoid tissue [1].

We herein report a case, along with the endoscopic findings, of a DC invading the subserosal layer.

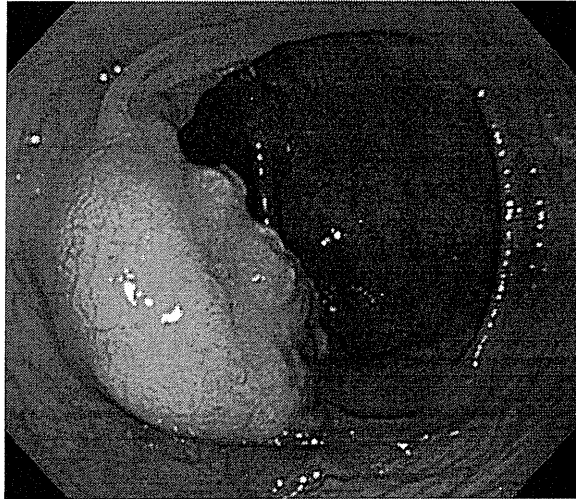
## Case presentation

A 77-year-old man suffered abdominal discomfort and underwent a total colonoscopy. The colonoscopy identified a highly elevated lesion, 30 mm in diameter, in the transverse colon (Figure 1). The tumor appeared to be similar to a submucosal tumor (SMT) with a sharply raised edge and a bridging fold. Examination with indigo carmine dye showed that the base of the lesion was covered with normal mucosa (Figure 2). However, a demarcated area of reddish and irregular mucosa was observed at the top of the tumor (Figure 3). There were no erosions or ulcers. The biopsy specimen taken from the top of the lesion revealed well-differentiated adenocarcinoma. Finally, the lesion was diagnosed as adenocarcinoma confined to the transverse colon and a laparoscopic-assisted right hemicolectomy was performed.

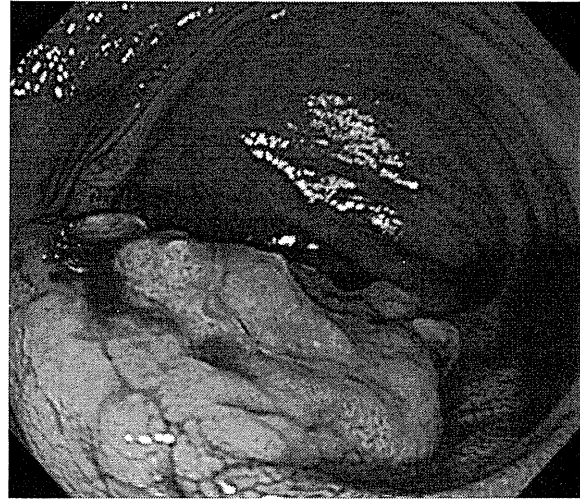Pathological examination revealed a well-circumscribed tumor invading the subserosal layer (Figure 4).

\* Correspondence: tamatsud@ncc.go.jp

<sup>3</sup>Endoscopy Division, National Cancer Center Hospital, Tokyo, Japan  
Full list of author information is available at the end of the article



**Figure 1** Conventional endoscopic image showing a submucosal tumor-like lesion of 30 mm in diameter in a 77-year-old man. A reddish rough mucosa can be seen on the top.



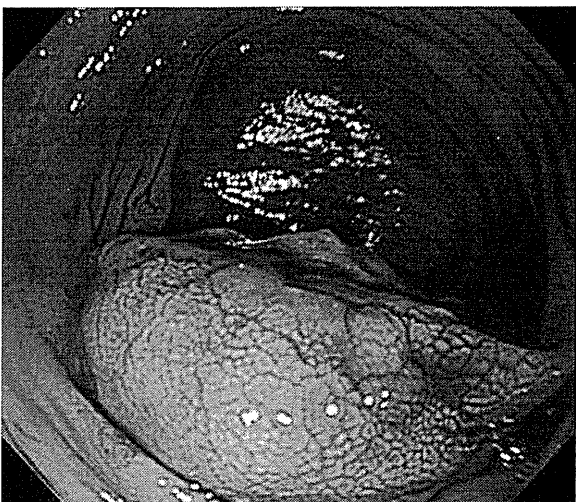
**Figure 3** The top of the tumor, showing a well demarcated irregular mucosa.

The tumor was a well-differentiated adenocarcinoma associated with a dense lymphocytic infiltration. The tumor showed expansive growth and no desmoplastic stroma was seen (Figure 5). Many of the tumor glands were cystically dilated and contained eosinophilic debris (Figure 6). The lymphoid stroma surrounding the neoplastic glands contained numerous germinal centers. The overlying mucosal layer showed high-grade dysplasia (Figure 7). Immunohistochemically, tumor cells were positive for 4 mismatch repair proteins (MLH1, PMS2, MSH2, MSH6), suggesting microsatellite stable phenotypes. In situ hybridization for Epstein-Barr virus (EBV)

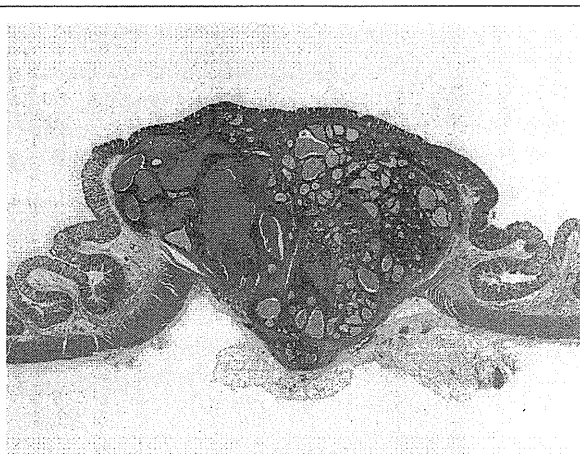
-encoded small RNA-1 was negative. No metastasis was detected in any of the 19 dissected lymph nodes. One and a half years after the resection, no recurrence was detected by follow up computed tomography or endoscopic examination.

### Conclusions

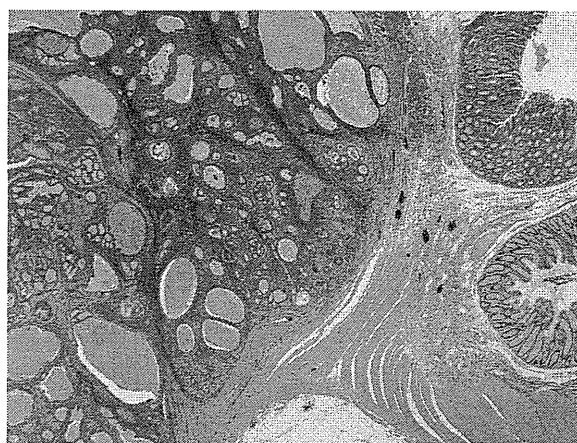
Jass *et al.* [1,2] reported 3 cases of "Adenocarcinoma of colon differentiating as dome epithelium of gut-associated lymphoid tissue" as a distinct variant of colon cancer. The reported lesions were characterized by well and/or moderately differentiated histology, expansive growth, confinement to an aggregate of lymphoid tissue, and cystically dilated tumor glands containing an abundance of necrotic debris. Because of the intimate



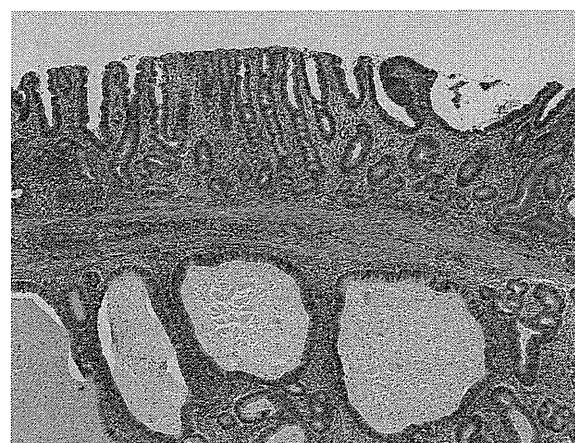**Figure 2** Endoscopic image after spraying with indigo carmine dye. The base of the tumor is covered with non-neoplastic mucosa.



**Figure 4** Panoramic view of the tumor described. A well-demarcated tumor grows into the subserosal layer (H&E).



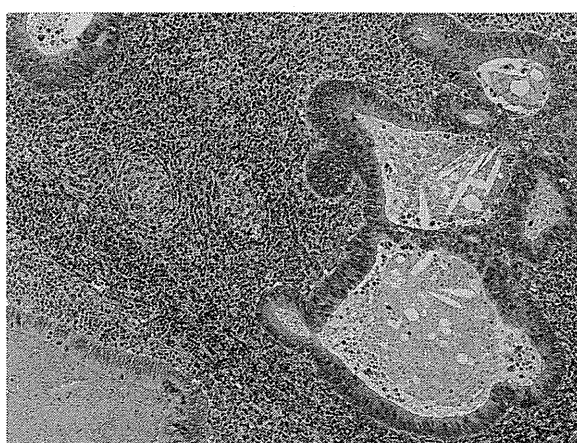
**Figure 5** The tumor associated with lymphoid stroma showing expansive growth. No desmoplastic stroma is observed (H&E, orig. mag.  $\times 12.5$ ).



**Figure 7** Overlying mucosa shows high-grade dysplasia. Invasive adenocarcinoma associated with prominent lymphoid stroma was observed in the submucosal layer. Note the intact muscularis mucosae (H&E, orig. mag.  $\times 40$ ).

relationship between the malignant epithelium and lymphoid tissue, they suggested that the tumor might be arising from the dome epithelium overlying gut-associated lymphoid tissue. After similar tumors were reported, the term DC was established [3-8].

Generally, prominent lymphocytic infiltration is known as a feature of colorectal cancers with a microsatellite instability-high phenotype and tumors with EBV infection. However, the present case, and the majority of the previously reported DCs, did not show evidence for microsatellite instability, as examined by either microsatellite instability test or immunohistochemistry for mismatch repair proteins, and EBV infection [9]. The lack of evidence for microsatellite instability and EBV infection is consistent with the concept that lymphoid



**Figure 6** The tumor is a well differentiated adenocarcinoma surrounded by dense lymphoid tissue with follicles. Neoplastic glands contain eosinophilic necrotic debris (H&E, orig. mag.  $\times 100$ ).

infiltration associated with DCs reflects the nature of their tissue of origin, which is the dome epithelium.

All but one previously reported DCs were early cancers limited to the submucosal layer [3]. It has been suggested that advanced DC is rare because DC might eventually progress to usual-type adenocarcinoma [7]. Consistent with this idea, 4 of 9 previously reported DCs, including one lesion that invaded the muscularis propria, were associated with a usual-type adenocarcinoma component that is characterized by the association with a desmoplastic reaction and the lack of lymphoid stroma [2,4,6,7]. However, the present case indicates that, in rare instances, DC can deeply invade the bowel wall in the absence of progression to usual-type adenocarcinoma.

Endoscopically, the present case resembled SMT, reflecting the expansive growth of the tumor. However, while the base of the lesion was covered with non-neoplastic mucosa, an area of mucosal dysplasia could be endoscopically detected on the top of the lesion, and a biopsy taken from this area allowed a diagnosis of adenocarcinoma. Because the previously reported DCs also lacked erosion or ulceration and were associated with mucosal dysplasia [2-4,7], the detection of dysplastic epithelium would be important to discriminate DCs from SMTs.

Even though the current classifications do not recognize DC as a distinct histological subtype, the present and previous reports illustrated peculiar histological and clinical characteristics of DC. Further accumulation of cases and phenotypical characterization, including the potential relationship to M-cells, may establish DC as a distinct subtype of colorectal adenocarcinoma.



## Consent

Written informed consent was obtained from the patient for publication of this case report and any accompanying images. A copy of the written consent is available for review by the editor-in-chief of this journal.

## Abbreviations

DC: Dome-type carcinoma; SMT: Submucosal tumor; EBV: Epstein-Barr virus.

## Author details

<sup>1</sup>Pathology Division, National Cancer Center Hospital, Tokyo, Japan. <sup>2</sup>Molecular Pathology Division, National Cancer Center Research Institute, Tokyo, Japan. <sup>3</sup>Endoscopy Division, National Cancer Center Hospital, Tokyo, Japan. <sup>4</sup>Colorectal Surgery Division, National Cancer Center Hospital, Tokyo, Japan. <sup>5</sup>Endoscopy Division, National Cancer Center Hospital, 5-1-1 Tsukiji, Chuo-ku, Tokyo 104-0045, Japan.

## Authors' contributions

MY for design and drafting of the manuscript; Dr. SS for the concept and the revision of the manuscript and the pathological diagnosis; Dr. TM for the revision of the manuscript and the supervision; Drs. MY, HT, and RK for the pathological diagnosis; Drs. TS, TN and YS for the endoscopic diagnosis; Dr. TA for the surgical treatment. All authors read and approved the final manuscript.

## Competing interests

The authors declare that they have no competing interests.

Received: 20 October 2011 Accepted: 8 March 2012

Published: 8 March 2012

## References

1. Jass JR, Constable L, Sutherland R, Winterford C, Walsh MD, Young J, Leggett BA: Adenocarcinoma of colon differentiating as dome epithelium of gut-associated lymphoid tissue. *Histopathology* 2000, **36**(2):116-120.
2. Clouston AD, Clouston DR, Jass JR: Adenocarcinoma of colon differentiating as dome epithelium of gut-associated lymphoid tissue. *Histopathology* 2000, **37**(6):567.
3. Stewart CJ, Hillery S, Newman N, Platell C, Ryan G: Dome-type carcinoma of the colon. *Histopathology* 2008, **53**(2):231-234.
4. Coyne JD: Dome-type colorectal carcinoma; a case report and review of the literature. *Colorectal Dis*.
5. de Petris G, Lev R: Adenocarcinoma of colon associated with gut-associated lymphoid tissue. *Histopathology* 2000, **37**(6):566.
6. De Petris G, Lev R, Quirk DM, Ferbend PR, Butmarc JR, Elenitoba-Johnson K: Lymphoepithelioma-like carcinoma of the colon in a patient with hereditary nonpolyposis colorectal cancer. *Arch Pathol Lab Med* 1999, **123**(8):720-724.
7. Asmussen L, Pachler J, Holck S: Colorectal carcinoma with dome-like phenotype: an under-recognised subset of colorectal carcinoma? *J Clin Pathol* 2008, **61**(4):482-486.
8. Rubio CA, Lindh C, Bjork J, Tornblom H, Befrits R: Protruding and non-protruding colon carcinomas originating in gut-associated lymphoid tissue. *Anticancer Res* 2010, **30**(7):3019-3022.
9. Bellizzi AM, Frankel WL: Colorectal cancer due to deficiency in DNA mismatch repair function: a review. *Adv Anat Pathol* 2009, **16**(6):405-417.

## Pre-publication history

The pre-publication history for this paper can be accessed here:  
<http://www.biomedcentral.com/1471-230X/12/21/prepub>

doi:10.1186/1471-230X-12-21

**Cite this article as:** Yamada et al.: Dome-type carcinoma of the colon; a rare variant of adenocarcinoma resembling a submucosal tumor: a case report. *BMC Gastroenterology* 2012 **12**:21.

**Submit your next manuscript to BioMed Central  
and take full advantage of:**

- Convenient online submission
- Thorough peer review
- No space constraints or color figure charges
- Immediate publication on acceptance
- Inclusion in PubMed, CAS, Scopus and Google Scholar
- Research which is freely available for redistribution

Submit your manuscript at  
[www.biomedcentral.com/submit](http://www.biomedcentral.com/submit)



# ENDOSCOPY CORNER

## Efficacy of Endoscopic Mucosal Resection With Circumferential Incision for Patients With Large Colorectal Tumors

TAKU SAKAMOTO, TAKAHISA MATSUDA, TAKESHI NAKAJIMA, and YUTAKA SAITO

*Endoscopy Division, National Cancer Center Hospital, Tokyo, Japan*

**BACKGROUND & AIMS:** Treatment of large colorectal neoplasms (>20 mm in diameter) by conventional endoscopic mucosal resection (EMR) often results in piecemeal resection that requires further intervention. We evaluated the efficacy of EMR with circumferential incision (CEMR). **METHODS:** From March 2008–July 2009, we resected 24 large colorectal neoplasms measuring 20–40 mm in diameter by using the CEMR technique. CEMR was performed by using a ball-tip bipolar needle knife with a snaring technique. After the injection of glycerol into the submucosal layer, a circumferential incision was made, and the neoplasm was resected by snaring. All lesions that showed a noninvasive pattern were diagnosed by magnifying chromoendoscopy as adenomas or intramucosal or submucosal superficial cancers. The number of en bloc resections and complications and the overall procedure time were determined. **RESULTS:** The proportions of en bloc and 2-piece resections by CEMR were 67% (16/24) and 17% (4/24), respectively. The median (interquartile range) time for CEMR completion was 40 minutes (30–63 minutes). No postsurgery complications occurred in any patient. **CONCLUSIONS:** CEMR might provide acceptable clinical outcomes for patients with large colorectal neoplasms. It results in a low incidence of incomplete treatments and low risk of complications.

**Keywords:** Endoscopic Submucosal Dissection; Early Colorectal Cancer; Therapy.

Endoscopic mucosal resection (EMR) of colorectal neoplasms has attained wide acceptance because of its attractive clinical advantages of simplicity, rapidity, and low complication rates.<sup>1-7</sup> However, lesions exceeding 20 mm in diameter must often be removed in a piecemeal fashion.<sup>8-10</sup> The rate of recurrence of these tumors is higher than that of those resected en bloc.<sup>11-14</sup> Most residual or recurrent lesions after piecemeal EMR (EPMR) are considered to occur because of residual tissues in the outer and inner resection margins. Thus, the incidence of these lesions is expected to increase as the number of resected specimens increases.

Endoscopic submucosal dissection (ESD) is an established therapeutic technique for the treatment of gastrointestinal neoplasms. Because it is typically completed as en bloc resection, this technique provides a complete specimen for precise histopathologic evaluation.<sup>14-16</sup> Several reports have indicated that the frequency of recurrence with ESD is clearly lower than that with piecemeal EMR.<sup>13</sup> However, owing to its technical diffi-

culty, longer procedure time, and increased risk of perforation, ESD is not as widely used in the treatment of colorectal neoplasms as in gastric cancers.<sup>17,18</sup>

Although the circumferential incision made during an ESD procedure after efficient submucosal injection is considered to be relatively clinically insignificant, reducing the complexity of the technical processes involved in submucosal dissection might decrease the overall risk of this procedure. One variation of this procedure is conventional EMR with circumferential incision (CEMR), which was first reported as endoscopic resection with local injection of hypertonic saline-epinephrine by Hirao et al<sup>19</sup> in 1986. The application of this technique to early gastric cancer has also been reported.<sup>20-22</sup>

CEMR might enable en bloc resection or at least fewer piecemeal resections for large colorectal neoplasms in a manner that is both safe and relatively rapid. Here we assessed the clinical outcome of CEMR in patients with relatively large neoplasms.

### Methods

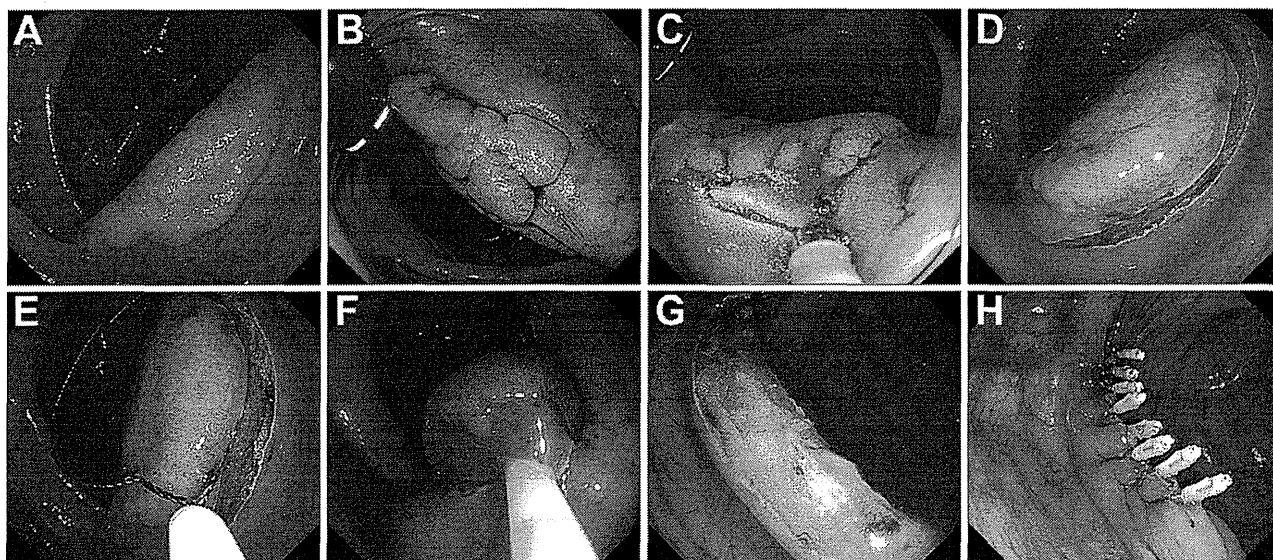
We retrospectively analyzed the data of all patients undergoing endoscopic treatment for neoplastic lesions >20 mm in size at the National Cancer Center Hospital from March 2008–July 2009. Written informed consent to participate was obtained from all patients who underwent colonoscopy examination or any form of treatment. CEMR was performed at our institution according to the following inclusion criteria, which partially overlap with those for ESD: lesions with a diameter of 20–40 mm (technically unsuitable for conventional EMR) that displayed a type V pit with a noninvasive pattern. Patients with lesions displaying an invasive pattern or type III/IV pit under magnifying chromoendoscopy and those whose lesions were non-neoplastic, such as large hyperplastic polyps and recurrent/residual tumors, were excluded.<sup>23</sup> Two hundred thirty-six lesions >20 mm in diameter were resected by endoscopy (conventional EMR, CEMR, or ESD). Of the 236 lesions, 39 displaying type III/IV pit on magnifying chromoendoscopy were resected by conventional EMR (en bloc, 26%; piecemeal,

**Abbreviations used in this paper:** CEMR, endoscopic mucosal resection with circumferential incision; EMR, endoscopic mucosal resection; EPMR, endoscopic piecemeal mucosal resection; ESD, endoscopic submucosal dissection; IQR, interquartile range.

© 2012 by the AGA Institute

1542-3565/\$36.00

doi:10.1016/j.cgh.2011.10.007



**Figure 1.** (A, B) Flat elevated lesion (30 mm) located in the sigmoid colon. (C, D) After submucosal injection of glycerol, a circumferential incision was made by using a BB knife. (E, F) After additional submucosal injection, a snaring technique was applied to achieve complete removal. (G) En bloc resection was achieved with no complications. (H) The mucosal defect was closed completely by using metallic endoclips.

74%). Twenty-four other lesions were resected by CEMR and 173 by ESD.

All procedures were performed by 2 colonoscopists. T.M. had performed >5000 colonoscopies and therapeutic procedures; T.S. was a trainee at the National Cancer Center Hospital and had performed approximately 500 colonoscopies with conventional EMR and >30 colorectal and 50 gastric ESDs. In this study, T.M. performed 16 CEMR procedures, and T.S. performed 8. With regard to the endoscopic management for surveillance of residual or recurrent tumors after resection, follow-up colonoscopy was performed at 6 months in all patients who underwent piecemeal EMR and at 12 months in those who underwent en bloc resection. A follow-up colonoscopy consisted mainly of total colonoscopy focused primarily on the endoscopic treatment site and the scar site as detected by chromoendoscopy with magnification. In the absence of recurrent or residual tumor, a second colonoscopic surveillance was performed 12 months after the first one. On detection of the recurrent or residual tumor, a second surveillance was performed 6 months after the first one, with additional endoscopic treatment.

### CEMR Technique

The CEMR technique is described in Figure 1. Glycerol is first injected into the submucosal layer around the lesion. After the injection, a circumferential incision of the mucosa is made by using a ball-tip bipolar needle knife (BB knife; Zeon Medical Institute, Tokyo, Japan) 2 mm beyond the tumor margin. After completion of the incision, an additional submucosal injection of a relatively large volume (10–20 mL) of glycerol is administered to maintain elevation of the lesion before initiating snaring. After the lesion is suitably elevated, the snare is placed around it via the circumferential incision and tightened. To prevent perforation, the snare is then loosened slightly under inflation to avoid grasping the muscular layer. The lesion is then removed by a conventional snaring technique, primarily

with a 25-mm Snare Master or a 20-mm Spiral Snare (Olympus, Co, Tokyo, Japan). The electric current used for the circumferential incision is set to the endocut mode (effect 3, output: 50 W, ERBE ICC-200; ERBE, Tübingen, Germany), and snaring is conducted in either the same mode with 120-W output or in forced coagulation mode with 50-W output. If the lesion is ultimately judged unresectable by this procedure, the treatment strategy is changed to ESD.

### Pathologic Evaluation

All resected specimens were fixed in 10% formalin, cut into 2-mm slices, and then microscopically evaluated for histologic type, depth of invasion, and cut margins. Lesions resected in a piecemeal fashion were reconstructed faithfully on the basis of the mirror endoscopic images obtained before treatment and fixed in formalin.

### Statistical Analysis

All values in this study are presented as median (interquartile range [IQR]). All statistical analyses were performed by using Stata version 10.0 (StataCorp, College Station, TX).

### Results

The clinicopathologic features and outcomes are summarized in Tables 1 and 2, respectively. Of the 24 patients, 10 (42%) were men, and the median (IQR) age was 69 years (59–75 years). Three lesions were located in the cecum, 6 in the ascending colon, 3 in the transverse colon, 3 in the descending colon, 4 in the sigmoid colon, and 5 in the rectum. Morphologically, 11 were polypoid (0-Is, Is+IIa), and 12 were elevated (0-IIa, IIa+IIc) and depressed (0-IIc). Of all the patients, only 1 (4%) was intraoperatively switched to an ESD procedure because of unresectability. The median (IQR) time for CEMR completion was 40 minutes (30–63 minutes), and the respective rates of en bloc and 2-piece resection by CEMR were 67% (16/24) and 17%



**Table 1.** Characteristics of Patients and Lesions

Characteristic	Value
Median age, y (IQR)	69 (59–75)
Gender (male/female)	10/14
Median tumor size, mm (IQR)	25 (25–32.5)
Location, n (%)	
Colon	19 (79)
Rectum	5 (21)
Macroscopic type, n (%)	
Protruded, sessile (0-Is, Is+IIa)	11 (46)
Superficial, elevated (0-IIa, IIa+IIc)	12 (50)
Superficial, shallow, depressed (0-IIc)	1 (4)
Invasion depth, n (%)	
LGIN	7 (29)
HGIN	17 (71)
Submucosa	0 (0)

HGIN, high-grade intraepithelial neoplasia; LGIN, low-grade intraepithelial neoplasia.

(4/24), respectively. The en bloc resection rate was similar between operators; that of T.M. was 69% (11/16) and that of T.S. was 63% (5/8) ( $P = .585$ ). The clinical characteristics of the patients receiving en bloc and piecemeal resection are summarized in Table 3. Regarding tumor size, almost all en bloc resected tumors were <30 mm in diameter, whereas most piecemeal EMR cases were >30 mm. No complications such as perforation, bleeding, or other clinical symptoms such as severe abdominal pain or high fever related to CEMR were observed. Histopathologically, 17 patients (71%) had high-grade intraepithelial neoplasia, and 7 (29%) had low-grade intraepithelial neoplasia. On histopathologic evaluation of the cut margin, R0 resection was achieved in 4 cases, whereas 4 were R1 and 16 were Rx. Of all the 16 en bloc resection cases, 4 were evaluated as R0, 4 as R1, and 8 as Rx procedures. No recurrence or residual tumors were noted on follow-up colonoscopy between 6 and 12 months after CEMR.

## Discussion

Here we assessed the clinical outcome of CEMR in patients with relatively large neoplasms. The advantages of

**Table 2.** Summary of Clinical Outcomes

Parameter	Value
Complete CEMR, n (%)	23 (96)
Change to ESD, n (%)	1 (4)
Median CEMR procedure duration, min (IQR)	40 (30–63)
En bloc or piecemeal CEMR, n (%)	
En bloc	16 (67)
2-piece	4 (17)
3-piece	2 (1)
4-piece	1 (4)
Complications, n (%)	
Perforation	0 (0)
Delayed bleeding	0 (0)
Resection status	
R0	4 (17)
R1 <sup>a</sup>	4 (17)
Rx	16 (66)
Incidence of recurrence, n (%)	0 (0)

<sup>a</sup>All R1 cases were lateral margin (+).

**Table 3.** Clinical Characteristics Between En Bloc Resection and Piecemeal EMR

	En bloc	Piecemeal EMR
Tumor size, n (%)		
20–30 mm	15 (94)	3 (38)
31–40 mm	1 (6)	5 (62)
Location, n (%)		
Colon	11 (69)	8 (100)
Rectum	5 (31)	0 (0)
Macroscopic type, n (%)		
Protruded, sessile (0-Is, Is+IIa)	8 (50)	3 (38)
Superficial, elevated (0-IIa, IIa+IIc)	7 (44)	5 (62)
Superficial, shallow, depressed (0-IIc)	1 (6)	0 (0)

using this procedure over conventional EMR for large sessile lesions has already been reported by Móss et al.<sup>24</sup> In that study, the rate of en bloc resection (70%) reflected the convenience of its use for imaginary lesions of porcine colon sized 40 × 40 mm. In our study, the en bloc resection rate was unexpectedly low (68%), yet the objective lesions were relatively smaller than those of the study by Moss et al. Thus, the low en bloc resection rate might have been attributable to the lesion configuration. Half of the cases were 0-IIa type lesions or the so-called laterally spreading tumors (nongranular type); these are sometimes difficult to raise by submucosal injection because of the development of submucosal fibrosis, and they have recently been considered as good indicators of the need for ESD. Combining the number of en bloc and 2-piece resections increases the total rate of these procedures to 84%. We believe that few-piece resections might be clinically acceptable because the resected specimen can be retrieved completely, and the lesion is easy to reconstruct from 2 or 3 specimens, allowing the almost complete evaluation of histopathologic features from the reconstructed lesion. Moreover, this procedure was used for lesions diagnosed as noninvasive neoplasms by pit pattern analysis, which is considered the most reliable method with regard to the evaluation of depth. Taken together, our findings suggest that CEMR might be efficient for the resection of large colorectal tumors that are difficult to remove via en bloc resection by conventional EMR.

Achievement of R0 resection with an adequate circumferential horizontal margin is the most desirable result from a curative point of view. However, most colorectal neoplasms are considered to develop via the adenoma-carcinoma sequence, and most lesions arise from the epithelium without chronic inflammation such as ulcerative colitis. Compared with early gastric cancers, the lesion margin can be recognized clearly, and marking during the endoscopic procedure is not required. In our series, the R0 resection rate was only 17% despite the achievement of en bloc resection. We made a marginal incision 2 mm beyond the tumor margin in both CEMR and ESD procedures without marking coagulation. As a consequence, the margin of the lesion might be easily affected by burning. In the case of detection of any burning by histologic analysis in any of the sliced tissue specimens, the horizontal margin was evaluated as “tumor cell (±).” This might explain the occurrence of Rx resection cases despite achievement of en bloc resection. However, we do not consider this issue to be clinically significant. Because the margin of a colorectal neoplasm is very easily detected by indigo-carmin spraying, it can be recognized dur-

ing marginal incision. Hence, a vertical margin that was negative for tumor cells and whose depth was limited to the intramucosa and superficial submucosa (<1000  $\mu\text{m}$ ) without lymphovascular infiltration by histologic evaluation was considered a curative resection. Nevertheless, no sign of recurrence was seen at the first follow-up colonoscopy in any case, suggesting that the pathologic findings for the vertical margin of the resected specimen are of no clinical significance. Moreover, we previously reported that most residual tumors can be cured with additional endoscopic treatment such as the simple coagulation method or conventional polypectomy, despite the presence of recurrent or residual tumor, provided proper surveillance is conducted after piecemeal EMR.

In addition to its reduced procedure time and decreased risk of perforation compared with ESD, owing to the omission of the submucosal dissection process, our CEMR procedure has several other advantages. First, the addition of a circumferential incision might reduce the risk of residual tumors because residual or recurrent tumors are believed to develop from remnant tumor tissues from the resected margin. Determining the blind side margin and confirming the presence of residual tumor after resection during conventional EMR with relatively large lesions are sometimes difficult because of the influence of ablation. After circumferential incision, however, the snare can be easily placed along the incision, and the tumor margin can be cut reliably. Second, this procedure is achievable with the technical competence of trainees. Third, complete resection of the tumor allows a thorough histologic analysis to be performed. This type of analysis is important for a better understanding of the characteristics of colorectal neoplastic lesions and for identifying good indicators for the CEMR procedure.

Indication for CEMR hitherto relies on lesion size only. In the present study, we performed CEMR for lesions measuring 20–40 mm, and the 8 patients in whom we were unable to achieve either en bloc resection or complete CEMR had lesions >35 mm. This greater reliability with slightly smaller lesions suggests that CEMR is most suitable in lesions measuring 20–30 mm. In their series, Uraoka et al<sup>25</sup> reported that larger tumor size is associated with an increased risk of submucosal invasion, except for the laterally spreading tumor granular uniform type; indeed, precise identification of the deepest penetration area was difficult in 30% of the laterally spreading tumor nongranular type submucosal cancers. Thus, lesions with a high chance of piecemeal resection, particularly laterally spreading tumor nongranular type lesions, should first be considered for ESD.

Notwithstanding the above-mentioned advantages, introduction of the CEMR procedure in the clinic might find some obstacles. First, a complete circumferential incision might hinder dissection into the submucosal layer because of the layer's inability to retain the injected submucosal fluid and the difficulty in maintaining a clear visual field. If the treatment procedure is changed to ESD, the level of technical difficulty might accordingly increase. Considering these limitations, the best strategy appears to be a careful observation of the lesion to determine the optimal treatment method in view of the skills of the individuals involved. Second, the CEMR procedure was performed by 2 endoscopists in a single center. Therefore, its technical acceptability by or safety for the general endoscopist, particularly those who are less experienced, is not guaranteed.

In conclusion, CEMR might represent an effective and uncomplicated procedure for treating relatively large colorectal neoplasms. The technique is clinically simple and has the same short treatment time as conventional EMR. Validation of this procedure awaits additional prospective or multicenter investigation.

### References

1. Van Gossum A, Cozzoli A, Adler M, et al. Colonoscopic snare polypectomy: analysis of 1485 resections comparing two types of current. *Gastrointest Endosc* 1992;38:472–475.
2. Kudo S. Endoscopic mucosal resection of flat and depressed types of early colorectal cancer. *Endoscopy* 1993;25:455–461.
3. Saito Y, Fujii T, Kondo H, et al. Endoscopic treatment for laterally spreading tumors in the colon. *Endoscopy* 2001;33:682–686.
4. Ahmad NA, Kochman ML, Long WB, et al. Efficacy, safety, and clinical outcomes of endoscopic mucosal resection: a study of 101 cases. *Gastrointest Endosc* 2002;55:390–396.
5. Hurlstone DP, Sanders DS, Cross SS, et al. Colonoscopic resection of lateral spreading tumours: a prospective analysis of endoscopic mucosal resection. *Gut* 2004;53:1334–1339.
6. Kiesslich R, Neurath MF. Endoscopic mucosal resection: an evolving therapeutic strategy for non-polypoid colorectal neoplasia. *Gut* 2004;53:1222–1224.
7. Puli SR, Kakugawa Y, Gotoda T, et al. Meta-analysis and systematic review of colorectal endoscopic mucosal resection. *World J Gastroenterol* 2009;15:4273–4277.
8. Soetikno RM, Inoue H, Chang KJ. Endoscopic mucosal resection: current concepts. *Gastrointest Endosc Clin N Am* 2000;10:595–617.
9. Tanaka S, Haruma K, Oka S, et al. Clinicopathologic features and endoscopic treatment of superficially spreading colorectal neoplasms larger than 20 mm. *Gastrointest Endosc* 2001;54:62–66.
10. Tamura S, Nakajo K, Yokoyama Y, et al. Evaluation of endoscopic mucosal resection for laterally spreading rectal tumors. *Endoscopy* 2004;36:306–312.
11. Walsh RM, Ackroyd FW, Shellito PC. Endoscopic resection of large sessile colorectal polyps. *Gastrointest Endosc* 1992;38:303–309.
12. Hotta K, Fujii T, Saito Y, et al. Local recurrence after endoscopic resection of colorectal tumors. *Int J Colorectal Dis* 2009;24:225–230.
13. Saito Y, Fukuzawa M, Matsuda T, et al. Clinical outcome of endoscopic submucosal dissection versus endoscopic mucosal resection of large colorectal tumors as determined by curative resection. *Surg Endosc* 2010;24:343–352.
14. Saito Y, Uraoka T, Matsuda T, et al. Endoscopic treatment of large superficial colorectal tumors: a case series of 200 endoscopic submucosal dissections (with video). *Gastrointest Endosc* 2007;66:966–973.
15. Fujishiro M, Yahagi N, Kakushima N, et al. Outcomes of endoscopic submucosal dissection for colorectal epithelial neoplasms in 200 consecutive cases. *Clin Gastroenterol Hepatol* 2007;5:678–683.
16. Tanaka S, Oka S, Kaneko I, et al. Endoscopic submucosal dissection for colorectal neoplasia: possibility of standardization. *Gastrointest Endosc* 2007;66:100–107.
17. Chung IK, Lee JH, Lee SH, et al. Therapeutic outcomes in 1000 cases of endoscopic submucosal dissection for early gastric neoplasms: Korean ESD Study Group multicenter study. *Gastrointest Endosc* 2009;69:1228–1235.
18. Yamamoto S, Uedo N, Ishihara R, et al. Endoscopic submucosal dissection for early gastric cancer performed by supervised residents: assessment of feasibility and learning curve. *Endoscopy* 2009;41:923–928.

19. Hirao M, Masuda K, Nakamura M. Endoscopic resection with local injection of HSE (ERHSE) in early gastric carcinomas [in Japanese with English abstract]. *Gan No Rinsho* 1986;32:1180–1184.
20. Ohkuwa M, Hosokawa K, Boku N, et al. New endoscopic treatment for intramucosal gastric tumors using insulated-tip diathermic knife. *Endoscopy* 2001;33:221–226.
21. Yamamoto H, Kawata H, Sunada K, et al. Success rate of curative endoscopic mucosal resection with circumferential mucosal incision assisted by submucosal injection of sodium hyaluronate. *Gastrointest Endosc* 2002;56:507–512.
22. Miyamoto S, Muto M, Hamamoto Y, et al. A new technique for endoscopic mucosal resection with an insulated-tip electro-surgical knife improves the completeness of resection of intramucosal gastric neoplasms. *Gastrointest Endosc* 2002;55:576–581.
23. Matsuda T, Fujii T, Saito Y, et al. Efficacy of the invasive/non-invasive pattern by magnifying chromoendoscopy to estimate the depth of invasion of early colorectal neoplasms. *Am J Gastroenterol* 2008;103:2700–2706.
24. Moss A, Bourke MJ, Tran K, et al. Lesion isolation by circumferential submucosal incision prior to endoscopic mucosal resection (CSI-EMR) substantially improves en bloc resection rates for 40-mm colonic lesions. *Endoscopy* 2010;42:400–404.
25. Uraoka T, Saito Y, Matsuda T, et al. Endoscopic indications for endoscopic mucosal resection of laterally spreading tumours in the colorectum. *Gut* 2006;55:1592–1597.

---

**Reprint requests**

Address requests for reprints to: Taku Sakamoto, MD, Endoscopy Division, National Cancer Center Hospital, 5-1-1 Tsukiji, Chuo-ku, Tokyo 1040045, Japan. e-mail: [tasakamo@ncc.go.jp](mailto:tasakamo@ncc.go.jp); fax: 81-3-3542-3815.

**Conflicts of interest**

The authors disclose no conflicts.

## Endoscopic submucosal dissection for large laterally spreading tumors involving the ileocecal valve and terminal ileum

Gustavo Kishimoto, Yutaka Saito, Hajime Takisawa, Haruhisa Suzuki, Taku Sakamoto, Takeshi Nakajima, Takahisa Matsuda

Gustavo Kishimoto, Yutaka Saito, Hajime Takisawa, Haruhisa Suzuki, Taku Sakamoto, Takeshi Nakajima, Takahisa Matsuda, National Cancer Center Hospital, Endoscopy Division, 5-1-1 Tsukiji, Chuo-ku, Tokyo 104-0045, Japan

Author contributions: Kishimoto G and Saito Y designed the study, collected and analyzed the data, and wrote the manuscript; Takisawa H, Suzuki H, Sakamoto T, Nakajima T, Matsuda T contributed to the discussion and reviewed the manuscript. Correspondence to: Yutaka Saito, MD, PhD, National Cancer Center Hospital, Endoscopy Division, 5-1-1 Tsukiji, Chuo-ku, Tokyo 104-0045, Japan. [ytsaito@ncc.go.jp](mailto:ytsaito@ncc.go.jp)

Telephone: +81-3-35422511 Fax: +81-3-35423815

Received: October 11, 2010 Revised: May 27, 2011

Accepted: June 4, 2011

Published online: January 21, 2012

kajima T, Matsuda T. Endoscopic submucosal dissection for large laterally spreading tumors involving the ileocecal valve and terminal ileum. *World J Gastroenterol* 2012; 18(3): 291-294 Available from: URL: <http://www.wjgnet.com/1007-9327/full/v18/i3/291.htm> DOI: <http://dx.doi.org/10.3748/wjg.v18.i3.291>

### INTRODUCTION

Laterally spreading tumors (LSTs)<sup>[1]</sup> are mainly located in the cecum and rectum and endoscopic mucosal resection (EMR) is the therapeutic choice<sup>[2,3]</sup> because of their lower incidence of submucosal (sm) invasion. Involvement of the ileocecal valve with possible spreading to the terminal ileum, however, complicates the EMR and resulting in piecemeal resection in which persistent recurrence leads to surgery even for adenomas and intramucosal cancers<sup>[4]</sup>. In addition, the thin wall of the narrow ileum increases the risk of perforation during EMR<sup>[5]</sup>.

Our experience suggests that the well-established endoscopic submucosal dissection (ESD) also produces good results in colorectal cases as in early gastric cancer treatment<sup>[6]</sup>. Unlike the stomach, colonic ESD presents high risk of complications<sup>[7]</sup> and increased patient discomfort. These factors motivated us to develop better techniques to achieve successful ESDs such as using a bipolar needle knife (B-Knife® Zeon Medical Co. Tokyo, Japan)<sup>[8]</sup> to reduce the risk of perforation and carbon dioxide (CO<sub>2</sub>) instead of conventional air insufflation for patient comfort<sup>[9]</sup>.

In the present report, we describe our experience and the utility of using ESD on one of 4 complete resections of large LSTs (70 mm in diameter) involving the ileocecal valve and terminal ileum.

### Abstract

Endoscopic submucosal dissection is a challenging technique that enables *en-bloc* resection for large colorectal tumors, as laterally spreading tumors, particularly difficult, if the ileocecal valve and terminal ileum is involved. Herein, we report on one of 4 cases. The procedures, using a bipolar needle knife (B-Knife) to reduce the perforation risk and carbon dioxide instead of conventional air insufflation for patient comfort, achieved curative resections without any complications.

© 2012 Baishideng. All rights reserved.

**Key words:** Ileocecal valve; Colorectal neoplasms; Laterally spreading tumor; Endoscopic mucosal resection; Endoscopic submucosal dissection; Bipolar current needle knife; B-Knife; IT-Knife

**Peer reviewer:** Giovanni D De Palma, Professor, Department of Surgery and Advanced Technologies, University of Naples Federico II, School of Medicine, Naples 80131, Italy

### CASE REPORT

A 76-year-old woman was referred to our hospital for