

INTRODUCTION

Colorectal cancer (CRC) has high mortality and morbidity rates, and its prevalence has been increasing^[1,2]. The development from normal colonic epithelium to small adenomas is little understood. In experimental models of colonic carcinogenesis, aberrant crypt foci (ACF) are the earliest detectable abnormality and precede adenomas. ACF was first discovered in mice treated with azoxymethane^[3], have been clearly shown to be precursor lesions of CRC, and are now established as a biomarker of the risk of CRC in azoxymethane-treated mice and rats^[4]. In humans, ACF can be detected using magnifying colonoscopy^[5]. Recent advances in magnification chromoendoscopy now allow these lesions to be identified *in vivo* and their natural history ascertained. It would be very useful, to clarify the relationship of ACF incidence to established risks for colorectal tumors. We have reported the relation between number of ACF and visceral fat obesity^[6]. In this study, human ACF in the lower rectum were assessed and subjects returned 1 year later to evaluate the natural history of the lesions. Herein, we wanted to determine the adenoma incidence over a 1-year period after polypectomy.

MATERIALS AND METHODS

Study population

We prospectively evaluated 89 subjects recruited from the population of Japanese individuals who underwent polypectomy at Yokohama City University Hospital. All patients had baseline adenomas (over 5 mm) removed at year 0 colonoscopy. The exclusion criteria included: presence of contraindications to colonoscopy; current or past non-steroidal anti-inflammatory drug use including aspirin; or family history of CRC; or history of carcinoma, familial adenomatous polyposis, inflammatory bowel disease, radiation colitis and diabetes mellitus. Written informed consent was obtained from all the subjects prior to their participation. The study protocol was approved by the Yokohama City University Hospital Ethics Committee.

Magnifying colonoscopy for identification of ACF

Participants' bowel preparation for the colonoscopy was carried out using polyethylene glycol solution. A Fujinon EC-490ZW5/M colonoscope was used to perform the magnifying colonoscopy (Fujinon Toshiba ES Systems Co., Ltd, Tokyo, Japan). Total colonoscopy was performed before imaging of lower rectal ACF. Subsequently, 0.25% methylene blue was applied to the mucosa with a spray catheter. Aberrant crypts were distinguished from normal crypts by their deeper staining, larger diameter, must be < 2 mm raised and the number of ACF in the lower rectum was counted. This counting was conducted in the lower rectal region, extending from the middle rectal fold to the dentate line, based on the results of a previous study^[5]. ACF were defined as lesions in which the crypts were more darkly stained with methylene blue

than normal crypts and had larger diameters, often with oval or slit-like lumens and a thicker epithelial lining^[7-10]. All ACF were recorded photographically by one endoscopist and evaluated by two independent observers who were unaware of the subjects' clinical histories.

Measurement of the visceral and subcutaneous fat areas

Body mass index (BMI) was calculated using the following equation: body weight (kg)/[height (m)²]. Intra-abdominal adipose tissue was assessed, as previously described by measuring the visceral fat area (VFA), subcutaneous fat area (SFA), total fat area (TFA) and waist circumference from computed tomography (CT) images at the level of the umbilicus^[6]. All CT scans were carried out with the subjects in the supine position. The borders of the intra-abdominal cavity were outlined on the CT images, and the VFA was quantified using Fat Scan software (N2 System Corporation, Kobe, Japan).

Statistical analysis

We examined the associations between clinical characteristics and number of ACF (0-3 *vs* over 3), because this criteria divided into almost same volume two groups. All data were expressed as mean \pm SD, unless otherwise indicated. Non-parametric tests were used to test differences. Statistical analyses were determined using the Stat View software (SAS Institute Inc., Cary, NC, United States). *P* < 0.05 were considered to denote statistical significance.

RESULTS

Patient characteristics

A total of 366 ACFs were identified in 89 patients; all had baseline adenomas (over 5 mm) removed at the first examination (year 0) colonoscopy and returned for the second examination (year 1). ACF in the lower rectum were assessed at year 0 and study group were divided into two groups depend on ACF numbers, 0-3 or over 3. Table 1 summarizes the clinical characteristics of study participants of the first examination. The mean age was 63.4 years and 69% were male. A total of 8% had advanced adenoma, 61% had non advanced adenoma and 31% had no adenoma. There was no statistical difference between 0-3 and over 3 numbers of ACF, in waist circumference, BMI, total cholesterol, triglyceride, hemoglobin A1c, TFA, VFA and SFA.

Natural history of ACF one year follows up after polypectomy

The mean number of observed ACF was 4.1 ± 3.7 at year 0, 4.0 ± 4.6 at year 1. This result shows natural history of ACF, and there was no statistical difference in number of ACF. The typical magnifying colonoscopic features of ACF at year 0 and 1 are shown in Figure 1.

Adenoma incidence and size one year after polypectomy

All participants were assigned two groups, 0-3 or over 3 with number of ACF, and examined in the number and

Table 1 Clinical characteristics of study participants at year 0

	Number of ACF			P value
	Total	0-3	> 3	
No. of subjects	89	41	48	
Age (yr)	63.4 ± 11.1	62.6 ± 12.9	64.1 ± 9.5	0.52
Gender (male:female)	61:28:00	28:14:00	33:15:00	
Waist Circumference (cm)	85.9 ± 11.5	84.7 ± 8.1	86.7 ± 13.6	0.57
BMI (kg/m ²)	23.2 ± 3.1	22.6 ± 2.3	23.8 ± 3.6	0.09
Total cholesterol (mg/dL)	210.7 ± 34.9	208.7 ± 32.6	212.2 ± 36.9	0.69
Triglyceride (mg/dL)	146.2 ± 77.1	125.9 ± 64.1	161.5 ± 83.2	0.06
Hemoglobin A1c (%)	5.9 ± 1.3	5.6 ± 1.2	6.2 ± 1.4	0.13
TFA (cm ²)	198.9 ± 95.2	177.0 ± 55.6	215.5 ± 115.2	0.19
VFA (cm ²)	90.4 ± 53.5	75.6 ± 41.1	101.6 ± 59.7	0.11
SFA (cm ²)	108.5 ± 58.1	101.4 ± 45.7	113.9 ± 66.4	0.49

Data are expressed as mean ± SD. ACF: Aberrant crypt foci; BMI: Body mass index; VFA: Visceral fat area; SFA: Subcutaneous fat area; TFA: Total fat area.

Table 2 Endoscopic results of adenoma at year 0 and year 1

No. of aberrant crypt foci at year 0	0-3	> 3	0-3 vs > 3
No. of subjects	41	48	
No. of adenoma at year 0	1.4 ± 1.2	1.6 ± 1.8	0.71
Maximum size of adenoma at year 0	6.0 ± 4.6	6.3 ± 7.2	0.81
No. of adenoma at year 1	1.0 ± 1.0	1.5 ± 1.4	0.08
Maximum size of adenoma at year 1	3.5 ± 3.5	5.5 ± 5.8	0.03 ¹

Data are expressed as mean ± SD. ¹P < 0.05.

maximum size of adenoma (Table 2). There was no statistical difference in number and maximum size of ACF at year 0, however, maximum size of adenoma was larger in over 3 group than 0-3 group at year 1.

DISCUSSION

Colorectal adenomas are considered to be a validated surrogate endpoint biomarker for sporadic CRC because removing adenomas by endoscopic polypectomy correlates with a decrease in CRC incidence^[11]. Therefore, the opportunity of endoscopic polypectomy and needs of predictive colorectal tumor marker are in increasing. ACF have emerged as the putative precursor to colorectal adenomas. In numerous animal studies, ACF predict subsequent development of CRC^[12,13]. Cross-sectional studies have shown that there is a higher rate of ACF in subjects with CRC and adenoma compared with those with normal colons^[5,14,15]. Because of the epidemiologic and genetic association of ACF with colorectal neoplasia, ACF are a potential biomarker for CRC. Therefore, some chemopreventive studies were reported using ACF as a surrogate marker^[16-24]. Natural history of human ACF was reported, however there was no significant change in number of ACF at one year observation^[25]. ACF are small lesions and it is possible that the biopsy forceps missed or overwhelmed the lesion. More importantly, because of issues in biopsy orientation and the small number of crypts affected in comparison with the biopsy sample, pathologic diagnosis may not be reliable. Assessment of molecular abnormalities in histologically confirmed



Figure 1 Typical features of aberrant crypt foci on magnifying colonoscopy.

ACF and in endoscopically suspected ACF that are not pathologically confirmed will be an additional means of assessing the validity of the endoscopic classification of an ACF. Some studies measuring ACF by magnification chromoendoscopy found a high degree of association between the number of rectal ACF and the presence of synchronous adenomas and adenocarcinomas^[26]. In this study, we demonstrated a correlation between the number of ACF 0-3 and over 3 in maximum size of adenoma at year 1. The meaning of the number of ACF is not elucidated, however the number of ACF may be a predictive factor of relatively large adenoma incidence in the pilot phase study.

COMMENTS

Background

Colorectal cancer (CRC) has high mortality and morbidity rates, and its prevalence has been increasing. The development from normal colonic epithelium to small adenomas is little understood. In experimental models of colonic carcinogenesis, aberrant crypt foci (ACF) are the earliest detectable abnormality and precede adenomas. In humans, ACF can be detected using magnifying colonoscopy.

Research frontiers

Recent advances in magnification chromoendoscopy now allow these lesions to be identified *in vivo* and their natural history ascertained. It would be very useful, to clarify the relationship of ACF incidence to established risks for colorectal

tumors.

Innovations and breakthroughs

The authors have reported the relation between number of ACF and visceral fat obesity, however the relation that human ACF and formation of colorectal polyp was unclear.

Applications

In this study, human ACF in the lower rectum were assessed and subjects returned 1 year later to evaluate the natural history of the lesions. Herein, the authors wanted to determine the adenoma incidence over a 1-year period after polypectomy.

Terminology

The meaning of human ACF is still unclear, however may be a surrogate marker of colorectal carcinogenesis. Therefore it is hoped that human ACF will be a surrogate marker of chemopreventive trials.

Peer review

The authors described the relationship of ACF with adenoma. In this study, the authors found maximum size of adenoma was larger in over 3 group than 0-3 group at year 1. It is a novel knowledge and nice to know for gastroenterologist. The authors reviewed their results by relevant high-integrity references. This report is a very interesting study and includes a novel finding. Furthermore, authors described and reviewed well.

REFERENCES

- Anderson WF, Umar A, Brawley OW. Colorectal carcinoma in black and white race. *Cancer Metastasis Rev* 2003; **22**: 67-82
- Rougier P, Mitry E. Epidemiology, treatment and chemoprevention in colorectal cancer. *Ann Oncol* 2003; **14** Suppl 2: ii3-ii5
- Bird RP. Observation and quantification of aberrant crypts in the murine colon treated with a colon carcinogen: preliminary findings. *Cancer Lett* 1987; **37**: 147-151
- Pretlow TP, O'Riordan MA, Somich GA, Amiri SB, Pretlow TG. Aberrant crypts correlate with tumor incidence in F344 rats treated with azoxymethane and phytate. *Carcinogenesis* 1992; **13**: 1509-1512
- Takayama T, Katsuki S, Takahashi Y, Ohi M, Nojiri S, Sakamaki S, Kato J, Kogawa K, Miyake H, Niitsu Y. Aberrant crypt foci of the colon as precursors of adenoma and cancer. *N Engl J Med* 1998; **339**: 1277-1284
- Takahashi H, Takayama T, Yoneda K, Endo H, Iida H, Sugiyama M, Fujita K, Yoneda M, Inamori M, Abe Y, Saito S, Wada K, Nakagama H, Nakajima A. Association of visceral fat accumulation and plasma adiponectin with rectal dysplastic aberrant crypt foci in a clinical population. *Cancer Sci* 2009; **100**: 29-32
- Roncucci L, Stamp D, Medline A, Cullen JB, Bruce WR. Identification and quantification of aberrant crypt foci and microadenomas in the human colon. *Hum Pathol* 1991; **22**: 287-294
- Roncucci L, Medline A, Bruce WR. Classification of aberrant crypt foci and microadenomas in human colon. *Cancer Epidemiol Biomarkers Prev* 1991; **1**: 57-60
- Pretlow TP, Barrow BJ, Ashton WS, O'Riordan MA, Pretlow TG, Jurcisek JA, Stellato TA. Aberrant crypts: putative preneoplastic foci in human colonic mucosa. *Cancer Res* 1991; **51**: 1564-1567
- Pretlow TP, O'Riordan MA, Pretlow TG, Stellato TA. Aberrant crypts in human colonic mucosa: putative preneoplastic lesions. *J Cell Biochem Suppl* 1992; **16G**: 55-62
- Winawer SJ, Zauber AG, Ho MN, O'Brien MJ, Gottlieb LS, Sternberg SS, Wayne JD, Schapiro M, Bond JH, Panish JF. Prevention of colorectal cancer by colonoscopic polypectomy. The National Polyp Study Workgroup. *N Engl J Med* 1993; **329**: 1977-1981
- Fenoglio-Preiser CM, Noffsinger A. Aberrant crypt foci: A review. *Toxicol Pathol* 1999; **27**: 632-642
- Corpet DE, Taché S. Most effective colon cancer chemopreventive agents in rats: a systematic review of aberrant crypt foci and tumor data, ranked by potency. *Nutr Cancer* 2002; **43**: 1-21
- Adler DG, Gostout CJ, Sorbi D, Burgart LJ, Wang L, Harmesen WS. Endoscopic identification and quantification of aberrant crypt foci in the human colon. *Gastrointest Endosc* 2002; **56**: 657-662
- Hurlstone DP, Karajeh M, Sanders DS, Drew SK, Cross SS. Rectal aberrant crypt foci identified using high-magnification-chromoscopic colonoscopy: biomarkers for flat and depressed neoplasia. *Am J Gastroenterol* 2005; **100**: 1283-1289
- Hosono K, Endo H, Takahashi H, Sugiyama M, Sakai E, Uchiyama T, Suzuki K, Iida H, Sakamoto Y, Yoneda K, Koide T, Tokoro C, Abe Y, Inamori M, Nakagama H, Nakajima A. Metformin suppresses colorectal aberrant crypt foci in a short-term clinical trial. *Cancer Prev Res (Phila)* 2010; **3**: 1077-1083
- Takahashi H, Hosono K, Uchiyama T, Sugiyama M, Sakai E, Endo H, Maeda S, Schaefer KL, Nakagama H, Nakajima A. PPARgamma Ligand as a Promising Candidate for Colorectal Cancer Chemoprevention: A Pilot Study. *PPAR Res* 2010; **2010**: pii257835
- Sakai E, Takahashi H, Kato S, Uchiyama T, Hosono K, Endo H, Maeda S, Yoneda M, Taguri M, Nakajima A. Investigation of the prevalence and number of aberrant crypt foci associated with human colorectal neoplasia. *Cancer Epidemiol Biomarkers Prev* 2011; **20**: 1918-1924
- Anderson JC, Swede H, Rustagi T, Protiva P, Pleau D, Brenner BM, Rajan TV, Heinen CD, Levine JB, Rosenberg DW. Aberrant crypt foci as predictors of colorectal neoplasia on repeat colonoscopy. *Cancer Causes Control* 2012; **23**: 355-361
- Anderson JC, Pleau DC, Rajan TV, Protiva P, Swede H, Brenner B, Heinen CD, Lambrecht RW, Rosenberg DW. Increased frequency of serrated aberrant crypt foci among smokers. *Am J Gastroenterol* 2010; **105**: 1648-1654
- Stevens RG, Swede H, Heinen CD, Jablonski M, Grupka M, Ross B, Parente M, Tirnauer JS, Giardina C, Rajan TV, Rosenberg DW, Levine J. Aberrant crypt foci in patients with a positive family history of sporadic colorectal cancer. *Cancer Lett* 2007; **248**: 262-268
- Mutch MG, Schoen RE, Fleshman JW, Rall CJ, Dry S, Seligson D, Charabaty A, Chia D, Umar A, Viner J, Hawk E, Pinsky PF. A multicenter study of prevalence and risk factors for aberrant crypt foci. *Clin Gastroenterol Hepatol* 2009; **7**: 568-574
- Uchiyama T, Takahashi H, Endo H, Kato S, Sakai E, Hosono K, Yoneda M, Inamori M, Hippo Y, Nakagama H, Nakajima A. Number of aberrant crypt foci in the rectum is a useful surrogate marker of colorectal adenoma recurrence. *Dig Endosc* 2012; **24**: 353-357
- Ohkubo H, Takahashi H, Yamada E, Sakai E, Higurashi T, Uchiyama T, Hosono K, Endo H, Taguri M, Nakajima A. Natural history of human aberrant crypt foci and correlation with risk factors for colorectal cancer. *Oncol Rep* 2012; **27**: 1475-1480
- Schoen RE, Mutch M, Rall C, Dry SM, Seligson D, Umar A, Pinsky P. The natural history of aberrant crypt foci. *Gastrointest Endosc* 2008; **67**: 1097-1102
- Stevens RG, Swede H, Rosenberg DW. Epidemiology of colonic aberrant crypt foci: review and analysis of existing studies. *Cancer Lett* 2007; **252**: 171-183

S- Editor Song XX L- Editor A E- Editor Zhang DN

Increased tumor necrosis factor receptor 1 expression in human colorectal adenomas

Kunihiro Hosono, Eiji Yamada, Hiroki Endo, Hirokazu Takahashi, Masahiko Inamori, Yoshitaka Hippo, Hitoshi Nakagama, Atsushi Nakajima

Kunihiro Hosono, Eiji Yamada, Hiroki Endo, Hirokazu Takahashi, Masahiko Inamori, Atsushi Nakajima, Division of Gastroenterology, Yokohama City University School of Medicine, Yokohama 2360004, Japan

Yoshitaka Hippo, Hitoshi Nakagama, Division of Cancer Development System, National Cancer Center Research Institute, Tokyo 1040045, Japan

Author contributions: Hosono K performed most of the research and wrote the paper; Yamada E, Endo H and Takahashi H performed the endoscopies; Inamori M analyzed the data; Hippo Y, Nakagama H and Nakajima A were major contributors in revising the manuscript critically for important intellectual content. Supported by Grant-in-Aid for Research from the Third-Term Comprehensive Control Research for Cancer Center of the Ministry of Health, Labor and Welfare, Japan; Grant from the Ministry of Education, Culture, Sports, Science and Technology, Japan (KIBAN-B); and the "Collaborative Development of Innovative Seeds" Grant Program from the Japan Science and Technology Agency

Correspondence to: Dr. Atsushi Nakajima, Professor, Division of Gastroenterology, Yokohama City University School of Medicine, 3-9 Fukuura, Kanazawa-ku, Yokohama 2360004, Japan. nakajima-ky@umin.ac.jp

Telephone: +81-45-7872640 Fax: +81-45-7843546

Received: March 6, 2012 Revised: June 7, 2012

Accepted: June 15, 2012

Published online: October 14, 2012

Abstract

AIM: To determine the expression statuses of tumor necrosis factor (TNF)- α , its receptors (TNF-R) and downstream effector molecules in human colorectal adenomas.

METHODS: We measured the serum concentrations of TNF- α and its receptors in 62 colorectal adenoma patients and 34 healthy controls. The protein expression of TNF- α , TNF-R1, TNF-R2 and downstream signals of the TNF receptors, such as c-Jun N-terminal kinase (JNK), nuclear factor- κ B and caspase-3, were also

investigated in human colorectal adenomas and in normal colorectal mucosal tissues by immunohistochemistry. Immunofluorescence confocal microscopy was used to investigate the consistency of expression of TNF-R1 and phospho-JNK (p-JNK).

RESULTS: The serum levels of soluble TNF-R1 (sTNF-R1) in adenoma patients were significantly higher than in the control group (3.67 ± 0.86 ng/mL vs 1.57 ± 0.72 ng/mL, $P < 0.001$). Receiver operating characteristic analysis revealed the high diagnostic sensitivity of TNF-R1 measurements (AUC was 0.928) for the diagnosis of adenoma, and the best cut-off level of TNF-R1 was 2.08 ng/mL, with a sensitivity of 93.4% and a specificity of 82.4%. There were no significant differences in the serum levels of TNF- α or sTNF-R2 between the two groups. Immunohistochemistry showed high levels of TNF-R1 and p-JNK expression in the epithelial cells of adenomas. Furthermore, a high incidence of co-localization of TNF-R1 and p-JNK was identified in adenoma tissue.

CONCLUSION: TNF-R1 may be a promising biomarker of colorectal adenoma, and it may also play an important role in the very early stages of colorectal carcinogenesis.

© 2012 Baishideng. All rights reserved.

Key words: Tumor necrosis factor- α ; Tumor necrosis factor receptor 1; c-Jun N-terminal kinase; Colorectal adenoma; Biomarker

Peer reviewers: Peter Laszlo Lakatos, MD, PhD, 1st Department of Medicine, Semmelweis University, Koranyi S2A, H1083 Budapest, Hungary; Annika Lindblom, Professor, Molecular Medicine and Surgery, Karolinska Institutet, S17176 Stockholm, Sweden; Manuel Romero-Gomez, Professor, Department of Medicine, University of Sevilla, Avda. de Bellavista, 41014 Sevilla, Spain

Hosono K, Yamada E, Endo H, Takahashi H, Inamori M, Hippo Y, Nakagama H, Nakajima A. Increased tumor necrosis factor receptor 1 expression in human colorectal adenomas. *World J Gastroenterol* 2012; 18(38): 5360-5368 Available from: URL: <http://www.wjgnet.com/1007-9327/full/v18/i38/5360.htm> DOI: <http://dx.doi.org/10.3748/wjg.v18.i38.5360>

INTRODUCTION

The proinflammatory cytokine, tumor necrosis factor (TNF), plays an important role in diverse cellular events, such as the induction of other cytokines' expression, cell proliferation, differentiation, necrosis and apoptosis^[1,2]. Many of the TNF-induced cellular responses are mediated by one of two specific cellular membrane receptors, tumor necrosis factor receptor 1 (TNF-R1) and TNF-R2, both of which belong to the TNF receptor superfamily^[3]. In response to TNF treatment, activation of nuclear factor- κ B (NF- κ B), a transcription factor, as well as mitogen-activated protein kinase (MAPK), extracellular signal-regulated kinase, p38, and c-Jun N-terminal kinase (JNK) have been reported in most cell types and, in some cases, after apoptosis or necrosis had been induced^[4,5].

Overexpression of TNF- α and its receptors often accompanies tumor development and progression, and their important role in the pathogenesis of cancer is now increasingly recognized. Several studies have reported on the status of TNF- α expression in various malignancies. For example, TNF- α mRNA and protein have been detected in both malignant and stromal cells in human ovarian cancer biopsies^[6,7]. The plasma levels of TNF- α have been reported to be increased in some cancer patients, especially those with poor prognoses^[8-11]. Blood TNF- α concentrations have been reported to be higher in prostate cancer patients with advanced, cachectic disease^[12]. These findings suggest that TNF- α might also have an important role in carcinogenesis. We now know that many of the cells and mediators of inflammation that have been detected in human and experimental cancers and inflammatory conditions increase the risk of cancer development^[13-16]. There is strong evidence to suggest that cancer-related inflammation aids in the proliferation and survival of malignant cells, stimulates angiogenesis and metastasis^[17-19], subverts adaptive immunity^[20-22], and modulates their responses to hormones and chemotherapy^[23,24].

In colitis-related colon cancer, TNF- α has been demonstrated to promote carcinogenesis, and anti-TNF- α drugs are being used therapeutically^[25,26]. Moreover, serum TNF- α is known to serve as an important pathophysiological marker for the presence and severity of inflammatory bowel disease^[27]. However, TNF- α has a short half-life (20 min); therefore, accurate measurement of the blood levels is difficult^[28]. There is some debate about whether TNF- α can actually be measured using some sort of physiologically active substance^[28,29]. On

the other hand, TNF-R1 and TNF-R2 are released into the blood as soluble TNF-R1 (sTNF-R1) and soluble TNF-R2 (sTNF-R2) after proteolysis of their extracellular domains in response to activators, including TNF- α itself^[30,31]. Their presence in the peripheral blood is reflective of an inflammatory response occurring within the body. sTNF-R1 and sTNF-R2 also have very long half-lives; thus, they are more stable than TNF- α ^[32,33]. These receptors may provide better serum biomarkers than TNF- α . Spoettl *et al.*^[34] found that serum sTNF-R1 levels were significantly increased in ulcerative colitis (UC) patients compared with that of healthy controls. However, there have been few reports of the association between TNF-R1 and TNF-R2 and sporadically occurring colorectal neoplasms^[35]. Thus, the association of these receptors with the risk of colorectal adenoma has not yet been fully clarified. The aim of this study was to investigate the serum levels of TNF- α , sTNF-R1 and sTNF-R2 in adenoma patients and also to investigate the expressions of downstream molecules in the TNF- α signaling pathway, including TNF-R1, TNF-R2, JNK, NF- κ B and caspase-3 in adenoma tissues in comparison to those in normal colorectal mucosa.

MATERIALS AND METHODS

Patients

The study population consisted of 62 consecutive patients with colorectal adenoma who underwent colonoscopy from January 2008 to January 2009 at the Division of Gastroenterology, Yokohama City University School of Medicine. Patients with concomitant diseases, including infectious diseases, inflammatory bowel diseases, autoimmune conditions, allergy or asthma, that were likely to elevate serum TNF- α levels were excluded from the study. The patients ranged in age from 54 to 86 years (mean \pm SD: 67.7 \pm 8.2 years) and consisted of 39 males and 23 females. The control group consisted of 34 healthy people, matched for age. The control group consisted of people undergoing colonoscopy after positive fecal occult blood test but not found to have adenomas. The study was carried out in accordance with the Declaration of Helsinki (revised 1989) and with the approval of the Ethics Committee of Yokohama City University School of Medicine. Informed consent was obtained from each patient participating in this study and for the use of the obtained data for research purposes.

Serum samples

Before colonoscopy, blood samples were obtained from all participants after an overnight fast to determine the serum concentrations of TNF- α , sTNF-R1 and sTNF-R2. The blood samples were centrifuged at 800 g for 5 min. Serum was separated as soon as possible from the clot of red blood cells by centrifugation to avoid TNF- α production by the blood cells, which would have led to falsely increased values^[36]. Then, the serum specimens were stored at -80 °C until the biochemical analyses.

Biochemical determinations

Serum concentrations of human TNF- α , sTNF-R1 and sTNF-R2 were determined by enzyme-linked immunosorbent assay (ELISA) kit (R and D Systems Inc., Minneapolis, MN, United States). The minimum limits of detection of the assay were as follows: TNF- α , 1.6 pg/mL; sTNF-R1, 0.77 pg/mL; and sTNF-R2, 0.6 pg/mL. The tests were carried out as described in the product manuals.

Immunohistochemical analysis

Immunohistochemical analysis was performed in the adenomatous polyps retrieved from the study patients ($n = 62$). Adenomatous polyps removed during colonoscopy, together with normal colorectal mucosal biopsies from the same patients when possible, were examined. Four-micrometer sections were prepared from the formalin-fixed, paraffin-embedded tissues and mounted on slides coated with polylysine. We examined only sporadically occurring polyps by excluding specimens from patients with familial adenomatous polyposis (FAP) or hereditary non-polyposis coli (HNPCC). The protein expression levels were determined in all 62 normal and colorectal adenomatous tissue sections by immunohistochemistry. Sections were deparaffinized in xylene and rehydrated. The sections were then heated in a 750 W microwave three times for 7 min. Inhibition of endogenous peroxidase activity was performed by treating sections with 3% hydrogen peroxide for 10 min. After washing three times with Tris-Buffered Saline (TBS), the blocking of non-specific interactions was accomplished by incubating the samples with blocking serum for 30 min at room temperature. Sections were then probed with the primary antibodies (Table 1) and subsequently incubated with the Histofine simple stain max PO kit for 30 min (Nichirei Laboratories, Tokyo, Japan) in accordance with the manufacturer's instructions. The signals were visualized by treatment with diaminobenzidine (peroxidase substrate kit, Vector Laboratories, Burlingame, CA, United States), and the sections were counterstained with hematoxylin. Six random microscopic fields per sample of approximately 250 cells were counted at a magnification of 400 \times under a bright-field microscope. The results were expressed as the percentage of positive cells with separating epithelial cells and stromal cells.

Immunofluorescence confocal microscopy

For immunofluorescence studies, the sections were stained with anti-TNF-R1 rabbit polyclonal antibody (Santa Cruz Biotechnology, Santa Cruz, CA, United States) at a dilution of 1:50, anti-TNF-R2 rabbit polyclonal antibody (Santa Cruz Biotechnology) at a dilution of 1:50, and anti-p-JNK mouse monoclonal antibody at Thr 183 and Tyr 185 (Santa Cruz Biotechnology) at a dilution 1:50. After thorough washes in TBS, sections were incubated with their respective Alexa594-conjugated anti-rabbit IgG secondary antibodies (Invitrogen, Carlsbad, CA, United States) or Alexa488-conjugated anti-mouse

Table 1 Summary of the specific antibodies used and immunohistochemistry

Protein	Antibody (catalog number)	Dilution	Incubation
TNF- α	Rabbit polyclonal (Abcam, ab6671)	1:100	Overnight
TNF-R1	Rabbit polyclonal (Abcam, ab19139)	1:2000	1 h
TNF-R2	Rabbit polyclonal (Abcam, ab15563)	1:50	30 min
p-JNK	Rabbit polyclonal (CST, #9251)	1:100	Overnight
NF- κ B	Rabbit polyclonal (CST, #3034)	1:50	Overnight
Caspase-3	Rabbit polyclonal (CST, #9661)	1:200	Overnight

Abcam (Cambridge, United Kingdom). CST: Cell signaling technology (Beverly, MA, United States).

Table 2 Comparison of the clinical data and measured biochemical parameters in the serum of patients with adenomas and control subjects (mean \pm SD)

Parameters	Control ($n = 34$)	Adenoma ($n = 62$)	<i>P</i> value
Age (yr)	67.6 \pm 15.9	67.7 \pm 8.2	NS
Sex (F/M)	14/20	23/39	NS
BMI	23.5 \pm 5.0	23.9 \pm 3.4	NS
TNF- α (pg/mL)	5.56 \pm 1.3	4.83 \pm 1.9	NS
sTNF-R1 (ng/mL)	1.57 \pm 0.72	3.67 \pm 0.86	< 0.001
sTNF-R2 (ng/mL)	2.72 \pm 1.15	3.09 \pm 0.91	NS

$P < 0.05$ was denoted significance. NS: Non-significant; TNF- α : Tumor necrosis factor- α ; sTNF-R1/2: Soluble tumor necrosis factor receptor 1/2; F/M: Female/male; BMI: Body mass index.

IgG secondary antibodies (Invitrogen) for 1 h, washed, and mounted.

The confocal imaging was carried out on a FV1000-D (Olympus, Tokyo, Japan) confocal laser scanning microscope. Excitation and detection of the samples were carried out in sequential modes to avoid overlapping of signals. Sections were scanned simultaneously at both wavelengths (488/594 nm) with appropriate laser intensity, confocal aperture, and gain. The Black-level setting was kept constant for all samples.

Statistical analysis

Data were expressed as the mean \pm SD unless otherwise indicated. The significances of the differences in clinical characteristics between patients with adenomas and controls were evaluated by the χ^2 -test for categorical variables and Welch's test for continuous variables. One-way analysis of variance was performed to compare the prevalence of each variable between groups. To assess the diagnostic sensitivity and specificity of the sTNF-R1 and sTNF-R2 measurements, receiver operating characteristic (ROC) curve analysis was performed. $P < 0.05$ was considered to indicate statistical significance.

RESULTS

Biochemical determinations

Table 2 shows a comparison of the clinical data and laboratory parameters between the 62 patients with adenoma and the 34 normal controls. No differences in

Table 3 Association between the measured biochemical parameters and the number of colorectal adenomas per person

	Control (n = 34)	≤ 3 (n = 34)	≥ 4 (n = 28)	P value
TNF-α (pg/mL)	5.63 ± 1.3	4.31 ± 1.9	4.95 ± 2.0	NS
sTNF-R1 (ng/mL)	1.57 ± 0.72	3.37 ± 0.93	4.05 ± 0.55	< 0.001
sTNF-R2 (ng/mL)	2.72 ± 1.15	3.13 ± 0.88	3.04 ± 0.95	NS

Values are expressed as the mean ± SD; P < 0.05 denoted significance. NS: Non-significant; TNF-α: Tumor necrosis factor-α; sTNF-R1/2: Soluble tumor necrosis factor receptor 1/2.

the age, sex or body mass index were found between the two studied groups. The mean serum levels of sTNF-R1 were significantly higher in the adenoma patients compared to the control group patients. On the other hand, there were no significant differences in the serum levels of TNF-α or sTNF-R2 between the two groups. Linear contrast analysis was conducted to evaluate the correlation between each variable and the number of adenomas per person (Table 3). The serum levels of sTNF-R1 were positively correlated with the number of adenomas in the colorectum (P < 0.001). As assessed by nonparametric analysis of the ROC curves, sTNF-R1 measurements showed a high diagnostic sensitivity at a value of 0.928 (Figure 1). The best cut-off level for TNF-R1 as 2.08 ng/mL, which showed a sensitivity of 93.4% and a specificity of 82.4%.

Immunohistochemical analysis

Immunohistochemistry showed varying expression intensities of TNF-α, TNF-R1, TNF-R2, p-JNK, NF-κB and caspase-3 in different areas of the samples. The expression of TNF-α in the stromal area of adenomas was significantly higher than that in the stromal areas of the normal mucosa (P < 0.05); however, the expression of TNF-α in the epithelial cells of adenomas was not as high as that in the epithelial cells of the normal mucosa (Figure 2). The expression of TNF-R1 in the epithelial cells of the adenomas was significantly higher than that in the epithelial cells of the normal mucosa (P < 0.05); however, in the stromal areas, the expression of TNF-R1 was equivalent between the adenomas and the normal mucosa. No significant difference in the expression of TNF-R2 was noted in either the epithelial cells or the stromal areas between the adenomas and the normal mucosa. In relation to the expressions of the downstream molecules in the TNF-α signaling pathway, the expression of p-JNK in both the epithelial cells and stromal areas of the adenoma were significantly higher than those in the normal mucosa (P < 0.05) (Figure 3). However, there were no significant differences in the expressions of NF-κB or caspase-3 in either the epithelial cells or stromal areas between the adenomas and the normal mucosa.

To investigate the consistency of TNF-R1 and p-JNK expression, we performed immunofluorescence staining of the adenoma tissues, because the results of immu-

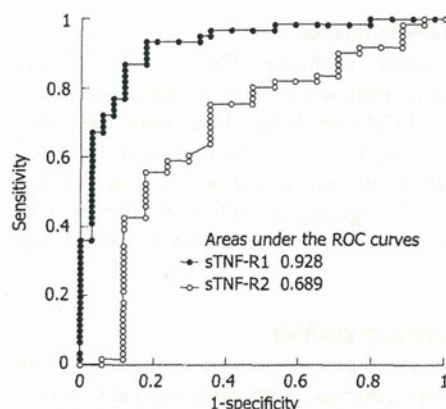


Figure 1 Receiver operating characteristic curves for soluble tumor necrosis factor receptor-1 and 2 in patients with adenomas. ROC: Receiver operating characteristic.

nohistochemistry revealed high levels of TNF-R1 and p-JNK expression in the epithelial cells of the adenomas. The results revealed expression of TNF-R1 and p-JNK co-localized predominantly in the epithelial cells of the adenomas. Merged images of TNF-R1 and p-JNK immunofluorescence staining demonstrated this co-localization (Figure 4). On the other hand, the expression of TNF-R2 was localized predominantly to the stromal area of the adenomas, and merged images of TNF-R2 and p-JNK immunofluorescence staining showed a lack of co-localization.

DISCUSSION

This is the first study to show marked changes in the expression levels of TNF-R1 in colorectal adenoma tissues. The serum sTNF-R1 levels were also significantly higher in colorectal adenoma patients than in the control subjects. To evaluate the possible usefulness of TNF-R1 as a biomarker for colorectal adenoma, we evaluated the correlation between the number of adenomas in the colorectum and the serum sTNF-R1 level. The results showed that the serum sTNF-R1 level positively correlated with the number of colorectal adenomas. A ROC analysis revealed the high diagnostic sensitivity and specificity of sTNF-R1 measurements for diagnosis of colorectal adenoma. These results may suggest that TNF-R1 is a promising biomarker for colorectal adenomas. In addition, our results agreed with the Kaminska *et al*^[37] study, which showed that sTNF-R1 had the highest diagnostic sensitivity in colorectal cancer patients. Other previous reports have shown a high diagnostic and prognostic accuracy of serum sTNF-R1 levels for various diseases. Determination of the TNF-R1 levels in several body fluids, including the serum, provides valuable insight into a variety of pathological conditions. For example, in cervical adenocarcinoma patients, serum sTNF-R1 is reported to be a useful marker, especially in the early stages of disease^[38]. In patients with breast cancer, serum sTNF-R1 is considered to be an independent and clinically useful

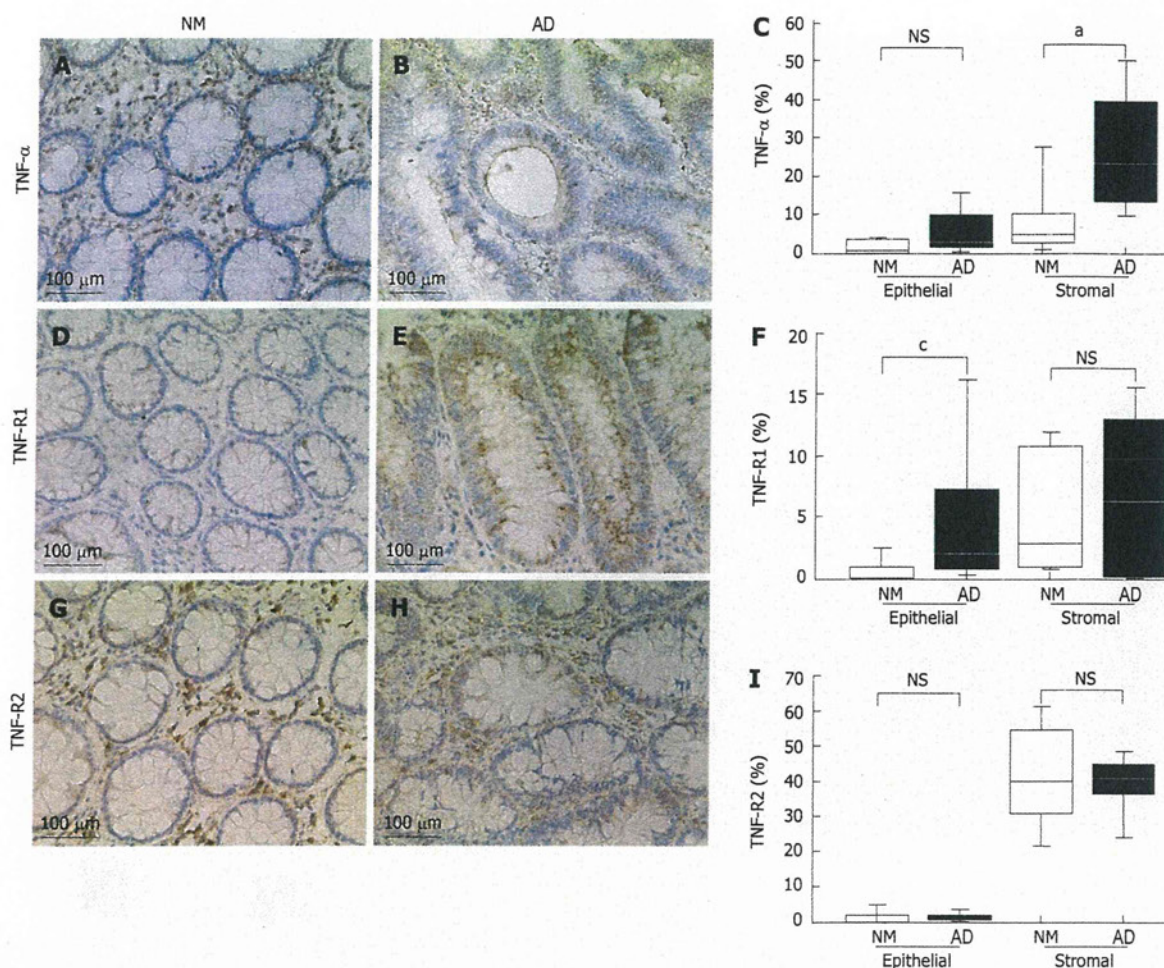


Figure 2 Immunohistochemical analyses in the normal colorectal mucosa and adenoma tissues. A: Tumor necrosis factor (TNF)- α expression in the normal colorectal mucosa; B: TNF- α expression in the adenoma tissues; C: The percentage of TNF- α -positive cells; D: Tumor necrosis factor-receptor 1 (TNF-R1) expression in the normal colorectal mucosa; E: TNF-R1 expression in the adenoma tissues; F: The percentage of TNF-R1-positive cells; G: TNF-R2 expression in the normal colorectal mucosa; H: TNF-R2 expression in the adenoma tissues; I: The percentage of TNF-R2-positive cells. Box plots display median values and interquartile ranges (C, F, I). The non-outlier range is also shown. * $P < 0.05$ between NM and AD in stromal of TNF- α ; ^c $P < 0.05$ between NM and AD in epithelial of TNF-R1. NS: Non-significant; NM: Normal mucosa; AD: Adenoma.

indicator of a poor prognosis^[39].

TNFR-1 is an important member of the death receptor family, which is capable of inducing apoptotic cell death^[40]. In addition to its involvement in apoptotic signaling, TNF-R1 has been widely studied because it is a dual-role receptor. In addition to inducing apoptosis, it also has the ability to transduce cell survival signals. When TNF-R1 transduces cell survival signals, TNFR-associated factor 2 (TRAF-2) is recruited to the complex, which inhibits apoptosis *via* the cytoplasmic inhibitor of apoptosis protein (cIAP). The binding of TRAF-2 initiates a sequence of phosphorylation steps resulting in the activation of cFos/cJun transcription factors *via* MAPK and JNK^[41]. The cFos/cJun transcription factors induce transcription of antiapoptotic, proliferative, immunomodulatory, and inflammatory genes.

TNF- α is a major mediator of cancer-related inflammation^[13,42], and most of the pro-tumor actions of

TNF- α appear to be mediated by TNF-R1. Mouse experiments have revealed that the development of primary cancers and metastases is attenuated in mice deficient in TNF-R1. For example, TNF-R1^{-/-} mice are resistant to DMBA-TPA carcinogenesis, as are TNF- α ^{-/-} mice^[43]. Experimental formation of lung and liver metastases was attenuated in TNF-R1^{-/-} mice compared with that in their normal counterparts^[44,45]. In wild-type mice with bone marrow cells repopulated using cells from TNF-R1^{-/-} mice, the likelihood of colitis and colon cancer development was reduced^[46] suggesting that TNF- α in the tumor microenvironment enhanced tumor development through its actions on TNF-R1-positive myeloid cells. In various pathologic states, it has been reported that the production and release of TNF-R1 may mediate host responses and determine the course and outcome of the disease by binding with TNF- α and competing with cell surface receptors.

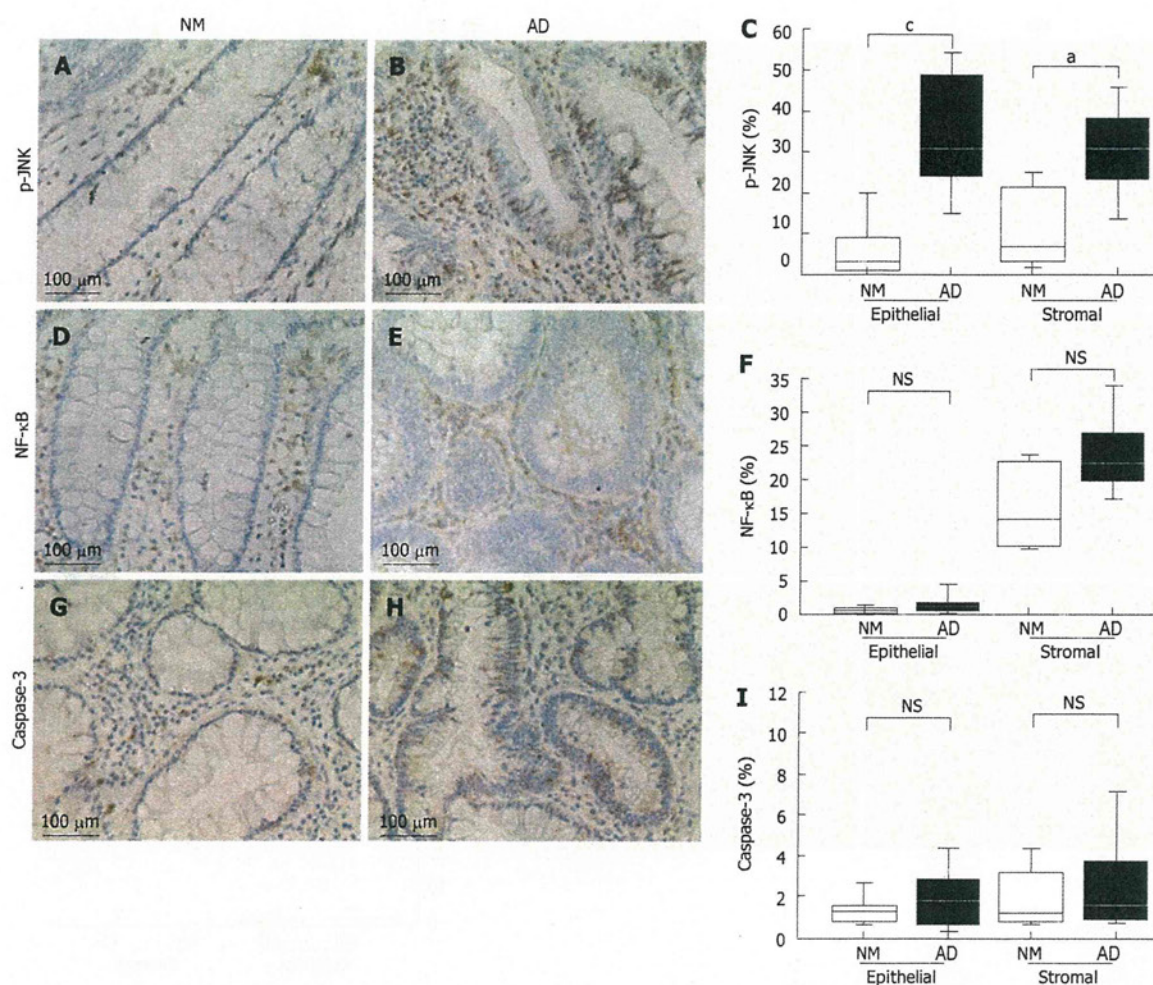


Figure 3 Immunohistochemical analyses in the normal colorectal mucosa and adenoma tissues. A: Phospho-c-Jun N-terminal kinase (p-JNK) expression in the normal colorectal mucosa; B: p-JNK expression in the adenoma tissues; C: The percentage of p-JNK positive cells; D: Nuclear factor-κ B (NF-κB) expression in the normal colorectal mucosa; E: NF-κB expression in the adenoma tissues; F: The percentage of NF-κB-positive cells; G: Caspase-3 expression in the normal colorectal mucosa; H: Caspase-3 expression in the adenoma tissues; I: The percentage of caspase-3-positive cells. Box plots display median values and interquartile ranges (C, F, I). The non-outlier range is also shown. * $P < 0.05$ between NM and AD in stromal of p-JNK; ^c $P < 0.05$ between NM and AD in epithelial of p-JNK. NS: Non-significant; NM: Normal mucosa; AD: Adenoma.

In addition to the systematic analysis of serum sTNF-R1, we also investigated, by immunohistochemical analysis, the local expressions of downstream molecules in the TNF- α signaling pathway in normal colorectal mucosa and adenoma tissues. The results revealed high levels of TNF-R1 and p-JNK expression in the epithelial cells of adenomas. Moreover, we identified co-localization of TNF-R1 and p-JNK in adenomas by immunofluorescence confocal microscopy. In the past, expression of p-JNK in adenomas has only been described by Hardwick *et al*^[47]. These authors found that the expression of p-JNK was observed mainly in stromal T-lymphocytes, and epithelial cells were not stained. The discrepancy in our results was presumably due to differences in the immunohistochemical staining protocol used. The Hardwick study used phosphate- buffered saline (PBS) as the wash buffer, while we used TBS. Additionally, different antibodies were used in the two studies, which may have

resulted in the absence of phospho-JNK staining in the epithelial cells of their study.

Our results suggest that the TNF-R1/p-JNK pathway is upregulated in adenomas and that this pathway may play an important role in adenoma formation, which represents the very early stages of colorectal carcinogenesis because this pathway is not upregulated in the normal colorectal mucosa. Expression of JNK in colon cancer has already received some attention^[48,49]; studies have found increased activity of JNK in both rat models of colon cancer and human colorectal tumors. In addition, Zhang *et al*^[50] indicated that the TNF-R1/JNK signaling cascade can functionally promote tumorigenesis of human epithelial cancers, such as squamous cell carcinomas. Moreover, a recent study conducted by our group showed that JNK/c-Jun may play an important role in promoting colorectal carcinogenesis and epithelial cell proliferation under high-fat dietary conditions^[51].

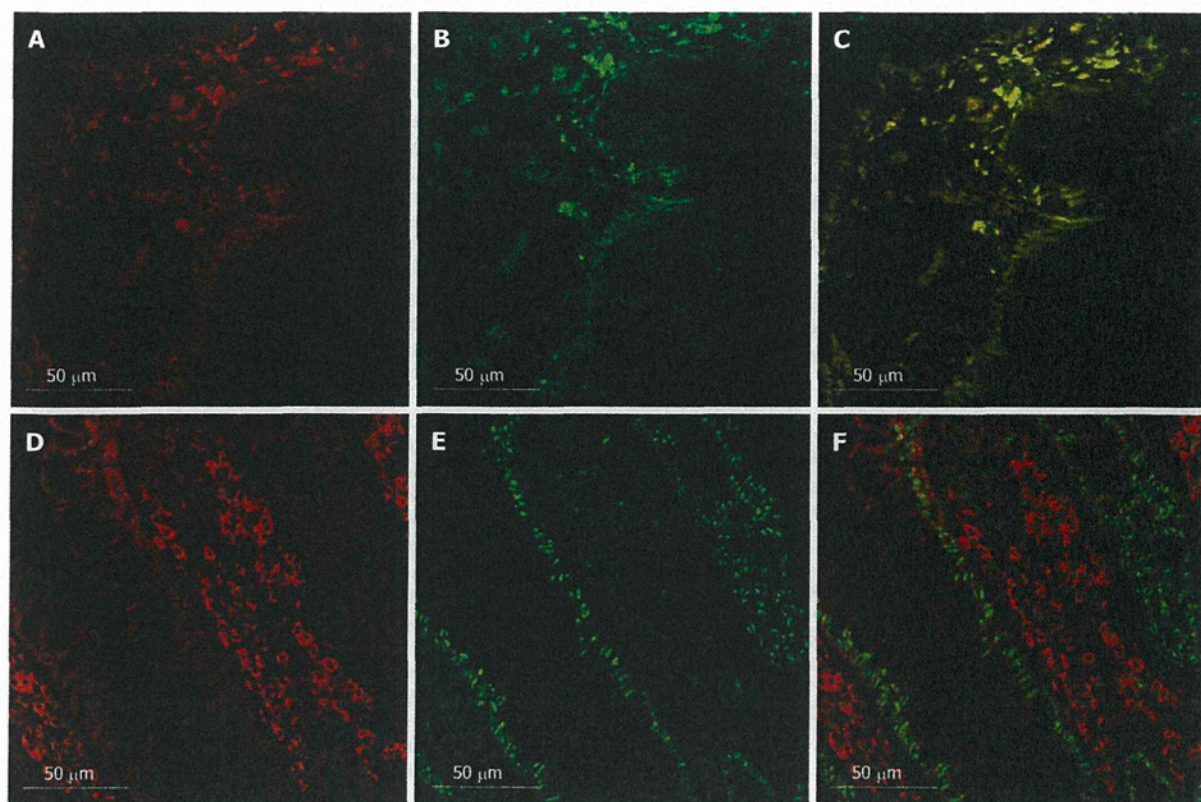


Figure 4 Confocal laser microscopic analyses of colorectal adenoma sections. A: Tumor necrosis factor receptor 1 (TNF-R1) expression; B: Phospho-c-Jun N-terminal kinase (p-JNK) expression; C: Merged image of A and B. Co-localized expression of TNF-R1 and p-JNK was noted predominantly in the epithelial cells of adenomas. Merged images showing co-localization; D: TNF-R2 expression; E: p-JNK expression; F: Merged image of D and E. Expression of TNF-R2 was localized predominantly to the stromal area of the adenoma. Merged images showed a lack of co-localization.

Our study had several important novelties. We showed for the first time that the serum levels of sTNF-R1 may have high diagnostic sensitivity and specificity as a biomarker for colorectal adenoma. Second, TNF-R1 was relatively undetectable in the normal colorectal mucosa, whereas adenomas showed high expression levels of TNF-R1. In addition, co-expression of p-JNK with TNF-R1 was observed in adenomas, although a previous study reported that the epithelial cells of adenoma showed a lack of p-JNK staining^[47]. These results suggest that the TNF-R1/JNK pathway may play an important role in the development/progression of colorectal adenoma.

The present study also had some limitations. First, our research target was colorectal adenoma and not colorectal cancer. Thus, further studies targeting colorectal cancer are needed. Secondly, the control population was small. Third, different cell death receptors are able to activate JNK. Therefore, the increased p-JNK expression in adenoma tissue may be related to TNF-R1 or other effectors. The expression of cell death receptors may also be altered in inflammatory cells, which may certainly be involved in cancer progression. Fourth, it was considered that TNF-R1 may directly stimulate JNK activation, but this would also be difficult to prove.

In conclusion, this is the first study to report elevated serum levels of sTNF-R1 in patients with adenomas compared to a control group. We also found, by immunohistochemical analysis, enhanced expression of TNF-R1 in colorectal adenomas. These results suggest that TNF-R1 may not only be a promising biomarker of colorectal adenoma but also plays an important role in the very early stages of colorectal carcinogenesis. More studies are needed to elucidate the exact functions of TNF-R1 in colorectal adenomas.

ACKNOWLEDGMENTS

We thank Machiko Hiraga for her technical assistance.

COMMENTS

Background

The proinflammatory cytokine, tumor necrosis factor (TNF)- α , is a major mediator of cancer-related inflammation. However, little has been reported on the relationship between TNF- α and sporadically occurring colorectal neoplasms. Studies on human colorectal adenoma were performed to determine the expression statuses of TNF- α and its receptors.

Research frontiers

Overexpression of TNF- α and its receptors often accompanies tumor development and progression, and their important role in the pathogenesis of cancer is