



**Table 2.** Summary of the very likely and possible pathogenic mutations identified in 100 Japanese arRP patients.

		Nucleotide change	Predicted effect	Location in gene	Domain <sup>a</sup>	Conservation in hu/o/m/ho/d/op/p/c/z/dr <sup>b</sup>	Allele frequency		Family ID	Reference	Species	Computational prediction <sup>c</sup>		
							Control	Patient				SIFT	PolyPhen2 (HumDiv)	PMut
<b>Very likely pathogenic mutations</b>	<b>Insertion</b>	c.2522_2523insA	p.Y841X	Exon 16	EGF	not applicable	0/400	1/200	RP81K	This study	Japanese			
		c.4957_4958insA	p.S1653KfsX2	Exon 26	Close to coiled-coil	not applicable	0/400	15/200	RP1H, RP3H, RP6H, RP12H, RP48K, RP51K, RP54K, RP44K, RP56K, RP87N, RP96H, RP100N	This study	Japanese			
	<b>Nonsense</b>	c.8868C>A	p.Y2956X	Exon 44	EGF	not applicable	0/400	5/200	RP8H, RP25H, RP35K, RP80K	This study	Japanese			
	<b>Deletion</b>	Deletion exon 32	p.D2142_52191delinsG	Exon 32	Laminin G	not applicable	0/200 <sup>d</sup>	2/200	RP21H	This study	Japanese			
	<b>Missense</b>	c.6557G>A	p.G2186E	Exon 32	Laminin G	G/G/G/G/G/G/-/-/-/-	0/400	2/200	RP44K, RP81K	Abd El-Aziz et al., 2010; Littink et al., 2010; This study	Chinese, South Korean/American, Japanese	Probably damaging	Pathological	Non-neutral
	c.7793G>A	p.G2598D	Exon 40	Close to Laminin G	G/G/G/-/-/-/-/G/A/T	0/400	1/200	RP87N	This study	Japanese	Probably damaging		Non-neutral	
c.8351T>G	p.L2784R	Exon 44	Laminin G	L/L/L/L/L/L/L/L/L/L/G	0/400	1/200	RP56K	This study	Japanese	Probably damaging		Non-neutral		
<b>Possible pathogenic mutations</b>	<b>Missense</b>	c.77G>A	p.R26Q	Exon 4	Close to signal peptide cleavage site	R/R/R/K/K/K/-/-/-/-	0/400	1/200	RP79K	This study	Japanese	Affected protein function		Pathological
	c.2923T>C	p.C975R	Exon 19	EGF	C/C/C/-/-/-/-/-/-	0/400	1/200	RP83K	This study	Japanese	Possibly damaging	Pathological	Non-neutral	
	c.5404C>T	p.L1802F	Exon 26	Close to Laminin G	L/L/L/-/-/-/-/-/-	0/400	1/200	RP74K	This study	Japanese	Possibly damaging			
	c.5884A>G	p.T1962A	Exon 28	Laminin G	T/T/T/T/-/-/-/-/-	0/400	1/200	RP53K	This study	Japanese	Possibly damaging			
	c.8875C>A	p.L2959M	Exon 44	EGF	L/L/L/L/L/L/A/N/-/S	0/400	1/200	RP9H	This study	Japanese	Possibly damaging			
	c.9272T>C	p.I3091T	Exon 44	Laminin G	V/V/V/V/V/V/V/L	0/400	3/200	RP4H, RP49K, RP55K	This study	Japanese	Affected protein function	Probably damaging		

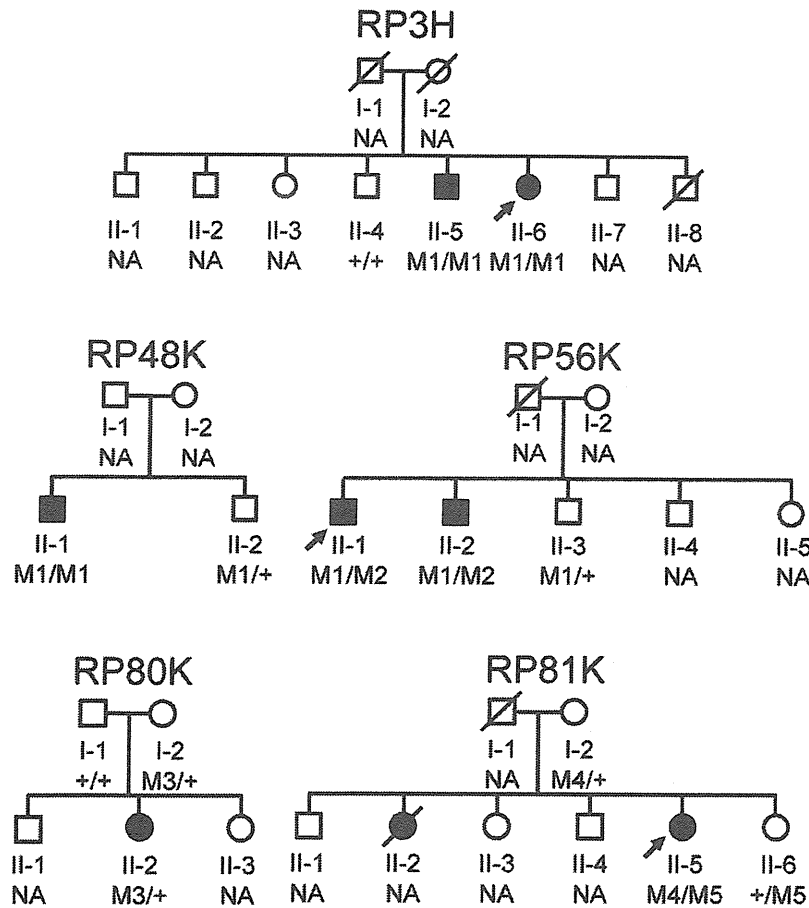
<sup>a</sup>EYS contains a signal peptide, a putative coiled-coil, 29 EGF, and 5 laminin G domains. See Fig. 3.

<sup>b</sup>hu/o/m/ho/d/op/p/c/z/dr denotes Human/Orangutan/Marmoset/Horse/Dog/Opossum/Platypus/Chicken/Zebrafish/Drosophila EYS orthologs, respectively. The hyphen (-) indicates that genomic sequence of corresponding region in the species was reported to be unknown [5].

<sup>c</sup>SIFT, PolyPhen2 (only the HumDiv data are shown), PMut, and SNAP were used as reference data to evaluate the pathogenicity of the missense mutations. c.77G>A, c.2923T>C, c.7793G>A, c.8351T>G, and c.9272T>C were predicted to be pathogenic by a number of different computational prediction programs. In addition, the c.6557G>A mutation, which had been previously reported as disease causing, was classified as pathogenic by the PolyPhen2, PMut, and SNAP programs.

<sup>d</sup>Homozygous exon 32 deletion mutation was not detected in 200 controls.

doi:10.1371/journal.pone.0031036.t002



**Figure 2. Pedigrees of the families that was available for mutation analysis.** Below the individuals, genotypes are presented for either p.S1653KfsX2 (M1), p.L2784R (M2), p.Y2956X (M3), p.Y841X (M4), or p.G2186E (M5) detected to segregate with RP. M1/M1 represents homozygous mutation. M1/+ indicates heterozygous carriers, +/+ indicates individuals carrying 2 wild-type alleles, whereas M1/M2 represents individuals presenting both mutations as compound heterozygous. Square boxes indicate men, circles denote women, and affected individuals are pointed out by a black symbol. Slashed symbols indicate deceased individuals. The probands are indicated with an arrow. NA denotes unavailable DNA samples. doi:10.1371/journal.pone.0031036.g002

c.4957\_4958insA/c.7793T>G (p.G2598D), respectively. None of these 7 very likely pathogenic mutations were found in the Japanese controls.

#### Families with single novel very likely pathogenic mutations

The rest of the patients comprising the group with very likely pathogenic mutations presented only single truncating mutations (Table 1 and Table 2). RP1H, RP6H, RP12H, RP51H, RP96H, and RP100N were heterozygous for c.4957\_4958insA. RP8H, RP25H, and RP80K were heterozygous for c.8868C>A. Segregation analysis was performed in patient RP80K. The unaffected father (I-1) demonstrated wild-type alleles, and the unaffected mother (I-2) was heterozygous for the mutation (Fig. 2). In RP96H, we found very likely pathogenic missense mutation c.8923T>C (p.F2975L), which was not detected in any of the 400 control alleles. However, as c.8923T>C has been described as rs79036642 in the dbSNP database, it was assigned to the group of possible non-pathogenic sequence alterations (Table 3).

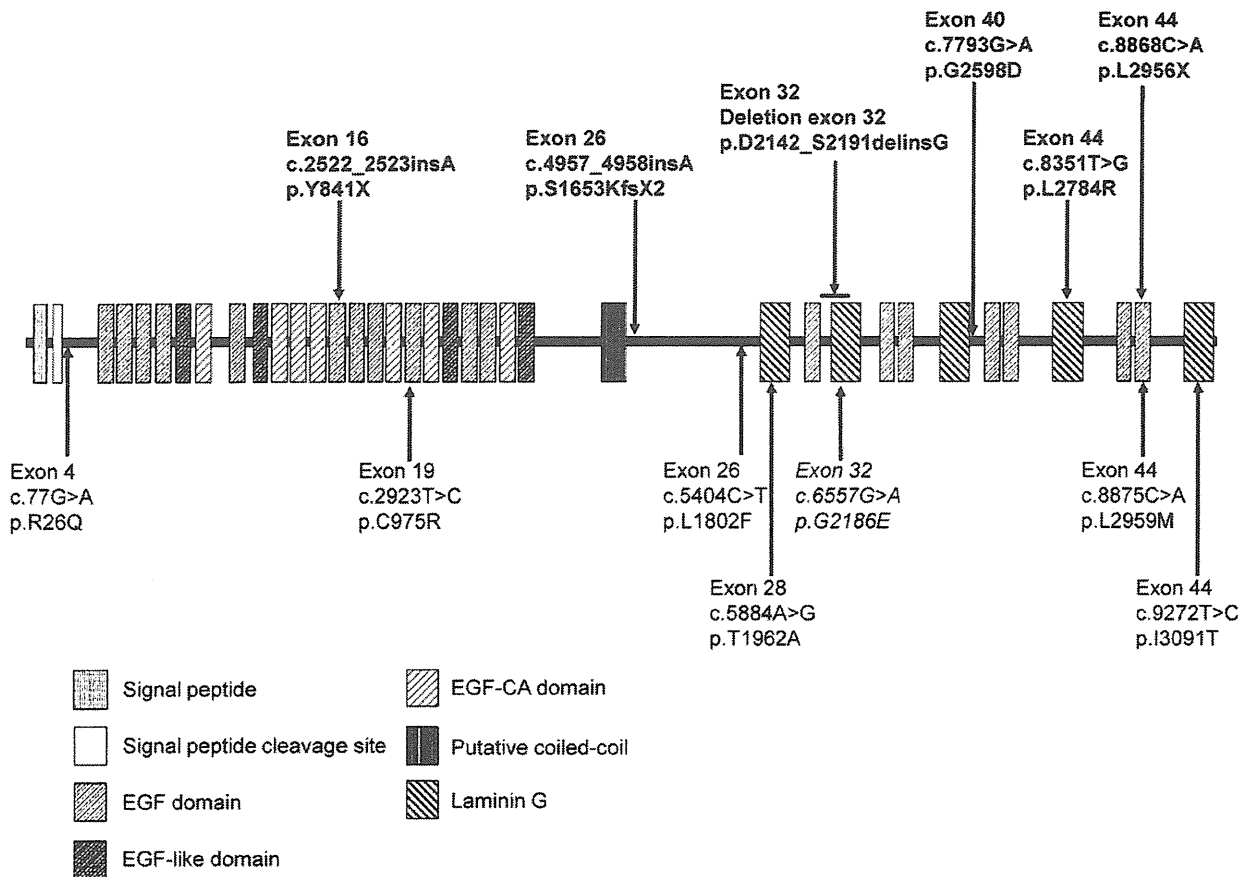
#### Families with single novel possible pathogenic mutations

A group of patients with possible pathogenic mutations had only single missense mutations (Table 1 and Table 2). We report 6

novel missense mutations in 8 different patients (Table 1 and Table 2), none of which were identified in the 400 Japanese control alleles. All amino acid residues affected by these mutations were compared with those encoded by orthologous genes of various vertebrates (orangutan, marmoset, horse, dog, opossum, platypus, chicken, and zebrafish) and *Drosophila* and found to be highly conserved across species (Table 2). The novel missense mutation c.2923T>C (p.C975R) was predicted to be pathogenic by 3 different computational prediction programs (PolyPhen2, PMut, and SNAP) (Table 2). RP4H, RP49K, and RP55K were heterozygous for the same missense mutation c.9272T>C (p.I3091T), which was predicted to be pathogenic by SIFT and PolyPhen2 programs (Table 2). In addition, 54 possible non-pathogenic sequence alterations were found, of which 9 were previously unreported (Table 3).

#### Screening of the 2 truncating mutations

We focused on 2 truncating mutations, c.4957\_4958insA in exon 26 and c.8868C>A in exon 44, which were identified in 16 separate Japanese arRP patients in this study. The frequency of the 2 mutations was very high in this Japanese arRP cohort. However, we did not detect the 2 mutations in 19 Japanese arRP



**Figure 3. Predicted domain structure and distribution of identified *EYS* mutations.** SMART (<http://smart.embl-heidelberg.de/>) and Pfam (<http://pfam.sanger.ac.uk/>) were used to search protein functional domains. A coiled-coil domain identified by Barragán et al. (2010) between the EGF-like domain and laminin G domain was also indicated. Novel very likely pathogenic mutations, novel possible pathogenic mutations, and a previously described mutation are shown in bold, normal, and italic type, respectively. Six out of 9 missense mutations were found in the EGF or laminin G domains. Furthermore, 7 were located in the latter half of the protein between the putative coiled-coil region and C-terminus. doi:10.1371/journal.pone.0031036.g003

patients and 28 LCA patients who were recruited and screened to evaluate the frequency of the mutations. We also recruited 32 unrelated Korean arRP patients and screened for the 2 *EYS* gene mutations. The c.4957\_4958insA mutation was detected in 2 patients and accounted for 3 of 64 Korean patient alleles (4.7%). One patient was homozygous and the other was heterozygous. The c.8868C>A mutation was identified in 1 patient and accounted for 1 of the 64 Korean patient alleles (1.6%).

### Clinical findings

Nine Japanese patients with very likely pathogenic *EYS* gene mutations in both alleles, 9 Japanese patients with single very likely pathogenic changes, and a Korean patient with homozygous c.4957\_4958insA mutation demonstrated classic RP with mostly night blindness as the initial symptom, followed by gradual constriction of the visual field. The fundus displayed bone spicules increasing in density with age and attenuated retinal vessels. Electroretinogram responses were not detectable, consistent with severe generalized rod-cone dysfunction. The remaining visual field determined using Goldmann kinetic perimetry with V-4 target ranged from approximately 10° to 60° of the central and inferior visual fields, respectively, in a 74-year-old woman (RP100N) to complete blindness in a 54-year-old man (RP21H).

No remarkable clinical difference was observed between 9 patients with very likely pathogenic *EYS* gene mutations in both alleles and 9 patients with single very likely pathogenic changes.

### Discussion

This study is the first to analyze mutations in the *EYS* gene among Japanese arRP patients. We detected 67 sequence alterations in the *EYS* gene, of which 21 were novel. Of these, 7 were very likely pathogenic mutations, 6 were possibly pathogenic mutations, and 54 were possible non-pathogenic sequence alterations (Table 1, Table 2, and Table 3).

Considering only the very likely pathogenic mutations, the minimum observed prevalence of distinct *EYS* gene mutations in our study is 18% (18/100, 9 patients with 2 very likely pathogenic mutations and 9 with only one such mutations). Additionally, if the possible pathogenic mutations are included in the prevalence estimation, prevalence increases to 26% (26/100, with 17 of 26 patients presenting single mutations). The estimated prevalence in our study may be extremely high compared with those in the previous studies [3–6]. Until recently, mutations in 34 genes have been associated with arRP (<http://www.sph.uth.tmc.edu/Retnet/>). The most frequently mutated gene is *USH2A*, accounting for

**Table 3.** Summary of the possible non-pathogenic sequence alterations in the *EYS* gene identified in this study.

Gene exon	Nucleotide change	Predicted effect	Conservation in hu/o/m/ho/d/op/p/c/z/dr <sup>a</sup>	Patient frequency	Control frequency	SNP ID	Reference	
Exon 1	c.-500A>G			13/200		rs1490127	Abd El-Aziz et al., 2010	
Exon 4	c.334G>A	p.V112I	V/V/V/V/V/-/-/E	1/200	0/192	rs112609906		
	c.359C>T	p.T120M	T/T/T/T/T/A/-/-/I	60/200		rs12193967	Audo et al., 2010; Abd El-Aziz et al., 2010	
	c.525_527delGGA	p.176delE	E/E/E/E/E/A/-/-/G	1/200	1/192		This study	
Intron 5	c.863-23_863-22insTT			53/200		rs34154043	Abd El-Aziz et al., 2010	
	c.863-23_863-22insTTT			44/200			This study	
Exon 6	c.1005G>T	p.E335D	E/E/D/-/-/-/-/-	3/200		rs80095433		
Exon 7	c.1146T>C	p.N382N	N/N/T/-/-/-/-/-	97/200		rs974110	Audo et al., 2010; Abd El-Aziz et al., 2010	
Intron 8	c.1300-3C>T			117/200		rs1936439	Audo et al., 2010; Abd El-Aziz et al., 2010	
Exon 9	c.1382G>A	p.C461Y	C/C/Y/-/-/-/-/-	8/200	4/192	rs76754818	Littink et al., 2010	
Intron 9	c.1599+96A>C			200/200		rs1502963	Abd El-Aziz et al., 2010	
Intron 10	c.1600-38G>A			12/200		rs1502965	Abd El-Aziz et al., 2010	
Exon 11	c.1712A>G	p.Q571R	Q/Q/Q/-/-/-/-/-	26/200		rs61753610	Audo I et al., 2010	
Exon 12	c.1809C>T	p.V603V	V/V/N/-/-/-/-/-	178/200		rs9345601	Audo et al., 2010; Abd El-Aziz et al., 2010	
	c.1891G>A	p.G631S	G/S/E/C/C/-/-/-/-	178/200		rs9342464	Audo et al., 2010; Abd El-Aziz et al., 2010	
	c.1922A>T	p.E641V	E/E/E/E/E/-/-/-/-	18/200		rs17411795	Audo et al., 2010; Abd El-Aziz et al., 2010	
	c.1985G>T	p.R662M	R/R/R/S/S/-/-/-/-	8/200	3/96		This study	
Intron 12	c.2023+6_2023+7insT			175/200		rs67504324		
	c.2024-14C>T			3/200		rs45628235		
Intron 15	c.2382-26C>G			106/200		rs9445437		
Exon 16	c.2490T>C	p.P830P	P/P/P/P/P/P/P/Q/P/-	2/200	1/392		This study	
	c.2528G>A	p.G843E	G/G/G/G/G/G/G/G/A/G	16/200	9/192	rs74419361		
	c.2555T>C	p.L852P	L/P/P/-/S/P/S/P/-/E	106/200		rs9294631	Audo et al., 2010; Abd El-Aziz et al., 2010	
Intron 18	c.2846+52_2846+53insTAAT			120/200		rs66504228	Abd El-Aziz et al., 2010	
	c.2847-24C>T			178/200		rs7743515		
Exon 19	c.2980C>G	p.P994A	P/P/P/-/-/-/-/-	3/200	2/192		This study	
Intron 22	c.3444-5C>T			69/200		rs9445051	Audo et al., 2010; Abd El-Aziz et al., 2010	
Intron 23	c.3568+60delA			1/200			This study	
Exon 25	c.3787A>G	p.I1263V	I/V/V/V/V/-/-/-/I	36/200		rs17404123	Audo et al., 2010; Abd El-Aziz et al., 2010	
	c.3809T>G	p.V1270G	V/V/V/V/V/-/-/-/P	1/200	1/192		This study	
Intron 25	c.3877+17_22delAGATA			36/200			Barragán I et al., 2010	
Exon 26	c.3906C>T	p.H1302H	H/H/H/H/H/-/-/-/S	10/200		rs12663916	Audo et al., 2010; Abd El-Aziz et al., 2010	
	c.3936A>G	p.T1312T	T/A/T/A/A/-/-/-/S	10/200		rs12662610	Audo et al., 2010; Abd El-Aziz et al., 2010	
	c.3973C>G	p.Q1325E	Q/E/K/K/K/-/-/-/S	12/200		rs12663622	Audo et al., 2010; Abd El-Aziz et al., 2010	
	c.4026C>T	p.S1342S	S/S/S/S/S/-/-/-/A	10/200		rs12663619	Audo et al., 2010; Abd El-Aziz et al., 2010	
	c.4081A>G	p.I1361V	I/V/T/V/V/-/-/-/S	12/200		rs17403955	Audo et al., 2010; Abd El-Aziz et al., 2010	
	c.4256T>C	p.L1419S	L/S/S/S/S/L/S/N/Q/V	137/200		rs624851	Audo et al., 2010; Abd El-Aziz et al., 2010	
	c.4352T>C	p.I1451T	I/T/T/K/K/-/-/-/T	13/200		rs62415828	Audo et al., 2010; Abd El-Aziz et al., 2010	
	c.4543C>T	p.R1515W	R/R/R/R/R/-/-/-/H	36/200		rs62415827	Audo et al., 2010; Abd El-Aziz et al., 2010	
	c.4549A>G	p.S1517G	S/G/D/T/T/-/-/-/H	36/200		rs62415826	Audo et al., 2010; Abd El-Aziz et al., 2010	
	c.4593G>A	p.E1531E	E/E/E/E/E/-/-/-/Q	36/200		rs62415825	Audo et al., 2010; Abd El-Aziz et al., 2010	
	c.5244A>C	p.L1748F	L/L/L/L/L/-/-/-/F	8/200		rs57312007	Audo I et al., 2010; Littink et al., 2010	
	c.5617C>G	p.L1873V	L/L/L/P/P/-/-/-/I	38/200		rs16895517	Audo I et al., 2010	
	Exon 27	c.5705A>T	p.N1902I	N/N/N/N/N/P/-/R/-/A	90/200		rs9353806	Audo et al., 2010; Abd El-Aziz et al., 2010
	Intron 28	c.5928-35T>C			118/200		rs587278	Abd El-Aziz et al., 2010
Intron 29	c.6078+68A>G			81/200		rs36133910	Abd El-Aziz et al., 2010	
	c.6079-4_6079-3delTC			87/200		rs35395170	Audo I et al., 2010	
Intron 34	c.6834+61T>G			60/200		rs66502009	Abd El-Aziz et al., 2010	

Table 3. Cont.

Gene exon	Nucleotide change	Predicted effect	Conservation in hu/o/m/ho/d/op/p/c/z/dr <sup>a</sup>	Patient frequency	Control frequency	SNP ID	Reference
Exon 35	c.6977G>A	p.R2326Q	R/R/R/L/L/L/L/L/I/L	95/200		rs4710457	Audo et al., 2010; Abd El-Aziz et al., 2010
Exon 37	c.7394C>G	p.T2465S	T/T/T/T/T/T/T/S/F	8/200	2/176		This study
Exon 39	c.7666A>T	p.S2556C	S/S/S/S/S/N/S/H/E/E	57/200		rs66462731	Audo et al., 2010; Abd El-Aziz et al., 2010; Barragán et al., 2010; Littink et al., 2010
Intron 41	c.8071+84T>G			53/200		rs4710257	Abd El-Aziz et al., 2010
Exon 44	c.8923T>C	p.F2975L	F/F/F/F/F/F/F/-/K	1/200	0/400	rs79036642	
	c.9300A>G	p.L3100L	L/L/L/L/L/L/L/V/I	4/200	2/192		This study

Fifty-four sequence alterations were identified in 100 patients. These alterations were predicted to be non-pathogenic for various reasons. Some have been reported as polymorphisms in previous reports. Newly identified alterations within the exons, except for c.334G>A and c.8923T>C, were also found in the control chromosome. The hyphen (-) indicates that genomic sequence of corresponding region in the species was reported to be unknown [5].

<sup>a</sup>hu/o/m/ho/d/op/p/c/z/dr denotes Human/Orangutan/Marmoset/Horse/Dog/Opossum/Platypus/Chicken/Zebrafish/Drosophila *EYS* orthologs, respectively.

doi:10.1371/journal.pone.0031036.t003

approximately 7% of arRP cases [9,10], whereas most other genes contribute to only 1% to 2% of arRP cases [11]. The estimated prevalence of very likely and possible pathogenic mutations of the *EYS* gene in our study was 26%, suggesting its major involvement in the pathogenesis of arRP in the Japanese population.

We found that 16% of Japanese arRP patients displayed at least one c.4957\_4958insA or c.8868C>A mutation, which accounted for 57.1% (15+5/35) of the mutated alleles. Thus, these mutations seem to be frequent among Japanese arRP patients. Previous studies employing Indonesian, Pakistani, Chinese, Israeli, Spanish, French, British, Dutch, and Palestinian RP patient populations have not detected them [3–6,12–15]. Since the Japanese were divided into small semi-closed population groups among which intercommunication was quite less until the mid-20<sup>th</sup> century, obvious or latent consanguineous marriages were carried out more frequently, leading to relatively high inbreeding levels in those populations. The frequency of the c.4957\_4958insA and c.8868C>A mutations may result from a founder effect like that of the 2299delG *USH2A* gene mutation, which accounts for 44% of disease alleles in Danish and Norwegian patients with Usher syndrome type II [16].

We detected 13 different very likely and possible pathogenic mutations. Three were truncating mutations and accounted for 60% (21/35) of mutated alleles. Likewise, previous studies reported that most pathogenic mutations were truncated type (nonsense, deletion, insertion, or splicing) [3–6,12–15]. Furthermore, c.6557G>A was the only mutation that was common between the Japanese and other populations. This mutation has been found in Korean/American and Chinese patients [3,6]. These results indicate that the *EYS* gene mutation spectrum among Japanese patients largely differs from that among the previously mentioned non-Asian populations. The Japanese and Korean mutation spectrum may resemble each other, but an accurate comparison could not be made, because further *EYS* gene analysis of Korean RP patients is required to clarify this possibility.

A second mutant allele could not be detected by direct sequencing in 17 of 26 patients in our study. Previous studies reported 7 of 10 [3] and 9 of 17 [5] patients with heterozygous *EYS* gene mutation, implying that this finding could be due to relatively large heterozygous deletions [15]. The second mutation in these families may also have been located within the gene regulatory elements or unknown exons including alternative splicing areas.

Although rare, a single *EYS* mutation in combination with another mutation on a second gene could also explain this phenotype [3].

The c.4957\_4958insA and c.8868C>A mutations were not detected in Japanese patients with adRP or with LCA. Abd El-Aziz et al. reported that *EYS* gene mutation screening did not reveal any pathogenic mutations in 95 British and Chinese adRP patients [3]. Bandah-Rosenfeld et al. reported that no mutation was found in 2 Oriental Jewish and Israeli Muslim LCA patients who had a large homozygous region harboring the *EYS* gene [12]. Although further analysis of all *EYS* gene exons is required, *EYS* gene mutations may not be detected in Japanese patients with adRP and LCA. The c.4957\_4958insA and c.8868C>A mutations were also detected in Korean patients with arRP and accounted for 6.3% (4/64 alleles) of the disease alleles. Similar to Japanese arRP results, the c.4957\_4958insA mutation was more frequently detected than the c.8868C>A mutation. The fact that both c.4957\_4958insA and c.8868C>A mutations were also detected in Korean patients suggests the possibility that the mutations occurred in an ancient common ancestor and spread throughout East Asia.

RP is a highly heterogeneous disease, with a reported prevalence rate of 1 in 4,000–8,000 people in Japan. Given the population of Japan, approximately a 100 million, the number of patients with RP can be estimated to be 12,500–25,000. The relative frequencies of RP inheritance patterns in Japanese patients were estimated as 25.2% for autosomal recessive, 16.9% for autosomal dominant, 1.6% for X-linked, and 56.3% for simplex, indicating that most Japanese RP patients represent arRP or isolated cases [17]. Autosomal recessive and simplex cases account over 80% of RP cases in Japan (approximately 10,000–20,000 people). Our results indicate that c.4957\_4958insA and c.8868C>A mutations are possibly present in 1,600–3,200 Japanese patients with RP. These 2 novel mutations will be very useful for genetic diagnosis and counseling, and analysis of the mutated proteins may be helpful in the development of effective therapies for RP in Japan and Korea.

In conclusion, mutation screening of the *EYS* gene in 100 Japanese patients revealed 13 different pathogenic mutations, confirming that the mutation spectrum in Japanese patients differs from the previously reported spectrum in patients of non-Asian populations. Among these 13 mutations, 2 truncating mutations, c.4957\_4958insA and c.8868C>A, were detected in at least one mutated allele in 16% of Japanese arRP patients and may be the

most frequent mutations causing RP in the Japanese populations. Screening for c.4957\_4958insA and c.8868C>A mutations in the *EYS* gene is, therefore, very effective for the genetic testing and counseling of RP patients in Japan. Further analysis is necessary to obtain a more precise mutation spectrum and to identify other frequent mutations in other East Asian populations.

### Supporting Information

**Table S1 PCR primer sequences for human *EYS*.**  
(DOC)

### References

1. Abd El-Aziz MM, Barragán I, O'Driscoll CA, Goodstadt L, Prigmore E, et al. (2008) *EYS*, encoding an ortholog of *Drosophila* spacemaker, is mutated in autosomal recessive retinitis pigmentosa. *Nat Genet* 40: 1285–1287.
2. Collin RW, Littink KW, Klevering BJ, van den Born LI, Koenekoop RK, et al. (2008) Identification of a 2 Mb human ortholog of *Drosophila* eyes shut/spacemaker that is mutated in patients with retinitis pigmentosa. *Am J Hum Genet* 83: 594–603.
3. Abd El-Aziz MM, O'Driscoll CA, Kaye RS, Barragán I, El-Ashry MF, et al. (2010) Identification of novel mutations in the ortholog of *Drosophila* eyes shut gene (*EYS*) causing autosomal recessive retinitis pigmentosa. *Invest Ophthalmol Vis Sci* 51: 4266–4272.
4. Audo I, Sahel JA, Mohand-Saïd S, Lancelot ME, Antonio A, et al. (2010) *EYS* is a major gene for rod-cone dystrophies in France. *Hum Mutat* 31: E1406–1435.
5. Barragán I, Borrego S, Pieras JI, González-del Pozo M, Santoyo J, et al. (2010) Mutation spectrum of *EYS* in Spanish patients with autosomal recessive retinitis pigmentosa. *Hum Mutat* 31: E1772–1800.
6. Littink KW, van den Born LI, Koenekoop RK, Collin RW, Zonneveld MN, et al. (2010) Mutations in the *EYS* gene account for approximately 5% of autosomal recessive retinitis pigmentosa and cause a fairly homogeneous phenotype. *Ophthalmology* 117: 2026–2033.
7. Hotta Y, Shiono T, Hayakawa M, Hashimoto T, Kanai A, et al. (1992) Molecular biological study of the rhodopsin gene in Japanese patients with autosomal dominant retinitis pigmentosa. *Nihon Ganka Gakkai Zasshi* 96: 237–242.
8. Jin ZB, Mandai M, Yokota T, Higuchi K, Ohmori K, et al. (2008) Identifying pathogenic genetic background of simplex or multiplex retinitis pigmentosa patients: a large scale mutation screening study. *J Med Genet* 45: 465–472.
9. Rivolta C, Sweklo EA, Berson EL, Dryja TP (2000) Missense mutation in the *USH2A* gene: association with recessive retinitis pigmentosa without hearing loss. *Am J Hum Genet* 66: 1975–1978.
10. Seyedahmadi BJ, Rivolta C, Keene JA, Berson EL, Dryja TP (2004) Comprehensive screening of the *USH2A* gene in Usher syndrome type II and non-syndromic recessive retinitis pigmentosa. *Exp Eye Res* 79: 167–173.
11. Hartong DT, Berson EL, Dryja TP (2006) Retinitis pigmentosa. *Lancet* 368: 1795–1809.
12. Bandah-Rozenfeld D, Littink KW, Ben-Yosef T, Strom TM, Chowers I, et al. (2010) Novel null mutations in the *EYS* gene are a frequent cause of autosomal recessive retinitis pigmentosa in the Israeli population. *Invest Ophthalmol Vis Sci* 51: 4387–4394.
13. Huang Y, Zhang J, Li C, Yang G, Liu M, et al. (2010) Identification of a novel homozygous nonsense mutation in *EYS* in a Chinese family with autosomal recessive retinitis pigmentosa. *BMC Med Genet* 11: 121.
14. Khan MI, Collin RW, Arimadyo K, Micheal S, Azam M, et al. (2010) Missense mutations at homologous positions in the fourth and fifth laminin A G-like domains of eyes shut homolog cause autosomal recessive retinitis pigmentosa. *Mol Vis* 16: 2753–2759.
15. Pieras JI, Barragán I, Borrego S, Audo I, González-Del Pozo M, et al. (2011) Copy-number variations in *EYS*: a significant event in the appearance of arRP. *Invest Ophthalmol Vis Sci* 52: 5625–5631.
16. Dreyer B, Tranebjaerg L, Brox V, Rosenberg T, Möller C, et al. (2001) A common ancestral origin of the frequent and widespread 2299delG *USH2A* mutation. *Am J Hum Genet* 69: 228–234.
17. Hayakawa M, Fujiki K, Kanai A, Matsumura M, Honda Y, et al. (1997) Multicenter genetic study of retinitis pigmentosa in Japan: I. Genetic heterogeneity in typical retinitis pigmentosa. *Jpn J Ophthalmol* 41: 1–6.

### Acknowledgments

We would like to thank the families who participated in the study.

### Author Contributions

Conceived and designed the experiments: KH MT SY MK YH. Performed the experiments: KH CI YZ. Analyzed the data: KH CI. Contributed reagents/materials/analysis tools: MT DHP YH HN SU TY AH TF SN JPS ITK SY NA HT MS MK YH. Wrote the paper: KH SM YH.

# Clinical Features of Congenital Retinal Folds

SACHIKO NISHINA, YUMI SUZUKI, TADASHI YOKOI, YURI KOBAYASHI, EIICHIRO NODA, AND NORIYUKI AZUMA

• **PURPOSE:** To investigate the clinical features and prognosis of congenital retinal folds without systemic associations.

• **DESIGN:** Retrospective observational case series.

• **METHODS:** The characteristics, clinical course, ocular complications, and best-corrected visual acuity (BCVA) of eyes with congenital retinal folds were studied during the follow-up periods. The affected and fellow eyes were examined by slit-lamp biomicroscopy, binocular indirect ophthalmoscopy, and fundus fluorescein angiography. The parents and siblings of each patient also underwent ophthalmoscopic examinations. The BCVA was measured using a Landolt ring VA chart.

• **RESULTS:** One hundred forty-seven eyes of 121 patients with congenital retinal folds were examined. Fifty-five patients (45.5%) were female. The fold was unilateral in 95 patients (78.5%), and 69 of those patients (72.6%) had retinal abnormalities in the fellow eye. The meridional distribution of folds was temporal in 136 eyes (92.5%). The family history was positive in 32 patients (26.4%). Secondary fundus complications, including fibrovascular proliferation and tractional, rhegmatogenous, and exudative retinal detachments, developed in 44 eyes (29.9%). The BCVAs could be measured in 119 eyes and ranged from 20/100 to 20/20 in 5 eyes (4.2%), 2/100 to 20/200 in 45 eyes (37.8%), and 2/200 or worse in 69 eyes (58.0%). The follow-up periods ranged from 4 to 243 months (mean,  $79.7 \pm 58.9$  months).

• **CONCLUSIONS:** These clinical features suggested that most congenital retinal folds may result from insufficient retinal vascular development, as in familial exudative vitreoretinopathy, rather than persistent fetal vasculature. Adequate management of active retinopathy and late-onset complications, especially retinal detachment, is required. (*Am J Ophthalmol* 2012;153:81–87. © 2012 by Elsevier Inc. All rights reserved.)

**A** CONGENITAL RETINAL FOLD (ABLATIO FALCIFORMIS congenital), extending radially from the optic disc toward the peripheral fundus, was first described in 1935 as a rare congenital anomaly.<sup>1,2</sup> The pathogenesis was investigated histologically, and the

Accepted for publication Jun 6, 2011.

From the Division of Ophthalmology, National Center for Child Health and Development, Tokyo, Japan.

Inquiries to Noriyuki Azuma, Division of Ophthalmology, National Center for Child Health and Development, 2-10-1 Ohkura, Setagaya-ku, Tokyo, 157-8535, Japan; e-mail: azuma-n@ncchd.go.jp

anomaly was hypothesized to be attributable to persistent hyaloid vessels leading to a pulled dysplastic retina. In 1955, Reese reported the clinical and pathologic features of persistent hyperplastic primary vitreous (PHPV).<sup>3</sup> In 1965, Michaelson<sup>4</sup> introduced the term “posterior PHPV,”<sup>4</sup> and in 1970 Pruett and Schepens<sup>5</sup> described a new clinical entity called “posterior hyperplastic primary vitreous,” the posterior form of PHPV, characterized by vitreous membranes extending from the disc toward the peripheral fundus. Those investigators used the term posterior PHPV as a synonym for falciform retinal folds and the term anterior PHPV as a synonym for the PHPV described by Reese.<sup>3</sup> Thus, congenital retinal folds often were diagnosed as posterior PHPV afterward. The term PHPV now has evolved to persistent fetal vasculature (PFV), which usually occurs as a nonheritable set of vascular malformations affecting 1 eye of an otherwise normal infant.<sup>6</sup> However, based on the fundus drawings of Pruett and Schepens,<sup>5</sup> vitreous membranes and retinal folds were not clearly distinguished. Those authors reported that the vitreous band and retinal folds extended toward the fundus periphery in various meridians but were most commonly nasal.<sup>5</sup> They also described the pleomorphism of posterior PHPV and complications such as microcornea, retinal detachment, vitreous hemorrhage, cataract, and glaucoma.<sup>7</sup> In most cases, posterior PHPV is unilateral and rarely familial.

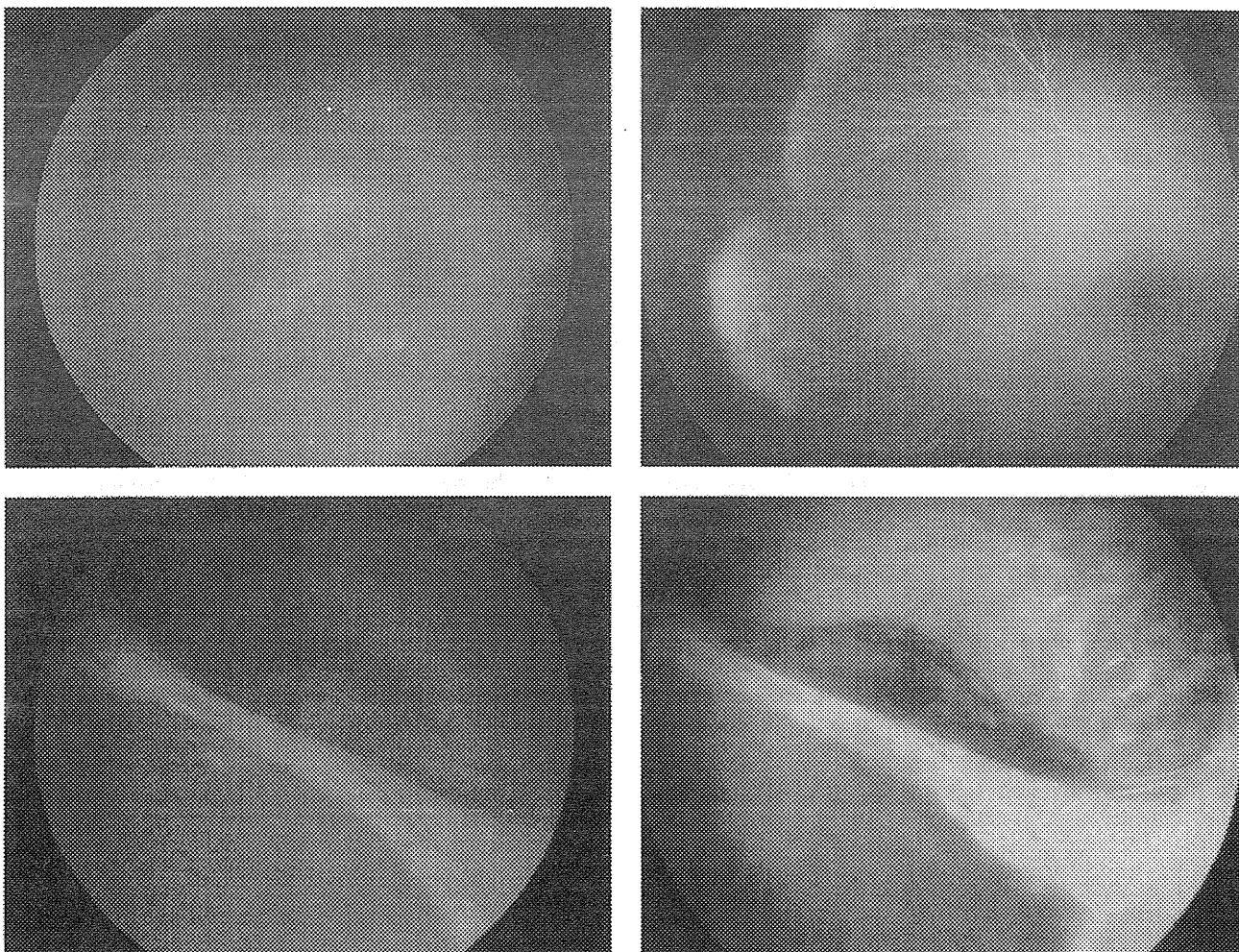
In 1969, familial (dominant) exudative vitreoretinopathy (FEVR), a developmental disorder of the retinal vasculature, was described and suggested to be the possible origin of congenital retinal folds.<sup>8–10</sup> Recently, congenital retinal folds were thought to occur even after birth and were caused by various infantile diseases such as FEVR, retinopathy of prematurity (ROP), Norrie disease, incontinentia pigmenti, and congenital toxoplasmosis. However, clinically distinguishing retinal folds without systemic associations is often difficult, and their pathogenesis remains controversial.

We conducted the current study to clarify the clinical features of congenital retinal folds without systemic associations.

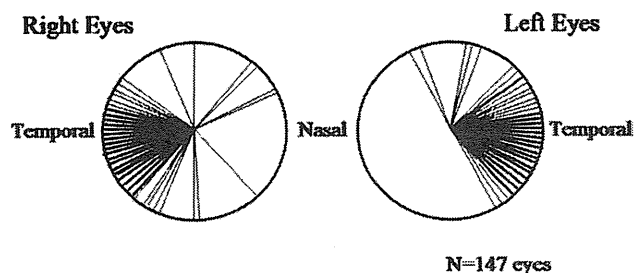
## METHODS

ONE HUNDRED FORTY-SEVEN EYES OF 121 PATIENTS WITH unilateral or bilateral congenital retinal folds, diagnosed at the National Center for Child Health and Development,





**FIGURE 1.** Unilateral congenital fold with retinal vascular abnormalities in the fellow eye. Fundus photographs and fluorescein angiography (FA) of a unilateral retinal fold in the left eye (Bottom left and right) and the fellow right eye (Top left and right) in a 4-month-old boy. (Top left) Retinal vascular abnormalities in the peripheral fundus are seen in the fellow right eye. (Top right) FA shows a peripheral avascular zone, supernumerous vascular branchings, arteriovenous shunt formation, a V-shaped area of degeneration, and neovascularization with dye leakage in the fellow right eye. Laser photocoagulation was applied to the peripheral avascular retina. (Bottom left) The retinal vessels within the fold are bundled and pulled toward the peripheral fibrous tissue and decreased in number in the stretched retina. (Bottom right) FA shows hyperfluorescence from folds in which the vessels are bundled and dye leakage from the fibrovascular tissue. Scleral buckling with laser photocoagulation was applied.



**FIGURE 2.** Meridional distribution of congenital retinal folds. The meridional distribution of the folds was temporal, superotemporal, or inferotemporal in 92.5% (136/147) eyes.

Tokyo, Japan, between June 1986 and February 2009, and examined between March 2002 and April 2009, were studied retrospectively. Patients with a history of premature birth, oxygen therapy, systemic associations, or positive laboratory examinations for infectious diseases were excluded. Eyes with anterior segment dysgenesis also were excluded.

The characteristics of retinal folds in affected eyes and findings in fellow eyes were examined by slit-lamp biomicroscopy and binocular indirect ophthalmoscopy. Thirty-six patients (29.8%) underwent fundus fluorescein angiography (FA) under general anesthesia. In patients with a unilateral retinal fold, the fundus periphery of the fellow eye also was examined and the retinal vascular development was evaluated. The criteria used to diagnose



**TABLE. Features of Secondary Ocular Complications in the Fundus in Eyes With Congenital Retinal Folds (N = 44 Eyes)**

	Tractional Retinal Detachment N = 19 Eyes	Rhegmatogenous Retinal Detachment N = 12 Eyes	Fibrovascular Proliferation N = 11 Eyes	Exudative Retinal Detachment N = 2 Eyes
Age at onset (months)	1-88 (mean, 25.8 ± 27.2)	33-195 (mean, 87.0 ± 56.5)	2-121 (mean, 19.4 ± 35.8)	31, 167
Origin of complications	Excessive fibrovascular proliferation, 15 (79%) Regrowth of fibrovascular tissue, 4 (21%)	Ocular trauma, 5 (42%) Unknown, 7 (58%)	NV, 10 (91%) Recurrence of NV, 1 (9%)	Unknown 2 (100%)
Treatment	V + L, 6 (32%) B + PC, 4 (21%) None, 9 (47%)	V + L, 5 (42%) V + L + B, 4 (33%) B, 2 (17%) None, 1 (8%)	V + L, 5 (46%) PC, 4 (36%) B + PC, 1 (9%) None, 1 (9%)	None, 2 (100%) <sup>a</sup>
Surgical outcomes	Retinal reattachment, 7/10 (70%)	Retinal reattachment, 3/11 (27%)	NV stabilization, 8/10 (80%)	

B = scleral buckling; B + PC = scleral buckling with laser photocoagulation; NV = neovascularization; PC = laser photocoagulation; V + L = vitrectomy with lensectomy; V + L + B = vitrectomy with lensectomy and scleral buckling.

<sup>a</sup>Untreated retinas reattached spontaneously.

retinal vascular abnormalities were the presence of a peripheral avascular zone, vitreoretinal adhesions, arteriovenous shunt formation, supernumerous vascular branchings, a V-shaped area of retinal degeneration, neovascularization, and cystoid degeneration.<sup>11-13</sup> Ophthalmoscopic examinations of the parents and siblings of each patient were performed when possible. A family history was judged to be present if retinal vascular abnormalities were found in any family members. The clinical course and the secondary ocular complications were investigated during the follow-up periods. The best-corrected visual acuities (BCVAs) were measured with a standard Japanese VA chart using Landolt rings at 5 meters and converted to Snellen VA. The follow-up periods ranged from 4 to 243 months (mean, 79.7 ± 58.9 months).

## RESULTS

• **CHARACTERISTICS OF EYES AND PATIENTS:** Sixty-six of the 121 patients (54.5%) were male and 55 (45.5%) were female. The ages of the patients at the first examination at our hospital ranged from 4 weeks to 9 years 1 month (mean, 17.9 ± 21.6 months). However, the families or pediatricians had observed the clinical manifestations, that is, poor fixation behavior, nystagmus, or strabismus, by 12 months of age in 105 patients (86.8%), and 91 patients (75.2%) had been examined by other ophthalmologists within the first year. A unilateral retinal fold in 16 patients (13.2%) identified after 13 months of age was confirmed not to have any acquired pathogenesis and diagnosed as a congenital retinal fold.

The retinal vessels within the fold were bundled and pulled toward the peripheral fibrous tissue and decreased in number in the stretched retina in 144 of 147 eyes (98.0%) (Figure 1, Bottom left). A peripheral avascular zone was seen more than 3 disc diameters' width in all eyes. Other ophthalmoscopic findings in affected eyes were intravitreal neovascularization in 13 eyes (8.8%), retinal hemorrhages in 8 eyes (5.4%), disc anomalies in 4 eyes (2.7%), retinal exudates in 3 eyes (2.0%), and coloboma and medullated nerve fiber in 1 eye (0.7%) each. Fundus FA, performed on 46 eyes of 36 patients, showed hyperfluorescence from bundling of the retinal vessels in the folds and fibrovascular tissue at the periphery of the folds in all eyes (100%). Dye leakage from an arteriovenous shunt and intravitreal neovascularization within the fibrovascular tissue was detected in 13 eyes (28.3%) (Figure 1, Bottom right).

• **MOST CASES OF CONGENITAL RETINAL FOLD WERE UNILATERAL AND ORIGINATED IN THE TEMPORAL QUADRANTS:** The fold was unilateral in 95 of 121 patients (78.5%) and bilateral in 26 patients (21.5%). The meridional distribution of the folds was temporal, superotemporal, or inferotemporal in 136 of 147 eyes (92.5%) (Figure 2). All folds in the other 11 eyes were unilateral, extending nasally, superonasally, inferonasally, superiorly, or inferiorly.

• **MOST CASES OF UNILATERAL RETINAL FOLD HAD IDENTIFIABLE ABNORMALITIES IN THE FELLOW EYE:** Only 26 cases (27.4%) of the 95 unilateral retinal folds identified demonstrated no pathology in the fellow eye. The remaining 72.6% had identifiable abnormalities as

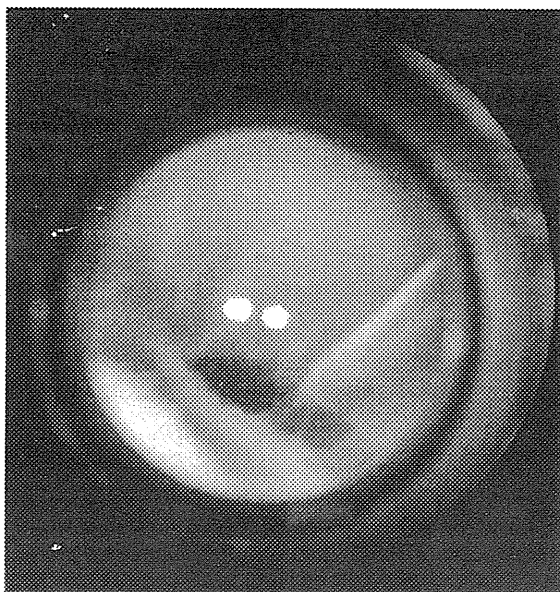
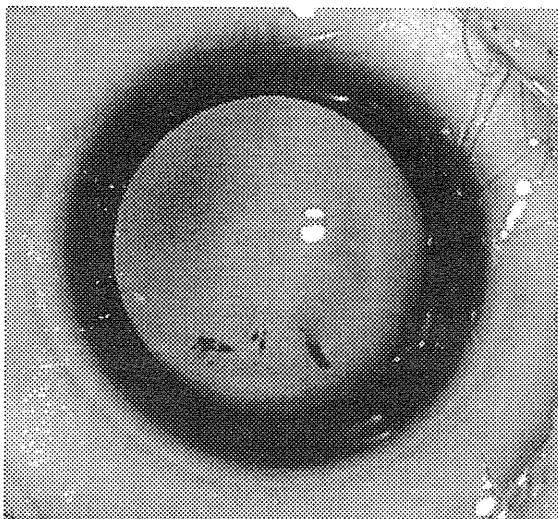
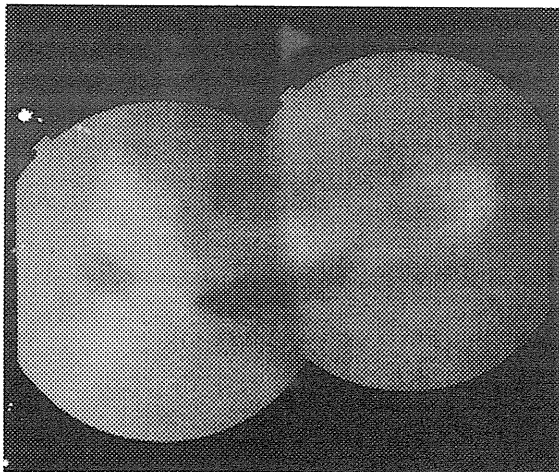


FIGURE 3. Secondary complications of congenital retinal folds. Photographs of secondary complications in the fundus of a 4-month-old girl (Top and Middle) and a 37-month-old boy (Bottom). (Top) Prominent fibrovascular proliferation

follows. Retinal vascular abnormalities in the peripheral fundus were identified in 33 of 95 cases (34.7%): an avascular zone in all eyes (100%), supernumerous vascular branchings in 15 eyes (45.5%), cystoid degeneration in 12 eyes (36.4%), a V-shaped area of retinal degeneration in 9 eyes (27.3%), vitreoretinal adhesions and fibrous membrane in 7 eyes (21.2%) each, arteriovenous shunt formation in 5 eyes (15.2%), and neovascularization in 4 eyes (12.1%) (Figure 1, Top left and right). A total retinal detachment and leukokoria, a dragged retina, and coloboma were found in 18 (18.9%), 17 (17.9%), and 1 (1.1%) of 95 cases, respectively.

The "true" unilateral congenital fold was seen in 26 patients out of all 121 patients (21.5%). Among these 26 patients, the meridional distribution of the folds was temporal in 17 eyes (65.4%) and nasally, superiorly, or inferiorly in 9 eyes (34.6%).

Fundus FA was performed on 24 fellow eyes in patients with a unilateral retinal fold and clearly showed various retinal vascular abnormalities in 18 eyes (75.0%). Hyperfluorescence of the vascular abnormalities in the periphery was seen in 8 of the 24 eyes (33.3%), in which dye leakage from the neovascularization was detected in 4 eyes (4/24; 16.7%) (Figure 1, Top right).

Among the 50 fellow eyes with retinal vascular abnormalities in the periphery or dragged retina, laser photocoagulation was applied to the peripheral avascular retina in 7 eyes (14.0%) and the neovascularization stabilized in all eyes (100%). Scleral buckling was performed in 3 fellow eyes (6.0%) for a late-onset tractional or rhegmatogenous retinal detachment, and retinal reattachment was achieved in all eyes (100%).

• **MOST CASES OF CONGENITAL RETINAL FOLD SUGGEST FAMILIAL INHERITANCE:** Family members were examined in 50 cases (41.3%), and a positive family history was identified in 32 cases (64.0%), with ophthalmoscopic findings of retinal vascular abnormalities in the periphery (81.2%), retinal folds (9.4%), dragged retina (6.3%), and leukokoria (3.1%). A negative family history was suspected by ocular examination of the parents in 18 cases (36.0%). In all cases with a positive family history, the trait originated in 1 of the family lines. In positive cases, the fold was bilateral in 12 cases (37.5%) and unilateral with abnormal retinal vascular changes in the fellow eye in the other 20 cases (62.5%). In negative cases,

progresses with the retinal hemorrhage in the right eye. Laser photocoagulation was applied to the peripheral avascular retina. (Middle) Two months later, a tractional retinal detachment has progressed rapidly. Vitrectomy with lensectomy was performed. (Bottom) Multiple retinal breaks in the periphery at the edge of the retinal fold have induced a rhegmatogenous retinal detachment in the left eye. Vitrectomy with lensectomy and scleral buckling were performed.

the fold was bilateral in 5 cases (27.8%), unilateral with abnormal retinal vascular change in the fellow eye in 9 cases (50.0%), and unilateral with normal fellow eye in 4 cases (22.2%).

• **SECONDARY COMPLICATIONS OF CONGENITAL RETINAL FOLD ARE COMMON AND VISUALLY DEVASTATING:** During the follow-up periods, secondary ocular complications developed in the fundus in 44 of 147 eyes (29.9%) with congenital retinal folds; progression of a tractional retinal detachment in 19 eyes (12.9%), rhegmatogenous retinal detachment in 12 eyes (8.2%), fibrovascular proliferation from the neovascularization in 11 eyes (7.5%), and exudative retinal detachment in 2 eyes (1.4%). The secondary complications in the fundus of 44 eyes are summarized in the Table.

Among the 26 patients with "true" unilateral congenital fold, secondary ocular complications also developed in the fundus in 6 eyes (23.1%); progression of a tractional retinal detachment in 2 eyes (7.7%), rhegmatogenous retinal detachment in 1 eye (3.8%), fibrovascular proliferation from the neovascularization in 2 eyes (7.7%), and exudative retinal detachment in 2 eyes (3.8%).

• **TRACTIONAL RETINAL DETACHMENTS:** Progression of tractional retinal detachment occurred in patients ranging in age from 1 to 88 months (mean,  $25.8 \pm 27.2$  months). Among the 19 eyes the tractional retinal detachment originated from excessive fibrovascular proliferation and contraction in 15 eyes (79%) (Figure 3, Top and Middle) and regrowth of fibrovascular tissue in 4 eyes (21%). Ten eyes (53%) were treated: vitrectomy with lensectomy was performed in 6 eyes (32%) and scleral buckling with laser photocoagulation in 4 eyes (21%). Retinal reattachment was achieved in 7 of 10 treated eyes (70%).

• **RHEGMATOGENOUS RETINAL DETACHMENTS:** A rhegmatogenous retinal detachment developed in patients ranging in age from 33 to 195 months (mean,  $87.0 \pm 56.5$  months). Among the 12 eyes, ocular trauma including the digito-ocular sign was involved in 5 eyes (42%). Multiple or expanded retinal breaks were seen in the periphery within the stretched and fragile retina at the edge of the retinal folds in 8 eyes (67%) (Figure 3, Bottom), dialysis developed in 1 eye (8.3%), and no breaks were seen in 3 eyes. Nine eyes (75%) with a rhegmatogenous retinal detachment had a total retinal detachment with proliferative vitreoretinopathy (PVR). Treatment was performed in 11 eyes (92%): vitrectomy with lensectomy in 5 eyes (42%), vitrectomy with lensectomy and scleral buckling in 4 eyes (33%), and scleral buckling in 2 eyes (17%); however, retinal reattachment occurred in 3 of 11 treated eyes (27%).

• **FIBROVASCULAR PROLIFERATION:** Fibrovascular proliferation progressed in patients ranging in age from 2 to 121 months (mean,  $19.4 \pm 35.8$  months), within the first year in 9 of 11 eyes (82%). Growth of neovascularization was identified in 11 eyes (100%). Treatment was performed in 10 eyes (91%): vitrectomy with lensectomy in 5 eyes (46%), laser photocoagulation applied to the peripheral avascular retina in 4 eyes (36%), and scleral buckling with laser photocoagulation in 1 eye (9%); treatment stabilized the neovascularization and prevented a retinal detachment in 8 of 10 treated eyes (80%).

• **ANTERIOR SEGMENT COMPLICATIONS:** Secondary complications in the anterior segments developed in 16 of 147 eyes (10.9%) with congenital retinal folds; glaucoma in 9 eyes (6.1%), cataract in 8 eyes (5.4%), and band keratopathy and keratoconus in 1 eye (0.7%) each. Two glaucoma eyes developed cataracts and 1 cataract eye developed glaucoma after cataract surgery. Glaucoma developed in patients ranging in age from 2 to 137 months (mean,  $60.1 \pm 46.8$  months). The main cause was fibrovascular proliferation and contraction that resulted in anterior lens displacement and angle-closure glaucoma. Neovascular glaucoma was identified in 1 eye. Treatment was performed in 6 eyes (67%): medical treatment in 4 eyes and lensectomy and peripheral iridectomy in 1 eye each. Cataract developed in patients ranging in age from 11 to 113 months (mean,  $59.1 \pm 40.2$  months). Lensectomy was performed in 4 eyes (50%).

Among the 26 patients with "true" unilateral congenital fold, secondary complications in the anterior segments developed in 4 eyes (15.4%): glaucoma in 1 eye (3.8%) and cataract in 3 eyes (11.5%).

• **VISUAL OUTCOMES WERE GENERALLY POOR:** The VA could be measured in 119 eyes. Of these, the final BCVA ranged from 20/100 to 20/20 in 5 eyes (4.2%) with macular formation, 2/100 to 20/200 in 45 eyes (37.8%), 2/200 to light perception in 46 eyes (38.7%), and no light perception in 23 eyes (19.3%). Among the total of 147 eyes, an ocular prosthesis was used in 8 eyes (5.4%) with phthisis bulbi or microphthalmos to facilitate orbital growth.

---

## DISCUSSION

IN THE CURRENT SERIES, THE RETINAL VESSELS WITHIN THE folds were bundled and pulled toward the temporal periphery in most cases. The retinal vessels may appear not to enter the fold but to have developed before the retina became folded. The folds mostly were composed of stretched retina rather than vitreous membranes, described by Michaelson<sup>4</sup> and by Pruett and Schepens,<sup>5</sup> extending from the disc toward the peripheral fundus. Pruett and Schepens reported that the meridional distribution of

vitreous bands and retinal folds was commonly on the nasal side,<sup>5</sup> but in the current study, the folds extended temporally in 92.5% (136/147) eyes, although in the "true" unilateral congenital fold group of 26 patients (26 eyes), the folds extended nasally, superiorly, or inferiorly in higher rate of 34.6% (9/26) eyes compared to 7.5% (11/147) eyes.

The affected eye also had a peripheral avascular zone and retinal vascular abnormalities including neovascularization, hemorrhage, and exudates that indicated active retinopathy. The retinal folds were unilateral in 78.5% of eyes; however, 71.5% of patients with a unilateral fold had abnormal retinal vascular changes, a dragged retina, or total retinal detachment and leukokoria in the fellow eye. Insufficient retinal vascular development and abnormal vascular changes were seen frequently in the temporal periphery of the fellow eyes (34.7%). Since the growth of retinal vessels is more likely to be delayed temporally than nasally, these features seemed to indicate that most retinal folds in the current series may have resulted from bilateral incomplete and abnormal vascular retinal development, similar to that of ROP. Most congenital retinal folds may be caused by insufficient retinal vascular development, as in FEVR, rather than by PFV. It is interesting that features in each eye of the same patient are often quite different in this series. It is distinctly unusual in ROP for patients to develop severe retinopathy in 1 eye but not develop a similar degree of pathology in the other eye. Insufficiency of vascular development of this series may originate from gene mutations that related to morphogenesis of the retinal vessels. The molecular mechanism needs further elucidation.

The family history was positive in 64.0% of cases in which family members were examined. All positive cases had bilateral manifestations of incomplete and abnormal vascular development that confirmed the diagnosis of FEVR. Most positive cases were transmitted by autosomal dominant inheritance, while none was transmitted by autosomal recessive or X-linked recessive inheritance. Sporadic cases may exist within 77.8% of negative cases with bilateral manifestations. Gene studies to detect mutations in *FZD4*, *LRP5*, and *NDP* are under way to clarify the genetic characteristics of Japanese patients.

Regarding secondary fundus complications, a high rate of fibrovascular proliferation and rapid progression of tractional retinal detachments indicate the characteristics of active FEVR. Van Nouhuys<sup>9</sup> and Nishimura and associates<sup>10</sup> reported similar features of retinal folds. Various retinal involvements in FEVR have been studied and reported since 1982 in Japan.<sup>10-12</sup> There may be differences among races, but FEVR is supposed to be a rather common origin of congenital retinal folds without systemic associations.

The "true" unilateral congenital fold, the small group of patients that most closely resemble "congenital retinal folds" as previously described, seems to have different

pathology. PFV may play a role in the pathogenesis of congenital retinal folds in unilateral cases, especially those associated with coloboma in the affected or fellow eye,<sup>14</sup> in which a tent-shaped retinal detachment (fold) extends inferiorly along with the fetal fissure. In those cases, the tractional fetal tissue pulled on the retina and caused a tent-like configuration.<sup>7</sup> The term anterior-peripheral PFV and not posterior PHPV should be used for the origin of congenital retinal folds pulled by the fetal fibrous tissue in the periphery. However, it is rare that PFV results in peripheral fibrous proliferation, because PFV usually proliferates along the hyaloid artery.

Few reports have been published on the long-term prognosis of retinal folds. Van Nouhuys reported that 3 different factors play an etiologic role in the pathogenesis of retinal detachments in eyes with FEVR: traction from vitreous membranes, atrophy of the peripheral retina, and subretinal exudation.<sup>15</sup> In that study, the most frequent late complication was a retinal detachment, which developed in 20% of 180 eyes with FEVR, and traction was the most important cause of the retinal detachment. Recently, surgery, including peripheral laser ablation and vitrectomy, has been advocated in FEVR including retinal folds. Previous reports of vitrectomy to treat FEVR mainly involved cases of tractional retinal detachment.<sup>16,17</sup>

In the current study, nearly 30% of affected eyes with congenital retinal folds developed secondary fundus complications including fibrovascular proliferation, tractional retinal detachment, rhegmatogenous retinal detachment, and exudative retinal detachment. Even in the group of patients with "true" unilateral congenital fold, secondary fundus complications developed in 23.1%. The complication rate with the "true" unilateral fold seems to be also high in fundus and rather higher in the anterior segments.

Fibrovascular proliferation developed from neovascularization of active retinopathy in 7.5% of eyes, mostly within the first year of life. Tractional retinal detachments developed from excessive fibrovascular proliferation and regrowth in 12.9% in infants and younger children under 4 years of age. However, it is noteworthy that fibrovascular proliferation and tractional retinal detachments may develop from regrowth in older children aged 7 to 10 years. Meanwhile, rhegmatogenous retinal detachments and exudative retinal detachments developed in 8.2% and 1.4%, respectively, in older children from 2 to 16 years old. Ocular trauma was highly involved in the development of rhegmatogenous retinal detachments. Retinal breaks mostly occurred in the periphery within the stretched retinal folds, resulting in intractable PVR. Laser photocoagulation, scleral buckling, and vitrectomy with lensectomy were performed in the affected eyes with useful vision; however, the success rates for eyes complicated with fibrovascular proliferation, a tractional retinal detachment, and a rhegmatogenous retinal detachment were 80%, 70%, and 27%, respectively.

These results indicated that very early diagnosis within the first months of life, frequent examinations at a young age, and early intervention with laser and vitreoretinal surgery are essential to prevent serious complications and preserve useful vision. Fundus FA is recommended in cases suspected to arise from neovascularization of active retinopathy. The current findings also confirmed the need for a thorough ophthalmoscopic examination of the fellow eye in patients with unilateral retinal folds and for examinations of siblings at an early age. Early detection of a retinal detachment was extremely hard in eyes with a unilateral fold or in worse eyes with bilateral folds. We also recommend that older children undergo follow-up every 3 months, avoid sports associated with a high risk of ocular trauma, and wear protective glasses. Secondary complications in the anterior segment also developed in nearly 11% with congenital retinal folds in the current series. Glaucoma

and cataract developed in 6.1% and 5.4%, respectively, in patients around 5 years of age; however, those diseases may develop in infants to older children older than 9 years of age. Longer follow-up may increase the morbidity of the anterior and posterior complications. Thus, life-long observation is needed to preserve vision in eyes with a retinal fold.

The final BCVAs were 20/100 to 20/20 in 5 eyes (4.2%), 2/100 to 20/200 in 45 eyes (37.8%), and 2/200 or worse in 69 eyes (58.0%), because the temporal retina including the macula was folded in most eyes. In 5 eyes with VA of 20/100 or better, the folds were pulled nasally, superiorly, or inferiorly to the periphery and the normal macular morphology was preserved. It is suggested that even in eyes with congenital retinal folds, if the macula is rotated, appropriate treatment for amblyopia should be performed to facilitate development of good vision and binocular function.<sup>18</sup>

PUBLICATION OF THIS ARTICLE WAS SUPPORTED BY HEALTH AND LABOUR SCIENCES RESEARCH GRANTS OF RESEARCH ON intractable diseases from the Ministry of Health, Labour and Welfare, Tokyo, Japan. Funding sources had no role in the design or conduct of this study. Involved in design and conduct of the study (S.N., N.A.); collection, management, analysis, and interpretation of the data (S.N., Y.S., T.Y., Y.K., E.N., N.A.); and preparation, review, and approval of the manuscript (S.N., Y.S., T.Y., Y.K., E.N., N.A.). This study was approved by the institutional ethics committee of the National Center for Child Health and Development; the parents of the patients provided informed consent before the infants were enrolled.

## REFERENCES

- Mann I. Congenital retinal fold. *Br J Ophthalmol* 1935; 19(12):641–658.
- Weve H. Ablatio falciformis congenita (retinal fold). *Br J Ophthalmol* 1938;22(8):456–470.
- Reese AB. Persistent hyperplastic primary vitreous. *Am J Ophthalmol* 1955;40(3):317–331.
- Michaelson IC. Intertissue vascular relationship in the fundus of the eye. *Invest Ophthalmol* 1965;4(6):1004–1015.
- Pruett RC, Schepens CL. Posterior hyperplastic primary vitreous. *Am J Ophthalmol* 1970;69(4):535–543.
- Goldberg MF. Persistent fetal vasculature (PFV): an integrated interpretation of signs and symptoms associated with persistent hyperplastic primary vitreous (PHPV). *Am J Ophthalmol* 1997;124(5):587–626.
- Pruett RC. The pleomorphism and complications of posterior hyperplastic primary vitreous. *Am J Ophthalmol* 1975; 80(4):625–629.
- Criswick VG, Schepens CL. Familial exudative vitreoretinopathy. *Am J Ophthalmol* 1969;68(4):578–594.
- Van Nouhuys CE. Congenital retinal fold as a sign of dominant exudative vitreoretinopathy. *Albrecht von Graefes Arch Klin Ophthalmol* 1981;217(1):55–67.
- Nishimura M, Yamana T, Sugino M, et al. Falciform retinal fold as sign of familial exudative vitreoretinopathy. *Jpn J Ophthalmol* 1983;27(1):40–53.
- Miyakubo H, Inohara N, Hashimoto K. Retinal involvement in familial exudative vitreoretinopathy. *Ophthalmologica* 1982;185(3):125–135.
- Miyakubo H, Hashimoto K, Miyakubo S. Retinal vascular pattern in familial exudative vitreoretinopathy. *Ophthalmology* 1984;91(12):1524–1530.
- Pendergast SD, Trese MT. Familial exudative vitreoretinopathy. Result of surgical management. *Ophthalmology* 1998(6); 105:1015–1023.
- Suzuki Y, Kawase E, Nishina S, Azuma N. Two patients with different features of congenital optic disc anomalies in the two eyes. *Graefes Arch Clin Exp Ophthalmol* 2006;244(2): 259–261.
- Van Nouhuys CE. Juvenile retinal detachment as a complication of familial exudative vitreoretinopathy. *Fortschr Ophthalmol* 1989;86(3):221–223.
- Glazer LC, Maguire A, Blumenkranz MS, et al. Improved surgical treatment of familial exudative vitreoretinopathy in children. *Am J Ophthalmol* 1995;120(4):471–479.
- Shubert A, Tasman W. Familial exudative vitreoretinopathy: surgical intervention and visual acuity outcome. *Graefes Arch Clin Exp Ophthalmol* 1997;235(8):490–493.
- Suzuki Y, Nishina S, Hiraoka M, et al. Congenital rotated macula with good vision and binocular function. *Jpn J Ophthalmol* 2009;53(5):452–454.



