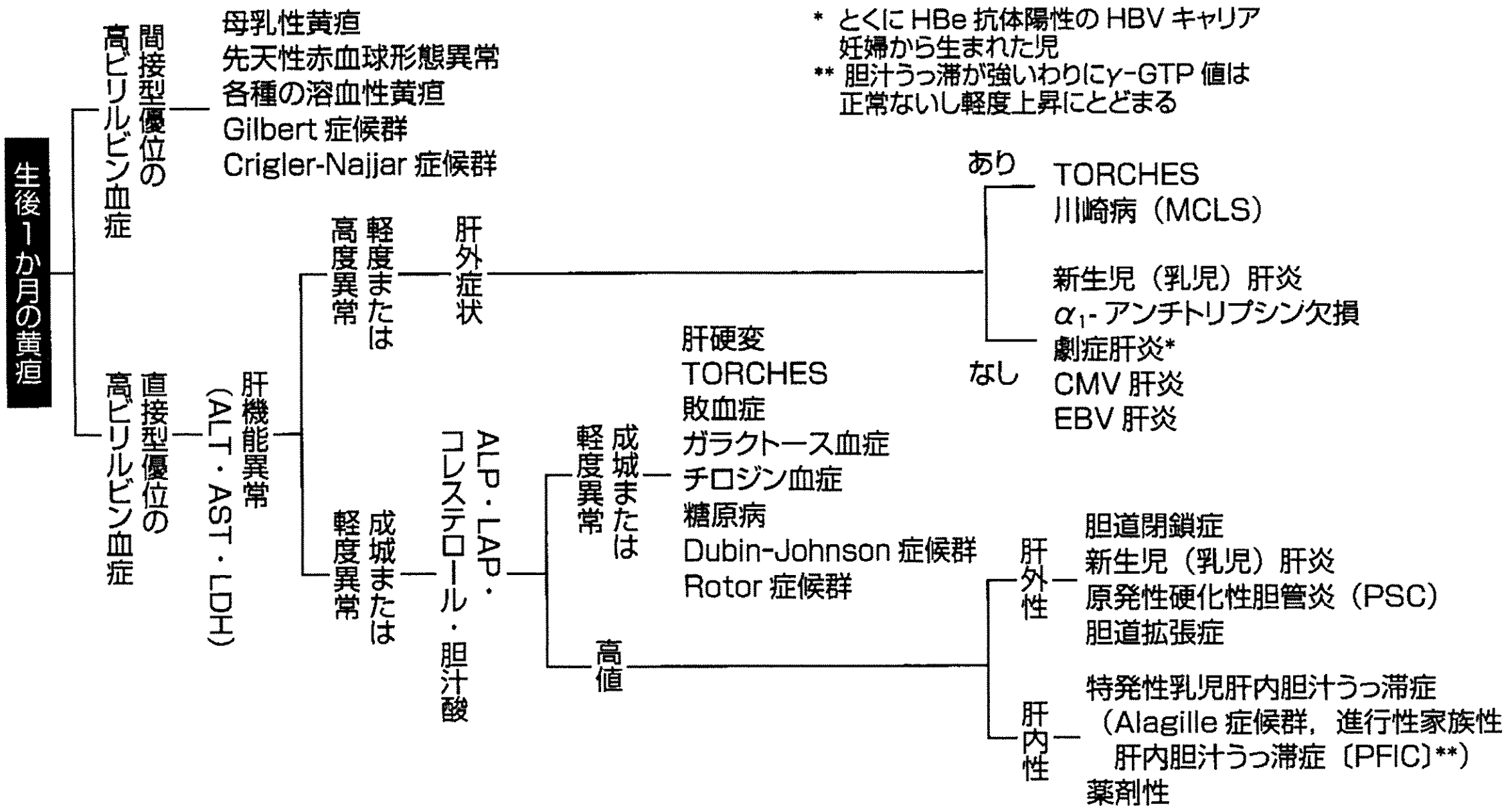
* とくにHBe抗体陽性のHBVキャリア妊婦から生まれた児
** 胆汁うっ滞が強いわりにγ-GTP値は正常ないし軽度上昇にとどまる
生後1か月の黄疸
間接型優位の高ビリルビン血症
母乳性黄疸
先天性赤血球形態異常
各種の溶血性黄疸
Gilbert症候群
Crigler-Najjar症候群
直接型優位の高ビリルビン血症
肝機能異常（ALT・AST・LDH）
軽度または高度異常
肝外症状
あり
TORCHES
川崎病（MCLS）
なし
新生児（乳児）肝炎
α1-アンチトリプシン欠損
劇症肝炎*
CMV肝炎
EBV肝炎
成城または軽度異常
ALP・LAP・コレステロール・胆汁酸
成城または軽度異常
肝硬変
TORCHES
敗血症
ガラクトース血症
チロジン血症
糖原病
Dubin-Johnson症候群
Rotor症候群
高値
肝外性
胆道閉鎖症
新生児（乳児）肝炎
原発性硬化性胆管炎（PSC）
胆道拡張症
肝内性
特発性乳児肝内胆汁うっ滞症
（Alagille症候群，進行性家族性肝内胆汁うっ滞症〔PFIC〕**）
薬剤性

図2　1か月健診でみられる黄疸の鑑別手順

が，体質性黄疸との鑑別が困難な場合は母乳の数日間にわたる断乳により黄疸は速やかに改善する。ただし先に述べたように，安易な断乳は行うべきではない。

- 母乳性黄疸であれば生後2～3か月ころには母乳を継続していても改善するはずである。

## Ⅳ. 直接型ビリルビン値が上昇する黄疸

### 1. 胆道閉鎖症

- 最も重要な鑑別疾患は胆道閉鎖症である。
- 胆道閉鎖症では生後1か月ころから胆汁うっ滞が目立つようになり，濃黄色尿と灰白色便～クリーム色便がみられる。早期発見のために1か月健診の果たす役割は大きい。
- マススクリーニングとして便色のカラー見本を母子手帳に添付して，色調から灰白色便を心配したら専門医に連絡するシステムが試みられている。
- 胆道閉鎖症の特異的な診断法はないが，直接型ビリルビン値の上昇，軽度の肝機能異常，腹部超音波検査で胆囊の萎縮，肝門部の高エコー輝度，十二指腸ゾンデ（チューブ）による無胆汁の証明，胆道シンチグラムによる腸管への排泄途絶，肝生検による病理所見などで診断する。
- 診断ができない場合は試験開腹し，術中胆道造影を行い確定診断できればただちに手術（肝門部空腸吻合術）をする。

### 2. 肝内胆汁うっ滞症

- 新生児肝炎，肝内胆管低形成，家族性進行性肝内胆汁うっ滞などがある。
- 新生児肝炎と類似の症状を呈し，肝組織では巨細胞性肝炎，脂肪変性，鉄沈着がみられ，シトルリン血症を含む多種高アミノ酸血症を呈するシトリン欠損による新生児肝内胆汁うっ滞（略してNICCD）が注目されている。

### 文献

1) 藤澤知雄：黄疸．佐地　勉，他（編著）：ナースの小児科学，改訂5版，中外医学社，東京，pp153-155，2011
2) 岩瀬孝志，伊藤　進：母乳性黄疸．別冊日本臨牀新領域別症候群シリーズNo. 13，肝・胆道系症候群，第2版，578-581，2010
3) Maruo Y, et al：Prolonged unconugated hyperbilirubinemia in breast milk and mutations of the bilirubin uridine diphosphate-glucuronosyltransferase gene. Pediatrics **106**：E59, 2000

Mod Rheumatol (2011) 21:641–645
DOI 10.1007/s10165-011-0442-7

CASE REPORT

# Patient with neonatal-onset chronic hepatitis presenting with mevalonate kinase deficiency with a novel MVK gene mutation

**Masahiro Tahara · Hidemasa Sakai · Ryuta Nishikomori · Takahiro Yasumi · Toshio Heike · Ikuo Nagata · Ayano Inui · Tomoo Fujisawa · Yosuke Shigematsu · Koji Nishijima · Katsuji Kuwakado · Shinichi Watabe · Junji Kameyama**

Received: 24 November 2010 / Accepted: 22 February 2011 / Published online: 12 March 2011
© Japan College of Rheumatology 2011

**Abstract** A Japanese girl with neonatal-onset chronic hepatitis and systemic inflammation was diagnosed with hyper-immunoglobulinemia D and periodic fever syndrome (HIDS). However, she lacked the typical HIDS features until the age of 32 months. She had compound heterozygous MVK mutations, H380R and A262P, the latter of which was novel. These findings suggest that HIDS patients could lack typical episodes of recurrent fever at the onset and that HIDS should be considered as a possible cause of neonatal-onset chronic hepatitis.

**Keywords** Autoimmune hepatitis · Hyper-IgD syndrome · Liver biopsy · MVK gene · Neonatal-onset chronic hepatitis

**Abbreviations**

| | |
|---|---|
| HIDS | Hyper-immunoglobulinemia D and periodic fever syndrome |
| IgD | Immunoglobulin D |
| MVK | Mevalonate kinase |
| FMF | Familial Mediterranean fever |
| MEFV | Familial Mediterranean fever gene |
| AIH | Autoimmune hepatitis |
| CRP | C-reactive protein |

## Introduction

Mevalonate kinase deficiency is an autosomal recessive metabolic disorder caused by mevalonate kinase (MVK) gene mutations. The disorder presents as a phenotypic spectrum in which mevalonic aciduria is the more severe form, with neurological complications, and hyperimmunoglobulinemia D and periodic fever syndrome (HIDS) is the milder form. HIDS is characterized by recurrent febrile attacks, with lymphadenopathy, abdominal symptoms, skin eruptions, and joint involvement [1]. In this report, we describe a patient with a severe form of HIDS caused by a novel MVK mutation; the patient had presented with neonatal-onset chronic hepatitis that was temporarily diagnosed as autoimmune hepatitis (AIH). The lack of typical recurrent fever and rashes at the onset of the disease delayed the diagnosis of HIDS, which alerted the clinicians that HIDS could exist in patients with continuous inflammatory episodes even with atypical clinical courses.

---

M. Tahara · K. Nishijima · K. Kuwakado · S. Watabe · J. Kameyama
Department of Pediatrics, Kurashiki Central Hospital,
Kurashiki, Japan

M. Tahara (✉)
Department of Pediatrics, Tsuchiya General Hospital,
3-30 Nakashima, Naka-ku, Hiroshima 730-8655, Japan
e-mail: mttahara@qg7.so-net.ne.jp

H. Sakai · R. Nishikomori · T. Yasumi · T. Heike
Department of Pediatrics,
Kyoto University Graduate School of Medicine,
Kyoto, Japan

I. Nagata
Division of Pediatrics and Perinatology, Faculty of Medicine,
Tottori University, Yonago, Japan

A. Inui · T. Fujisawa
Department of Pediatrics, Yokohama City Tobu Hospital,
Yokohama, Japan

Y. Shigematsu
Department of Health Science, Faculty of Medicine Sciences,
University of Fukui, Fukui, Japan

## Case report

A Japanese girl was born at 36 weeks' gestation with a weight of 2,240 g. Her parents were non-consanguineous and the family history was unremarkable. At birth she had no symptoms, but physical examination revealed hepatomegaly (1.5 cm below the right costal margin) without splenomegaly. No jaundice, ascites, or coagulation abnormalities were present. Laboratory examinations showed increased white blood cell count (45,700/mm$^3$) and serum C-reactive protein (CRP) (15.8 mg/dl), as well as increased transaminase levels (aspartate aminotransferase [AST] 207 IU/l, alanine aminotransferase [ALT] 96 IU/l), lactate dehydrogenase (LDH) (6,575 IU/l), and biliary enzyme levels ($\gamma$-guanosine triphosphate [GTP] 61 IU/l). An increased immunoglobulin M level (53.0 mg/dl) caused us to work on congenital infections, with bacterial cultures of blood, cerebrospinal fluid (CSF), and gastric fluid, and determination of serum $\beta$ D-glucan, and measurements of serum antibodies against cytomegalovirus, toxoplasmosis, syphilis, rubella, herpes simplex type I and type II, listeriosis, Epstein-Barr virus, adenovirus, hepatitis A and B and C viruses, *Chlamydia trachomatis*, and mycoplasma, all of which were negative. Radiographic work-up with computed tomography (CT), magnetic resonance imaging (MRI), and gallium scintigraphy, as well as bone-marrow aspirate examination, did not reveal any congenital neoplasm. A search for metabolic disorders by measurements of blood amino acids and urinary organic acids was negative.

Without any specific treatments, the hepatomegaly gradually increased, although abdominal MRI revealed diffuse inflammation of the liver. To explore further the cause of the hepatomegaly, a needle liver biopsy was performed at the age of 6 months. The biopsied liver specimen showed the presence of mild lymphocytic infiltration and fibrosing lesions in the portal area, and short septa extending from a slightly enlarged portal tract (Fig. 1a, b), which indicated a diagnosis of chronic hepatitis without specific causes.

At the age of 14 months, splenomegaly appeared, and elevated serum IgG (2,299 mg/dl) as well as anti-smooth muscle antibodies (1:160) were detected, which led us to diagnose the patient as having AIH [2]. The patient received methylprednisolone pulse therapy, followed by prednisolone and azathioprine for the presumed AIH [3]. Serum transaminase levels normalized in response to the treatment, although cervical lymphadenopathy, hepatosplenomegaly, and elevated serum CRP persisted.

The continuous elevation of CRP prompted us to consider autoinflammatory diseases; thus, we performed genetic analysis for familial Mediterranean fever (FMF), tumor necrosis factor (TNF) receptor-associated periodic syndrome, and cryopyrin-associated periodic syndrome, at the age of 26 months. After obtaining written informed consent from the parents and approval from the Institutional Review Board of Kyoto University, peripheral blood samples were collected from the patient and her parents for genetic analysis. The analysis was done by sequencing all the exons, including exon–intron junctions, which showed heterozygous L110P and E148Q missense mutations on the familial Mediterranean fever (MEFV) gene (Fig. 2a) without any mutations of the TNFRSF1A and NLRP3

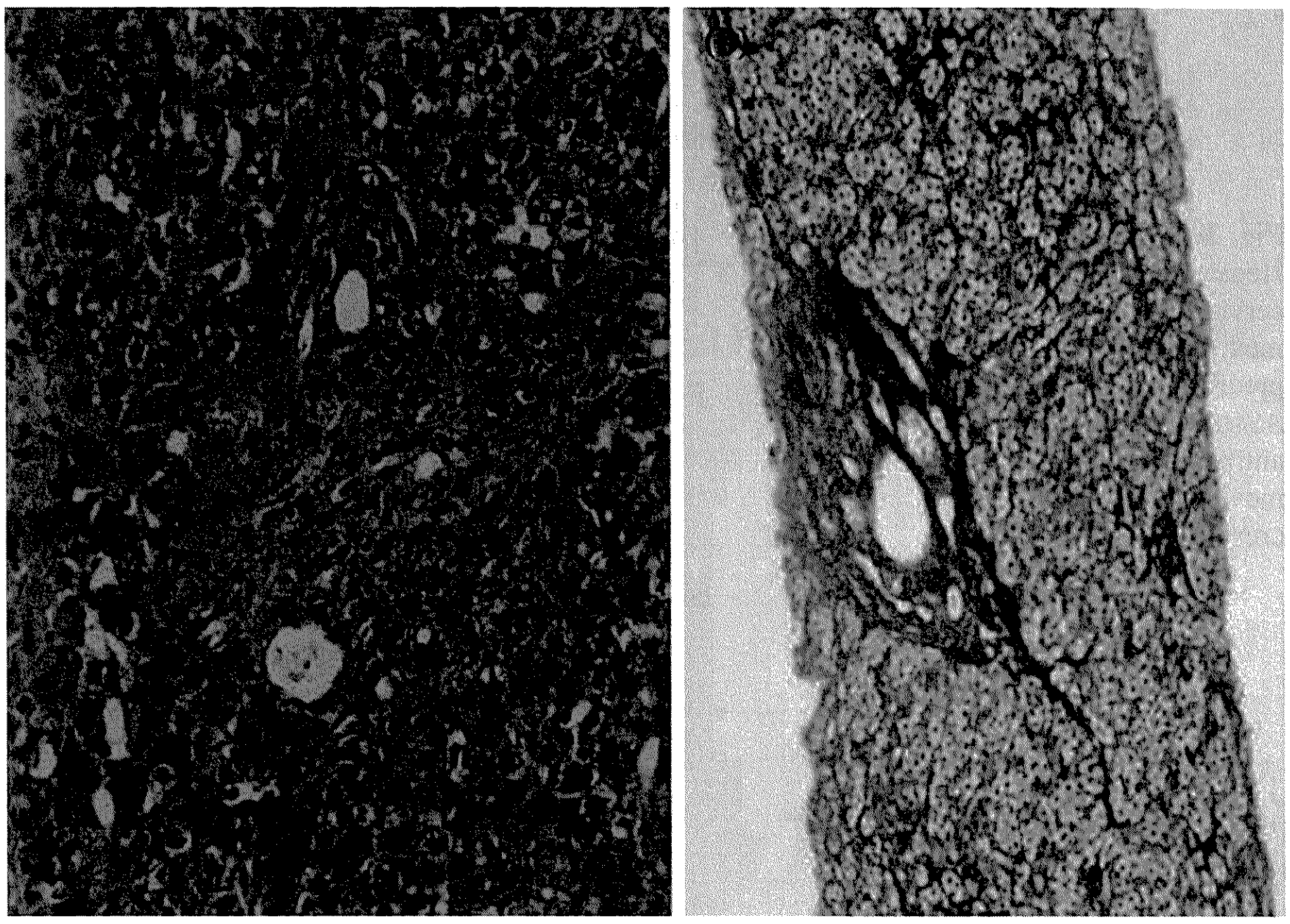

**Fig. 1** Liver biopsy specimen showing chronic hepatitis. **a** The portal tract is infiltrated with lymphocytes (H&E, ×200). **b** Short septa extend from the slightly enlarged portal tract (reticulum, ×100)

genes. The L110P and E148Q mutations on MEFV were considered to be single-nucleotide polymorphisms (SNPs), based upon the prevalence of the mutations, as well as their weak association with FMF in Japan. Because none of periodic fever, rashes, gastrointestinal symptoms, or elevated serum IgD was observed at that time, the MVK gene was not examined.

The patient continued to show a good response to the AIH treatments, although tapering off the prednisone induced periodic fever with maculopapular rashes approximately once a month, shown for the first time at the age of 32 months. The fever episodes persisted for 3–5 days and the duration of the fever was reduced to 1–2 days by temporarily increasing the dose of prednisone. Serum CRP levels were around 20 mg/dl at the onset of fever, and 1–4 mg/dl in the asymptomatic period. The newly emerged clinical symptoms and the good response to the systemic steroid prompted us to consider HIDS. Full examination for HIDS showed: (1) elevated serum IgD (19.2 mg/dl) (control 0–9 mg/dl); (2) increased urinary mevalonic acid (49.1 μg/mg creatinine) (control 0.091 ± 0.028 μg/mg creatinine); and (3) a significant decrease in the mevalonate kinase activity of peripheral blood mononuclear cells (PBMCs; below the detection limit). Genetic analysis of the MVK gene revealed compound heterozygous mutations, A262P and H380R, the former of which was a novel mutation (Fig. 2b). The MVK mutations were not identified in 100 healthy Japanese controls. Finally we diagnosed the patient with HIDS, at the age of 6 years. We treated the patient with simvastatin (0.07 mg/kg/day), which was partially effective in reducing the frequency of the periodic fever. Although no decline in urinary mevalonic acid has been produced by simvastatin (33.7–107.8 μg/mg creatinine), the patient has had a benign course, without mental retardation or neurological impairments (Fig. 3).

To see if the patient's liver abnormalities were due to either AIH or HIDS, we performed an immunohistological analysis of the biopsied liver specimen. It was stained for CD68, and unstained for CD3 and CD79 (Fig. 4). These

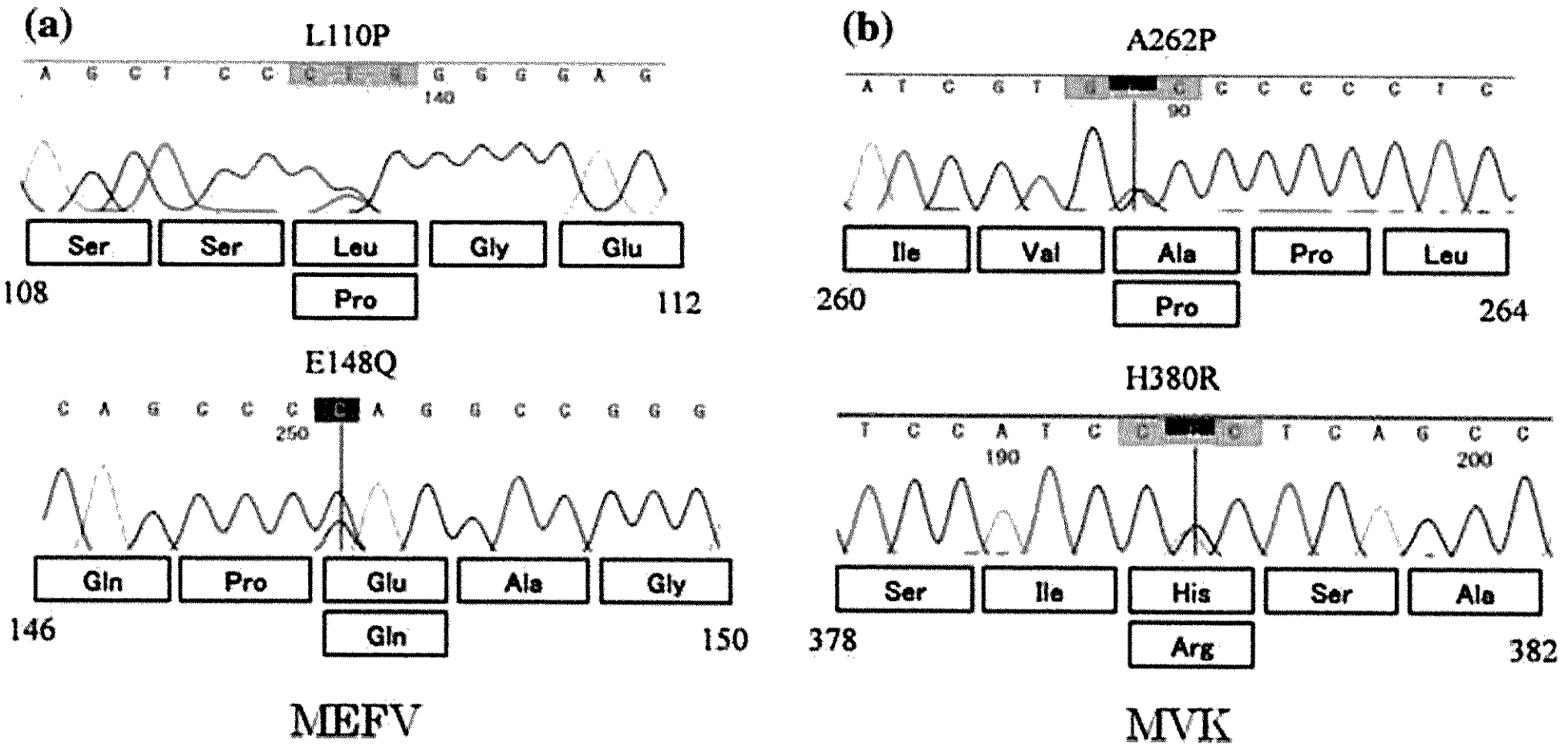

**Fig. 2** Genetic analysis. **a** Genetic analysis of the MEFV gene. The patient had heterozygous amino acid changes of L110P and E148Q. **b** Genetic analysis of the MVK gene. The patient had heterozygous mutations of A262P and H380R

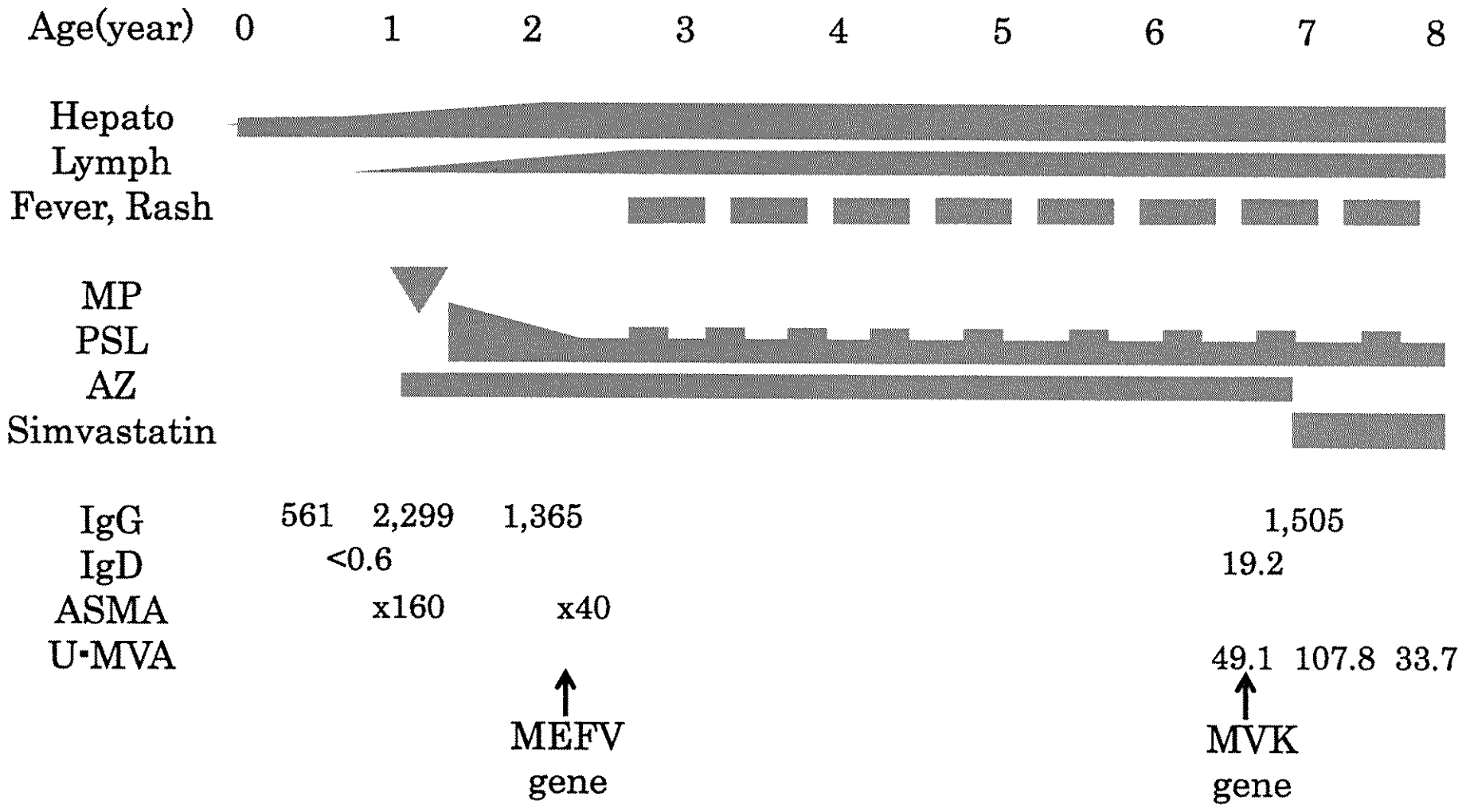

**Fig. 3** Clinical course. *Hepato* Hepatosplenomegaly, *Lymph* cervical lymphadenopathy, *MP* methylprednisolone, *PSL* prednisolone, *AZ* azathioprine, *ASMA* anti-smooth muscle antibody, *U-MVA* urinary mevalonic acid (μg/mg creatinine)



**Fig. 4** Immunohistochemical analysis of the biopsied liver tissues. **a** CD3 (×400), **b** CD68 (×400), **c** CD79 (×400)

data led us to conclude that the hepatitis seemed to be a manifestation of HIDS, rather than resulting from an autoimmune response.

## Discussion

We have reported here a Japanese girl who was diagnosed with HIDS by genetic analysis, as well as by laboratory examinations such as mevalonate kinase activity and urinary excretion of mevalonate. According to the report of the Japanese HIDS registry, the 4 most prevalent MVK mutations (V377I, I268T, H20P/N, and P167L) accounted for 71.5% of the mutations found. Our patient had a very rare genotype among the patients on the HIDS registry, as the H380R mutation was identified in 1.5% of the patients and A262P was a novel mutation. Because mevalonate kinase activity was below the detection limit, mevalonic aciduria could have been considered as the diagnosis in our patient. However, the mevalonic acid level in the urine was not as high as that reported for patients with mevalonic aciduria [4] and the clinical features of our patient lacked the neurological and developmental abnormalities that are distinctive signs of mevalonic aciduria. Thus, we concluded that the patient suffered from a severe form of HIDS, although we note that mevalonate kinase deficiency presents as a phenotypic continuum in which disease severity ranges from mevalonic aciduria to HIDS [5].

Serum transaminase levels in our patient were elevated since birth, which is relatively rare for HIDS, and liver biopsy showed chronic non-specific hepatitis [6]. Although the serum transaminase levels were improved by the treatment for AIH, the histological and immunohistochemical findings were not typical of AIH [6], which is a generally unresolving inflammation of the liver of unknown cause [7]. There have been some reports of HIDS patients with liver abnormalities. Topaloglu et al. [8] reported a similar case of HIDS in a patient who had neonatal hepatosplenomegaly without fever at the beginning, and they performed liver biopsy which showed portal fibrosis. Hinson et al. [9] reported two patients with mevalonate kinase deficiency who had neonatal hepatosplenomegaly and elevated transaminase levels; liver biopsy showed chronic active cholestatic hepatitis and portal fibrosis, respectively.

Neonatal hepatitis is a syndrome associated with a history that includes any type of infectious, genetic, toxic, or metabolic causation. Neonatal hepatitis is characterized by clinical and laboratory findings of liver dysfunction, particularly conjugated hyperbilirubinemia. In our patient, the clinical course in early childhood was not typical of neonatal hepatitis. But the clinical course in our patient suggests that it is important to include HIDS in the differential diagnosis of neonatal hepatitis or neonatal-onset chronic hepatitis.

Genetic analysis of autoinflammatory disease genes in our patient revealed 2 heterozygous amino acid changes, L110P and E148Q, in the MEFV gene, which were shared with the patient's asymptomatic mother. It has been reported that the allele frequency of E148Q in the Japanese population was high (16.38%), and both E148Q and L110P are considered as SNPs [10]. On the other hand, Touitou et al. [11] demonstrated that E148Q may have an exacerbating effect on FMF when it is part of complex alleles. In addition, there are other reports that mutations in 2 autoinflammatory genes cause more severe diseases [8, 12]. Thus, the heterozygous E148Q and L110P amino acid changes in the MEFV gene may cause a more severe form of HIDS.

The name ‘HIDS’ was given to the disorder because of the observed elevation in serum IgD, before the identification of the disease-causing mutations in the MVK gene. In a study of 103 HIDS patients, 22% had normal serum IgD, particularly during infancy [13], which indicates that serum IgD is not sensitive enough for diagnosing HIDS. In Asian countries like Japan, HIDS is so rare that clinicians do not know the clinical relevance of IgD in relation to the diagnosis of HIDS. Therefore, it is very important to let clinicians know that more specific and more sensitive diagnostic tests; namely, measurement of urinary mevalonic acid and/or genetic analysis of the MVK gene are necessary to diagnose HIDS. It should also be pointed out that both the measurements of urinary mevalonic acid and the genetic tests of the MVK gene require special laboratory equipment, which makes it difficult to access such diagnostic tests.

In conclusion, we have reported a patient with a severe form of HIDS who presented with neonatal-onset chronic hepatitis with a novel MVK mutation. HIDS should be included in the differential diagnosis of neonatal-onset chronic hepatitis, even if the serum IgD is within the normal range and typical recurrent fever is not identified.

**Acknowledgments** We are grateful to Dr. Hans R. Waterham for measurement of mevalonate kinase activity.

**Conflict of interest** The authors have no conflicts of interest to declare.

## References

1. Drenth JP, Denecker NE, Prieur AM, van der Meer JW. Hyperimmunoglobulin D syndrome. Presse Med. 1995;24:1211–3.
2. Alvarez F, Berg PA, Bianchi FB, Bianchi L, Burroughs AK, Cancado EL, et al. International Autoimmune Hepatitis Group report: review of criteria for diagnosis of autoimmune hepatitis. J Hepatol. 1999;31:929–38.
3. Sogo T, Fujisawa T, Inui A, Komatsu H, Etani Y, Tajiri H, et al. Intravenous methylprednisolone pulse therapy for children with autoimmune hepatitis. Hepatol Res. 2006;34:187–92.
4. Houten SM, Wanders RJA, Waterham HR. Biochemical and genetic aspects of mevalonate kinase and its deficiency. Biochim Biophys Acta. 2000;1529:19–32.
5. Simon A, Kremer HPH, Wevers RA, Scheffer H, de Jong JG, van der Meer JWM, et al. Mevalonate kinase deficiency: evidence for a phenotypic continuum. Neurology. 2004;62:994–7.
6. Kage M. Pathology of autoimmune liver diseases in children. Hepatol Res. 2007;37:S502–8.
7. Manns MP, Czaja AJ, Gorham JD, Krawitt EI, Mieli-Vergani G, Vergani D, et al. Diagnosis and management of autoimmune hepatitis. Hepatology. 2010;51:2193–213.
8. Topaloglu R, Ayaz NA, Waterham HR, Yuce A, Gumruk F, Sanal O. Hyperimmunoglobulinemia D and periodic fever syndrome; treatment with etanercept and follow-up. Clin Rheumatol. 2008;27:1317–20.
9. Hinson DD, Rogers ZR, Hoffmann GF, Schachtele M, Fingerhut R, Kohlschtter A, et al. Hematological abnormalities and cholestatic liver disease in two patients with mevalonate kinase deficiency. Am J Med Genet. 1998;78:408–12.
10. Komatsu M, Takahashi T, Uemura N, Takada G. Familial Mediterranean fever medicated with an herbal medicine in Japan. Pediatr Int. 2004;46:81–4.
11. Touitou I. The spectrum of familial Mediterranean fever (FMF) mutations. Eur J Hum Genet. 2001;9:473–83.
12. Stojanov S, Lohse P, Lohse P, Hoffmann F, Renner ED, Zellerer S, et al. Molecular analysis of the MVK and TNFRSF1A genes in patients with a clinical presentation typical of the hyperimmunoglobulinemia D with periodic fever syndrome: a low-penetrance TNFRSF1A variant in a heterozygous MVK carrier possibly influences the phenotype of hyperimmunoglobulinemia D with periodic fever syndrome or vice versa. Arthritis Rheum. 2004;50:1951–8.
13. Van der Hilst JC, Bodar EJ, Barron KS, Frenkel J, Drenth JP, van der Meer JW, International HIDS Study Group, et al. Long-term follow-up, clinical features, and quality of life in a series of 103 patients with hyperimmunoglobulinemia D syndrome. Medicine (Baltimore). 2008;87:301–10.

Journal of Paediatrics and
Child Health

doi:10.1111/j.1440-1754.2011.02213.x

INSTRUCTIVE CASE

# Acute liver failure in young children with systemic-onset juvenile idiopathic arthritis without macrophage activation syndrome: Report of two cases

Eitaro Hiejima,[1,2] Haruki Komatsu,[1] Yoshitake Takeda,[1] Tsuyoshi Sogo[1] Ayano Inui,[1] Ikuo Okafuji,[2,3]
Ryuta Nishikomori,[2] Tatsutoshi Nakahata[2] and Tomoo Fujisawa[1]

[1]Department of Pediatrics, Eastern Yokohama Hospital, Yokohama, and [2]Department of Pediatrics, Kyoto University, Kyoto and [3]Department of Pediatrics, Kobe City Medical Center General Hospital, Kobe, Japan

---

**Abstract:** Acute liver failure (ALF) with macrophage activation syndrome (MAS) is well known as a complication of systemic-onset juvenile idiopathic arthritis (S-JIA). However, liver failure without overt MAS is rare in S-JIA. We encountered two Japanese children with S-JIA in whom ALF developed during the remission of clinical manifestations. ALF without MAS was improved with plasma exchange and cyclosporine A combined with pulse methylprednisolone.

**Key words:** adult-onset Still's disease; cyclosporine A; plasma exchange; pulse methylprednisolone; systemic-onset juvenile idiopathic arthritis.

---

Liver dysfunction is an infrequent complication in systemic-onset juvenile idiopathic arthritis (S-JIA). However, it is known that among rheumatic disease patients, those with S-JIA are the most susceptible to macrophage activation syndrome (MAS),[1,2] which is among the secondary causes of hemophagocytic lymphohistiocytosis (HLH) in rheumatic diseases.[3] The excessive activation and proliferation of T-cells and well-differentiated macrophages lead to an overwhelming inflammatory reaction which can be fatal. We describe two Japanese children with S-JIA in whom acute liver failure (ALF) developed during the course of corticosteroid treatment. *Neither of them had hemophagocytosis demonstrated on bone marrow aspirates.* In addition, their clinical manifestations and laboratory findings did not fulfil the diagnostic criteria for HLH. Their diseases were diagnosed as ALF without MAS.

**Key Points**

1 Systemic-onset juvenile idiopathic arthritis is often followed by macrophage activation syndrome, which causes severe cytopenia, organ dysfunction and intravascular coagulopathy.
2 The diagnosis of macrophage activation syndrome is made based on the clinical features and laboratory findings.
3 Acute liver failure in patients with systemic juvenile idiopathic arthritis was caused by the localized activation of intrahepatic macrophage/Kupffer cells, which did not fulfill the criteria of macrophage activation syndrome.

---

**Correspondence:** Dr Haruki Komatsu, Department of Pediatrics, Eastern Yokohama Hospital, 3-6-1 Simosueyoshi Tsurumi, Yokohama, Kanagawa 230-0012, Japan. Fax: +88 45 576 3525; email: haruki-komatsu@chive.ocn.ne.jp

Conflict of interest: There are no financial/commercial conflicts of interests. All of the listed authors have participated actively in this study. All the authors concurred with the submission and will take the responsibility for the manuscript.

Accepted for publication 21 April 2011.

## Case 1

In 2003, a previously healthy 4-year-old girl presented with high fever, joint pain and a salmon-coloured rash. Her right elbow and both knees were painful and resisted full range of motion. On day 4 of illness, laboratory findings showed a white blood cell count and serum C-reactive protein (CRP) values were increased (Table 1). Liver enzyme values were within normal limits. Clinical symptoms were not improved by treatment with antibiotics. Bacterial infection, leukaemia, inflammatory bowel disease and other rheumatic diseases such as systemic lupus erythematosus were excluded by clinical symptoms and laboratory findings. Magnetic resonance imaging (MRI) of her right knee showed joint effusion. Arthritis and daily fever persisted for more than 6 weeks after October. Because her clinical manifestations fulfilled the criteria of S-JIA,[4] her disease was diagnosed as S-JIA. A 3-day course of intravenous pulse methylprednisolone (PM) (30 mg/kg/day) was started on day 43 of illness, followed by oral steroid therapy (prednisolone 2 mg/kg/day). After the treatment, her clinical symptoms improved, and serum CRP values became normal. On day 57 of illness, however, an elevation of serum liver enzyme values was found, and serum CRP values were slightly increased (Table 1). Although she no longer had fever or joint pain, a flare-up of S-JIA was suspected. She gradually became jaundiced but had no fever. On day 83 of illness, the laboratory findings were presented (as shown in Table 1). Viral markers

© 2011 The Authors
Journal of Paediatrics and Child Health © 2011 Paediatrics and Child Health Division (Royal Australasian College of Physicians)

**Table 1** Laboratory findings at onset and during clinical course

| Laboratory findings | Case 1 | | | Case 2 | | | |
|---|---|---|---|---|---|---|---|
| (normal values) | Day 4 | Day 57 | Day 83 | Day27 | Day 58 | Day 69 | Day 70 |
| WBC (3.5–8.5 × $10^3$/μL) | 14.5 | 18.0 | 13.5 | 19.5 | 10.3 | 8.3 | 16.4 |
| Hemoglobin (13.5–17.0 g/dL) | 11.7 | 12.1 | 14.0 | 11.7 | 11.5 | 12.8 | 13.6 |
| Platelet count (15–35 × $10^4$/μL) | 37.6 | 27.3 | 26.2 | 45.2 | 33.8 | 24.9 | 24.6 |
| Total bilirubin (0.2–1.2 mg/dL) | 0.4 | 0.4 | 13.7 | ND | 0.4 | 5.8 | 7.3 |
| AST (8–38 U/L) | 22 | 72 | 1 349 | 23 | 43 | 764 | 890 |
| ALT (4–44 U/L) | 23 | 169 | 1 814 | 10 | 46 | 1699 | 1565 |
| ALP (104–338 U/L) | ND | 323 | 535 | ND | 312 | 1980 | 1987 |
| γ-GTP (16–73 U/L) | ND | ND | 105 | ND | 60 | 451 | 490 |
| C-reactive protein (<0.5 mg/dL) | 6.7 | 2.9 | 0.5 | 9.0 | 1.6 | ND | ND |
| Prothrombin time (70–140%) | ND | ND | 51 | 83.6 | ND | ND | 59.9 |
| International normalized ratio (0.8–1.2) | ND | ND | 1.65 | 1.07 | ND | ND | 1.3 |
| Ferritin (21–282 μg/L) | ND | ND | 992 | 849 | 258 | 438 | 620 |
| Soluble IL-2 receptor (190–650 U/mL) | ND | ND | 10 100 | ND | ND | ND | 4803 |
| Triglyceride (<50 mg/dL) | ND | ND | 262 | ND | ND | ND | 280 |
| Fibrinogen (150–350 mg/dL) | ND | ND | 173 | ND | ND | ND | 100 |

ALP, alkaline phosphatase; ALT, alanine aminotransferase; AST, aspartate aminotransferase; ND, no data; WBC, white blood cell count.

**Table 2** Diagnostic guidelines for hemophagocytic lymphohistiocytosis in the two patients†

| | Case 1 | Case 2 |
|---|---|---|
| Fever | No | Yes |
| Splenomegaly | No | No |
| Cytopenias (affecting >2 of 3 lineages in the peripheral blood) | No | No |
| Hypertriglyceridemia and/or hypofibrinogenemia<br>Fasting triglycerides >265 mg/dL<br>Fibrinogen <150 mg/dL | No | Yes |
| Hemophagocytosis in bone marrow, spleen, or lymph nodes | No | No |
| Low or absent NK-cell activity | Not performed | Not performed |
| Ferritin ≥500 μg/L | Yes | Yes |
| Soluble CD25 (soluble IL-2 receptor) ≥2400 U/mL | Yes | Yes |

†Adopted from Henter *et al.*[3] NK, natural killer.

and screening tests for metabolic disease were all negative. Although she was suspected to be complicated with MAS, her bone marrow aspirate showed no evidence of hemophagocytosis. Additionally, her clinical signs and laboratory findings did not meet the criteria of HLH (Table 2). A percutaneous liver biopsy showed confluent necrosis with lobular inflammation, interface hepatitis and rosette formation. These findings were consistent with autoimmune hepatitis (AIH). According to the diagnostic scoring system of the International Autoimmune Hepatitis Group,[5] her disease was classified as 'probable AIH'. On day 86 of illness, she became somnolent as jaundice continued. Although coagulopathy deteriorated, she was afebrile. We thought that ALF was caused by subclinical MAS or AIH; hence, plasma exchange and PM administration (30 mg/kg/day for 3 days) were performed, followed by intravenous cyclosporine (1 mg/kg/day). Her clinical symptoms were dramatically improved and liver dysfunction resolved within a month.

## Case 2

A previously healthy 5-year-old boy was referred to our hospital with high fever persisting for 14 days, erythematous rash and joint pain in 2007. He had intermittent fever and complaints of joint pain in the 3 months prior. On day 27 of illness, leukocytosis, thrombocytosis and anaemia were found (Table 1). The joint pain in his hip and knee was so severe he could not walk. MRI of his right knee joint showed synovial hypertrophy and effusion. These findings were consistent with the early features of JIA. On the basis of clinical, laboratory and MRI findings, a diagnosis of S-JIA was made on day 31 of illness. Intravenous PM was started, followed by oral prednisolone (1 mg/kg/day). After this initial treatment, his high fever subsided and polyarthritis was improved. On day 58 of illness, the elevation of serum transaminase values was detected by routine blood examination (Table 1). However, he had no clinical signs or symptoms of S-JIA. On day 69 of illness, jaundice and diarrhoea appeared. Moreover, serum transaminase values were markedly increased (Table 1). Suddenly, on day 70 of illness, he began vomiting and became somnolent. His temperature was 38.3°C. Laboratory findings are shown in Table 1. Viral markers, autoantibodies and screening tests for metabolic disease were all negative. In addition, there was no evidence of hemophagocytosis in the bone marrow aspirate. Although natural killer activity was not measured, his clinical symptoms and laboratory findings did not fulfil the criteria of HLH (Table 2). A percutaneous liver biopsy showed severe

© 2011 The Authors
Journal of Paediatrics and Child Health © 2011 Paediatrics and Child Health Division (Royal Australasian College of Physicians)

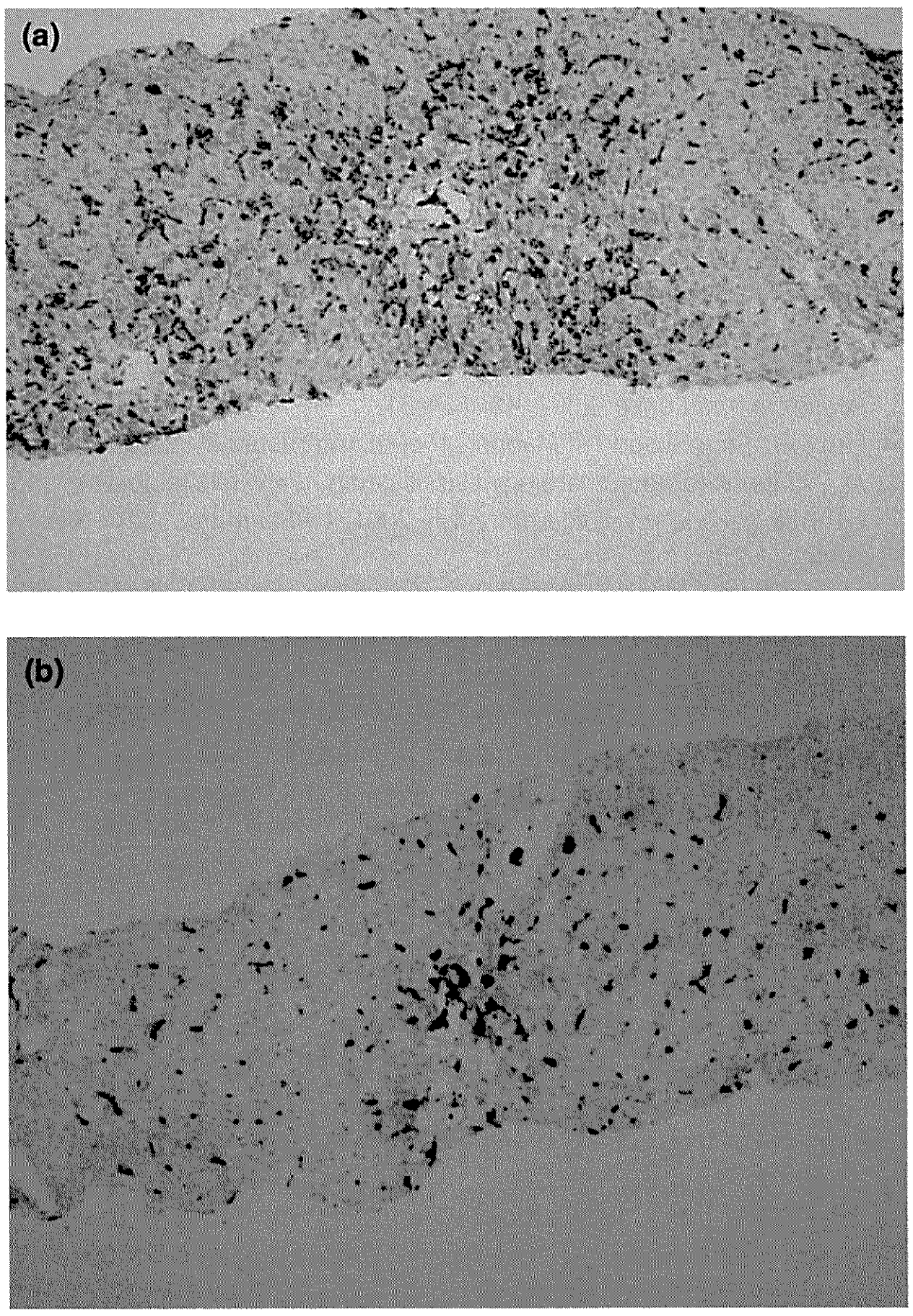

**Fig. 1** Immunochemical staining was performed with liver tissue using CD68. (a) This biopsy shows that intra-sinusoidal CD68-positive macrophages were numerous in the portal and peri-portal area before treatment. (b) Intra-sinusoidal CD68-positive macrophages were present but not markedly so in the convalescent phase.

degeneration of hepatocytes with slight necro-inflammatory changes. Numerous large and irregularly shaped CD68+ cells (macrophages/Kupffer cells) were seen in the lobular area (Fig. 1a). Therefore, he was diagnosed with ALF of unknown aetiology. Because the activated intrahepatic cells were presumed to be associated with ALF, plasma exchange, PM (30 mg/kg/day for 3 days) and intravenous administration of cyclosporine A were initiated. He made a good clinical recovery with full remission of the ALF. The number of CD68+ cells in the liver was decreased after these treatments (Fig. 1b). After cessation of cyclosporine A, he remained in full, clinical and laboratory remission.

## Discussion

Unless MAS occurs, liver abnormalities are uncommon in S-JIA. When the two children were diagnosed with S-JIA, the levels of serum liver enzymes were normal. They responded well to the initial therapy, and the manifestations of S-JIA such as high fever and joint pains were improved. However, ALF developed a few months after the onset of S-JIA. We strongly suspected that MAS was associated with ALF. Although bone marrow aspirates are not the gold standard for the diagnosis of MAS, bone marrow aspirates did not show the finding of hemophagocytosis. Additionally, their clinical features and their laboratory findings did not fulfil the criteria of HLH. These cases suggest that there is another mechanism of liver dysfunction, which are not associated with MAS, in S-JIA.

First, the liver was injured by the intrahepatic activated macrophages/Kupffer cells. MAS is caused by the excessive activation of well-differentiated macrophages, resulting in fever, hepatosplenomegaly, cytopenia, liver disease and neurological involvement. Usually, multiple organs are affected by systemic activated macrophages. In both cases, however, the activation of macrophages seemed to be localized in the liver. Therefore, these patients did not meet the criteria of MAS. Although it is difficult to clarify the mechanism of the localization of macrophage activation based on only two cases, we speculated that an infectious trigger was related to ALF without 'systemic' MAS. In case 2, diarrhoeagenic *Escherichia coli* O44 was isolated from stool culture, although stool culture was not performed in case 1. Blood supply of the liver depends on the portal venous system as well as the hepatic artery. Thus, the liver is well known as the first line of host defence and likely to be influenced by intestinal conditions via portal venous system.[6,7] Various bacterial infections could activate intrahepatic macrophages/Kupffer cells by producing endotoxin and bacterial antigens in the intestinal tract.[6,7] Localized intrahepatic macrophage activation might be a special form of MAS induced by intestinal infection. The immunochemical studies demonstrated that the number of intrahepatic macrophages/Kupffer cells in acute phase was higher than that after treatment. These findings suggested that activated intrahepatic macrophages/Kupffer cells were associated with ALF in S-JIA. Plasma exchange was used for the purpose of the rapid reduction of cytokine levels. Cyclosporine A combined with PM was effective for the control of the activated intrahepatic macrophage/Kupffer cells.

Second, there is a possibility that the liver failure was caused by acute-onset AIH concomitant with S-JIA. On the basis of the international criteria for AIH, the child in case 1 was classified as 'probable' AIH[5]. Although no autoantibodies were detected in case 1, histologic features such as interface hepatitis and rosette formation suggested that the ALF might have been due to acute-onset AIH. AIH frequently coexist in other autoimmune diseases such as rheumatoid arthritis and celiac disease. Recently, two case reports describing a diagnosis of AIH made after an initial manifestation of S-JIA have appeared.[8,9]

Third, ALF with S-JIA could be induced by drugs. In particular, non-steroidal anti-inflammatory drugs (NSAIDs) are well known as causative agents of liver failure.[10] However, while an NSAID was prescribed in case 1, it was not in use when liver enzyme values became elevated. We evaluated the probability of a diagnosis of drug-induced liver injury using a previously reported scoring system.[11] The results were 'unlikely' and 'excluded' in case 1 and 2, respectively.

In conclusion, we present two cases in which S-JIA was complicated with ALF without MAS. In these two cases of S-JIA with ALF in which MAS could not be confirmed,

© 2011 The Authors
Journal of Paediatrics and Child Health © 2011 Paediatrics and Child Health Division (Royal Australasian College of Physicians)

plasma exchange and cyclosporine A combined with PM were effective.

## Multiple Choice Questions

1. Which markers are not useful for diagnosis of macrophage activation syndrome?
   - A C-reactive protein.
   - B White blood cell/Hb/Plt counts.
   - C NK cell activity.
   - D Fibrinogen.
   - E Ferritin.
2. Which autoimmune diseases can be often followed by macrophage activation syndrome? Choose all that apply.
   - A SLE.
   - B Autoimmune hepatitis.
   - C Systemic JIA.
   - D Graves-Basedow disease.
   - E Ulcerative colitis.
3. Which drugs are effective for the treatment of macrophage activation syndrome?
   - A H2-blocker.
   - B Antibiotics.
   - C Methotrexate.
   - D Corticosteroid.
   - E Non-steroidal anti-inflammatory drugs.

Answers

1 A C-reactive protein is not included in the criteria of hemophagocytic lymphohistiocytosis.

2 A and C. SLE and systemic JIA are well known as an association with macrophage activation syndrome.

3 D Corticosteriod, cyclosporine A, and etoposide are recommended for the treatment of hemophagocytic lymphohistiocytosis.

## References

1 Avcin T, Tse SM, Schneider R, Ngan B, Silverman ED. Macrophage activation syndrome as the presenting manifestation of rheumatic diseases in childhood. *J. Pediatr.* 2006; **148**: 683–6.

2 Behrens EM, Beukelman T, Paessler M, Cron RQ. Occult macrophage activation syndrome in patients with systemic juvenile idiopathic arthritis. *J. Rheumatol.* 2007; **34**: 1133–8.

3 Henter JI, Horne A, Arico M *et al.* HLH-2004: diagnostic and therapeutic guidelines for hemophagocytic lymphohistiocytosis. *Pediatr. Blood Cancer* 2007; **48**: 124–31.

4 Petty RE, Southwood TR, Manners P *et al.* International League of Associations for Rheumatology classification of juvenile idiopathic arthritis: second revision, Edmonton, 2001. *J. Rheumatol.* 2004; **31**: 390–2.

5 Alvarez F, Berg PA, Bianchi FB *et al.* International Autoimmune Hepatitis Group Report: review of criteria for diagnosis of autoimmune hepatitis. *J. Hepatol.* 1999; **31**: 929–38.

6 Seki S, Habu Y, Kawamura T *et al.* The liver as a crucial organ in the first line of host defense: the roles of Kupffer cells, natural killer (NK) cells and NK1.1 Ag+ T cells in T helper 1 immune responses. *Immunol. Rev.* 2000; **174**: 35–46.

7 Knolle PA, Gerken G. Local control of the immune response in the liver. *Immunol. Rev.* 2000; **174**: 21–34.

8 Nobili V, Devito R, Comparcola D, Cortis E, Sartorelli MR, Marcellini M. Juvenile idiopathic arthritis associated with autoimmune hepatitis type 2. *Ann. Rheum. Dis.* 2005; **64**: 157–8.

9 Fathalla BM, Goldsmith DP, Pascasio JM, Baldridge A. Development of autoimmune hepatitis in a child with systemic-onset juvenile idiopathic arthritis during therapy with etanercept. *J. Clin. Rheumatol.* 2008; **14**: 297–8.

10 Lapeyre-Mestre M, de Castro AM, Bareille MP *et al.* Non-steroidal anti-inflammatory drug-related hepatic damage in France and Spain: analysis from national spontaneous reporting systems. *Fundam. Clin. Pharmacol.* 2006; **20**: 391–5.

11 Maria VA, Victorino RM. Development and validation of a clinical scale for the diagnosis of drug-induced hepatitis. *Hepatology* 1997; **26**: 664–9.

© 2011 The Authors
Journal of Paediatrics and Child Health © 2011 Paediatrics and Child Health Division (Royal Australasian College of Physicians)

特集・胆汁うっ滞—診療の最先端

# 先天性胆汁酸代謝異常

水落建輝*　木村昭彦

## はじめに

胆汁酸とは，肝臓でコレステロールより生合成されるステロイドの1群である。先天性胆汁酸代謝異常症とは，この生合成経路の遺伝性酵素欠損を1次性の病因とするもので，常染色体劣性遺伝形式を示す遺伝性疾患である。1980年代後半に疾患概念が確立され，2000年前後に責任遺伝子が次々と同定された。中間代謝産物の異常胆汁酸もしくは胆汁アルコールが蓄積し，無治療であれば肝不全へ移行し死亡する。症状は，出生時から続く黄疸，肝腫大，灰白色便などであり，胆道閉鎖症や新生児肝炎との鑑別が重要である。本疾患で特徴的なのは，胆汁うっ滞（ALTとD-Bilの上昇）を認めるにもかかわらず，血清γ-GTPと総胆汁酸値が正常な点である。治療は1次胆汁酸療法か肝移植が行われる。

本稿では，先天性胆汁酸代謝異常症の病態，診断，治療について述べる。

## I 病態，症状，診断

先天性胆汁酸代謝異常症は，胆汁酸生合成経路の遺伝性酵素欠損により，異常胆汁酸もしくは胆汁アルコールが蓄積する。異常胆汁酸は細胞毒性が強く，肝臓を中心にさまざまな臓器障害をひき起こす。異常胆汁酸の蓄積により，肝細胞が障害を受け胆汁うっ滞型肝障害をひき起こす。症状は，出生時から続く黄疸，肝腫大，灰白色便（脂肪便）などである。進行すれば肝硬変，肝不全へ移行する。乳児胆汁うっ滞症をひき起こす鑑別疾患として，胆道閉鎖症，先天性胆道拡張症，シトリン欠損症（NICCD），進行性家族性肝内胆汁うっ滞症（PFIC），Alagille症候群，新生児肝炎などがあげられる。本疾患で特徴的なのは，胆汁うっ滞を認めるにもかかわらず，血清γ-GTPと総胆汁酸値が正常な点である。なぜ，このような検査所見を認めるかというと，異常胆汁酸は胆管へ排泄されにくい性質があるため，胆管の逸脱酵素であるγ-GTPは正常値となる。また，異常胆汁酸は水酸基の構造変化が起こるため，現在の一般的な胆汁酸測定方法では胆汁酸として認識できない。よって，異常胆汁酸は増加しているものの，検査で認識できる正常胆汁酸が減少しているため，血清総胆汁酸値はみかけ上，正常もしくは低値となる。異常胆汁酸の測定には，ガスクロマトグラフィー質量分析法（GC-MS）を用いる。GC-MSは異常胆汁酸とその組成まで検出可能で，その組成より胆汁酸代謝異常症の予測が可能である。GC-MSによる胆汁酸分析は，血清，尿，胆汁などの検体を用いるが，採取の容易さと異常胆汁酸の排泄量から最も適切なのは尿検体である。胆汁酸分析で各疾患に特異的な異常胆汁酸が検出された場合，疑われる疾患の責任遺伝子を解析し確定診断へつなげる。また，最終診断と肝臓の状態をみきわめ1次胆汁酸療法や肝移植などの治療を行う。病態・診断のアルゴリズムを図1に示す[1)]。

## II 疾患分類

現在，広義の胆汁酸代謝異常症は9疾患報告されている[2)]。胆汁酸代謝には細胞内小器官であるミトコンドリアやペルオキシゾームも関与しており，その異常症も含まれている。本項では，ス

---

*Mizuochi Tatsuki　Kimura Akihiko*
* 久留米大学医学部小児科
〔〒830-0011　久留米市旭町67〕
TEL 0942-31-7565　FAX 0942-38-1792
E-mail：mizuochi_tatsuki@kurume-u.ac.jp

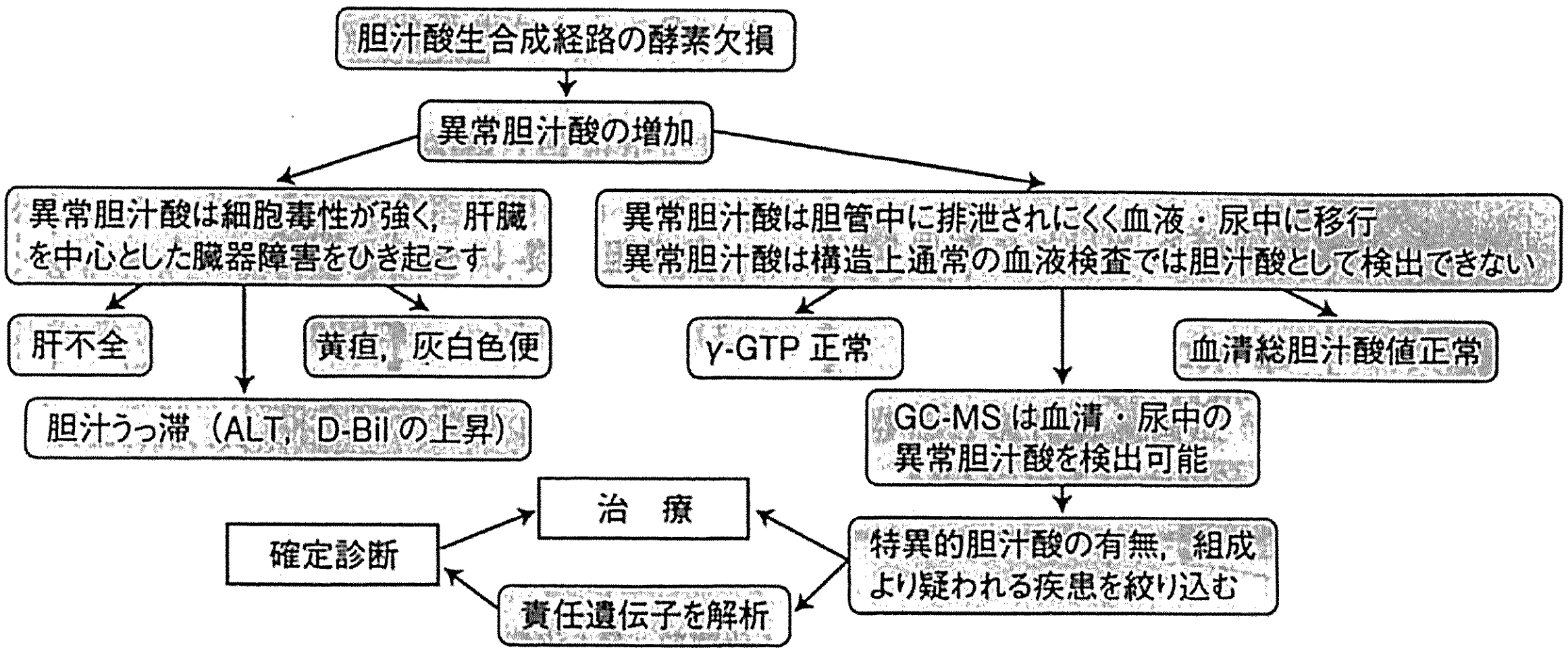
胆汁酸生合成経路の酵素欠損
異常胆汁酸の増加
異常胆汁酸は細胞毒性が強く，肝臓を中心とした臓器障害をひき起こす
異常胆汁酸は胆管中に排泄されにくく血液・尿中に移行
異常胆汁酸は構造上通常の血液検査では胆汁酸として検出できない
肝不全
黄疸，灰白色便
胆汁うっ滞（ALT，D-Bil の上昇）
γ-GTP 正常
血清総胆汁酸値正常
GC-MS は血清・尿中の異常胆汁酸を検出可能
治　療
確定診断
特異的胆汁酸の有無，組成より疑われる疾患を絞り込む
責任遺伝子を解析

図 1　病態・診断のアルゴリズム（水落ら1)，2010）

テロイド骨格の水酸化や酸化還元に関する酵素欠損により特異的な異常胆汁酸が蓄積し，小児期に発症する狭義の先天性胆汁酸代謝異常症 3 疾患について述べる。

### 1．3β-HSD 欠損症

3β-hydroxy-$\Delta^5$-$C_{27}$-steroid dehydrogenase/isomerase deficiency（3β-HSD 欠損症）は最も頻度の高い胆汁酸代謝異常症である。肝不全の進行は比較的緩徐であり，年長児や成人で診断された報告もある。胆汁酸分析で，異常胆汁酸である 3β-hydroxy-$\Delta^5$-bile acids を多量に検出する。責任遺伝子は *HSD3B7* で，遺伝子診断された報告はわが国で 3 例ある3,4)。治療は 1 次胆汁酸療法が非常に有効で，肝移植回避には早期診断と治療が重要である。

### 2．5β-reductase 欠損症

3-oxo-$\Delta^4$-steroid 5β-reductase deficiency（5β-reductase 欠損症）は，肝不全の進行は比較的早い。胆汁酸分析で，異常胆汁酸である 3-oxo-$\Delta^4$-bile acids を多量に検出する。責任遺伝子は *SRD5B1* で，遺伝子診断された報告はわが国で 5 例ある（2 例は台湾人，3 例は論文未発表）5)。治療は 1 次胆汁酸療法が有効な例と無効な例がある。まずは 1 次胆汁酸療法を行い，無効であれば肝移植が必要である。この疾患で注意が必要な点は，異常胆汁酸の 3-oxo-$\Delta^4$-bile acids は他の重症肝疾患（劇症肝炎，肝硬変など）でも検出されるため6)，1 次性（遺伝性）か 2 次性かの鑑別が必要である。2 次性の代表的疾患である，新生児ヘモクロマトーシスとの鑑別は重要であるが，異常胆汁酸の程度と遺伝子解析により鑑別は可能である5)。

### 3．oxysterol 7α 欠損症

oxysterol 7α-hydroxylase deficiency（oxysterol 7α 欠損症）は，乳児期に急速に肝不全へ移行する最も重症な胆汁酸代謝異常症である。胆汁酸分析で，異常胆汁酸である 3β-monohydroxy-$\Delta^5$-bile acids を多量に検出する。責任遺伝子は *CYP7B1* で，遺伝子診断された報告はわが国で 2 例ある（1 例は台湾人，1 例は論文投稿中）7)。治療は，1 次胆汁酸療法は無効で肝移植のみと考えられている。過去の報告例は肝移植前後の乳児期に死亡しており救命例はなかったが，われわれはわが国の患者で世界初の肝移植救命例を経験し，現在 2 歳で肝機能異常なく順調な経過である（論文投稿中）。

## Ⅲ 治　療

3β-HSD 欠損症と 5β-reductase 欠損症に対する経口 1 次胆汁酸療法の有効性が報告されている。1 次胆汁酸とはコール酸（CA）とケノデオキシコール酸（CDCA）の 2 つである。治療のメカニズムは，1 次胆汁酸置換により胆汁酸生合成を調節する核内受容体の farnesoid X receptor に feed back がかかり，cholesterol 7α-hydroxylase

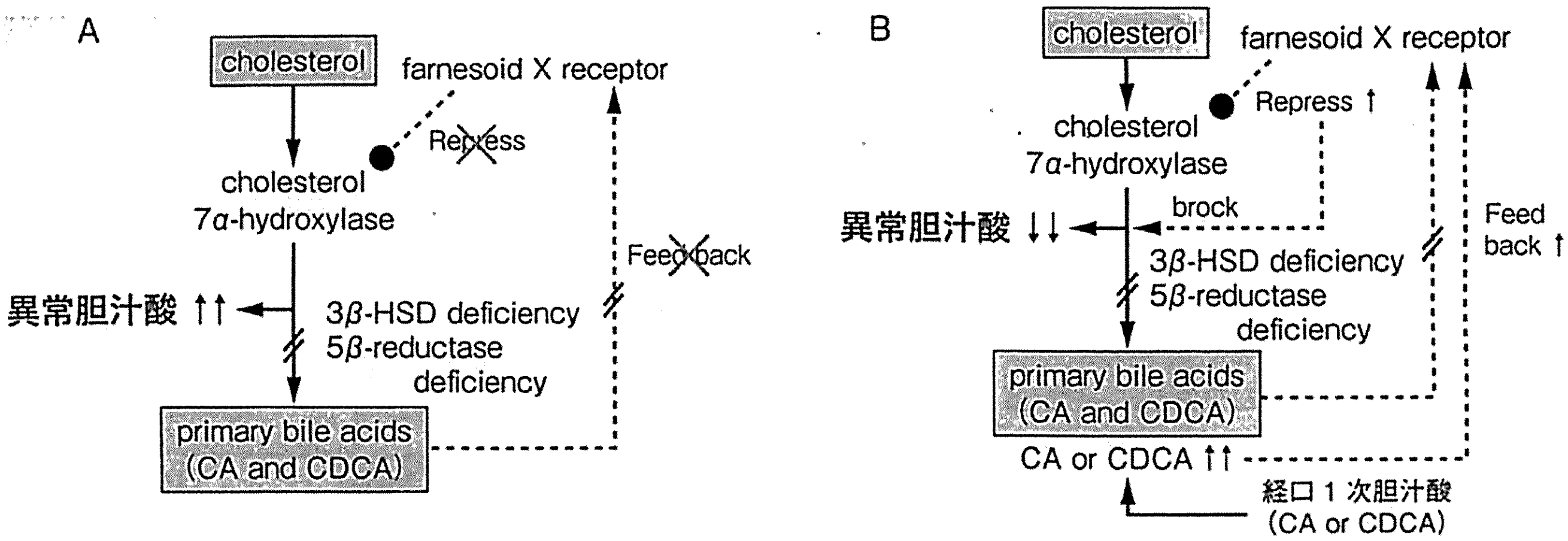
A
cholesterol
farnesoid X receptor
Repress
cholesterol
7α-hydroxylase
Feedback
異常胆汁酸 ↑↑
3β-HSD deficiency
5β-reductase
deficiency
primary bile acids
(CA and CDCA)
B
cholesterol
farnesoid X receptor
Repress ↑
cholesterol
7α-hydroxylase
brock
異常胆汁酸 ↓↓
Feed
back ↑
3β-HSD deficiency
5β-reductase
deficiency
primary bile acids
(CA and CDCA)
CA or CDCA ↑↑
経口1次胆汁酸
(CA or CDCA)

図2　1次胆汁酸療法のメカニズム　A：治療前　B：治療後（水落ら[1]，2010）

の活性が抑制され結果として異常胆汁酸が減少するためである。治療前後の1次胆汁酸療法のメカニズムを図2に示す[1]。肝炎や胆汁うっ滞症での使用頻度が高い3次胆汁酸であるウルソデオキシコール酸（UDCA）は，この作用がないため基本的には無効である。肝細胞への抗炎症および利胆作用があるため，短期的には有効なこともあるが，徐々に肝硬変へと進行するため注意が必要である。1次胆汁酸療法にはCA単独，CDCA単独，CA＋CDCA併用，以上の報告がある。欧米ではCA単独療法が主流である[8]が，わが国では市販されているCA製剤はない。よって，わが国における1次胆汁酸療法はCDCA（チノカプセル®）単独となる。われわれは，3β-HSD欠損症3例，5β-reductase欠損症2例に対し経口CDCA療法を行い，良好な経過を得ている[3,4]。

1次胆汁酸療法が無効な際は，肝移植が必要となる。他の常染色体劣性遺伝形式をとる代謝性肝疾患と同様に，ヘテロ接合体（両親）をドナーとした肝移植は可能で，生体肝移植の適応疾患である。わが国で肝移植が行われた先天性胆汁酸代謝異常症は，前述のoxysterol 7α欠損症1例のみである。

## Ⅳ 症例

胆汁酸代謝異常症は非常にまれな疾患であるため，診断から治療へのアプローチを実際の症例を提示し解説する。

6か月　女児

**主訴**　遷延性黄疸

**家族歴，既往歴**　特記事項なし。

**病歴**　1か月，3か月健診時に黄疸の指摘受けるも，軽度であるため経過観察されていた。6か月時に遷延性黄疸，肝機能異常の指摘を受け紹介。

**血液検査**　AST/ALT 571/333 U/L，T-Bil/D-Bil 6.9/4.0 mg/dL，γ-GTP 45 U/L（10～47），総胆汁酸 2.2 μmol/L（<10），PT（%）68%（>70）。

**経過**　黄疸，肝腫大，灰白色下痢便を認めた。腹部エコー・CT，十二指腸ゾンデ，肝胆道シンチグラフィなど行うも，胆道閉鎖症や拡張症などの構造異常は否定。他の一般的な乳児胆汁うっ滞症の精査を行うも原因不明。血清γ-GTPと総胆汁酸値が正常である点より，胆汁酸代謝異常症を鑑別にあげ尿中胆汁酸分析を実施。多量の3-oxo-$\Delta^4$-bile acidsを検出し，臨床経過より1次性5β-reductase欠損症が疑われた。*SRD5B1*遺伝子を解析し，複合ヘテロ変異を認めた。経口CDCA療法を行い，胆汁うっ滞は改善した。

**最終診断**　5β-reductase欠損症（1次性）

**本症例のポイント**

胆汁うっ滞を認めるにもかかわらず，血清γ-GTPと総胆汁酸値が正常である典型的な胆汁酸代謝異常症の臨床像である。担当医が胆汁酸代謝異常症を鑑別にあげ尿中胆汁酸分析を行ったため，早期診断・治療へとつながり良好な経過を得ることができた。

## Ⅴ まとめ

乳幼児の胆汁うっ滞症を診た際，鑑別疾患とし

て胆汁酸代謝異常症という疾患があることを覚えていただきたい。特徴は，胆汁うっ滞があるにもかかわらず，血清 $\gamma$-GTP と総胆汁酸値が正常な点である。このような値をきたす胆汁うっ滞症はほかにないため，血液検査で疑うことができる。小児肝疾患を専門に診ている小児科医以外は，$\gamma$-GTP や総胆汁酸値を検査しないことが多い。しかし，この 2 つの値をみることは，本疾患を含め，乳幼児胆汁うっ滞症の鑑別疾患を考えるうえで非常に重要であるため9)，ぜひ検査していただきたい。

先天性胆汁酸代謝異常症は，原因不明の乳幼児胆汁うっ滞症の約 6%を占めるまれな疾患である10)。事実，2007 年までに遺伝子診断された英文報告は約 20 例程しかなかった。しかし，われわれは 2008 年から現在まで約 3 年間で 10 例（4 例は論文未発表）を遺伝子診断した3~5,7)。原因不明の肝硬変，肝不全として肝移植が行われたり，新生児肝炎として UDCA で治療されている患者のなかに，本疾患が隠れている可能性がある。診断には GC-MS による胆汁酸分析と遺伝子解析が必要である。現在，胆汁酸分析は順伸クリニック胆汁酸研究所（http://www8.ocn.ne.jp/~bile-res/〔2011 年 4 月 19 日アクセス〕），遺伝子解析は久留米大学小児科で行っている。胆汁酸代謝異常症を疑った際は連絡していただきたい。

**Key Points**

❶ 胆汁うっ滞症を診たときは，必ず血清 $\gamma$-GTP と総胆汁酸値を測定する。
❷ 血清 $\gamma$-GTP と総胆汁酸値が正常な胆汁うっ滞症を診たときは，胆汁酸代謝異常症を疑う。
❸ 胆汁酸代謝異常症を疑ったときは，GC-MS による尿中胆汁酸分析を行う。

## おわりに

先天性胆汁酸代謝異常症は，早期診断すればそのほとんどが経口 1 次胆汁酸療法による内科的治療可能な疾患である。診断が遅れたり，無治療であれば，肝硬変へと移行し肝移植以外に救命の手段はない。血清 $\gamma$-GTP と総胆汁酸値が正常な胆汁うっ滞症の小児を診た際は，胆汁酸代謝異常症を鑑別にあげ，尿中胆汁酸分析を行っていただきたい。

### 文献

1) 水落建輝，木村昭彦：胆汁酸代謝異常症―診断へのアプローチと 1 次胆汁酸療法．小児科臨床 **63**：2081-2087，2010
2) Sundaram SS, Bove KE, et al：Mechanisms of disease：inborn errors of bile acid synthesis. Nat Clin Pract Gastroenterol Hepatol **5**：456-468, 2008
3) Mizuochi T, Kimura A, et al：Molecular genetic and bile acid profiles in two Japanese patients with $3\beta$-hydroxy-$\Delta^5$-$C_{27}$-steroid dehydrogenase/isomerase deficiency. Pediatr Res **68**：258-263, 2010
4) Nittono H, Takei H, et al：$3\beta$-hydroxy-$\Delta^5$-$C_{27}$-steroid dehydrogenase/isomerase deficiency in a patient who underwent oral bile acid therapy for 10 years and delivered two healthy infants. Pediatr Int **52**：e192-e195, 2010
5) Ueki I, Kimura A, et al：*SRD5B1* gene analysis needed for the accurate diagnosis of primary 3-oxo-$\Delta^4$-steroid $5\beta$-reductase deficiency. J Gastroenterol Hepatol **24**：776-785, 2009
6) Kimura A, Suzuki M, et al：Urinary $7\alpha$-hydroxy-3-oxochol-4-en-24-oic and 3-oxochola-4,6-dien-24-oic acids in infants with cholestasis. J Hepatol **28**：270-279, 1998
7) Ueki I, Kimura A, et al：Neonatal cholestatic liver disease in an Asian patient with a homozygous mutation in the oxysterol $7\alpha$-hydroxylase gene. J Pediatr Gastroenterol Nutr **46**：465-469, 2008
8) Gonzales E, Gerhardt MF, et al：Oral cholic acid for hereditary defects of primary bile acid synthesis：A safe and effective long-term therapy. Gastroenterology **137**：1310-1320, 2009
9) 木村昭彦，水落建輝，他：乳児胆汁うっ滞症の診断アプローチ：胆道閉鎖症の早期発見．日児栄消肝誌 **23**：1-7，2009
10) Nittono H, Takei H, et al：Diagnostic determination system for high-risk screening for inborn errors of bile acid metabolism based on an analysis of urinary bile acids using gas chromatography-mass spectrometry：Results for 10 years in Japan. Pediatr Int **51**：535-543, 2009

# 胆汁酸，ビリルビンの肝細胞内輸送

木村昭彦*

## はじめに

胆汁酸は肝臓でコレステロールからつくられ，胆管を通って十二指腸へ排泄される。胆汁酸は，毛細胆管でコレステロールとリン脂質とミセル形成し，細胞毒性が弱まった状態で胆管に排泄され小腸で脂肪分解などに働いた後，小腸下部（主に回腸末端）で再吸収され門脈を経て肝臓にもどる（腸肝循環）。回収率は95%以上である。

肝臓でつくられる胆汁酸（1次胆汁酸）はコール酸（CA：cholic acid）とケノデオキシコール酸（CDCA：chenodeoxycholic acid）で，主に側鎖のカルボキシル基がグリシンおよびタウリンなどのアミノ酸抱合を受ける。さらに，一部は3位水酸基が硫酸抱合を受ける。これら抱合型胆汁酸が主要成分として胆管に排泄される。腸管では，これら一次胆汁酸は腸内細菌により2次胆汁酸，デオキシコール酸（DCA：deoxycholic acid）とリトコール酸（LCA：lithocholic acid）に変換される[1,2]。

腸肝循環によって取り込まれた胆汁酸の肝臓内（肝細胞内）濃度の増減は肝臓における胆汁酸生合成と排泄機構のフィードバックより制御されている。すなわち，胆汁酸濃度が上昇すれば生合成を抑制し，同時に胆管への排泄能を上昇させる。これにより体内の胆汁酸プールは一定に保たれている（詳しくは，後述）。

一方，ビリルビンは，ヘモグロビン，プロトポルフィリンが肝臓，脾臓，腎臓，骨髄などでビルベルジンに代謝され，さらにビリルビンに還元されつくられる。血中では，2分子のビリルビンが1分子のアルブミンと結合し肝臓に取り込まれ，グルクロン酸抱合型となった後，胆汁中に排泄される。胆汁酸と同様腸肝循環する[3)]。

腸管内では抱合型ビリルビンは腸内細菌により脱抱合を受け遊離ビリルビンとなる。遊離ビリルビンはウロビリノーゲンに変換される。ウロビリノーゲンは酸化されウロビリンとなり糞便中に排泄される。ビリルビンあるいはウロビリノーゲンの20%は腸から再吸収され，門脈を経て肝臓にもどり再び胆汁中に排泄される。その一部は尿中にも排泄される。原則として，尿中に排泄されるのは抱合型ビリルビンである[3)]。

## I トランスポーター

トランスポーターは，基質輸送に働く蛋白質で細胞膜に存在し，細胞内への取り込みや細胞外への排泄に関わる。輸送される基質は，脂質，糖質，ビタミン，蛋白質，薬物などさまざまである。さらに，トランスポーターは1つの基質を一方向だけに輸送するのではなく，2種類の基質を相互に逆方向へ輸送する働きや，2種類の基質を同方向へ輸送する働きをもち細胞内外の基質輸送を調節している。

## II 肝細胞トランスポーターと肝細胞内輸送

胆汁酸のトランスポーター（図1）は肝臓，胆管，腸，腎臓，脳に局在している。ここでは肝臓について述べる。

最近，胆汁酸の腸肝循環に関わる種々のトラン

---

*Kimura Akihiko*
* 久留米大学医学部小児科
〔〒830-0011　久留米市旭町67〕
TEL 0942-31-7565　FAX 0942-38-1792
E-mail：a-kimura@kumin.ne.jp

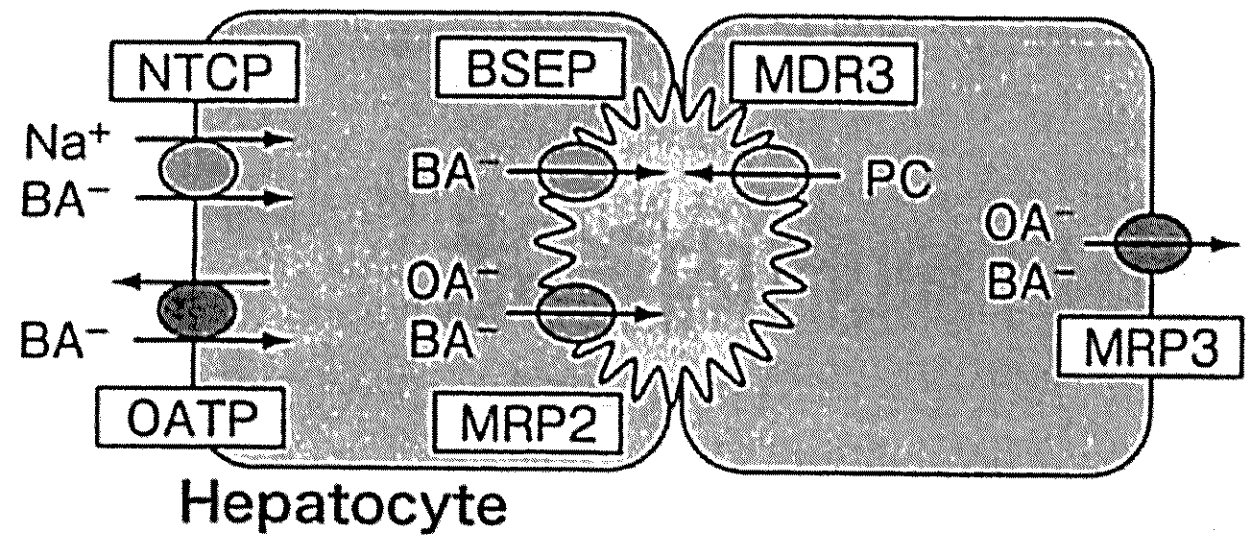

図 1　胆汁酸，ビリルビンに関与するトランスポーター（Trauner ら7)，2003）

スポーターの存在が明らかとなり，その機能解析ならびに各種病態との関連について多くの研究がなされている。これらトランスポーターは，胆汁酸の細胞内の取り込みに働く群と，細胞内から外へ排出に働く群に大別される。胆汁酸の肝細胞への取り込みは，Na イオン依存性の経路および非依存性経路に大別され，前者は $Na^+$-taurocholate co-transporting polypeptide（NTCP）群が，後者は organic anion transporting proteins（OATP）群が細胞への取り込みを担っている。これらのトランスポーターは肝細胞の類洞膜（血管側）に局在し，血液中の胆汁酸を肝細胞内へ輸送する機能をもっている4〜6)。

一方，胆汁酸の肝外への排泄には各種 ATP binding cassette（ABC）トランスポーターが関与している。ABC トランスポーターは，細胞内 ATP の加水分解により生じるエネルギーを駆動力として，リガンドの方向性輸送を行うトランスポーターである。胆汁酸の肝外への排泄に関与する主な ABC トランスポーターは，bile salt export pump（BSEP），multidrug resistance associated protein 2（MRP2），ならびに multidrug resistance associated protein 3（MRP3）が知られている。前 2 者は肝細胞内の胆管側膜上（細胆管側）に局在し，肝細胞内から胆管へ胆汁酸を排泄することが明らかにされている。BESP はヒト体液中における主要胆汁酸であるグリシンおよびタウリン抱合型胆汁酸（1 価胆汁酸）の排泄を担っており，胆汁酸排泄に最も密接に関与するトランスポーターと考えられている。MRP2 はグリシンおよびタウリン抱合型胆汁酸を基質とせず，硫酸抱合型胆汁酸（2 価胆汁酸）の排泄を担うとともに，エストラジオール，ビリルビンなどのグルクロン酸抱合体のみならず，さまざまな薬物のグルクロン酸抱合体の輸送にも関与する5,7)。

さらに，MRP3 は肝臓および小腸にも発現しており肝細胞においては BSEP，MRP2 とは異なり類洞膜（血管側）に局在し，肝細胞から血管方向への排泄に関与すると考えられており，BSEP の輸送基質である 1 価胆汁酸のみならず 2 価胆汁酸の両者の輸送能を有することが明らかにされている。また，グルクロン酸抱合胆汁酸も分泌するといわれる7)。

肝細胞内に取り込まれた胆汁酸は細胞質の結合蛋白（Y′，Y および Z 蛋白）と結合し，ゴルジ装置や毛細胆管周囲へ細胞内を拡散輸送される。これら結合蛋白のなかでも，Y′ 蛋白は 3α-hydroxysteroid dehydrogenase および dihydrodiol dehydrogenase 活性を有し，肝細胞内の胆汁酸輸送に最も重要な働きをすると考えられている8,9)。

ビリルビンの肝細胞への取り込みは OATP1 が行う。肝内に取り込まれたビリルビンは主に glutathione S-transferase をもつ Y 蛋白と結合し，ついで bilirubin-UDP-glucronyltransferase によりグルクロン酸抱合型となり MRP2 を介して胆汁中に分泌される。

## III　胆汁酸およびビリルビントランスポーター異常症

厳密にいえば，胆汁酸トランスポーターの遺伝的疾患は，BSEP の遺伝子異常によって生じる進行性家族性肝内胆汁うっ滞症 2 型および良性反復性肝内胆汁うっ滞症 2 型（PFIC2：progressive familial intrahepatic cholestasis type 2，BRIC2：benign recurrent intrahepatic cholestasis type 2）とビリルビントランスポーターの異常でもある MRP2 の遺伝子異常による Dubin-Johnson 症候群である。これら 3 疾患のまとめを表に示す10)。

代表的な遺伝的疾患に PFIC 1 と 3，および BRIC1 が報告されているが，PFIC1 と BRIC1 の責任遺伝子である famirial intrahepatic cholestasis 1（FIC1）の機能は十分に解明されておらず，細胞膜を構成する脂質二重層の外側から内側へアミノリン脂質（phosphatidylserine）を輸送するト

表　胆汁酸・ビリルビントランスポーターとその異常によって起こる疾患

| | 原因トランスポーター | 遺伝子統一名 | 遺伝子座 | 血清γ-GTP | 血清総胆汁酸 | 掻痒感 | 特徴的所見 |
|---|---|---|---|---|---|---|---|
| PFIC 2 | BSEP | *ABCB11* | 2q24 | 正常 | 高値 | あり | 電顕で細胆管内の無構造もしくは微細フイラメント状胆汁 |
| BRIC 2 | BSEP | *ABCB11* | 2q24 | 正常 | 間欠的高値 | 間欠的にあり | 黄疸時には胆汁うっ滞を伴うが，正常の小葉構造。無黄疸時には正常もしくは軽度の線維化 |
| Dubin-Johnson 症候群 | MRP2 | *ABCC2* | 10q24 | 正常* | 正常* | なし | 直接型高ビリルビン血症を呈するが，胆汁うっ滞はみられない* |

* 新生児期には胆汁うっ滞を呈することあり，このときはγ-GTP，総胆汁酸は高値。

（須磨崎・長谷川10) 2007 より一部追加）

ランスポーターと推測されている。また，PFIC3 の責任遺伝子 multidrug resistance protein 3 (MDR3) はリン脂質（主として phosphatidylcholine）を排泄する ABC トランスポーターで肝細胞内の胆管側膜上（細胆管側）に局在する11)。したがって，FIC1 と MDR3 は胆汁酸トランスポーターとはいえない。

## Ⅳ 胆汁うっ滞時の胆汁酸肝細胞内輸送

胆汁うっ滞時に重要な働きをするのは核内レセプターである。

肝臓において合成された胆汁酸の大部分はグリシンあるいはタウリン抱合を受け，最終的に陰イオン性の胆汁酸（塩）に変換される。この過程において親水性が増大した抱合型胆汁酸の細胞膜への透過性が低下することから，腸肝循環を円滑に行うために肝臓および小腸の特定のトランスポーターの活性を調節する必要がある。核内レセプターである farnesoid X receptor (FXR) は胆汁酸の肝臓から胆管への排泄，腸管での吸収および肝臓での再取り込みのレベルで腸肝循環を制御している12)。

すなわち，胆汁うっ滞時には，高濃度の肝臓内（肝細胞内）胆汁酸は，FXR を介して胆汁酸排泄レベル（細胆管測）では，BSEP と MDR3 の 2 種類の ABC トランスポーターを誘導し，胆汁酸とリン脂質の比率を調節しながら分泌を促進させる。また，FXR は MRP2 を誘導しグルタチオンや胆汁酸グルクロン酸および硫酸抱合体の排泄を促進させる。さらに，MRP3 のトランスポーターが肝細胞膜の血管側に発現し胆汁酸を肝細胞から血液側へ逆走させる。一方，回腸末端では FXR は胆汁酸吸収を抑制する。

また，肝臓での胆汁酸の再吸収に関与する NTCP や OATP の発現を減少させることから，肝臓での胆汁酸再吸収は抑制されると考えられる。よって，肝細胞内の胆汁酸濃度を低下させ肝毒性を下げる方向へ向ける。

そのほか，FXR はグリシンやタウリン抱合に関わる bile acid-CoA synthetase (BACS) や bile acid-CoA：amino acid *N*-acetyltransferase (BAT)，胆汁酸の親水性を増大させ排泄を促進させる UDP-glucronosyltransferase (UGT2B4) および salfotransferase (SULT2A1) といった遺伝子（酵素）群を誘導する13,14)。さらに，胆汁酸生合成の律速酵素であるコレステロール 7α-水酸化酵素 (CYP7A1) の活性を抑制し胆汁酸の生成を抑制する。

## Ⅴ ウルソデオキシコール酸とリファンピシンについて

胆汁うっ滞時に上記の生理的肝細胞障害防御機構が働くが，実際これのみでは胆汁うっ滞および肝細胞障害（肝機能障害）は改善されない。したがって，薬剤の力を借りざるをえない。そこで，昔から胆汁うっ滞時の痒みに対して使用されてき

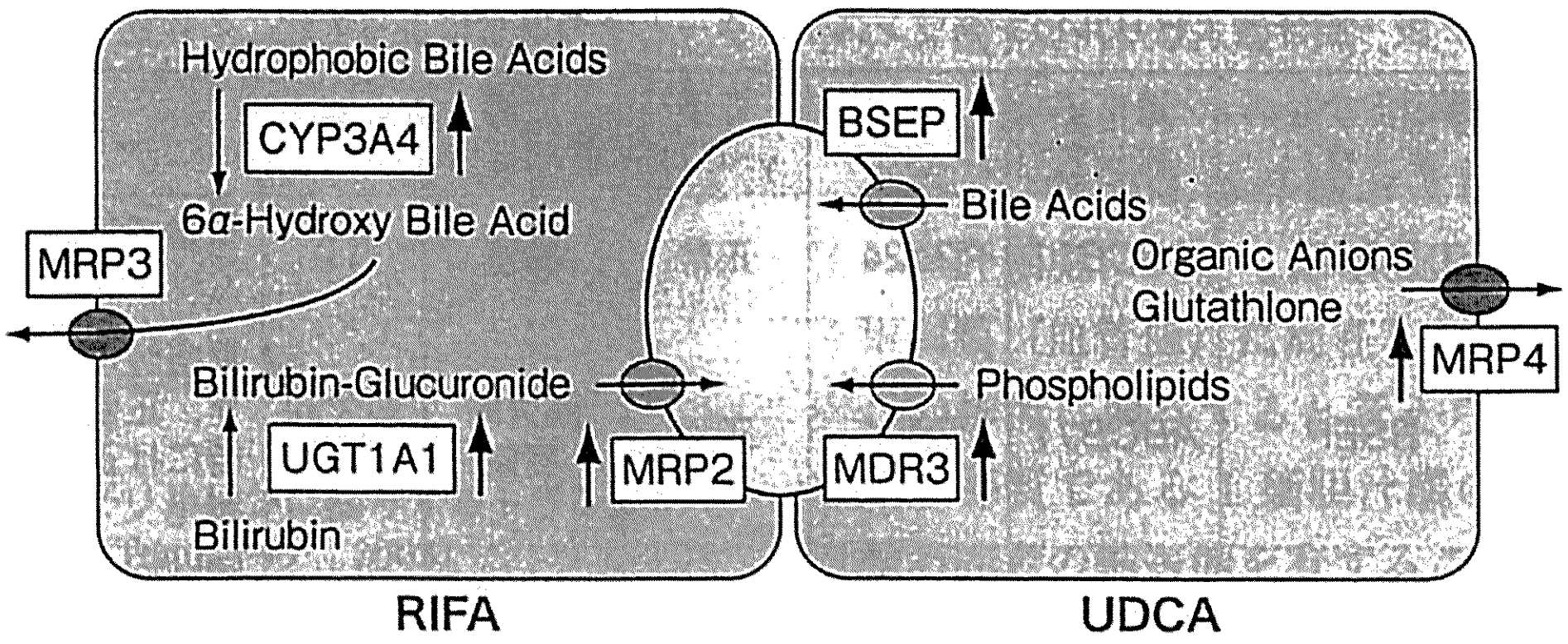
Hydrophobic Bile Acids
CYP3A4
6α-Hydroxy Bile Acid
MRP3
Bilirubin-Glucuronide
UGT1A1
Bilirubin
MRP2
BSEP
Bile Acids
Organic Anions
Glutathione
MRP4
Phospholipids
MDR3
RIFA
UDCA

図 2　リファンピシン（RIFA）とウルソテオキシコール酸（UDCA）の作用機序
(Marschall ら[15]，2005)

た rifampicin（RIFA）療法と頻繁に使用される ursodeoxycholic acid（UDCA）療法のメカニズムについて述べる（図 2）[15,16]。

RIFA は，bilirubin-UDP-glucronyltransferase（UGT1A1）を誘導するとともに MRP2 の蛋白も誘導する。それによりビリルビンはグルクロン酸抱合型となり MRP2 を介して胆汁中への分泌を増す。さらに CYP3A4 を活性化し疎水性胆汁酸（CDCA や LCA など）の C6 の $\alpha$ 位に水酸基を付け親水性胆汁酸へ変え，MRP3 より血液中へ逆輸送する。これら 6$\alpha$ 水酸化胆汁酸はグルクロン酸抱合体である。

UDCA は，親水性胆汁酸であり疎水性胆汁酸と置換することで細胞毒性を和らげる働きがあるとともに，BSEP，MDR3 および MRP4 の蛋白を誘導する。MRP4 はまだ詳しく解明されておらず本稿では説明していないが，ABC トランスポーターで MRP3 と同様の働きがあるようだ。これにより，胆汁酸は BSEP を介して，リン脂質は MDR3 を介して胆汁中に排泄されミセルを形成し胆汁の流出を増す。さらに，MRP4 を介して胆汁酸，有機アニオンの血液中への逆輸送を行う。

最近，BSEP および MRP2 の蛋白誘導および機能を上げる薬剤としてフェニルブチレートが注目されている。

## おわりに

以上のように，胆汁酸の肝細胞内輸送機構が徐々に明らかになり，遺伝性の胆汁排泄異常症も明らかになってきた。今後さらに，胆汁酸トランスポーターと病態との関連が明らかになるものと思われる。

**Key Points**

❶ 腸肝循環と胆汁酸・ビリルビントランスポーターの関連および胆汁酸，ビリルビンの肝細胞内輸送について理解する。
❷ 遺伝性胆汁酸およびビリルビントランスポーター異常症を理解する。
❸ 胆汁うっ滞時の胆汁酸およびビリルビンの排泄メカニズムを理解するとともに，治療メカニズムについても理解する。

## 文　献

1) Russell DW, Setchell KDR：Bile acid biosynthesis. Biochemistry **20**：4737-4749, 1992
2) Russell DW：The enzymes, regulation, and genetics of bile acid synthesis. Annu Rev Biochem **72**：137-174, 2003
3) 内田清久：胆汁酸と胆汁，創英社/三省堂，東京，2009
4) Wagner M, Trauner M：Transcriptional regulation of hepatobiliary transport systems in health and disease：Implications for a rationale approach to the treatment of intrahepatic cholestasis. Ann Hepatol **4**：77-99, 2005
5) Alrefai WA, Gill RK：Bile acid transporters：Structure function, regulation and pathophysiological implications. Pharm Res **24**：1803-1823, 2007
6) Dawson PA, Lan T, Rao A：Bile acid trans-

porters. J Lipid Res **50** : 2340-2357, 2009

7) Trauner M, Boyer JL : Bile salt transporters : Molecular characterization, function, and regulation. Physiol Res **83** : 633-671, 2003

8) Takikawa H, Stolz A, Sugimoto M, et al : Comparison of the affinities of newly identified human bile acid binder and cationic glutathione S-ransferase for bile acids. J Lipid Res **27** : 652-657, 1986

9) Takikawa H, Stolz A, sugiyama Y, et al : Relationship between the newly identified bile acid binder and bile acid oxidoreductases in human liver. J Biol chem **265** : 2132-2136, 1990

10) 須磨崎亮，長谷川誠：進行性家族性肝内胆汁うっ滞症の病態．小児科診療 **70**：924-929，2007

11) Oude Elferink RPJ, Paulusma CC, Groen AK : Hepatocanalicular transport defects : Pathophysiologic mechanisms of rare disease. Gastroenterology **130** : 908-925, 2006

12) Kullak-Ublick GA, Stieger B, Meier PJ : Enterohepatic bile salt transporters in normal physiology and liver disease. Gastroenterology **126** : 322-342, 2004

13) Kalaany NY, Mangelsdorf DJ : LXRS and FXR : The yin and yang of cholesterol and fat metabolism. Annu Rev Physiol **68** : 159-191, 2004

14) Eloranta JJ, Kullak-Ublick GA : Coordinate transcriptional regulation of bile acid homeostasis and drug metabolism. Arch Biochem Biophys **433** : 397-412, 2005

15) Marschall H-U, Wagner M, Zollner G, et al : Complementary stimulation of hepatobiliary transport and detoxification systems by refampicin and ursodeoxycholic acid in humans. Gastroenterology **129** : 476-485, 2005

16) Stapelbroek JM, von Erpecum KJ, Klomp LWJ, et al : Liver disease associated with canalicular transport defect : Current and future therapies. J Hepatol **52** : 258-271, 2010

LIVER TRANSPLANTATION 17:1059-1065, 2011

ORIGINAL ARTICLE

# Successful Heterozygous Living Donor Liver Transplantation for an Oxysterol 7α-Hydroxylase Deficiency in a Japanese Patient

**Tatsuki Mizuochi,[1] Akihiko Kimura,[1] Mitsuyoshi Suzuki,[2] Isao Ueki,[1] Hajime Takei,[3] Hiroshi Nittono,[3] Toshihiko Kakiuchi,[4] Takanobu Shigeta,[4] Seisuke Sakamoto,[4] Akinari Fukuda,[4] Atsuko Nakazawa,[5] Toshiaki Shimizu,[2] Takao Kurosawa,[6] and Mureo Kasahara[4]**

*[1]Department of Pediatrics and Child Health, Kurume University School of Medicine, Kurume-Shi, Fukuoka, Japan; [2]Department of Pediatrics, Juntendo University School of Medicine, Bunkyo-Ku, Tokyo, Japan; [3]Institute of Bile Acids, Junshin Clinic, Meguro-Ku, Tokyo, Japan; Departments of [4]Transplant Surgery and [5]Clinical Pathology, National Center for Child Health and Development, Setagaya-Ku, Tokyo, Japan and [6]Faculty of Pharmaceutical Sciences, Health Sciences University of Hokkaido, Ishikari-Tobetsu, Hokkaido, Japan*

Only 2 patients with an oxysterol 7α-hydroxylase deficiency caused by mutations of the cytochrome P450 7B1 (*CYP7B1*) gene have been reported; for both, the outcome was fatal. We describe the clinical and laboratory features, the hepatic and renal histological findings, and the results of bile acid and *CYP7B1* gene analyses for a third patient. This Japanese infant presented with progressive cholestatic liver disease and underwent successful heterozygous living donor liver transplantation. Sources of relevant data included medical records, hepatic and renal histopathological findings, gas chromatography/mass spectrometry analyses of bile acids in serum and urine samples, and analyses of the *CYP7B1* gene in the DNA of peripheral blood lymphocytes. Large excesses of 3β-hydroxy-5-cholen-24-oic acid were detected in the patient's serum and urine. Cirrhosis and polycystic changes in the kidneys were documented. The demonstration of compound heterozygous mutations (R112X/R417C) of the *CYP7B1* gene led to the diagnosis of an oxysterol 7α-hydroxylase deficiency. After liver transplantation with an allograft from a heterozygous living donor (the patient's mother), the features of decompensated hepatocellular failure abated, and the renal abnormalities were resolved. In conclusion, we report the first Japanese patient with an oxysterol 7α-hydroxylase deficiency associated with compound heterozygous mutations of the *CYP7B1* gene; in this patient, liver transplantation with an allograft from a parental donor was effective. ***Liver Transpl 17: 1059-1065, 2011.*** © 2011 AASLD.

Received December 21, 2010; accepted April 12, 2011.

Nine inborn errors of bile acid synthesis are categorized as inherited metabolic liver diseases.[1] One of these inborn errors of bile acid synthesis, an oxysterol 7α-hydroxylase deficiency, was first described by Setchell et al.[2] and is due to autosomal recessive inheritance. The gene encoding oxysterol 7α-hydroxylase, cytochrome P450 7B1 (*CYP7B1*), is located on chromosome 8q21.3. This rare inborn error of bile acid synthesis responds poorly to bile acid therapy because the progression to cirrhosis is rapid and occurs at an early age. So far, only 2 patients with an oxysterol 7α-hydroxylase deficiency and an associated mutation of the *CYP7B1* gene have been reported; both died in infancy either before or after liver transplantation (LT).[2,3]

We report the first successful use of LT in the management of an oxysterol 7α-hydroxylase deficiency associated with a mutation of the *CYP7B1* gene; we

Abbreviations: CA, cholic acid; CDCA, chenodeoxycholic acid; CYP7A1, cytochrome P450 7A1; CYP7B1, cytochrome P450 7B1; FXR, farnesoid X receptor; LDLT, living donor liver transplantation; LT, liver transplantation; ND, not detected; PCR, polymerase chain reaction; TBA, total bile acid; UDCA, ursodeoxycholic acid.

Address reprint requests to Akihiko Kimura, M.D., Ph.D., Department of Pediatrics and Child Health, Kurume University School of Medicine, 67 Asahi-Machi, Kurume-Shi, Fukuoka, Japan 830-0011. Telephone: 81-942-31-7565; FAX: 81-942-38-1792; E-mail: hirof@med.kurume-u.ac.jp

DOI 10.1002/lt.22331
View this article online at wileyonlinelibrary.com.
LIVER TRANSPLANTATION.DOI 10.1002/lt. *Published on behalf of the American Association for the Study of Liver Diseases*

© 2011 American Association for the Study of Liver Diseases.