

- human epileptic hippocampus. *Neuroscience* 106, 275–285.
- Whitaker, W.R., Faull, R.L., Waldvogel, H.J., Plumpton, C.J., Emson, P. C., Clare, J.J., 2001b. Comparative distribution of voltage-gated sodium channel proteins in human brain. *Brain Res. Mol. Brain Res.* 88, 37–53.
- Yu, F.H., Mantegazza, M., Westenbroek, R.E., Robbins, C.A., Kalume, F., Burton, K.A., Spain, W.J., McKnight, G.S., Scheuer, T., Catterall, W.A., 2006. Reduced sodium current in GABAergic interneurons in a mouse model of severe myoclonic epilepsy in infancy. *Nat. Neurosci.* 9, 1142–1149.



## Case report

## Diagnosing nocturnal frontal lobe epilepsy: A case study of two children

Yuko Tomonoh<sup>a</sup>, Sawa Yasumoto<sup>a</sup>, Yukiko Ihara<sup>a</sup>, Takako Fujita<sup>a</sup>, Noriko Nakamura<sup>a</sup>, Shinya Ninomiya<sup>a</sup>, Rie Kodama<sup>a</sup>, Hiroshi Ideguchi<sup>a</sup>, Takahito Inoue<sup>a</sup>, Akihisa Mitsudome<sup>b</sup>, Shinichi Hirose<sup>a,\*</sup>

<sup>a</sup> Department of Pediatrics, School of Medicine, Fukuoka University, 45-1, 7-chome, Nanakuma, Jonan-ku, Fukuoka 814-0180, Japan

<sup>b</sup> International University of Health and Welfare, Okawa, Japan

## ARTICLE INFO

## Article history:

Received 23 August 2010

Received in revised form 26 February 2011

Accepted 18 March 2011

## Keywords:

Nocturnal frontal lobe epilepsy

Nocturnal sleep EEGs

Parasomnia

## ABSTRACT

We describe two children of nocturnal frontal lobe epilepsy (NFLE) diagnosed using carefully observed nocturnal sleep EEGs and detailed patient histories.

Case #1, a 14-year-old boy, showed repeated generalized tonic convulsions and frequent eyes opening seizures during sleep. Conventional EEGs – done with the patient awake or in sleep stage I – showed no abnormalities, while a nocturnal sleep EEG – done during in sleep stage II – revealed the repeated, sharp wave bursts predominantly in the right frontal lobe characteristic of NFLE. During these wave bursts, we noticed the boy's eyes opening, although his parents had not been aware this NFLE symptom.

Case #2, a 12-year-old boy, showed one daytime generalized convulsion. He had also been suffering from repeated paroxysmal episodes similar to parasomnia – waking up, sitting, walking, screaming, and speaking – which always followed the same patterns lasting several minutes. During the nocturnal sleep EEG, episodes occurred twice, showing abnormal epileptic discharges predominantly in the frontal lobe. His parents did not mention the episodes to us until questioned, as they had recognized them as parasomnia. The previous conventional EEG showed abnormal slow waves in the frontal lobe, which led us to suspect frontal lobe epilepsy and to take a detailed patient history.

The frequency and stereotypy of their symptoms during sleep caused us to perform nocturnal sleep EEGs and led us NFLE diagnosis. Detailed patient histories including sleep habits and carefully observed nocturnal sleep EEGs enabled us to recognize these NFLE clinical features.

© 2011 British Epilepsy Association. Published by Elsevier Ltd. All rights reserved.

## 1. Introduction

Nocturnal frontal lobe epilepsy is a condition which occurs only during sleep and which originates in the frontal lobes.<sup>1,2</sup> NFLE's unusual seizure symptoms often lead to its being confused with non epileptic parasomnia, making nocturnal sleep EEGs with video monitoring reliable method for diagnosing it.

## 2. Case reports

Case #1 is a 14-year-old boy who experienced – only during sleep – repeated generalized tonic seizures. His interictal conventional EEG findings prior to sleep stage I were normal. The nocturnal sleep EEG we gave him provided evidence for an NFLE diagnosis.

The patient complained of headache and pain in both thighs on waking in the morning, an indication he may have had generalized

convulsions during sleep. In the afternoon, again while asleep, he had a generalized tonic convulsion lasting 3 min and was brought to a nearby hospital, where his EEG was taken twice and was normal each time. His brain MRI was also normal and his family had no history of epilepsy or febrile seizures. Four months later, while sleeping, he had another episode of generalized tonic convulsion, this one lasting 2 min. A week after this, because of these seizures, we performed a nocturnal sleep EEG. No abnormality was found during sleep stage I, but 30 min later, beginning sleep stage II, the EEG showed repeated sharp wave bursts predominantly in the right frontal lobe (Fig. 1). The patient's eyes opened half-way during the sharp wave bursts and closed when they ended, lasting several seconds. On the basis of his symptoms and the EEG findings, our diagnosis was NFLE. CBZ was administered and the symptoms and sharp wave bursts ceased.

Case #2 is a 12-year-old boy who, while he had had only one generalized daytime tonic seizure, had experienced nocturnal episodes (somnambulism and night terrors) which led us to administer a nocturnal sleep EEG. Its results led to our diagnosis of NFLE.

\* Corresponding author. Tel.: +81 92 801 1011; fax: +81 92 863 1970.

E-mail address: [hirose@fukuoka-u.ac.jp](mailto:hirose@fukuoka-u.ac.jp) (S. Hirose).

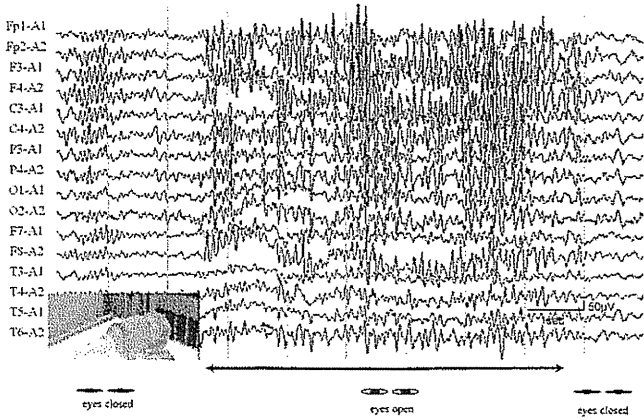


Fig. 1. Case #1's nocturnal sleep EEG. When sleep stage II begins, sharp wave bursts (predominantly in the right frontal lobe) recur repeatedly for several seconds at a time. The patient does not move during the bursts but his eyes open half-way. No abnormalities are seen until sleep stage I.

The patient, at school, had one generalized convulsion lasting 5–10 s. The day following this episode, he was given an interictal awaking EEG in which irregular high voltage slow wave bursts were seen in the frontal lobe, causing us to wonder whether he had frontal lobe epilepsy. We questioned his mother and, surprisingly, found he had been suffering from episodes similar to somnambulism and night terrors. At the age of 11, these episodes occurred a few times a month. One or two hours after falling asleep, he would suddenly wake up, sit, walk a few steps, scream, and then speak. The attacks, which always followed the same pattern, lasted 5 min, during which he was sometimes fearful, sometimes happy. Afterwards, he would fall asleep again, and next morning remembered nothing. At the age of 12, he had such episodes every night. His mother and sister had had febrile seizures in childhood; his grandmother and aunt currently suffer from migraines.

During the nocturnal sleep EEG testing, about 20 min after falling asleep, he suddenly woke, looked around, and said “yes” when his name was called. After about 50 s, he lay down and slept again. Thirty minutes later, he woke again, spoke, and repeatedly made a fist with his right hand. After 25 s, he lay down and slept. When he was in sleep stage II, frontal high voltage sharp wave bursts began 2–3 min before his first episode. Their amplitude increased gradually and 10 s before he awakened frontal high voltage slow waves began. During and after the seizure, frontal irregular high voltage slow waves and sharp wave bursts continued but decreased in frequency, and his sleep returned to sleep stage II (Fig. 2). Similar EEG findings were recorded during the second episode. On the basis of his symptoms and the EEG findings, we diagnosed his nocturnal paroxysmal movements as NFLE seizures. After starting CBZ, auditory side effects began to occur. When ZNS was substituted for CBZ, the side effects stopped and the nocturnal episodes disappeared.

### 3. Discussion

There are circumstances under which NFLE should always be suspected. Among these are: paroxysmal nocturnal events which occur several times a night; events which persist into post-puberty/adulthood or which exhibit extra pyramidal features; agitated behaviors; and stereotypic attacks.<sup>1,3,4</sup> NFLE seizure symptoms may include sudden nocturnal awakenings or opening of the eyes; the placement of the arms or legs in bizarre postures; frightened or surprised facial expressions; screams; dystonic and tonic postures; and clonic limb convulsions.<sup>1–8</sup>

The clinical features table shows the symptoms which led us to suspect that both Cases #1 and #2 had NFLE and caused us to administer nocturnal sleep EEGs (Table 1). Case #1 had repeated tonic seizures and frequent eyes opening seizures during sleep. The eyes opening in particular occurred many times during sleep stage II. Case #2 had – exclusively during sleep – repeated stereotypic episodes similar to parasomnia. The frequency and stereotypy of

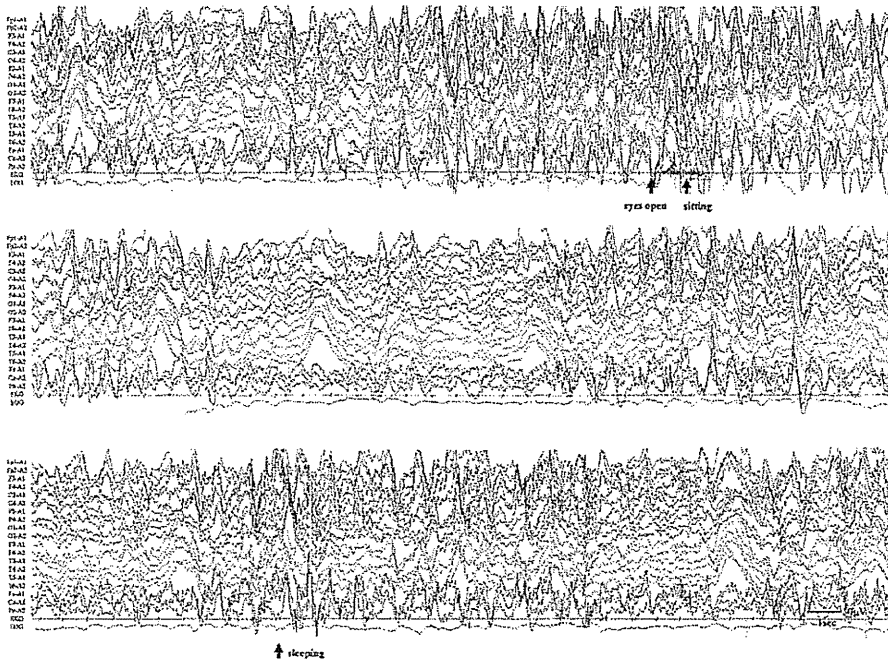


Fig. 2. Case #2's first ictal EEG. Frontal high voltage sharp wave bursts begin during sleep stage II, 2–3 min before the first episode. Their amplitude increases gradually and 10 s before the patient awakens frontal high voltage slow waves begin. During and after the seizure, frontal irregular high voltage slow waves and sharp wave bursts continue but decrease in frequency.

**Table 1**  
Cases #1 and #2 clinical features.

		Case #1	Case #2
Age at onset		4 years	11 years
Age at diagnosis		14 years	12 years
Sex		Male	Male
Symptoms	Tonic seizures	Eyes opening seizure	Tonic seizure
Frequency	3 times	10–20 times during sleep stage II	Once
Duration	2–3 min	Several seconds	5–10 s
Timing	Within 1 h of sleep	Within 30 min of sleep	Daytime
Stereotypy	(+)	(+)	(+)

The table shows the clinical features of both cases. The frequency and stereotypy of the boys' symptoms during sleep contributed to our NFLE diagnosis.

the boys' symptoms during sleep contributed to our NFLE diagnosis.

Although these features strongly indicate NFLE, family members were unaware that some of the symptoms were abnormal and, indeed, Case #1's parents had not noticed the frequent eyes opening during sleep. Similarly, Case #2's parents, who had recognized the boy's nocturnal episodes as parasomnia, did not mention them to us until questioned.

When patients with severe or frequent nocturnal events seek medical attention, a detailed patient history is essential; equally important is carefully viewing any video provided by family members of the patient during sleep.<sup>1,3,4</sup> If, however, family members do not recognize paroxysmal sleep events, or consider them normal, they are unlikely to mention them unless, as in our two cases, they are carefully questioned by the attending physician. Accordingly, sleep habit interviews are necessary for all patients showing either daytime or nocturnal seizures. The interviews are particularly important for patients who have abnormal EEGs findings predominantly in the frontal lobes.

Nocturnal sleep EEGs are useful for diagnosing NFLE and distinguishing NFLE from parasomnia. Video monitoring can catch the NFLE symptoms mentioned earlier and also recognize stereotypy.<sup>1</sup> Ictal EEGs can show theta activity, diffuse/focal flattening of background activity, focal theta activity, rhythmic delta activity, spikes, sharp waves, and spike/sharp and wave activity mainly from the frontal lobe.<sup>1,11</sup>

Parasomnic episodes, however, begin when high voltage slow waves expand and end when wave arousal patterns form; during the episodes, EEGs show diffuse  $\delta$  waves or  $\theta$  waves without spikes.<sup>9,10</sup> Many NFLE seizures occur during sleep stage II,<sup>1</sup> while parasomnia usually occurs during the first cycle of sleep stage III–IV.

In Case #1, while conventional EEGs – done while the patient was awake or during stage I – showed no abnormalities, a nocturnal sleep EEG – done during sleep stage II – revealed the repeated, sharp wave bursts characteristic of NFLE. We observed him carefully and noticed his eyes opening during these wave bursts.

In Case #2's episode, we recognized dystonic movements of his hands and stereotypy. Case #2's episodes began in the sleep stage II, showing high voltage sharp wave bursts which started 2–3 min before the episode in the bilateral frontal lobes. During and after the seizure, irregular high voltage slow waves and sharp wave bursts continued in the bilateral frontal lobes, and ended in the sleep stage II; that led us to diagnose NFLE.

Another possible cause of NFLE – genetic mutation – was eliminated from considering by testing. Mutations in 2 genes that encode the  $\alpha 4$  and  $\beta 2$  subunits of the neuronal nicotinic acetylcholine receptor (*CHRNA4* and *CHRN2*) have been associated

with ADNFLE,<sup>12–15</sup> although they are identified only in a minority of families with this condition.<sup>16</sup> In both Cases # 1 and # 2, we screened all exons of *CHRNA4*, *CHRN2* and *CHRNA2* using the direct sequencing method, and found no mutations.

#### 4. Conclusion

The frequency and stereotypy of the patients' symptoms during sleep caused us to perform nocturnal sleep EEGs and led us NFLE diagnosis. Our cases showed repeated generalized convulsions, frequent eyes opening seizures, and repeated paroxysmal movements similar to parasomnia. Detailed patient histories including sleep habits and carefully observed nocturnal sleep EEGs enabled us to recognize these NFLE clinical features.

#### References

1. Provini F, Plazzi G, Tinuper P, Vandi S, Lugaresi E, Montagna P. Nocturnal frontal lobe epilepsy. A clinical and polygraphic overview of 100 consecutive cases. *Brain* 1999;122(Pt 6):1017–31.
2. Ryvlin P, Rheims S, Risse G. Nocturnal frontal lobe epilepsy. *Epilepsia* 2006;47(Suppl. 2):83–6.
3. Derry CP, Davey M, Johns M, Kron K, Glencross D, Marini C, et al. Distinguishing sleep disorders from seizures: diagnosing bumps in the night. *Arch Neurol* 2006;63:705–9.
4. Zucconi M, Ferini-Strambi L. NREM parasomnias: arousal disorders and differentiation from nocturnal frontal lobe epilepsy. *Clin Neurophysiol* 2000;111(Suppl. 2):S129–35.
5. Gastaut H, Broughton R. Paroxysmal psychological events and certain phases of sleep. *Percept Mot Skills* 1963;17:362.
6. Tassinari CA, Mancina D, Bernardina BD, Gastaut H. Pavor nocturnus of non-epileptic nature in epileptic children. *Electroencephalogr Clin Neurophysiol* 1972;33:603–7.
7. Lugaresi E, Cirignotta F. Hypnogenic paroxysmal dystonia: epileptic seizure or a new syndrome? *Sleep* 1981;4:129–38.
8. Lugaresi E, Cirignotta F, Montagna P. Nocturnal paroxysmal dystonia. *J Neurol Neurosurg Psychiatry* 1986;49:375–80.
9. Nozawa T. Abnormal behavior during sleep—relationships between parasomnias and epilepsy. *J Jpn Epil Soc* 2002;20:3–10.
10. Nozawa T. Diagnosis and treatment in parasomnias. *Clin Electroencephalogr* 2002;44:32–7.
11. Scheffer IE. Autosomal dominant nocturnal frontal lobe epilepsy. *Epilepsia* 2000;41:1059–60.
12. Hirose S, Iwata H, Akiyoshi H, Kobayashi K, Ito M, Wada K, et al. A novel mutation of *CHRNA4* responsible for autosomal dominant nocturnal frontal lobe epilepsy. *Neurology* 1999;53:1749–53.
13. Combi R, Dalpra L, Malcovati M, Oldani A, Tenchini ML, Ferini-Strambi L. Evidence for a fourth locus for autosomal dominant nocturnal frontal lobe epilepsy. *Brain Res Bull* 2004;63:353–9.
14. De Fusco M, Becchetti A, Patrignani A, Annesi G, Gambardella A, Quattrone A, et al. The nicotinic receptor beta 2 subunit is mutant in nocturnal frontal lobe epilepsy. *Nat Genet* 2000;26:275–6.
15. Phillips HA, Favre I, Kirkpatrick M, Zuberi SM, Goudie D, Heron SE, et al. *CHRN2* is the second acetylcholine receptor subunit associated with autosomal dominant nocturnal frontal lobe epilepsy. *Am J Hum Genet* 2001;68:225–31.
16. Steinlein OK, Mulley JC, Propping P, Wallace RH, Phillips HA, Sutherland GR, et al. A missense mutation in the neuronal nicotinic acetylcholine receptor alpha 4 subunit is associated with autosomal dominant nocturnal frontal lobe epilepsy. *Nat Genet* 1995;11:201–3.

## DRAVET SYNDROME

# Mortality in Dravet syndrome: Search for risk factors in Japanese patients

\*<sup>1</sup>Masako Sakauchi, \*<sup>1</sup>Hirokazu Oguni, \*<sup>1</sup>Ikuko Kato, \*<sup>1</sup>Makiko Osawa,  
†<sup>1</sup>Shinichi Hirose, ‡<sup>1</sup>Sunao Kaneko, §<sup>1</sup>Yukitoshi Takahashi,  
§<sup>1</sup>Rumiko Takayama, and §<sup>1</sup>Tateki Fujiwara

\*Department of Pediatrics, Tokyo Women's Medical University, Tokyo, Japan; †Department of Pediatrics, School of Medicine, Fukuoka University, Fukuoka, Japan; ‡Department of Neuropsychiatry, School of Medicine, Hirosaki University, Aomori, Japan; and §National Epilepsy Center, Shizuoka Institute of Epilepsy and Neurological Disorder, Shizuoka, Japan

### SUMMARY

A questionnaire survey was conducted in Japan to investigate the causes and prevalence of death related to Dravet syndrome. The questionnaire was delivered to 246 hospitals at which physicians were treating childhood epilepsy to gain information about the total number of patients with Dravet syndrome and the prevalence of early death due to the disorder. Responses to the survey were collected from 91 hospitals, and a total of 63 of 623 patients with Dravet syndrome had died. Data from 59 of these patients were analyzed. The age at death for these patients ranged from 13 months to 24 years and 11 months, with a median age of 6 years and 8 months. The causes of mortality included sudden death in 31 patients (53%), acute encephalopathy with status epilepticus (SE) in 21 patients (36%), drowning in 6 patients (10%), and

other causes in one patient (1%). The incidence of sudden death reached a first peak at 1–3 years of age and a second peak at 18 years and older. In contrast, the incidence of acute encephalopathy with SE reached a peak at 6 years of age. Seven of the 10 patients who underwent SCN1A mutation analysis exhibited positive mutations but exhibited no consistent phenotype. The prevalence of Dravet syndrome–related mortality was 10.1%. The incidence of sudden death and acute encephalopathy with SE was higher in infancy (1–3 years) and at early school ages (with a peak at 6 years), respectively. Neither the treatment nor the number of seizures was associated with any cause of mortality. Factors leading to a fatal outcome are difficult to predict.

**KEY WORDS:** Dravet syndrome, Severe myoclonic epilepsy in infants, Mortality, Sudden death, Acute encephalopathy.

Among the various types of childhood epilepsy, Dravet syndrome is one of the most malignant epileptic forms (Oguni et al., 2001; Dravet et al., 2005) and exhibits a higher mortality rate. Sudden death from unknown causes and mortality associated with lethal status epilepticus (SE) have been reported, accounting for a percentage that is consistent from author to author (Oguni et al., 2001; Dravet et al., 2005). In addition, unexpected death during the treatment course for this catastrophic disorder may have influenced the reliance of patients' families on physi-

cians (So et al., 2009). Until now, no systematic study has been conducted to clarify the incidence of unexpected death or the prognostic factors associated with the mortality in this disorder. Because Dravet syndrome is relatively rare, an analysis involving a large number of patients in a single hospital is difficult, necessitating a nationwide survey. In this study, we conducted a nationwide questionnaire survey regarding Dravet syndrome–related mortality in Japan and investigated the causes of mortality, the clinical characteristics at the time of death, and the risk factors related to mortality.

<sup>1</sup>Dravet Syndrome Prognosis Research Group.

Address correspondence to Masako Sakauchi, Department of Pediatrics, Tokyo Women's Medical University, Tokyo, Japan. E-mail: sakauchi@ped.twmu.ac.jp

Wiley Periodicals, Inc.

© 2011 International League Against Epilepsy

### METHODS

In July 2009, a questionnaire was delivered to the epilepsy training hospitals that were authorized by the

Japanese Society of Epilepsy, to hospitals/institutions that were authorized to train specialists from the Society of Pediatric Neurology; and to university hospitals (total of 246 hospitals). This survey allowed us to collect information about the total number of past and present patients with Dravet syndrome who had been under care, and of those who died. A secondary questionnaire was sent by mail to the 26 hospitals who reported mortality cases to obtain information on the following items for each patient: (1) gender, (2) age at the onset of epilepsy, (3) clinical type (typical or borderline groups), (4) *SCN1A* gene testing, if any, and the results, (5) age at death, (6) causes of mortality, (7) the presence or absence of risk factors at death, such as fever/infection, bathing, seizures, and the child's state (asleep or awake), (8) frequency of seizures and of SE before death, (9) treatment regimen, (10) neurologic condition, (11) electroencephalographic and neuroimaging findings, and (12) autopsy findings.

Statistical analyses were performed using the SPSS 15.0J for Windows software program (SPSS Japan, Tokyo, Japan). The chi-square test, *t*-test, and Mann-Whitney *U*-test, were employed to compare the results between two variables. A comparison among more than three variables was performed using the chi-square test with cross-tabulation. A *p*-value of <0.05 was regarded as statistically significant.

## RESULTS

### Subjects

Responses were collected from 147 of the 246 hospitals (response rate 59.8%). In 91 of the 147 hospitals, a total of 623 patients with Dravet syndrome had been treated (median 2 patients/hospital; range 1–109/hospital). In addition, data on 63 patients who had died were collected from 26 hospitals (438 patients). For four patients information at the time of death was insufficient. Data on the remaining 59 patients were analyzed.

### Clinical characteristics of patients who died

For the 59 patients who had died, the male-to-female ratio was 26:33. Age at onset of epilepsy ranged from 2–10 months, with a mean of 5.1 months. Of the 59 patients, 20 comprised the borderline group without myoclonic or atypical absence seizures, and 39 comprised the typical group (Fujiwara et al., 2003; Oguni et al., 2005). Seizure frequency before death was daily in 15 patients, weekly in 23 patients, and monthly in 18 patients. The patients who had died were not always those with the most severe manifestations. With regard to the treatment regimen, there were 33 patients who were treated with three antiepileptic drugs, and 23 with more than four drugs. No significant differences were observed between the typical and the borderline groups in term of their clinical characteristics (*p* > 0.05).

### Mortality

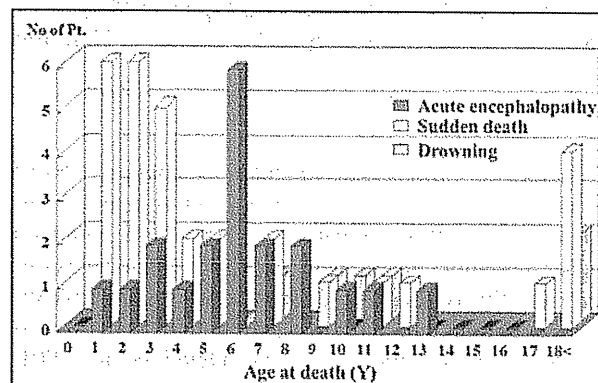
For the 26 hospitals that reported their mortality rates for this nationwide survey, mortality accounted for 14.4% of the patients with Dravet syndrome (63 of 438 patients). When using the 91 hospitals (623 patients) as a denominator population, the mortality rate was 10.1%.

### Causes of mortality and age distribution

The causes of mortality were largely classified into three groups: sudden death (*n* = 31, 53%), acute encephalopathy with SE (*n* = 21, 36%), and drowning (*n* = 6, 10%). The remaining patient died during fulminant hepatitis B (1%). The patients' ages at the time of death ranged from 13 months to 24 years and 11 months, with a median of 80.4 months. When reviewing the age distribution with respect to the causes of mortality, two characteristic patterns were observed (Fig. 1). Briefly, the prevalence of sudden death reached a first peak at 1–3 years of age and a second peak at 18 years of age and older. In contrast, the prevalence of acute encephalopathy with SE reached a peak at 6 years of age.

### Causes of mortality and clinical features

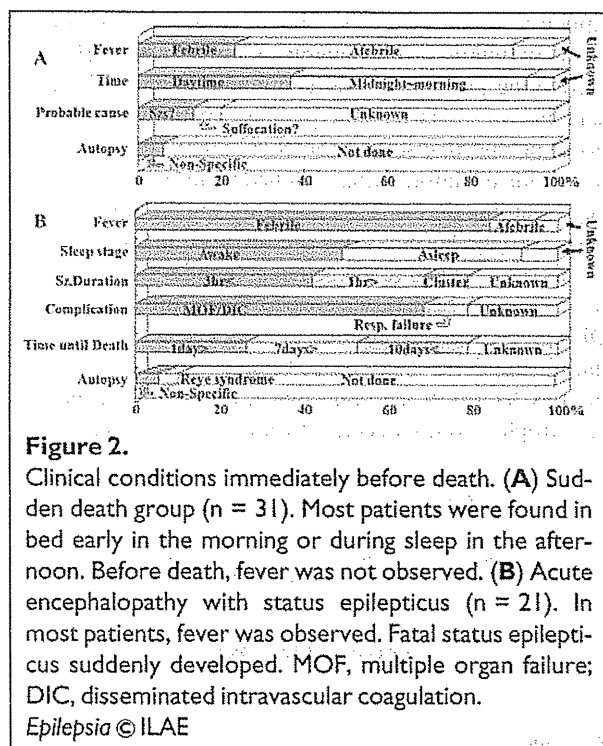
In the sudden death group, the median age at death was 43 months, which was significantly lower than that in the acute encephalopathy group (72 months). These two groups exhibited characteristic age distributions with different peaks (*p* < 0.05), as described earlier. Fever was noted at the time of death in 81% of the patients who died of acute encephalopathy with SE. Fever was also observed in 26% of the patients who died suddenly (*p* < 0.05). The clinical features at death with respect to the causes of



**Figure 1.**

Distribution of ages at death with respect to the causes of mortality. The incidence of sudden death reached a first peak at 1–3 years old and a second peak at 18 years and older. In contrast, the acute encephalopathy-related mortality rate reached a peak at 6 years old.

Epilepsia © ILAE



mortality are shown in Fig. 2. Twenty (65%) and 8 (26%) of the 31 patients in the sudden death group were found to have died during sleep or in the early morning, or during the daytime, respectively. For the remaining three patients, information about the exact time of their deaths was unavailable.

In 6 of the 31 patients in the sudden death group, rigid limbs and trace amounts of vomit suggested that epileptic seizures or suffocation were involved in their deaths. However, an autopsy was not performed for any of these six patients; therefore, no cause of death was specified. In 14 patients (67%) in the acute encephalopathy group, systemic involvement, such as multiple organ failure and disseminated intravascular coagulation (DIC), became evident during or after the successful treatment of SE. Therefore, the clinical response and features of SE differed from those that the children had repeatedly experienced before. This lethal febrile SE developed suddenly at a peak age of 6 years, when the seizure or SE frequency had abated, and led to coma and multiple organ failure despite vigorous treatment. The time interval from the onset of SE to death was 24 h or less in five patients (24%), 1 week or less in six patients (29%), more than 1 week in six patients (29%), and unknown for the remaining four patients (18%).

An autopsy was performed for only 6 (10%) of the 59 patients: one who died suddenly, four who died of acute encephalopathy with SE, and one who died of fulminant hepatitis B. For these six patients, the causes of mortality

were identified as Reye syndrome in two and fulminant hepatitis in one. However, for the remaining four patients, no cause of mortality was identified, despite the autopsy.

In the six patients who died from drowning, accidents occurred while bathing at home or in the hospital. These patients were 7 years old or older, including two patients older than 18 years old; as a result, these patients were able to bathe alone.

### SCN1A mutation analysis

Genetic testing for *SCN1A* mutations was performed for only 10 of the 59 patients. Gene mutations were detected in 7 of these 10 patients. The mutation sites were scattered within the *SCN1A* gene, similar to previous reports. Therefore, no mutation site that was characteristic of mortality was detected (Depienne et al., 2009; Lossin, 2009).

## DISCUSSION

In this nationwide survey, data were collected for 63 patients with Dravet syndrome who died, and data from 59 of these patients were used for the analyses. The causes of mortality were classified into three types: sudden death, acute encephalopathy with SE, and drowning. Sudden death and acute encephalopathy with SE accounted for 53% and 31% of the causes of deaths, respectively. Sudden death occurred most frequently in infancy, and acute encephalopathy with SE in the preschool ages.

Sudden unexpected death in epilepsy (SUDEP) has been reported to account for approximately 2–18% of all epilepsy-related deaths. Therefore, the incidence of SUDEP in Dravet syndrome is higher than expected (Gaitatzis & Sander, 2004; Tomson et al., 2008). During infancy, patients with Dravet syndrome experience recurrent febrile/afebrile SE, despite vigorous antiepileptic drug treatment (Claes et al., 2001; Dravet et al., 2005). In the present study, neither the number of antiepileptic drugs nor the frequency of the seizures was abnormally high immediately before death; however, no control group was established. Most patients with Dravet syndrome who died suddenly were found in bed early in the morning or after sleeping in the afternoon. This result is consistent with common-type SUDEP. Neither electrocardiographic abnormalities nor heart/respiratory dysfunctions have been reported in any children with this disorder. Unfortunately, no study has so far demonstrated any other arrhythmia-associated gene mutations in patients with Dravet syndrome. More work is, therefore, needed to clarify whether the *SCN1A* mutation site is associated with sudden death in Dravet syndrome.

The mortality rate resulting from acute encephalopathy with SE reached a peak at approximately 6 years old, and in these cases, coma or multiple organ failure led to a fatal



outcome despite seizure control. The frequency of SE or of prolonged seizures decreases markedly in children with Dravet syndrome aged over 4 years. Therefore, mortality related to acute encephalopathy with SE at this age is an unexpected event for the families of these patients and for health care professionals (Oguni et al., 2001; Dravet et al., 2005). In Japan, fulminant acute encephalopathy associated with SE in children has recently been identified as a complication of influenza infection. The individual genetic factors that contribute to the susceptibility to acute encephalopathy are suggested to play an important role in the disease pathogenesis (Mizuguchi et al., 2007). For patients with Dravet syndrome, *SCN1A* mutations are related to seizures that are markedly sensitive to elevated temperature. This disorder frequently causes acute encephalopathy; however, the causes for a peak incidence of fatal acute encephalopathy with SE at approximately 6 years old should be clarified.

All of the patients who had accidental deaths drowned while bathing. Drowning-related mortality is avoidable in patients with Dravet syndrome and in patients with other types of epilepsy (Gaitatzis & Sander, 2004). Because seizures that are hypersensitive to elevated body temperature continue through adulthood in most patients with this disorder, the Japanese-style bathing that raises body temperature is a potential risk factor (Oguni et al., 2001). Therefore, it is necessary to train caregivers to be vigilant when such patients take a bath.

The prevalence of mortality in patients with Dravet syndrome has been shown to range from 5–20%, which is markedly higher than in patients with other types of epilepsy (Oguni et al., 2001; Dravet et al., 2005). In the present study, the statistical analyses involving the 91 hospitals showed a mortality rate of 10.1%. The data from the 26 hospitals that reported mortality cases indicated that the mortality rate was 14.4%. However, a limitation of this study was that the survey period differed among the hospitals, leading to difficulty in accurately evaluating the population (as a denominator). Other limitations of this study included a 60% response rate to the questionnaire, retrospective case ascertainment, a very low autopsy rate, and a low incidence of *SCN1A* mutation analyses, all of which lowered the validity of this study. Despite these limitations, the mortality rate would still be estimated to range from 10–15%, which is markedly higher than the rate in patients with other types of epilepsies.

In conclusion, this study identifies the high-risk age periods with respect to the specific causes of mortality; however, no other prognostic factors, including *SCN1A* mutations, could be identified. Since the 1980s, there has been a strong medical/social interest in SUDEP in patients with epilepsy (Nilsson et al., 1999; Gaitatzis & Sander, 2004; Tomson et al., 2008). According to a report that was published by a collaborative special committee of the American Society of Epilepsy and the Foundation of

Epilepsy, future endeavors should emphasize the importance of talking with patients' families about SUDEP, facilitating physicians' and community members' understanding of SUDEP, and planning nationwide/international prospective studies (So et al., 2009). It is necessary to provide the information obtained in this nationwide survey regarding the causes of mortality and the high-risk age periods to the hospitals that are involved in the treatment of this disorder and to the patients' families despite objections that have been raised concerning the difficulty of SUDEP prediction and families' anxiety levels. A worldwide multiinstitutional study needs to be performed to identify the risk factors at the molecular level and to prevent the catastrophic events associated with this syndrome.

## ACKNOWLEDGMENTS

We are grateful to all of the doctors who participated in this nationwide study and who provided clinical data on their patients.

## DISCLOSURE

The authors declare no conflicts of interest.

We confirm that we have read the Journal's position on issues involved in ethical publication and affirm that this report is consistent with those guidelines.

## REFERENCES


- Claes L, Del-Favero J, Ceulemans B, Lagae L, Van Broeckhoven C, De Jonghe P. (2001) De novo mutations in the sodium-channel gene *SCN1A* cause severe myoclonic epilepsy of infancy. *Am J Hum Genet* 68:1327–1332.
- Depienne C, Trouillard O, Saint-Martin C, Gourfinkel-An I, Bouteiller D, Carpentier W, Keren B, Abert B, Gautier A, Baulac S, Arzimanoglou A, Cazeneuve C, Nabbout R, LeGuem E. (2009) Spectrum of *SCN1A* gene mutations associated with Dravet syndrome: analysis of 333 patients. *J Med Genet* 46:183–191.
- Dravet C, Bureau M, Oguni H, Fukuyama Y, Cokar O. (2005) Severe myoclonic epilepsy in infancy (Dravet syndrome). In Roger J, Bureau M, Dravet C, Genton P, Tassinari CA, Wolf P (Eds) *Epileptic syndromes in infancy, childhood and adolescence*. 4th ed. John Libbey Eurotext Ltd., London and Paris, pp. 89–113.
- Fujiwara T, Sugawara T, Mazaki-Miyazaki E, Takahashi Y, Fukushima K, Watanabe M, Hara K, Morikawa T, Yagi K, Yamakawa K, Inoue Y. (2003) Mutations of sodium channel  $\alpha$  subunit type 1 (*SCN1A*) in intractable childhood epilepsies with frequent generalized tonic clonic seizures. *Brain* 126:531–546.
- Gaitatzis A, Sander JW. (2004) The mortality of epilepsy revisited. *Epileptic Disord* 6:3–13.
- Lossin C. (2009) A catalog of *SCN1A* variants. *Brain Dev* 31:114–130.
- Mizuguchi M, Yamanouchi H, Ichiyama T, Shitomi M. (2007) Acute encephalopathy associated with influenza and other viral infections. *Acta Neurol Scand Suppl* 186:45–56.
- Nilsson L, Farahmand BY, Persson PG, Thiblin I, Tomson T. (1999) Risk factors for sudden unexpected death in epilepsy: a case-control study. *Lancet* 353:888–893.
- Oguni H, Hayashi K, Awaya Y, Fukuyama Y, Osawa M. (2001) Severe myoclonic epilepsy in infants—a review based on the Tokyo Women's Medical University series of 84 cases. *Brain Dev* 23:736–748.
- Oguni H, Hayashi K, Osawa M, Awaya Y, Fukuyama Y, Fukuma G, Hirose S, Mitsudome A, Kaneko S (2005) Severe myoclonic epilepsy in infants. Typical and borderline groups in relation to *SCN1A*



- mutations. In Delgado-Escueta V, Guerrini R, Medina MT, Genton P, Bureau M, Dravet C (Eds) *Advances in neurology, vol 95, myoclonic epilepsies*. Lippincott Williams & Wilkins, Philadelphia, pp. 103–117.
- So EL, Bainbridge J, Buchhalter JR, Donalty J, Donner EJ, Finucane A, Graves NM, Hirsch LJ, Montouris GD, Temkin NR, Wiebe S, Sierzant TL. (2009) Report of the American Epilepsy Society and the Epilepsy Foundation joint task force on sudden unexpected death in epilepsy. *Epilepsia* 50:917–922.
- Tomson T, Nashef L, Ryvlin P. (2008) Sudden unexpected death in epilepsy: current knowledge and future directions. *Lancet Neurol* 7:1021–1031.



ELSEVIER

journal homepage: [www.elsevier.com/locate/epilepsyres](http://www.elsevier.com/locate/epilepsyres)

# Callosotomy and subsequent surgery for children with refractory epilepsy

Tomonori Ono<sup>a,\*</sup>, Hiroshi Baba<sup>a</sup>, Keisuke Toda<sup>a</sup>, Kenji Ono<sup>b</sup>

<sup>a</sup> Department of Neurosurgery, National Nagasaki Medical Center, Omura, Nagasaki, Japan

<sup>b</sup> Yokoo Hospital, Isahaya, Nagasaki, Japan

Received 19 November 2010; received in revised form 15 December 2010; accepted 21 December 2010

## KEYWORDS

Epilepsy surgery;  
Generalized seizures;  
Frontal lobe epilepsy;  
Drop attacks;  
Electroencephalography

**Summary** Callosotomy has been considered as a palliative therapy for refractory epilepsy patients with non-focal onset seizures. Residual partial seizures and unilateral epileptiform discharges on electroencephalography (EEG) are sometimes observed after callosotomy. These findings suggest that some patients may be candidates for subsequent resective surgery. Of 149 children who received a callosotomy, resective/disconnective surgery was subsequently performed in 19 patients. Most patients had generalized seizures and epileptiform discharges on EEG before callosotomy. Two-third had normal neuroimaging studies at initial presurgical evaluation. After callosotomy, ictal symptoms evolved into asymmetric features suggesting partial onset seizures. Post-callosotomy EEG showed completely lateralized or localized epileptiform discharges responsible for residual partial seizures in 16 of 19 patients. Fifteen patients underwent resective surgery of the unilateral frontal lobe, and the remaining received hemispherotomy or posterior quadrantectomy. After subsequent surgery, favorable seizure outcomes were obtained in 11 patients (57.9%). Favorable seizure outcomes may be achieved with callosotomy and subsequent surgery in selected patients who are not candidates for a conventional resective surgery at initial presurgical evaluation.

© 2010 Elsevier B.V. All rights reserved.

## Introduction

Callosotomy is considered a palliative therapy for refractory epilepsy without a resectable epileptic focus (Asadi-Pooya et al., 2008). Benefits have been shown for patients with disabling drop attacks, particularly children (Maehara

and Shimizu, 2001; Cross et al., 2006; Sunaga et al., 2009). This procedure has also been used in patients with symptomatic or cryptogenic generalized epilepsy including infantile spasms and Lennox–Gastaut syndrome (Pinar et al., 1999; Cukiert et al., 2006). However, postoperative residual partial seizures are often observed even in patients without generalized seizures (Gates et al., 1987; Spencer et al., 1991). These residual partial seizures may occur more frequently postoperatively (Spencer et al., 1984), but are often milder with a more gradual onset (Baba et al., 1996; Sunaga et al., 2009). In addition, electroencephalography (EEG) often reveals localized/lateralized epileptiform dis-

\* Corresponding author at: Department of Neurosurgery, National Nagasaki Medical Center, 2-1001-1 Kubara, Omura, Nagasaki 856-8562, Japan. Tel.: +81 957523121; fax: +81 957540292.

E-mail address: [tomo@yokoo-hosp.jp](mailto:tomo@yokoo-hosp.jp) (T. Ono).

charges after callosotomy (Spencer et al., 1993; Oguni et al., 1994; Baba et al., 1996; Matsuzaka et al., 1999). These improvements are associated with functions of the corpus callosum in epilepsy, i.e., propagation of focal onset seizures (Spencer et al., 1993; Tanaka et al., 2001) and synchrony and facilitation of epileptogenic activities between hemispheres (Wada and Komai, 1985; Ono et al., 2002; Matsuo et al., 2003). Although there has been controversy whether post-callosotomy residual partial seizures should be regarded as fragments of preoperatively observed generalized seizures or newly developed seizures (Spencer et al., 1984; Gates et al., 1987), those findings may suggest the existence of predominant epileptogenicity in the unilateral hemisphere (Ono et al., 2009).

The above concepts indicate that callosotomy is a diagnostic as well as palliative therapy, and selected patients who undergo this procedure may be candidates for subsequent resective surgery. So far, there have been some case presentations and small studies of this stepwise surgery reporting successful cases (Clarke et al., 2007; Nakayama et al., 2009) or poor results (Silverberg et al., 2010). However, no larger studies have been conducted. The authors' experiences with this stepwise procedure of callosotomy and subsequent resective surgery are discussed in this report.

## Methods

In the Nagasaki Epilepsy Surgery Program, EEG-video monitoring, magnetic resonance imaging (MRI), interictal single photon emission computed tomography (SPECT), and developmental or cognitive tests have been routinely performed as an initial presurgical evaluation for children with refractory epilepsy. Patients with presumed partial epilepsy additionally received ictal SPECT and/or positron emission tomography (PET) if required. Then, resective or hemispheric/multilobar surgery (hemispherotomy or multilobar disconnective surgery) was planned for patients with partial onset epilepsy in whom a resectable focus was identified. Wada test and intracranial EEG (IEEG) study including functional mapping were also performed if possible and needed.

On the other hand, callosotomy was considered when resective surgery was not deemed applicable through the preoperative survey. Typical criterion for consideration of corpus callosotomy were (1) semiology of seizures (e.g., generalized atonic, tonic, tonic-clonic, and myoclonic seizures that were often expressed as drop attacks, epileptic spasms, atypical absence, and complex partial seizures (CPSs) which presumably originated from frontal lobe); (2) no responsible focal abnormality on MRI; (3) bilaterally synchronous or multiple interictal epileptiform discharges; and (4) bilaterally diffuse onset of ictal discharges (e.g., electro-decremental patterns and fast activities on EEGs) (Hanson et al., 2002). Although recent papers suggested the effect of callosotomy on seizures in patient with idiopathic generalized epilepsy (Jenssen et al., 2006; Cukiert et al., 2009), such patients have not been included in our surgical series as yet. Extension of callosal bisection was mainly determined by patient age and by distribution of epileptiform discharges on EEG. Patients less than 10 years old were usually submitted to total callosotomy. This was because total callosotomy was more effective than the partial callosotomy in children with drop attacks (Maehara and Shimizu, 2001), and disconnection syndrome was not obvious in children less than 10 years old (Sauerwein and Lassonde, 1997).

Postoperative clinical evaluations, including EEG-video monitoring, were usually scheduled at 1, 6, and 12 months, and then yearly after callosotomy. Depending on seizure status during the follow-up period, medical treatments were occasionally adjusted. In patients with stereotypical asymmetric seizures or with com-

plex partial seizures suggesting a unilateral epileptogenic focus, examinations were repeated as with the initial presurgical evaluation and subsequent resective surgery was planned if applicable. Subsequent surgery was usually excluded for patients manifesting either multiple types of seizures or bilateral epileptiform activity.

Between 1987 and 2009, 149 children less than 15 years old received a callosotomy through our epilepsy surgery program. Of these, subsequent resective or hemispheric/multilobar surgery was performed in 19 patients (12.8%). Medical records and EEGs of these 19 patients were reviewed. The most recent seizure frequency at the final follow-up point was scored 6–95 months after the final surgery, and postoperative outcome was categorized with Engel's classification (Engel et al., 1993). Classes I and II outcomes were defined as favorable outcomes.

Correlations of some clinical measures or categories with the latest seizure frequency (including favorable or unfavorable outcomes) were statistically tested with Fisher's exact test and the Mann–Whitney *U* test if needed. *P* values of less than 0.05 were considered statistically significant. Multivariate analysis was not feasible due to the lack of sufficient sample size.

Our pediatric epilepsy surgery program and study were approved by National Nagasaki Medical Center Institutional Review Board.

## Results

### Pre-callosotomy status

Details concerning pre-callosotomy status are summarized in Table 1. Initial seizures were generalized tonic seizures in 10 patients, epileptic spasms in 7, atonic seizures in 3, CPSs in 2 and secondarily generalized tonic-clonic seizure (SG) in 3 patients. These seizures had poor lateralizing signs such as asymmetric postures, clonic movements of unilateral limbs, auras or starting from partial motor seizures. Drop attacks due to the above seizures were also seen in 8 patients. Seizures had occurred daily in all patients. Developmental delay or cognitive impairment was revealed in all patients. MRI demonstrated hemispheric cerebral atrophy after meningitis in 2, focal atrophy in the frontal lobe after head injury in 1, cortical dysplasia existing in the bilateral posterior cortex in 1, tuberous sclerosis with multiple and bilateral cortical lesions in 3, and no abnormality in 12 patients. Three patients with unilateral cerebral atrophy had mild or moderate hemiplegia, but they could walk independently. Interictal SPECT exhibited asymmetry in 8 patients: unilateral hypoperfusion in 5 patients (3 with atrophic lesions), and multiple hypo- or hyper-perfused areas in 3 patients with tuberous sclerosis. Bilaterally synchronous epileptiform discharges were observed on EEG in all patients except for 3 patients with hypersarrhythmia or multifocal epileptiform discharges. In 3 patients with unilateral cerebral atrophy, the amplitude of EEG discharges was inversely dominant in the non-affected hemisphere. Ictal EEGs were not focal but instead had a bilaterally diffuse onset pattern in all 19 patients.

Callosotomy was performed to prevent drop attacks and other generalized seizures because a resectable focus could not be identified through preoperative evaluations. Postoperative courses were uneventful, and permanent disconnection syndrome was not observed in any patients.

**Table 1** Patients' status before callosotomy.

PN	Gender	Age at callosotomy	Seizures	MRI	SPECT	IIDs on EEG	Type of callosotomy
1	M	5 m.o.	SP	NL	Symmetric	HYPs	TC
2	F	9 m.o.	TS	BL (TSC)	Asymmetric	MF	TC
3	F	1 y.o.	CPS, TS, SP	BL (TSC)	Asymmetric	MF	TC
4	F	1 y.o.	SP	NL	Symmetric	BS	AC-PC
5	F	1 y.o.	SP	BL (CD)	Asymmetric	HYPs	TC
6	M	1 y.o.	SP	NL	Symmetric	BS	TC
7	F	3 y.o.	SP (DA)	NL	Symmetric	BS	AC
8	F	3 y.o.	SP (DA)	NL	Symmetric	BS	TC
9	M	3 y.o.	AT (DA)	NL	Symmetric	BS	TC
10	F	4 y.o.	TS (DA)	NL	Symmetric	BS	AC-PC
11	M	5 y.o.	TS (DA)	HAL	Asymmetric	BS-CP	TC
12	M	6 y.o.	TS, SG	NL	Symmetric	BS	AC
13	F	7 y.o.	TS (DA)	HAL	Asymmetric	BS-CP	TC
14	M	7 y.o.	AT (DA)	NL	Symmetric	BS	TC
15	M	11 y.o.	TS	NL	Symmetric	BS	AC
16	M	11 y.o.	CPS, SG	FAL	Asymmetric	BS-CP	AC
17	M	11 y.o.	TS	BL (TSC)	Asymmetric	BS	AC
18	F	12 y.o.	AT, TS (DA)	NL	Asymmetric	BS	AC
19	M	13 y.o.	TS, SG	NL	Symmetric	BS	AC

PN, patient number; M, male; F, female; m.o., month-old; y.o, year-old; SP, epileptic spasms; TS, tonic seizures; DA, drop attacks; AT, atonic seizures; SG, secondary generalization; CPSs, complex partial seizures; NL, no lesion; BL, bilateral lesions; TSC, tuberous sclerosis complex; CD, cortical dysplasia; HAL, hemispheric atrophic lesion; FAL, focal atrophic lesion in the frontal lobe; IIDs, interictal epileptiform discharges; HYPs, hypsarrhythmia; BS, bilaterally synchronous IIDs; MF, multi focal IIDs; BS-CP, bilaterally synchronous but contralaterally predominant IIDs; TC, one-staged total callosotomy; AC, anterior callosotomy; PC, posterior callosotomy.

**Table 2** Patients' status after callosotomy.

PN	Seizures	SPECT or PET	IIDs on EEG	Subsequent surgery (interval, month)	IOZ on EEG	Follow-up (month)	Seizure outcome
1	ASP (H&L)	Asymmetric	UH	Hemispherotomy (6)		41	I
2	ATS (H&L)	Asymmetric	MF	RSF (3)		10	III
3	CPS, ATS (H&L)	Asymmetric	MF	RSF (6)		6	I
4	ASP (H&L)	Asymmetric	UF	IEEG/RSF (62)	Extended	41	III
5	ASP (H)	Asymmetric	UP	PQ (10)		21	II
6	ASP (H&L)	Asymmetric	UF	RSF (6)		9	I
7	Subclinical	Asymmetric	UF	IEEG/RSF (55)	Localized	31	I
8	ASP (H&L)	Asymmetric	UF	IEEG/RSF (12)	Extended	34	I
9	AHD (H)	Asymmetric	UF	RSF (33)		10	II
10	ATS (H&L)	Asymmetric	UF	IEEG/RSF (21)	Extended	72	III
11	ASP (H&L)	Asymmetric	UH	Hemispherotomy (11)		59	I
12	ATS (H&L), SG	Symmetric	BF-IP	IEEG/RSF (38)	Extended	46	III
13	ATS (L)	Asymmetric	UH	Hemispherotomy (19)		41	I
14	AHD(H)	Asymmetric	UF	IEEG/RSF (11)	Localized	34	I
15	ATS (H&L)	Asymmetric	UF	IEEG/RSF (95)	Extended	62	III
16	CPS	Asymmetric	UF	IEEG/RSF (13)	Localized	95	I
17	ATS (H&L)	Asymmetric	UF	IEEG/RSF (6)	Extended	21	III
18	ATS (H&L)	Asymmetric	BF-IP	IEEG/RSF (22)	Extended	69	III
19	ATS (H&L), SG	Symmetric	BF-IP	IEEG/RSF (8)	Extended	71	III

PN, patient number; ASP asymmetric epileptic spasms; ATS, asymmetric tonic seizures; AHD, asymmetric head drops; H&L, both head and limbs were ictally involved; H or L, head or limbs were ictally involved, respectively; SG, secondary generalization; CPSs, complex partial seizures; IIDs, interictal epileptiform discharges; UH, unilateral hemispheric IIDs; MF, multi-focal IIDs; UF, unilateral frontal IIDs; UP, unilateral posterior IIDs; BF-IP, bilateral frontal but ipsilaterally predominant IIDs; interval, interval between callosotomy and subsequent surgery; IEEG, intracranial EEG; RSF, resective surgery of the unilateral frontal lobe; PQ, posterior quadrantectomy; IOZ, ictal onset zone; extended, extended to the motor cortex/parietal lobe; localized, localized to the resectable frontal lobe; seizure outcome, Engel's classification.

Please cite this article in press as: Ono, T., et al., Callosotomy and subsequent surgery for children with refractory epilepsy. *Epilepsy Res.* (2011), doi:10.1016/j.eplepsyres.2010.12.011

## Post-callosotomy status

Clinical details concerning post-callosotomy status are summarized in Table 2. Clinical seizures were more or less reduced in frequency but still persisted (almost daily) after callosotomy in 18 patients. However, post-callosotomy residual seizures were transformed into milder seizures and were suspected to be unilateral in onset. Residual seizures were classified as asymmetric tonic seizures in 9 patients, asymmetric epileptic spasms in 6, asymmetric head drops in 2, and CPS without SG in 2 patients. Asymmetric tonic seizures were characterized by sustained posturing of unilateral limbs contralateral to the epileptic focus with or without head/body version. Asymmetric epileptic spasms briefly involved contralateral limbs and usually coincided with neck flexion. Asymmetric head drops were characterized by atonic head falling with ipsilateral deviation. Drop attacks were suppressed in 6 of 8 patients after callosotomy. Two patients had SG with improved duration and severity of seizures (patients 12 and 19). One patient had no obvious clinical seizures, but EEG showed frequent focal ictal discharges in the right frontal region (subclinical discharges, patient 7). In 9 patients, post-callosotomy interictal SPECT or PET revealed new ipsilateral hypo-perfusion/metabolism. Post-callosotomy interictal EEG demonstrated epileptiform discharges unilaterally localized in the frontal region in 10 patients, in the posterior region in 1, diffuse hemispheric discharges in 3, bilateral frontal discharges in 3 and bilaterally multifocal (frontal and temporal) discharges in 2 patients. Ictal EEGs exclusively suggested ipsilateral ictal onset in 17 (frontal region in 13 and hemispheric in 4) patients. Two patients had bilaterally independent frontal seizures (asymmetric tonic seizures and SG), but they predominantly occurred unilaterally. Based on these findings, subsequent resective surgery of the unilateral frontal lobe (RSF,  $n=15$ ) or hemispheric/multilobar disconnective surgery (HMDS,  $n=4$ ) were planned. Intervals between callosotomy and the second surgery ranged from 3 to 95 months. This range was due to additional medication prescribed as therapy for control of residual partial seizures. The reproducibility of seizures and EEG was also confirmed with repeated monitoring by EEG-video for most of the patients.

## Resective surgery of the frontal lobe (RSF)

Eleven of the 15 RSF patients underwent IEEG-video monitoring using implanted subdural electrodes prior to RSF. The ictal onset zone (IOZ) was detected in the frontal lobe in all 11. However, IOZ simultaneously or immediately involved the primary motor cortex, and occasionally the parietal lobe in 9 (extended IOZ). RSF was performed based on ictal IEEG findings. However, functional or anatomical motor- and language-related areas were preserved even if they were encompassed by the IOZ. Resection of the prefrontal cortex guided by intraoperative EEG was performed in the remaining 4 patients because of younger age and clearly localized EEG abnormalities. Two of the 4 patients had an apparent cortical lesion of tuberous sclerosis within the resected area. Postoperative histological examination revealed microdysgenesis in 7 patients with normal MRI.

One patient (patient 11) still had secondary generalized seizures after RSF, and posterior callosotomy was additionally performed 2 years later in order to prevent secondary generalization.

Concerning surgically related complications, epidural empyema requiring surgical evacuation occurred in one patient (patient 17), but no morbidity remained. Postoperative hydrocephalus was seen in another patient (patient 3), and ventricle peritoneal shunting was required 1 month later.

## Hemispheric/multilobar disconnective surgery (HMDS)

Hemispherotomy was performed in 3 patients and posterior quadrantectomy (Daniel et al., 2007) was performed in 1 patient without IEEG-video monitoring. It was determined by neurological conditions and findings from MRI and scalp EEG. Postoperative hydrocephalus was seen in one patient (patient 10), and ventricle peritoneal shunting was required 6 months later.

## Postsurgical evaluation and statistical analysis

At the latest evaluation after the final surgery, freedom from seizures (class I) was accomplished in 9 patients (47.4%), and favorable outcomes (classes I and II) were achieved in 11 patients (57.9%). Anticonvulsants were continued after final surgery in all but one patient (patient 7). In patients who did not achieve favorable seizure control, residual seizures were similar to those post-callosotomy, such as asymmetric tonic seizures and asymmetric epileptic spasms. Independent seizures from the bilateral hemisphere continued in two patients (patients 12 and 19).

Pre-callosotomy factors, such as age at epilepsy onset, duration of epilepsy (not shown in table), age at callosotomy, presence of lesion(s) on MRI and asymmetric perfusion on SPECT, were not correlated with favorable outcomes. With respect to post-callosotomy factors, HMDS yielded more favorable outcomes than RSF, though this difference did not reach statistical significance (HMDS vs. RSF, 100% vs. 46.7%;  $P=0.1$ ). Latency between callosotomy and subsequent surgery and asymmetric finding on PET/SPECT after callosotomy were not significantly correlated with seizure outcome. In patients with submitted RSF, ictal involvement of contralateral limbs and extended IOZ on IEEG were associated with unfavorable outcomes (classes III and IV) ( $P=0.026$  and  $P=0.024$ , respectively).

## Discussion

### Seizure outcome comparing with conventional resective surgery

In this pediatric series, after stepwise surgery consisting of callosotomy and resective surgery, more than half of the patients had no or rare seizures. This result is comparable with previous reports of conventional resective surgery. Favorable surgical outcomes have been reported in 45–85% of patients with extratemporal lobe epilepsy (Wyllie et al.,

1998; Paolicchi et al., 2000; Alarcon et al., 2006; Kim et al., 2008; Zupanc et al., 2010).

Although all 4 patients who underwent subsequent HMDS had favorable outcomes, only 46.7% of patients who received subsequent RSF achieved favorable outcomes in this series. In the previous surgical series of frontal lobe epilepsy, seizure-free and favorable outcomes have been reported in 30–70% and 50–80% of patients (Cascino et al., 1992; Swartz et al., 1998; Ferrier et al., 1999; Jobst et al., 2000; Mosewich et al., 2000; Siegel et al., 2001; Zupanc et al., 2010). Some prognostic factors for unfavorable postoperative outcome were also documented including no focal lesion on MRI (Cascino et al., 1992; Ferrier et al., 1999; Mosewich et al., 2000), histologically proven malformation of cortical development (Jeha et al., 2007), generalized or non-focal ictal onset pattern on preoperative EEG (Jeha et al., 2007), and incomplete resection due to extended electrographic abnormality proximity to the functional cortex (Paolicchi et al., 2000). A majority of patients in the present series who underwent RSF possessed these “unfavorable” findings indicating more extended epileptogenicity (e.g., non-focal ictal onset pattern in all at initial presurgical evaluation; extended IOZ in 8 of 11 patients with IEEG study). However, normal MRI, which was also found in 11 of 15 patients, was not a statistically significant factor for unfavorable outcome in this study.

### Ictal symptoms after callosotomy

Some ictal symptoms after callosotomy may have had an influence on final seizure outcome in patients who underwent RSF.

In frontal lobe epilepsy, there have been reports of successful resective surgery for unilateral tonic posturing seizures and asymmetric epileptic spasms (Janszky et al., 2001; Ramachandran et al., 2008). Similarly, two patients with epileptic spasms involving the contralateral upper limb (patients 6 and 8) and one patient with contralateral tonic posturing following CPS (patient 3) achieved favorable outcome after the subsequent resection. However, most patients who had ictal involvement of the contralateral limb (such as asymmetric epileptic spasms and tonic posturing) had residual seizures after the RSF. Together with IEEG, an extended IOZ might contribute to the ictal symptoms and result in incomplete resection in those patients. Therefore, ictal involvement of the contralateral limb after callosotomy may be a negative predictor for favorable outcomes.

In contrast, all 4 patients without ictal involvement of the contralateral limb achieved favorable outcomes. One had CPS (patient 16), two had asymmetric head drops (patients 9 and 14), and one had only subclinical seizures (patient 7) after callosotomy. CPS in frontal lobe epilepsy usually originates from the medial frontal, orbito-frontal or fronto-polar cortex (Jobst et al., 2000), and is usually resectable.

Asymmetric head drops were characterized by atonic head falling deviating ipsilaterally. The responsible IOZ for this type of seizure is uncertain. Atonic seizures are produced by a sudden reduction of axial muscle tone, and results in head drops and body fall. Generalized atonic seizures are most probably the result of activation of the inhibitory centers in the brain stem mediated by cortical

epileptic discharges and the cortico-reticulo-spinal systems (Noachtar and Peters, 2009). When bilateral epileptogenic hemispheres are synchronously activated (Spencer et al., 1993; Ono et al., 2002), this hypothesis can account for generalized atonic drop attacks before callosotomy. It has also been suggested that drop attacks in partial seizures may be close in mechanism to those seen in generalized seizures (So, 1995). If the connection between the lateralized epileptogenic hemisphere and brain stem persists after callosotomy, unilateral alteration of axial muscular tone and asymmetric head drops may occur. Unfortunately, in patients in the present report, the responsible IOZ for asymmetric head drops could not be clearly revealed by intracranial EEGs. However, it might be possible that unilateral epileptogenic activity in the frontal lobe evoked asymmetric head drops.

### Stepwise procedure for patients with unilateral/bilateral lesions

The present series consisted of three patients with unilateral atrophic lesions who were etiologically suspected to have partial epilepsy. Pre-callosotomy EEGs revealed predominant epileptiform discharges in the non-affected hemisphere, and those in the atrophic hemisphere might have been masked. However, in the case of generalized seizures such as epileptic spasms or tonic seizures, it is difficult to confirm that the atrophic hemisphere is exclusively responsible for the seizures (Andermann et al., 1993).

Wyllie et al. (2007) summarized their large surgical series of pediatric patients with unilateral lesions on MRI and generalized abnormalities on preoperative EEG. Most patients had a congenital or early-acquired lesion. They concluded that hemispherectomy and lobar/multi-lobar resective surgery for the affected hemisphere might be successful for selected patients despite abundant generalized or bilateral epileptiform discharges on EEG. However, residual seizures and generalized or contralateral epileptiform discharges on EEG persisted after surgery in some patients (Wyllie et al., 2007). Hallbook et al. (2010) reported that a majority of their patients with congenital or acquired lesions, who underwent hemispherectomy, had contralateral MRI abnormalities. They also mentioned that seizure-free outcome was less frequent in children with generalized or contralateral epileptiform discharges on postoperative EEG (Hallbook et al., 2010). Thus, it should be considered that those patients had more or less bilateral epileptogenic processes, despite the unilateral nature of the lesions. In the present series, three patients had mild or moderate contralateral hemiparesis, but no focal motor seizures attributable to the affected hemisphere were present. Two patients had tonic seizures frequently causing drop attacks and physical injuries (patients 11 and 13), and the other patient experienced CPS and SG without lateralizing ictal features (patient 16). For such patients, callosotomy could be an initial surgical option, and subsequent surgery may be possible depending on their post-callosotomy seizures. This stepwise procedure can be accurate and safe for these patients.

Callosotomy has been occasionally performed on patients with bilateral lesions (Kawai et al., 2004; Silverberg et al., 2010). Kawai et al. (2004) stated that total callosotomy



is a viable option for the treatment of drop attacks and other seizures in patients with bihemispheric malformation of cortical development. In the present series, 4 patients had bilateral lesions (tuberous sclerosis and cortical dysplasia) and generalized seizures such as epileptic spasms and tonic seizures at initial presurgical evaluation (patients 2, 3, 5 and 17). Their seizures transformed into asymmetric seizures after callosotomy. Favorable outcomes were achieved after the subsequent surgery in one patient. Callosotomy can therefore be considered as a palliative and diagnostic therapy for patients with bilateral lesions and generalized seizures.

### Repetitive surgeries: complications and surgical interval

In this series, two patients had postoperative hydrocephalus after RSF or HMDS, and one had epidural infection after implantation of subdural electrodes and RSF. Although additional surgical treatment was required for these patients, permanent deficits did not persist. These complications are possible after conventional resective surgery and hemispherotomy (Behrens et al., 1997; Limbrick et al., 2009) and not particular to the stepwise procedure described herein.

Although it ranged widely in the present series, a sufficient interval between callosotomy and subsequent surgery should be required for individual patients. A recent paper documented that callosotomy followed by immediate IEEG study and resective surgery did not achieve favorable outcomes, and suggested delayed IEEG (Silverberg et al., 2010). It is important to confirm that the seizures and EEG findings are stereotypical and reproducible after callosotomy. Patients with suspected partial onset seizures after callosotomy should be repeatedly examined with video-EEG.

### Callosotomy for patients excluded from conventional resective surgery

It is important to note that all patients in this series were excluded from conventional resective surgery mainly due to normal MRI and bilateral EEG findings at initial presurgical evaluation. Most reported outcomes after epilepsy surgery have been conducted with treated patients. However, there should be a considerable number of excluded patients. For instance, Wetjen et al. (2009) reported that 50% of MRI-negative extratemporal resections resulted in a favorable postoperative outcome if the patients had focal ictal EEG onset by invasive monitoring. However, that rate dropped to 27.5% if all implanted patients (including patients that were implanted but ultimately had no resection) were considered (Roper, 2009). Although the precise number is not known, some significant number of patients should be excluded from conventional resective surgery in general. Callosotomy is not only a palliative therapy, but also a diagnostic for "buried" patients. Hopefully, callosotomy will result in improved outcomes through subsequent resective surgeries.

### Conflicts of interest

None of the authors has any conflict of interest to disclose.

### Acknowledgements

This study was supported by Health Labor Sciences Research Grant, the Ministry of Health Labor and Welfare of Japan.

### References

- Alarcon, G., Valentin, A., Watt, C., Selway, R.P., Lacruz, M.E., Elwes, R.D., Jarosz, J.M., Honavar, M., Brunhuber, F., Mullatti, N., Bodi, I., Salinas, M., Binnie, C.D., Polkey, C.E., 2006. Is it worth pursuing surgery for epilepsy in patients with normal neuroimaging? *J. Neurol. Neurosurg. Psychiatry* 77, 474–480.
- Andermann, F., Freeman, J.M., Vigeveno, F., Hwang, P.A., 1993. Surgically remediable diffuse hemispheric syndromes. In: Engel Jr., J. (Ed.), *Surgical Treatment of Epilepsies*, second ed. Raven Press, New York, pp. 87–101.
- Asadi-Pooya, A.A., Sharan, A., Nei, M., Sperling, M.R., 2008. Corpus callosotomy. *Epilepsy Behav.* 13, 271–278.
- Baba, H., Ono, K., Matsuzaka, T., Yonekura, M., Teramoto, S., 1996. Surgical results of anterior callosotomy on medically intractable epilepsy. In: Abe, O., Inokuchi, K., Takasaki, K. (Eds.), *XXX World Congress of the International College of Surgeons*. Monduzzi Editore, Bologna, pp. 1131–1135.
- Behrens, E., Schramm, J., Zentner, J., Konig, R., 1997. Surgical and neurological complications in a series of 708 epilepsy surgery procedures. *Neurosurgery* 41, 1–9 (discussion 9–10).
- Cascino, G.D., Jack Jr., C.R., Parisi, J.E., Marsh, W.R., Kelly, P.J., Sharbrough, F.W., Hirschorn, K.A., Trenerry, M.R., 1992. MRI in the presurgical evaluation of patients with frontal lobe epilepsy and children with temporal lobe epilepsy: pathologic correlation and prognostic importance. *Epilepsy Res.* 11, 51–59.
- Clarke, D.F., Wheless, J.W., Chacon, M.M., Breier, J., Koenig, M.K., McManis, M., Castillo, E., Baumgartner, J.E., 2007. Corpus callosotomy: a palliative therapeutic technique may help identify resectable epileptogenic foci. *Seizure* 16, 545–553.
- Cross, J.H., Jayakar, P., Nordli, D., Delalande, O., Duchowny, M., Wieser, H.G., Guerrini, R., Mathern, G.W., 2006. Proposed criteria for referral and evaluation of children for epilepsy surgery: recommendations of the Subcommittee for Pediatric Epilepsy Surgery. *Epilepsia* 47, 952–959.
- Cukiert, A., Burattini, J.A., Mariani, P.P., Camara, R.B., Seda, L., Baldauf, C.M., Argentoni, M., Baise-Zung, C., Forster, C.R., Mello, V.A., 2006. Extended, one-stage callosal section for treatment of refractory secondarily generalized epilepsy in patients with Lennox–Gastaut and Lennox-like syndromes. *Epilepsia* 47, 371–374.
- Cukiert, A., Burattini, J.A., Mariani, P.P., Cukiert, C.M., Argentoni-Baldochi, M., Baise-Zung, C., Forster, C.R., Mello, V.A., 2009. Outcome after extended callosal section in patients with primary idiopathic generalized epilepsy. *Epilepsia* 50, 1377–1380.
- Daniel, R.T., Meagher-Villemure, K., Farmer, J.P., Andermann, F., Villemure, J.G., 2007. Posterior quadrant epilepsy surgery: technical variants, surgical anatomy, and case series. *Epilepsia* 48, 1429–1437.
- Engel Jr., J., Van Ness, P.C., Rasmussen, T.B., Ojemann, L.M., 1993. Outcome with respect to epileptic seizure. In: *Surgical Treatment of the Epilepsies*, second ed. Raven Press, New York, pp. 609–621.
- Ferrier, C.H., Engelsman, J., Alarcon, G., Binnie, C.D., Polkey, C.E., 1999. Prognostic factors in presurgical assessment of frontal lobe epilepsy. *J. Neurol. Neurosurg. Psychiatry* 66, 350–356.
- Gates, J.R., Rosenfeld, W.E., Maxwell, R.E., Lyons, R.E., 1987. Response of multiple seizure types to corpus callosum section. *Epilepsia* 28, 28–34.
- Hallbook, T., Ruggieri, P., Adina, C., Lachhwani, D.K., Gupta, A., Kotagal, P., Bingaman, W.E., Wyllie, E., 2010. Contralateral MRI

Please cite this article in press as: Ono, T., et al., Callosotomy and subsequent surgery for children with refractory epilepsy. *Epilepsy Res.* (2011), doi:10.1016/j.eplepsyres.2010.12.011

- abnormalities in candidates for hemispherectomy for refractory epilepsy. *Epilepsia* 51, 556–563.
- Hanson, R.R., Risinger, M., Maxwell, R., 2002. The ictal EEG as a predictive factor for outcome following corpus callosum section in adults. *Epilepsy Res.* 49, 89–97.
- Janszky, J., Fogarasi, A., Jokeit, H., Ebner, A., 2001. Lateralizing value of unilateral motor and somatosensory manifestations in frontal lobe seizures. *Epilepsy Res.* 43, 125–133.
- Jeha, L.E., Najm, I., Bingaman, W., Dinner, D., Widdess-Walsh, P., Luders, H., 2007. Surgical outcome and prognostic factors of frontal lobe epilepsy surgery. *Brain* 130, 574–584.
- Jenssen, S., Sperling, M.R., Tracy, J.I., Nei, M., Joyce, L., David, G., O'Connor, M., 2006. Corpus callosotomy in refractory idiopathic generalized epilepsy. *Seizure* 15, 621–629.
- Jobst, B.C., Siegel, A.M., Thadani, V.M., Roberts, D.W., Rhodes, H.C., Williamson, P.D., 2000. Intractable seizures of frontal lobe origin: clinical characteristics, localizing signs, and results of surgery. *Epilepsia* 41, 1139–1152.
- Kawai, K., Shimizu, H., Yagishita, A., Maehara, T., Tamagawa, K., 2004. Clinical outcomes after corpus callosotomy in patients with bihemispheric malformations of cortical development. *J. Neurosurg.* 101, 7–15.
- Kim, S.K., Wang, K.C., Hwang, Y.S., Kim, K.J., Chae, J.H., Kim, I.O., Cho, B.K., 2008. Epilepsy surgery in children: outcomes and complications. *J. Neurosurg. Pediatr.* 1, 277–283.
- Limbrick, D.D., Narayan, P., Powers, A.K., Ojemann, J.G., Park, T.S., Bertrand, M., Smyth, M.D., 2009. Hemispherotomy: efficacy and analysis of seizure recurrence. *J. Neurosurg. Pediatr.* 4, 323–332.
- Maehara, T., Shimizu, H., 2001. Surgical outcome of corpus callosotomy in patients with drop attacks. *Epilepsia* 42, 67–71.
- Matsuo, A., Ono, T., Baba, H., Ono, K., 2003. Callosal role in generation of epileptiform discharges: quantitative analysis of EEGs recorded in patients undergoing corpus callosotomy. *Clin. Neurophysiol.* 114, 2165–2171.
- Matsuzaka, T., Ono, K., Baba, H., Matsuo, M., Tanaka, S., Kamimura, N., Tsuji, Y., 1999. Quantitative EEG analyses and surgical outcome after corpus callosotomy. *Epilepsia* 40, 1269–1278.
- Mosewich, R.K., So, E.L., O'Brien, T.J., Cascino, G.D., Shambrough, F.W., Marsh, W.R., Meyer, F.B., Jack, C.R., O'Brien, P.C., 2000. Factors predictive of the outcome of frontal lobe epilepsy surgery. *Epilepsia* 41, 843–849.
- Nakayama, T., Otsuki, T., Kaneko, Y., Nakama, H., Kaido, T., Otsubo, H., Nakagawa, E., Sasaki, M., Sugai, K., 2009. Repeat magnetoencephalography and surgeries to eliminate atonic seizures of non-lesional frontal lobe epilepsy. *Epilepsy Res.* 84, 263–267.
- Noachtar, S., Peters, A.S., 2009. Semiology of epileptic seizures: a critical review. *Epilepsy Behav.* 15, 2–9.
- Oguni, H., Andermann, F., Gotman, J., Olivier, A., 1994. Effect of anterior callosotomy on bilaterally synchronous spike and wave and other EEG discharges. *Epilepsia* 35, 505–513.
- Ono, T., Baba, H., Toda, K., Ono, K., 2009. Hemispheric asymmetry of callosal neuronal participation in bilaterally synchronous epileptiform discharges. *Seizure* 18, 7–13.
- Ono, T., Matsuo, A., Baba, H., Ono, K., 2002. Is a cortical spike discharge “transferred” to the contralateral cortex via the corpus callosum?: an intraoperative observation of electrocorticogram and callosal compound action potentials. *Epilepsia* 43, 1536–1542.
- Paolicchi, J.M., Jayakar, P., Dean, P., Yalçali, I., Morrison, G., Prats, A., Resnik, T., Alvarez, L., Duchowny, M., 2000. Predictors of outcome in pediatric epilepsy surgery. *Neurology* 54, 642–647.
- Pinard, J.M., Delalande, O., Chiron, C., Soufflet, C., Plouin, P., Kim, Y., Dulac, O., 1999. Callosotomy for epilepsy after West syndrome. *Epilepsia* 40, 1727–1734.
- Ramachandranair, R., Ochi, A., Imai, K., Benifla, M., Akiyama, T., Holowka, S., Rutka, J.T., Snead 3rd, O.C., Otsubo, H., 2008. Epileptic spasms in older pediatric patients: MEG and ictal high-frequency oscillations suggest focal-onset seizures in a subset of epileptic spasms. *Epilepsy Res.* 78, 216–224.
- Roper, S.N., 2009. Surgical treatment of the extratemporal epilepsies. *Epilepsia* 50 (Suppl. 8), 69–74.
- Sauerwein, H.C., Lassonde, M., 1997. Neuropsychological alterations after split-brain surgery. *J. Neurosurg. Sci.* 41, 59–66.
- Siegel, A.M., Jobst, B.C., Thadani, V.M., Rhodes, C.H., Lewis, P.J., Roberts, D.W., Williamson, P.D., 2001. Medically intractable, localization-related epilepsy with normal MRI: presurgical evaluation and surgical outcome in 43 patients. *Epilepsia* 42, 883–888.
- Silverberg, A., Parker-Menzer, K., Devinsky, O., Doyle, W., Carlson, C., 2010. Bilateral intracranial electroencephalographic monitoring immediately following corpus callosotomy. *Epilepsia* 51, 2203–2206.
- So, N.K., 1995. Atonic phenomena and partial seizures. A reappraisal. *Adv. Neurol.* 67, 29–39.
- Spencer, S.S., Elguera, E.D., Williamson, P.D., Spencer, D.D., Mattson, R.H., 1991. Evolution of seizure characteristics after callosotomy. *J. Epilepsy* 4, 149–156.
- Spencer, S.S., Spencer, D.D., Glaser, G.H., Williamson, P.D., Mattson, R.H., 1984. More intense focal seizure types after callosal section: the role of inhibition. *Ann. Neurol.* 16, 686–693.
- Spencer, S.S., Spencer, D.D., Sass, K., Westerveld, M., Katz, A., Mattson, R., 1993. Anterior, total, and two-stage corpus callosum section: differential and incremental seizure responses. *Epilepsia* 34, 561–567.
- Sunaga, S., Shimizu, H., Sugano, H., 2009. Long-term follow-up of seizure outcomes after corpus callosotomy. *Seizure* 18, 124–128.
- Swartz, B.E., Delgado-Escueta, A.V., Walsh, G.O., Rich, J.R., Dwan, P.S., DeSalles, A.A., Kaufman, M.H., 1998. Surgical outcomes in pure frontal lobe epilepsy and foci that mimic them. *Epilepsy Res.* 29, 97–108.
- Tanaka, T., Hashizume, K., Sawamura, A., Yoshida, K., Tsuda, H., Hodozuka, A., Nakai, H., 2001. Basic science and epilepsy: experimental epilepsy surgery. *Stereotact. Funct. Neurosurg.* 77, 239–244.
- Wada, J.A., Komai, S., 1985. Effect of anterior two-thirds callosal bisection upon bisymmetrical and bisynchronous generalized convulsions kindled from amygdala in epileptic baboon, *Papio papio*. In: Reeves, A.G. (Ed.), *Epilepsy and the Corpus Callosum*. Raven Press, New York, pp. 243–257.
- Wetjen, N.M., Marsh, W.R., Meyer, F.B., Cascino, G.D., So, E., Britton, J.W., Stead, S.M., Worrell, G.A., 2009. Intracranial electroencephalography seizure onset patterns and surgical outcomes in nonlesional extratemporal epilepsy. *J. Neurosurg.* 110, 1147–1152.
- Wyllie, E., Comair, Y.G., Kotagal, P., Bulacio, J., Bingaman, W., Ruggieri, P., 1998. Seizure outcome after epilepsy surgery in children and adolescents. *Ann. Neurol.* 44, 740–748.
- Wyllie, E., Lachhwani, D.K., Gupta, A., Chirila, A., Cosmo, G., Worley, S., Kotagal, P., Ruggieri, P., Bingaman, W.E., 2007. Successful surgery for epilepsy due to early brain lesions despite generalized EEG findings. *Neurology* 69, 389–397.
- Zupanc, M.L., Rubio, E.J., Werner, R.R., Schwabe, M.J., Mueller, W.M., Lew, S.M., Marcuccilli, C.J., O'Connor, S.E., Chico, M.S., Eggener, K.A., Hecox, K.E., 2010. Epilepsy surgery outcomes: quality of life and seizure control. *Pediatr. Neurol.* 42, 12–20.

Please cite this article in press as: Ono, T., et al., Callosotomy and subsequent surgery for children with refractory epilepsy. *Epilepsy Res.* (2011), doi:10.1016/j.epilepsyres.2010.12.011



