

Table 1. Coagulation disorders in Japan

	Hemophilia		VWD	VWD-related disease	Total
	A	B			
Total	4211	916	892	452	6471
Male	4185	908	406	246	5745
Female	29	8	486	206	726
HIV negative					
Total	3609	733	885	448	5675
Male	3583	725	404	245	4957
Female	26	8	481	203	718
HIV positive					
Total	602	183	7	4	796
Male	602	183	2	1	788
Female	0	0	5	3	8

Source: Official Report of the National Surveillance on Coagulation Disorders in Japan, 2008
HIV, human immunodeficiency virus; VWD, von Willebrand disease

Table 2. Stage of liver disease in patients with hemophilia and HIV infection (only reported surviving cases with HCV coinfection)

	No hepatitis	Acute hepatitis	Chronic hepatitis	Liver cirrhosis	HCC	Liver failure	Cured with IFN	Spontaneous cure	LT	Total
Hemophilia A	45	2	350	33	5	2	59	26	2	524
Hemophilia B	15	1	100	11	6	0	19	8	2	162
Total	60	3	450	44	11	2	78	34	4	686

Source: Official Report of the National Surveillance on Coagulation Disorders in Japan, 2008
HIV, human immunodeficiency virus; HCV, hepatitis C virus; HCC, hepatocellular carcinoma; LT, liver transplantation; IFN, interferon

with cirrhosis may be candidates for liver transplantation in the future. In fact, this survey revealed that one-third of the deaths of HIV-HCV coinfecting patients with blood-borne diseases were caused by liver disease.

A characteristic that should be taken into account when using imported blood products is that the proportion of patients with HCV genotype 1b is low, at 25% vs 70% in general for Japanese, and the proportion of patients with HCV genotype 3a is high, at 23%. Also, one study found that the proportion of patients with HIV-HCV coinfection with an HCV titer below the level of sensitivity of the assay was significantly lower than the proportion of such patients among non-HIV cases of HCV infection, at 44.0% vs 55.4%, respectively.⁷ There have been a few reports from other countries on the problems associated with HCV and HIV infections in hemophiliac patients.^{8,9}

Liver Transplantations in HIV-HCV Coinfected Patients

Indications for Liver Transplantation in Patients with HIV-HCV Coinfection

Regardless of the presence of hemophilia, the indications for and methods of liver transplantation are the

same for patients with HIV-HCV coinfection. Therefore, information on liver transplantation for HIV-HCV coinfecting patients without hemophilia is presented in this section. In fact, after successful liver transplantation, hemophilia can normally be cured. In principle, as for a non-HIV-infected patient, liver transplantation is indicated for patients with type C cirrhosis in liver failure and no expectation of a long-term prognosis.¹⁰⁻¹⁴ Liver transplantation is also indicated for patients not yet in liver failure, but with severe liver damage caused by HAART, especially those with chronic hepatitis C, who need to suspend or stop HAART.¹⁵⁻¹⁸ For patients receiving HAART, the indication needs to be considered in terms of both hepatic reserve and status of the HIV infection. Liver transplantation may also be indicated for hepatocellular carcinoma that develops during follow-up.¹⁹ The conditions for liver transplantation are often defined as follows: AIDS symptoms have not surfaced; the CD4+ lymphocyte count is 200-250/ μ l or above; and as a result of HAART, the amount of HIV in the blood is below the level of sensitivity of the assay. However, there are cases of pancytopenia resulting from portal hypertension and, as such, some institutions believe that the criterion for liver transplantation resolved be a CD4+ lymphocyte count of 100/ μ l or more.¹⁹⁻²² Therefore, an issue to be resolved is whether

the indication can be based solely on a CD4+ lymphocyte count. Although a ratio of CD4 to CD8 lymphocyte count of 14% or greater is also considered an indication, individual institutions still refer to their own criteria. A recent study found a significant correlation between the preoperative model for end-stage liver disease (MELD) score and the postoperative survival rates of HIV-HCV coinfecting patients: this also warrants investigation.²³

Results of Liver Transplantation for Patients with HIV-HCV Coinfection

Liver transplantation from deceased donors has been performed in HIV patients since the 1980s in the United States and Europe. Initially the results were poor, with survival rates of only about 47%,²⁴ but this has improved remarkably since the introduction of HAART (Table 3). According to a review article published in 2004, 51 HIV-positive patients received liver transplantation between 1996 and 2004 worldwide, with liver damage caused by HCV being the indication in 68%. Since 1997, liver transplantation has been performed in 29 HIV patients at the University of Pittsburgh: 26% of these patients were hemophiliac and 89% were HCV-positive.²⁵ According to a retrospective study by the United Network for Organ Sharing, involving 138 HIV-positive persons and 30520 HIV-negative persons and evaluating liver transplantation, from 1997 when HAART was introduced and thereafter, the prognosis of patients who were only HIV-positive was relatively good.²⁶ In this study, the prognosis of HIV-HCV coinfecting patients was worse than that of patients who were positive only for HIV. A series of reports are listed in Table 3.^{13,20,21,25-34} In reality, in addition to those listed there have been many sporadic reports, such as reviews, regarding expectations for liver transplantation, and assessments of indications.

A recent important study in France, on 14 patients, provided details on interferons, HAART therapy, and liver fibrosis.³³ In all patients, the preoperative amount of HIV in the blood was below the level of sensitivity, and the CD4+ T-cell counts ranged from 85 to 1015. As for calcineurin inhibitors, tacrolimus 0.5 mg per week was started in the 2nd week after surgery in principle; however, there were five cases (36%) of an overdose. HAART was recommenced in the 2nd week after surgery, resulting in the long-term administration of steroids. Liver biopsies in the 12th month after liver transplantation revealed one case of fibrosing cholestatic hepatitis (FCH), one case of fibrosis stage F3, two cases of F2, and five cases of F1. The prognosis after transplantation was thought to be encouraging, since there was only one death as a result of FCH in the series.

Living Donor Liver Transplantation for Patients with HIV-HCV Coinfection

The Koike Group of the Ministry of Health, Labour, and Welfare reported seven cases of living donor liver transplantation (LDLT) for HIV-HCV coinfecting patients with hemophilia at The University of Tokyo, and one at Hiroshima University.^{35,36} The HCV genotypes were 1a and 1b ($n = 1$), 1b and 3a ($n = 1$), 2a ($n = 1$), 2a and 2b ($n = 1$), and 3a and 1b ($n = 1$). The HCV-RNA levels ranged from 2.8 to 1410 kIU/ml, the HIV-RNA levels in two cases were 50 copies/ml or less, being below the sensitivity level, and the CD4+ T-cell counts ranged from 120 to 618/ μ l and were 250/ μ l or less in two cases. At the time of the report in 2005, four patients were alive. Small bowel bleeding (suspected cytomegalovirus enteritis) and graft dysfunction were cited as the causes of death of the nonsurviving patients. Interestingly, interferon therapy was given after surgery to the surviving patients, whereas it was suspended in the two patients who died. HAART therapy was not given to one patient on the grounds that the HIV virus disappeared as the interferon treatment progressed. The report stated that the administration of factor 8 products was never required after surgery for patient #1.

Living donor liver transplantation from a hemophilia carrier was reported in 2002,³⁷ and it seems that LDLT has been performed in up to 10 patients in Japan. As noted in the section on epidemiology, there are some 50 patients coinfecting with HIV-HCV from blood products, in whom liver failure has developed. They, like other patients with chronic hepatitis, may be candidates for liver transplantation, so it is necessary to collect sufficient information.

Problems with Liver Transplantation in HIV-HCV Coinfecting Patients with Hemophilia

The Blood Concentration of the Calcineurin Inhibitor Used in Combination with HAART Is Increased

The risk of opportunistic infections caused by a delay in starting HAART and the appropriate time to start HAART has not been established. Moreover, early initiation of the therapy is associated with a high risk of drug-induced liver damage.^{38,39} A new drug, Raltegravir, does not interfere with the metabolism of the calcineurin inhibitor, and might reduce the chance of overshooting the trough level of the calcineurin inhibitor.⁴⁰

Progression of HCV Recurrence Is Accelerated in These Patients Compared with Those Who Are Only HIV-Positive⁴¹

The HIV virus population dynamics manifest via the immune systems, which are targeted by antiviral drugs such as interferon and ribavirin as well as the HAART

Table 3. Reported series of liver transplantation for patients with HIV infection

First author, year, institution (Journal ^{Ref.})		<i>n</i>	Survival	Findings
Ragni, 2003, Pittsburgh (J Infect Dis ²⁷)	HIV only	24	3-Year 72.8%	Risk factor for mortality after LT CD4+ <200/μl, HAART resume not possible HIV viral load >400 copies/ml
	HIV+HCV	15	3-Year 56.9%	
Neff, 2003, Pittsburgh (Liver Transpl ²⁸)	HIV positive	16	14/16	2 HAART discontinued due to liver damage 13/16 HIV negative before LT CD4+ <200/μl (6/16), <100/μl (2/16) ACR (6/16). FK trough level increased (6/16) 68% HCV coinfection, 26% hemophilia
Fung, 2004, Review (Liver Transpl ²⁵)	HIV positive (total)	51	80%	
Norris, 2004, London (Liver Transpl ²⁹)	HIV+HCV	29	20/29	4 HCV recurrence, died with sepsis HBV no recurrence
	HIV only	7	7/7	
Moreno, 2005, Madrid (Liver Transpl ³⁰)	HIV+HCV	4	3/4	1 died with FCH 17 months after LT CD4+ <100/μl (2/16) ACR (1/4), no opportunistic infection 2 survived case on HAART
Radecke, 2005, Essen (Liver Int ³¹)	HIV+HCV	5	2/5	
Miró, 2007, Barcelona (J HIV Ther ¹¹)	HIV+HCV	Review (<i>n</i> > 200)	1-Year 50%–55% (without LT)	Indication for LT: CD4+ >100/μl, HIV negative
Schreibman, 2007, Miami (Transplantation ²⁰)	HIV positive	15	3-Year 73.3%	SVR rate (post LT) 15%–20% Infectious complication 26.7% vs 8.7% (<i>P</i> = 0.006)
	HIV negative	857	3-Year 79.4%	Indication for LT: CD4+ >100/μl, HIV <200 copies/mm ³
Reiberger, 2008, Vienna (Eur J Clin Invest ³²)	HIV+HCV (post)	31		HCV viral load increased on immunosuppression IFN effective if CD4+ preserved SVR rate: HIV–HCV (post LT) 28%
	HIV+HCV (pre)	20		
	HCV only (pre)	25		
	HIV+HCV (post LT) 50%, HCV only (post LT) 56%			
Mindikoglu, 2008, UNOS (Transplantation ²⁶)	HIV positive	138	2-Year 70%, 3-year 66%	All after HAART era, HCV+ poor prognostic factor
	HIV+HCV	58	2-Year 52%	
	HIV negative	520	2-Year 81%, 3-year 77%	
Duclos-Vallée, 2008, France (THEVIC study group) (Hepatology ²¹)	HIV+HCV	35	2-Year 73%, 5-year 51%	Pre LT MELD score most important factor for mortality HIV coinfection: fibrosis progression (>F2) quicker LT indication: CD4+ > 100/μl, HIV negative LT indication: HIV negative, no AIDS
	HCV only	44	2-Year 91%, 5-year 81%	
Samri, 2009, France (multicenter) (J Hepatol ³³)	HIV+HCV	14	2-Year 93%	FK and HAART resumed 2 weeks after LT, FK overdose 5/14 (36%) 1 FCH died. 1-year F2 2, F3 1, F4 (FCH) 2 Patient survival, HCV recurrence, FCH not different (<i>P</i> = 0.09) from LT for patients without HIV
Testillano, 2009, Bilbao (Transplant Proc ³⁴)	HIV+HCV	12	3-Year 62%	
	HCV only	59	3-Year 84%	

.HIV, human immunodeficiency virus; HCV, hepatitis C virus; HBV, hepatitis B virus; HAART, highly active antiretroviral therapy; FCH, fibrosing cholestatic hepatitis; LT, liver transplantation; ACR, acute cellular rejection; SVR, sustained virological response; IFN, interferon; UNOS, United Network for Organ Sharing; MELD, model for end-stage liver disease; FK, tacrolimus

drugs.^{42–45} The best time to start interferon treatment and other post-transplantation measures to prevent HCV, optimal immunosuppressive regimens, and ways of monitoring drug blood levels are being studied, and further reports are expected.^{46–51}

According to a review on the effects of interferon treatment after liver transplantation, the SVR rate ranges from 0% to 50%. This article reported that there had been many side effects in HIV-positive patients, especially caused by anemia and a low white blood cell

count, and that the continuation of treatment for such patients had been made possible by administration of the growth factor.⁵²

Some Studies Refer to the Correlation Between T-Cell Counts and Acute Rejection

In practice, some studies showed the rate of acute cellular rejection to be similar, regardless of HIV positivity.^{11,53} Induction therapy without steroids has also been attempted,⁵⁴ and the rate of opportunistic infection is reported to be similar after organ transplantation in HIV-positive patients.²⁰ Thus, the number of CD4+ lymphocytes present prior to liver transplantation is an important factor.

*HAART Drugs Can Cause Hepatic Toxicity*⁵⁵

If HAART drugs induce liver failure, the best HAART drug to use after liver transplantation must be selected carefully. HAART drug toxicity can also induce complications with acute cellular rejection or other hepatic problems after liver transplantation. A liver biopsy may be needed to elucidate the real cause. Noncirrhotic portal hypertension has recently been reported in HIV-positive patients. HAART drugs may be related to those unresolved pathogenesises.⁵⁶

The Control of Infection After Liver Transplantation for HIV–HCV Coinfection Is Based on the Count of CD4+ Lymphocytes Obtained During the Perioperative Period

Therefore, the timing of recommencement of the HAART drug and the preoperative CD4+ lymphocytes counts are both important factors. According to previous reports, prophylaxis against bacterial and viral infections seems to be the same as for liver transplantation without HIV infection.²⁰

The Presence of Hemophilia Makes It Difficult to Manage the Coagulation Time and Control Bleeding During the Intra- and Postoperative Period Before a Transplanted Liver Starts to Function

Moreover, when considering LDLT and when only carrier-donors exist, an assessment of the risks associated with the resection of the carrier-donor's liver would also be a problem.³⁷

Conclusions

This review is an overview of liver transplantation performed to date for HIV–HCV coinfecting persons. Although there have been no cadaveric liver transplantations for these patients in Japan,⁵⁷ conventional knowledge about cadaveric liver transplantation may be

applicable in most cases, despite the unresolved problems. In light of the fact that most of these Japanese patients are the victims of contaminated blood products, we believe that the number of liver transplantations will increase, in the context of medical relief.⁵⁸

Acknowledgment. This work was supported in part by a Grant-in-Aid for Research on HIV/AIDS from the Ministry of Health, Labour and Welfare of Japan.

References

1. Annual report on patients with AIDS. Program entrusted by Ministry of Health, Labour and Welfare, Japan. 2005.
2. Annual report on patients with AIDS. Program entrusted by Ministry of Health, Labour and Welfare, Japan. 2008.
3. Valdez H, Chowdhry TK, Asaad R, Woolley II, Davis T, Davidson R, et al. Changing spectrum of mortality due to human immunodeficiency virus: analysis of 260 deaths during 1995–1999. *Clin Infect Dis* 2001;32:1487–93.
4. del Amo J, Hernández-Aguado I, Pérez-Hoyos S. Effect of antiviral therapy on liver-related mortality in patients with HIV and hepatitis C virus coinfection. *Lancet* 2003;362:1708–13.
5. Pineda JA, Romero-Gómez M, Díaz-García F, Giron-Gonzalez JA, Montero JL, Torre-Cisneros J, et al. HIV coinfection shortens the survival of patients with hepatitis C virus-related decompensated cirrhosis. *Hepatology* 2005;41:779–89.
6. Japan Foundation for AIDS Prevention. Official report of the national surveillance on coagulation disorders in Japan 2008.
7. Thomas DL. The challenge of hepatitis C in the HIV-infected person. *Annu Rev Med* 2008;59:473–85.
8. Rumi MG, De Filippi F, Santagostino E, Colombo M. Hepatitis C in haemophilia: lights and shadows. *Haemophilia* 2004;suppl 4:211–5.
9. Wilde JT. HIV and HCV coinfection in haemophilia. *Haemophilia* 2004;10:1–8.
10. Kumar R, Singla V, Kacharya S. Impact and management of hepatitis B and hepatitis C virus co-infection in HIV patients. *Trop Gastroenterol* 2008;29:136–47.
11. Miro JM, Aguero F, Laguno M, Tuset M, Cervera C, Moreno A, et al. Liver transplantation in HIV/hepatitis co-infection. Hospital Clinic OLT in HIV Working Group. *J HIV Ther* 2007;12:24–35.
12. Castells L, Escartín A, Bilbao I, Len O, Allende H, Vargas V, et al. Liver transplantation in HIV–HCV coinfecting patients: a case-control study. *Transplantation* 2007;83:354–8.
13. Miró JM, Laguno M, Moreno A, Rimola A; Hospital Clinic OLT in HIV Working Group. Management of end stage liver disease (ESLD): what is the current role of orthotopic liver transplantation (OLT)? *J Hepatol* 2006;44(1 suppl):S140–5.
14. Ragni MV, Eghtesad B, Schlesinger KW, Dvorchik I, Fung JJ. Pretransplant survival is shorter in HIV-positive than HIV-negative subjects with end-stage liver disease. *Liver Transpl* 2005;11:1425–30.
15. Antoniadis C, Macdonald C, Knisely A, Taylor C, Norris S. Mitochondrial toxicity associated with HAART following liver transplantation in an HIV-infected recipient. *Liver Transpl* 2004;10:699–702.
16. Bonacini M. Liver injury during highly active antiretroviral therapy: the effect of hepatitis C coinfection. *Clin Infect Dis* 2004;38 suppl 2:S104–8.
17. Duclos-Vallée JC, Vittecoq D, Teicher E, Feray C, Roque-Afonso AM, Lombres A, et al. Hepatitis C virus viral recurrence and liver mitochondrial damage after liver transplantation in HIV–HCV co-infected patients. *Hepatology* 2005;42:341–9.
18. Polard E, Camus C, Abault AY, Turlin B, Arvieux C, Messner M, et al. Retransplantation for acute liver failure due to combined

- antiviral agents in an HIV-HCV coinfecting liver transplant recipient. *Transplantation* 2005;80:1136–8.
19. Di Benedetto F, De Ruvo N, Berretta M, Masetti M, Montalti R, DiSandro S, et al. Hepatocellular carcinoma in HIV patients treated by liver transplantation. *Eur J Surg Oncol* 2008;34:422–7.
 20. Schreiber I, Gaynor JJ, Jayaweera D, Pyrsopoulos N, Weppler D, Tzakis A, et al. Outcomes after orthotopic liver transplantation in 15 HIV-infected patients. *Transplantation* 2007;84:697–705.
 21. Duclos-Vallée JC, Féray C, Sebah M, Teicher E, Roque-Afonso A, Roche B, et al. THEVIC Study Group. Survival and recurrence of hepatitis C after liver transplantation in patients coinfecting with human immunodeficiency virus and hepatitis C virus. *Hepatology* 2008;47:407–17.
 22. Maida I, Núñez M, González-Lahoz J, Soriano V. Liver transplantation in HIV-HCV coinfecting candidates: what is the most appropriate time for evaluation? *AIDS Res Hum Retroviruses* 2005;21:599–601.
 23. Subramanian A, Sulkowski M, Barin B, Stablein D, Curry M, Nissen N, et al. MELD score is an important predictor of pretransplantation mortality in HIV-infected liver transplant candidates. *Gastroenterology* 2010;138:159–64.
 24. Tzakis AG, Cooper MH, Dummer JS, Rangl M, Ward JW, Startzl TE. Transplantation in HIV+ patients. *Transplantation* 1990;49:354–8.
 25. Fung JJ, Eghtesad B, Patel-Tom K, De Vera M, Chapman H, Ragni M. Liver transplantation in patients with HIV infection. *Liver Transpl* 2004;10(10 suppl 2):S39–53.
 26. Mindikoglu AL, Regev A, Magder LS. Impact of human immunodeficiency virus on survival after liver transplantation: analysis of United Network for Organ Sharing database. *Transplantation* 2008;85:359–68.
 27. Ragni MV, Belle SH, Im KA, Neff G, Roland M, Stock P, et al. Survival of human immunodeficiency virus-infected liver transplant recipients. *J Infect Dis* 2003;188:1412–20.
 28. Neff GW, Bonham A, Tzakis AG, Ragni M, Jayaweera D, Schiff ER, et al. Orthotopic liver transplantation in patients with human immunodeficiency virus and end-stage liver disease. *Liver Transpl* 2003;9:239–47.
 29. Norris S, Taylor C, Muiesan P, Portmann BC, Knisely AS, Bowles M, et al. Outcomes of liver transplantation in HIV-infected individuals: the impact of HCV and HBV infection. *Liver Transpl* 2004;10:1271–8.
 30. Moreno S, Fortún J, Quereda C, Moreno A, Perez-Elias MJ, Martín-Davila P, et al. Liver transplantation in HIV-infected recipients. *Liver Transpl* 2005;11:76–81.
 31. Radecke K, Frühauf NR, Miller M, Ross B, Köditz R, Malagó M, et al. Outcome after orthotopic liver transplantation in five HIV-infected patients with virus hepatitis-induced cirrhosis. *Liver Int* 2005;25:101–8.
 32. Reiberger T, Rasoul-Rockenschaub S, Rieger A, Ferenci P, Gangl A, Peck-Radosavljevic M. Efficacy of interferon in immunocompromised HCV patients after liver transplantation or with HIV co-infection. *Eur J Clin Invest* 2008;38:421–9.
 33. Samri A, Roque-Afonso AM, Beran O, Tateo M, Teicher E, Féray C, et al. Preservation of immune function and anti-hepatitis C virus (HCV) immune responses after liver transplantation in HIV-HCV coinfecting patients (ANRS-HC08 “THEVIC” trial). *J Hepatol* 2009;51:1000–9.
 34. Testillano M, Fernandez JR, Suarez MJ, Gastaca M, Bustamante J, Pijoan JI, et al. Survival and hepatitis C virus recurrence after liver transplantation in HIV- and hepatitis C virus-coinfecting patients: experience in a single center. *Transpl Proc* 2009;41:1041–3.
 35. Treatment guideline for patients with HIV-HCV co-infection. Project (Program) entrusted by Ministry of Health, Labour And Welfare, Japan (Study on hepatic diseases combined to HIV infection). 2005.
 36. Sugawara Y, Ohkubo T, Makuuchi M, Kimura S, Tachikawa N. Living-donor liver transplantation in an HIV-positive patient with hemophilia. *Transplantation* 2002;74:1655–6.
 37. Horita K, Matsunami H, Shimizu Y, Shimizu A, Kurimoto M, Suzuki K, et al. Treatment of a patient with hemophilia A and hepatitis C virus-related cirrhosis by living-related liver transplantation from an obligate carrier donor. *Transplantation* 2002;73:1909–12.
 38. Teicher E, Abbara C, Duclos-Vallée JC, Antonini T, Bonhomme-Faivre L, Desbois D, et al. Enfuvirtide: safe and effective antiretroviral agent for human immunodeficiency virus-infected patients shortly after liver transplantation. *Liver Transpl* 2009;15:1336–42.
 39. Graham CS, Baden LR, Yu E, Mrus JM, Carnie J, Heeren T, et al. Influence of human immunodeficiency virus infection on the course of hepatitis C virus infection: a meta-analysis. *Clin Infect Dis* 2001;33:562–9.
 40. Tricot L, Teicher E, Peytavin G, Zucman D, Conti F, Calmus Y, et al. Safety and efficacy of raltegravir in HIV-infected transplant patients cotreated with immunosuppressive drugs. *Am J Transplant* 2009;9:1946–52.
 41. Benhamou Y, Bochet M, Di Martino V, Charlotte F, Azria F, Coutellier A, et al. Liver fibrosis progression in human immunodeficiency virus and hepatitis C virus coinfecting patients. The Multivirc Group. *Hepatology* 1999;30:1054–8.
 42. Lavuer GM, Lucas M, Timm J, Ouchi K, Kim AY, Day CL, et al. Full-breadth analysis of CD8+ T-cell responses in acute hepatitis C virus infection and early therapy. *J Virol* 2005;79:12979–88.
 43. Berenguer J, Alvarez-Pellicer J, Martín PM, Lopez-Aldeguer J, von-Wichmann MA, Quereda C, et al. Sustained virological response to interferon plus ribavirin reduces liver-related complications and mortality in patients coinfecting with human immunodeficiency virus and hepatitis C virus. *Hepatology* 2009;50:407–13.
 44. Weis N, Lindhardt BO, Kronborg G, Hansen AB, Laursen AL, Christensen PB, et al. Impact of hepatitis C virus coinfection on response to highly active antiretroviral therapy and outcome in HIV-infected individuals: a nationwide cohort study. *Clin Infect Dis* 2006;42:1481–7.
 45. Ciuffreda D, Comte D, Cavassini M, Giostra E, Buhler L, Perruchoud M, et al. Polyfunctional HCV-specific T-cell responses are associated with effective control of HCV replication. *Eur J Immunol* 2008;38:2665–77.
 46. Reiberger T, Rasoul-Rockenschaub S, Rieger A, Ferenci P, Gangl A, Peck-Radosavljevic M. Efficacy of interferon in immunocompromised HCV patients after liver transplantation or with HIV co-infection. *Eur J Clin Invest* 2008;38:421–9.
 47. Castells L, Esteban JI, Bilbao I, Vargas V, Allende H, Ribera E, et al. Early antiviral treatment of hepatitis C virus recurrence after liver transplantation in HIV-infected patients. *Antivir Ther* 2006;11:1061–70.
 48. Moreno A, Bárcena R, García-Garzón S, Muriel A, Quereda C, Moreno L, et al. HCV clearance and treatment outcome in genotype 1 HCV-monoinfected, HIV-coinfecting and liver transplanted patients on peg-IFN-alpha-2b/ribavirin. *Hepatology* 2005;43:783–90.
 49. Gruber SA, Doshi MD, Cincotta E, Brown KL, Singh A, Morawski K, et al. Preliminary experience with renal transplantation in HIV+ recipients: low acute rejection and infection rates. *Transplantation* 2008;86:269–74.
 50. Rafecas A, Rufi G, Figueras J, Fabregat J, Xiol X, Ramos E, et al. Liver transplantation without steroid induction in HIV-infected patients. *Liver Transpl* 2004;10:1320–3.
 51. Guaraldi G, Cocchi S, Codeluppi M, Di Benedetto F, Bonora S, Pecorari M, et al. Role of therapeutic drug monitoring in a patient with human immunodeficiency virus infection and end-stage liver disease undergoing orthotopic liver transplantation. *Transplant Proc* 2005;37:2609–10.

52. Fredrick RT, Hassanein TI. Role of growth factors in the treatment of patients with HIV/HCV coinfection and patients with recurrent hepatitis C following liver transplantation. *J Clin Gastroenterol* 2005;39(1 suppl):S14–22.
53. Gruber SA, Doshi MD, Cincotta E, Brown KL, Singh A, Morawski K, et al. Preliminary experience with renal transplantation in HIV+ recipients: low acute rejection and infection rates. *Transplantation* 2008;86:269–74.
54. Tan HP, Kaczorowski DJ, Basu A, Khan A, McCauley J, Marcos A, et al. Living-related donor renal transplantation in HIV+ recipients using alemtuzumab preconditioning and steroid-free tacrolimus monotherapy: a single center preliminary experience. *Transplantation* 2004;78:1683–8.
55. Turkova A, Ball C, Gilmour-White S, Rela M, Mieli-Vergani G. A paediatric case of acute liver failure associated with efavirenz-based highly active antiretroviral therapy and effective use of raltegravir in combination antiretroviral treatment after liver transplantation. *J Antimicrob Chemother* 2009;63:623–5.
56. Mendizabal M, Craviotto S, Chen T, Silva MO, Reddy KR. Noncirrhotic portal hypertension: another cause of liver disease in HIV patients. *Ann Hepatol* 2009;8:390–5.
57. Yoshimura N, Okajima H, Ushigome H, Sakamoto S, Fujiki M, Okamoto M. Current status of organ transplantation in Japan and worldwide. *Surg Today* 2010;40:514–25.
58. Joshi D, O'Grady J, Dieterich D, Gazzard B, Agarwal K. Increasing burden of liver disease in patients with HIV infection. *Lancet* 2011;377:1198–209.

How to Do It

Living Donor Liver Transplantation with Extensive Caval Thrombectomy for Acute-on-Chronic Budd–Chiari Syndrome

AKIHIKO SOYAMA¹, SUSUMU EGUCHI¹, KATSUHIKO YANAGA², MITSUHISA TAKATSUKI¹, MASAOKI HIDAKA¹, and TAKASHI KANEMATSU¹

¹Department of Surgery, Nagasaki University Graduate School of Biomedical Sciences, 1-7-1 Sakamoto, Nagasaki 852-8501, Japan

²Department of Surgery, Jikei University School of Medicine, Tokyo, Japan

Abstract

The key consideration when performing living donor liver transplantation (LDLT) in patients with Budd–Chiari syndrome (BCS) is careful management of a stenotic or occluded inferior vena cava (IVC), because it is not possible to replace the recipient stenotic or occluded IVC with donor IVC as in cadaver donor transplantation. We describe how we performed LDLT with extensive thrombectomy in a patient with acute-on-chronic BCS with a totally thrombosed retrohepatic IVC. The operation was successful and the patient remains well, with follow-up images showing a patent IVC and hepatic veins. To our knowledge, LDLT for a BCS patient with severe extensive caval thrombus has never been reported before. We consider that the successful outcome of this patient clearly demonstrates the feasibility of our technique of extensive thrombectomy, without a vessel graft, to manage a stenotic or occluded IVC in LDLT in patients with BCS.

Key words Living donor liver transplantation · Budd–Chiari syndrome · Thrombectomy · Cavoplasty

Introduction

Liver transplantation is ultimately the treatment of choice for patients with Budd–Chiari syndrome (BCS), especially those with fulminant forms of BCS, those with established cirrhosis or frank fibrosis, and those with defined hepatic metabolic defects such as protein C or protein S deficiency.¹ The safety and efficacy of liver transplantation for patients with BCS has been

confirmed by a multicenter study conducted in Europe and by a United States national registry analysis.^{2,3}

In contrast to deceased donor liver transplantation, when the recipient stenotic or occluded inferior vena cava (IVC) can be replaced with the donor IVC, in living donor liver transplantation (LDLT) it cannot, so appropriate management of a stenotic or occluded IVC is imperative in LDLT in the patient with BCS. We recently performed successful LDLT with extensive thrombectomy in a patient with acute-on-chronic BCS with a totally thrombosed retrohepatic IVC.

Patient

A 63-year-old man was admitted with general fatigue and vomiting to a local hospital, where liver dysfunction was confirmed. He was transferred to our hospital when his liver function deteriorated severely, with the following laboratory findings: serum total bilirubin 5.6 mg/dl, aspartate aminotransaminase 3573 IU/l, and alanine aminotransferase 2034 IU/l. He also had grade 3 hepatic encephalopathy. Abdominal computed tomography (CT) showed occlusion of the middle and left hepatic veins with thrombus in the IVC, extending from below the renal vein to the suprahepatic IVC (Fig. 1), as well as moderate ascites, and a patent portal vein. As a result of intensive care including plasma exchange, the acute liver failure improved and the patient was referred as a candidate for LDLT, with a diagnosis of BCS.

Technique

The patient underwent LDLT 3 months after the onset of acute liver failure. He received a right lobe liver graft from his son. The intraoperative findings revealed a hard and irregular liver, with moderate ascites and signs of portal hypertension.

Reprint requests to: S. Eguchi

Received: August 24, 2009 / Accepted: February 18, 2010

The preoperative abdominal CT showed a thrombosed IVC, so a portovenous bypass was established early in the procedure. The supradiaphragmatic IVC was cross-clamped after opening the pericardium. We introduced a Fogarty catheter through the opened and widened orifice of the right hepatic vein and common trunk of the left and middle hepatic veins. Since part of

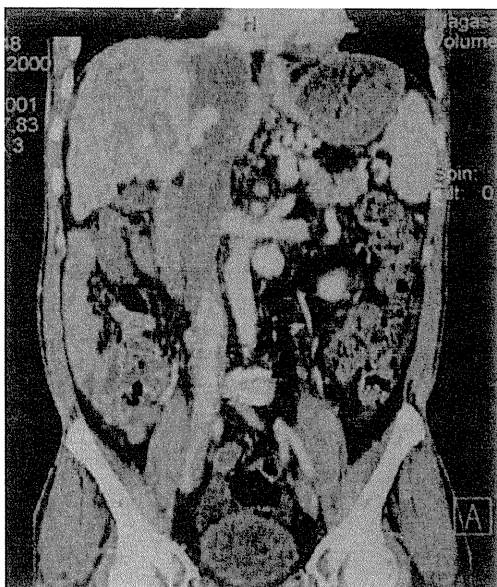


Fig. 1. Coronal view of preoperative abdominal computed tomography (CT) showed thrombosis of the inferior vena cava (IVC) extending from the suprahepatic IVC to below the left renal vein, a cirrhotic liver, and collateral vessels

the thrombus was difficult to remove by using only a Fogarty catheter, we performed thrombectomy through a longitudinally opened IVC wall with segmental cross-clamp.

After removing the thrombus from the IVC, we performed cavoplasty to match the orifice of donor's hepatic vein without any patch or interposition graft. The right hepatic vein of the graft was anastomosed to the recipient's IVC in an end-to-side fashion (Fig. 2), and portal, arterial, and biliary anastomoses were completed in a standard fashion. Immediately after LDLT, intravenous heparin therapy was started, which was later changed to oral warfarin. The patient had an uneventful postoperative recovery and was discharged on postoperative day 28. Follow-up CT confirmed a patent IVC and hepatic veins (Fig. 3). The patient is now doing well without any signs of recurrence of BCS.

Discussion

Yamada et al.⁴ reported three cases of patients who underwent LDLT without replacement of a chronically occluded IVC because they had well-developed hemiazygos veins. As our patient did not have well-developed hemiazygos veins, the IVC had to be preserved as a return from the lower half of the body and as an outflow route from the liver.

As options to replace an occluded retrohepatic IVC in LDLT, Yan et al.⁵ reported the usefulness of a cryopreserved vena cava graft, and Shimoda et al.⁶ advocated an autologous vein graft. Although these

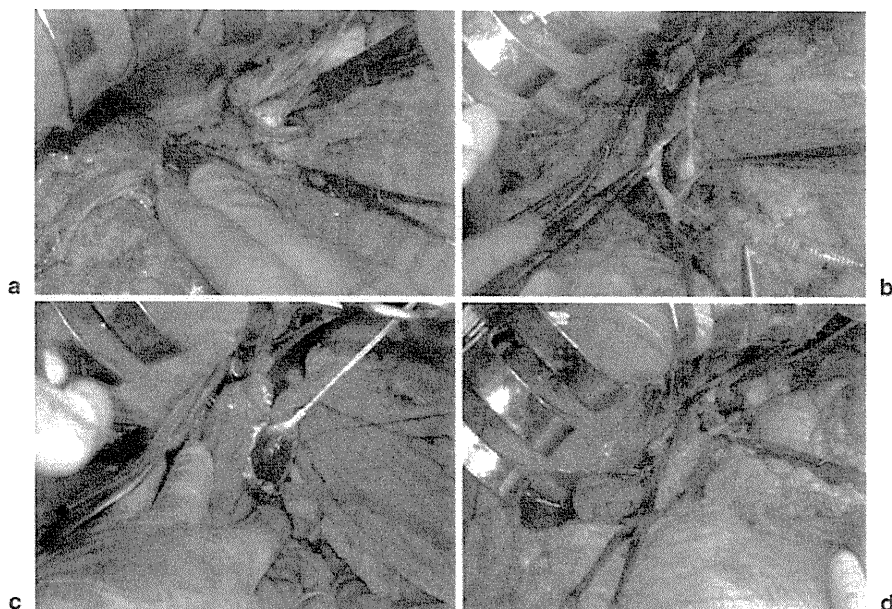


Fig. 2. Intraoperative photos showing cross-clamping of the IVC after opening the pericardium (a), opening of the IVC and subsequent thrombectomy with a Fogarty catheter (b, c), and cavoplasty performed to match the right hepatic vein of the graft (d)

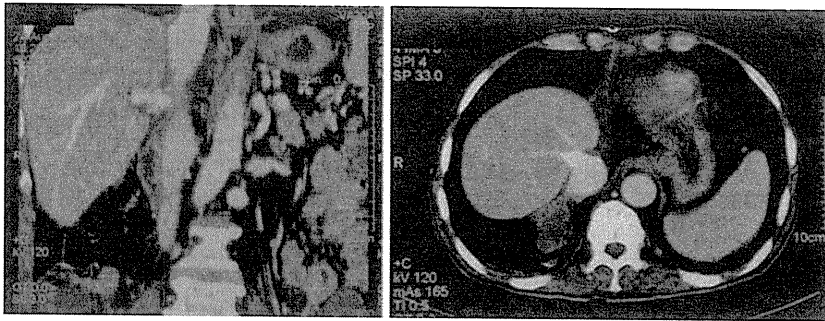


Fig. 3. Follow-up abdominal CT confirmed a patent IVC with no signs of recurrent thrombus

techniques have merit, appropriate cryopreserved grafts or autologous vessel grafts are not always available. Lee et al.⁷ described replacing the diseased stenotic retrohepatic vena cava of the recipient with a large-caliber Dacron interposition graft, placed between the right atrium and the infrahepatic IVC. Although long-term outcomes should be evaluated, their technique might be feasible if the thrombotic obstruction of the suprahepatic IVC extends almost to the junction of the right atrium and the intrapericardiac IVC.⁷

The successful outcome of our patient confirms the feasibility of our technique, including extensive thrombectomy without a vessel graft, for managing a stenotic or occluded IVC in LDLT for the BCS patient. In slow-progressing BCS, the wall of inferior caval vein can become fibrotic if thrombosis exists there long term. Although our technique might be applicable for slow-progressing as well as acute BCS, it is important to check if the IVC has a fibrotic wall that could make the IVC stenotic even after thrombectomy.

To the best of our knowledge, this is the first report of LDLT in a BCS patient with such severe extensive caval thrombus. Thus, for patients with acute deteriorating BCS with IVC thrombosis, and for those without CT evidence of a well-developed long-standing hemiazygos

vein, we consider LDLT with extensive thrombectomy to be a good treatment option.

References

1. Klein AS, Molmenti EP. Surgical treatment of Budd–Chiari syndrome. *Liver Transpl* 2003;9:891–6.
2. Mentha G, Giostra E, Majno PE, Bechstein WO, Neuhaus P, O’Grady J, et al. Liver transplantation for Budd–Chiari syndrome: A European study on 248 patients from 51 centres. *J Hepatol* 2006;44:520–8.
3. Segev DL, Nguyen GC, Locke JE, Simpkins CE, Montgomery RA, Maley WR, et al. Twenty years of liver transplantation for Budd–Chiari syndrome: a national registry analysis. *Liver Transpl* 2007;13:1285–94.
4. Yamada T, Tanaka K, Ogura Y, Ko S, Nakajima Y, Takada Y, et al. Surgical techniques and long-term outcomes of living donor liver transplantation for Budd–Chiari syndrome. *Am J Transplant* 2006;6:2463–9.
5. Yan L, Li B, Zeng Y, Wen T, Zhao J, Wang W, et al. Living donor liver transplantation for Budd–Chiari syndrome using cryopreserved vena cava graft in retrohepatic vena cava reconstruction. *Liver Transpl* 2006;12:1017–9.
6. Shimoda M, Marubashi S, Dono K, Miyamoto A, Takeda Y, Nagano H, et al. Utilization of autologous vein graft for replacement of the inferior vena cava in living-donor liver transplantation for obliterative hepatocavopathy. *Transpl Int* 2007;20:804–7.
7. Lee SG, Hwang S, Kim KH, Ahn CS, Moon DB, Ha TY, et al. Toward 300 liver transplants a year. *Surg Today* 2009;39:367–73.

Surgical Technique

Elective living donor liver transplantation by hybrid hand-assisted laparoscopic surgery and short upper midline laparotomy

Susumu Eguchi, MD, Mitsuhsa Takatsuki, MD, Akihiko Soyama, MD, Masaaki Hidaka, MD, Tetsuo Tomonaga, MD, Izumi Muraoka, MD, and Takashi Kanematsu, MD, Nagasaki, Japan

Background. Although the technique of liver transplantation is well developed, the invasiveness of the operation can be decreased with laparoscopic procedures.

Methods. We performed elective living donor liver transplantation (LDLT) through a short midline incision combined with hand-assisted laparoscopic surgery (HALS). Nine selected patients with end stage liver disease underwent the procedure between July, 2010 and February, 2011 (median age 60, median Child-Pugh 9, median MELD score 14). Splenectomy was performed simultaneously in 7 cases. The liver (and spleen) were mobilized by a sealing device under a HALS procedure with an 8-cm upper midline incision, followed by explantation of the diseased liver (and spleen) through the upper midline incision which was extended to 12 to 15 cm. Partial liver grafts were implanted through the upper midline incision.

Results. The median duration of the operation was 741 minutes, the median time needed for anastomosis was 48 minutes, the median blood loss was 3,940 g, and the median liver weight was 866 g.

Eight recipients are alive and have good graft function. A difficult implantation for one patient required an additional right transverse incision. When compared with 13 recent liver recipients who underwent LDLT with a regular Mercedes-Benz-type incision, no clinically relevant drawbacks of the HALS hybrid procedure were observed.

Conclusion. We have shown the feasibility and safety of LDLT performed through a short midline incision without abdominal muscle disruption with the aid of HALS. (*Surgery* 2011;150:1002-5.)

From the Department of Surgery, Nagasaki University Graduate School of Biomedical Sciences, Nagasaki, Japan

IN AN ATTEMPT to decrease the morbidity and invasiveness associated with liver surgery, several liver transplant teams have developed laparoscopic approaches to hepatectomy for living donors and patients with hepatic malignancies.¹⁻⁵ The surgical procedure performed on liver transplant recipients with portal hypertension is considered one of the most difficult abdominal operations because of the existence of collateral vessels. Nevertheless,

selected patients have undergone a less invasive procedure with laparoscopic assistance, including patients with portal hypertension who underwent splenectomy.⁶ We postulated that an elective liver transplant recipient procedure could be performed through an upper midline laparotomy after mobilization of the liver and spleen using hand-assisted laparoscopic surgery (HALS). We report a safe method for less invasive liver transplantation via a short midline incision without disruption of the abdominal musculature and nerves.⁷

MATERIALS AND METHODS

Living donor liver transplantation (LDLT) through a midline incision using a hand-assisted laparoscopic procedure was planned in 9 patients between July 2010 and February 2011. Seven patients had liver cirrhosis due to hepatitis C, in

Accepted for publication June 15, 2011.

Reprint requests: Susumu Eguchi, MD, Department of Surgery, Nagasaki University, Graduate School of Biomedical Sciences, 1-7-1 Sakamoto, Nagasaki 852-8501, Japan. E-mail: sueguchi@nagasaki-u.ac.jp.

0039-6060/\$ - see front matter

© 2011 Mosby, Inc. All rights reserved.

doi:10.1016/j.surg.2011.06.021

Table. Comparison of patient demographics and operative results

	<i>HALS + upper midline</i> (n = 9)	<i>Mercedes-Benz-type incision</i> (n = 13)	<i>P value</i>
Age	60 (44–69)	54 (27–72)	NS
Gender (Male:Female)	4:5	8:5	NS
Child-Pugh score	9 (6–14)	10 (5–15)	NS
MELD score	14 (7–43)	15 (7–35)	NS
Graft (RL:ELL)	1:8	6:7	NS
Operation duration (min)	741 (599–839)	812 (654–1,097)	<i>P</i> < .05
Anastomosis (min)	48 (37–55)	36 (32–65)	NS
Blood loss (g)	3,940 (1,300–18,400)	3,350 (520–5,600)	NS
Explanted liver (g)	866 (596–1,270)	830 (399–1,250)	NS
Outcome	1 death	2 deaths	NS

Values are expressed as median (range).

HALS, Hand-assisted laparoscopic surgery; *MELD*, model for end-stage liver disease; *Anastomosis*, anastomosis for hepatic vein and portal vein reconstruction; *ELL*, extended left lobe graft with middle hepatic vein; *RL*, right lobe graft.

whom splenectomy was performed simultaneously. One patient required LDLT because of hepatitis B cirrhosis, and another for Caroli's disease. The Ethics Committee of Nagasaki University Hospital approved a laparoscopic approach for the living donors as well. After experience with the 3 living donor right hepatectomy procedures, we planned to introduce the procedure in the recipient operation as well. The laparoscopic procedure was described in detail to the recipients and they gave their written consent. Patient demographics are provided in the Table. This combined laparoscopic and upper midline laparotomy procedure was indicated only for elective LDLT without a previous history of upper abdominal surgery. Neither ascites nor the degree of portal hypertension was considered as an exclusion criterion. Splenectomy was performed for preemptive interferon therapy after the liver transplantation.

Operative technique. Patients were placed supine with arms adducted and a urinary catheter, and arterial and central venous lines were inserted. An 8-cm upper midline laparotomy was made followed by a 12-mm infra umbilical incision for the laparoscope. A Gelport (Applied Medical, Rancho Santa Margarita, CA) was used in at the 8-cm incision, and a 5-mm port was placed in the right and left lateral upper abdomen under pneumoperitoneum (CO₂ at 8 mmHg) (Fig. A). This configuration enabled the first assistant surgeon, who stood on the left side of the patient, to use the hand port for liver manipulation. The primary operator stood on the right side and used the right lateral 5-mm port for dissection. Using a laparoscopic sealing device (Enseal; Ethicon Endo-Surgery, Cincinnati, OH) and hand assist, the right lobe of the liver was mobilized until the inferior vena cava was exposed (Fig. B). For patients who needed splenectomy, the primary operator moved to the left side and used the left lateral

5-mm port to mobilize the spleen from the retroperitoneum, which was handled by the first assistant surgeon through a Gelport from the right side, using a sealing device. After those bilateral mobilizations, the midline incision was extended to 12–15 cm, and a wound protector was applied. The wound was retracted and opened with the Omnitract retractor. Under direct view, the short hepatic veins were divided and the right hepatic vein was encircled through a midline incision as well as by transection of the splenic hilum with an endovascular stapler. After hepatic hilum dissection, explantation of the liver was performed in our regular manner without venovenous bypass (Fig. C).

Implantation of the left hepatic lobe with the middle hepatic vein was performed through the midline under cross-clamping on inferior vena cava using the standard procedure, followed by arterial and biliary reconstruction. Implantation of the right hepatic lobe was performed under partial clamping on inferior vena cava. After the procedure (Fig. D), 2 drains were placed through the 5-mm trochars, and the midline wound was closed.

In order to clarify the effect of our HALS hybrid procedure, data from 13 recent cases of the LDLT procedure involving a Mercedes-Benz-type incision after January 2010 were analyzed and compared (Table).

Statistical analysis. Univariate analysis was performed using the chi-square test for categorical factors and the Mann-Whitney test for numerical values. *P* values of less than .05 were considered to be statistically significant.

RESULTS

The Table shows the patient demographics and operation results for our hybrid procedure of LDLT in comparison with LDLT under regular Mercedes-Benz-type incision. Case 2 had massive

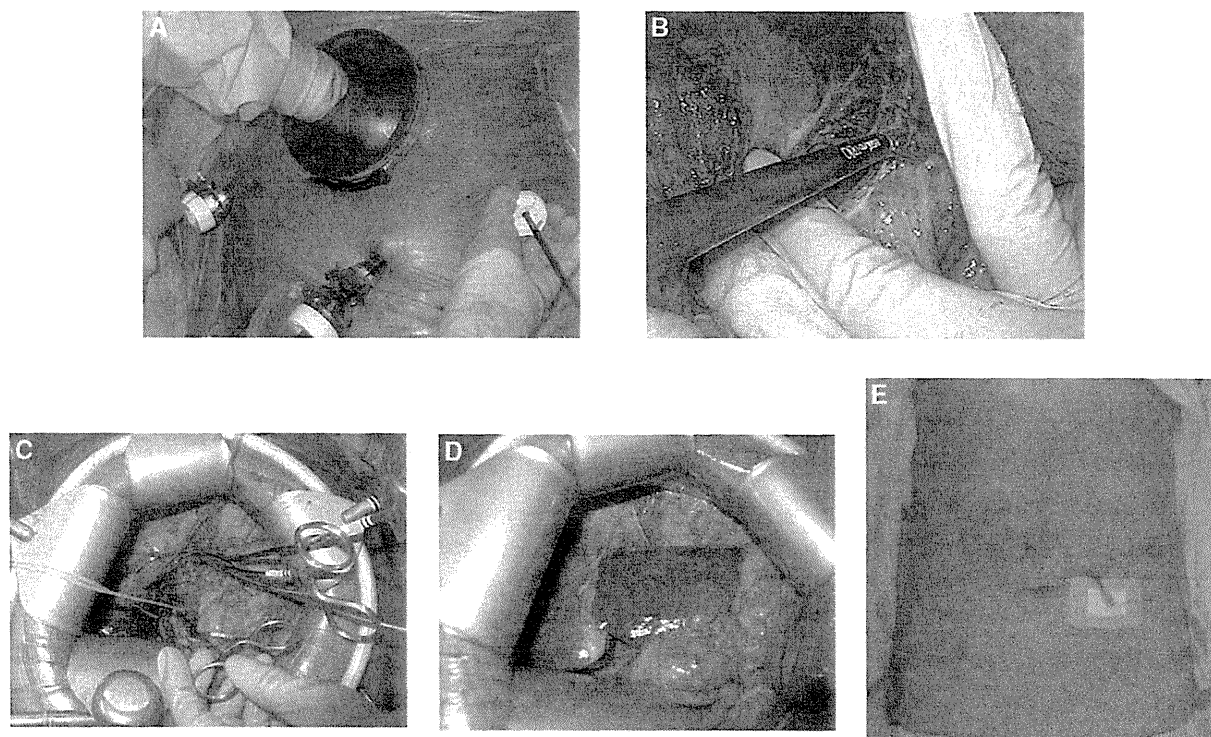


Fig. Case 2, 68 years old, female. (A) Hand-assisted port was applied for pneumoperitoneum. (B) Laparoscopic mobilization of the diseased liver. (C) Anhepatic phase through midline incision. (D) Implanted extended left liver lobe graft. (E) The abdominal wound 2 months after the operation. A biliary splint and tube jejunostomy was still placed and covered with white gauze.

3.5-L ascites that was evacuated through the laparotomy. A left lobe graft with the middle hepatic vein was implanted through the upper midline incision in 8 patients. The median duration of the operation was 741 minutes (range, 599–839) with a median blood loss of 3,940 ml (range, 1,300–18,400). The hepatic venous and portal venous reconstruction lasted a median of 48 minutes (range, 35–55). In case 2, the caudate lobe vein was also reconstructed. One case (Case 8) required an additional right transverse incision as it involved a difficult implantation. Eight recipients are alive and have excellent graft function. One death (Case 8) occurred due to thrombolytic microangiopathy on day 68. The wound in Case 2 was shown at 2 months after the LDLT (Fig, E).

When the results of the HALS hybrid procedure were compared with those of 13 recent LDLT recipients performed using a regular Mercedes-Benz-type incision, no clinically important limitations were observed with the HALS hybrid procedure (Table). In fact, the operative time was less in HALS hybrid cases (HALS: median 741 vs Mercedes-Benz: 812 minutes). Otherwise, there were no important differences between HALS hybrid cases and regular incision cases.

DISCUSSION

We showed the feasibility of LDLT through a midline incision without abdominal muscle disruption as occurs with the usual transverse incision, combined with HALS. Because LDLT is performed usually in an elective manner, this procedure could be planned and prepared for.

Before this study, we had performed 130 LDLTs through the usual transverse Mercedes-Benz-type incisions.⁸ Based on that experience, we presumed that it would be possible to perform explantation of the liver and spleen followed by implantation of the partial graft liver through a midline incision, because the liver hilum and inferior vena cava are usually located in the center of the upper abdomen. Also, because HALS has been used in the hepatectomy from the living donors, hepatic malignancy, and splenectomy, its use in the recipients seemed logical, because the magnified view under laparoscopy would allow us to obtain hemostasis using sealing devices.^{9,10} Because the transverse incision is usually needed only for mobilization of the right liver lobe and spleen, the laparoscopic procedure would allow this mobilization, especially in patients with an increased body mass index.^{11,12}

During liver transplantation for patients with hepatitis C, we perform splenectomy for postoperative interferon treatment with ribavirin, which is sometimes complicated by thrombocytopenia.¹³ For this combined procedure with mobilization of the liver and spleen, as presented in 7 cases, the HALS procedure showed a marked benefit of visualization not possible with the usual open laparotomy. It made sense for us to perform the mobilization of the liver and spleen using HALS under the laparoscope, because after these procedures the liver transplantation could be performed through the short upper midline incision. Quick celiotomy and closure of the abdomen were also benefits of the upper midline incision.¹⁴ Because no muscle disruption occurred, we believe that postoperative rehabilitation was facilitated. The additional duration of the laparoscopic procedure was offset by the rapid opening and closing of the abdominal incision.

In our series, for the hybrid procedure of HALS and a short midline laparotomy, we selected patients without a history of previous upper abdominal surgery. Although there was still a risk of massive bleeding from collateral vessels, the use of a sealing device with a magnified view allowed us to perform the laparoscopic mobilization. The median blood loss during LDLT was similar to what is reported in large LDLT series.¹⁵ Although we have not had serious complications during the procedure, we would not hesitate to add a wide transverse incision if any difficulty occurred during the procedure, as occurred in our case 8.

REFERENCES

1. Cherqui D, Soubrane O, Husson E, Barshasz E, Vignaux O, Ghimouz M, et al. Laparoscopic living donor hepatectomy for liver transplantation in children. *Lancet* 2002;359:392-6.
2. Koffron AJ, Kung R, Baker T, Fryer J, Clark L, Abecassis M. Laparoscopic-assisted right lobe donor hepatectomy. *Am J Transplant* 2006;6:2522-5.
3. Kim SH, Cho SY, Lee KW, Park SJ, Han SS. Upper midline incision for living donor right hepatectomy. *Liver Transpl* 2009;15:193-8.
4. Nitta H, Sasaki A, Fujita T, Itabashi H, Hoshikawa K, Takahara T, et al. Laparoscopy-assisted major liver resections employing a hanging technique: the original procedure. *Ann Surg* 2010;251:450-3.
5. Nguyen KT, Gamblin TC, Geller DA. World review of laparoscopic liver resection-2,804 patients. *Ann Surg* 2009;250:831-41.
6. Tomikawa M, Akahoshi T, Sugimachi K, Ikeda Y, Yoshida K, Tanabe Y, et al. Laparoscopic splenectomy may be a superior supportive intervention for cirrhotic patients with hypersplenism. *J Gastroenterol Hepatol* 2010;25:397-402.
7. Jain A, Nemitz P, Sharma R, et al. Incidence of abdominal wall numbness post-liver transplantation and its complications. *Liver Transpl* 2009;15:1488-92.
8. Eguchi S, Takatsuki M, Hidaka M, Tajima Y, Kanematsu T. Evolution and changes in living donor liver transplantation. A single center experience over 10 years. *Surg Today* 2008;38:785-800.
9. Soubrane O, Cherqui D, Scatton O, Stenard F, Bernard D, Branchereau S, et al. Laparoscopic left lateral sectionectomy in living donors: safety and reproducibility of the technique in a single center. *Ann Surg* 2006;244:815-20.
10. Kurosaki I, Yamamoto S, Kitami C, Yokoyama N, Nakatsuka H, Kobayashi T, et al. Video-assisted living donor hemihepatectomy through a 12-cm incision for adult-to-adult liver transplantation. *Surgery* 2006;139:695-703.
11. Koffron AJ, Kung RD, Auffenberg GB, Abecassis MM. Laparoscopic liver surgery for everyone: the hybrid method. *Surgery* 2007;142:463-8.
12. Wakabayashi G, Nitta H, Takahara T, Shimazu M, Kitajima M, Sasaki A. Standardization of basic skills for laparoscopic liver surgery towards laparoscopic donor hepatectomy. *J Hepatobiliary Pancreat Surg* 2009;16:439-44.
13. Eguchi S, Takatsuki M, Soyama A, Hidaka M, Tokai H, Hamasaki K, et al. Intentional conversion from tacrolimus to cyclosporine for HCV-positive patients on preemptive interferon therapy after living donor liver transplantation. *Ann Transplant* 2007;12:11-5.
14. Nguyen KT, Marsh JW, Tsung A, Steel JL, Gamblin TC, Geller DA. Comparative benefits of laparoscopic versus open hepatic resection: a critical appraisal. *Arch Surg* 2011;146:348-56.
15. Morioka D, Egawa H, Kasahara M, Ito T, Haga H, Takada Y, et al. Outcomes of adult-to-adult living donor liver transplantation: a single institution's experience with 335 consecutive cases. *Ann Surg* 2007;245:315-25.

原 著

マイアミ大学での HIV 陽性患者に対する肝移植

西田 聖剛¹⁾, 江口 晋²⁾, 曾山 明彦^{2,3)}, 日高 匡章²⁾, 高槻 光寿²⁾,
高橋 正浩¹⁾, Andreas G. Tzakis¹⁾, 兼松 隆之²⁾¹⁾マイアミ大学移植外科, ²⁾長崎大学大学院移植・消化器外科, ³⁾エイズ予防財団**目的:** 肝移植先進国での HIV 陽性患者に対する肝移植成績を明らかにする。**患者と方法:** 1999 年より 2010 年 1 月までに米国マイアミ大学で 26 人に対して 29 回の肝移植を施行した。HIV 感染経路は、血液製剤 2 例、輸血 1 例、静注薬使用 7 例、同性間性感染の男性 13 例、異性間性感染 3 例であった。移植時年齢は以下中央値(範囲) 45 歳(36~62)、男性 23 例、女性 3 例。2002 年以降 24 例の MELD (model for end-stage liver disease) スコア 22 (1~43)、HIV 以外に HBV 感染 10 例、HCV 感染 12 例、HBV/HCV 共感染 2 例であり、肝細胞癌合併 5 例、CD4 陽性 T 細胞実数は 155/μL (23~1,045) であった。**結果:** 脳死ドナー年齢 46 歳 (18~65)、移植手術は冷阻血時間 436 分 (256~1,946)、温阻血時間 33 分 (25~57) で、輸血量は 12U (0~45)、FFP 17U (0~97)、PC18U (0~98) であった(米国 1U は日本 2U に相当)。移植後入院期間は 12 日 (1~107) で、overall の患者生存は 3 年 69.1%、5 年 61.4%、死亡例 12 例の死因は敗血症 4、HCV 再燃 3、再発肝細胞癌 1、移植後リンパ増殖性疾患 1、進行性多巣性白質脳症 1、不明 2 であった。全症例タクロリムスを使用した免疫抑制で、前半は過剰投与によるトラフ値の overshoot 傾向がみられたが、後期では調節良好であった。**結論:** 今回の共同研究結果を参考に、本邦での HIV 陽性患者に対する肝移植も進めることができると考えられた。**キーワード:** HIV, HCV, 肝移植, 血友病, マイアミ

日本エイズ学会誌 13: 137-144, 2011

1. はじめに

1995 年以降、HIV 陽性患者の死亡数は Highly Active Anti-Retroviral Therapy (HAART) による HIV のコントロールの改善により減少するとともに、死因に大きな変化が見られた。米国では 1997~2000 年に死亡した 135 人の HIV 陽性患者のうち、AIDS 関連死(日和見感染による死亡)は約 50%、残りの約半数のうち、約 90% は肝疾患関連であり、多くは HCV 感染症による死亡であった¹⁾。その他の諸国でも同様な問題が指摘されてきている^{2~4)}。

本邦では、特に血友病など血液疾患に対する過去の汚染血液製剤使用による HIV 感染者は 90% 以上が HCV にも重複感染しており、今後、肝移植を念頭においたフォローが必要となってくる⁵⁾。しかし、本邦でも肝移植の報告は約 10 例程度であり、本邦での患者救済への情報が欠乏している⁶⁾。そこで、2009 年に「血液製剤による HIV/HCV 重複感染者に対する肝移植のための組織構築」研究班(兼松班)が立ち上がり、本邦における当該患者に対する肝移植のための情報収集を開始した。研究班の事業の一環とし

て、HIV 陽性患者に対する肝移植を積極的に施行しているマイアミ大学へ海外委託事業として共同研究を開始した。その結果を今回マイアミ大学⁷⁾での最新の肝移植成績を解析、公表し、本邦での当該患者に対する肝移植の一般化に向けての考察を行うこととした。

2. 患者と方法

マイアミ大学およびその関連施設では 1999 年より 2010 年 1 月までに 26 人に対して 29 回の肝移植が施行された。その詳細を表 1 に示す。HIV 感染症の原因は、血友病に対する血液製剤によるものが 2 例、輸血によるもの 1 例、iv drug 濫用 7 例、MSM (man who have sex with men) 13 例、同性間性感染の男性 3 例であった。患者の移植時の年齢は中央値 45 歳 (36~62 歳)、男性 23 例、女性 3 例、血液型は A 型 12 例、B 型 2 例、O 型 11 例、AB 型 1 例、人種は白人 23 例(ヒスパニック 2 例)、アフリカンアメリカン 3 例であった。レシビエントの BMI 中央値は 24 (16~32)、ICU 管理中 2 例、入院中 8 例、自宅待機 17 例であった。

マイアミ大学での HIV 陽性患者における肝移植適応は、通常の肝移植患者と同様に MELD (model for end-stage liver disease) により決定されていた。加えて HIV 感染患者では HIV 検出感度以下で、活動性感染症がないことが適応

著者連絡先: 江口 晋 (〒852-8501 長崎市坂本 1-7-1 長崎大学大学院移植・消化器外科)

2011 年 1 月 5 日受付; 2011 年 6 月 16 日受理

表 1 マイアミ大学での HIV 陽性肝移植患者

初回移植/再移植	26/3 計 29 回
移植時年齢	中央値 45 歳 (36~62)
性別 (男性/女性)	23/3
HIV 感染症の原因 (MSM/iv drug 濫用/性交感染/血友病に対する血液製剤/輸血)	13/7/3/2/1
血液型 (A/B/O/AB)	12/2/11/1
人種 (白人/アフリカンアメリカン)	23 (ヒスパニック 2)/3
BMI	中央値 24 (16~32)
レシピエント状態 (ICU 管理中/入院中/自宅待機)	2/8/17
移植時重症度	
2002 年までの 5 例 (Status 1/2a/2b)	1/1/2
2002 年以降 24 例	MELD スコア中央値 22 (1~43)
ウイルスマーカー (HBV 単独感染/HCV 単独感染/HBV/HCV 共感染, HIV のみ)	10/12/2/5
HCC 合併	5 (19.2%)
劇症肝炎	4 (3 例は HBV, 残りの 1 例は薬剤性)
CD4 実数	中央値 205 (23~1,780)
CD4%	中央値 29% (8~56%)
門脈血栓 (ありなし)	6/23

条件となっていた。一方、CD4 の実数は移植適応には意味されていなかった。

移植時の重症度は 2002 年までの 5 症例では医学的緊急度 Status 1 (劇症肝炎、移植肝不全など) が 1 例、2a (ICU 待機) が 1 例、2b (在院 ICU 外待機) が 2 例であった。2002 年以降は MELD (model for end-stage liver disease) スコアが計算されており、24 例の MELD スコア中央値 22 (1~43) であった。ウイルスマーカー別では HBV 単独感染が 10 例、HCV 単独感染が 12 例、HBV/HCV 共感染が 2 例であり、HCC の合併は 5 例に認めていた。劇症肝炎は 4 例のうち 3 例は HBV によるもので、残りの 1 例は薬剤性であった。CD4 陽性 T 細胞の実数は中央値 155 (23~1,045) で、CD4 陽性 T 細胞の%は 26% (8~50%) であった。また、4 例 (13.8%) に門脈血栓症を認めていた。

3. 肝移植成績

表 2 に肝移植脳死ドナー、手術概要を示す。手術患者に移植された脳死ドナーは年齢の中央値 46 歳 (18~65 歳) で、男性 15 例、女性 14 例であった。

移植手術は conventional 法は 2 例のみで、他は piggy back 法で施行され、バイパスは 8 例で使用されていた。胆道再建法としては胆管空腸吻合が 22 例、胆管胆管吻合は 7 例

であった。冷阻血時間中央値 436 分 (256~1,946 分)、温阻血時間中央値 33 分 (25~57 分) で、輸血量は 12U (0~45)、FFP 17U (0~97)、PC18U (0~98) であった (米国の 1U は日本の 2U に相当する)。

移植後入院期間の中央値は 12 日 (1~107 日) で、移植成績としては、2010 年 1 月までで 17 例生存、12 例死亡で、3 例に再移植が施行されていた。再移植 3 例中 2 例は死亡していた。患者生存中央値は 112 日 (1~1,928) であった。Overall の患者生存は 3 年 69.1%、5 年 61.4% であった (図 1)。また門脈血栓の有無でも肝移植成績に有意差を認めなかった (図 1)。CD4 陽性 T 細胞の実数別で患者生存を分類してみても、肝移植成績に有意差を認めなかった (図 2)。

死亡例 12 例の死因は敗血症 4 例、HCV 再燃 3 例 (1 例は慢性拒絶合併)、再発 HCC 1 例、移植後リンパ増殖性疾患 1 例、進行性多巣性白質脳症 1 例、不明 2 例であった。

免疫抑制剤はすべての症例でタクロリムスを使用した免疫抑制を行った。各症例でトラフ値は様々であったが、前半はリトナビルと FK の相互作用による FK トラフ値の overshoot 傾向がみられた (図 3 (1)、(2))。後半は 1 週間に 1 回投与などの工夫により通常の免疫抑制レベルでコントロール良好な症例が多かった (図 3 (3))。

表 2 マイアミ大学での HIV 陽性患者に対する肝移植手術 (1999~2010. 1)

脳死ドナー年齢	46 歳 (18~65)
冷阻血時間	436 分 (256~1,946)
温阻血時間	33 分 (25~57)
輸血量 (日本の 2U が米国 1U)	12U (0~45), FFP 17U (0~97), PC18U (0~98)
胆道再建	胆管空腸吻合 22, 胆管胆管吻合 7
免疫抑制剤開始	中央値 1 日 (0~20)
HAART 再開	中央値 1 日 (0~109)
インターフェロン開始日	中央値 44 日 (2~220)
移植後入院期間	12 日 (1~107)
	17 例生存, 12 例死亡
死因	
敗血症	4
HCV 再燃	4 (1 例は慢性拒絶合併)
再発 HCC	1
PTLD	1
進行性多発性白質脳症	1
不明	2

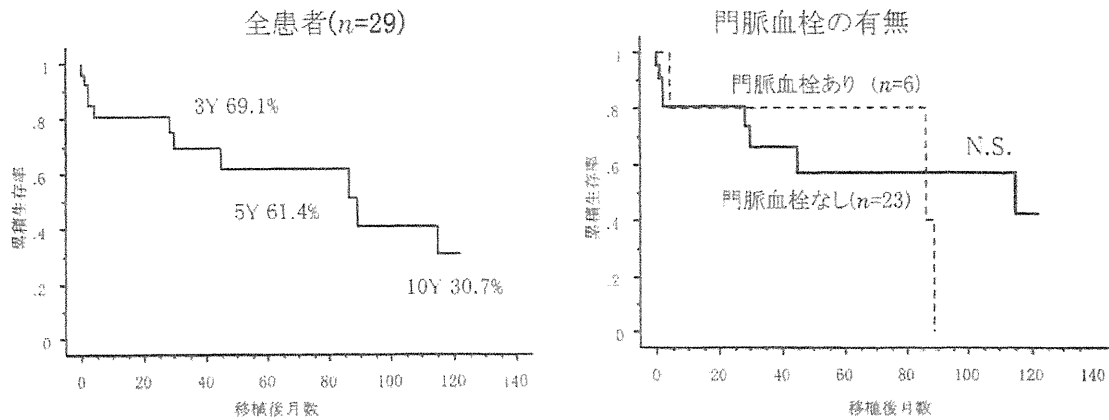


図 1 肝移植後患者生存率—マイアミ大学 (1999~2010. 1)

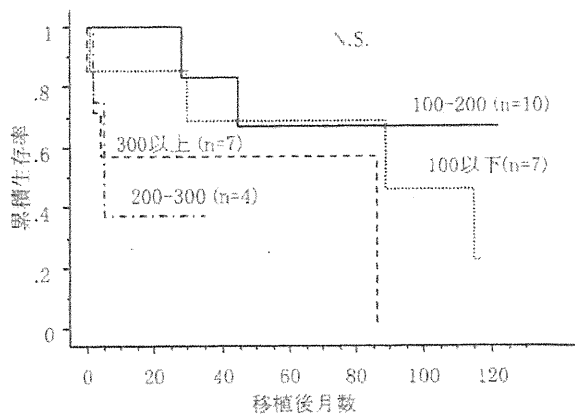


図 2 CD4 実数別 HIV 陽性患者に対する肝移植後患者生存率

4. 考 察

移植適応に関しては、基本的には非 HIV 陽性患者と同様に肝不全 (特に C 型肝硬変) の状態となり、長期予後が望めない患者が適応となる。また、肝不全には至っていないが、HAART による (C 型慢性肝炎をベースとした) 肝障害が高度で、HAART の中断・中止が必要な場合も適応とされる⁸⁾。HAART 施行中の患者では肝予備能、HIV 感染症の状況の双方からの適応検討が必要である。また経過中に肝細胞癌を発症した場合も適応となることがある⁹⁾。マイアミ大学での HIV 陽性患者における肝移植適応は、米国での通常の肝移植患者と同様に MELD (model for end-stage liver disease) により決定されていた。加えて HIV 感

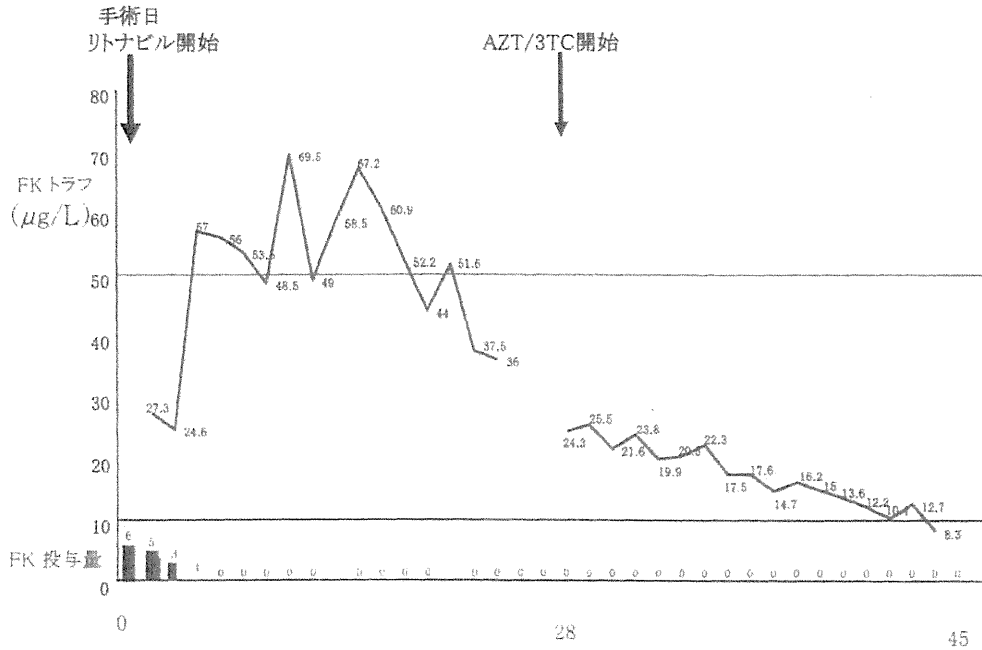


図 3 (1) 術後 FK506 血中濃度の推移

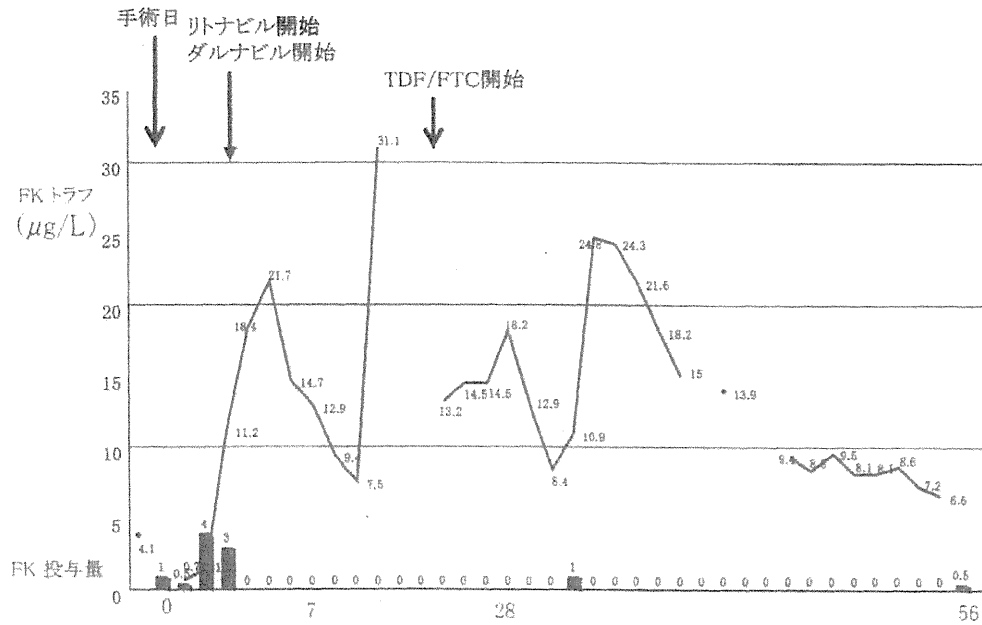


図 3 (2) 術後 FK506 血中濃度の推移

染患者では ACTIVE な感染症がないことが適応条件である。一般的には、CD4 200/µL 以上、HIV のウイルスが感知されないことが、肝移植適応条件となるが、最近ではマイアミ大学では、あまり CD4 陽性 T 細胞の数にこだわっていないのが現状である。CD4 陽性 T 細胞の実数は中央値 155 (23~1,045) で、CD4 陽性 T 細胞の % は 26% (8~

50%) であった。これは肝硬変の患者では総白血球数、総リンパ球数が減少しており、それ自体が肝移植成績とは関連しないと考えたからである。厚生労働研究小池班のガイドラインでは、CD4 陽性 T 細胞実数が 250 以上を適応としている¹⁰⁾ が、今回のマイアミでのデータに基づき、高度肝硬変の患者では CD4 陽性 T 細胞の移植基準値をたと

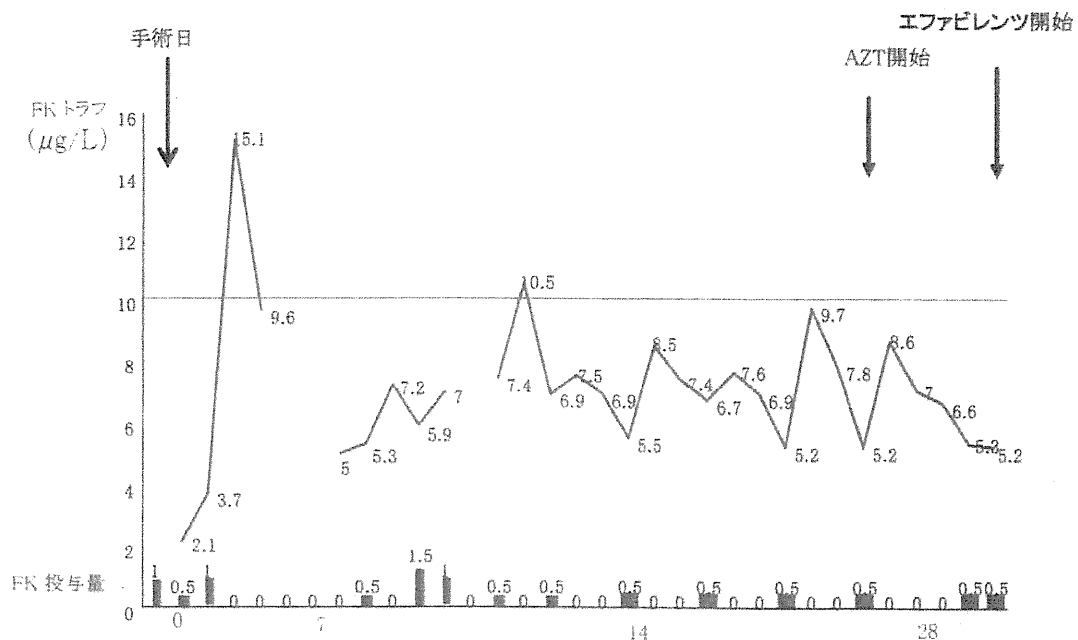


図 3 (3) 術後 FK506 血中濃度の推移

えば 150 などに低下させてもよい可能性が示唆される。また、脾臓摘出術を併施することを計画しているさいは、術後 CD4 陽性 T 細胞数の上昇も予想される。移植後の感染性合併症も特に上昇しておらず、マイアミ大学のように通常の肝移植管理 + HIV 感染症内科また血友病患者では血液内科の合同チームにより multi-disciplinary team を形成し、肝移植の成功率の向上に寄与しうると考えられた。

HIV 陽性感染者に対する肝移植で通常の肝移植と異なる問題点は次のような事項があげられる。1. HAART との併用によるカルシニューリン阻害薬の著明な血中濃度上昇¹¹⁾、2. 適正な HAART 開始のタイミングが未確立で、早期開始での薬剤性肝障害のリスク高¹²⁾、3. HAART 開始の遅れによる日和見感染のリスク、4. HIV 陽性患者に対して移植の考慮が遅れ、結果として移植時期が遅れる、5. HCV 重複感染例では、HIV のみ陽性患者に比較して、HCV 再発後の進展が早い¹³⁾、6. インターフェロン、リバビリンなどの抗ウイルス剤の免疫系を介しての HIV ウイルス動態、HAART 薬剤との相互作用¹⁴⁾ である。

今回、移植先進国である米国で HIV 陽性患者に対する肝移植を積極的に施行しているマイアミ大学のデータを解析した。本邦でも、特に血液製剤による HIV-HCV 重複感染患者で、すでに肝硬変となっている患者約 50 例、また慢性肝炎患者の約 400 例が今後本邦でも肝移植適応となってくる可能性があり、十分な情報集約が必要となる⁵⁾。前出の小池班ガイドラインでは、HIV-HCV 重複感染例に対する肝移植として、東京大学 6 例、広島大学 1 例を報告し

ている¹⁰⁾。また、血友病保因者よりの生体肝移植も 2002 年に報告されており¹⁵⁾、実際は 10 例ほどの生体肝移植が施行されているようである。情報の集約化が本患者群に対する肝移植成績の向上には不可欠であり、今後の報告が待たれる。

免疫抑制剤については通常のタクロリムスの投与期間、投与量を調節することで、HAART の併用を行うことが可能であった。実際の個々の患者の免疫抑制剤の投与量、トラフ値と HAART 薬剤の投与タイミングをグラフ化した。各症例でトラフ値は様々であったが、前半は過剰投与によるタクロリムストラフ値の overshoot 傾向がみられた。後半は、おそらく経験値の上昇により、1 週間に 1 回投与などの工夫により通常の免疫抑制レベルで落ち着いている症例が多かった。最近では raltegravir などカルシニューリン阻害薬と相互作用を持たないとされる HAART も可能となっており、肝移植例での仕様につき、今後の報告が待たれる¹⁶⁾。HAART 再開時期に関しては、術前に投与していた薬剤を可及的早期に再開するのが望ましいと考えられるが、患者の腎機能、移植肝機能を考慮しつつ、徐々に再開されているのが実情であった。

最近のフランスからの 14 例の報告では、インターフェロン、HAART、肝線維化などの詳細な報告がなされている¹⁷⁾。全例、術前血中 HIV 量は検出感度以下で、CD4+T 細胞数は 85~1,015 と幅があった。カルシニューリン阻害剤はタクロリムスを 0.5 mg/週で基本的には術後 2 週間目より開始されているが、それでも 5 例 (36%) で過剰投与と

なっていた。また HAART も術後 2 週目より再開されていた。肝移植後 12 カ月目の肝生検では FCH 1 例、F3 1 例、F2 2 例、F1 5 例であった。移植予後は 1 例を FCH により失ったのみであり、encouraging な成績であると考えられる。

本邦では血友病患者に対して過去に投与された汚染血液が原因となっていることが多いため、術中、術後の移植肝が機能を発揮開始するまでの凝固、出血管理が困難であることがあげられる。マイアミ大学での検討では血友病患者は 1 例のみしか含まれておらず、本点については参考とらなかった。また、本邦では法改正により脳死下臓器提供が増加しているものの、全肝移植である脳死肝移植は待機期間が長く、部分肝移植である生体肝移植がいまだ中心的な役割を果たしている。よって、部分肝移植であることの欠点、つまり small-for-size 症候群の出現、初期移植肝機能遅延、移植時の血管グラフトの不足を克服する必要がある¹⁸⁾。

また、最近、話題となっている HAART 実施中の患者での特発性門脈圧亢進症¹⁹⁾に生じる門脈血栓症患者に対する肝移植成績を考察するため、門脈血栓の有無にて移植成績を比較したが、特に有意差を認めなかった。脳死肝移植では十分な長さの門脈を使用することができ、また血管グラフトの入手も容易であるため今回の結果が得られたのではないかと推測する。生体肝移植の場合は、グラフト血管長が短いため、ジャンプグラフトなども入手が制限されるため、同様の成績が得られるかは、不明である。

以上、マイアミ大学での本研究結果を、本邦での肝移植に外挿し検討することにより、肝移植合併症の頻度を低下させ、成績向上を図ることができると考えられる。

謝辞

本論文は厚生労働省厚生労働科学研究 H21-エイズ一般-004、および平成 21 年度エイズ予防財団海外委託事業により執筆した。稿を終えるにあたり、データ収集に尽力頂いた感染症内科 Prof. Jayaweera、Nurse Coordinator の Ms. Weppler に深く御礼申し上げます。

文 献

- 1) Valdez H, Chowdhry TK, Asaad R, Woolley JJ, Davis T, Davidson R, Beinker N, Gripshover BM, Salata RA, McComsey G, Weissman SB, Lederman MM. : Changing spectrum of mortality due to human immunodeficiency virus : Analysis of 260 deaths during 1995-1999. *Clin Infect Dis* 32 : 1487-1493, 2001.
- 2) Marcellin P, Pequignot F, Delarocque-Astagneau E, Zarski JP, Ganne N, Hillon P, Antona D, Bovet M, Mechain M, Asselah T, Desenclos JC, Jouglu E : Mortality related to chronic hepatitis B and chronic hepatitis C in France : Evidence for the role of HIV coinfection and alcohol consumption. *J Hepatol* 48 : 200-207, 2008.
- 3) Wojeik K, Vogel M, Voigt E, Speidel N, Kalff JC, Goldmann G, Oldenburg J, Sauerbruch T, Rockstroh JK, Spengler U : Antiviral therapy for hepatitis C virus recurrence after liver transplantation in HIV-infected patients : Outcome in the Bonn cohort. *AIDS* 21 : 1363-1365, 2007.
- 4) Ballester JM, Rivero RA, Villaescusa R, Merlin JC, Arce AA, Castillo D, Lam RM, Ballester A, Almaguer M, Melians SM, Aparicio JL : Hepatitis C virus antibodies and other markers of blood-transfusion-transmitted infection in multi-transfused Cuban patients. *J Clin Virol* 34 Suppl 2 : S39-46, 2005.
- 5) 財団法人エイズ予防財団 : 血液凝固異常症全国調査厚生労働省委託事業. 平成 20 年度報告書.
- 6) Sugawara Y, Ohkubo T, Makuuchi M, Kimura S, Tachikawa N : Living-donor liver transplantation in an HIV-positive patient with hemophilia. *Transplantation* 74 : 1655-1656, 2002.
- 7) Schreiber I, Gaynor JJ, Jayaweera D, Pysopoulos N, Weppler D, Tzakis A, Schiff ER, Regev A : Outcomes after orthotopic liver transplantation in 15 HIV-infected patients. *Transplantation* 84 : 697-705, 2007.
- 8) Duclos-Vallée JC, Vittecoq D, Teicher E, Teicher E, Feray C, Roque-Afonso AM, Lombès A, Jardel C, Gigou M, Dussaix E, Sebah M, Guettier C, Azoulay D, Adam R, Ichaï P, Saliba F, Roche B, Castaing D, Bismuth H, Samuel D : Hepatitis C virus viral recurrence and liver mitochondrial damage after liver transplantation in HIV-HCV co-infected patients. *Hepatology* 42 : 341-349, 2005.
- 9) Di Benedetto F, De Ruvo N, Berretta M, Masetti M, Montalti R, Di Sandro S, Ballarin R, Codeluppi M, Guaraldi G, Gerunda GE : Hepatocellular carcinoma in HIV patients treated by liver transplantation. *Eur J Surg Oncol* 34 : 422-427, 2008.
- 10) HIV・HCV 重複感染時の診療ガイドライン 平成 16 年度厚生労働省科学研究費補助金エイズ対策研究事業「HIV 感染症に合併する肝疾患に関する研究」班 2005 年.
- 11) Brook MG, Jones K, Dale AW, Miller RF : Management of hepatitis C virus infection in HIV/HCV co-infected patients : Clinical review. *W J Gastroenterol* 15 : 3713-3724, 2009.
- 12) Graham CS, Baden LR, Yu E, Mrus JM, Carnie J, Heeren T, Koziel MJ : Influence of human immunodeficiency virus

- infection on the course of hepatitis C virus infection : A meta-analysis. *Clin Inf Dis* 33 : 562-569, 2001.
- 13) Benhamou Y, Bochet M, Di Martino V, Charlotte F, Azria F, Coutellier A, Vidaud M, Bricaire F, Opolon P, Katlama C, Poynard T : Liver fibrosis progression in human immunodeficiency virus and hepatitis C virus coinfecting patients. The Multivirc Group. *Hepatology* 30 : 1054-1058, 1999.
- 14) Berenguer J, Alvarez-Pellicer J, Martín PM, López-Aldeguer J, Von-Wichmann MA, Quereda C, Mallolas J, Sanz J, Tural C, Bellón JM, González-García J ; GESIDA3603/5607 Study Group : Sustained virological response to interferon plus ribavirin reduces liver-related complications and mortality in patients coinfecting with human immunodeficiency virus and hepatitis C virus. *Hepatology* 50 : 407-413, 2009.
- 15) Horita K, Matsunami H, Shimizu Y, Shimizu A, Kurimoto M, Suzuki K, Tsukadaira T, Arai M : Treatment of a patient with hemophilia A and hepatitis C virus-related cirrhosis by living-related liver transplantation from an obligate carrier donor. *Transplantation* 73 : 1909-1912, 2002.
- 16) Turkova A, Ball C, Gilmour-White S, Rela M, Mieli-Vergani G : A paediatric case of acute liver failure associated with efavirenz-based highly active antiretroviral therapy and effective use of raltegravir in combination antiretroviral treatment after liver transplantation. *J Antimicrob Chemother* 63 : 623-625, 2009.
- 17) Samri A, Roque-Afonso AM, Beran O, Tateo M, Teicher E, Feray C, Sebah M, Guettier C, Dussaix E, Vittecoq D, Samuel D, Autran B, Duclos-Vallée JC : Preservation of immune function and anti-hepatitis C virus (HCV) immune response after liver transplantation in HIV-HCV coinfecting patients (ANRS-HC08 "THEVIC" trial). *J Hepatol* 51 : 1000-1009, 2009.
- 18) 江口晋, 曾山明彦, 高槻光寿, 日高匡章, 兼松隆之 : 肝移植前後の門脈血行異常. *肝胆膵* 61 : 223-234, 2010.
- 19) Kovari H, Ledergerber B, Peter U, Flepp M, Jost J, Schmid P, Calmy A, Mueller NJ, Muellhaupt B, Weber R : Swiss HIV Cohort Study. Association of noncirrhotic portal hypertension in HIV-infected persons and antiviral therapy with Didanosine: A nested case-control study. *Clin Infect Dis* 15 : 626-635, 2009.