


- Uemura K., Kihara T., Kuzuya A., Okawa K., Nishimoto T., Bito H., Ninomiya H., Sugimoto H., Kinoshita A. and Shimohama S. (2006a) Activity-dependent regulation of beta-catenin via epsilon-cleavage of N-cadherin. *Biochem. Biophys. Res. Commun.* **345**, 951–958.
- Uemura K., Kihara T., Kuzuya A., Okawa K., Nishimoto T., Ninomiya H., Sugimoto H., Kinoshita A. and Shimohama S. (2006b) Characterization of sequential N-cadherin cleavage by ADAM10 and PS1. *Neurosci. Lett.* **402**, 278–283.
- Uemura K., Kuzuya A., Shimozono Y., Aoyagi N., Ando K., Shimohama S. and Kinoshita A. (2007) GSK3beta Activity Modifies the Localization and Function of Presenilin 1. *J. Biol. Chem.* **282**, 15823–15832.
- Wolfe M. S. (2007) When loss is gain: reduced presenilin proteolytic function leads to increased Abeta42/Abeta40. Talking Point on the role of presenilin mutations in Alzheimer disease. *EMBO Rep* **8**, 136–140.



Autoimmune autonomic ganglionopathy with Sjögren's syndrome: Significance of ganglionic acetylcholine receptor antibody and therapeutic approach

Takayuki Kondo^a, Haruhisa Inoue^a, Takashi Usui^b, Tsuneyo Mimori^b, Hidekazu Tomimoto^a, Steven Vernino^c, Ryosuke Takahashi^a

^a Department of Neurology, Kyoto University Hospital, Kyoto, Japan

^b Department of Rheumatology and Clinical Immunology, Kyoto University Hospital, Kyoto, Japan

^c University of Texas Southwestern Medical Center, Dallas, TX, USA

ARTICLE INFO

Article history:

Received 4 August 2008

Received in revised form 29 November 2008

Accepted 1 December 2008

Keywords:

Ganglionic acetylcholine receptor antibody

Autoimmune autonomic ganglionopathy

Sjögren's syndrome

Prednisolone

ABSTRACT

Autoimmune autonomic ganglionopathy (AAG) is a disorder defined by antibodies to the nicotinic acetylcholine receptor of the autonomic ganglia. We report two patients with chronically progressing dysautonomia with Sjögren's syndrome (SS). The first case showed elevated titer of ganglionic acetylcholine receptor (AChR) antibody and improved with oral intake of prednisolone. In contrast, the second case showed no elevation of ganglionic AChR antibody titer and had poor response to immunomodulatory therapy. These two cases indicate that chronic AAG may be treatable by immunomodulatory therapy, and have relevance to SS.

© 2008 Elsevier B.V. All rights reserved.

1. Introduction

Peripheral autonomic failures have various backgrounds such as diabetes mellitus, amyloidosis, inherited autonomic neuropathy or autoimmune disorders (e.g. Guillain-Barré syndrome, paraneoplastic syndrome, Sjögren's syndrome etc.). In this decade Vernino et al. proposed a novel disease entity of autoimmune autonomic failure, characterized by positive ganglionic acetylcholine receptor (AChR) antibody in the serum (Vernino et al., 2000) and designated autoimmune autonomic ganglionopathy (AAG). Ganglionic AChR antibody binds to alpha 3 subunits of the nicotinic acetylcholine receptor, which is localized to the postsynaptic neuron in the autonomic nerve ganglion, and disturbs the function of postganglionic autonomic nerves. Serum levels of the ganglionic AChR antibody significantly correlates with both neurological severity and clinical course (high titer; severe symptoms with acute or subacute progression, low titer; mild symptoms with chronic progression) (Low et al., 2003).

Here we present two Japanese patients with Sjögren's syndrome (SS), who also developed gradually progressive autonomic dysfunction. Detailed evaluation revealed clear differences between these two similar cases; one showed elevated titer of ganglionic AChR antibody, improved by oral prednisolone, whereas the other did not show elevation of ganglionic AChR antibody titer and had poor response to

immunomodulatory therapy. In the analysis of these two patients, we discussed the potential relationships between ganglionic AChR and SS.

2. Case presentation

2.1. Patient 1

A 74-year-old healthy man has suffered from oral sicca symptom and chronically progressive orthostatic dizziness for 3 years. When changing from the supine to the standing position, he lost consciousness and his blood pressure became too low to be measured. Physiological evaluation revealed orthostatic hypotension (supine position; blood pressure 90/60 mmHg and heart rate 61/min, standing position; 40/30 mmHg and 63/min), tonic pupil (3/3 mm), dry mouth, dry skin, urinary frequency (more than 6 times a night) and constipation. There were no other abnormal findings on neurologic examination. Routine laboratory examinations of blood, CSF and urine showed no abnormal findings. Anti muscarinic acetylcholine receptor M3 antibody was not examined. Plasma noradrenaline concentration decreased to 116 pg/ml (normal 140–570) at rest and failed to respond to tilting. There was no conspicuous abnormality in brain magnetic resonance imaging (MRI), single photon emission computed tomography (IMP-SPECT; imaging for cerebral blood flow) and peripheral nerve conduction studies. Cardiac uptake of 123I-metaiodobenzylguanidine (MIBG) scintigraphy decreased, with heart to mediastinum (H/M) ratio at 1.73 (examined at 15 min after injection, normal H/M > 1.92). The R–R interval variation on the electrocardiogram was 0.62% at rest. Tonic pupil responded to

Corresponding author. Tel.: +81 75 751 3768.

E-mail address: haruhisa@kuhp.kyoto-u.ac.jp (H. Inoue).

0.125% pilocarpine (2/2 mm), establishing denervation hypersensitivity of the pupillary constrictor. At first, because all of the autonomic dysfunctions were localized to postganglionic autonomic nerves, we diagnosed this patient with pure autonomic failure (PAF).

However further laboratory investigation revealed that anti SS-B (La) antibody was positive at 21.7 U/ml (normal <15). Oral and conjunctival sicca were objectively confirmed either by Schirmer test or by Gum test. Salivary gland biopsy revealed lymphocytic infiltration at both periglandular and perivascular regions. All of these findings fulfilled diagnostic criteria of primary SS (Vitali et al., 2002). Moreover, ganglionic AChR antibody was mildly elevated at 300 pmol/l (normal <50 pmol/L). There were no abnormal findings in both tumor markers (including CEA, CA19-9, NSE, SCC, PSA and sIL-2R) and in CT scans from neck to abdomen. Based on these findings, we diagnosed this patient as AAG concomitant with primary SS.

We attempted to administer 1 mg/kg/day prednisolone and gradually tapered to 0.3 mg/kg/day across 3 months. 3 weeks after starting therapy we observed improvement of autonomic dysfunction including orthostatic hypotension, tonic pupil, urinary frequency (returned to normal, less than 2 times a night), constipation and sicca symptoms. Also serum titer of both ganglionic AChR antibody and anti SS-B (La) antibody decreased from 300 to 150 pmol/l and 21.7 to 14.2 U/ml, respectively. After 2 years follow-up we did not observe any symptomatic exacerbation despite prednisolone dosage reduction down to 0.075 mg/kg/day.

2.2. Patient 2

A 79-year-old healthy woman presented with oral sicca symptoms for 4 years and also suffered from chronically progressive orthostatic dizziness, which sometimes resulted in faintness. Physiological evaluation revealed orthostatic hypotension (supine position; blood pressure 156/104 mmHg and heart rate 81/min, standing position; 84/52 mmHg and 84/min), tonic pupil (3/3 mm), dry mouth, dry skin of whole body, urinary frequency (more than 6 times a night) and constipation. There were no other abnormal findings on neurologic examination. Routine laboratory examinations of blood, CSF, and urine revealed no abnormal findings. Anti muscarinic acetylcholine receptor M3 antibody was not examined. Plasma noradrenalin concentration decreased to 136 pg/ml (normal 140–570) at rest and failed to respond to tilting. There were no conspicuous abnormalities in MRI and IMP-SPECT and nerve conduction studies. Cardiac uptake of 123I-MIBG scintigraphy was decreased, with heart to mediastinum (H/M) ratio at 1.40 (examined at 15 min after injection). The R-R interval variation on the electrocardiogram was 1.01% at rest. Tonic pupil responded to 0.125% pilocarpine (2/2 mm), indicating denervation hypersensitivity of the pupillary constrictor.

Anti SS-A (La) antibody was positive, 75.5 U/ml (normal <10). Oral and conjunctival sicca were objectively confirmed by Schirmer test and Gum test. Salivary gland biopsy revealed lymphocytic infiltration at both periglandular and perivascular regions. All of these findings fulfilled diagnostic criteria of primary SS. There were no abnormal findings in both tumor markers (including CEA, CA19-9, NSE, SCC, PSA and sIL-2R) and in CT scans from neck to abdomen. In contrast to patient 1, serum ganglionic AChR antibody was negative in patient 2. Finally we diagnosed her with PAF, partially overlapping with autoimmune autonomic neuropathy (AAN) associated with primary SS.

We attempted to administer 1 mg/kg/day prednisolone and gradually tapered to 0.4 mg/kg/day across 6 months, with no discernible effect on autonomic dysfunction (titer of anti SS-A (La) antibody decreased to 45.5).

3. Discussion

In patient 1 we could treat the patient of AAG by oral prednisolone monotherapy. There are no controlled studies of AAG treatment and only a few case reports describe the effectiveness of intravenous

immunoglobulin, plasmapheresis, L-threo-3,4-dihydroxyphenyl-serine (L-threo-DOPS) and a combination of these therapies (Christopher et al., 2008; Modoni et al., 2007; Schroeder et al., 2005). It is difficult to discriminate AAG from AAN or PAF because all of these diseases impair postganglionic autonomic nerves and present similar symptoms. Therefore ganglionic AChR antibody is critical for the diagnosis of AAG, which is treatable by medication.

Patient 1 showed decrease of cardiac MIBG-uptake, indicating postganglionic sympathetic denervation. On the other hand, some cases with AAG showed normal sympathetic innervation, assessed by 6-[¹⁸F] norepinephrine positron emission tomographic scanning (Goldstein et al., 2002). We speculated that the denervation of the present case was derived from secondary impairment of postganglionic nerves by ganglionic AChR antibody or by overlap of SS-induced AAN. Peripheral nerve conduction studies revealed intactness of large fibers in the present cases. However lack of nerve biopsy limited pathological evaluation of peripheral nerves, frequently involved in SS. Therefore we could not exclude the possibilities that different steroid-responses of the present two cases originated from 1) different severity of coincident SS-associated polyneuropathy, or 2) different severity of dysfunction in the autonomic ganglion. Unfortunately we have no modality to determine the histopathological distribution among autonomic ganglia, postganglionic nerve fibers, or both. Consequently the term 'ganglioneuropathy' can be more appropriate for cases like patient 1. Furthermore, urinary urgency, observed in the present two cases, is an unusual finding for AAN. We speculate that this urinary urgency was partially caused by Sjögren syndrome and the anti muscarinic acetylcholine receptor M3 antibody (Wang et al., 2004).

SS is a systemic autoimmune disease characterized by sicca symptoms, and accompanied by a wide variety of neurological complications. Among these, AAN is a rare complication of SS (Mori et al., 2005). AAN originating from SS is usually refractory to immunomodulative therapy (Shimoyama et al., 2002). Patient 1 (with primary SS and mildly elevated ganglionic AChR antibody) showed marked response to oral prednisolone, even though patient 2 (with SS and without ganglionic AChR antibody) was refractory to oral prednisolone. In primary SS, not only cellular immunity but also humoral immunity plays an important role. Primary SS is currently recognized as a multifactorial disorder associated with various antibodies (e.g. anti SS-A/Ro antibody, anti SS-B/La antibody, anti alpha-fodrin antibody, anti muscarinic acetylcholine receptor antibody etc.). Our cases suggest that a part of AAG may be relevant to SS and treatable by immunomodulatory therapy. However our present report is based on a limited number of cases and case accumulation is necessary to clarify the precise association between AAG and SS.

Acknowledgement

The authors wish to thank Dr Gavinio R. for editing the manuscript.

References

- Christopher, H., Gibbons, C.H., Vernino, S.A., Freeman, R., 2008. Combined immunomodulatory therapy in autoimmune autonomic ganglionopathy. *Arch. Neurol.* 65, 213–217.
- Goldstein, D.S., Holmes, C., Dendi, R., Li, S.T., Brentzel, S., Vernino, S., 2002. Pandy's autonomic neuropathy associated with impaired ganglionic neurotransmission and circulating antibody to the neuronal nicotinic receptor. *Clin. Auton. Res.* 12, 281–285.
- Low, P.A., Vernino, S., Suarez, G., 2003. Autonomic dysfunction in peripheral nerve disease. *Muscle Nerve* 27, 646–661.
- Modoni, A., Mirabella, M., Madia, F., Sauna, T., Lanza, G., Tonali, P.A., Silvestri, G., 2007. Chronic autoimmune autonomic neuropathy responsive to immunosuppressive therapy. *Neurology* 68, 161–162.
- Mori, K., Iijima, M., Koike, H., Hattori, N., Tanaka, F., Watanabe, H., Katsuno, M., Fujita, A., Aiba, I., Ogata, A., Saito, T., Asakura, K., Yoshida, M., Hirayama, M., Sobue, G., 2005. The wide spectrum of clinical manifestations in Sjögren's syndrome-associated neuropathy. *Brain* 128, 2518–2534.
- Schroeder, C., Vernino, S., Birkenfeld, A.L., Tank, J., Heusser, K., Lipp, A., Benter, T., Lindschau, C., Kretzitz, R., Luft, F.C., Jordan, J., 2005. Plasma exchange for primary autoimmune autonomic failure. *N. Engl. J. Med.* 353, 1585–1590.

- Shimoyama, M., Ohtahara, A., Okamura, T., Watanabe, M., Fujimoto, Y., Teshima, S., Takeda, S., Hisatome, I., Shigamasa, C., 2002. Isolated autonomic cardiovascular neuropathy in a patient with primary Sjögren syndrome: a case of successful treatment with glucocorticoid. *Am. J. Med. Sci.* 324, 170–172.
- Vernino, S., Low, P.A., Fealey, R.D., Stewart, J.D., Farrugia, G., Lennon, V.A., 2000. Autoantibodies to ganglionic acetylcholine receptors in autoimmune autonomic neuropathies. *N. Engl. J. Med.* 343, 847–855.
- Vitali, C., Bombardieri, S., Jonsson, R., Moutsopoulos, H.M., Alexander, E.L., Carsons, S.E., Daniels, T.E., Fox, P.C., Fox, R.I., Kassan, S.S., Pillemer, S.R., Talal, N., Weisman, M.H., European Study Group on Classification Criteria for Sjögren's Syndrome, 2002. Classification criteria for Sjögren's syndrome: a revised version of the European criteria proposed by the American–European Consensus Group. *Ann. Rheum. Dis.* 61, 554–558.
- Wang, F., Jackson, M.W., Maughan, V., Cavill, D., Smith, A.J., Waterman, S.A., Gordon, T.P., 2004. Passive transfer of Sjögren's syndrome IgG produces the pathophysiology of overactive bladder. *Arthritis Rheum.* 50, 3637–3645.

Diagnostic accuracy of cardiac metaiodobenzylguanidine scintigraphy in Parkinson disease

H. Sawada^{a,b}, T. Oeda^{a,b}, K. Yamamoto^{a,b}, N. Kitagawa^{a,b}, E. Mizuta^{a,b}, R. Hosokawa^c, M. Ohba^c, R. Nishio^c, K. Yamakawa^{a,d}, H. Takeuchi^{a,d}, S. Shimohama^d, R. Takahashi^d and T. Kawamura^{e,1}

^aClinical Research Center, Utano National Hospital, Kyoto, Japan; ^bCenter for Parkinson Disease and Related Disorders, Utano National Hospital, Kyoto, Japan; ^cDepartment of Cardiology, Kyoto University Hospital, Kyoto, Japan; ^dDepartment of Neurology, Kyoto University Hospital, Kyoto, Japan; and ^eKyoto University Health Service, Kyoto, Japan

Keywords:
norepinephrine,
preclinical diagnosis,
ROC curve, sympathetic
nerve

Received 16 August 2008
Accepted 17 October 2008

Background and purpose: To estimate the diagnostic accuracy of cardiac ¹²³I-metaiodobenzylguanidine (MIBG) scintigram for detection of Parkinson disease. **Methods:** A cross-sectional study with index test of MIBG scintigram and reference standard of U.K. Parkinson's Disease Brain Bank Criteria was performed in 403 patients. Ratio of cardiac-to-mediastinum MIBG accumulation was determined at 20 min (early H/M) and 4 h (late H/M). Area under the receiver-operator characteristic (ROC) curve, sensitivity and specificity in detecting Parkinson disease were analyzed. Accuracy was analyzed in a subgroup of patients with disease duration of 3 years or less. **Results:** Area under the ROC curve was 0.89 using either early or late H/M as a diagnostic marker (95% CI 0.85–0.92 for early H/M and 0.86–0.93 for late H/M). Sensitivity and specificity were 81.3% (76.1–85.8%) and 85.0% (77.7–90.6%) for early H/M and 84.3% (79.3–88.4%) and 89.5% (83.01–94.1%) for late H/M. In the subgroup with duration of 3 years or less, the ROC curve area, sensitivity, and specificity were 0.86 (0.79–0.92), 76.0% (64.8–85.1%), and 83.9% (71.7–92.4%) for early H/M and 0.85 (0.78–0.92), 73.3% (61.9–82.9%), and 87.5% (75.9–94.8%) for late H/M. **Conclusion:** Although diagnostic accuracy of cardiac MIBG scintigram is high, it is limited because of insufficient sensitivity in patients with short duration.

Introduction

In Parkinson disease degeneration of striatal dopaminergic neuronal terminals can be detected by neuroimaging using carbomethoxy-iodophenyl-tropine [1,2], or fluorodopa [3]. However, these findings are not disease specific because they may be observed in multiple system atrophy and progressive supranuclear palsy [4].

Sympathetic post-ganglionic fibers are markedly lost in the myocardium of patients with Parkinson disease [5–7], and denervation precedes the neuronal loss in the sympathetic ganglion [8] and the extent reflects pathological changes in sympathetic ganglion cells [5].

Goldstein and colleagues demonstrate that sympathetic neurocirculatory failure is important feature for the disease [9,10]. Denervation of cardiac sympathetic nerve terminals have been proven by a study using 6-¹⁸F-fluorodopamine [9] and is thought to be specific

for Parkinson disease [10–13]. Additionally, studies have revealed that uptake of metaiodobenzylguanidine (MIBG) into the myocardium is reduced in patients with Parkinson disease [12,14,15]. Cardiac sympathetic denervation can precede motor disturbance [16], and might be marked even in the initial stage of Parkinson disease [15]. However, it remains to be determined whether a reduction in cardiac MIBG accumulation is sensitive and specific enough to detect Parkinson disease, especially in the disease's early stages [17].

Subjects and methods

Study subjects

We enrolled 403 consecutive patients with muscular rigidity, hand or leg tremor, or slowed movements who had undergone a ¹²³I-MIBG cardiac scintigram at the two hospitals. Patients with history of myocardial infarction, current heart diseases including heart failure and cardiomyopathy, uncontrolled diabetes mellitus, and current use of tricyclic antidepressants or selegiline (10 mg of more) were excluded because tricyclic antidepressants block MIBG uptake and selegiline

Correspondence: Dr Hideyuki Sawada, Clinical Research Center, Utano National Hospital, 8 Ondoyamacho, Ukyoku, Kyoto, Japan (tel.: +81-75-461-5121; fax: +81-75-464-0021; e-mail: sawada@unh.hosp.go.jp).

¹Statistical analysis was conducted by Takashi Kawamura.

elevates serum norepinephrine concentrations. Informed consent was obtained from the participants. A total of 413 tests were performed in 403 patients, and 10 of these patients received an MIBG test at both hospitals.

Reference standard for clinical diagnosis of Parkinson disease

A detailed history was taken and neurological examinations were performed to make a clinical diagnosis of Parkinson disease according to the United Kingdom Parkinson's Disease Society Brain Bank Clinical Diagnostic Criteria (UK PD Brain Bank Criteria) [18]. These criteria were used as the reference standard, blind to the results of MIBG tests. Parkinson disease was diagnosed after fulfilling steps 1, 2 and 3 of UK PD Brain Bank criteria. Brain magnetic resonance imaging (MRI) was used to confirm the diagnosis of Parkinson disease.

Protocol for cardiac scintigram of MIBG

To investigate cardiac sympathetic nerve terminal denervation, 3 mCi (111 MBq) ^{123}I -MIBG was injected intravenously into each patient in the supine position. A planar image of the chest was obtained at 20 min and at 4 h. The regions of interest were set in the heart, mediastinum, and lung. Relative cardiac accumulation was calculated as the ratio of the heart to the mediastinum at 20 min (early H/M) and at 4 h (late H/M).

Interhospital reliability

Interhospital reliability was assessed by agreement of H/M using the method of Bland and colleagues [19] in patients who had been tested at both hospitals. The relative ratio of the H/M values of the tests performed at the two hospitals was plotted. The latest H/M values of these 10 patients are incorporated into the analysis for the area under ROC curves, sensitivity and specificity.

Relationship between cardiac MIBG uptake and the severity and duration of Parkinson disease

Because some patients have 'wearing-off' or 'on-off' phenomena we evaluated the severity of such patients in the 'on' period. Patients were assigned to five groups according to the Hoehn and Yahr Stage (H-Y), and the relationship between the grades on the H-Y and H/M was analyzed. We analyzed the relationship between the Unified Parkinson's Disease Rating Scale subset-3 (UPDRS-3) or disease duration and H/M in patients with Parkinson disease.

Determination of a cut-off point of H/M as a diagnostic marker and diagnostic accuracy

According to the ROC curve, we determined the most discriminative cut-off point of H/M for diagnosing Parkinson disease. The positive likelihood ratio, or a ratio of true-positive to false-positive, was calculated at the cut-off point. The negative likelihood ratio also was determined. To evaluate the diagnostic accuracy of the MIBG test in the early stages of the disease, we classified patients into two subgroups, those with disease duration of 3 years or less and those with disease duration longer than 3 years. We investigated the statistical diagnostic accuracy in these two subgroups.

Statistical analysis

Sample size was determined by power analysis comparing two means. According to our previous study, we estimated the mean H/M to be 2.45 ± 0.47 (mean \pm SD) in control patients [20]. We hypothesized that H/M should be lower in Parkinson disease than in other disorders and that the MIBG test should detect the difference of 0.1 of H/M. The sample size was calculated as 398 for a power greater than 80% and an α error of 0.05, one-sided test.

Owing to its non-Gaussian distribution, the difference in H/M in the groups of patients with Parkinson disease and with other disorders was statistically analyzed using the non-parametric Mann-Whitney *U* test. The correlation between H/M and the severity (H-Y grades or UPDRS-3 scores) or duration of the illness was analyzed using the non-parametric Spearman's rank correlation test. All statistical analyses were carried out using GraphPad Prism 4.0 for Windows (GraphPad Software, San Diego, CA, USA, <http://www.graphpad.com>). Data were expressed as mean \pm SD. *P* values less than 0.05 were considered statistically significant.

Results

Subjects characteristics

Excluding three patients (one because of cardiomyopathy and two because they had been prescribed selegiline 10 mg), 400 patients were included in the study. Of these, 267 were diagnosed as having Parkinson disease according to the UK PD Brain Bank Clinical Diagnostic Criteria. According to the UK PD Brain Bank Criteria, patients with severe disturbance of cognition in the early phase were not included in those having Parkinson disease, but patients presenting with

mild-to-moderate cognitive disturbances were included. Thirty-three patients showed clinical features suggesting Lewy body disease, and they were included in Parkinson disease because they fulfilled the criteria for Parkinson disease. Additionally, no abnormal MRI findings suggested multiple system atrophy in any of the 267 patients. Of the remaining 133 patients who did not fulfill the criteria for Parkinson disease, 76 had features typical of diseases other than Parkinson; these persons had multiple system atrophy ($n = 36$), progressive supranuclear palsy ($n = 15$), essential tremor ($n = 12$), Alzheimer's disease with extrapyramidal signs ($n = 5$), corticobasal degeneration ($n = 3$), stroke ($n = 3$), drug-induced Parkinsonism ($n = 1$), and motor neuron disease with extrapyramidal signs ($n = 1$) (Fig. 1). The remaining 57 patients had extrapyramidal signs but were not given a specific clinical diagnosis. We accepted all of these 133 patients as not having Parkinson disease (Table 1).

Interhospital reliability

Interhospital agreement of the MIBG was evaluated in 10 patients (eight with Parkinson disease and two with progressive supranuclear palsy). The intervals of the tests in the two hospitals were 8 months to 3 years. The interhospital agreement was a mean bias of 1.03 with limits of agreement of 0.87–1.22 (95% CI) for early H/M and a mean bias of 1.08 with limits of agreement of 0.78–1.50 (95% CI) for late H/M. Agreement of the tests was higher in early H/M than in late H/M (Fig. 2).

Relationship between cardiac MIBG uptake and the severity and duration of Parkinson disease

Cardiac accumulation of MIBG was significantly reduced in patients with Parkinson disease compared with those without Parkinson disease (Fig. 3). The mean early H/M value was 2.39 ± 0.49 in patients with other

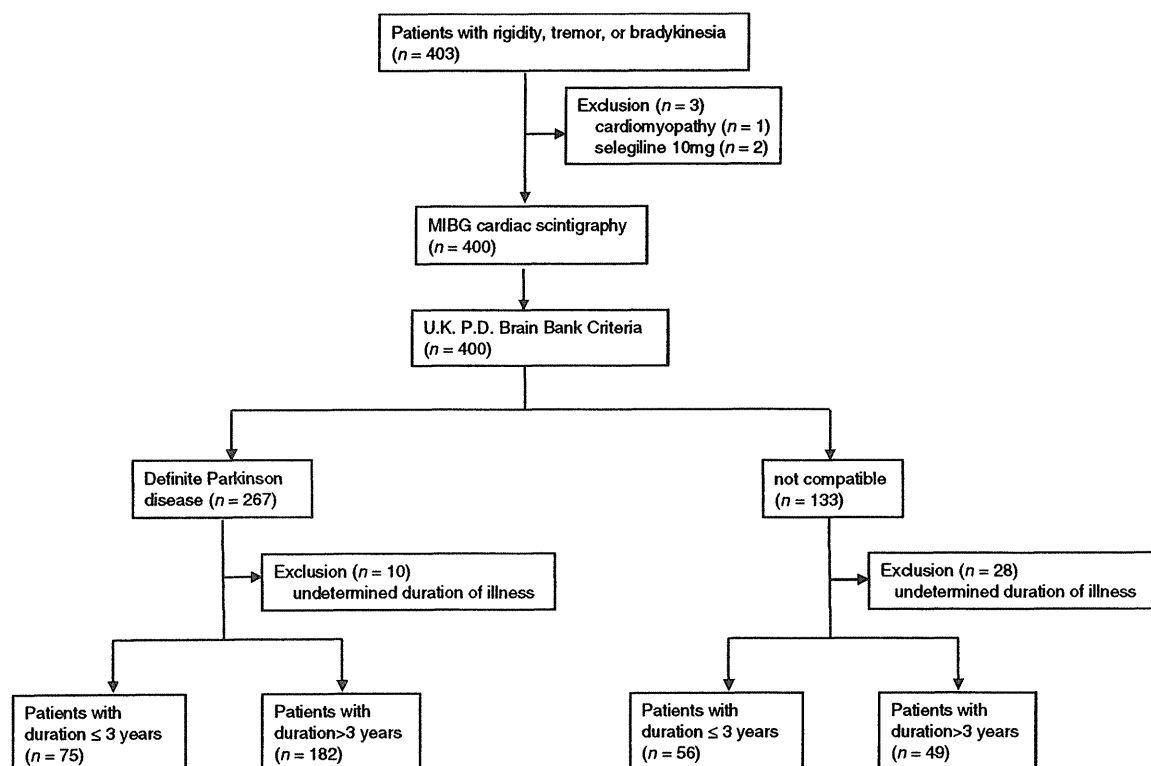


Figure 1 Flow diagram of the eligible patients and the enrolling process of the study. Eligible patients were 403 consecutive patients who underwent MIBG cardiac scintigraphy because of extrapyramidal signs; three patients were excluded: one with cardiomyopathy and one using selegiline (10 mg); this left 400 enrolled patients. According to the UK Brain Bank criteria of Parkinson's disease as a reference standard, 267 of 400 patients had Parkinson disease, and the remaining 133 patients had other disorders. Diagnostic accuracy was analyzed in 400 patients. Of the 267 patients with Parkinson disease, 10 with unspecified disease duration were excluded. Of the 133 patients without Parkinson disease, 28 with unspecified disease duration were excluded. The remaining patients were separated into two groups: those with a disease duration of 3 years or less (75 patients with Parkinson disease and 56 patients without Parkinson disease) and those with a disease duration longer than 3 years (56 patients with Parkinson disease and 49 patients without Parkinson disease).

Table 1 Patient characteristics

	<i>n</i>	M/F	Age [Mean (SD)]
Parkinson disease	267	116/151	70.1 (10.0)
Other disorders without Parkinson disease	133	76/57	70.4 (8.7)

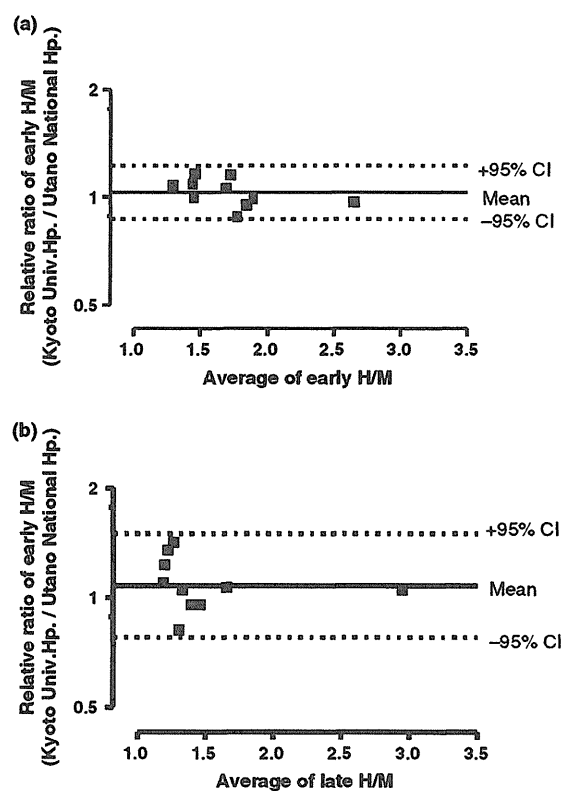


Figure 2 Bland-Altman plots for interhospital agreement of early H/M (a) and late H/M (b). The vertical axis represents the ratio of H/M performed at Kyoto University Hospital to those performed at Utano National Hospital. The bias was expected to be 1.0 when there is complete interhospital agreement.

disorders and 1.66 ± 0.33 in patients with Parkinson disease; this difference was highly significant ($P < 0.001$). Similarly, the mean late H/M value of 1.44 ± 0.39 in patients with Parkinson disease was significantly lower than that for patients with other extrapyramidal disorders (2.42 ± 0.62 ; $P < 0.001$).

According to the H-Y grades, 267 patients with Parkinson disease were separated into five groups: H-Y 1 ($n = 12$), H-Y 2 ($n = 49$), H-Y 3 ($n = 74$), H-Y 4 ($n = 96$), and H-Y 5 ($n = 18$). Eighteen patients were excluded from the subgroup analysis because the H-Y grade could not be specified. The relationship

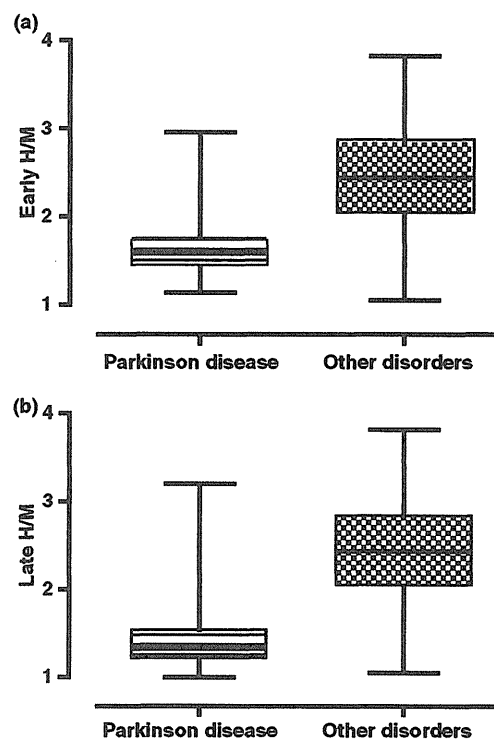


Figure 3 Box plot with whiskers presenting early H/M (a) and late H/M (b) of patients with Parkinson disease and those with other disorders. Early and late H/M was significantly lower in patients with Parkinson disease than it was in patients with other disorders. Box shoulders represent the 25th and 75th percentiles of the distribution and whiskers represent minimum and maximum data of the groups. The difference in H/M was significant between patients with Parkinson disease and those with other disorders.

between H-Y grades and H/M was analyzed in the remaining 249 patients (Fig. 4a and b). There was a significant negative correlation between early H/M and H-Y grade (Spearman $r = -0.184$, $P = 0.0036$). Similarly, late H/M also was negatively correlated with H-Y grade ($r = -0.23$, $P = 0.0004$). The relationship between UPDRS-3 score and H/M was analyzed in 116 patients whose UPDRS-3 scores were obtained. There was a significant negative correlation between late H/M and UPDRS-3 scores [$r = -0.215$, $P = 0.0204$ (early H/M) and $r = -0.231$, $P = 0.013$ (late H/M)] (Fig. 4c and d). In addition, the relationship between the duration of the illness and H/M was analyzed in 257 patients. Ten patients were excluded from this analysis because the duration of their illness had not been determined. Early and late H/M reduction correlated significantly with the duration of illness ($r = -0.1548$, $P = 0.013$ for early H/M, $r = -0.1379$, $P = 0.027$ for late H/M) (Fig. 4e and f).

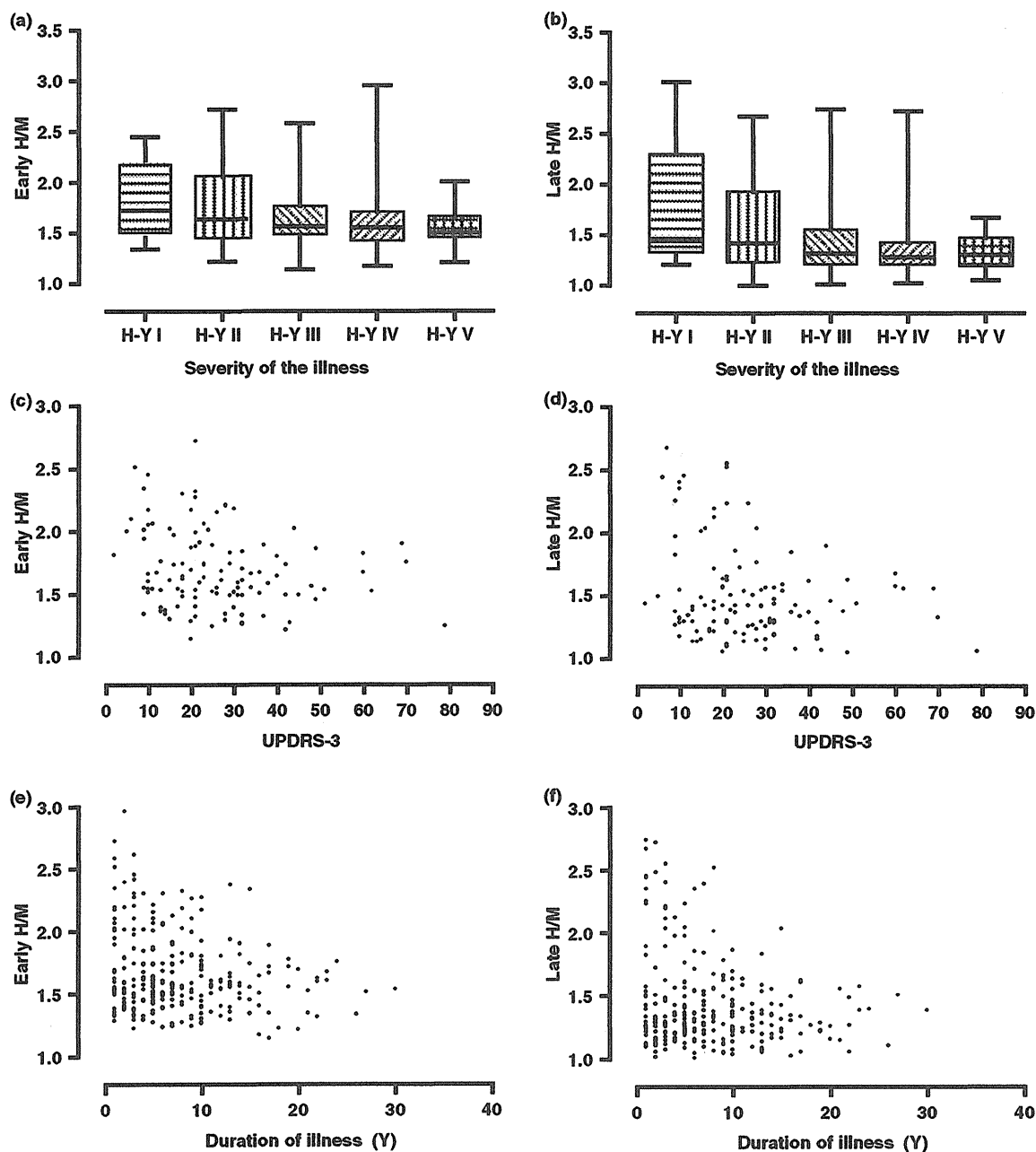


Figure 4 Relationship of H/M to the severity and duration of Parkinson disease. Early and late H/M decreased with both the Hoehn-Yahr grades (range, 1–5; 1 = unilateral disability, 5 = bed- or wheelchair-bound) (a, b) and UPDRS-3 scores (semiquantitative scale of motor disturbance of unified Parkinson’s disease rating scale, range, 0–108, 0 = best, 108 = worst) (c, d). Furthermore, H/M decreased in parallel with the duration of the illness (e, f).

Determination of a cut-off point of H/M as a diagnostic marker

The area under the ROC curve was 0.89 (95% CI, 0.85–0.92) for early H/M and 0.89 (0.86–0.93) for late H/M. According to the ROC curves, the most discriminative

cut-off point was 1.92 for early H/M and 1.68 for late H/M (Fig. 5). The sensitivity and specificity was 81.3% (95% CI, 76.1–85.8%) and 85.0% (77.7–90.6%) for early H/M (<1.92) and 84.3% (79.3–88.4%) and 89.5% (83.0–94.1%) for late H/M (<1.68). At these cut-off points, the positive likelihood ratio was 5.40

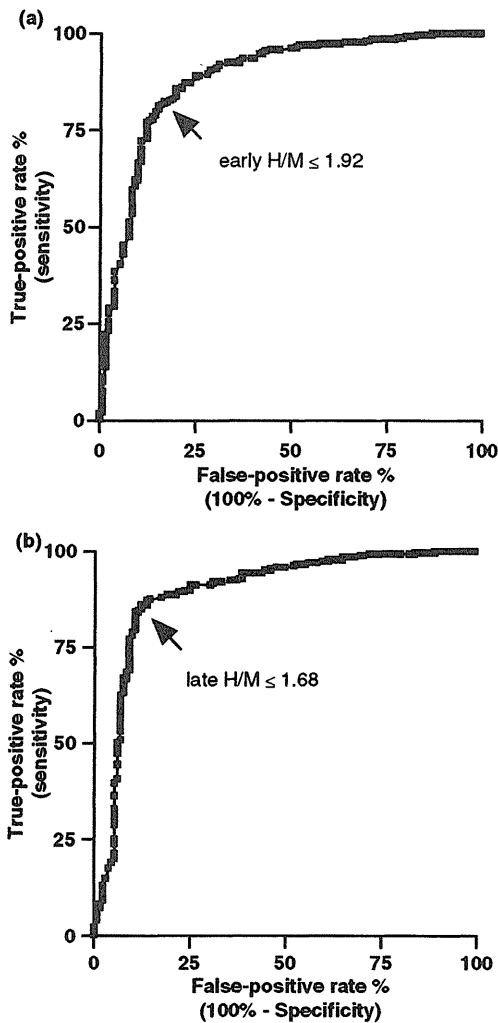


Figure 5 Curves of receiver-operator characteristics (ROC) of the diagnosis of Parkinson disease in early H/M (a) and late H/M (b). The most discriminative cut-off point (near the left upper corner of the graph) is represented by arrows. The sensitivity and specificity were determined according to the ROC curves.

(2.71–10.8) for early H/M and 8.01 (2.84–22.6) for late H/M. The negative likelihood ratio was 0.22 (0.15–0.33) for early H/M and 0.18 (0.11–0.29) for late H/M. The diagnostic accord between MIBG criteria and UK PD brain bank diagnostic criteria is shown in Table 2.

Analysis in patients with short and long duration

According to disease duration, 362 patients were classified into two subgroups: 131 patients with disease duration of 3 years or less and 231 patients with disease duration more than 3 years. Seventy-five of the 131 patients and 182 of the 231 patients, respectively, were

Table 2 Contingency table for diagnosis of Parkinson disease

Patients category	MIBG test	UK brain bank criteria	
		PD	non-PD
Total	Early H/M		
	+	217	20
	-	50	113
	Late H/M		
	+	225	14
	-	42	119
Duration ≤ 3 years	Early H/M		
	+	57	9
	-	18	47
	Late H/M		
	+	55	7
	-	20	49
Duration > 3 years	Early H/M		
	+	152	5
	-	30	44
	Late H/M		
	+	164	5
	-	18	44

diagnosed with Parkinson disease according to the UK PD brain bank criteria. Thirty-eight patients (10 with Parkinson disease and 28 with other disorders) were excluded from the subgroup analysis because of an undetermined onset of the extrapyramidal signs (Fig. 1). ROC curves were obtained, and these curves were used to determine the most discriminative cut-off points for diagnosing Parkinson disease in the subgroups (Fig. 6).

Analyses of the subgroup of patients with duration of 3 years or less led to an area under the ROC curve of 0.86 (0.79–0.92) for early H/M and 0.85 (0.78–0.92) for late H/M. According to the ROC curves, the most discriminative cut-off points were 2.04 for early H/M and 1.84 for late H/M. For early H/M, the sensitivity and specificity were 76.0% (64.8–85.1%) and 83.9% (71.7–92.4%). For late H/M, the sensitivity and specificity were 73.3% (61.9–82.9%) and 87.5% (75.9–94.8%). Positive likelihood ratios were 4.73 for early H/M and 5.87 for late H/M.

Analyses of the subgroup of patients with duration longer than 3 years led to an area under the ROC curve of 0.91 (0.86–0.96) for early H/M and 0.92 (0.86–0.98) for late H/M. The sensitivity and specificity were 83.5% (77.3–88.6%) and 89.8% (77.8–96.6%) (early H/M < 1.83) or 90.1% (84.8–94.0%) and 89.8% (77.8–96.6%) (late H/M < 1.68). Positive likelihood ratios were 8.19 for early H/M and 8.83 for late H/M. The relationship of MIBG test results and UK PD brain bank criteria is shown in Table 2, and the accuracy of the MIBG test in diagnosing Parkinson disease is summarized in Table 3.

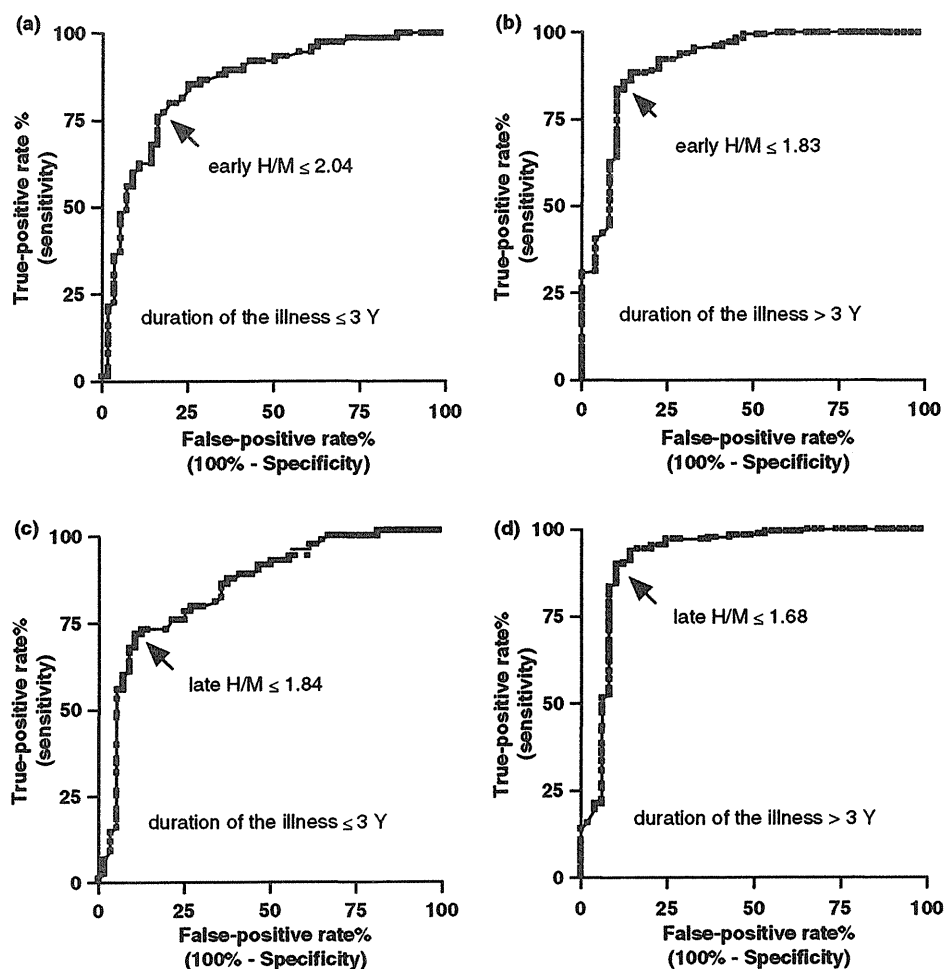


Figure 6 ROC curves in patients with shorter and longer durations of illness. ROC curves were created in a subgroup of patients with disease duration of 3 years or less (a, c) and with disease duration longer than 3 years (b, d). Recruitment of the subjects is demonstrated in Fig. 1b. The most discriminative cut-off points were set nearest to the upper left corner of the graph (arrows).

Table 3 Diagnostic accuracy of MIBG test in diagnosis of Parkinson disease

	Early H/M			Late H/M		
	Duration ≤ 3 years	Duration > 3 years	Total	Duration ≤ 3 years	Duration > 3 years	Total
AUC of ROC	0.86 (0.79–0.92)	0.91 (0.86–0.97)	0.89 (0.85–0.92)	0.85 (0.78–0.92)	0.92 (0.86–0.98)	0.89 (0.86–0.93)
Most discriminative cut-off point	2.04	1.83	1.92	1.84	1.68	1.68
Sensitivity, %	76.0 (64.8–85.1)	83.5 (77.3–88.6)	81.3 (76.1–85.8)	73.3 (61.9–82.9)	90.1 (84.8–94.0)	84.3 (79.3–88.4)
Specificity, %	83.9 (71.7–92.4)	89.8 (77.8–96.6)	85.0 (77.7–90.6)	87.5 (75.9–94.8)	89.8 (77.8–96.6)	89.5 (83.0–94.1)
Positive likelihood ratio	4.73 (1.83–12.2)	8.19 (1.42–47.2)	5.40 (2.71–10.8)	5.87 (1.68–20.5)	8.83 (1.44–54.1)	8.00 (2.84–22.6)
Negative likelihood ratio	0.29 (0.17–0.48)	0.18 (0.10–0.33)	0.22 (0.15–0.33)	0.30 (0.19–0.48)	0.11 (0.04–0.30)	0.18 (0.11–0.29)

Parenthesis indicates 95% confidential intervals.

Discussion

Consistent with previous studies, cardiac accumulation of MIBG has been shown to be significantly reduced in

patients with Parkinson disease [10,12,14,15]. In previous studies, it has been controversial whether reduction in H/M is associated with the severity and duration of the illness [1,11,21], and the controversy could depend

on the size of the study sample. In the current study, a reduction in H/M was mildly but significantly associated with the severity and duration of the illness. Orimo and colleagues demonstrated that a reduction in cardiac MIBG accumulation reflects the degeneration of post-ganglionic sympathetic nerve terminals in the myocardium [8]. In addition to sporadic patients, cardiac uptake of ^{18}F -fluorodopamine is also reduced in patients with a mutation or triplication of the α -synuclein gene [22], which causes familial Parkinson disease with autosomal dominant inheritance [23]. In this context, a reduction in MIBG cardiac accumulation reflects the systemic pathological process of the disease and may be a peripheral biological marker of Parkinson disease including triplication of the α -synuclein gene.

The diagnostic accuracy of index test is limited by that of standard reference test and it was not confirmed pathologically in this study. In addition to this limitation the following several points can be limitation of the study. In contrast to α -synuclein gene triplication, MIBG cardiac accumulation is preserved in patients with mutations in the Park2 gene [24] and they may be diagnosed with definite Parkinson disease according to UK PD brain bank criteria. A recent study suggests that cardiac MIBG accumulation is often preserved in patients with hereditary Parkinsonism including LRRK2 [25]. According to the UK PD brain bank criteria patients with autosomal dominant hereditary Parkinsonism may not be diagnosed as Parkinson disease because patients with two or more members who are diagnosed as the disease are excluded. Additionally, cardiac accumulation of MIBG may be preserved in an early stage of Parkinson disease as shown in Fig. 4. Therefore, patients with Park2 mutations or those in the early stages of Parkinson disease may show false-negative results on the MIBG test. There were no specific neurological features in patients with preserved MIBG uptake who were diagnosed as Parkinson disease.

In a Bland-Altman plot, the mean interhospital bias of H/M was small (1.03 for early H/M and 1.08 for late H/M, complete agreement was expected when the bias was calculated as 1.0), but the range of limits was relatively wide. The interhospital concordance might have been influenced by the intervals of the tests because cardiac MIBG uptake can decrease during the course of Parkinson disease [26]. In the context of temporal influences, interhospital reliability may be accepted clinically as an objective diagnostic marker especially in early H/M.

As shown in Fig. 4e and f, H/M was preserved above 2.0 in some patients with a short duration of Parkinson disease. In patients with a disease duration of 10 years or more, late H/M was lower than 2.2 without excep-

tion. These results suggest the possibility that peripheral sympathetic denervation succeeds or precedes degeneration of striatal dopaminergic nerve terminals. In the subgroup of patients with a disease duration of 3 years or less, the sensitivity was low; however, the positive likelihood ratio, area under the ROC curve, and specificity were high enough to make a diagnosis.

Acknowledgements

We would like to thank Yoshihisa Matsumoto for his technical support with MIBG scintigraphy at Utano National Hospital. We also thank Dr Fukashi Udata at Sumitomo Hospital, Osaka, Japan for helpful discussion.

Funding

This work was supported by grants-in-aid for scientific research from the Minister of Health, Labor, and Welfare of Japan and the National Hospital Organization in the management and preparation of the study.

References

1. Spiegel J, Mollers MO, Jost WH, *et al.* FP-CIT and MIBG scintigraphy in early Parkinson's disease. *Movement Disorders* 2005; **20**: 552–561.
2. Seibyl JP, Marek KL, Quinlan D, *et al.* Decreased single-photon emission computed tomographic [123I]beta-CIT striatal uptake correlates with symptom severity in Parkinson's disease. *Annals of Neurology* 1995; **38**: 589–598.
3. Brooks DJ, Playford ED, Ibanez V, *et al.* Isolated tremor and disruption of the nigrostriatal dopaminergic system: an 18F-dopa PET study. *Neurology* 1992; **42**: 1554–1560.
4. Marshall V, Grosset D. Role of dopamine transporter imaging in routine clinical practice. *Movement Disorders* 2003; **18**: 1415–1423.
5. Mitsui J, Saito Y, Momose T, *et al.* Pathology of the sympathetic nervous system corresponding to the decreased cardiac uptake in 123I-metaiodobenzylguanidine (MIBG) scintigraphy in a patient with Parkinson disease. *Journal of the Neurological Sciences* 2006; **243**: 101–104.
6. Orimo S, Oka T, Miura H, *et al.* Sympathetic cardiac denervation in Parkinson's disease and pure autonomic failure but not in multiple system atrophy. *Journal of Neurology, Neurosurgery and Psychiatry* 2002; **73**: 776–777.
7. Iwanaga K, Wakabayashi K, Yoshimoto M, *et al.* Lewy body-type degeneration in cardiac plexus in Parkinson's and incidental Lewy body diseases. *Neurology* 1999; **52**: 1269–1271.
8. Orimo S, Amino T, Itoh Y, *et al.* Cardiac sympathetic denervation precedes neuronal loss in the sympathetic ganglia in Lewy body disease. *Acta Neuropathologica (Berlin)* 2005; **109**: 583–588.
9. Goldstein DS, Holmes C, Li ST, Bruce S, Metman LV, Cannon RO, 3rd. Cardiac sympathetic denervation in

- Parkinson disease. *Annals of Internal Medicine* 2000; **133**: 338–347.
10. Goldstein DS. Dysautonomia in Parkinson's disease: neurocardiological abnormalities. *Lancet Neurology* 2003; **2**: 669–676.
 11. Nagayama H, Hamamoto M, Ueda M, Nagashima J, Katayama Y. Reliability of MIBG myocardial scintigraphy in the diagnosis of Parkinson's disease. *Journal of Neurology, Neurosurgery and Psychiatry* 2005; **76**: 249–251.
 12. Orimo S, Ozawa E, Nakade S, Sugimoto T, Mizusawa H. (123)I-metaiodobenzylguanidine myocardial scintigraphy in Parkinson's disease. *Journal of Neurology, Neurosurgery and Psychiatry* 1999; **67**: 189–194.
 13. Yoshita M. Cardiac uptake of [123I]MIBG separates PD from multiple system atrophy. *Neurology* 2000; **54**: 1877–1878.
 14. Takatsu H, Nagashima K, Murase M, *et al.* Differentiating Parkinson disease from multiple-system atrophy by measuring cardiac iodine-123 metaiodobenzylguanidine accumulation. *JAMA* 2000; **284**: 44–45.
 15. Druschky A, Hilz MJ, Platsch G, *et al.* Differentiation of Parkinson's disease and multiple system atrophy in early disease stages by means of I-123-MIBG-SPECT. *Journal of the Neurological Sciences* 2000; **175**: 3–12.
 16. Orimo S, Takahashi A, Uchiyama T, *et al.* Degeneration of cardiac sympathetic nerve begins in the early disease process of Parkinson's disease. *Brain Pathology* 2007; **17**: 24–30.
 17. Gerlach M, Hendrich A, Hueber R, *et al.* Early detection of Parkinson's disease: unmet needs. *Neuro-Degenerative Diseases* 2008; **5**: 137–139.
 18. Daniel SE, Lees AJ. Parkinson's Disease Society Brain Bank, London: overview and research. *Journal of Neural Transmission. Supplementum* 1993; **39**: 165–172.
 19. Bland JM, Altman DG. Statistical methods for assessing agreement between two methods of clinical measurement. *Lancet* 1986; **1**: 307–310.
 20. Sawada H, Yamakawa K, Yamakado H, *et al.* Cocaine and phenylephrine eye drop test for Parkinson disease. *JAMA* 2005; **293**: 932–934.
 21. Hamada K, Hirayama M, Watanabe H, *et al.* Onset age and severity of motor impairment are associated with reduction of myocardial 123I-MIBG uptake in Parkinson's disease. *Journal of Neurology, Neurosurgery and Psychiatry* 2003; **74**: 423–426.
 22. Singleton A, Gwinn-Hardy K, Sharabi Y, *et al.* Association between cardiac denervation and parkinsonism caused by alpha-synuclein gene triplication. *Brain* 2004; **127**: 768–772.
 23. Singleton AB, Farrer M, Johnson J, *et al.* alpha-Synuclein locus triplication causes Parkinson's disease. *Science* 2003; **302**: 841.
 24. Orimo S, Amino T, Yokochi M, *et al.* Preserved cardiac sympathetic nerve accounts for normal cardiac uptake of MIBG in PARK2. *Movement Disorders* 2005; **20**: 1350–1353.
 25. Quattrone A, Bagnato A, Annesi G, *et al.* Myocardial 123metaiodobenzylguanidine uptake in genetic Parkinson's disease. *Movement Disorders* 2008; **23**: 21–27.
 26. Li ST, Dendi R, Holmes C, Goldstein DS. Progressive loss of cardiac sympathetic innervation in Parkinson's disease. *Annals of Neurology* 2002; **52**: 220–223.

FULL-LENGTH ORIGINAL RESEARCH

Negative motor seizure arising from the negative motor area: Is it ictal apraxia?

*Akio Ikeda, †Ken-ichi Hirasawa, *Masako Kinoshita, *Takefumi Hitomi,
*Riki Matsumoto, *Takahiro Mitsueda, ‡§Jun-ya Taki, *Morito Inouch,
‡Nobuhiro Mikuni, †Tomokatsu Hori, §Hidenao Fukuyama, ‡Nobuo Hashimoto,
¶Hiroshi Shibasaki, and *Ryosuke Takahashi

*Department of Neurology, Kyoto University School of Medicine, Shogoin, Sakyo-ku, Kyoto, Japan;
†Department of Neurosurgery, Tokyo Women's Medical University, Tokyo, Japan; ‡Department of Neurosurgery,
Kyoto University School of Medicine, Shogoin, Sakyo-ku, Kyoto, Japan; §Human Brain Research Center,
Kyoto University School of Medicine, Shogoin, Sakyo-ku, Kyoto, Japan; and ¶Takeda General Hospital,
Ishida-mori, Fushimi-ku, Kyoto, Japan

SUMMARY

Purpose: Seizure manifesting motor arrest, that is, negative motor seizure (NMS), is a rare epileptic condition in which only inability to conduct voluntary movements or praxis is produced, although consciousness is preserved. The negative motor area (NMA) seems to be responsible, but its generator mechanism has not yet been clarified.

Patients and Methods: Three patients manifesting NMS were investigated. Two patients (ages 33 and 17) with intractable frontal lobe epilepsy had subdural grid implantation for epilepsy surgery, and one (age 77) had scalp electroencephalography (EEG) monitoring.

Results: Ictal semiologies commonly observed, at least in the two patients, were found as follows; (1) indescribable or ill-localized aura, (2) repetitive involuntary vocalization, (3) inability to speak, (4) inability to move the extremities, and (5) subse-

quent evolution to positive motor seizures. Awareness and comprehension were preserved throughout the episode before generalized seizures. In two patients with epicortical EEG recording, ictal activity arose from the lateral NMA in one, and from the rostral supplementary motor area in the other. Cortical stimulation at NMA in one patient elicited symptoms identical to NMS. Another patient had scalp EEG and magnetic resonance imaging (MRI) abnormality, both suggesting the epileptogenic focus in the mesial frontal area. **Conclusion:** We showed that (1) NMS was a rare condition in patients with seizure focus in the frontal lobe, and (2) that the NMA was responsible for the symptoms. The documented state in the present study may reflect ictal apraxia, but it requires further investigation.

KEY WORDS: Negative motor seizure, Speech arrest, Negative motor area, Supplementary motor area.

Penfield and Jasper (1954), and later Lüders et al. (1987), reported that a certain cortical area in the frontal cortices produced arrest of voluntary movements, during cortical mapping in patients with intractable partial epilepsy by means of high-frequency electric cortical

stimulation; this cortical area was given the name negative motor area (NMA) (Lüders et al., 1987). It produced the cessation of the voluntary tonic muscle contraction or the rapid alternating movements without loss of awareness, called a negative motor response (NMR).

By contrast, seizure manifesting solely motor arrest without loss of awareness is a rare epileptic condition in which no positive motor symptom but only inability to conduct the voluntary movements is produced, even though consciousness and cognitive function are preserved. It can be called a negative motor seizure (NMS), following NMR because of its similarity. It is entirely

Accepted February 8, 2009; Early View publication May 12, 2009.
Address correspondence to Akio Ikeda, M.D., D.M.S., Department of Neurology, Kyoto University School of Medicine, Shogoin, Sakyo-ku, Kyoto 606, Japan. E-mail: akio@kuhp.kyoto-u.ac.jp. [Correction added after online publication 20 May 2009: Spelling of Morito Inouch changed from Moritoh to Morito below title of paper.]

Wiley Periodicals, Inc.
© 2009 International League Against Epilepsy

different from focal ictal paresis or ictal monoparesis (Fisher, 1978; Abou-Khalil et al., 1995; So, 1995; Noachtar & Lüders, 1999, 2000; Matsumoto et al., 2005) or epileptic negative myoclonus (Guerrini et al., 1993), which should show mainly weakness or abrupt interruption among continuous muscle contraction, respectively. However, (1) NMS has not been well differentiated from focal ictal paresis, and (2) it has not yet been fully proven whether NMA is responsible for NMS, although semiology of NMS is very similar to NMR produced by cortical stimulation of NMA. In fact, the clinical semiology of seizures from NMA in humans is still uncertain. Previously, three patients with focal "ictal paresis" were reported as having "focal akinetic seizures" (Noachtar & Lüders, 1999). These patients demonstrated an inability to hold the paretic arm outstretched when asked to do so, and they were conscious and speech was not impaired. The two patients had scalp electroencephalography (EEG) monitoring showing the ictal focus in the contralateral central area, and one had subdural EEG recording before epilepsy surgery. EEG disclosed that the ictal onset zone was in the mesial frontal area, possibly corresponding to the supplementary motor area (SMA). Although they could not find the seizure focus in the NMA, they speculated that the ictal onset zone was in the NMA.

Ictal speech arrest due to NMS is also different from ictal aphasia. Aphasic seizure is a well-known, simple partial seizure, which arises from or involves the language areas such as Broca's area (Hamilton & Matthews, 1979), Wernicke's area (Salanova et al., 1995), and basal temporal language area (Kirshner et al., 1995). In addition, ictal speech arrest has been described when the seizures arose from SMA (Penfield & Rasmussen, 1950), but it still remains unresolved whether this condition was produced because of a dysfunction of the NMA within the SMA.

Herein we present three patients who commonly showed ictal motor arrest and/or speech arrest. Two of them had subdural EEG recording, showing ictal activity arising from the NMA in one, and from the rostral SMA in the other. In another patient, scalp EEG and magnetic resonance imaging (MRI) both suggested that the seizure focus was in the mesial frontal area. We showed that (1) NMS is a rare condition in patients with frontal lobe epilepsy or with seizure focus in the frontal lobe, and is different from ictal paresis; (2) the symptoms are often overlooked or unrecognized, and easily masked by the immediately upcoming robust positive motor symptoms; and (3) the NMA is responsible for the symptoms.

Previously the term of NMS was applied to a patient with ictal paresis in a case report (Villani et al., 2006). However, because of the preceding reasons, we will use NMS to describe the rather clear clinical situation based on the present findings, being distinct from ictal paresis.

PATIENTS AND METHODS

Patients

We defined NMS as a partial seizure where, by semiology, no positive motor symptoms but only the inability to conduct the voluntary movements or arrest of speech without impairment of comprehension was produced, even though consciousness and cognitive function were preserved. Patients who showed arrest of movements predominantly caused by weakness and decreased tonus of the affected limbs were not included in this study.

Among epileptic patients who had prolonged video-EEG monitoring in the Kyoto University Hospital (KUH) and in the Tokyo Women's Medical University Hospital (TWMUH), three patients presented with NMS. Two of them (Patients 1 and 2) had subdural EEG recording and functional mapping before epilepsy surgery, and another (Patient 3) had scalp EEG recording.

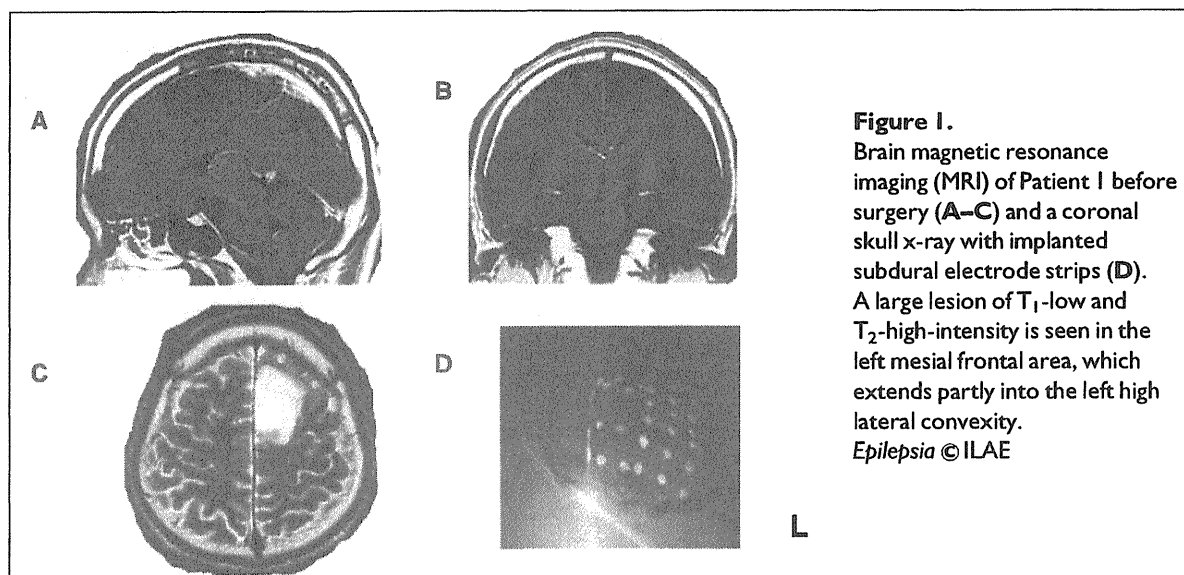
Patient 1 was a 33-year-old, right-handed man with a history of seizures during the 8 months prior to hospitalization. The abstract of the case presentation has been presented previously (Hirasawa et al., 2001). The first seizure occurred as a focal motor seizure involving the tongue, immediately followed by generalized tonic-clonic seizure (GTCS). After treatment with anticonvulsants, the patient had habitual, simple partial seizures occurring every few days as NMS, as described in the Table 1. The patient had no neurologic deficits. The patient had a T₁-low, T₂-high-intensity lesion in the left frontal area involving the mesial frontal to the high lateral convexity area (Fig. 1). The subdural electrode grids were implanted before surgery at TWMUH. Finally, the lesion and its surrounding area were resected and the patient had infrequent generalized seizures about three times per year; the pathologic diagnosis was anaplastic astrocytoma.

Patient 2 was a 17-year-old, left-handed man with a history of seizures since the age of 15. The first attack occurred as GTCS. Afterward, GTCSs occurred about once per month with a maximum frequency of seven times per week; these seizures were intractable to medication. The patient initially had a diagnosis of left hand focal motor seizures with Jacksonian march and secondarily GTCSs in the local hospital. He had no focal deficits. The MRI showed a cystic lesion in the right frontal area over the high lateral convexity (Fig. 2). The presence of the lesion, the detailed seizure semiology, and the scalp-recorded ictal EEG finding led us to the diagnosis of intractable right frontal lobe epilepsy. Subdural electrode grids were implanted over the right premotor area at KUH. The epilepsy surgery in this case was described in another paper for an entirely different purpose (Mikuni et al., 2007). The main epileptogenic area was resected and he was free from seizures, except for very brief auras every few months. Pathologic diagnosis was dysembryonic neuroepithelial tumor.

Patient	1	2	3
Handedness	R	L	R
Age/gender	33/man	17/man	77/woman
Ictal semiology	Indescribable aura ^a Repetitive vocalization ^a Inability to move the limbs ^a and tongue ^a Speech arrest ^b No loss of awareness ^b	Floating or rising sensation in the whole body ^a Inability to move the whole body ^b Speech arrest ^b No loss of awareness ^b Asymmetric tonic convulsion	Rhythmic vocalization ^a Speech arrest ^b Slow tongue wiggling ^a No loss of awareness ^b Slow movements of the right hand Very mild weakness of the right proximal upper limb
MRI	History of GTCS ^a A T1-low, T2-high, left mesial frontal lesion	History of GTCS ^a A cystic lesion in the right, high lateral premotor area	T ₂ -positive abnormality in the left mesial frontal surface
Type of EEG recording/interictal findings	Subdural Frequent spikes at ictal onset zone	Subdural Frequent spikes at ictal onset zone	Scalp Frequent spikes at Cz
Type of EEG recording/ictal findings	Subdural A2 showed 100-Hz burst activity, and then A2 and adjacent three electrodes showed 7–8 Hz spikes	Subdural Three electrodes initially showed 8–12 Hz rhythmic activities	Scalp No definite changes
Focus location: in relation to NMA	No NMA defined seizures arose from SMA close to VAC	Five electrodes defined as NMA, from which seizures arose	Most likely located on the SMA

GTCS, generalized tonic-clonic seizures, MRI, magnetic resonance imaging; L, left; EEG, electroencephalography; NMA, negative motor area; R, right; SMA, supplementary motor area; VAC, a line on the anterior commissure vertical to AC-PC line (a line crossing anterior commissure and posterior commissure line).

^aObserved in two patients. ^bObserved in three patients.



Patient 3 was a 77-year-old, right-handed woman who was admitted to KUH because of frequent attacks of inability to speak. Twenty days before admission the patient hit the occipital region of her head on the floor at home. She did not lose her consciousness but after half an hour her speech was incoherent. Three days later, the patient started having episodes of being unable to speak. The episodes lasted from several seconds to a minute. The

episodes increased in frequency and occurred 30 times per day. On admission, the patient was alert interictally and well-oriented. No motor or sensory impairments were observed. The patient had had no previous convulsions. Cranial computed tomography (CT) scan revealed a mild subdural effusion with slightly increased CT density throughout the left hemisphere (Fig. 3A). Cranial MRI showed a similar finding (Fig. 3B), and T₂- and

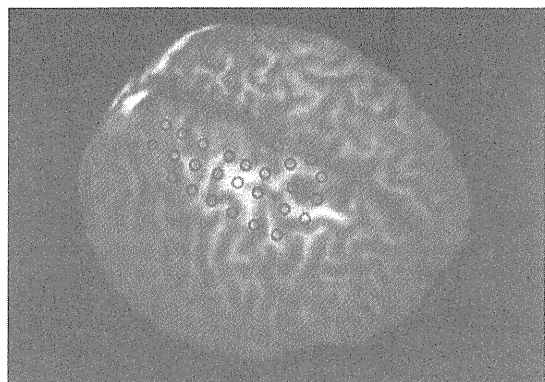


Figure 2.

Three-dimensional magnetic resonance imaging (3D-MRI) of Patient 2 viewed from the right anterior top. A cystic lesion is present in the right frontal, high lateral convexity. The whole brain with a level of 5 mm depth from the outer cortical surface is viewed. Only the subdural grid and strip electrodes placed on the lateral surface of the right cerebral cortex are viewed. A detailed location of electrodes relative to the cortical sulci and cystic lesion is shown in Fig. 6.

Epilepsia © ILAE

T2*-weighted images showed the low intensity area within the left superior frontal gyrus (Fig. 3C, D). Those findings strongly suggested a chronic course of small subdural hemorrhage after head trauma producing hemosiderin deposits. The patient was on 250 mg of carbamazepine (CBZ) and 1 month later, both subdural effusion and low intensity abnormality on T2*-weighted image disappeared. The patient has been free from seizures for the last 4 years.

Video-EEG monitoring and cortical mapping

Finally, subdural electrode grids were implanted in Patients 1 and 2 in the frontal area at and close to the lesion as described previously, in order to cure the lesion and intractable seizures. Long-term video-EEG monitoring with subdural electrodes was carried out for 14 days. All subdural electrodes were made of platinum (AD-TECH Corp., Racine, WI, U.S.A.) and were arranged as grids (8 × 2 and 5 × 4) or as strips (1 × 4) with a center-to-center interelectrode distance of 1 cm. Each electrode had a recording surface diameter of 3 mm. Patient 1 had seven 1 × 6 strips—four on the left mesial and three on the left lateral convexity—covering the lesion and its adjacent area. Patient 2 had two 2 × 8 grids and one 1 × 6 strip on the right lateral convexity and mesial frontal surface.

For recording cortical potentials, all subdural electrodes were referenced to a scalp electrode placed on the skin over the mastoid process, contralateral to the side of

implantation. All ictal EEGs were digitized by an analog-to-digital converter at a sampling rate of 500 Hz per channel in Patient 1 and of 200 Hz in Patient 2, and stored on an EEG 2100 (Nihon Kohden, Tokyo, Japan) for subsequent review and analysis. Seizures were recorded with a low-frequency filter (LFF) setting (−3 dB of down point) of AC amplifier to 0.016 Hz. High-frequency filter (HFF) (−3 dB of down point) was set to 120 or 60 Hz depending on the sampling rate of 500 or 200 Hz, and LFF and HFF were appropriately changed in data analysis. Display sensitivity was set to 50–75 μV/mm. The recording and display conditions followed those from the previous report (Ikeda et al., 1999).

Patients 1 and 2 had cortical mapping including 50 Hz, cortical electric stimulation [by delineating positive motor response, NMR, positive sensory response or speech arrest] and somatosensory evoked potentials (SEPs); the details of the methods have been described previously (Ikeda et al., 1992). Stimulus condition was set as trains of 50 Hz, electric current of square-wave pulses of alternate polarity for up to 5 s. Each pulse width was set to 0.5 ms, with a maximum intensity of 10 mA in Patient 1, and 0.3 ms with a maximum intensity of 15 mA in Patient 2.

In Patient 3, prolonged video-EEG monitoring was carried out for 24 h with scalp electrodes. All EEGs were digitized by an analog-to-digital converter at a sampling rate of 200 Hz per channel, and stored on an EEG 2100 (Nihon Kohden) for subsequent analysis. The recording conditions also followed those from the previous report (Ikeda et al., 1997).

A comparison of NMS and NMR

NMS was defined as described in the Patients section. NMR was also precisely defined previously (Lüders et al., 1987). Namely, it was defined as the cessation of voluntary tonic muscle contraction or rapid alternating movements without loss of awareness during high-frequency cortical stimulation, and it was assessed by examining the wiggling of the tongue from side-to-side, rapid alternating horizontal or vertical eye movements, rapid alternating hand or foot movements, and sustained muscle contraction of the extremities.

Symptoms of NMS were carefully analyzed in each patient based on the history and data documented by video obtained during video-EEG monitoring. NMR obtained during cortical high-frequency stimulation was also analyzed in each patient based on the documented materials including video tapes. Both findings were carefully compared.

RESULTS

Ictal semiology (Table 1)

In Patient 1, the seizures were always preceded by an indescribable feeling of auras, and thus he was very sure

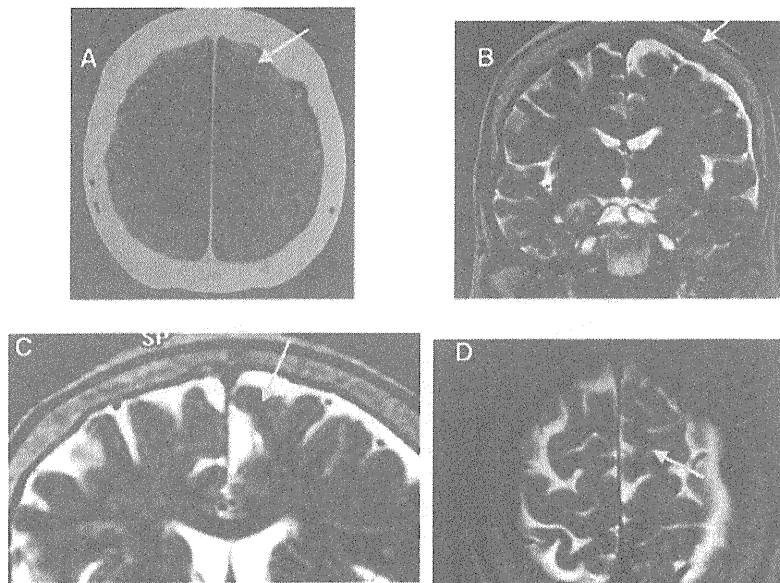


Figure 3.

An axial computed tomography (CT) (A) and magnetic resonance imaging (MRI) (B–D) of Patient 3. In the CT (A), subdural bleeding is seen as a high-density, subdural space in the left lateral convexity. It is also seen in the coronal T₂-weighted MRI as a high-intensity space in the left high lateral to mesial frontal area (B). T₂-weighted coronal and axial MRI (C,D) shows a low-intensity signal area in the mesial frontal (C) to high lateral convexity area (D), both belonging to the superior frontal gyrus around the VAC line (a line on the anterior commissure vertical to AC-PC line).

Epilepsia © ILAE

that the habitual seizure was coming. It was immediately followed by the abrupt onset of repetitive vocalization of “da-da-da-da-” for about 10 s, and then followed by complete arrest of motion and vocalization, while he was completely aware. During video-EEG monitoring, when examined by a doctor-in-charge (K.H.), both of the patient’s hands could remain in the air after being passively positioned, and no apparent weakness was observed. The tonus of the all extremities was normal by neurologic examination, but he could not move all of his extremities smoothly: not at all on the right, and severely impaired on the left. When bilateral finger tapping was tested, the patient could initially execute bilaterally, but became slower bilaterally, and then stopped completely on the right and partially on the left. He could not speak out loud at all, and could not stick out his tongue. The attacks lasted for about 1 min, and then he often gave a big sigh and told us that the seizure was over. He remembered everything and knew what he was doing but could not do anything during seizures.

In Patient 2, the seizures were always preceded by a floating or rising sensation that was ill-localized within the body. It was followed by an inability to move; he could no longer write, he could not hold a pencil in his right hand and thus often dropped it, and he could not hold a cellular

phone in his left hand. He could not speak out loud at all, although he knew what he wanted to say. When seizures occurred while he was standing, he could not maintain the standing posture steadily and thus stepped backward and fell on the ground. About once out of five occasions, the seizures proceeded to left hand convulsions, and then bilateral, left-side dominant, asymmetric GTCS.

In Patient 3, no auras preceded the seizures and the patient could suddenly not speak out loud at all or vocalize any words or even sounds. She had no convulsion or weakness and was aware of everything. She could communicate with hand and finger gestures, and thus the patient informed us of the beginning of an episode. At times, the family witnessed that at the beginning of event, the patient just moaned as “uh, uh, uh, uh, uh” in a rhythmic way, and then became completely mute. During the video/scalp-EEG monitoring, when the patient was examined during seizures by a doctor-in-charge (A.I.), she understood the spoken language well and thus she could follow the commands such as raising one hand and finger signs. The bilateral upper extremities showed normal tonus. She showed poor finger tapping on the right hand, and very mild proximal weakness was observed in the out-stretched right arm during only several, recorded seizures. Tongue protrusion was possible but wiggling was slow.

The patient remembered the test words given during the episodes. The seizures stopped abruptly and she gave a big sigh and started talking very fluently. After the seizures, the patient clearly mentioned that she had understood the situation and what had been said to her, and she knew what she had to answer, but that she could not during seizures.

EEG findings (Table 1) and functional mapping

In Patient 1, interictal, background activity was abnormal at A and B strips due to decreased amplitude of fast activity (Fig. 4; Table 1). More than 10 habitual seizures were recorded. All the seizures started with a sharp transient and low amplitude, 100-Hz burst activity for <1 s at A2 (a posterior margin of the lesion), followed by 7–8 Hz spike activity at A2. It spread into B2 and C3–5 (a part posterior to the lesion) within 10 s (Fig. 5A, B). It then at times spread into the adjacent, lateral convexity such as E, F, and G. Clinically initial vocalization and the symptoms of NMS were observed throughout this EEG change.

For cortical stimulation with 50-Hz electric pulses, C2 showed right hand positive motor responses, most likely the SMA proper hand area. D2–D4 showed right foot positive motor responses, most likely the primary foot motor area, and D1 showed right foot sensory impairment, most likely the primary foot sensory area. However, in the rest of the electrodes, we could not increase the stimulus intensity sufficiently to examine the NMR because both mesial and lateral frontal areas were epilep-

tically so irritable as to induce afterdischarges, simple partial seizures, or EEG seizure patterns very frequently. Therefore, it was uncertain whether NMA was present within the mesial frontal surface, mainly covered by strips of A, B, and C (Fig. 4).

In Patient 2, during video/subdural-EEG monitoring, the patient had a total of five habitual seizures (one with nonmotor symptoms and four with motor ones) (Fig. 6). At least two of the seizures were definitely preceded by very brief or ill-defined auras as described previously while the patient was lying on the bed silently, and those were immediately followed by left hand or bilateral convulsive seizures. Therefore, ictal semiologies belonging to NMS could not be examined objectively during the monitoring. In one nonmotor seizure in Fig. 7, the patient noticed the aura, and was unable to move or speak out loud at all for about 5 s, and associated ictal EEG lasted for 10 s.

In all the recorded seizures, the ictal EEG patterns started as 8–12 Hz rhythmic activities commonly at three electrodes (A6, A7, and C14) just over the cystic lesion rostral to the precentral sulcus, always before onset of tonic seizures by 4–34 s (average of 14 s) (Fig. 6). The pattern spread into the mesial and lateral sites once tonic seizures occurred. For 50-Hz cortical stimulation, six electrodes (A7, A8, C5–7, and C14), which partly included the ictal focus (A7, 8 and C14) and the adjacent, spread area (C5, 6), showed NMR involving the tongue and all extremities. Five of the six electrodes (A7, 8, C6,

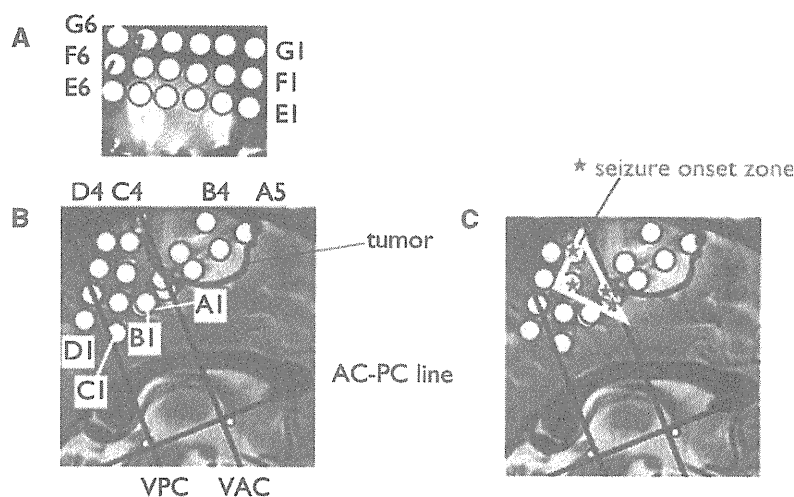


Figure 4.

Placement of subdural strip electrodes on the left lateral- (a) and mesial (b) frontal cortices in Patient 1. Strips E, F and G are placed in an anteroposterior direction with E1, F1, and G1 facing rostrally (A). A2 and B2 are located on the VAC line (a line on the anterior commissure vertical to AC-PC line), and the tumor is located on and anterior to the VAC line (B). Seizure-onset zone is labeled by asterisks at A2, B2, C3, and C4 (C), as also enclosed by an open triangle.

Epilepsia © ILAE

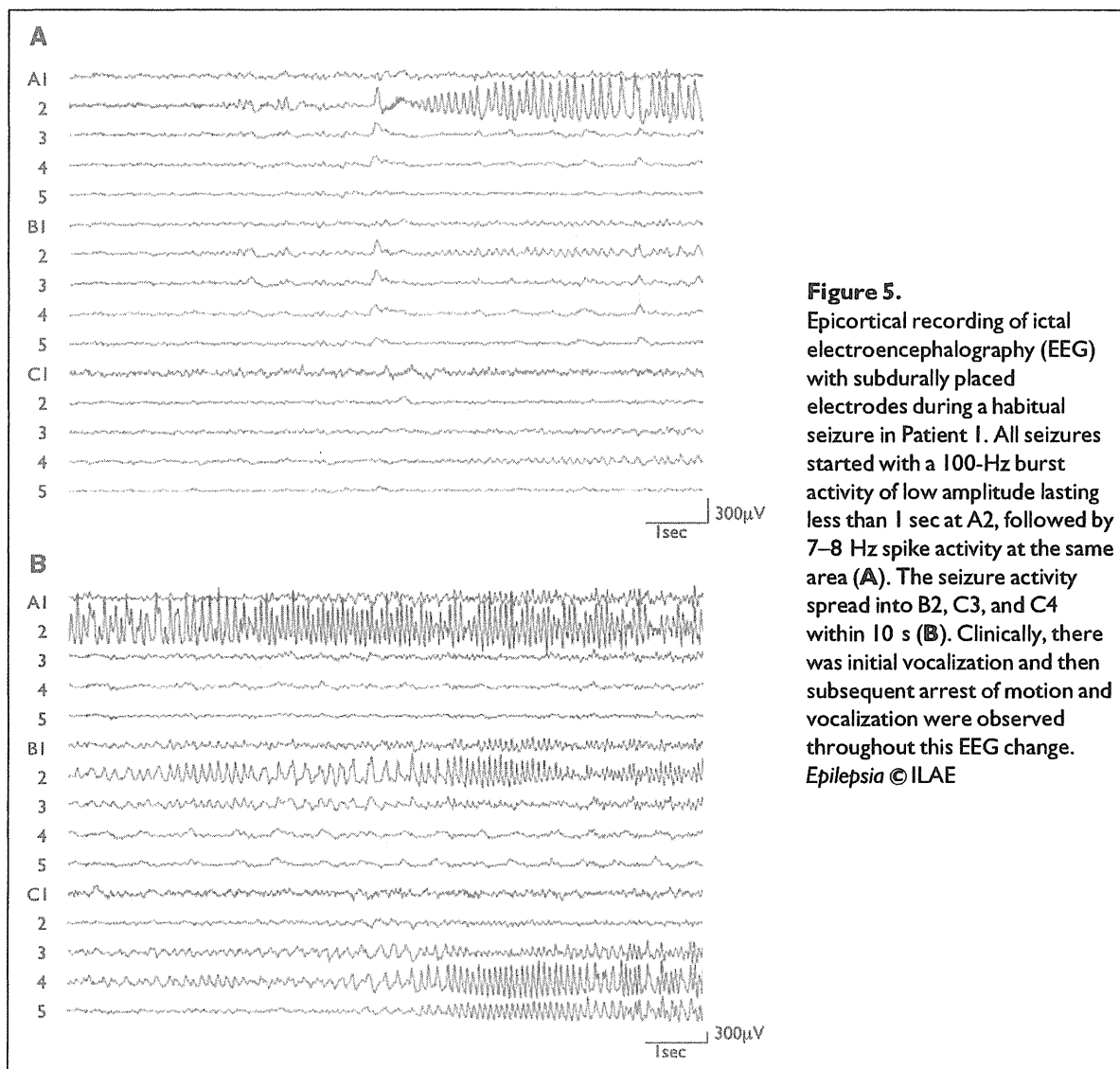


Figure 5. Epicortical recording of ictal electroencephalography (EEG) with subdurally placed electrodes during a habitual seizure in Patient 1. All seizures started with a 100-Hz burst activity of low amplitude lasting less than 1 sec at A2, followed by 7–8 Hz spike activity at the same area (A). The seizure activity spread into B2, C3, and C4 within 10 s (B). Clinically, there was initial vocalization and then subsequent arrest of motion and vocalization were observed throughout this EEG change. *Epilepsia* © ILAE

7, and 14) also showed the habitual aura elicited by the stimulus intensity of 5–13 mA (average of 7.4 mA) (Fig. 6).

In Patient 3, routine scalp EEG revealed normal posterior dominant rhythms for her age of 77 years, and no apparent focal slow or diminished fast activity was observed. No clear epileptiform discharges were recorded during routine EEG. Prolonged video/scalp-EEG monitoring recorded small, but consistent, spikes in the vertex (maximum at Cz) during the sleep period (Fig. 8). A total of 10 seizures were recorded, and a clear ictal pattern was not specifically recorded, but questionable, low-voltage 3–6 Hz spiky activities were recorded in the vertex region (maximum at Cz). Based on those findings, it was judged that the patient had status epilepticus partialis, most likely arising from the superior frontal gyrus.

Symptoms of NMS and NMR

Commonly observed ictal semiologies among the three patients were (1) inability to speak, (2) no loss of awareness, and (3) preserved comprehension. Common findings in two patients were (1) inability to move the extremities (Patients 1 and 2), (2) normal tonus of the extremities (Patients 1 and 3), (3) indescribable or ill-localized aura (Patients 1 and 2), (4) repetitive involuntary vocalization at the beginning (Patients 1 and 3), and (5) subsequent evolution to the positive motor seizures (Patients 1 and 2). Findings observed in only one patient but clearly confirmed were (1) progressive slowing and arrest of bilateral finger movements (Patient 1), and (2) slow movements of the distal hand (Patient 3) (Table 1).

In Patient 2, cortical stimulation at the ictal focus clearly elicited NMR of the tongue and all extremities; the