

tiple nodules, or lack of a circumscribed border with miliary spread into adjacent lung parenchyma.

There is a strong tendency for multicentric, multilobar, and bilateral lung involvement, which may reflect aerogenous spread. Mixtures of mucinous and nonmucinous tumors may rarely occur; then the percentage of invasive mucinous adenocarcinoma should be recorded in a comment. If there is at least 10% of each component, it should be classified as "Mixed mucinous and nonmucinous adenocarcinoma." Invasive mucinous adenocarcinomas (formerly mucinous BAC) need to be distinguished from adenocarcinomas that produce mucin but lack the characteristic goblet cell or columnar cell morphology of the tumors that have historically been classified as mucinous BAC. When mucin is identified by light microscopy or mucin stains in adenocarcinomas that do not meet the above criteria, this feature should be reported in a comment after classifying the tumor according to the appropriate terminology and criteria proposed in this classification. This can be done by adding a descriptive phrase such as "with mucin production" or "with mucinous features" rather than the term "invasive mucinous adenocarcinoma."

Pathology Recommendation 8

For adenocarcinomas formerly classified as mucinous BAC, we recommend they be separated from the adenocarcinomas formerly classified as nonmucinous BAC and depending on the extent of lepidic versus invasive growth that they be classified as mucinous AIS, mucinous MIA, or for overtly invasive tumors "invasive mucinous adenocarcinoma" (weak recommendation, low-quality evidence).

Colloid adenocarcinoma shows extracellular mucin in abundant pools, which distend alveolar spaces with destruction of their walls (Figure 8A). The mucin pools contain clusters of mucin-secreting tumor cells, which may comprise only a small percentage of the total tumor and, thus, be inconspicuous (Figure 8A).^{155,156} The tumor cells may consist of goblet cells or other mucin secreting cells. Colloid adenocarcinoma is found more often as a mixture with other adenocarcinoma histologic subtypes rather than as a pure pattern. A tumor is classified as a colloid adenocarcinoma when it is the predominant component; the percentages of other components should be recorded.¹⁵⁰ Cystic gross and histologic features are included in the spectrum of colloid adenocarcinoma, but in most cases, this is a focal feature. Cases previously reported as mucinous cystadenocarcinoma are extremely rare, and now these should be classified as colloid adenocarcinoma with cystic changes. The cysts are filled with mucin and lined by goblet or other mucin secreting cells (Figure 8B). The lining epithelium may be discontinuous and replaced with inflammation including a granulomatous reaction or granulation tissue. Cytologic atypia of the neoplastic epithelium is usually minimal.¹⁵⁷

Fetal adenocarcinoma consists of glandular elements with tubules composed of glycogen-rich, nonciliated cells that resemble fetal lung tubules (Figure 8C).⁴ Subnuclear vacuoles are common and characteristic. Squamoid morules may be seen within lumens. Most are low grade with a favorable outcome. High-grade tumors occur. When mixtures

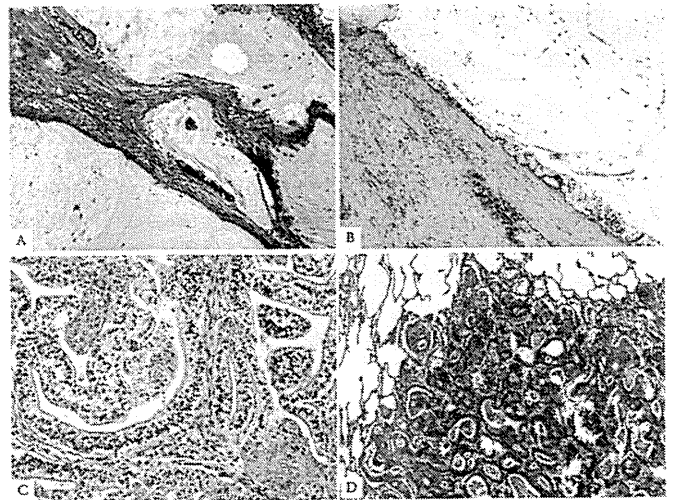


FIGURE 8. Adenocarcinoma, variants. *A*, Colloid adenocarcinoma consists of abundant pools of mucin growing within and distending airspaces. Focally well-differentiated mucinous glandular epithelium grows along the surface of fibrous septa and within the pools of mucin. Tumor cells may be very inconspicuous. *B*, This colloid adenocarcinoma contains a cystic component surrounded by a fibrous wall that is filled with pools of mucin; such a pattern was previously called mucinous cystadenocarcinoma. The surface of the fibrous wall is lined by well-differentiated cuboidal or columnar mucinous epithelium. *C*, Fetal adenocarcinoma consists of malignant glandular cells growing in tubules and papillary structures. These tumor cells have prominent clear cytoplasm, and squamoid morules are present. *D*, Enteric adenocarcinoma consists of an adenocarcinoma that morphologically resembles colonic adenocarcinoma with back-to-back angulated acinar structures. The tumor cells are cuboidal to columnar with nuclear pseudostratification.

occur with other histologic subtypes, the tumor should be classified according to the predominant component.¹⁵⁸ This tumor typically occurs in younger patients than other adenocarcinomas. Uniquely, these tumors appear driven by mutations in the beta-catenin gene, and the epithelial cells express aberrant nuclear and cytoplasmic staining with this antibody by immunohistochemistry.^{159,160} Nakatani et al. and Sekine et al.^{159,160} have suggested that up-regulation of components in the Wnt signaling pathway such as β -catenin is important in low-grade fetal adenocarcinomas and in biphasic pulmonary blastomas in contrast to high-grade fetal adenocarcinomas.

Enteric differentiation can occur in lung adenocarcinoma, and when this component exceeds 50%, the tumor is classified as pulmonary adenocarcinoma with enteric differentiation. The enteric pattern shares morphologic and immunohistochemical features with colorectal adenocarcinoma.¹⁵⁴ In contrast to metastatic colorectal adenocarcinoma, these tumors are histologically heterogeneous with some component that resembles primary lung adenocarcinoma such as lepidic growth. Recording of the percentages of these other components may be useful. The enteric pattern consists of glandular and/or papillary structures sometimes with a cribriform pattern, lined by tumor cells that are mostly tall-

columnar with nuclear pseudostratification, luminal necrosis, and prominent nuclear debris (Figure 8D).¹⁵⁴ Poorly differentiated tumors may have a more solid pattern. These tumors show at least one immunohistologic marker of enteric differentiation (CDX-2, CK20, or MUC2). Consistent positivity for CK7 and expression of TTF-1 in approximately half the cases helps in the distinction from metastatic colorectal adenocarcinoma.^{154,161} CK7-negative cases may occur.¹⁶² Primary lung adenocarcinomas that histologically resemble colorectal adenocarcinoma but lack immunohistochemical markers of enteric differentiation are probably better regarded as lung adenocarcinomas with enteric morphology rather than pulmonary adenocarcinoma with enteric differentiation.¹⁶³

CLASSIFICATION FOR SMALL BIOPSIES AND CYTOLOGY

Clinical Relevance of Histologic Diagnosis Drives Need to Classify NSCLC Further

This section applies to pathologic diagnosis of the majority of patients with lung cancer due to presentation with locally advanced or metastatic disease. Because of the need for improved separation of squamous cell carcinoma from adenocarcinoma, as it determines eligibility for molecular testing and impacts on specific therapies, there is now greater clinical interest in application of additional pathology tools to refine further the diagnosis in small biopsies (bronchoscopic, needle, or core biopsies) and cytology specimens from patients with advanced lung cancer, when morphologic features are not clear.^{30,39,40,164,165} Patients with adenocarcinoma should be tested for *EGFR* mutations (see evidence in Clinical Recommendation section) because patients with *EGFR* mutation-positive tumors may be eligible for first-line TKI therapy.^{8–11} Adenocarcinoma patients are also eligible for pemetrexed^{12–15} or bevacizumab-based chemotherapy regimens (see Clinical Recommendation section).^{16,17}

Pathology Recommendation 9

For small biopsies and cytology, we recommend that NSCLC be further classified into a more specific histologic type, such as adenocarcinoma or squamous cell carcinoma, whenever possible (strong recommendation, moderate quality evidence).

Data Driving Need to Classify NSCLC Further are Based Only on Light Microscopy

All current data that justify the importance of the distinction between histologic types of NSCLC in patients with advanced lung cancer are based on light microscopy alone.^{8–16} Thus, the diagnosis for clinical work, research studies, and clinical trials should be recorded in a manner, so it is clear how the pathologist made their determination: based on light microscopy alone or light microscopy plus special studies.

Pathology Consideration for Good Practice

1. When a diagnosis is made in a small biopsy or cytology specimen in conjunction with special studies, it

should be clarified whether the diagnosis was established based on light microscopy alone or whether special stains were required.

Management of Tissue for Molecular Studies is Critical

Strategic use of small biopsy and cytology samples is important, i.e., use the minimum specimen necessary for an accurate diagnosis, to preserve as much tissue as possible for potential molecular studies (Figure 9).¹⁶⁶ Methods that use substantial amounts of tissue to make a diagnosis of adenocarcinoma versus squamous cell carcinoma, such as large panels of immunohistochemical stains or molecular studies, may not provide an advantage over routine light microscopy with a limited immunohistochemical workup.¹⁶⁵

Pathology Consideration for Good Practice

2. Tissue specimens should be managed not only for diagnosis but also to maximize the amount of tissue available for molecular studies.
3. To guide therapy for patients with advanced lung adenocarcinoma, each institution should develop a multidisciplinary team that coordinates the optimal approach to obtaining and processing biopsy/cytology specimens to provide expeditious diagnostic and molecular results.

If Light Microscopic Diagnosis is Clearly Adenocarcinoma or Squamous Cell Carcinoma, Use These WHO Diagnostic Terms

Squamous cell carcinoma and adenocarcinoma should be diagnosed on biopsy and cytological materials when the criteria for specific diagnosis of these tumor types in the 2004 WHO classification are met. Nevertheless, for tumors that do not meet these criteria, newly proposed terminology and criteria are outlined in Table 2 and Figure 9.⁴

Histologic Heterogeneity of Lung Cancer is an Underlying Complexity

Because of histologic heterogeneity, small biopsy and/or cytology samples may not be representative of the total tumor, and there may be a discrepancy with the final histologic diagnosis in a resection specimen. Still, combined histologic types that meet criteria for adenosquamous carcinoma comprise less than 5% of all resected NSCLCs.⁴ A much more common difficulty in small biopsies or cytologies is classifying poorly differentiated tumors where clear differentiation is difficult or impossible to appreciate on light microscopy. The heterogeneity issue also makes it impossible to make the diagnosis of AIS, MIA, large cell carcinoma, or pleomorphic carcinoma in a small biopsy or cytology, because resection specimens are needed to make these interpretations. The term “large cell carcinoma” has been used in some clinical trials, but the pathologic criteria for that diagnosis are not defined, and it is not clear how these tumors were distinguished from NSCLC-NOS, as this diagnosis cannot be made in small biopsies or cytology, the type of

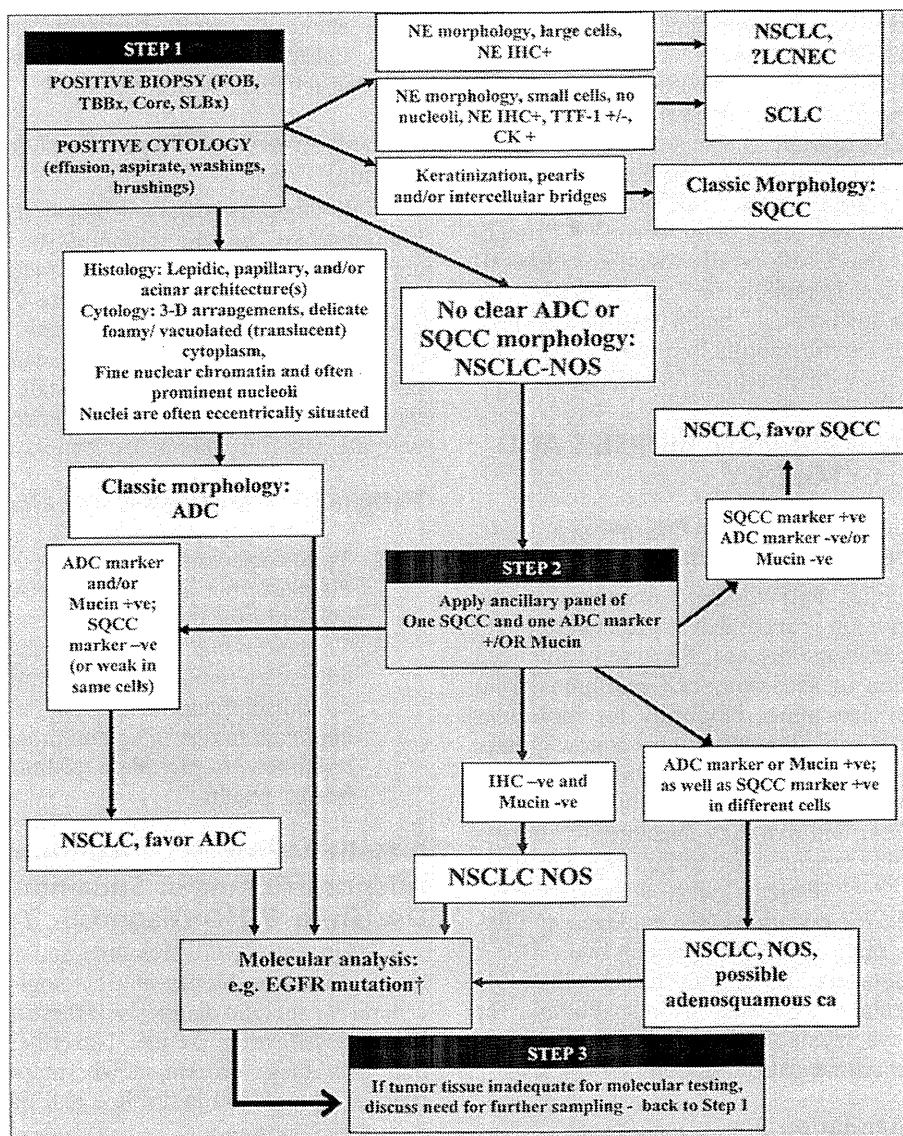


FIGURE 9. Algorithm for adenocarcinoma diagnosis in small biopsies and/or cytology. Step 1: When positive biopsies (fiberoptic bronchoscopy [FOB], transbronchial [TBBx], core, or surgical lung biopsy [SLBx]) or cytology (effusion, aspirate, washings, and brushings) show clear adenocarcinoma (ADC) or squamous cell carcinoma (SQCC) morphology, the diagnosis can be firmly established. If there is neuroendocrine morphology, the tumor may be classified as small cell carcinoma (SCLC) or non-small cell lung carcinoma (NSCLC), probably large cell neuroendocrine carcinoma (LCNEC) according to standard criteria (+ = positive, - = negative, and ± = positive or negative). If there is no clear ADC or SQCC morphology, the tumor is regarded as NSCLC-not otherwise specified (NOS). Step 2: NSCLC-NOS can be further classified based on (a) immunohistochemical stains (b) mucin (DPAS or mucicarmine) stains, or (c) molecular data. If the stains all favor ADC: positive ADC marker(s) (i.e., TTF-1 and/or mucin positive) with negative SQCC markers, then the tumor is classified as NSCLC, favor ADC. If SQCC markers (i.e., p63 and/or CK5/6) are positive with negative ADC markers, the tumor is classified as NSCLC, favor SQCC. If the ADC and SQCC markers are both strongly positive in different populations of tumor cells, the tumor is classified as NSCLC-NOS, with a comment it may represent adenosquamous carcinoma. If all markers are negative, the tumor is classified as NSCLC-NOS. See text for recommendations on NSCLCs with marked pleomorphic and overlapping ADC/SQCC morphology. †EGFR mutation testing should be performed in (1) classic ADC, (2) NSCLC, favor ADC, (3) NSCLC-NOS, and (4) NSCLC-NOS, possible adenosquamous carcinoma. In a NSCLC-NOS, if EGFR mutation is positive, the tumor is more likely to be ADC than SQCC. Step 3: If clinical management requires a more specific diagnosis than NSCLC-NOS, additional biopsies may be indicated (-ve = negative; +ve = positive; TTF-1: thyroid transcription factor-1; DPAS +ve: periodic-acid-Schiff with diastase; +ve: positive; e.g., IHC, immunohistochemistry; NE, neuroendocrine; CD, cluster designation; CK, cytokeratin; NB, of note). EGFR, epidermal growth factor receptor; DPAS, diastase-periodic acid Schiff.

specimens used to diagnose the patients with advanced-stage lung cancer studied in these trials.^{13,15,167}

Pathology Considerations for Good Practice

4. The terms AIS or MIA should not be diagnosed in small biopsies or cytology specimens. If a noninvasive pattern is present in a small biopsy, it should be referred to as a lepidic growth pattern.
5. The term large cell carcinoma should not be used for diagnosis in small biopsy or cytology specimens and should be restricted to resection specimens where the tumor is thoroughly sampled to exclude a differentiated component.

Use Minimal Stains to Diagnose NSCLC, Favor Adenocarcinoma, or Favor Squamous Cell Carcinoma

In those cases where a specimen shows NSCLC lacking either definite squamous or adenocarcinoma morphology, immunohistochemistry may refine diagnosis (Figure 9, step 2). To preserve as much tissue as possible for molecular testing in small biopsies, the workup should be minimal.¹⁶⁵ Realizing that new markers are likely to be developed, we suggest the initial evaluation use as only one adenocarcinoma marker and one squamous marker. At the present time, TTF-1 seems to be the single best marker for adenocarcinoma. TTF-1 provides the added value of serving as a pneumocyte marker that can help confirm a primary lung origin in 75 to 85% of lung adenocarcinomas.^{69,168,169} This can be very helpful in addressing the question of metastatic adenocarcinoma from other sites such as the colon or breast. Diastase-periodic acid Schiff or mucicarmine mucin stains may also be of value. p63 is consistently reported as a reliable marker for squamous histology and CK5/6 also can be useful.^{39,40,170–176} Cytokeratin 7 also tends to stain adenocarcinoma more often than squamous cell carcinoma.¹⁷⁷ Other antibodies (34 β E12 and S100A7) are less specific and sensitive for squamous differentiation. These data have been confirmed using resections where biopsies were interpreted as NSCLC³⁹ and also work on most needle aspirate specimens.⁴⁰ It is possible that cocktails of nuclear and cytoplasmic markers (TTF-1/CK5/6 or p63/napsin-A) may allow for use of fewer immunohistochemical studies of multiple antibodies.¹⁶⁴ Cases positive for an adenocarcinoma marker (i.e., TTF-1) and/or mucin with a negative squamous marker (i.e., p63) should be classified as “NSCLC favor adenocarcinoma” (Figures 10A–C) and those that are positive for a squamous marker, with at least moderate, diffuse staining, and a negative adenocarcinoma marker and/or mucin stains, should be classified as “NSCLC favor squamous cell carcinoma,” with a comment specifying whether the differentiation was detected by light microscopy and/or by special stains. These two small staining panels are generally mutually exclusive. If an adenocarcinoma marker such as TTF-1 is positive, the tumor should be classified as NSCLC, favor adenocarcinoma despite any expression of squamous markers.^{164,165} If the reactivity for adenocarcinoma versus squamous markers is positive in a different population of tumor cells, this may suggest adenosquamous carcinoma.

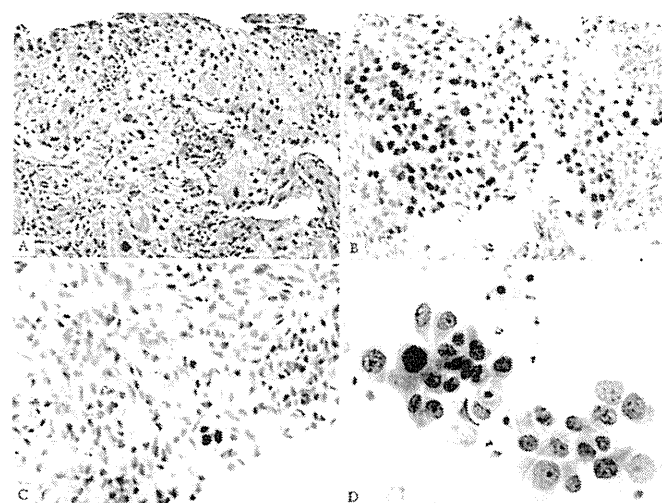


FIGURE 10. Adenocarcinoma in small biopsy and cytology. Poorly differentiated non-small cell carcinoma, favor adenocarcinoma. *A*, This core biopsy shows a solid pattern of growth, and morphologically, it lacks any acinar, papillary, or lepidic patterns. The mucin stain was also negative. *B*, The TTF-1 stain is strongly positive. *C*, The p63 stain is very focally positive. The strongly and diffusely positive TTF-1 and only focal p63 staining favor adenocarcinoma. In this case, *EGFR* mutation was positive. *D*, Cytology from different adenocarcinoma shows large malignant cells with abundant cytoplasm and prominent nuclei growing in an acinar structure. *EGFR*, epidermal growth factor receptor; TTF, thyroid transcription factor.

If tumor tissue is inadequate for molecular testing, there may be a need to rebiopsy the patient to perform testing that will guide therapy (step 3, Figure 9).

There may be cases where multidisciplinary correlation can help guide a pathologist in their evaluation of small biopsies and/or cytology specimens from lung adenocarcinomas. For example, if a biopsy showing NSCLC-NOS is obtained from an Asian, female, never smoker with ground-glass nodules (GGNs) on CT, the pathologist should know this information as the tumor is more likely to be adenocarcinoma and have an *EGFR* mutation.

Cytology is a Useful Diagnostic Method, Especially When Correlated with Histology

Cytology is a powerful tool in the diagnosis of lung cancer, in particular in the distinction of adenocarcinoma from squamous cell carcinoma.¹⁷⁸ In a recent study, of 192 preoperative cytology diagnoses, definitive versus favored versus unclassified diagnoses were observed in 88% versus 8% versus 4% of cases, respectively.¹⁷⁹ When compared with subsequent resection specimens, the accuracy of cytologic diagnosis was 93% and for definitive diagnoses, it was 96%. For the adenocarcinoma and squamous cell carcinoma cases, only 3% of cases were unclassified, and the overall accuracy was 96%. When immunohistochemistry was used in 9% of these cases, the accuracy was 100%.¹⁷⁹

Whenever possible, cytology should be used in conjunction with histology in small biopsies (Figure 10D).^{40,180}

In another study where small biopsies were evaluated in conjunction with cytology for the diagnosis of adenocarcinoma versus squamous cell carcinoma versus unclassified (NSCLC-NOS), the result for cytology was 70% versus 19% versus 11% and for biopsies, it was 72%, 22%, and 6%, respectively.¹⁸⁰ Still when cytology was correlated with biopsy, the percentage of cases diagnosed as NSCLC-NOS was greatly reduced to only 4% of cases.¹⁸⁰ In a small percentage of cases (<5%), cytology was more informative than histology in classifying tumors as adenocarcinoma or squamous cell carcinoma.¹⁸⁰ The factors that contributed the greatest to difficulty in a specific diagnosis in both studies were poor differentiation, low specimen cellularity, and squamous histology.^{179,180}

Pathology Consideration for Good Practice

6. When paired cytology and biopsy specimens exist, they should be reviewed together to achieve the most specific and nondiscordant diagnoses.

Preservation of Cell Blocks from Cytology Aspirates or Effusions for Molecular Studies

The volume of tumor cells in biopsies may be small due to frequent prominent stromal reactions, so that there may be insufficient material for molecular analysis. Material derived from aspirates or effusions may have more tumor cells than a small biopsy obtained at the same time, so any positive cytology samples should be preserved as cell blocks, so that tumor is archived for immunohistochemical and molecular studies. Furthermore, these materials should be used judiciously in making the diagnosis to preserve as much material as possible for potential molecular studies.^{40,181–183} In a recent study, material from cell blocks prepared from 128 lung cancer cytology specimens was suitable for molecular analysis for *EGFR* and *KRAS* mutations in 126 (98%) of specimens.¹⁷⁹

Pathology Consideration for Good Practice

7. Cell blocks should be prepared from cytology samples including pleural fluids.

NSCLC-NOS: If No Clear Differentiation by Morphology or Immunohistochemistry

There will remain a minority of cases where the diagnosis remains NSCLC-NOS, as no differentiation can be established by routine morphology and/or immunohistochemistry (Figure 9, step 2). In the setting of a tumor with a negative adenocarcinoma marker (i.e., TTF-1), and only weak or focal staining for a squamous marker, it is best to classify the tumor as NSCLC-NOS rather than NSCLC, favor squamous cell carcinoma. These cases may benefit from discussion in a multidisciplinary setting (a) to determine the need for a further sample if subtyping will affect treatment; (b) whether molecular data should be sought, again if treatment will be defined by such data; (c) whether noninvasive features such as imaging characteristics (e.g., peripheral GGN supporting adenocarcinoma) favor a tumor subtype; and (d) whether clinical phenotype (e.g., female, never

smoker, and Asian) may assist in determining future management (Figure 9, step 3).

Pathology Recommendation 10

We recommend that the term NSCLC-NOS be used as little as possible, and we recommend it be applied only when a more specific diagnosis is not possible by morphology and/or special stains (strong recommendation, moderate quality evidence).

Pathology Consideration for Good Practice

8. The term nonsquamous cell carcinoma should not be used by pathologists in diagnostic reports. It is a categorization used by clinicians to define groups of patients with several histologic types who can be treated in a similar manner; in small biopsies/cytology, pathologists should classify NSCLC as adenocarcinoma, squamous cell carcinoma, NSCLC-NOS, or other terms outlined in Table 2 or Figure 9.

NSCLC-NOS: When Morphology and Immunohistochemistry are Conflicting

Rarely, small samples may show either morphologic features of both squamous cell carcinoma and adenocarcinoma with routine histology or by immunohistochemical expression of both squamous and adenocarcinoma markers; these should be termed as “NSCLC-NOS” with a comment recording the features suggesting concurrent glandular and squamous cell differentiation, specifying whether this was detected by light microscopy or immunohistochemistry. As p63 expression can occur in up to one third of adenocarcinomas,^{40,184,185} in a tumor that lacks squamous cell morphology, virtually all tumors that show coexpression of p63 and TTF-1 will be adenocarcinomas. It is possible that the tumor may be an adenosquamous carcinoma but that diagnosis cannot be established without a resection specimen showing at least 10% of each component. If TTF-1 and p63 positivity are seen in different populations of tumor cells, it is possible that this may be more suggestive of adenosquamous carcinoma than if these markers are coexpressed in the same tumor cells.

Interpret Morphologic and Staining Patterns to Maximize Patient Eligibility for Therapies

Presently, the recommendation for *EGFR* mutation testing and candidacy for pemetrexed or bevacizumab therapy is for the diagnosis of (1) adenocarcinoma, (2) NSCLC-NOS, favor adenocarcinoma, or (3) NSCLC-NOS (see Clinical Recommendation section later). For this reason, in most NSCLC, the primary decision pathologists need to focus on, while interpreting small biopsies and cytology specimens, whether the tumor is a definite squamous cell carcinoma or NSCLC, favor squamous cell carcinoma versus one of the above diagnoses. Thus, when morphology or immunohistochemical findings are equivocal, pathologists need to keep in mind that a diagnosis of squamous cell carcinoma or NSCLC, favor squamous cell carcinoma will exclude them from histologically driven molecular testing or chemotherapy. In such

a situation, it may be best to favor NSCLC-NOS, to allow the patient to be eligible for the therapeutic options mentioned earlier in the text. Hopefully, effective therapies, perhaps based on molecular targets, will become available for squamous cell carcinoma in the near future.

Pathology Consideration for Good Practice

9. The above strategy for classification of adenocarcinoma versus other histologies and the terminology in Table 2 and Figure 9 should be used in routine diagnosis and future research and clinical trials, so that there is uniform classification of disease cohorts in relationship to tumor subtypes and data can be stratified according to diagnoses made by light microscopy alone versus diagnoses requiring special stains.

Distinction of Adenocarcinoma from Sarcomatoid Carcinomas

Cases that show sarcomatoid features such as marked nuclear pleomorphism, malignant giant cells, or spindle cell morphology should be preferentially regarded as adenocarcinoma or squamous cell carcinoma if these features are clearly present, as this is apt to influence management. Nevertheless, pleomorphic carcinoma, carcinosarcoma, and blastoma are very difficult to diagnose in small specimens due to the limited ability to assess for mixed histologies. Nevertheless, if a small biopsy shows what is probably an adenocarcinoma with pleomorphism, a comment should be made, e.g., “NSCLC, favor adenocarcinoma, with giant and/or spindle cell features” (depending on which feature is identified).

Pathology Consideration for Good Practice

10. Tumors that show sarcomatoid features, such as marked nuclear pleomorphism, malignant giant cells, or spindle cell morphology, should be preferentially regarded as adenocarcinoma or squamous cell carcinoma if clear glandular or squamous features are present, as this is apt to influence management. If such features are not present, the term “poorly differentiated non-small cell carcinoma with giant and/or spindle cell features” (depending on what feature is present) should be used.

Distinction of Adenocarcinoma from Neuroendocrine Carcinomas

Some cases of NSCLC may suggest neuroendocrine (NE) morphology; these should be assessed with NE markers (CD56, chromogranin, and/or synaptophysin), so that a diagnosis of large cell NE carcinoma (LCNEC) can be suggested. The term NSCLC, possible LCNEC is usually the best term when this diagnosis is suspected as it is difficult to establish a diagnosis of LCNEC on small biopsies. In those lacking NE morphology, we recommend against using routine staining with NE markers, as immunohistochemical evidence of NE differentiation in otherwise definite adenocarcinoma and squamous cell carcinoma does not seem to affect prognosis^{186,187} or treatment.

Pathology Consideration for Good Practice

11. NE immunohistochemical markers should only be performed in cases where there is suspected NE morphology. If NE morphology is not suspected, NE markers should not be performed.

GRADING OF ADENOCARCINOMAS

No well-established histologic or cytologic grading system exists for lung adenocarcinoma. Most publications which grade adenocarcinomas do not cite specific morphologic criteria. The overall grade of a tumor is typically determined by the component with the worst grade. Only a few studies have evaluated detailed morphologic grading systems.^{41,188–191} The primary approaches are based on architectural and/or nuclear attributes. Nevertheless, the following histologic features are promising candidates for components of a grading system. By architecture, the following prognostic associations have been reported: poor (solid^{41,43,44,53,69} and micropapillary),^{43,44,108,109} favorable (nonmucinous lepidic^{43,44,46,192} [formerly BAC]), and intermediate (papillary and acinar).^{43,44} Thus, comprehensive histologic subtyping method and subclassification of invasive tumors by the predominant subtype may be a simple way to develop the architectural grade of lung adenocarcinomas,^{43,44} similar to the Gleason grading system for prostate cancer.¹⁹³ By nuclear criteria, preliminary data suggest poor prognosis may be associated with large nuclei and variability in nuclear size and shape.^{190,191,194} As stated earlier in the text, histologic grading should not be confused with the GRADE method of formulating recommendations and weighing evidence.^{190,191}

STRATEGIC USE OF PATHOLOGIC SPECIMENS FOR MOLECULAR STUDIES

With the emerging importance of molecular diagnostics to guide therapy, a multidisciplinary approach is needed to set a consistent strategy for obtaining and preserving tissue samples optimized to perform studies such as DNA sequence analysis, fluorescence in situ hybridization (FISH), and, in some settings, RNA-based studies. It is not yet possible to provide specific guidelines on how to do this in the current document because of the wide variation in infrastructure and expertise from one institution to another. Still, this process begins with the method of obtaining tissue (fine needle aspiration [FNA], core or transbronchial biopsy, and surgical resection) and continues with the processing of the specimen in the pathology department, to delivery of material for molecular analysis, and communication of the molecular results in pathology reports.

If a portion of a sampled tumor is snap frozen for molecular studies, a few considerations exist as regards resection specimens. As most critical molecular studies can be performed from formalin-fixed paraffin-embedded tissue, there is a need for frozen samples only for certain techniques such as comparative genomic hybridization (CGH) and gene expression profiling. If frozen tissue is being obtained from tumors with lepidic predominant tumors where AIS or MIA is in the differential diagnosis, efforts should be made to

ascertain whether this frozen piece has an invasive component. The CT and gross appearance of the lesion should be considered to ensure a solid component is sampled in a tumor that appeared part solid on CT. Another approach is to perform a frozen section from the tissue saved for storage in a freezer.

Small biopsies and/or cytologic samples including pleural fluids can be used for many molecular analyses.^{179,181,183,195–205} *EGFR* mutation testing and *KRAS* mutation testing are readily performed on these specimens.^{179–181,195–199,203–205} Formalin-fixed paraffin-embedded samples can be used effectively for polymerase chain reaction-based mutation testing and for FISH or chromogenic in situ hybridization (CISH) testing for gene amplification and for immunohistochemistry. Cytology smears can be analyzed for immunohistochemical and certain molecular studies, but it is far preferable if cell blocks are available. Manual or laser-guided microdissection may enrich tumor cells for molecular studies. Assessment of *EGFR* mutations helps in selecting patients to be treated with *EGFR*-TKIs. Molecular testing in the setting of clinical trials can stratify patients by results of gene expression or markers of sensitivity to specific cytotoxic agents such as excision repair cross-complementation group 1 or breast cancer 1 for platinum, ribonucleotide reductase M1 for gemcitabine or thymidylate synthase for antifolates.^{206–211}

Summary of Pathology Recommendations

1. We recommend discontinuing the use of the term “BAC” (strong recommendation, low-quality evidence).
2. For small (≤ 3 cm), solitary adenocarcinomas with pure lepidic growth, we recommend the term “Adenocarcinoma in situ” that defines patients who should have 100% disease-specific survival, if the lesion is completely resected (strong recommendation, moderate quality evidence). Remark: Most AIS are nonmucinous, rarely are they mucinous.
3. For small (≤ 3 cm), solitary, adenocarcinomas with predominant lepidic growth and small foci of invasion measuring ≤ 0.5 cm, we recommend a new concept of “Minimally invasive adenocarcinoma” to define patients who should have near 100%, disease-specific survival, if completely resected (strong recommendation, low-quality evidence). Remark: Most MIA are nonmucinous, rarely are they mucinous.
4. For invasive adenocarcinomas, we suggest comprehensive histologic subtyping be used to assess histologic patterns semiquantitatively in 5% increments, choosing a single predominant pattern. We also suggest that individual tumors be classified according to the predominant pattern and that the percentages of the subtypes be reported (weak recommendations and low-quality evidence).
5. In patients with multiple lung adenocarcinomas, we suggest comprehensive histologic subtyping in the comparison of the complex, heterogeneous mixtures of histologic patterns to determine whether the tumors are metastases or separate synchronous or metachronous primaries (weak recommendation, low-quality evidence).
6. For nonmucinous adenocarcinomas previously classified as mixed subtype where the predominant subtype consists of the former nonmucinous BAC, we recommend use of the term LPA and discontinuing the term “mixed subtype” (strong recommendation, low-quality evidence).
7. In patients with early-stage adenocarcinoma, we recommend the addition of “micropapillary predominant adenocarcinoma,” when applicable, as a major histologic subtype due to its association with poor prognosis (strong recommendation, low-quality evidence).
8. For adenocarcinomas formerly classified as mucinous BAC, we recommend that they be separated from the adenocarcinomas formerly classified as nonmucinous BAC and depending on the extent of lepidic versus invasive growth that they be classified as mucinous AIS, mucinous MIA, or for overtly invasive tumors “invasive mucinous adenocarcinoma” (weak recommendation, low-quality evidence).
9. For small biopsies and cytology, we recommend that NSCLC be further classified into a more specific type, such as adenocarcinoma or squamous cell carcinoma, whenever possible (strong recommendation, moderate quality evidence).
10. We recommend that the term NSCLC-NOS be used as little as possible, and we recommend it be applied only when a more specific diagnosis is not possible by morphology and/or special stains (strong recommendation, moderate quality evidence).

Summary of Pathology Considerations for Good Practice

1. When a diagnosis is made in a small biopsy or cytology specimen in conjunction with special studies, it should be clarified whether the diagnosis was established based on light microscopy alone or whether special stains were required.
2. Tissue specimens should be managed not only for diagnosis but also to maximize the amount of tissue available for molecular studies.
3. To guide therapy for patients with advanced lung adenocarcinoma, each institution should develop a multidisciplinary team that coordinates the optimal approach to obtaining and processing biopsy/cytology specimens to provide expeditious diagnostic and molecular results.
4. The terms AIS or MIA should not be used in small biopsies or cytology specimens. If a noninvasive pattern is present in a small biopsy, it should be referred to as lepidic growth.
5. The term large cell carcinoma should not be used for diagnosis in small biopsy or cytology specimens and should be restricted to resection specimens where the tumor is thoroughly sampled to exclude a differentiated component.

6. When paired cytology and biopsy specimens exist, they should be reviewed together to achieve the most specific and nondiscordant diagnoses.
 7. Cell blocks should be prepared from cytology samples including pleural fluids.
 8. The term nonsquamous cell carcinoma should not be used by pathologists in diagnostic reports. It is a categorization used by clinicians to define groups of patients with several histologic types who can be treated in a similar manner; in small biopsies/cytology, pathologists should classify NSCLC as adenocarcinoma, squamous cell carcinoma, NSCLC-NOS, or other terms outlined in Table 2 or Figure 9.
 9. The above strategy for classification of adenocarcinoma versus other histologies and the terminology in Table 2 and Figure 9 should be used in routine diagnosis and future research and clinical trials, so that there is uniform classification of disease cohorts in relationship to tumor subtypes and data can be stratified according to diagnoses made by light microscopy alone versus diagnoses requiring special stains.
 10. Tumors that show sarcomatoid features, such as marked nuclear pleomorphism, malignant giant cells, or spindle cell morphology, should be preferentially regarded as adenocarcinoma or squamous cell carcinoma if clear glandular or squamous features are present, as this is apt to influence management. If such features are not present, the term “poorly differentiated non-small cell carcinoma with giant and/or spindle cell features” (depending on what feature is present) should be used.
 11. NE immunohistochemical markers should only be performed in cases where there is suspected NE morphology. If NE morphology is not suspected, NE markers should not be performed.
- should the lepidic pattern be distinguished from other invasive patterns such as acinar and papillary?
 4. Do tumors that meet criteria for MIA have 100% disease-free survival if the invasive component is predominantly solid, micropapillary or if they show giant cell and spindle cell components that fail to qualify for a diagnosis pleomorphic carcinoma?
 5. What is the long-term follow-up for completely resected solitary mucinous MIA? Can this be the initial presentation for multifocal invasive mucinous adenocarcinoma?
 6. Does the micropapillary pattern have a similar poor prognostic significance in advanced stage and early stage?
 7. Is there any prognostic significance to the aggressive micropapillary or solid components when present in relatively small amounts if they do not represent the predominant pattern? If so, what percentage is needed for such significance?
 8. Is immunohistochemical testing using *EGFR* mutation-specific antibodies a reliable method for predicting the presence of an *EGFR* mutation?
 9. It is unknown whether there is any added value provided by refining NSCLC-NOS via immunohistochemistry on small biopsies or cytology samples. This requires assessment in future trials using systemic therapy.
 10. Additional markers for squamous or adenocarcinoma differentiation, such as desmocolein-3²¹² or desmocollin²¹³ for squamous cell carcinoma or napsin-A for adenocarcinoma,²¹⁴ need further evaluation.
 11. The ability of pathologists to distinguish AIS from invasive disease at frozen section is not proven.
 12. Currently, we cannot recommend any specific grading system. Further investigation is needed to determine whether the optimal grading system should include architectural versus nuclear assessment or both.
 13. In specimens from metastatic sites, is there any clinical significance to recognizing histologic patterns, including the predominant pattern?

Pathology Research Recommendations

1. Criteria for MIA are based on limited published data and require further validation. Persistent questions include what is the optimal method for measuring the size of the invasive component? Is 0.5 cm the best size cut off? If multiple areas of invasion are present, should the greatest dimension of the largest invasive focus be used or the total size multiplied times the percentage of the invasive components? What should be the impact of scar size or prominent stromal desmoplasia and stromal inflammation on determining size of the invasive component? Should criteria for MIA be different for mucinous versus nonmucinous tumors?
2. Lepidic growth may also be composed of neoplastic cells with nuclear atypia resembling that of the adjacent invasive patterns. Whether there is any clinical implication is unknown. That is, it is not established if this is in situ or invasive carcinoma.
3. The level of reproducibility for identifying predominant histologic patterns is untested. In particular, how

CLINICAL FEATURES

Several important clinical facts have had a significant impact on this classification: (1) adenocarcinoma histology is a strong predictor for outcome to pemetrexed therapy in advanced-stage patients.^{13–15} (2) Distinction between adenocarcinoma or other non-small cell histologies and squamous cell carcinoma is important because of potential life-threatening hemorrhage in patients with squamous cell carcinoma who receive bevacizumab therapy.¹⁶ (3) *EGFR* mutation is a validated predictive marker for response and progression-free survival (PFS) with *EGFR*-TKIs in the first-line therapy in advanced lung adenocarcinoma.^{8,215–218} (4) Molecular markers are an important evolving area in evaluation and management of patients with lung adenocarcinoma.²¹⁹ More data are needed regarding other molecular markers beyond *EGFR* mutation, such as *KRAS* mutation, *EGFR* gene copy number,

and *EML4-ALK* fusion, before they can be accepted as validated markers for a recommendation in this document.^{153,220}

Biopsy and Pathology Issues for the Clinician

After initial evaluation, a plan for an invasive procedure to obtain a diagnosis and complete staging should be made in a multidisciplinary setting.²²¹ The site for the biopsy should be chosen to yield the maximal information with the least risk. A key element in determining the type of procedure is the need to obtain adequate tissue for all pathologic and molecular evaluations (e.g., mutation analysis and immunohistochemistry).

For sampling a peripheral nodular lesion that contains a solid component, the suitable invasive procedures are thoracic biopsy such as CT-guided biopsies, bronchoscopy/navigation-assisted bronchoscopy, sublobar resection, or lobectomy (e.g., by video-assisted thoracic surgery, VATS, or thoracoscopy). Either a core biopsy or a FNA with a cell block will reliably obtain adequate tissue.^{179,203} For mediastinal involvement, sampling can be achieved by blind TBNA, endobronchial endoscopy (endobronchial ultrasound)-guided TBNA, EUS-guided FNA, mediastinoscopy, VATS, or Chamberlain procedure. For patients with recurrent disease, repeat biopsy can be useful not only to confirm the diagnosis but also the molecular profile.

Prognostic and Predictive Factors

Multiple clinical, pathologic, and molecular factors have been explored for their association with patient outcome. To facilitate the discussion, we divided them into two categories although both categories are prognostic factors in the strict sense: prognostic factors, which dictate the virulence of the disease (e.g., progression and recurrence), and predictive factors, which are correlated with the outcome for specific therapies. Predictive and prognostic factors may overlap; however, they are often different.

The main independent clinical prognostic factors for patients with lung adenocarcinoma are stage, performance status, age, and sex.²²² The independent prognostic value of stage exists whether using clinical²²³ or pathological²²⁴ staging. Data also suggest that smoking history may be an independent prognostic factor.²²⁵

Although clinical factors provide important prognostic information, recently there has been greater focus on predictive factors for specific therapies, initially focusing on histology.²¹⁹ In early clinical trials of erlotinib and gefitinib, some patients with good responses to these drugs were those with adenocarcinoma with lepidic growth patterns (formerly known as BAC).²²⁶ This led to trials of gefitinib and erlotinib in patients formerly diagnosed with BAC. West et al.²²⁷ reported the results of a Southwest Oncology Group trial in which 17% of patients had a response to gefitinib. Similarly, Miller et al.¹⁹⁸ reported a 22% response rate to erlotinib in patients formerly diagnosed with BAC or adenocarcinoma with BAC features. In the new classification, many of these tumors would be regarded to be invasive adenocarcinomas with varying degrees of lepidic growth.

Although histology will continue to play an important predictive role, recently the use of molecular markers for

predicting response to therapy has become more prominent, particularly after the discovery of *EGFR* mutations and their association with sensitivity to erlotinib and gefitinib.^{215–217,219} Although *KRAS* mutations were identified in patients with NSCLC more than 20 years ago, their clinical role as predictive and prognostic biomarkers remains controversial. Several phase 2 clinical trials^{228–233} verified use of *EGFR* mutations as predictors of response to erlotinib and gefitinib. *EGFR* mutations occur most frequently in East Asian patients and in those patients with little or no smoking history. The *EGFR* mutations that are most common and recognized to be of greatest clinical significance are somatic point mutations in codon L858R in exon 21 and in-frame deletions in exon 19.^{215–217,219} Four recent phase 3 trials were based on patients with either pure or predominantly lung adenocarcinoma histology; one which selected patients clinically and three which selected patients by *EGFR* mutations have demonstrated that patients with *EGFR* mutation lung cancer have better treatment outcomes (response rate and PFS) when treated with the *EGFR* inhibitor gefitinib than with conventional platin-based doublet chemotherapy.^{8–11} In the Iressa Pan Asian Survival Study trial, molecular subset analysis showed that PFS benefit was limited to the patients with *EGFR* mutation (hazard ratio [HR]: 0.48, 95% confidence interval [CI]: 0.36–0.64) and that gefitinib therapy was detrimental for those without mutations (HR: 2.85, 95% CI: 2.05–3.98).⁸ Maemondo et al.¹⁰ showed PFS of patients with *EGFR* mutations was 10.8 months in patients who received gefitinib compared with 5.4 months in those who received carboplatin plus paclitaxel (HR: 0.30, 95% CI: 0.22–0.41, $p < 0.001$) and a higher response rate (73.7% versus 30.7%, $p < 0.001$). Mitsudomi et al.⁹ showed that patients with *EGFR* mutations who received gefitinib had significantly longer median PFS of 9.2 months versus 6.3 months (HR: 0.489, 95% CI: 0.336–0.710, $p < 0.001$). Zhou et al.¹¹ showed that patients with *EGFR* mutations treated with erlotinib have significantly longer median PFS of 13.1 months compared with 4.6 months for those treated with gemcitabine/carboplatin (HR: 0.16, 95% CI: 0.10–0.26, $p < 0.0001$). These trials do not demonstrate significant differences in overall survival for gefitinib treatment, likely an effect of cross-over treatment with gefitinib or erlotinib in second-line therapy. Similarly, in a chemotherapy-controlled phase III study (INTEREST) comparing gefitinib with docetaxel, *EGFR* mutation-positive patients had longer PFS and higher objective response rates (42% versus 7%) than those without mutations for gefitinib.²³⁴ The finding that *EGFR* mutation is predictive of important benefit for PFS and responsiveness to TKI therapy is also supported by multiple phase 2 clinical trials.^{228–233}

Other molecular predictors of outcome have also been explored for erlotinib and gefitinib treatment. Retrospective analysis of data from the Iressa Survival Evaluation in Lung Cancer study showed that *EGFR* copy number and protein expression were predictive of significantly better overall survival after treatment with gefitinib.²³⁵ A multivariate analysis of data from the Canadian BR.21, phase 3 randomized, placebo-controlled trial of erlotinib in advanced NSCLC showed that *EGFR* copy number (but not *EGFR* mutation

status) was associated with worse survival (HR: 1.9, 95% CI: 1.1–3.4) and a better response to erlotinib ($p = 0.005$), after controlling for race, performance status, weight loss, smoking history, prior treatment, and response to prior treatment.²³⁶ In a second-line, chemotherapy controlled phase III study (INTEREST) comparing gefitinib with docetaxel, overall survival was similar in the two arms, and there were no statistically significant interactions between treatment and EGFR copy number, protein expression, or mutation status.²³⁴ The results of all three of these studies may be influenced by inclusion of large numbers of patients with histologies other than adenocarcinoma and should be regarded as exploratory.^{234–236}

For treatment of advanced NSCLC, response and outcome to EGFR-TKIs have been demonstrated in most studies to be better predicted by EGFR mutation testing rather than copy number or immunohistochemistry. In a phase II study of erlotinib-treated patients, multivariate analysis of molecular predictors showed that EGFR mutations, but not copy number, was predictive of response to erlotinib with a response of 83% in patients with EGFR mutations versus 7% in those without ($p < 0.01$).¹⁹⁸ In this study, immunohistochemistry was not predictive of response.¹⁹⁸ Another study by Sholl et al.²³⁷ found EGFR mutation status, but not FISH, CISH, or immunohistochemistry, was useful for predicting response and PFS for TKI therapy. The recent development of new mutation-specific antibodies for EGFR exon 19 deletion and L858R mutation seems to be much more reliable in predicting EGFR mutation status, and these need to be evaluated in future clinical trials.^{238–240} In the Iressa Pan Asian Survival Study, in FISH+ patients, gefitinib was worse than chemotherapy if those patients lacked EGFR mutations.²⁴¹ All these studies used RECIST to measure response to therapy.^{8–11,198,234–236,241}

More recently, investigators have noted that all NSCLC histologies other than squamous cell carcinoma seem to garner more benefit from two drugs, pemetrexed for efficacy and bevacizumab for avoidance of toxicity. Nevertheless, most of the analyses are subgroup analyses with the known shortcomings. Pemetrexed, a multitargeted antifolate agent, seems to have greater activity in NSCLCs with nonsquamous histology (adenocarcinoma and NSCLC-NOS), with the greatest proportion of benefit observed in patients with adenocarcinomas as demonstrated in two phase 3 trials.^{12–15} In a phase 3 trial, comparing cisplatin/pemetrexed with cisplatin/gemcitabine, preplanned subgroup analysis, revealed median overall survival was significantly better for patients with adenocarcinoma (12.6 versus 10.9 months, HR = 0.81, 95% CI: 0.71–0.99, $p = 0.03$) and large cell carcinoma (would be called NSCLC-NOS by the current proposal), overall survival of 10.4 versus 6.7 months (HR = 0.67; CI: 0.48–0.96), whereas no benefit was seen with squamous cell carcinoma or with all histologies combined.¹³ Follow-up analysis of the same patients from this phase 3 study but focusing on those without grade 3 or 4 drug toxicity, a similar benefit for overall survival was found in patients with nonsquamous histology comparing cisplatin pemetrexed with cisplatin/gemcitabine (median survival of 5.6 months versus 2.8 months, respectively, HR = 0.64, 95% CI: 0.56–0.72, $p < 0.001$).¹²

Ciuleanu et al. showed in a phase 3 trial comparing pemetrexed versus placebo, where prespecified analysis for histology were performed, that patients with adenocarcinoma histology had better median PFS (4.5 versus 1.5 months, HR = 0.511; CI: 0.38–0.68; $p < 0.0001$) and median overall survival (16.8 versus 11.5 months; HR = 0.73; CI: 0.56–0.96; $p < 0.026$). The benefit was also significant for nonsquamous carcinomas classified as other, and for nonsquamous cell carcinoma overall, but not for large cell carcinomas or squamous cell carcinomas.¹⁴ Several phase II studies have also shown a benefit for pemetrexed in patients with advanced NSCLC with nonsquamous histologic subtypes.^{242,243} Nevertheless, a recent phase III trial, with primary end point as the assessment of quality of life, observed similar outcomes for patients treated with pemetrexed/carboplatin regardless of histology.²⁴⁴ Patients with adenocarcinoma or NSCLC-NOS (nonsquamous NSCLC histology) are the only patients who have been demonstrated to benefit from bevacizumab in combination with chemotherapy.²⁴⁵ Indeed, patients with squamous cell carcinoma are at greater risk of adverse events, and therefore, such patients have been excluded from receiving this drug by the Food and Drug Administration,¹⁷ but they are eligible for adjuvant therapy in ongoing trials.¹⁶

Very recently, a new predictive biomarker has been identified in patients with NSCLC, the EML4/ALK translocation. This translocation leads to an oncogenic constitutive activation of ALK.^{220,246,247} A recent study of 82 patients with NSCLC confirmed to have ALK fusion by FISH demonstrated a 57% overall response rate to crizotinib (PF-02341066), an inhibitor of MET and ALK, and the estimated 6-month PFS was 72%.²⁴⁸ De novo resistance mutations in the kinase domain of EML4-ALK have been reported to develop during ALK inhibitor therapy.²⁴⁹

Clinical Implications of Histology and Molecular Testing

Accurate histologic subtyping and EGFR mutation testing are important and should be included in the initial work-up of patients with advanced lung adenocarcinoma because it may guide treatment decisions. Whether other EGFR tests should be recommended (i.e., immunohistochemistry and FISH) and/or KRAS mutation as an indicator of TKI resistance is not yet clear.^{250,251} In addition to EGFR mutation analysis, additional molecular tests are in development and may be more useful when further clinical data support their use.

Surgically Resectable NSCLC

Twenty to 30% of patients with NSCLC are diagnosed with stage I to stage IIIA disease and, thus, may be amenable to surgical resection. Patients who undergo resection have differing prognoses based on pathologic stage. The recent IASLC staging project has demonstrated overall 5-year survival of 73% for stage IA, 58% for stage IB, 46% for stage IIA, 36% for stage IIB, 24% for stage IIIA, and 9% for stage IIIB.^{252,253} The introduction of adjuvant cisplatin-based chemotherapy represented a major step forward with a 5% increase in cure rate.²⁵⁴ Still, 27% of patients with stage IA

disease and 42% of patients with stage IB NSCLC eventually recur and die of their disease; there is no accurate way to predict which of these patients have poor-risk disease and are likely to recur. Similarly, 41% of patients with stage II NSCLC are cured by surgery alone and do not need any adjuvant therapy.^{252,253} Thus, an urgent need to identify factors, which will select patients for adjuvant therapy, exists. Several predictive factors for better efficacy of adjuvant chemotherapy have been described in retrospective analyses of phase III randomized adjuvant studies. An example is low expression of the DNA repair genes excision repair cross-complementation group 1 for greater benefit from cisplatin-based chemotherapy, although this needs further validation.²⁰⁷ Based on initial data showing striking differences in survival predicted by histologic subtyping according to this proposed classification of lung adenocarcinomas in resected specimens,⁴⁴ it is possible in the future that histology will play an important role in selecting patients for adjuvant therapy.

Clinical Recommendation

In patients with advanced lung adenocarcinoma, we recommend testing for *EGFR* mutation (strong recommendation, moderate quality evidence).

Remarks: This is a strong recommendation because potential benefits clearly outweigh harms. This recommendation assumes that correct classification by *EGFR* mutation status is associated with important benefit based on randomized phase 3 clinical trials of EGFR-TKI therapy, which demonstrate a predictive benefit for response rate and PFS, but not overall survival, and subset analyses of multiple additional studies.

Clinical Consideration for Good Practice

1. If molecular testing is planned, appropriate biopsy methods should be used to obtain sufficient tissue for both pathologic diagnosis and molecular analyses, and the specimens should be handled appropriately.

Clinical Research Recommendations

1. How can this histological and/or molecular classification improve our ability to estimate prognosis and optimize the selection of patients for a specific therapy?
2. What is the relative importance of histologic versus molecular data for identifying prognostic or predictive markers based on small biopsies and cytology versus resected specimens?
3. Is immunohistochemical testing using *EGFR* mutation-specific antibodies as predictive of response to EGFR-TKIs as *EGFR* mutations?
4. In advanced lung adenocarcinomas, are the prognostic and therapeutic implications of histology any different if the pathologic diagnosis is based on a combination of histology and immunohistochemistry (i.e., TTF-1 and/or p63) versus conventional light microscopy alone which is the basis for current data?
5. In metastatic lung adenocarcinomas, what are the clinical implications of any potential differences in molec-

ular or histologic features compared with primary tumors?

6. What are the clinical, epidemiological, molecular, and histologic characteristics of never smokers with lung adenocarcinoma?

MOLECULAR FEATURES

There are several molecular observations that have important implications for lung adenocarcinoma patients: (1) *EGFR* mutation is a validated predictive marker for response and PFS with EGFR-TKIs in the first-line therapy in advanced lung adenocarcinoma.^{8,215-218} (2) Tumors with an *EGFR* mutation have been associated with a more indolent course.^{8,234} (3) *EGFR* and *KRAS* mutations are virtually mutually exclusive.^{236,255} (4) *EGFR/KRAS* mutation-negative cases may have detectable fusion of *EML4-ALK*.^{153,220}

Histogenetic Origins of Lung Adenocarcinoma Subtypes

Normal lung tissues, from which lung cancers arise, can be anatomically divided into two major components, the air-conducting system and the peripheral lung parenchyma where gases are exchanged. After generation of the two embryologic lung buds, repeated branching morphogenesis results in conducting airways and the subsequent development of the terminal sac and alveoli. During the later stages, the regulatory TTF-1 is ubiquitously expressed in the peripheral lung epithelial cells such as small bronchioles and alveoli.²⁵⁶ TTF-1 is potentially a lineage-specific survival oncogene of some lung adenocarcinomas.^{257,258} The peripheral bronchioloalveolar compartment (terminal bronchioles, alveolar ducts, and alveoli) also contains two potential tumor cells of origin, the Clara cells and type II pneumocytes,²⁵⁹ which together comprise the terminal respiratory unit (TRU) and give rise to tumors expressing TTF-1. These often manifest as a GGN on CT. The central conducting airways (bronchi) contain two potential candidate progenitor cells that give rise to tumors: the bronchial basal cells and the mucous cells.^{259,260} These tumors are TTF-1 negative and demonstrate a solid appearance on CT. Hierarchical clustering analysis of lung adenocarcinoma based on the expression profile demonstrated two major clusters, which correspond to TRU and non-TRU-type adenocarcinomas and thus two major subsets of adenocarcinoma with distinct histogenetic origins.²⁶¹

It is hypothesized that a subset of lung adenocarcinomas undergoes progression from AAH to AIS to invasive carcinoma and that this may be a stepwise process triggered by multiple genetic changes that supplement those responsible for initiation of the malignant phenotype.^{4,77,262,263} Although *EGFR* and *KRAS* mutations are observed from the earliest stages including normal epithelium^{264,265} and AAH, to invasive adenocarcinoma, *EGFR* gene copy number changes become widespread later at the stage of invasion and metastases.^{266,267} *EGFR*, *KRAS*, and *TTF-1* amplification are characteristic of this progression.^{258,266,268} *p53* mutation is more often found in invasive compared with noninvasive adenocarcinomas.^{48,269-273} Nevertheless, *p53* mutation has not been identified as a reliable prognostic marker or a therapeutic target.

Histologic Molecular Correlations

High-throughput analysis of DNA mutations has reshaped the molecular landscape of lung adenocarcinomas.⁹⁸ DNA sequencing of 623 known cancer-related genes in 188 adenocarcinomas identified 1013 somatic mutations.⁹⁸ In addition to confirmation of known tumor suppressor genes *p53*, *P16^{INK4}*, and *STK11/LKB1*, newly described mutations in *NF1* and *RBI* were detected at a frequency of 10% each. There were two other important findings: (1) mutations were often detected in the tyrosine kinase gene family members *EGFR*, *KRAS*, *ERBB4*, *EPHA4*, *EPH3*, *KDR*, and *FGFR4* that are potentially targetable by tyrosine-kinase inhibitors and (2) mutual exclusivity was demonstrated in several gene

mutation pairs including *EGFR/KRAS*, *EGFR/STK11*, and *NF1* and *p53/ATM*.^{98,274} Mutation frequency showed negative correlations between acinar, papillary, and BAC subtypes with mutations in *LRP1B*, *p53*, and *INHBA*.⁹⁸ Nevertheless, these mutations showed significant positive correlations with the solid subtype (Table 5).⁹⁸

Many publications have studied the prevalence and specificity of *KRAS* and *EGFR* alterations in lung adenocarcinoma (Table 5). The frequency of *KRAS* and *EGFR* mutations is each 10 to 30% with higher *EGFR* mutation frequency in Asians, never smokers, and nonmucinous tumors, whereas *KRAS* mutations are most common in non-Asians, smokers, and in invasive mucinous adenocarcinoma.¹⁴⁰ Mu-

TABLE 5. Adenocarcinoma Histologic Subtypes, Molecular, and Radiological Associations

Histological Subtype Predominant	Molecular Features	CT Scan Appearance	Gene Pathways Associated	References
Nonmucinous AIS and MIA	TTF-1 + (100%) <i>EGFR</i> mutation never smokers: 10–30% <i>KRAS</i> mutation smokers: 10–30%	GGN, part-solid nodule	Not known	141, 261, 275–277
Lepidic (nonmucinous)	TTF-1 + (100%) <i>EGFR</i> mutation never smokers: 10–30% <i>EGFR</i> amplification: 20–50% <i>KRAS</i> mutation smokers: 10% <i>BRAF</i> mutations: 5%	Part solid nodule GGN or solid nodule	Low cell cycle stimulatory ²⁷⁸ High Wnt	69, 261, 266, 276, 279–283
Papillary	TTF-1 + (90–100%) <i>EGFR</i> mutation: 10–30% <i>EGFR</i> amplification: 20–50% <i>KRAS</i> mutation 3% (lack of <i>KRAS</i>) <i>ERBB2</i> mutations: 3% <i>p53</i> mutations: 30% <i>BRAF</i> mutations: 5%	Solid nodule	Low cell cycle ²⁷⁸ stimulatory High EGFR High notch	69, 98, 264, 266, 279, 280–282, 284–286
Acinar	TTF-1 + or – <i>KRAS</i> mutation in smokers (20%) <i>EGFR</i> mutations <10% nonsmokers <i>EGFR</i> amplification: 10% <i>EML4/ALK</i> translocation: >5% <i>P53</i> mutations: 40%	Solid nodule	High PDGF ²⁷⁸ Low EGFR Low angiogenesis	69, 98, 269, 287
Micropapillary	<i>KRAS</i> mutations (33%) <i>EGFR</i> mutations (20%) <i>BRAF</i> mutations (20%)	Unknown	Unknown	69, 95, 283
Solid	TTF-1 (70%) MUC1 positive <i>KRAS</i> mutation smokers: 10–30% <i>EGFR</i> mutation never smokers: 10–30% <i>EGFR</i> amplification: 20–50% <i>EML4/ALK</i> translocation >5% <i>p53</i> mutation: 50% <i>LRP1B</i> mutations <i>INHBA</i> mutations	Solid	High cell cycle stimulatory ⁺²⁷⁸ High angiogenesis High JAK-STAT Low notch	69, 98, 125, 269, 287, 288
Invasive mucinous adenocarcinoma	TTF-1 (0–33% positive) <i>KRAS</i> mutation: 80–100% No <i>EGFR</i> mutation MUC5+ MUC6+ MUC2+	Consolidation, air bronchograms; less often GGO	Not known	123, 125, 126, 137, 140–142, 286, 289–291

AIS, adenocarcinoma in situ; MIA, minimally invasive adenocarcinoma; GGN, ground-glass nodule; EGFR, epidermal growth factor receptor; TTF, thyroid transcription factor.

tations in *EGFR* mainly affect the adenosinetriphosphate-binding pocket within the tyrosine kinase domain. The most common mutations result in an arginine for leucine substitution at amino acid 858 and in-frame deletions at exon 19. *EGFR* mutation status has been reported to be significantly associated with AIS, LPA, papillary, and micropapillary adenocarcinoma subtypes, although *EGFR* mutations can be seen in tumors with other histologic subtypes (Table 5). A large cohort of 806 NSCLC specimens showed a correlation between the presence of *EGFR* mutation and adenocarcinomas formerly classified as BAC or with BAC features (probably including AIS, MIA, and LPA),²⁷⁵ but another study with pathology review of 97 adenocarcinomas showed no difference.²⁷⁴ Predominant solid subtype has been shown to be significantly associated with *KRAS* mutations²⁸⁸ but not in all studies.⁶⁹ V600E *BRAF* mutations, occur in less than 5% of cases, and they have been associated with papillary, micropapillary, and lepidic components of invasive lung adenocarcinomas.^{95,279} Other less common types of *BRAF* mutations are reported such as V599E in a patient with a “well differentiated adenocarcinoma” (no subtyping information)²⁹² and two cases with missense mutations in exon 11 (G465V) and in exon 15 (L596R) where no histologic subtyping was reported.²⁹³

Table 5 summarizes our present knowledge on the molecular features associated with predominant patterns of adenocarcinoma. The only example of a strong correlation between a histologic subtype and a set of molecular and biologic features is that of invasive mucinous adenocarcinoma (former mucinous BAC), which typically have *KRAS* mutations and lack of *EGFR* mutation.^{55,140,141–144} Most of these tumors are negative for TTF-1, and they may express MUC 2-5-6 because of their derivation from bronchiolar mucinous goblet cells.^{146,289}

EGFR mutation is a specific target for therapy by EGFR-TKIs and is a validated biomarker of treatment response based on three recent phase 3 trials (see detailed explanation in Clinical Recommendation section)^{8–11} and multiple phase 2 trials.^{228–233} Recently described mutation-specific antibodies for the *EGFR* exon 19 deletion and L858R mutation seem to be much more reliable in predicting *EGFR* mutation status than previous antibodies, but they require further testing and validation in clinical trials.^{238–240} Specific acquired *EGFR* mutations such as T790M as well as, other genetic alterations in *MET* (amplification), *ERBB3* (overexpression), and epiregulin (autocrine loop activation), account for approximately 50% of cases of TKI resistance.^{236,250,294–299}

Lung Cancers with ALK Translocations

A minority of lung tumors harbor a small inversion within chromosome 2p giving rise to the transforming fusion gene *EML4-ALK*. No activating mutations in the kinase domain are observed; the dimerization of the fusion protein causes its activation.²⁴⁶ Epidemiological characteristics include prevalence in 5% of lung adenocarcinomas. Younger age, male gender, and never or light smokers may identify a population of patients with greater chance of harboring this aberration.^{153,220,248,300} A variety of histologic features are reported including acinar, papillary, cribriform, mucin pro-

duction (intra- and extracytoplasmic), and signet-ring patterns.^{153,220,300–304}

It is still at issue whether other histological types such as squamous cell carcinoma and mucoepidermoid carcinoma also contain *EML4-ALK* translocations. Detection of the *EML4-ALK* translocations can be difficult and can be approached with several methods including immunohistochemistry, FISH, and reverse transcription-polymerase chain reaction.^{153,248,249,300–303,305} Immunohistochemistry requires use of antibodies and methods that are validated to correspond well to *EML4-ALK* translocations, and it may serve as a useful screening method.^{153,302,306–308} Most tumors with *EML4-ALK* translocations are positive for TTF-1 and may be p63 positive.^{301,303} Tumors with *EML4-ALK* translocations seem to be mutually exclusive with *EGFR* and *KRAS* mutations and have a lower frequency of *p53* mutations.^{153,247,300,301,303} Another ALK translocation involving *KIF5B-ALK* fusion has been recently identified in lung adenocarcinomas; however, at present, insufficient data exist to define its specific histological nature.³⁰² De novo resistance mutations in the kinase domain of *EML4-ALK* have been reported to develop during ALK inhibitor therapy.²⁴⁹

Lung Adenocarcinoma Gene Expression Analyses

The messenger RNA genomic profiling of tumors can provide important information about pathogenesis, patient prognosis, and prediction of response to therapy in a fashion that complements histological evaluation. Unsupervised clustering analysis consistently shows three distinct groups of adenocarcinomas associated with tumor morphology^{69,261,309,310} and with lung developmental pathways. Beer et al.³⁰⁹ showed that tumors within the three clusters were significantly correlated with differentiation, stage, and morphology as classified by bronchial-derived or lepidic morphology. Borczuk et al.³¹⁰ showed that invasive features were associated with the cluster containing more aggressive tumors. The three groups consisted of noninvasive and minimally invasive tumors (≤ 5 mm); mixed-invasive and lepidic pattern tumors; and solid-invasive cancers. Motoi et al.⁶⁹ demonstrated that the three clusters correlated strongly with former BAC, solid, and papillary subtypes, respectively. Takeuchi et al.²⁶¹ showed that expression profile-defined adenocarcinoma subtypes were correlated with morphology and with normal lung developmental pathways. Morphologic analysis revealed two branches consisted of TRU-type adenocarcinomas, which are based on lepidic pattern and expression of TTF-1 and surfactant proteins, and non-TRU adenocarcinomas that lack these characteristics. TRU tumors were further divided into TRU-a and TRU-b classes. Functional annotation showed retention of normal peripheral differentiated lung features in the TRU types, which contrasted with the cell cycling and proliferation enriched annotation of genes associated with the non-TRU tumors.

Although *EGFR* mutations are found in association with papillary predominant adenocarcinomas (Table 5)^{69,98} and TRU-a tumors, whereas *KRAS* mutations are more frequent in the solid and TRU-b tumors, it is clear that oncogene mutation status is not a primary determinant of the molecular

subtypes as defined by gene expression profiling.³¹¹ Taken together, unsupervised clustering defines three morphologically distinct groups of lung adenocarcinomas. These include (1) AIS and MIA; (2) invasive nonsolid adenocarcinoma; and (3) invasive adenocarcinoma, predominantly solid.^{69,261,309,310} Thus, these molecular profiles provide biological plausibility for the proposed classification scheme that creates separate categories based on evaluation of lepidic pattern and other components, including solid pattern.

Recently Bryant et al.²⁷⁸ used the lung adenocarcinoma gene expression data from Shedden et al.⁹⁹ together with complete pathological review to examine associations between 27 known cancer-related pathways and the adenocarcinoma subtype, clinical characteristics, and patient survival. Unsupervised clustering of adenocarcinoma and gene expression enrichment analysis reveals three main clusters and that cell proliferation is the most important pathway separating tumors into subgroups.²⁷⁸ Further, adenocarcinomas with increased cell proliferation demonstrate significantly poorer outcome and an increased solid subtype component. Interestingly, tumors with any solid component have decreased survival, when compared with tumors without a solid component. Significant associations between specific histologic subtypes, gene expression pathways, and clusters were also reported, some of these are included in Table 5. The consistency of these findings was demonstrated using two independent lung adenocarcinoma cohorts from Japan ($N = 87$) and France ($N = 89$) using the identical analytic procedures.²⁷⁸

Tumor messenger RNA profiling is emerging as a source of clinically significant information regarding patient outcome after resection. Several predictors have been developed based on methodologically sound approaches that include independent validation.^{312–324} The results of these studies are heterogeneous in terms of the number of genes both in the predictors and in the specific genes included in each signature. This heterogeneity is expected given differences in study design, assay platform, tumor histology, and patient selection. A large, multicenter, blinded evaluation of eight independently derived genomic signatures of prognosis in 442 adenocarcinomas demonstrated that the addition of clinical covariates enhanced the performance of the signatures, relative to using gene expression alone.⁹⁹ A method that relied on the correlated expression of 100 gene clusters to predict subject outcome produced relatively good performance with several other methods showing similar performance.⁹⁹ Relatively higher expression of a cluster of 545 genes enriched for cell proliferation was associated with poor outcome. This study is a model for the careful handling of challenges inherent in translational cancer genomic studies and for its vast repository of clinical and pathologically annotated data. Independent prospective evaluation of the predictive accuracy of these signatures, prospective clinical trials, and application to small biopsy specimens^{200–203} will be required to extend this area of research.

Copy Number Analyses of Lung Adenocarcinoma Subtypes

Multiple studies have defined lung adenocarcinoma subtypes by using techniques to assess DNA copy number

changes.^{41,69,257,280,284,325–327} Adenocarcinoma subtype was examined in a comprehensive analysis using CGH by Aviel-Ronen et al.,³²⁶ who contrasted former BAC and invasive mixed-type adenocarcinoma with former BAC features, most of which would probably be classified as invasive adenocarcinoma with predominant lepidic growth in the new classification. A large number of specific chromosomal alterations were detected such as gain at 1p, 2q, 5p, 7p, 11p, 11q, 12q, 16p, 16q, 17q, 20q, and 21q in both former BAC and the adenocarcinomas with lepidic growth. Although both types had similar chromosomal changes, the invasive adenocarcinomas with lepidic growth showed greater variability and frequency of chromosomal changes and with longer segmental alterations and deletions. Deletions were also more common in adenocarcinomas with lepidic growth and were observed mainly on 3p and 5q and to a lesser extent on 4q and 6q. The genomic profile of former BAC seems to be distinguishable from that of invasive adenocarcinoma with lepidic growth, with the latter displaying greater genomic aberrations. This demonstrates a progression at the genomic level from former BAC to the invasive areas of adenocarcinoma with lepidic growth.

Weir et al.²⁵⁷ found the most common focal amplification event in lung adenocarcinoma involved chromosome 14q13.3 in 12% of cases and *TTF-1*, also known as *NKX2-1* was identified in this region. Barletta et al.⁴¹ examined histologic correlations with amplification of the *TTF-1* gene, and six cases demonstrated *TTF-1* amplification among the 49 acinar, papillary, and solid subtypes but not in tumors classified formerly as BAC.

EGFR gene amplification was examined using FISH by Hirsch et al.,²⁸⁴ who demonstrated that *EGFR* gene copy number detected by FISH is associated with improved response to gefitinib therapy in patients with advanced-stage former BAC and in adenocarcinomas with lepidic growth. A strong relationship between mutation and *EGFR* amplification was also reported by Cappuzzo et al.³²⁸ Conde et al.²⁸⁰ reported similar results with a higher percentage of mutations among adenocarcinomas with former BAC and papillary morphologies relative to adenocarcinomas without these features. Chang et al.³²⁷ used CISH and found that TKI responsiveness was significantly associated with *EGFR* mutation and adenocarcinoma morphology but only marginally with increased *EGFR* gene copy number. Other studies report similar findings, but the relationship between adenocarcinoma subtype and *EGFR* copy number changes is often not indicated.^{195,198,287} Motoi et al.⁶⁹ was one of the first studies to examine this and found no strong correlations between adenocarcinoma subtype and *EGFR* amplification using CISH.

EGFR copy number analysis during the progression of adenocarcinomas has been examined.^{264,267} *EGFR* mutations precede copy number abnormalities. *EGFR* copy number heterogeneity was greater in the primary tumor than in corresponding metastases.²⁶⁴ *EGFR* amplification correlated with high histologic grade and/or invasive growth and was rare in the precursor lesions AAH and former BAC.²⁶⁷ Thus, tumors with these changes appear more aggressive. Zhu et

al.²³⁶ showed that using a multivariate Cox model, high *EGFR* copy number was both a significant prognostic factor for poor survival (HR: 1.93, CI: 1.09–3.44, $p < 0.025$) and a significant predictive factor of an erlotinib effect on survival (HR: 0.33, CI: 0.15–0.71, $p < 0.005$). The amplification of *MET* may be one possible mechanism associated with tumor resistance to erlotinib.²⁶⁷ Finally, the application of these types of FISH analyses to small diagnostic samples was examined by Zudaire et al.²⁰¹ They found that more than 90% of cases of paraffin-embedded transthoracic FNA samples were suitable for FISH for both *EGFR* and *c-MYC* analyses. These studies suggest that even when limited tumor material is available, copy number analyses may provide prognostic information for *EGFR* amplification and an explanation for resistance to EGFR-TKIs for *MET* amplification. Nevertheless, *EGFR* mutation is more predictive of response to EGFR-TKIs than amplification.^{198,241}

Multiple Pulmonary Nodules

Several techniques have been tested to distinguish metastases from synchronous primary tumors including DNA microsatellite analysis,^{329,330} CGH,³³¹ DNA mutation sequencing,^{332–336} immunohistochemistry,³³⁷ and gene expression analysis. The utility of these assays is enhanced by their potential application to small biopsy specimens. These approaches have not been prospectively validated; thus, their performance and efficacy in routine clinical practice remain to be established. Nevertheless, these molecular techniques offer promising new ways to help in the distinction of synchronous primary tumors from metastases in patients with multiple adenocarcinoma nodules, which is critical for accurate tumor staging, determination of prognosis, and for planning treatment.^{338,339}

Molecular Differences in Metastases versus Primary Tumors

There may be important differences between the primary tumor and metastases of lung adenocarcinoma both with respect to morphology and biomarker expression; however, more study of this problem is needed.³⁴⁰ The mutation status of metastases can be the same^{341,342} or different from that of the primary tumor and also among metastases, so a multidisciplinary approach is needed.^{343,344} The available data regarding *EGFR* mutations is mainly from tumor material collected at the time of diagnosis (either from the primary tumor or from metastases) and not from the point in time at which treatment with EGFR inhibitors is given.

Molecular Prognostic Factors

Biomarkers that can predict patient prognosis have been extensively sought during the past 20 years. Immunohistochemical markers for which meta-analyses have been done include *EGFR*,³⁴⁵ *TTF-1*,³⁴⁶ *p21ras*,³⁴⁷ *HER2*,³⁴⁸ *p53*,^{349,350} *Ki67*,³⁵¹ *BcIII*,³⁵² and cyclooxygenase 2.³⁵³ All but *EGFR*, *p21 ras*, and cyclooxygenase 2 were statistically significant by meta-analysis. Nevertheless, the magnitude of the association is generally weak with HRs that range from 1.13 to 1.57.

Meta-analyses^{347,349,350} showed that although prognostic impact of mutations of *p53* or *KRAS* gene might be statistically significant, their impact was not strong enough to be recommended for routine clinical use. In contrast, there is a suggestion that patients who underwent surgical resection for lung adenocarcinomas that have *EGFR* mutations seem to have better prognosis in the absence of EGFR-TKI therapy than those without, based on two retrospective observational studies.^{354,355}

Molecular Research Recommendations

1. More investigation is needed of copy number variation, genomic, and proteomic markers for their relationship to clinical and pathologic variables.
2. *EML4-ALK* fusion gene needs further study, particularly in *EGFR/KRAS*-negative cases.
3. We recommend that research studies of molecular markers be based on well-annotated clinical and pathologic datasets, with adenocarcinomas diagnosed according to this classification.
4. MicroRNAs need further evaluation to determine whether they can be helpful in lung adenocarcinoma risk stratification and outcome prediction.^{356,357} There is limited information regarding correlation with adenocarcinoma subtype classification.
5. Investigations combining both genomic and proteomic studies are needed to determine whether they can provide more accurate subclassification of NSCLC and adenocarcinoma, and more precise information regarding the risk stratification, outcome prediction, and treatment selection for different subtypes of adenocarcinoma.

RADIOLOGIC FEATURES

A number of terms have been used to describe lung adenocarcinomas by CT imaging. In particular, for tumors that present as small nodules, the terms used have reflected the various ground glass (nonsolid), solid, or part-solid appearances that can occur. Largely based on the Fleischner Society glossary of terms³⁵⁸ and the recently suggested guidelines by Godoy and Naidich³⁵⁹ for subsolid nodules, we propose the following definitions: (1) a pure GGN (synonym: nonsolid nodule) as a focal area of increased lung attenuation within which the margins of any normal structures, e.g., vessels, remain outlined, (2) a solid nodule as a focal area of increased attenuation of such density that any normal structures, e.g., vessels, are completely obscured, and (3) part-solid nodule (synonym: semisolid nodule) as a focal nodular opacity containing both solid and ground-glass components.^{358,359} The Fleischner Society glossary of terms for thoracic imaging defines a nodule on a CT scan as “a rounded or irregular opacity, well or poorly defined, measuring up to 3 cm in greatest diameter” in any plane.³⁵⁸ If the opacity is greater than 3 cm, it is referred to as a mass.³⁵⁸ The ≤ 3 cm cutoff is in keeping with our concept of the maximum accepted size for the pathologic diagnosis of AIS and MIA. The term subsolid nodule has also entered common radiologic usage, referring to both part-solid nodules and pure

GGN.³⁵⁹ Optimal evaluation of subsolid nodules requires thin-section CT scans (≤ 3 mm thickness) to assess the solid versus ground-glass components.^{359,360}

Radiologic Spectrum According to Histologic Subtype

AAH is the earliest preinvasive lesion for lung adenocarcinoma detectable by thin-section CT. It appears as a small (usually ≤ 5 mm), GGN (Figure 11).^{19,23,129,361–365} AAH characteristically appears as a very faint pure GGN usually measuring ≤ 5 mm.^{130,366} The pure GGN of AAH can be single or multiple.^{129,365,367}

AIS is best demonstrated at CT (preferably thin section) and sometimes can be seen on chest radiography. It is a noninvasive lesion and nonmucinous AIS presents typically as a pure GGN (Figure 12) but sometimes as a part solid or occasionally a solid nodule.^{19,23,128,131,362,367–370} AIS can be bubble like.^{131,365,370,371} Mucinous AIS can appear as a solid nodule or consolidation (Figure 13). The pure GGN of AIS usually appears at thin-section CT as slightly higher attenuation than the very faint GGN of AAH.^{130,366,367} AIS also can be single or multiple.^{19,128,131,365,370}

MIA is variable in its imaging presentation and is, as yet, not fully described, but a provisional description of the nonmucinous type at thin-section CT is a part-solid nodule consisting of a predominant ground-glass component and a small central solid component measuring 5 mm or less (Figure 14).^{47,58} Mucinous MIA (Figure 14) is less common than nonmucinous MIA and appears as a solid or part-solid nodule.^{52,93,126} There is an overlap among imaging features of AAH, AIS, and MIA.

Radiology Recommendation 1

When an opacity in the lung adenocarcinoma spectrum is either a pure GGN or part-solid nodule with a predominant ground-glass component, we recommend that the term BAC no longer be used. These tumors should be classified by the new terms: AIS, MIA, and LPA (strong recommendation, low-quality evidence).

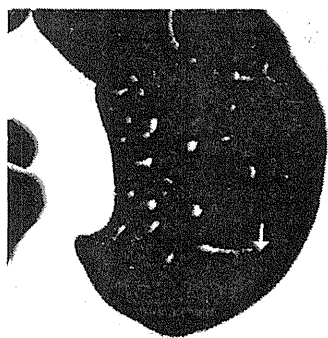


FIGURE 11. CT of preinvasive lesion (AAH or AIS). Axial 2-mm image through the left upper lobe shows a 5 mm pure ground-glass nodule (GGN), which has remained stable for 8 years (arrow). AAH and AIS can be single or multiple. AIS, adenocarcinoma in situ; CT, computed tomography.

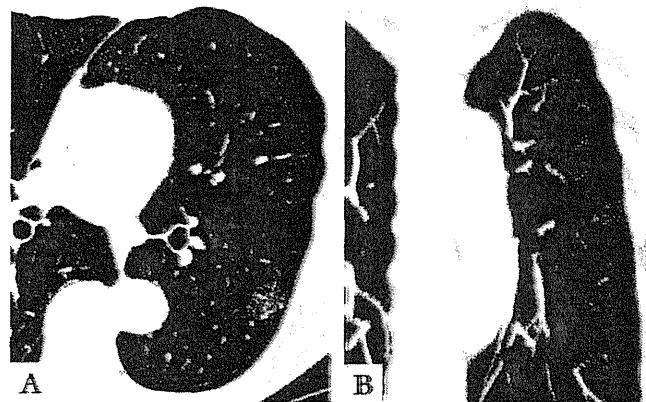

FIGURE 12. CT of a peripheral 2 cm nonmucinous AIS. A, Axial CT section. B, Coronal maximal intensity projection (MIP) image shows a pure GGN in the left lower lobe. Vessels and lung architecture are seen through the nodule. AIS, adenocarcinoma in situ; CT, computed tomography; GGN, ground-glass nodule.

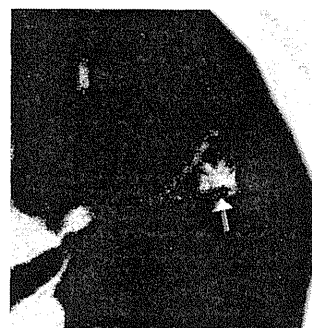

FIGURE 13. CT of mucinous adenocarcinoma in situ; 2 cm predominantly solid nodule with air bronchogram (arrow) is noted in the left upper lobe. CT, computed tomography.

Invasive adenocarcinoma is usually a solid nodule (Figure 15) but may also be part solid (Figure 16) and occasionally a GGN.^{23,58,103,125,129–134,367,370–372} A lobar pattern of ground-glass opacity (GGO) may occur (Figure 17). Bubble-like or cystic lucencies in stage IA adenocarcinoma have been described as correlating with well-differentiated tumors^{131,132,370,371,373,374} and slow growth.^{132,374} Thick (≥ 2 mm) coarse spiculation has been associated with lymph node metastasis, vascular invasion, and decreased survival post resection.^{23,375} For stage IA adenocarcinoma presenting as a part-solid nodule, an extensive ground-glass component suggests a favorable prognosis.^{18,20,23,103,105,376–388} Histologically, the ground-glass component typically corresponds to a lepidic pattern and the solid component to invasive patterns. An intratumoral air bronchogram usually indicates a well-differentiated tumor.^{132,370,375,387} Absence of pleural retraction for stage IA adenocarcinoma is also a favorable prognostic sign.^{375,389} In solid adenocarcinomas, the presence of notches, or concave cuts on thin section CT, has been associated with poor differentiation on histology and adverse outcome.³⁹⁰

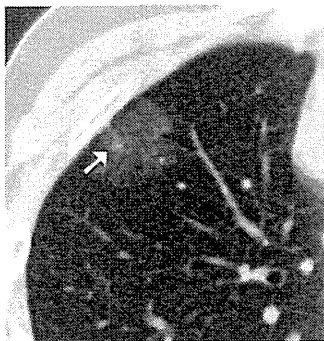

FIGURE 14. CT of nonmucinous minimally invasive adenocarcinoma. Axial 2-mm CT section shows a peripheral, predominantly ground-glass, part-solid nodule in the right upper lobe that includes a 4×3 mm solid component (arrow), which corresponded to invasion by pathology. CT, computed tomography.

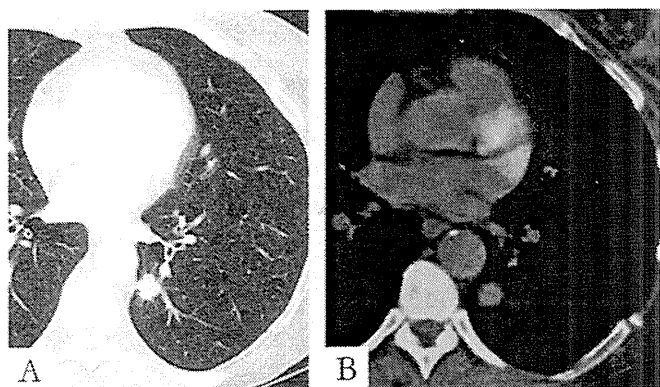


FIGURE 15. CT and FDG-PET of invasive adenocarcinoma. A, Axial CT image and (B) FDG-PET images show a 2-cm spiculated hypermetabolic solid nodule in the left lower lobe. CT, computed tomography; FDG-PET, fluorodeoxyglucose positron emission tomography.

Invasive mucinous adenocarcinoma, formerly called mucinous BAC, characteristically presents in imaging studies as a range of nodules to lobar replacement by a spectrum of patterns including GGO, mixed GGO/solid foci, or consolidation,^{126,128} but intraalveolar mucus may make the CT appearance solid or nearly solid (Figs. 18 and 19).^{125,391} The mucoid component may appear as homogeneous consolidation with soft-tissue attenuation that is lower than that of muscle. After administration of an intravenous iodinated contrast agent, vessels are well shown traversing these regions (CT angiogram sign).^{126,125,133,391} Overlap does occur between imaging features of mucinous and nonmucinous invasive adenocarcinomas.

Radiology Recommendation 2

For overtly invasive adenocarcinomas previously classified as mucinous BAC, we recommend they be separated from nonmucinous adenocarcinomas and be classified as invasive mucinous adenocarcinoma (strong recommendation, moderate quality evidence).

Remark: At CT, this entity is usually solid or mostly solid, has frequent air bronchograms, shows a lobar or multilobar distribution, and frequently consists of multiple nodular or consolidative opacities (former term multicentric BAC).

Size and Growth Rate of Lesions

AAH characteristically is ≤ 5 mm but in a minority of cases may be up to 12 mm.^{19,276,129,363,364,368} Growth is very slow. Although it has been suggested that a pure GGN less than 5 mm is so unlikely to become a cancer that it needs no follow-up,³⁵⁹ optimal frequency and duration of CT follow-up of a GGN of any size are as yet unclear.

AIS is variable in size, but most are 2 cm or less. Growth is very slow. Suspicious GGNs, i.e., ≥ 5 mm diameter, are usually followed by at least annual follow-up CT examination, and an increase in size or attenuation is regarded as a sign of probable progression to invasive disease.³⁵⁹ For sizes more than 10 mm, closer follow-up is indicated with CT every 6 months to 1 year. Nevertheless, all recommendations for following suspicious GGNs to date have been based on data from small observational studies and need further evaluation.^{131,361,368,372,387,392-394}

MIA has not yet been well defined in terms of imaging findings, in part, because the histopathologic definition is difficult, and little is known about size and growth rates, but most MIA are less than 2 cm.⁵⁸ Invasive adenocarcinomas of the lung are variable in size and growth rates. For adenocarcinoma less than 2 cm, the smaller the tumor, the less likely there is to be vascular invasion.³⁷³ Size of an adenocarcinoma does predict metastatic disease to the central nervous system: for a node-negative adenocarcinoma of 2 to 6 cm, the probability of metastatic disease to the central nervous system has been reported as 0.14 for a 2 cm tumor, increasing linearly to 0.72 for a 6 cm tumor.^{395,396}

For small solid nodules suspicious for lung cancer at CT, the recommendations for follow-up per Fleischner Society guidelines are currently widely recognized.³⁹⁷⁻³⁹⁹ Nevertheless, these guidelines do not specifically address GGNs and part-solid nodules, as discussed by Godoy and Naidich.³⁵⁹

Because the sizes of many of the clinically problematic nodular lesions at CT are small, how size is measured is especially important. Differences in CT scanners, window settings, and inter- and intraobserver performance are common and may impact critically on assessments of size, especially in the CT follow-up of nodular lesions.⁴⁰⁰⁻⁴⁰⁵

Multiple Primary Lung Cancers

Multifocal lung adenocarcinomas are not uncommon, being found in up to 8 to 22% in surgically resected adenocarcinomas^{406,407} and 18% of adenocarcinomas detected in screening programs.⁶⁴ Multiple lung adenocarcinomas can occur in the setting of multiple AAH, AIS, and invasive adenocarcinoma (Figure 20).³⁶⁵ Similarities or differences in attenuation may provide clues regarding the relative percentage of lepidic versus solid histologic components.³⁵⁹ Subsolid nodules are very rarely metastatic.⁴⁰⁸

Positron Emission Tomography (Scanning)

Elevated standard uptake values (SUVs) on fluorodeoxyglucose positron emission tomography (PET) correlate

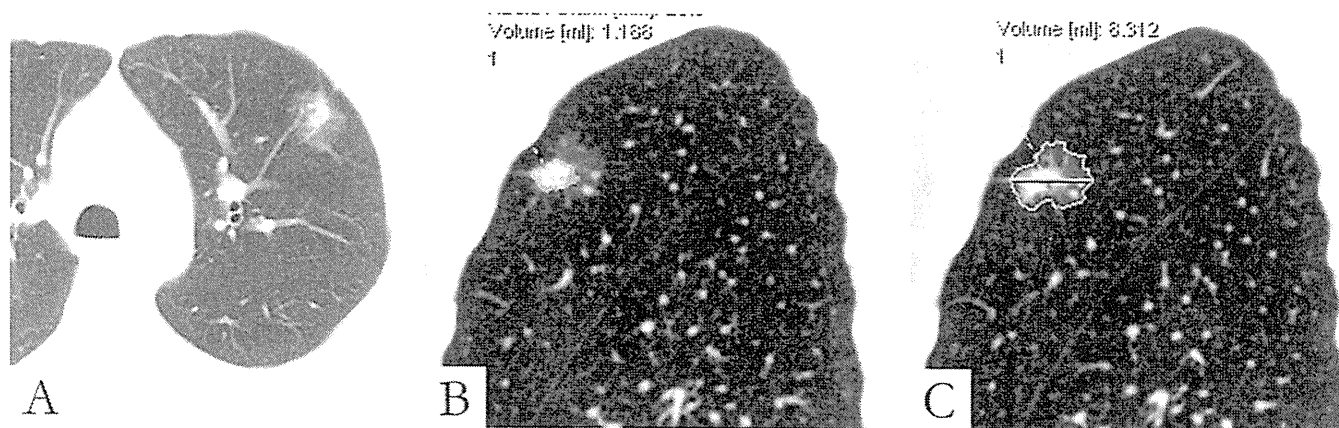


FIGURE 16. Invasive adenocarcinoma. *A*, Axial CT image shows a part-solid nodule in the left upper lobe. *B*, Corresponding sagittal CT images show automated estimation of the volume of (*B*) the solid component (1.188 cm³) and (*C*) the entire lesion (8.312 cm³). In this case, if tumor size were measured only by the invasive component, the size T factor would change from T2a (3.2 cm) to T1a (1.8 cm). Recording of total and invasive sizes are suggested until it is known whether invasive size predicts prognosis better than total size. CT, computed tomography.

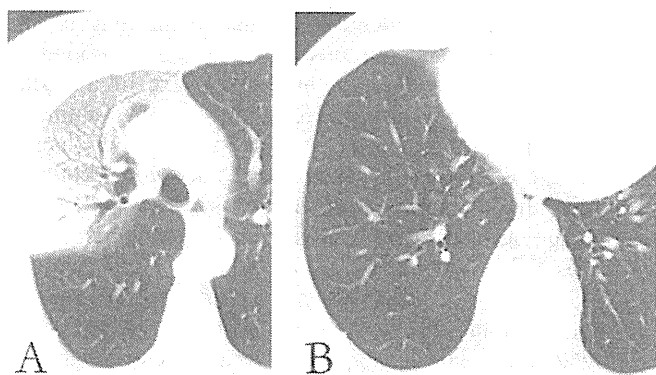


FIGURE 17. CT of nonmucinous lepidic predominant adenocarcinoma. CT images show (*A*) predominantly GGO in the right upper lobe and (*B*) multiple GGN in the right lower lobe. CT, computed tomography; GGN, ground-glass nodule.

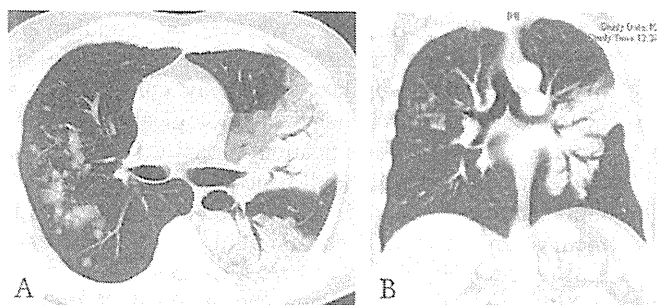


FIGURE 18. CT of invasive mucinous adenocarcinoma. *A*, Axial and (*B*) coronal CT images show multilobar consolidation and nodules mixed with GGO. Air bronchograms are present. CT, computed tomography; GGO, ground-glass opacity.

with cellular proliferation and aggressiveness of the primary cancer (Figures 15 and 19).^{369,409–417} Sensitivity of PET for AIS is usually very low.^{410,414} PET is commonly used for staging and follow-up of invasive adenocarcinoma, and for

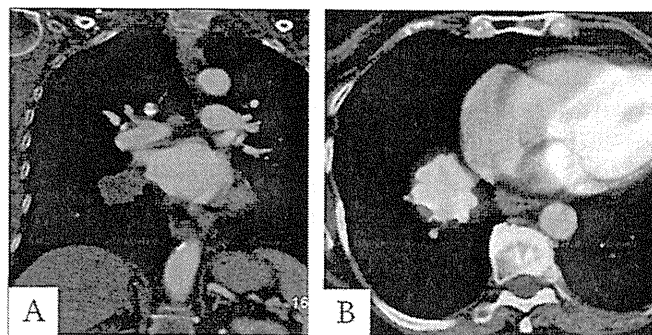


FIGURE 19. CT and FDG-PET of invasive mucinous adenocarcinoma. *A*, Coronal CT and (*B*) FDG-PET images show a hypermetabolic hypodense solid 4 cm mass in the right lower lobe. CT, computed tomography; FDG-PET, fluorodeoxyglucose positron emission tomography.

lesions of 7 mm or larger, SUV for adenocarcinoma of the lung tends to be lower than for other histologic types of lung cancer and correlate inversely with survival.^{416,418,419} PET may be more accurate than CT for assessing response to chemotherapy, although more studies are needed.^{420,421} For mucinous versus nonmucinous adenocarcinoma, after adjusting for size of the lesion, no significant difference in SUV has been found.¹²⁵ For a small, well-differentiated adenocarcinoma of low fluorodeoxyglucose avidity (e.g., maximum SUV <2.5), follow-up PET to assess change in SUV as a diagnostic tool unfortunately seems to be of only limited value.⁴²²

Magnetic Resonance

Magnetic resonance has been investigated as a method for differentiating among small AIS, mixed invasive adenocarcinoma/AIS, and invasive adenocarcinoma.^{285,423} In the studies by Ohno et al. and Tanaka et al.,^{285,423} for the distinction of AIS/lepidic predominant (former BAC) from

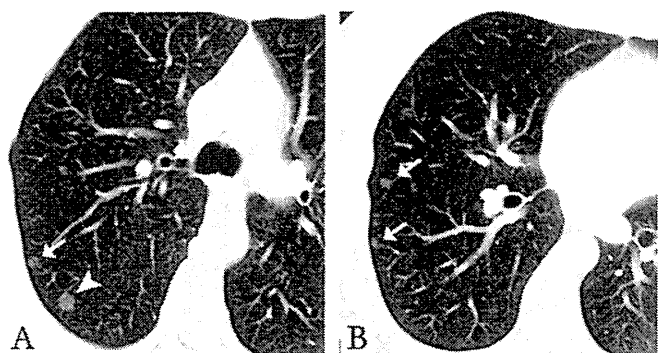


FIGURE 20. CT of multicentric GGNs of AIS/AAH. *A* and *B*, Multiple subsolid nodules (arrows) on axial 3-mm CT images show differing sizes and attenuation. These were presumed to represent preinvasive lesions (AAH and AIS). Because the dominant nodule in the right upper lobe posteriorly near the fissure in part *A* (large arrowhead) appears somewhat dense, it was excised surgically and found to be nonmucinous AIS. AAH, atypical adenomatous hyperplasia; AIS, adenocarcinoma in situ; CT, computed tomography; GGN, ground-glass nodule.

invasive adenocarcinoma, sensitivity was 86% and 97%, and specificity was 100% and 77%, respectively.

Imaging-Guided Percutaneous Needle Biopsy for Molecular and Immunohistochemical Correlations

Percutaneous imaging-guided needle biopsy, whether obtained by aspiration or as a core, allows molecular characterization from even minimal samples.^{200,201,203}

Radiology Recommendations

1. When an opacity in the lung adenocarcinoma spectrum is either a pure GGN or part-solid nodule with a predominant ground-glass component, we recommend that the term BAC no longer be used. These tumors should be classified by the new terms: AIS, MIA, and LPA (strong recommendation, low-quality evidence).
2. For overtly invasive adenocarcinomas previously classified as mucinous BAC, we recommend they be separated from nonmucinous adenocarcinomas and be classified as invasive mucinous adenocarcinoma (strong recommendation, moderate quality evidence).

Remark: At CT, this entity is usually solid or mostly solid, has frequent air bronchograms, shows a lobar or multilobar distribution, and frequently consists of multiple nodular or consolidative opacities (former term multicentric BAC).

Radiology Considerations for Good Practice

1. Radiologists performing biopsies should obtain sufficient tissue not only for traditional microscopic analysis but also for immunohistochemical and molecular analysis.
2. Thin-section CT technique should be used for part-solid lesions, to record the size of (a) the solid component and

(b) total tumor size, including both solid and ground-glass components (Figure 16).

3. Changes in shape, size, and attenuation help determine follow-up and when intervention is appropriate.

Radiology Research Recommendations

1. What is the natural history of single and multiple GGNs? The frequency of invasive transformation of these lesions is unknown.
2. How should tumor size be measured: single largest diameter, bidimensional, volume? For part-solid lesions, size of both the entire lesion and solid component should be mentioned, because prognosis as a function of size is not yet well established in terms of the dimensions of the solid component. Correlation of the measurement of the solid component of part-solid lesions and size of the invasive component at histopathologic assessment is also needed. Careful attention to thin-section CT technique to assess changes over time in sizes of small adenocarcinomas of the lung is warranted. Inter- and intraobserver differences among radiologists for measurements of the size of a nodule remain an important arena for inquiry.^{400,402} Volumetric measurements also offer promise for assessing changes in size of indeterminate nodules, but error—both human and computer—remains an issue for small GGN, including identifying a possible solid component (Figures 17*B*, *C*).^{405,424,425}
3. What is the CT attenuation according to the newly proposed lung adenocarcinoma histologic subtypes? CT histogram analysis suggests that attenuation characteristics may differ among AAH, AIS, and MIA.³⁶⁶ Further investigations of these lesions using quantitative analysis are in order.
4. In the setting of multiple adenocarcinomas, can careful description of the attenuation (e.g., relative extent of ground glass versus solid components) for each nodule assist in the determination whether the nodules are metastases versus synchronous or metachronous primary carcinomas, similar to the way comprehensive histologic subtyping is helpful pathologically?¹⁰²
5. How can this new classification impact CT screening? Screening may reveal small cancers early in their natural history,^{64,372,426–434} and cost/benefit issues, both medical and economic, remain an arena of active current research.^{424,435–439}
6. What molecular correlations can be made with the spectrum of radiologic patterns of lung adenocarcinoma? Not many studies have attempted correlation of imaging and molecular findings. *EGFR* mutations have been described as correlating with more than 50% GGO,^{271,440,441} with size less than 3.5 cm^{440,442} and with a high SUV level at PET of advanced-stage disease.^{440,443} Ki-67 has been described as associated with high SUV levels at PET^{444,445} and with dedifferentiation of the tumor.⁴⁴⁵

SURGICAL FEATURES

The newly proposed adenocarcinoma classification, particularly introduction of the concepts of AIS and MIA, raises surgical issues to which no definite answer is available yet. This relates to sublobar resection for early-stage lung cancer, role of chest CT in selecting patients for sublobar resection, specific surgical approach for these lesions, extent of lymph node dissection, the role of frozen section analysis, and the treatment of multiple small lung cancers.

Is Sublobar (Limited) Resection Adequate Oncologic Treatment for Some Early Adenocarcinomas?

One of the main reasons for defining the concepts of AIS and MIA in this classification is to raise the question whether these diagnoses can be anticipated by a GGO appearance on CT when presenting as a small, solitary lesion and whether limited resection may be effective therapy for such lesions. Lobectomy is still considered standard surgical treatment for tumors 2 cm or less in size, which have a solid appearance on CT, because such tumors are invasive carcinomas. Whether there can be any change in this standard care for lesions that present with a GGO appearance on CT awaits the results of two randomized trials (Japan Clinical Oncology Group, JCOG 0802 in Japan and CALGB 140503 in North America) that randomize such patients to either lobectomy or sublobar resection. Recently, there have been numerous retrospective studies that have suggested that sublobar (limited) resection for early lung cancers may be adequate surgical treatment; however, these are not randomized trials.^{24–26} Most reports showed no difference in survival or in locoregional recurrence between lobectomy and sublobar resection for tumors 2 cm or less in size. Tumors with a GGN (GGO) appearance on CT are reported to have 100% disease-free survival at 5 years after complete resection.^{18–21}

Can CT be Used to Select Patients for Sublobar Resection?

In performing sublobar resections, several important factors affect the appropriateness of this intervention. These include the location (peripheral versus central), appearance (ground glass versus solid), and size (T1a versus T1b versus T2) of the tumor. CT images, especially obtained by high-resolution CT scan with thin slices, are indispensable to evaluate these factors, and recent studies show rather good image-pathological correlations.³⁵⁹ In recent studies correlating CT findings of GGOs with histopathology, many of these lesions, though not all, correspond to preinvasive, noninvasive, or early forms of neoplastic growth, especially those of adenocarcinoma lineage.^{18–23,359,424}

Is There a Difference in Outcome between Video-Assisted Thoracoscopic surgery versus Thoracotomy in the Treatment of Early-Stage Lung Adenocarcinoma?

Several series suggest that there is no difference in overall survival between patients who have lobectomies performed by video-assisted thoracoscopic surgery (VATS) versus those performed by thoracotomy for clinical stage I non-small cell lung

cancer.^{446,447} Morbidity seems to be lower with the VATS approach. VATS is a standard approach for peripheral wedge resections; VATS segmentectomy is much less widely performed and requires further evaluation.⁴⁴⁸

What can be Expected of Pathologists at Frozen Section?

For a limited resection to be adequate oncologically, a precise pre- and intraoperative diagnosis is critical. The accuracy of intraoperative frozen section analysis in determining whether small lung adenocarcinomas have an invasive component still needs to be defined. The predictive value of frozen section ranges from 93 to 100% but not all articles clearly report the accuracy of frozen section analysis.^{65–67,449}

Evaluation of margins by frozen section may be problematic, especially when stapler cartridges have been used on both sides. Scraping or washing of staple lines with subsequent cytological analysis has been attempted.^{450,451} When a sublobar resection is performed, frozen section analysis of an interlobar, hilar, or any suspicious lymph node is a useful staging evaluation, and when positive nodes are found, a lobectomy is indicated when there is no functional cardiopulmonary limitation.

Should a Systematic Lymph Node Dissection be Performed in Every Early-Stage Adenocarcinoma?

The necessity of systematic hilar and mediastinal lymph node dissection is based on the fact that approximately 20% of pulmonary adenocarcinomas ≤ 20 mm and 5% of cases ≤ 10 mm in size are reported to have nodal metastases.^{452–454} Lobe-specific nodal dissection, which limits dissection to the primary nodal regions draining the involved lobe, has been shown to be a potentially adequate alternative to complete systematic nodal dissection.^{26,455,456} A recently reported multicenter prospective clinical trial randomizing patients with intraoperatively staged T1–2N0 nonhilar N1 NSCLC to lymph node sampling versus systematic nodal dissection showed that systematic nodal dissection identified occult disease in 3.8% of patients but was not associated with a benefit in overall survival.⁴⁵⁷ These results should not be generalized to higher stage tumors. Recent studies also show that in some specific subsets of very early-stage adenocarcinoma, especially GGO lesions, systematic lymph node dissection is not always required.⁴⁵⁸

Multiple Lesions

In the setting of multifocal lung adenocarcinomas, when there is no evidence of mediastinal lymph node invasion, multiple nodules are not a contraindication for surgical exploration.^{64,459} A standard treatment algorithm for multiple lesions has not yet been established. Several factors have to be taken into consideration: number and size of the different nodules, synchronous versus metachronous lesions, ipsilateral versus contralateral, primary versus metastatic lesions, and specific nature (AAH, AIS, and MIA).