

better visualization of such lesions compared to the NBI videoendoscope system.

Conflict of Interests

All authors have no conflict of interests or financial ties to disclose.

Acknowledgment

The authors wish to thank Christopher Dix for his assistance in editing the English-language revision of this paper.

References

- [1] A. Jemal, R. Siegel, E. Ward, Y. Hao, J. Xu, and M. J. Thun, "Cancer statistics, 2009," *CA Cancer Journal for Clinicians*, vol. 59, no. 4, pp. 225–249, 2009.
- [2] H. Y. Yiu, A. S. Whittemore, and A. Shibata, "Increasing colorectal cancer incidence rates in Japan," *International Journal of Cancer*, vol. 109, no. 5, pp. 777–781, 2004.
- [3] S. J. Winawer and A. G. Zauber, "Colonoscopic polypectomy and the incidence of colorectal cancer," *Gut*, vol. 48, no. 6, pp. 753–754, 2001.
- [4] D. K. Rex, C. S. Cutler, G. T. Lemmel et al., "Colonoscopic miss rates of adenomas determined by back-to-back colonoscopies," *Gastroenterology*, vol. 112, no. 1, pp. 24–28, 1997.
- [5] S. Bensen, L. A. Mott, B. Dain, R. Rothstein, and J. Baron, "The colonoscopic miss rate and true one-year recurrence of colorectal neoplastic polyps. Polyp prevention study group," *The American Journal of Gastroenterology*, vol. 94, no. 1, pp. 194–199, 1999.
- [6] S. E. Kudo, H. Kashida, T. Tamura et al., "Colonoscopic diagnosis and management of nonpolypoid early colorectal cancer," *World Journal of Surgery*, vol. 24, no. 9, pp. 1081–1090, 2000.
- [7] T. Uraoka, Y. Saito, T. Matsuda et al., "Endoscopic indications for endoscopic mucosal resection of laterally spreading tumours in the colorectum," *Gut*, vol. 55, no. 11, pp. 1592–1597, 2006.
- [8] J. C. Brooker, B. P. Saunders, S. G. Shah et al., "Total colonic dye-spray increases the detection of diminutive adenomas during routine colonoscopy: a randomized controlled trial," *Gastrointestinal Endoscopy*, vol. 56, no. 3, pp. 333–338, 2002.
- [9] T. Matsuda, Y. Saito, K. I. Fu et al., "Does autofluorescence imaging videoendoscopy system improve the colonoscopic polyp detection rate?—a pilot study," *American Journal of Gastroenterology*, vol. 103, no. 8, pp. 1926–1932, 2008.
- [10] N. Uedo, K. Higashino, R. Ishihara, Y. Takeuchi, and H. Iishi, "Diagnosis of colonic adenomas by new autofluorescence imaging system. New autofluorescence imaging system: a pilot study," *Digestive Endoscopy*, vol. 19, no. 1, pp. S134–S138, 2007.
- [11] N. Nakaniwa, A. Namihisa, T. Ogihara et al., "Newly developed autofluorescence imaging videoscope system for the detection of colonic neoplasms," *Digestive Endoscopy*, vol. 17, no. 3, pp. 235–240, 2005.
- [12] A. L. McCallum, J. T. Jenkins, D. Gillen, and R. G. Molloy, "Evaluation of autofluorescence colonoscopy for the detection and diagnosis of colonic polyps," *Gastrointestinal Endoscopy*, vol. 68, no. 2, pp. 283–290, 2008.
- [13] H. Machida, Y. Sano, Y. Hamamoto et al., "Narrow-band imaging in the diagnosis of colorectal mucosal lesions: a pilot study," *Endoscopy*, vol. 36, no. 12, pp. 1094–1098, 2004.
- [14] H. M. Chiu, C. Y. Chang, C. C. Chen et al., "A prospective comparative study of narrow-band imaging, chromoendoscopy, and conventional colonoscopy in the diagnosis of colorectal neoplasia," *Gut*, vol. 56, no. 3, pp. 373–379, 2007.
- [15] M. Y. Su, C. M. Hsu, YU. P. Ho, P. C. Chen, C. J. Lin, and C. T. Chiu, "Comparative study of conventional colonoscopy, chromoendoscopy, and narrow-band imaging systems in differential diagnosis of neoplastic and nonneoplastic colonic polyps," *American Journal of Gastroenterology*, vol. 101, no. 12, pp. 2711–2716, 2006.
- [16] T. Uraoka, Y. Saito, T. Matsuda et al., "Detectability of colorectal neoplastic lesions using a narrow-band imaging system: a pilot study," *Journal of Gastroenterology and Hepatology*, vol. 23, no. 12, pp. 1810–1815, 2008.
- [17] S. R. Hamilton and L. A. Aaltonen, Eds., *World Health Organization Classification of Tumours: Pathology and Genetics of Tumours of the Digestive System*, IARC Press, Lyon, France, 2000.
- [18] A. Rastogi, A. Bansal, S. Wani et al., "Narrow-band imaging colonoscopy—a pilot feasibility study for the detection of polyps and correlation of surface patterns with polyp histologic diagnosis," *Gastrointestinal Endoscopy*, vol. 67, no. 2, pp. 280–286, 2008.
- [19] C. Helbig and D. K. Rex, "Narrow band imaging (NBI) versus white-light for colon polyp detection using high definition (HD) colonoscopies," *Gastrointestinal Endoscopy Journal*, vol. 63, Article ID AB213, 2006.
- [20] T. R. Kaltenbach, S. Friedland, and R. Soetikno, "A new benchmark in the colorectal neoplasm miss rate during colonoscopy: results of a randomized controlled trial of a wide-angle view (170°) colonoscopy comparing narrow band imaging and white light," *Gastrointestinal Endoscopy Journal*, vol. 65, Article ID AB127, 2007.

FUTURE TECHNOLOGY FOR INTUATION IMPROVEMENT

RESPONSIVE INSERTION TECHNOLOGY

[Online Video](#)

 YUTAKA SAITO¹ AND HIDENOBU KIMURA²

¹Endoscopy Division, National Cancer Center Hospital, Tokyo, Japan; and ²R&D Division 1, Endoscope Department, Olympus Medical Systems Corp. Tokyo Japan

The colonoscopic insertion technique is still one of the most difficult endoscopic procedures to master and development of a new colonoscope that is easier to insert is much awaited especially into the cecum without patient discomfort. We focused on reducing patient pain and boosting the success rate of colonoscope insertion into the cecum in complicated cases. As a result, we have successfully developed two mechanisms: “Passive Bending” and use of a “High Force Transmission insertion tube.”

We believe these two mechanisms when combined together will contribute to a reduction in patient discomfort and an increase in the cecal intubation rate during many difficult colonoscopies, but further evaluation is required with respect to therapeutic endoscopy effectiveness and insertion for patients with long colons.

Key words: colonoscopic insertion, cecal intubation rate, passive bending, high force transmission insertion tube, difficult colonoscopy.

INTRODUCTION

Cecal intubation rates without patient discomfort are dramatically increasing with the development of the colonoscope into the pediatric-type colonoscope and improvements in insertion techniques for the one-man method.

A number of techniques and devices have reportedly been effective in reducing patient discomfort during difficult colonoscopies, improving the successful cecal intubation rate, shortening the insertion time to the cecum and reducing sedative dosages.¹ These include use of the pediatric colonoscope,² the variable stiffness colonoscope,³ the gastroscope,⁴ the double balloon endoscope,⁵ attaching a hood to the distal end of the colonoscope⁶ and the use of CO₂ insufflation.⁷

The colonoscopic insertion technique is, however, still one of the most difficult endoscopic procedures to master and development of a new colonoscope that is easier to insert is much awaited.

OLYMPUS TECHNOLOGY PART

Colonoscopes are said to be difficult to insert, especially into the cecum without patient discomfort. We have been working to improve the ease of insertion, mainly focusing on the mechanical phase. Although new technology has been developed in an attempt to improve insertion based on various innovative ideas that reach beyond conventional endoscope models, we are using technology based on conventional endoscopes. It is well recognized that colonoscopes show a diverse array of problems that need solving in order to improve insertion.

Correspondence: Yutaka Saito, Endoscopy Division, National Cancer Center Hospital, Tokyo 104-0045, Japan. Email: ytsaito@ncc.go.jp

Received 20 December 2010; accepted 17 January 2011.

© 2011 The Authors

Digestive Endoscopy © 2011 Japan Gastroenterological Endoscopy Society

Among those problems, we focused on reducing patient pain and boosting the success rate of colonoscope insertion into the cecum in complicated cases including adhesion cases where insertion is very difficult. We have successfully developed two techniques, which are introduced below: ‘passive bending’ and use of a ‘high force transmission insertion tube.’ Passive bending is a technique to improve insertion through flexure in the colon. The technology behind the high force transmission insertion tube enables the proximal control force applied by the physician to be efficiently transmitted to the distal end of the colonoscope, even when the insertion tube has looped.

Passive bending

Mechanism

The passive bending is located in proximity to the bending section located at the distal end of the endoscope as shown in Fig. 1. The passive bending portion basically has the same

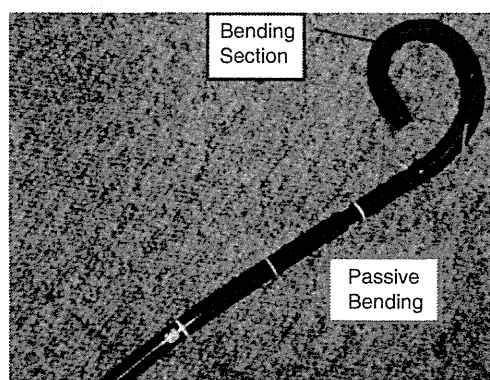


Fig. 1. Location of the passive bending portion in the endoscope insertion tube.

structure as that of the bending section, but unlike the bending section that bends through controlling it with the angulations' control knob, it will quickly bend when subject to external forces. It is characterized by a structure in which the curvature gradually increases from the bending section to the insertion tube as shown in Fig. 2.

In conventional colonoscopes, when the scope passes through a sharp flexure in the colon, the force applied by the physician when inserting the scope can sometimes directly

push up the wall of the colon because the distal end of the scope bends with a small radius – commonly known as the stick phenomenon (Fig. 3).

In a colonoscope equipped with a passive bending portion, the force applied by the physician will bend the passive bending portion in response to the reactive force from the colon. This will distribute the force with which the insertion tube is pushed so that the force that pushes the scope tip forward will be greater than that pushes up the wall of the colon. That is, the force applied by the physician is physically transferred at the passive bending portion, pushing the scope tip forward. The effect of the behavior is shown in Video 1 (see Supporting Information Video Clip S1). The passive bending enables the scope to make a mild turn so that it can pass smoothly through the sharp flexure in the colon, eliminating the stick phenomenon (Fig. 4).

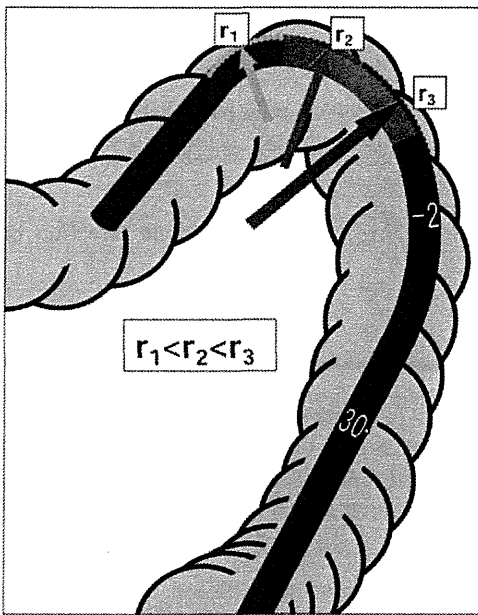


Fig. 2. Curvature of the passive bending.

High force transmission insertion tube

Mechanism

The colonoscope insertion tube essentially has a three-layer structure consisting of a metal flex tube (the innermost layer), a mesh tube and a polymer resin (the outermost layer) (Fig. 5). Any change in these materials or their production

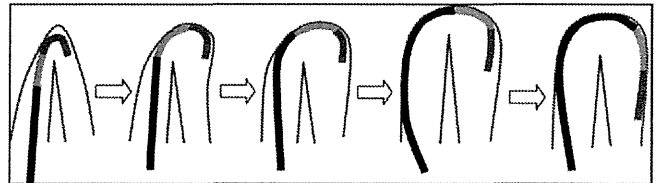


Fig. 4. Mechanism of passing through the sharp flexure by the passive bending.

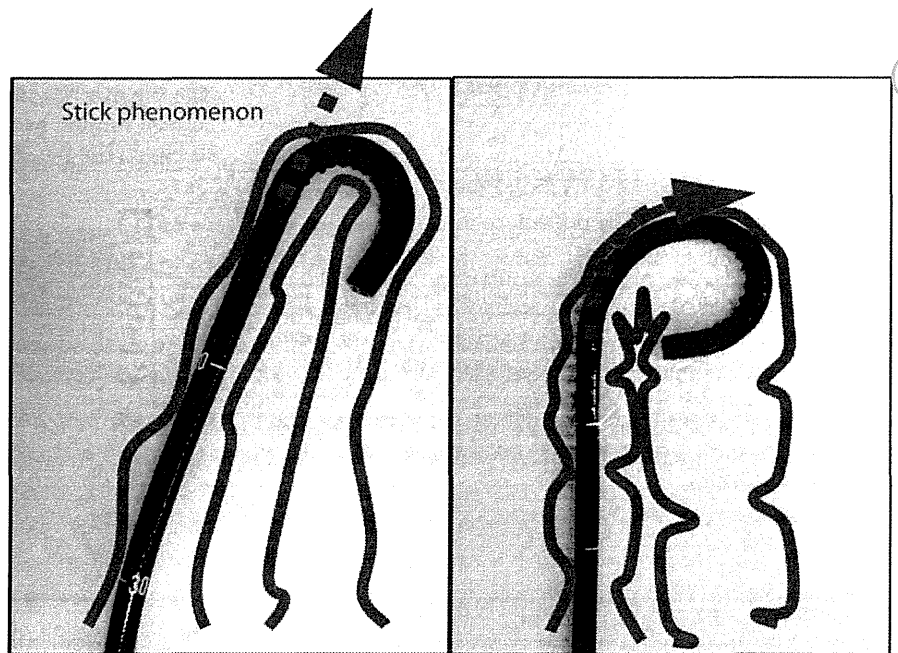


Fig. 3. Comparison figure between conventional model and passive bending model.

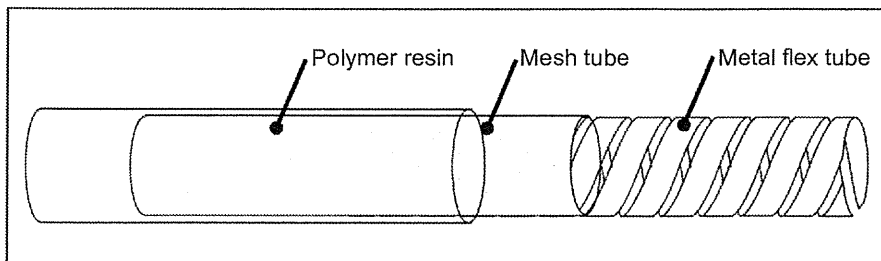


Fig. 5. Structure of the insertion tube.

methods will change the characteristics of the insertion tube. With the high force transmission insertion tube, it is possible to change the characteristics of the insertion tube so that the proximal control forces – ‘push,’ ‘twist’ and ‘pull’ – applied by the physician may be efficiently transmitted to the distal end of the colonoscope. This has enabled a fine manipulation at the proximal control section to be precisely transmitted to the insertion section so as to delicately rotate and push the tip of the colonoscope even when the insertion tube of the scope forms a loop. Similarly, when the distal end of the colonoscope reaches the deep portion of the colon (when the cecal intubation completed), a ‘twist’ control at the proximal insertion section is linearly transmitted to the distal end.

We believe these two mechanisms, when pulled together, will be able to contribute to a reduction in patient discomfort and an increase in the cecal intubation rate with difficult colonoscopies, including adhesion cases.

DISCUSSION

From the hands-on trial using PCF-PQ260L/I for the colon model and the floor discussions, we reached definite agreement on the usefulness of the responsive insertion technology for relieving patient discomfort.

The newly developed PCF-PQ260L/I has both the functions of passive bending and the high force transmission insertion tube. It was obvious that the bending function is useful for preventing the stick phenomenon, which causes severe pain for patients during colonoscopic insertion in splenic or hepatic flexures. In the practical setting, there are still some uncertain factors as to whether the torque of the right hand is transmitted to the tip of the colonoscope efficiently. This is solved by the new high force transmission insertion tube.

In contrast, there were several questions about the movement of the scope distal tip when using retroflex. In colorectal endoscopic submucosal dissections, endoscopists need to carry out delicate left and right angle operations using scope retroflexion, but it was argued whether such a delicate angle operation is possible with this ‘passive bending function’ in such a situation.

There is another limitation with cecal insertion. This scope is so thin and soft that it would be very difficult to insert the scope into the cecum without making a giant loop. The high force transmission insertion tube is another new and very effective function. The loss of torque transmission by the PCF-PQ260L/I is 40–50% less than with the conventional PCF-P240AL/I. It seems that the high force transmission insertion tube can be carried on all types of endoscopes and

has the big advantage of giving a marked improvement in the various endoscopic controls and has the potential to make up for the softness of the scope.

The final and most important question is what kind of interaction will happen when both passive bending and the high force transmission insertion tube are used. The OLYMPUS technicians should consider this further and improve the interaction between these two new functions.

In conclusion, this new scope with both the passive bending and high force transmission insertion tube functions seems very useful for difficult colonoscopies such as in thin old thin ladies or with severe adhesion patients. This scope is expected to find further practical applications for enteroscopy and endoscopic retrograde cholangiopancreatography for patients after a Roux-en-Y operation that has been very difficult or impossible to carry out with conventional endoscopy.

REFERENCES

1. Rex DK, Chen SC, Overhiser AJ. Colonoscopy technique in consecutive patients referred for prior incomplete colonoscopy. *Clin. Gastroenterol. Hepatol.* 2007; **5**: 879–83.
2. Marshall JB, Perez RA, Madsen RW. Usefulness of a pediatric colonoscope for routine colonoscopy in women who have undergone hysterectomy. *Gastrointest. Endosc.* 2002; **55**: 838–41.
3. Brooker JC, Saunders BP, Shah SG, Williams CB. A new variable stiffness colonoscope makes colonoscopy easier: A randomized controlled trial. *Gut* 2000; **46**: 801–5.
4. Kozarek RA, Botoman VA, Patterson DJ. Prospective evaluation of a small caliber upper endoscope for colonoscopy after unsuccessful standard examination. *Gastrointest. Endosc.* 1989; **35**: 333–5.
5. Kaltenbach T, Soetikno R, Friedland S. Use of a double balloon enteroscope facilitates cecal intubation after incomplete colonoscopy with a standard colonoscope. *Dig. Liver Dis.* 2006; **38**: 921–5.
6. Kondo S, Yamaji Y, Watabe H *et al.* A randomized controlled trial evaluating the usefulness of a transparent hood attached to the tip of the colonoscope. *Am. J. Gastroenterol.* 2007; **102**: 75–81.
7. Uraoka T, Kato J, Kuriyama M *et al.* CO₂ insufflation for potentially difficult colonoscopies: Efficacy when used by less experienced colonoscopists. *World J. Gastroenterol.* 2009; **15** (41): 5186–92.

SUPPORTING INFORMATION

Additional Supporting Information may be found in the online version of this article:

Video Clip S1. Comparison movie between conventional model and passive bending model. The passive bending enables the scope to make a mild turn so that it can pass smoothly through the sharp flexure in the colon, eliminating the stick phenomenon.

Please note: Wiley-Blackwell are not responsible for the content or functionality of any supporting materials supplied by the authors. Any queries (other than missing material) should be directed to the corresponding author for the article.



CURRENT STATUS AND THE CHALLENGES OF THE NBI DIAGNOSIS FOR COLORECTAL TUMOR

WEST MEETS EAST: PRELIMINARY RESULTS OF NARROW BAND IMAGING WITH OPTICAL MAGNIFICATION IN THE DIAGNOSIS OF COLORECTAL LESIONS: A MULTICENTER AUSTRALIAN STUDY USING THE MODIFIED SANO'S CLASSIFICATION

RAJVINDER SINGH,^{1,2} NAZREE NORDEEN,¹ SWEE LIN CHEN YI MEI,¹ ARTHUR KAFFES,³ WILLIAM TAM^{1,2} AND YUTAKA SAITO⁴

¹Lyell McEwin Hospital, ²University of Adelaide, Adelaide, South Australia and ³Royal Prince Alfred Hospital, Sydney, New South Wales, Australia; and ⁴National Cancer Centre Tokyo, Tokyo, Japan

Introduction: Narrow band imaging with optical magnification (NBI-Z) enables mucosal morphology to be assessed in real time by using light with narrowed band width and magnification of up to 115 \times .

Methods: Colorectal lesions detected were assessed with NBI-Z. Histology was predicted using the modified Sano's classification based on capillary network patterns (cn); type I: absent cn (hyperplastic polyp), type II: cn present, surrounding mucosal glands (adenoma), type IIIa: high density cn with tortuosity and lack of uniformity (intramucosal cancer) and type IIIb: nearly avascular cn (invasive cancer). Each lesion was also graded with a confidence level (low/high). High-definition videos (mean 28.2 s; range 12–55) of each lesion assessed with NBI-Z were then taken. This was followed by polypectomy, endoscopic or surgical resection. NBI-Z diagnosis was compared with the final histopathology. To test for interobserver agreement, an endoscopist blinded to the video acquisition process/histology was invited to grade the videos.

Results: A total of 50 lesions (2 assessors: 100 studies), with an average size of 8.4 mm (range 3–30), in 32 patients were assessed. Twenty were hyperplastic, 25 adenomas, 2 intramucosal and 3 invasive cancers of which 19 were located in the right and 31 in the left colon. The overall accuracy of NBI-Z in predicting histology was 90%, which increased to 95% (88/93) when lesions were predicted with high confidence. The sensitivity (Sn), specificity (Sp), positive (PPV) and negative predictive values (NPV) in differentiating neoplastic from non-neoplastic lesions with high confidence were 98%, 89%, 93% and 97%, respectively, while the Sn, Sp, PPV and NPV in predicting endoscopic resectability (type II, IIIa vs type I, IIIb) was 100%, 90%, 93% and 100%, respectively. The interobserver agreement between both assessors (κ value) was substantial at 0.89.

Conclusions: Using confidence levels, NBI-Z permits prediction of colorectal neoplasia with high accuracies and might allow prompt decisions to be made if a lesion should be left *in situ*, resected and discarded or biopsied. This approach might lead to substantial time and cost savings and could potentially reduce complications associated with polypectomy and endoscopic resections.

Key words: colorectal polyps, NBI, magnification.

INTRODUCTION

The detection rate of colonic polyps has greatly increased with improvements in resolution of imaging in video colonoscopy over the last few years. The higher pick-up rates of polyp detection has resulted in more polyps of non-neoplastic nature being biopsied or removed. This has inevitably created additional burden for pathological interpretation¹ as well as increased cost in addition to the added risk of complications. A suitable technique therefore, which enables distinction between non-neoplastic and neoplastic colorectal polyps *in vivo*, would not only increase the efficiency of treatment but minimize the cost and risks to patients. The hallmark of

differentiation would be dependent on predicting the underlying pathology based on the surface appearance of a colonic polyp.

Several endoscopic optical enhancing devices have been developed to improve visualization of mucosal microstructural and microvascular pattern, in an attempt to predict the underlying histology of lesions in real time. Optical techniques that are currently being researched include autofluorescence imaging, confocal endomicroscopy, endocytoscopy and optical coherence tomography.² All these techniques however require sophisticated and expensive instrumentation, and generally a great deal of expertise in using them in a clinical setting. Moreover most of these techniques are still mostly confined to tertiary level academic centers.

Narrow band imaging (NBI) is a novel endoscopic imaging technique that enhances the diagnostic capability of endoscopes in characterizing pathology, by using narrow band width filters.³ It is relatively simple to use, involving the activation of a switch during endoscopy to enhance the

Correspondence: Rajvinder Singh, Lyell McEwin Hospital, Haydown Road, Elizabeth Vale, SA 5112, Australia. Email: rajvinder.singh@health.sa.gov.au

Received 7 December 2010; accepted 13 January 2011.

© 2011 The Authors

Digestive Endoscopy © 2011 Japan Gastroenterological Endoscopy Society

visualization of mucosal and vascular surface topography. The advent of high-resolution magnification endoscopes provides the ability to magnify images up to a 115 times with resolutions up to 7.9 microns. Combination of NBI together with optical magnification has been reported to be useful in the diagnosis of pathologic lesions by improving mucosal pattern, vascular contrast and detail in the colon in a number of studies.⁴⁻⁹ However, all of these reports were based on the Lucera processor, which is not widely used in the Western world.

Olympus Optical (Tokyo, Japan) has recently developed a colonoscope (CF Q160Z1), which incorporates both NBI and optical magnification, and is compatible with Evis Exera II processor, which is commonly used in Australia, the USA and continental Europe. The Exera processor differs from the Lucera processor in that the color chip CCD is used compared with the black and white chip of the Lucera processor. The main aim of this study was hence to use this novel technology to validate the modified Sano's classification in the assessment of mucosal surface morphology in the prediction of colorectal neoplasia.

METHODS

The study was approved by the Central Northern Adelaide Health Service Ethics of Human Research Committee, Australia. Patients undergoing colonoscopy for bowel symptoms, polyp surveillance and family history screening for bowel cancer were invited to participate in the study. All patients gave written consent. Patients who were unable to consent, pregnant, breastfeeding, of child-bearing age, under 18 years of age or unable to undergo adequate bowel preparation were excluded from this study.

Equipment

All examinations were carried out with Olympus Exera II system (Olympus Co. Ltd, Melbourne, Australia). This system is equipped with a sequential illumination xenon light source, a zoom colonoscope (Olympus CF Q160Z1) and a high-definition television monitor (Olympus OEV181H). NBI splits white light into narrowed bandwidth light; blue (400–430 nm) and green (530–550 nm), with red light, which is normally used with white light endoscopy taken out of the equation. This allows the blue and green lights, which have more superficial penetration, to penetrate the superficial mucosal architecture, resulting in enhancement of mucosal pit patterns and vasculature. Optical magnification function is applied by depressing a lever on the colonoscope, which activates a motorized zoom lens at the distal tip of the scope. Altering focal distance of the lens allows a maximal magnification of up to 115×. Before colonoscopy, a transparent plastic cap was fitted and adjusted to a distance of 2 mm from the tip of the endoscope. Correct positioning of the cap was checked by seeing a thin rim of the cap on endoscopic views once it had been snugly fitted to the tip. Use of a cap enables the endoscopist to steadily fix the mucosa to the colonoscope, before applying the zoom mode. This allows optimal focus on the area of interest, to better assess mucosal patterns.

Procedure

All patients were offered deep sedation with intravenous Midazolam and Propofol by a nurse sedationist or an anes-

thetist. Bowel preparation was carried out with a combination of sodium picosulfate (10–20 mg) and polyethylene glycol (2 L) the day before the procedure. Liberal flushing of the mucosa with water and a defoaming agent, Simethicone was used to see the mucosa clearly. If interference from peristaltic activity of the colon was seen, an antispasmodic agent, hyoscine butyl bromide (Buscopan) (10–20 mg) was administered intravenously to minimize movement artifact. Once a polyp/lesion was detected, it was examined in greater detail after adequate cleansing of the surface. Each colorectal lesion was examined with NBI with optical zoom magnification (NBI-Z). If the image was out of focus, the non-zoom mode could be applied to obtain an overview of the colon and re-identify the polyp before application of the zoom mode again. All procedures were recorded and saved as high-definition wmv files.

Classification of polyps

Histology of these polyps were predicted using the modified Sano's classification, based on capillary network patterns (cn) seen on the surface of the polyp;

Type I: absent cn (hyperplastic polyp) (Fig. 1)

Type II: cn present, surrounding mucosal glands (adenoma) (Fig. 2)

Type IIIa: high density cn, with tortuosity and lack of uniformity (intramucosal cancer) (Fig. 3)

Type IIIb: nearly avascular or loose cn (invasive cancer) (Fig. 4)

Each of these lesions was then graded with a confidence level (low/high) for their presumed underlying histology in real time. Lesions were graded with high confidence only if the assessors were convinced beyond a reasonable doubt that the lesion showed characteristic features as described above. Conversely if there was any doubt about the endoscopic appearances, a low confidence rating was given. It must be stressed that these assessments was purely subjective in nature. This was followed by biopsies, polypectomy or surgical resection of the lesion. Specimens were sent in 10% formalin and processed with conventional Hematoxylin & Eosin stain. Histology was reviewed by a pathologist who was blinded to the endoscopic findings. NBI-Z diagnosis was then compared with the final histopathology. To test for interobserver agreement, an endoscopist blinded to the video acquisition process/histology was invited to grade the videos.

Statistical analysis

Statistical analysis was carried out using the Stata Statistical software (Stat ver. 10, College Station, TX, USA). The sensitivity (Sn), specificity (Sp), positive predictive value (PPV) and negative predictive value (NPV) of NBI-Z in differentiating neoplastic from non-neoplastic lesion and predicting endoscopic resectability was then compared with reference to the final histopathological diagnosis. Interobserver agreement of predicting histology of lesions was assessed using κ statistics.

RESULTS

A total of 50 lesions (2 assessors: 100 studies) in 32 patients, with a mean size of 8.4 mm (range 3–30) were assessed.

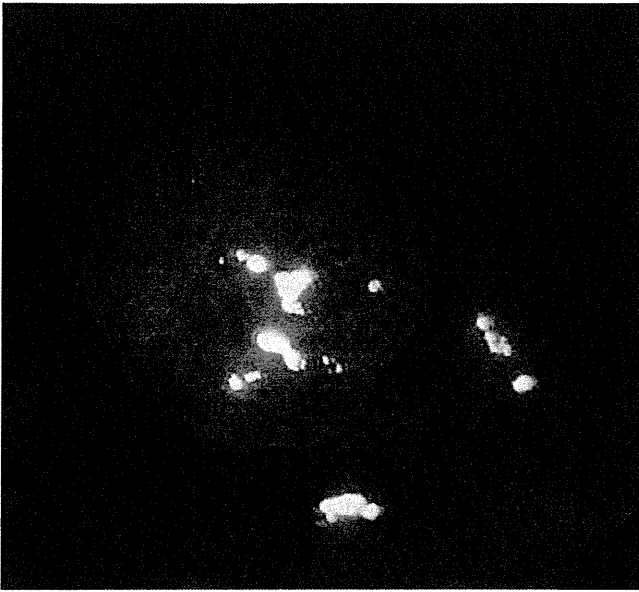


Fig. 1. Type I: absent capillary network (hyperplastic polyp).

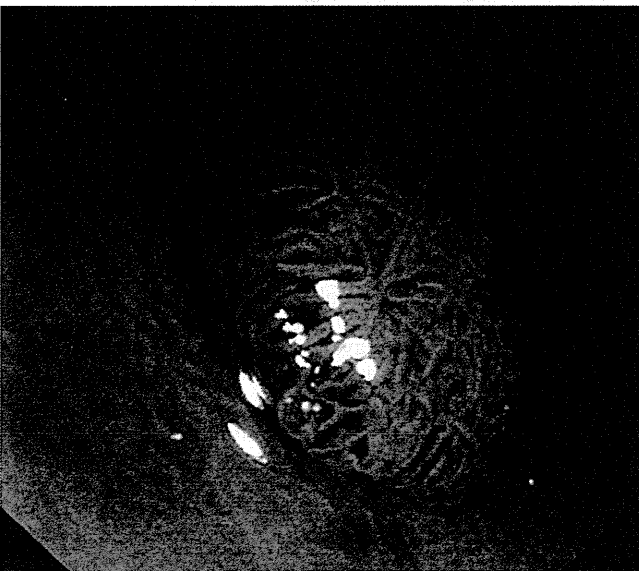


Fig. 2. Type II: capillary network present, surrounding mucosal glands (adenoma).

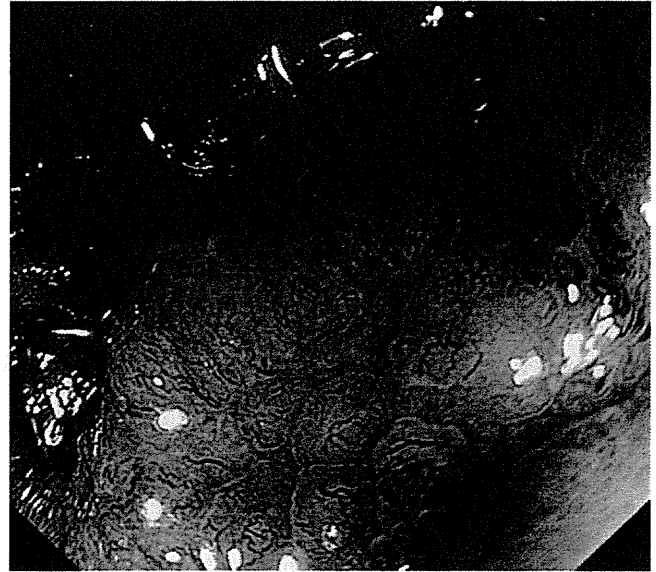


Fig. 3. Type IIIa: high density capillary network, with tortuosity and lack of uniformity (intramucosal cancer).

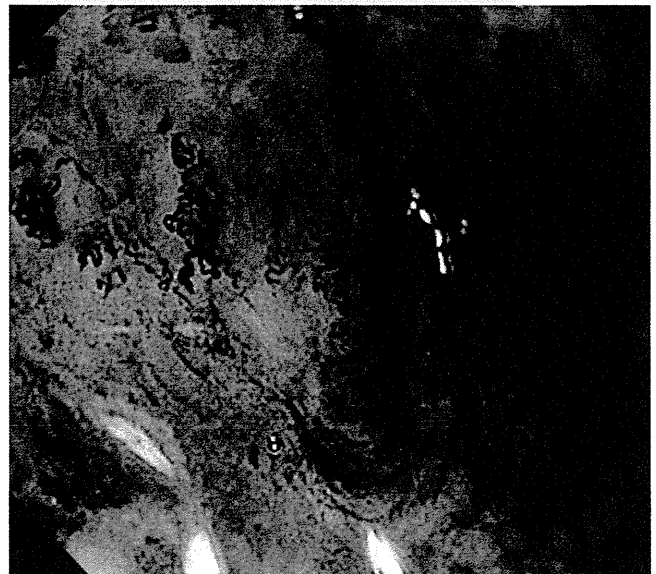


Fig. 4. Type IIIb: nearly avascular or loose capillary network (invasive cancer).

Twenty were hyperplastic, 25 adenomas, 2 intramucosal cancers and 3 invasive cancers. Nineteen lesions were located on the right side and 31 on the left side of the colon. The overall accuracy of NBI-Z in predicting histology was 90%, which increased to 95% (88/93) when lesions were predicted with high confidence. The Sn, Sp, PPV and NPV of using NBI-Z in differentiating neoplastic from non-neoplastic lesions with high confidence were 98%, 89%, 93% and 97%, respectively (Table 1). The Sn, Sp, PPV and NPV in predicting endoscopic resectability (type II, IIIa vs type I, IIIb) was 100%, 90%, 93% and 100%, respectively (Table 1). The inter-observer agreement between both assessors was substantial with a κ score at 0.89.

DISCUSSION

Bowel cancer screening programs instituted worldwide involve colonoscopic examination with the aim of halting the natural progression of adenomatous lesions into carcinoma. Ideally, the ability to discriminate between neoplasia and non-neoplastic lesions could make this practice more efficient, whereby a 'one stop' approach¹⁰ can be used. Lesions that are neoplastic can be resected and non-neoplastic lesions photographed, documented and left *in situ*.

Narrow band imaging with optical magnification has been commercially available for some time in the East and more recently in the West. This technique has been shown to

Table 1. Sensitivity (Sn), specificity (Sp), positive (PPV) and negative predictive values (NPV) in the prediction of neoplastic and non-neoplastic polyps and endoscopic resectability

	Sn	Sp	PPV	NPV
Neoplasia vs non-neoplasia	98%	89%	93%	97%
Endoscopic resectability	100%	90%	93%	100%

Comparison of NBI-Z Classification					
Pathology	Hyper	Adenoma	M-SM1, Ca	SM2	
Pit Pattern (Kudo)	I-II	III, IIIc, IV	VI	VN	
Inv. pattern	Non-neoplastic	Non-invasive		Invasive	
Sano	I	II	IIIa	IIIb	
Hirata	A	B	C1	C2	C3
Saito S	1	2	3v	3f	4
Wada	Normal, faint	network	dense	irregular/sparse	

Fig. 5. Comparison of various narrow band imaging with optical magnification (NBI-Z) classifications.

provide superior imaging characteristics compared with conventional white light endoscopy. Several studies have been published that shows the accuracy of NBI-Z at predicting histology of colorectal lesions (neoplastic vs non-neoplastic)^{4,11-13} and characterizing colorectal tumors based on evaluation of microvasculature appearance.¹⁴⁻¹⁶ All these studies, mainly from Japan and Taiwan were evaluated as being positive. This study in Australia, in which we set out to assess the usefulness of NBI-Z in differentiating neoplastic colonic lesions, has yet again yielded similar results albeit using a totally different processor. We also looked at the reproducibility by carrying out interobserver agreement with 'real-time' high-quality video assessments and applying confidence levels to the prediction. Apart from emphasizing its usefulness, this study also reflects that NBI-Z is certainly feasible beyond the East.

The ease of use, the relatively low cost of instrumentation and the proven high accuracy in predicting the histology of colonic polyps makes NBI-Z a very feasible option as a diagnostic digital chromoendoscopy tool. There is a huge potential in its application where hyperplastic polyps that are detected can be ignored, adenomatous polyps resected and discarded while carcinomatous polyps biopsied for confirmation of histology before surgical intervention. It must be stressed though that the variety of classification systems that are available presently can appear quite daunting and confusing for any endoscopist to follow (Fig. 5). We deliberately opted to follow the modified Sano's classification in this study as in our opinion it appeared to be relatively simple to follow.

Standardization of all the classifications is however of paramount importance and urgently needed.

In conclusion, this study has showed that using the modified Sano's classification and application of confidence levels, NBI-Z is able to predict colorectal neoplasia with high accuracies (West meets East!). This might allow prompt decisions to be made if a lesion should be left *in situ*, resected and discarded, or biopsied and might not only lead to substantial time/cost savings but could potentially reduce complications associated with polypectomy and endoscopic resection. Further studies addressing the cost benefits of this approach are warranted.

ACKNOWLEDGEMENT

This study would not have been possible without the continuous support of the ANZELF (Australian New Zealand Endoscopic Leaders Forum) and Olympus Australia.

REFERENCES

- Butterly LF, Chase MP, Pohl H, Fiarman GS. Prevalence of clinically important histology in small adenomas. *Clin. Gastroenterol. Hepatol.* 2006; **4**: 343-8.
- Tajiri H, Matsuda K, Fujisaki J. What can we see with the endoscope? Present status and future perspectives. *Dig. Endosc.* 2002; **14**: 131-7.
- DaCosta RS, Wilson BC, Marcon NE. Optical techniques for the endoscopic detection of dysplastic colonic lesions. *Curr. Opin. Gastroenterol.* 2005; **21**: 70-9.
- Machida H, Sano Y, Hamamoto Y *et al.* Narrow-band imaging in the diagnosis of colorectal mucosal lesions: a pilot study. *Endoscopy* 2004; **36**: 1094-8.
- Yashui S, Manabo M, Atsushi O *et al.* Optical digital chromoendoscopy during colonoscopy using narrow band imaging system. *Dig. Endosc.* 2005; **17**: S43-8.
- Singh R, Shonde A, Kaye P *et al.* Distinction between neoplastic and non-neoplastic colorectal polyps utilizing narrow band imaging with magnification: a novel technique to increase the efficacy of CRC screening? *Scand. J. Gastroenterol.* 2008; **43** (3): 380-1.
- East JE, Suzuki N, Stanrinidis M, Guenther T, Thomas HJ, Saunders BP. Narrow Band Imaging for colonoscopic surveillance in hereditary nonpolyposis colorectal cancer. *Gut* 2008; **57** (1): 65-70.
- Singh R, Owen V, Shonde A, Kaye P, Hawkey C, Ragnath K. White light endoscopy, narrow band imaging and chromoendoscopy with magnification in diagnosing colorectal neoplasia. *World J. Gastrointest. Endosc.* 2009; **1** (1): 45-50.
- Ikematsu H, Matsuda T, Emura F *et al.* Efficacy of capillary pattern type IIIA/IIIB by magnifying narrow band imaging for estimating depth of invasion in early colorectal neoplasms. *BMC Gastroenterol.* 2010; **10** (33).
- East JE, Suzuki N, Saunders BP. Comparison of magnified pit pattern interpretation with narrow band imaging versus chromoendoscopy for diminutive colonic polyps: a pilot study. *Gastrointest. Endosc.* 2007; **66**: 310-16.
- Hirata M, Tanaka S, Oka S *et al.* Evaluation of microvessels in colorectal tumors by narrow band imaging magnification. *Gastrointest. Endosc.* 2007; **66**: 945-52.
- Su MY, Hsu CM, Ho YP, Chen PC, Lin CJ, Chiu CT. Comparative study of conventional colonoscopy, chromoendoscopy, and narrow band imaging systems in differential

- diagnosis of neoplastic and non-neoplastic colonic polyp. *Am. J. Gastroenterol.* 2006; **101** (12): 2711–16.
13. Chiu HM, Chang CY, Chen CC *et al.* A prospective comparative study of narrow-band imaging, chromoendoscopy, and conventional colonoscopy in the diagnosis of colorectal neoplasia. *Gut* 2007; **56**: 373–9.
 14. Hirata M, Tanaka S, Oka S *et al.* Magnifying endoscopy with narrow band imaging for diagnosis of colorectal tumours. *Gastrointest. Endosc.* 2007; **65**: 988–95.
 15. Kanao H, Tanaka S, Oka S *et al.* Clinical significance of type VI pit pattern subclassification in determining the depth of invasion of colorectal neoplasms. *World J. Gastroenterol.* 2008; **14** (2): 211–17.
 16. Katagiri A, Fu KI, Sano Y *et al.* Narrow band imaging with magnifying colonoscopy as a diagnostic tool for predicting the histology of early colorectal neoplasia. *Aliment. Pharmacol. Ther.* 2008; **27** (12): 1269–74.

CURRENT STATUS AND THE CHALLENGES OF THE NBI DIAGNOSIS FOR COLORECTAL TUMOR

SANO'S CAPILLARY PATTERN CLASSIFICATION FOR NARROW-BAND IMAGING OF EARLY COLORECTAL LESIONS

TOSHIO URAOKA,¹ YUTAKA SAITO,² HIROAKI IKEMATSU,³ KAZUHIDE YAMAMOTO⁴ AND YASUSHI SANO⁵

¹Department of Endoscopy, Okayama University Hospital and ⁴Department of Gastroenterology and Hepatology, Okayama University Graduate School of Medicine, Dentistry and Pharmaceutical Sciences, Okayama, ²Endoscopy Division, National Cancer Center Hospital, Tokyo, ³Department of Gastrointestinal Oncology & Endoscopy, National Cancer Center East Hospital, Kashiwa and ⁵Gastrointestinal Center, Sano Hospital, Kobe, Japan

Narrow-band imaging enhances visualization of the mucosal surface structure and vascular network and helps to increase the visibility of neoplasia by improving contrast. Sano and his colleagues first reported its efficacy for endoscopic use in the gastrointestinal tract and later proposed a sequential classification of the mucosal vascular network patterns according to histopathological categories. Sano's 'capillary pattern classification' was established to facilitate diagnosis of early colorectal lesions on a step-by-step basis. This review focuses on the utility and effectiveness of Sano's capillary pattern classification when examining early colorectal lesions using narrow-band imaging.

Key words: capillary pattern, colonoscopy, narrow-band imaging (NBI), Sano classification.

INTRODUCTION

A prototype narrow-band imaging (NBI) system was developed in 1999 and its efficacy for endoscopic use in the gastrointestinal tract was first reported in 2001 by Sano *et al.*¹ This unique optical imaging technology is based on modifying the bandwidth transmittance of spectral features using various filters to enhance real-time visualization of the mucosal surface structure and vascular network that cannot be observed using white light endoscopy or chromoendoscopy during colonoscopy.^{2–4} Sano and his colleagues later proposed a sequential classification of the mucosal vascular network patterns according to histopathological categories. This review focuses on the utility and effectiveness of Sano's 'capillary pattern (CP) classification' when examining early colorectal lesions using NBI.

PRINCIPLE OF CP CLASSIFICATION

Angiogenesis is critical for the transition of premalignant lesions in a hyperproliferative state to the malignant phenotype. Microcapillary vessels in normal mucosa or on the surface of hyperplastic lesions are arranged in a honeycomb pattern around mucosal crypts without any change in vessel diameter, but the capillaries in neoplastic lesions become elongated with larger diameters as the number and density of microcapillary vessels increase in the process of changing from premalignant to malignant lesions. Sano *et al.* focused on microvascular differences based on their histopathological

findings. Contrast of the CP in the superficial mucosal layer markedly improved by utilizing narrow-band illumination with the central wavelengths of 415 nm and 540 nm. As a result, Sano *et al.* were able to develop a sequential method using NBI to more readily identify abnormal microcapillaries as indicators of neoplasia. In addition, they called the mucosal capillary mesh arranged in a honeycomb pattern around mucosal crypts 'meshed capillary vessels' (MCVs)³ and referred to the microvascular architecture using NBI colonoscopy with magnification as the CP classification.⁵

Machida, Sano and their colleagues first reported that the NBI system was effective as a means of high-contrast endoscopy for improving endoscopic visualization of early colorectal lesions in their pilot study.⁶ In addition, their research examined the usefulness of NBI with magnification for the differential diagnosis of neoplastic from non-neoplastic lesions based on the presence of vascular network patterns and determined that diagnostic accuracy using NBI with magnification was higher than that of conventional colonoscopy (93.4% vs 79.1%) and equivalent to that of chromoendoscopy using indigo-carmin dye spraying (93.4% vs 93.4%).

SANO'S CP CLASSIFICATION

Meshed capillary vessels are classified by microvascular architecture using NBI colonoscopy with magnification into three CP classifications: types I, II and III.³ In addition, CP type III lesions are further subdivided into types IIIA and IIIB.⁷ The definition of each CP classification is summarized in Fig. 1 and described in detail below.

CP type I

The MCVs arranged in a honeycomb pattern around the mucosal glands are invisible or only faintly visible on

Correspondence: Toshio Uraoka, Department of Endoscopy, Okayama University Hospital, 2-5-1 Shikata-cho, Kita-ku, Okayama 700-8558, Japan. Email: turaoka@md.okayama-u.ac.jp

Conflict of interest: The authors declare no conflict of interest.

Received 16 December 2010; accepted 27 December 2010.

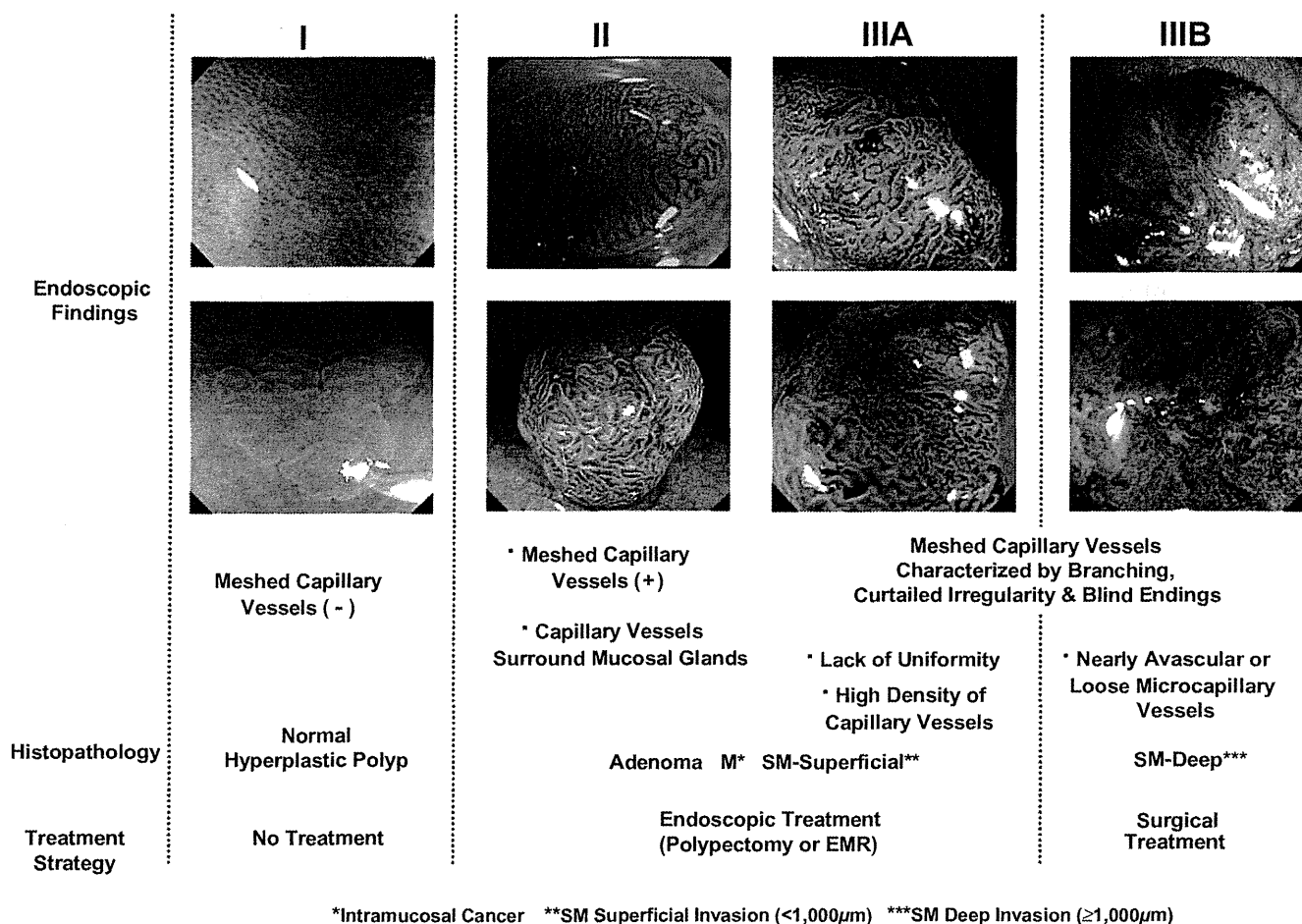


Fig. 1. Sano's capillary pattern classification (CP classification) of early colorectal lesions using NBI.

magnification observation using NBI colonoscopy because image resolution is insufficient to view the network in normal mucosa closely. Although microvessel density in small hyperplastic polyps is greater than in normal mucosa^{5,8} the diameter of MCVs is not substantially larger than in normal mucosa so MCVs are virtually impossible to see or only slightly visible. MCVs are often recognized in portions of hyperplastic polyps including large hyperplastic polyps and hyperplastic polyps with serrated changes.

CP type II

Adenomatous lesions regardless of macroscopic type appear as dark brown neovascular lesions (brownish areas) easily identifiable using NBI colonoscopy without magnification. MCVs are clearly visible because these capillaries are elongated and have abnormally large diameters.

CP type III

Capillary pattern type III lesions are defined as showing an irregular unstructured pattern in a mesh-like microvascular architecture and show at least one of the following characteristics: irregular size, complicated branching and/or dis-

rupted irregular winding when compared with small caliber capillaries observed in adenomatous polyps (CP type II).

CP type IIIA

Capillary pattern type IIIA lesions clearly show visible microvascular architecture and high microvessel density with a lack of uniformity, branching, curtailed irregularly and blind endings.

CP type IIIB

Capillary pattern type IIIB lesions show a clearly visible demarcation between normal and cancerous mucosa on the surface based on the presence of a nearly avascular or loose microvascular area.

USING NBI TO DIFFERENTIATE NEOPLASTIC FROM NON-NEOPLASTIC COLORECTAL POLYPS

The effectiveness of NBI in the differential diagnosis of colorectal polyps has clearly been shown in several prospective studies⁹⁻¹¹ indicative of a growing consensus on the subject.

Table 1. Correlation of MCVs using NBI and histopathology

	Histopathology	
	Neoplastic	Non-neoplastic
MCVs (+)	107	3
MCVs (-)	4	36

Sensitivity, specificity and overall accuracy: 96.4%, 92.3% and 95.3%, respectively.

MCV, meshed capillary vessels; NBI, narrow-band imaging.

Table 2. Correlation of capillary patterns II/III and histopathology

	Histopathology	
	Neoplastic	Non-neoplastic
CP II	100	3
CP III	3	38

Sensitivity, specificity and overall accuracy: 96.4%, 92.3% and 95.3%, respectively.

CP, capillary pattern.

Sano *et al.* conducted a prospective study to evaluate the usefulness of MCVs observed by NBI magnification for differentiating between neoplastic and non-neoplastic colorectal lesions polyps <10 mm that are the most common and difficult to diagnosis accurately.¹⁰ NBI was successful in detecting MCVs in 107 of 111 neoplastic and 36 of 39 non-neoplastic polyps resulting in overall diagnostic accuracy, sensitivity and specificity of 95.3%, 96.4% and 92.3%, respectively (Table 1). In addition, Horimatsu *et al.* reported that the appearance of visualized MCVs during magnifying NBI colonoscopy could be used to identify angiogenesis in colorectal low grade adenomas and hyperplastic polyps based on immunohistochemical analysis.¹² These two studies showed the capability of NBI to differentiate between neoplastic and non-neoplastic lesions using real-time image processing during colonoscopy without the need for any dye spraying or staining.

USING NBI TO PREDICT HISTOLOGY OF EARLY COLORECTAL NEOPLASIA

Katagiri *et al.* conducted a prospective study to evaluate whether different CP (CP type II and CP type III) visible using NBI with magnification provided sufficiently high reliability for distinguishing adenomas from intramucosal and invasive cancers.¹³ The overall diagnostic accuracy, sensitivity and specificity of their results were 95.5%, 90.3% and 97.1%, respectively (Table 2).

USING NBI TO DETERMINE DEPTH DIAGNOSIS OF EARLY COLORECTAL CANCER

The CP classification was established to facilitate diagnosis of early colorectal lesions on a step-by-step basis. CP type III has been shown to be highly accurate in predicting carcinomatous lesions so a sequential study was conducted to clarify

Table 3. Correlation of capillary patterns IIIA/IIIB and histopathology

	Histopathology	
	M [†] , SM-superficial (SM1) [‡]	SM-deep (SM2-3) [§]
CP IIIA	100	3
CP IIIB	3	38

Sensitivity, specificity and overall accuracy: 84.8%, 88.7% and 87.7%, respectively.

[†]M, intramucosal cancer.

[‡]SM1, slight submucosal invasive cancer (<1000 µm).

[§]SM2-3, deep submucosal invasive cancer (≥1000 µm).

CP, capillary pattern.

the diagnostic accuracy of the CP classification for assessing depth of invasion of early colorectal cancers. Ikematsu *et al.* reported that the sensitivity, specificity and diagnostic accuracy of CP types IIIA and IIIB for differentiating intramucosal or slight submucosal invasion <1000 µm from deep submucosal invasion ≥1000 µm were 84.8%, 88.7% and 87.7%, respectively (Table 3).⁷

THERAPEUTIC STRATEGY BASED ON CP CLASSIFICATION

The NBI system is a new non-dye device for differentiating neoplastic from non-neoplastic polyps with a diagnostic accuracy including pit pattern analysis equivalent to that of chromoendoscopy. Normal mucosa and hyperplastic lesions are categorized as type I in the CP classification so follow up without endoscopic resection is generally recommended whereas endoscopic resection should be carried out for CP classification type II lesions, which indicate adenomas.

In contrast, the treatment options for CP type III lesions are considered to be either endoscopic resection or surgery. Diagnostic accuracy of CP types IIIA and IIIB has been very reliable in predicting depth of invasion of early colorectal tumors although other published reports have showed even higher diagnostic accuracy ranging from 93.3% to 98.8% based on an analysis of pit patterns with crystal violet staining.^{14,15} When CP type III is identified on the surface of a lesion therefore we recommend conducting a careful diagnosis of the pit pattern using crystal violet staining before making any treatment decisions.

FUTURE PROSPECTS FOR CP CLASSIFICATION

An accurate and efficient classification method is needed that is generally easy to use and has the capacity of improving the learning curve. It has been reported that NBI using the CP classification increased the differential diagnostic skill of less-experienced colonoscopists, who underwent specialized training, to a level comparable with that of highly experienced colonoscopists.¹⁶ North American validation has also been recently reported using the CP classification and NBI without magnification for identification of neoplastic and non-neoplastic colorectal lesions.¹⁷ As for determining invasion depth of early colorectal cancers, however, there has not been any prospective study conducted so far comparing the

CP and pit pattern classification methods. In addition, potential cost savings in screening and surveillance colonoscopy examinations need to be determined before widespread adoption of the CP classification will be practical.

In conclusion, Sano's CP classification has been shown to be useful and effective in the diagnosis of early colorectal lesions without the necessity of using any dye spraying or staining instruments or techniques. It is our understanding that NBI is now available worldwide for use in the diagnosis of colorectal neoplastic lesions. A large prospective trial involving multiple institutions therefore is needed for further validation.

REFERENCES

1. Sano Y, Kobayashi M, Hamamoto Y *et al.* New diagnostic method based on color imaging using narrow band imaging (NBI) system for gastrointestinal tract. *Gastrointest. Endosc.* 2001; **53**: AB125.
2. Gono K, Obi T, Yamaguchi M *et al.* Appearance of enhanced tissue features in narrow-band endoscopic imaging. *J. Biomed. Opt.* 2004; **9**: 568–77.
3. Sano Y, Muto M, Tajiri H *et al.* Optical/digital chromoendoscopy during colonoscopy using narrow-band image system. *Dig. Endosc.* 2005; **17**: S43–8.
4. Uraoka T, Sano Y, Saito Y, Saito H, Matsuda T, Yamamoto K. Narrow-band imaging for improving colorectal adenoma detection: Appropriate system function settings are required. *Gut* 2009; **58**: 604–5.
5. Sano Y, Horimatsu T, Fu KI, Katagiri A, Muto M, Ishikawa H. Magnifying observation of microvascular architecture of colorectal lesions using a narrow band imaging system. *Digest Endosc.* 2006; **18**: S44–51.
6. Machida H, Sano Y, Hamamoto Y *et al.* Narrow-band imaging for differential diagnosis of colorectal mucosal lesions: A pilot study. *Endoscopy* 2004; **36**: 1094–8.
7. Ikematsu H, Matsuda T, Emura F *et al.* Efficacy of capillary pattern type IIIA/IIIB by magnifying narrow band imaging for estimating depth of invasion of early colorectal neoplasms. *BMC Gastroenterol.* 2010; **10**: 33.
8. Sano Y, Maeda N, Kanzaki A *et al.* Angiogenesis in colon hyperplastic polyp. *Cancer Lett.* 2005; **218**: 223–8.
9. Sano Y, Ikematsu H, Fu KI *et al.* Meshed capillary vessels by use of narrow-band imaging for differential diagnosis of small colorectal polyps. *Gastrointest. Endosc.* 2009; **69**: 278–83.
10. Chiu HM, Chang CY, Chen CC *et al.* A prospective comparative study of narrow-band imaging, chromoendoscopy, and conventional colonoscopy in the diagnosis of colorectal neoplasia. *Gut* 2007; **56**: 373–9.
11. Tischendorf JJ, Wasmuth HE, Koch A *et al.* Value of magnifying chromoendoscopy and narrow band imaging (NBI) in classifying colorectal polyps: A prospective controlled study. *Endoscopy* 2007; **39**: 1092–6.
12. Horimatsu T, Sano Y, Kaneko K *et al.* Relationship between MVD and meshed-capillaries using magnifying NBI colonoscopy in colorectal precursor lesions. *Hepatogastroenterology* 2009; **56**: 372–7.
13. Katagiri A, Fu KI, Sano Y *et al.* Narrow band imaging with magnifying colonoscopy as diagnostic tool for predicting histology of early colorectal neoplasia. *Aliment. Pharmacol. Ther.* 2008; **27**: 1269–74.
14. Kudo S, Rubio CA, Teixeira CR *et al.* Pit pattern in colorectal neoplasia: Endoscopic magnifying view. *Endoscopy* 2001; **33**: 367–73.
15. Matsuda T, Fujii T, Saito Y *et al.* Efficacy of the invasive/non-invasive pattern by magnifying chromoendoscopy to estimate the depth of invasion of early colorectal neoplasms. *Am. J. Gastroenterol.* 2008; **103**: 2700–6.
16. Higashi R, Uraoka T, Kato J *et al.* Diagnostic accuracy of narrow-band imaging and pit pattern analysis significantly improved for less experienced endoscopists following expanded training program. *Gastrointest. Endosc.* 2010; **72**: 127–35.
17. Henry ZH, Yeaton P, Shami VM *et al.* Meshed capillary vessels found on narrow-band imaging without optical magnification effectively identifies colorectal neoplasia: A North American validation of the Japanese experience. *Gastrointest. Endosc.* 2010; **72**: 118–26.

CURRENT STATUS AND THE CHALLENGES OF THE NBI DIAGNOSIS FOR COLORECTAL TUMOR

COMPARATIVE EVALUATION OF ENDOSCOPIC FACTORS FROM CONVENTIONAL COLONOSCOPY AND NARROW-BAND IMAGING OF COLORECTAL LESIONS

HIROAKI IKEMATSU,¹ YUTAKA SAITO² AND HIROO YAMANO³

¹Department of Gastroenterology and Gastrointestinal Oncology, National Cancer Center Hospital East, Kashiwa, ²Gastrointestinal Endoscopy Division, National Cancer Center Hospital, Tokyo, and ³Division of Gastroenterology, Akita Red Cross Hospital, Akita, Japan

Background: Narrow-band imaging (NBI) diagnosis of colorectal lesions requires further consideration and standardized classification for attaining consensus among endoscopists.

Objective: Compare vascular findings and diagnosis of colorectal lesions using various endoscopic images to assess effectiveness of NBI with magnification.

Method: Three endoscopic factors (vascular findings; diagnosis from NBI with magnification images; and total diagnosis from all available colonoscopic images including white light endoscopy, chromoendoscopy, NBI with magnification and magnifying chromoendoscopy) for 15 colorectal lesions were evaluated by 12 expert colonoscopists (Group A), 36 endoscopists not expert in colonoscopy (Group B) and 55 individuals not medical doctors, but familiar with gastrointestinal endoscopy or other medical products (Group C). We calculated accuracy percentages for all three endoscopic factors based on responses from each group. Highest percentage for vascular finding, NBI with magnification diagnosis and total diagnosis for each lesion assumed to be opinion of each group. We compared incidence of agreement among three groups and calculated invasion depth diagnostic accuracy rate for each group.

Results: For vascular findings from NBI with magnification images, incidence of complete agreement among three groups was 46.7%, incidence of disagreement among three groups was 46.7% and incidence of complete disagreement among three groups was 6.7%. For diagnosis from NBI with magnification images and total diagnosis from all available endoscopic images, incidence of complete agreement, disagreement and complete disagreement were 40.0%, 60.0% and 0.0%, respectively, and 60.0%, 40.0% and 0.0%, respectively. Invasion depth diagnostic accuracy from NBI with magnification images and all available endoscopic images were 60.0% and 73.3%, respectively, in Group A; 46.7% and 66.7%, respectively, in Group B; and 46.6% and 60.0%, respectively, in Group C.

Conclusion: Results suggest some level of educational training is required for effective application of NBI with magnification for precise diagnosis of colorectal lesions.

Key words: colorectal lesion, endoscopic diagnosis, narrow-band imaging.

INTRODUCTION

Narrow-band imaging (NBI) is a recently developed method of endoscopic detection and diagnosis that has been under study for a relatively short period. There are currently several reported classifications for NBI diagnosis of colorectal lesions in Japan^{1–4} and additional time will be required for attaining a consensus among endoscopists. Consequently, NBI diagnosis requires further consideration and a standardized classification before achieving such a consensus. We conducted a comparative evaluation of vascular findings and diagnosis of colorectal lesions using conventional endoscopy

and NBI with magnification for the purpose of assessing the effectiveness of NBI with magnification.

METHODS

Endoscopic images of lesions

Fifteen colorectal lesions (three adenomas, six intramucosal cancers and six submucosal cancers including one superficial submucosal cancer (<1,000 μm) and five deep submucosal cancers ($\geq 1,000 \mu\text{m}$) that had been examined from October 2005 to May 2010 using NBI with magnification, conventional white light endoscopy, chromoendoscopy and magnifying chromoendoscopy were selected for this study. Surgical or endoscopic resections were carried out on all 15 lesions and histopathological diagnoses were made by a highly experienced pathologist. The best quality NBI with magnification, white light endoscopy, chromoendoscopy and magnifying chromoendoscopy images for each lesion were digitally stored in JPEG format. (Fig. 1)

Correspondence: Hiroaki Ikematsu, Department of Gastroenterology and Gastrointestinal Oncology, National Cancer Center Hospital East, 6-5-1 Kashiwanoha, Kashiwa, Chiba 277-8577, Japan. Email: hikemats@east.ncc.go.jp

Received 27 December 2010; accepted 4 February 2011.

© 2011 The Authors

Digestive Endoscopy © 2011 Japan Gastroenterological Endoscopy Society

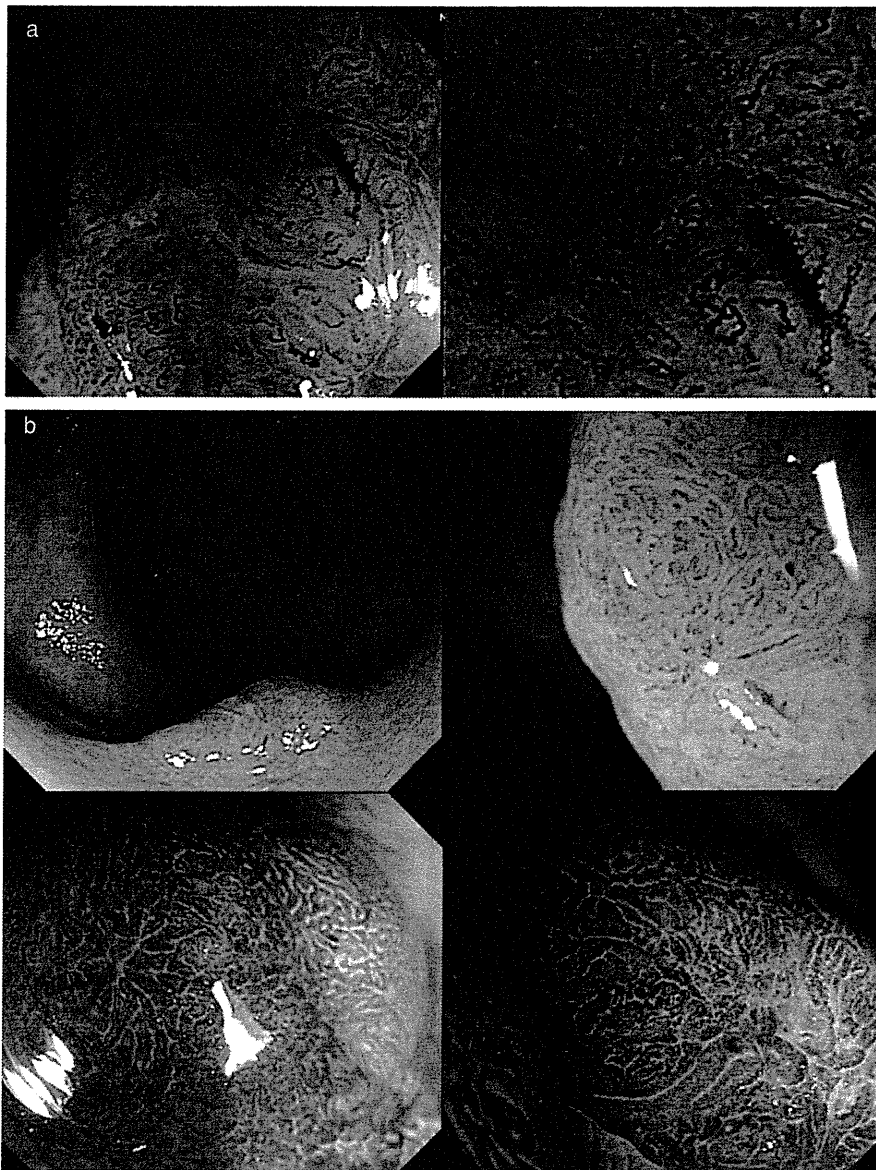


Fig. 1. Endoscopic images used in this study. (a) Narrow-band imaging with magnification images. (b) White light endoscopy, chromoendoscopy and magnifying chromoendoscopy images.

Image evaluators

A total of 103 individuals participated as image evaluators in this study including 12 expert colonoscopists (Group A), 36 endoscopists who were not experts in colonoscopy (Group B) and 55 individuals who were not medical doctors (Group C). None of the Group C evaluators had been educated or trained in endoscopic diagnosis before this study although all of them were engineers or sales agents for gastrointestinal endoscopy or other medical products. These individuals were included in the study to show whether it was possible to diagnose capillary pattern irregularities and malignancies based solely on their observational abilities without any previous endoscopic diagnosis education or training.

Evaluation factors

Three endoscopic factors (vascular findings based only on NBI with magnification images; diagnosis based only on NBI

with magnification images; and total diagnosis based on all available endoscopic images (white light endoscopy, chromoendoscopy, NBI with magnification and magnifying chromoendoscopy)) were evaluated in this study. Vascular findings from only NBI with magnification images were separated into four categories (regular network, irregular network, coarse vessels and fragmentation, and avascular area). Diagnoses from only NBI with magnification images as well as total diagnoses from all available endoscopic images were divided into three types (adenomas, intramucosal and superficial submucosal cancers [$<1,000 \mu\text{m}$], and deep submucosal cancers [$\geq 1,000 \mu\text{m}$]). (Table 1)

Assessment of endoscopic images

First, the evaluators examined NBI with magnification images of the 15 colorectal lesions and then selected the best description for each lesion from the four possible vascular

Table 1. Image evaluation questionnaire/answer sheet

Q1: What vascular findings did you choose in this NBI magnifying image?
1. Regular network
2. Irregular network
3. Coarse vessels & fragmentation
4. Avascular area
Q2: How do you diagnosis from this NBI image?
1. Adenoma
2. M-SM slight invasion
3. SM massive invasion
Q3: How do you diagnosis from total image?
1. Adenoma
2. M-SM slight invasion
3. SM massive invasion

NBI, narrow-band imaging, M-SM, mucosal-submucosal; SM, submucosal.

finding categories (regular network, irregular network, coarse vessels and fragmentation, and avascular area). Next, the evaluators diagnosed each lesion from the three possible types (adenomas, intramucosal and superficial submucosal cancers [$<1,000 \mu\text{m}$], and deep submucosal cancers [$\geq 1,000 \mu\text{m}$]) based only on the NBI with magnification images. Finally, the evaluators examined white light endoscopy, chromoendoscopy and magnifying chromoendoscopy images of the 15 colorectal lesions and then made a total diagnosis from the three possible types for each lesion taking into account all endoscopic images. Evaluators made diagnostic decisions in real time using response cards so as to answer immediately and were subsequently prohibited from changing an initial NBI diagnosis after making a total diagnosis for a particular lesion. Patient information such as age, sex and clinical diagnosis was not disclosed to any of the evaluators and discussions were not permitted among the 48 endoscopists either individually or in groups.

Statistical analysis

We calculated the percentages for all three endoscopic factors based on the responses from each group. The highest percentage for the vascular finding, NBI with magnification diagnosis and total diagnosis for each lesion was assumed to be the opinion of each group. We then compared the percentages for the three groups for each of the three endoscopic factors. 'Complete agreement' meant all three groups made the same choice. 'Disagreement' meant one of the groups made a choice that was different from the other two groups whereas 'complete disagreement' meant there were three completely different choices made by the three groups. We also calculated the invasion depth diagnostic accuracy rate for each group. All statistical analyses were carried out using a Microsoft Excel 2007 spreadsheet (Microsoft, Renton, WA, USA).

RESULTS

Comparative agreement on vascular findings and diagnoses

For vascular findings of the 15 colorectal lesions using only NBI with magnification images, the incidence of complete

Table 2. Comparison of assessment agreement rates for three endoscopic factors

	Vascular findings – only narrow-band imaging (%)	Diagnosis – only narrow-band imaging (%)	Total diagnosis – all endoscopy images (%)
Complete agreement	46.7	40.0	60.0
Disagreement	46.7	60.0	40.0
Complete disagreement	6.7	0.0	0.0

agreement among the three groups was 46.7%, the incidence of disagreement among the three groups was 46.7% and the incidence of complete disagreement among the three groups was 6.7%. For diagnosis using only NBI with magnification images and total diagnosis using all available endoscopic images, the incidence of complete agreement, disagreement and complete disagreement among the three groups were 40.0%, 60.0%, 0.0%, respectively, and 60.0%, 40.0%, 0.0%, respectively. (Table 2)

The incidence of agreement between Group A/Group B, Group B/Group C and Group A/Group C on vascular findings using only NBI with magnification images was 66.7%, 60.0% and 60.0%, respectively. For diagnosis using only NBI with magnification images, the incidence of agreement between Group A/Group B, Group B/Group C and Group A/Group C was 73.3%, 60.0% and 53.3%, respectively, whereas the incidence of agreement between Group A/Group B, Group B/Group C and Group A/Group C on total diagnosis using all available endoscopic images was 80.0%, 80.0% and 73.3%, respectively. (Table 3) One case of complete agreement and another case of complete disagreement between the three groups are shown in Figs 2 and 3, respectively.

For diagnosis from NBI with magnification images and total diagnosis from all available endoscopic images, incidence of complete agreement, disagreement and complete disagreement were 40.0%, 60.0% and 0.0%, respectively, and 60.0%, 40.0% and 0.0%, respectively. Invasion depth diagnostic accuracy from NBI with magnification images and all available endoscopic images were 60.0% and 73.3%, respectively, in Group A; 46.7% and 66.7%, respectively, in Group B; and 46.6% and 60.0%, respectively, in Group C.

Invasion depth diagnostic accuracy

Invasion depth diagnostic accuracy using only NBI with magnification images and using all available endoscopic images was 60.0% and 73.3%, respectively, in Group A; 46.7% and 66.7%, respectively, in Group B; and 46.6% and 60.0%, respectively, in Group C (Table 4) although there were no significant differences among the three groups in invasion depth diagnostic accuracy using only NBI with magnification images or using all available endoscopic images.

Table 3. Comparison of assessment agreement rates between image evaluator groups

	Vascular findings – only narrow-band imaging (%)			Diagnosis – only narrow-band imaging (%)			Total diagnosis – all endoscopy images (%)		
	Group A vs. Group B	Group B vs. Group C	Group A vs. Group C	Group A vs. Group B	Group B vs. Group C	Group A vs. Group C	Group A vs. Group B	Group B vs. Group C	Group A vs. Group C
	Agreement	66.7	60.0	60.0	73.3	60.0	53.3	80.0	80.0
Disagreement	33.3	40.0	40.0	26.7	40.0	46.7	20.0	20.0	26.7

Group A: 12 expert colonoscopists.
 Group B: 36 endoscopists non-expert in colonoscopy.
 Group C: 55 individuals who were not medical doctors.

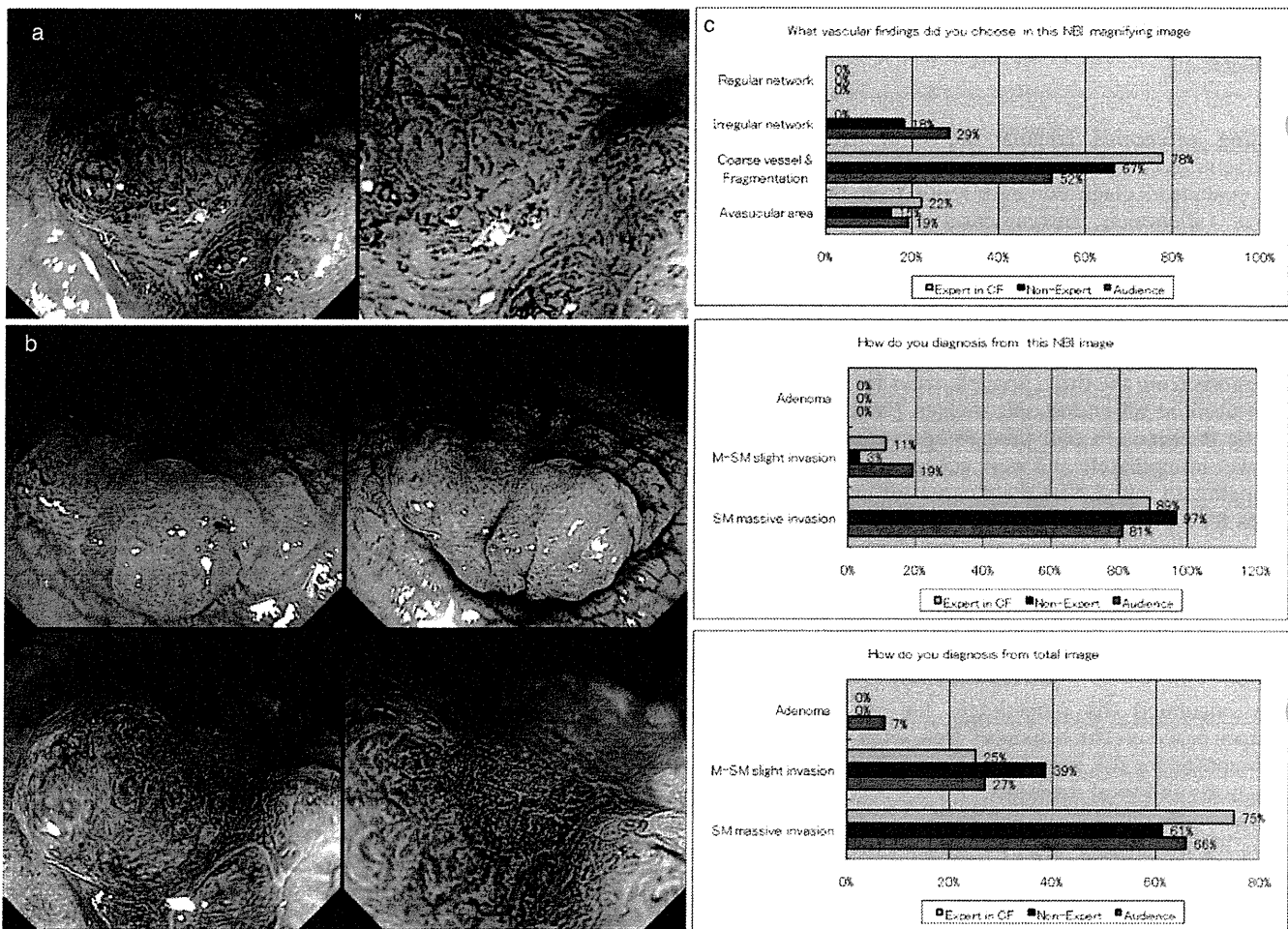


Fig. 2. Complete agreement among three image evaluator groups on 25 mm polypoid is lesion located in rectum. Histopathological analysis of endoscopically resected specimen showed intramucosal cancer. (a) Narrow-band imaging (NBI) with magnification images. (b) White light endoscopy, chromoendoscopy and magnifying chromoendoscopy images. (c) Detailed questionnaire results for three endoscopic factors. (□) Expert in CF; (■) non-expert; (■) audience. M-SM, mucosal-submucosal; SM, submucosal.

DISCUSSION

Total diagnosis in Group A had the highest diagnostic accuracy followed by total diagnosis in Group B. NBI with magnification diagnostic accuracy in Group A was lower than total diagnosis in Group B and the same as total diagnosis in

Group C. NBI with magnification diagnosis in Group B and Group C produced the lowest diagnostic accuracy rates recorded in this study. These results suggest that some level of educational training is required for the effective application of NBI with magnification for precise diagnosis of colorectal lesions.

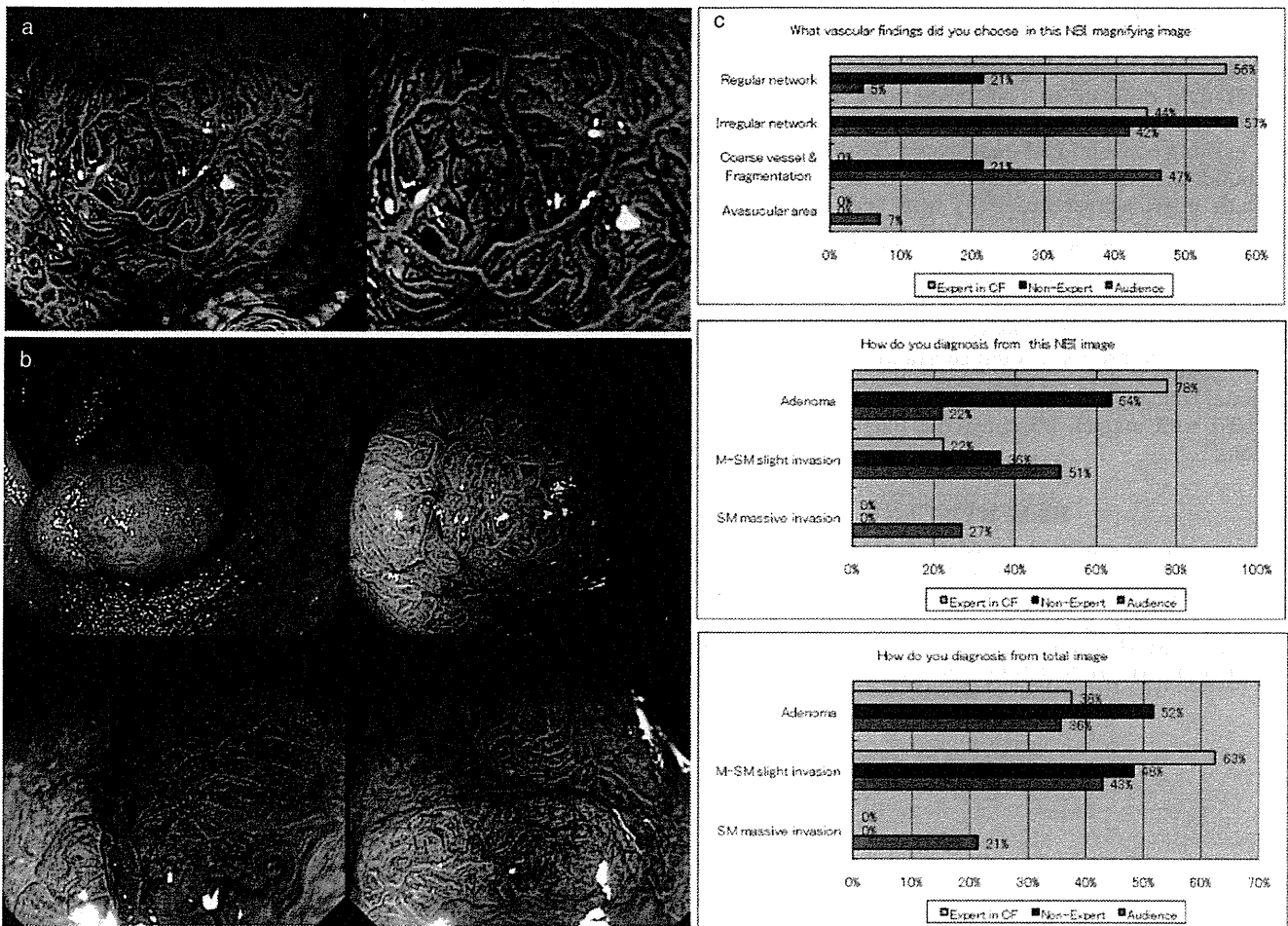


Fig. 3. Complete disagreement among three image evaluator groups on 15 mm flat IIA+IIC lesion located in rectum. Histopathological analysis of surgically resected specimen showed deep submucosal cancer ($\geq 1,000 \mu\text{m}$). (a) Narrow-band imaging (NBI) with magnification images. (b) White light endoscopy, chromoendoscopy and magnifying chromoendoscopy images. (c) Detailed questionnaire results for three endoscopic factors. (■) Expert in CF; (■) non-expert; (■) audience. M-SM, mucosal-submucosal; SM, submucosal.

Table 4. Comparison of invasion depth diagnostic accuracy rates

	Diagnosis – only narrow-band imaging (%)	Total diagnosis – all endoscopy images (%)
Group A	60.0	73.3
Group B	46.7	66.7
Group C	46.6	60.0

There are currently several reported classifications for NBI diagnosis of colorectal lesions¹⁻⁴ so it might be some time before a consensus is reached among endoscopists on NBI with magnification diagnosis in comparison to pit pattern diagnosis and conventional endoscopic diagnosis. Throughout the floor discussion, it was evident that agreement on determining regular from irregular capillary patterns was an unresolved issue even among expert colonoscopists thereby indicating that NBI diagnosis will require further consider-

ation and a standardized classification must be established before a consensus is possible.

Over the last 20 years, pit pattern analysis has resulted in precise endoscopic diagnosis including differential diagnosis among hyperplastic polyps, adenomas and cancers in addition to accurate depth of invasion diagnosis for early colorectal cancers.⁵⁻⁷ Pit pattern diagnosis is now considered more objective than conventional endoscopic diagnosis although it still remains subjective in diagnosing pit pattern irregularities.

In contrast, NBI is a recently developed method of endoscopic detection and diagnosis that has been under study for a relatively short period. NBI with magnification facilitates detailed observation of a lesion's microvascular architecture and is widely used for the endoscopic diagnosis of colorectal tumors. Although NBI with magnification has proven very useful for differential diagnosis between non-neoplastic and neoplastic lesions using capillary pattern classification,⁸⁻¹⁰ there is no consensus as yet on depth of invasion diagnosis or determining the borderline between regular and irregular networks despite some agreement on the definition of capillary irregularity.

Based on the floor discussion, we realize that our most urgent task now is to standardize a classification for diagnosis using NBI colonoscopy. A multicenter study will then be required to evaluate the diagnostic accuracy of NBI with magnification in determining invasion depth compared with the existing conventional endoscopic classification in order to build a consensus. Undoubtedly, it will be difficult to exclude interobserver variability from such an NBI classification for colorectal lesions so interpretation of NBI with magnification findings based on an objective set of standards will also be necessary. Computer-assisted analysis might be one means of reducing the subjective nature of endoscopic diagnosis. Once achieved, a highly accurate automatic identification process should substantially enhance the educational training of less-experienced endoscopists in the use of NBI with magnification for the diagnosis of colorectal lesions.

REFERENCES

1. Sano Y, Horimatsu T, Fu KI, Katagiri A, Muto M, Ishikawa H. Magnifying observation of microvascular architecture of colorectal lesions using a narrow band imaging system. *Dig. Endosc.* 2006; **18**: S44–51.
2. Ikematsu H, Matsuda T, Emura F *et al.* Efficacy of capillary pattern type IIIA/IIIB by magnifying narrow band imaging for estimating depth of invasion of early colorectal neoplasms. *BMC Gastroenterol.* 2010; **10**: 33.
3. Hirata M, Tanaka S, Oka S *et al.* Magnifying endoscopy with narrow band imaging for diagnosis of colorectal tumors. *Gastrointest. Endosc.* 2007; **65**: 988–95.
4. Wada Y, Kudo S, Kashida H *et al.* Diagnosis of colorectal lesions with the magnifying narrow-band imaging system. *Gastrointest. Endosc.* 2009; **70**: 522–31.
5. Kudo S, Hirota S, Nakajima T *et al.* Colorectal tumours and pit pattern. *J. Clin. Pathol.* 1994; **47**: 880–5.
6. Konishi K, Kaneko K, Kurahashi T *et al.* A comparison of magnifying and nonmagnifying colonoscopy for diagnosis of colorectal polyps: A prospective study. *Gastrointest. Endosc.* 2003; **57**: 48–53.
7. Matsuda T, Fujii T, Saito Y *et al.* Efficacy of the invasive/non-invasive pattern by magnifying chromoendoscopy to estimate the depth of invasion of early colorectal neoplasms. *Am. J. Gastroenterol.* 2008; **103**: 2700–6.
8. Chiu HM, Chang CY, Chen CC *et al.* A prospective comparative study of narrow-band imaging, chromoendoscopy, and conventional colonoscopy in the diagnosis of colorectal neoplasia. *Gut* 2007; **56**: 373–9.
9. Sano Y, Ikematsu H, Fu KI *et al.* Meshed capillary vessels by use of narrow-band imaging for differential diagnosis of small colorectal polyps. *Gastrointest. Endosc.* 2009; **69**: 278–83.
10. Emura F, Saito Y, Ikematsu H. Narrow-band imaging optical chromocolonoscopy: Advantages and limitations. *World J. Gastroenterol.* 2008; **14** (31): 4867–72.