

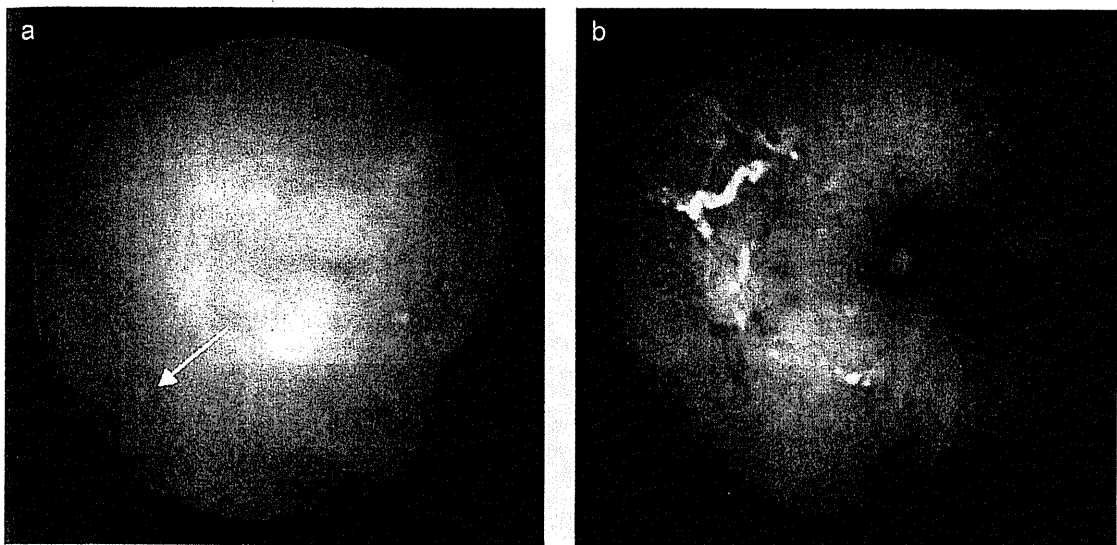図7 小腸 CMV 感染症でみられるカプセル内視鏡所見  
びらん (a), 潰瘍 (b)。潰瘍 (b) があれば消化管 CMV 感染症の診断は容易であるが、多くはびらん (a) に留まっている。分布は散在性である。

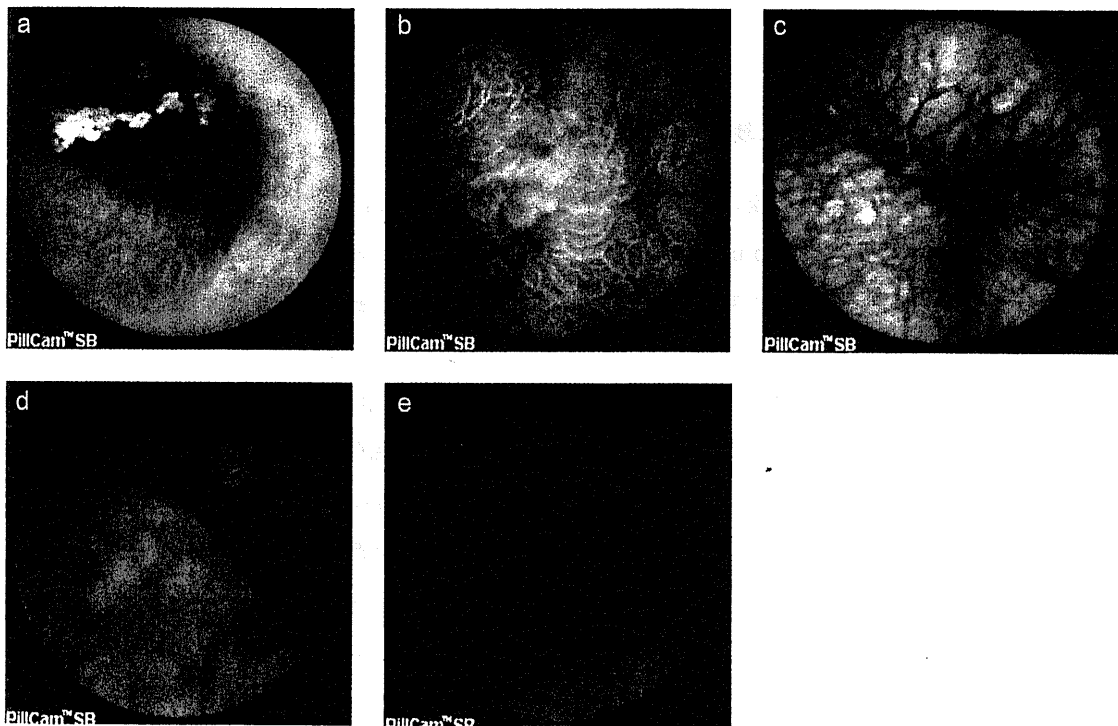


図8 小腸 GVHD でみられるカプセル内視鏡所見  
発赤 (a), 浮腫 (b), 粗造粘膜 (c), 絨毛萎縮 (一部絨毛脱落) (d), 絨毛脱落 (e)。炎症は腸管内腔にわたってびまん性にみられる。これらの所見の中でも、絨毛萎縮や絨毛脱落は GVHD に特異的である。

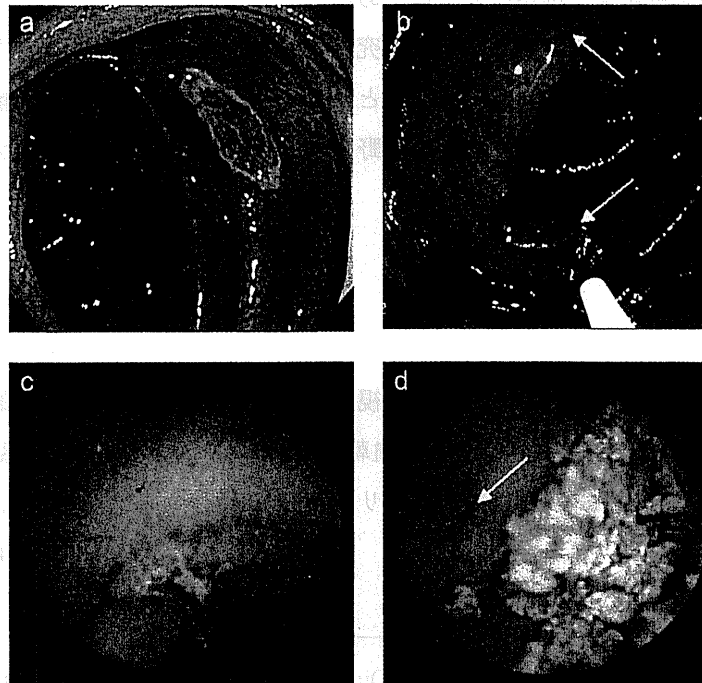


図9 小腸 CMV 感染症

a, b : 大腸 CMV 感染症, c, d : 小腸 CMV 感染症。

49 歳男性, MDS (myelodysplastic syndromes : 骨髄異形成症候群)。Day 213。

腹痛および水溶性下痢の精査目的にて大腸内視鏡検査が施行された。上行結腸に潰瘍 (a) とその周辺にびらんが散見された (b) (矢印)。潰瘍とびらんのいずれからも CMV 封入体が証明された。

同時期に施行した小腸カプセル内視鏡でも空腸に潰瘍 (c) およびびらん (d) (矢印) を認めた。同部位からの生検は行っていないが、大腸内視鏡検査でみられた肉眼像 (a, b) とほぼ同様の所見であることから、併発する小腸 CMV 感染症と考えられた。ガンシクロビル投与により、症状の改善とともに上行結腸および空腸のいずれの所見も改善、消失した。

## 2) 小腸カプセル内視鏡における小腸 CMV 感染症の肉眼像

小腸 CMV 感染症の肉眼所見もびらん、潰瘍が挙げられる (図 7)<sup>13)</sup>。一方、鑑別疾患である GVHD は図 8 のような所見がみられる。しかし、これらの肉眼像は未だ十分な検討とはいえず、今後の検討課題である。

図 9 はカプセル内視鏡で観察された小腸 CMV 感染症の一例である<sup>13)</sup>。ガンシクロビル投与後の検査では改善していた。

## 3) 小腸カプセル内視鏡の適応

小腸カプセル内視鏡は患者の受容性が高く、診断能も優れている。大腸内視鏡検査で全大腸の観察が困難な場合、特に回腸末端の観察が困難な場合には、このカプセル内視鏡は良好な適応となると考えられる。少量の下剤を併用すれば、バッテリーの時間が延びてきているだけに、

行半結腸の観察が可能な症例が出てくるであろう。

また、海外では大腸カプセル内視鏡の研究、開発も盛んに行われている<sup>15, 16)</sup>。この大腸カプセル内視鏡がわが国に導入されれば、小腸と大腸の観察が一度の検査で可能となる。侵襲の少ないカプセル内視鏡が造血幹細胞移植の分野で果たす役割は、今後さらに大きくなっていくであろう。

## おわりに

造血幹細胞移植後に施行される消化管内視鏡検査に当たっては、病理学的診断のみならず、肉眼的診断も非常に重要である。今回、造血幹細胞移植後の消化管 CMV 感染症の内視鏡診断、踏まえておきたい注意点および最新のモダリティの有用性につき概説した。

(角川 康夫, 福田 隆浩)

## 文 献

- 1) Iqbal N, Salzman D, Lazenby AJ, et al : Diagnosis of gastrointestinal graft-versus-host disease. *Am J Gastroenterol* 95 (11) : 3034-3038, 2000.
- 2) Iwasaki T : Alimentary tract lesions in cytomegalovirus infection. *Acta Pathol Jpn* 37 (4) : 549-565, 1987.
- 3) Kakugawa Y, Kami M, Kozu T, et al : Endoscopic evaluation for cytomegalovirus enterocolitis after allogeneic haematopoietic stem cell transplantation. *Gut* 55 (6) : 895-896, 2006.
- 4) Kakugawa Y, Kami M, Matsuda T, et al : Endoscopic diagnosis of cytomegalovirus gastritis after allogeneic hematopoietic stem cell transplantation. *World J Gastroenterol* 16 (23) : 2907-2912, 2010.
- 5) 角川康夫, 福田隆浩 : 造血幹細胞移植における消化管合併症 - 内視鏡診断を中心に -. *内科* 104 (2) : 278-285, 2009.
- 6) 角川康夫, 福田隆浩 : 免疫不全 - 移植片対宿主病 (GVHD). どう診る? 小腸疾患 - 診断から治療まで (上西紀夫 監修). 診断と治療社, 東京, 2010, p120-124.
- 7) Einsele H, Ehninger G, Hebart H, et al : Incidence of local CMV infection and acute intestinal GVHD in marrow transplant recipients with severe diarrhoea. *Bone Marrow Transplant* 14 (6) : 955-963, 1994.
- 8) Kakugawa Y, Fukuda T, Saito Y : Cautionary note on using rectosigmoid biopsies to diagnose graft-versus-host disease: necessity of ruling out cytomegalovirus colitis. *Am J Gastroenterol* 103 (11) : 2959-2960, 2008.
- 9) Yakoub-Agha I, Maunoury V, Wacrenier A, et al : Impact of Small Bowel Exploration Using Video-Capsule Endoscopy in the Management of Acute Gastrointestinal Graft-versus-Host Disease. *Transplantation* 78 (11) : 1697-1701, 2004.
- 10) Shapira M, Adler SN, Jacob H, et al : New insights into the pathophysiology of gastrointestinal graft-versus-host disease using capsule endoscopy. *Haematologica* 90 (7) : 1003-1004, 2005.
- 11) Silbermintz A, Sahdev I, Moy L, et al : Capsule endoscopy as a diagnostic tool in the evaluation

## II. ウイルス感染症

- of graft-vs.-host disease. *Pediatr Transplant* 10 (2) : 252-254, 2006.
- 12) Eisen GM : Using capsule endoscopy to diagnose graft-versus-host disease : seeing is believing ? *Gastrointest Endosc* 65 (3) : 410-411, 2007.
  - 13) Kakugawa Y, Kim SW, Takizawa K, et al : Small intestinal CMV disease detected by capsule endoscopy after allogeneic hematopoietic SCT. *Bone Marrow Transplant* 42 (4) : 283-284, 2008.
  - 14) Varadarajan P, Dunford LM, Thomas JA, et al : Seeing what's out of sight : wireless capsule endoscopy's unique ability to visualize and accurately assess the severity of gastrointestinal graft-versus-host-disease. *Biol Blood Marrow Transplant* 15 (5) : 643-648, 2009.
  - 15) 角川康夫, 斎藤 豊 : 大腸カプセル内視鏡. *消化器内視鏡* 22 (3) : 364-368, 2010.
  - 16) Spada C, Hassan C, Sturniolo GC, et al : Literature review and recommendations for clinical application of Colon Capsule Endoscopy. *Dig Liver Dis* 43 (4) : 251-258, 2011.

## 大腸カプセル内視鏡における新しい腸管前処置方法

### —本邦におけるパイロット試験の報告—

角川康夫<sup>\*1,\*2</sup>・斎藤 豊<sup>\*2</sup>・斎藤彰一<sup>\*3</sup>・渡辺憲治<sup>\*4</sup>・大宮直木<sup>\*5</sup>  
村野実之<sup>\*6</sup>・岡 志郎<sup>\*7</sup>・相原弘之<sup>\*3</sup>・倉本貴典<sup>\*6</sup>・荒川哲男<sup>\*4</sup>  
後藤秀実<sup>\*5</sup>・樋口和秀<sup>\*6</sup>・田中信治<sup>\*7</sup>・石川秀樹<sup>\*8</sup>・田尻久雄<sup>\*3</sup>

#### KEY WORDS

大腸カプセル内視鏡, 腸管前処置, 腸管洗浄度, クエン酸マグネシウム

#### はじめに

欧州では2006年に大腸カプセル内視鏡(PillCam® COLON, Given Imaging社)が臨床現場に登場し, さらに2009年には第2世代の大腸カプセル内視鏡(PillCam® COLON 2, Given Imaging社)が登場した。

この第2世代のPillCam® COLON 2は, 視野角が第1世代大腸カプセルの156度から172度に広がり, 電池寿命も大幅に延長された。サイズは長さ31 mm, 幅11 mmで, 小腸カプセル内視鏡よりも5 mmほど長い(1)。この大腸カプセル内視鏡には前後にビデオカメラを有している。このPillCam® COLON 2の大きな特徴にデータのやりとりが大腸カプセル内視鏡とデータレコーダーの双方向性になった点がある。これは, 大腸カプセル内視鏡がほと

<sup>\*1</sup>国立がん研究センターがん予防・検診研究センター検診開発研究部, <sup>\*2</sup>同中央病院消化管内視鏡科, <sup>\*3</sup>東京慈恵会医科大学消化器・肝臓内科, <sup>\*4</sup>大阪市立大学医学研究科消化器内科学, <sup>\*5</sup>名古屋大学消化器内科, <sup>\*6</sup>大阪医科大学第2内科, <sup>\*7</sup>広島大学内視鏡診療科, <sup>\*8</sup>京都府立医科大学分子標的癌予防医学

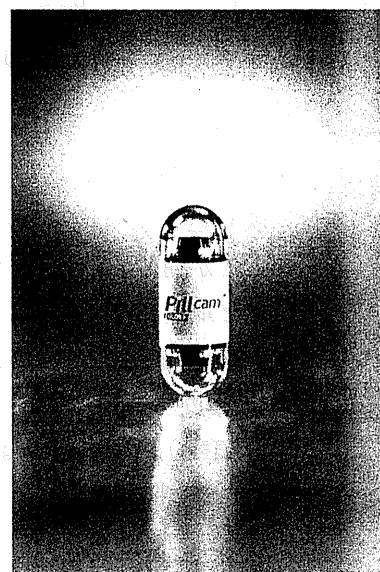

図1 第2世代の大腸カプセル内視鏡 PillCam® COLON 2は撮影頻度が4枚/秒と35枚/秒の2パターンあり, カプセルが早く進むときは35枚/秒で撮影される。そのため, 従来の第1世代カプセルで危惧された見落とし(病変は存在するが画面に映りこまない状態)が大幅に減少することが期待される。撮影時間も大幅に延長した。

んど動いていない状態では従来通り4枚/秒の頻度で, 大腸カプセル内視鏡が早く進んでいる時は35枚/秒の頻度で撮影される機能(Adaptive Frame Rate; AFR)を可能にした。これに

表1 大腸カプセル内視鏡の大腸ポリープに対する感度、特異度

	Eliakim	Schoofs	Sieg	Van Gossum	Gay	Sacher-Huvelin	Pilz	Eliakim	Spada
発表年	2006	2006	2009	2009	2010	2010	2010	2009	2011
ジャーナル	Endoscopy	Endoscopy	Am J Gastroenterol	NEJM	Am J Gastroenterol	Aliment Pharmacol Ther	BMC Gastroenterology	Endoscopy	Gastrointest Endosc
参加国	Israel	Belgian	German	European Union	France	France	Switzerland	Israel	European Union
施設数	3施設	1施設	1施設	8施設	1施設	16施設	1施設	5施設	8施設
使用カプセル	第1世代大腸カプセル	第1世代大腸カプセル	第1世代大腸カプセル	第1世代大腸カプセル	第1世代大腸カプセル	第1世代大腸カプセル	第1世代大腸カプセル	第2世代大腸カプセル	第2世代大腸カプセル
症例数	n=91	n=41	n=38	n=332	n=128	n=545	n=59	n=104	n=117
平均年齢	57歳	56歳	56歳	58.5歳	55歳	59歳	60歳	49.8歳	60歳
Polyp ≥ 6mm 感度 特異度	58% 83%	60% 73%	63% Not Reported	64% 84%	77% Not Reported	39% 88%	79% 54%	89% 76%	84% 65%

NEJM : New England Journal of Medicine, BMC : BioMed Central

より撮影頻度が4枚/秒に固定されていた第1世代の時代に危惧されていた見落とし(病変は存在するが画像に映り込まない状態)のリスクを大幅に抑え込むことが期待される<sup>1)</sup>。実際に第1世代の大腸カプセル内視鏡では、6 mm以上の大腸ポリープの感度は39~79%であったが<sup>2~8)</sup>、第2世代の大腸カプセルでは84~89%にまで向上している(表1)<sup>1,9)</sup>。特異度は6 mm以上の大腸ポリープの第1世代の大腸カプセル内視鏡で54~88%<sup>2,3,5,7,8)</sup>であるのに対し、第2世代の大腸カプセルでは65~76%であった<sup>1,9)</sup>。

2009年にThe New England Journal of Medicine誌に掲載されたVan Gossumらの検討では、第1世代の大腸カプセル内視鏡PillCam COLONを用いた328例の検討で、6 mm以上のポリープの感度は64%であると報告しており、advanced adenomaに限定すると、その感度は73%になると述べている<sup>5)</sup>。彼らは大腸ポリープの発見率に最も寄与する因子は腸管洗浄度と述べており、腸管洗浄度が良好(adequate)な場合はadvanced adenomaの感度は88%まで上昇することを報告している。逆に洗浄度が不

良(inadequate)の場合には、その感度は44%に留まる。そのため、海外では、intensiveな腸管前処置にすべし、といった論調が少なくない。

しかし、これまでに報告された大腸カプセル内視鏡の腸管前処置は<sup>2~8)</sup>、いずれも被験者にかかる負担が少なくない。例えばVan Gossumらの方法<sup>5)</sup>では、検査前日から禁食となり、夕方にはポリエチレングリコール含有電解質溶液(polyethylene glycol electrolyte lavage solution; PEG-ELS)3Lの服用が要求される。さらに検査当日にもPEG-ELS 1Lの服用が必要とされ、その後にと大腸カプセル内視鏡検査を開始することができる。しかし、このままでは小腸通過に何時間も要するため、カプセルを大腸まで押し流す目的でリン酸ナトリウムが用いられる。これをBoosterと呼び、現在はBooster IとBooster IIの2回に分けて行うことが一般的で、このときに水も同時に飲むため、結果的に2L程度の水分がさらに負荷されることとなる。最後に座薬(Bisacodyl)を用いて最終排便を行い、カプセル内視鏡検査は完了する。

2日間で負荷される水分は6Lに及ぶ。禁食も

2日間に及ぶ。これでは、本来侵襲の少ないことが最大の売りであるはずのカプセル内視鏡のメリットは大きく損なわれてしまう。このような腸管前処置方法により洗浄度がAdequateになった割合は52~88%, またカプセル内視鏡の検査時間内の体外排出率は64~94%であった<sup>2~8)</sup>。

良好な洗浄度および高い体外排出率を維持しつつ、かつ被験者の負担をいかに軽減させていくかが課題である。そこで、被験者の侵襲をできるだけ減らし、かつこれまでと同等の洗浄度を確保した腸管前処置方法を探究する。

## 対象, 方法

本研究は多施設共同研究(6施設: 東京慈恵会医科大学, 名古屋大学, 大阪市立大学, 大阪医科大学, 広島大学, 国立がん研究センター)である<sup>10)</sup>。研究対象者は18~65歳までで大腸内視鏡検査予定患者, あるいは無症状健常ボランティアである。研究期間は2009年10月~2010年3月までとした。本研究は第3次対がん10か年総合戦略研究事業の斎藤豊班「新しい内視鏡診断機器の臨床への応用とこれらを用いた診断精度の向上に関する調査研究」の一環として行った。

われわれは被験者にかかる負担を少なくした腸管前処置方法(1日法)を提唱し、従来から海外で用いられている方法(2日法)と比較検討した。本研究は無作為割付比較試験とした。層別化因子は以下のとおり: (i)年齢(40歳未満あるいは40歳以上), (ii)性別, (iii)検査理由(大腸内視鏡検査予定患者あるいは無症状健常ボランティア), (iv)各施設。

1日法および2日法の下剤服用スケジュールは以下のとおりである。

1日法:

検査前日: 下剤服用せず。就寝時センノシド(プルセニド<sup>®</sup>) 2錠服用。

検査当日: ①プロナーゼ水100 ml, ②モサ

プリド(ガスモチン<sup>®</sup>) 15 mg服用, ③PEG-ELS (ムーベン<sup>®</sup>) 2L (ガスコン溶液400mg含)服用, ④カプセル内視鏡(PillCam<sup>®</sup> COLON, GivenImaging Inc., Israel)服用, ⑤Booster I & II: クエン酸マグネシウム(マグコロール<sup>®</sup> P) 100 g/1,800 mlを分割しそれぞれ900 mlずつ服用, ⑥モサプリド(ガスモチン<sup>®</sup>) 5 mg服用, ⑦ピサコジル(テレミンソフト<sup>®</sup>)坐薬1個(頓用)挿肛する。

2日法:

検査前日: PEG-ELS (ムーベン<sup>®</sup>) 2Lを服用する。就寝時センノシド(プルセニド<sup>®</sup>) 2錠服用。

検査当日: ①プロナーゼ水100 ml, ②モサプリド(ガスモチン<sup>®</sup>) 15 mg服用, ③PEG-ELS (ムーベン<sup>®</sup>) 1L (ガスコン溶液400mg含)服用, ④カプセル内視鏡(PillCam<sup>®</sup> COLON, GivenImaging Inc., Israel)服用, ⑤Booster I & II: クエン酸マグネシウム(マグコロール<sup>®</sup> P) 100 g/1,800 mlを分割しそれぞれ900 mlずつ服用, ⑥モサプリド(ガスモチン<sup>®</sup>) 5mg服用, ⑦ピサコジル(テレミンソフト<sup>®</sup>)坐薬1個(頓用)挿肛する。

本研究に参加された全症例の検査が終了後に、中央判定として大腸カプセル内視鏡画像による大腸腸管洗浄度の評価がなされた。選定された3名の熟練医(YK, SS, KW)は、あらかじめ匿名化された全症例の全大腸データ画像をそれぞれ80 fps (frame per second)のスピードで見返すことで腸管洗浄度の評価を行った。評価基準は従来<sup>2)</sup>の方法に準じ、excellentあるいはgoodをadequate, fairあるいはpoorをinadequateとした。3人の判定に差が生じた場合で2人の判定が一致した場合はその判定を採用した。3人全員の判定が異なった場合は中央の判定を採用した。中央判定は常にスーパーバイザー(YS)が監修する状態で行われた。

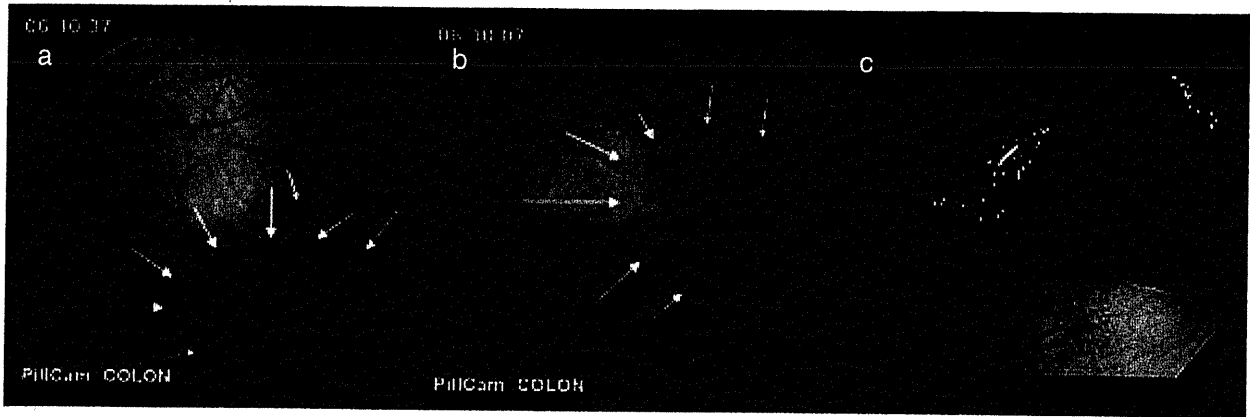


図2 大腸LST-NG病変の1例

(a) (b)大腸カプセル内視鏡画像：横行結腸に血管透見が低下した淡い発赤調の扁平隆起を認める(矢印)。このような表面型腫瘍の発見は腸管洗浄度が良好であることが決め手になると思われる。  
 (c)大腸内視鏡画像：横行結腸に30mm大のLST-NGを認めた。ESDにより根治的切除がなされた。Well differentiated adenocarcinoma, 深達度：Mの大腸がんであった。

## 結果

エントリーされた65名のうち、1名が同意撤回、4名がカプセル内視鏡の電源障害で撮影できなかったため、本検討からは除外した。60名のうち、1日法に31名、2日法に29名が無作為に割りつけられた。1日法31名の患者背景は、年齢中央値39歳、男性：女性＝19例：12例、無症状健常ボランティア27例、大腸内視鏡検査予定患者4例、2日法29名の患者背景は、年齢中央値39歳、男性：女性＝20例：9例、無症状健常ボランティア25例、大腸内視鏡検査予定患者4例であった。

全症例とも規定の下剤を服用できた。なお、1日法の1名、2日法の3名は、カプセル服用前の腸管洗浄度が十分に良好とはいえない状態であったため、PEG-ELS 300 mlが追加服用された。その結果、2日間における総水分摂取量は中央値で1日法3.8L (range, 3.8～4.1L)、2日法4.8L (range, 4.8～5.1L)となった。

中央判定の結果、腸管洗浄度の評価は次のようになった。adequate (excellentあるいはgood)の割合は1日法で94% (29/31)、2日法で86% (25/29)であった(ns)。カプセル服用前にPEG-ELS 300 mlが追加服用された4例(1日法

1例、2日法3例)はいずれも excellent(adequate)であった。図2は腸管洗浄度が excellent (adequate)な状態で観察されたLST-NGの1例である。

また、バッテリー時間内にカプセルが体外に排出された割合は1日法で71% (22/31)、2日法で55% (16/29)であった(ns)。

1日法のうち、大腸内視鏡検査予定患者は4例で、全例(100%)がバッテリー時間内にカプセルは体外に排出された。一方、1日法のうち、無症状健常ボランティアは27例で、そのうちバッテリー時間内にカプセルが体外に排出したのは18例(67%)であった。

2日法のうち、大腸内視鏡検査予定患者は4例で、バッテリー時間内にカプセルが体外に排出したのは3例(75%)であった。一方、2日法のうち、無症状健常ボランティアは25例で、そのうちバッテリー時間内にカプセルが体外に排出したのは13例(52%)であった。

## 考察

本検討は大腸カプセル内視鏡検査の際に服用する下剤を主に当日だけに限定した初めての研究である<sup>10)</sup>。従来からある大腸内視鏡検査につ



いては、欧米では前日の腸管前処置に重点が置かれてきた。本邦の大腸内視鏡検査では、検査当日の1日だけで腸管前処置を行う方法が主流であり、当院で内視鏡診断学を学び1日法の有用性を理解した海外からの研修内視鏡医らが、母国に戻り無作為化比較試験を行い1日法の有用性を証明したことで<sup>11,12)</sup>、ようやく欧米においても当日に限局した腸管前処置の重要性が認識されてきた。これを踏まえ、われわれは大腸カプセル内視鏡検査でもPEG-ELSの服用を当日だけに限定し、かつ前日の食事(低残渣食)を可能にしたスケジュールを考案した。このわれわれが提案した1日法は大腸カプセル内視鏡検査でも有効に機能した。洗浄度は2日法で行うのと同様に非常に良好であった。図2は腸管洗浄度が良好な状態で観察されたLST-NGの1例であるが、もし洗浄度が不良でカプセル画像の視界が悪ければ、この病変が観察されるか否かは定かではない。

カプセル内視鏡はもちろん検査中に腸管内容物を吸引したり、粘液を洗い落としたりすることはできない。1日法で吸引や洗浄を必要としない状態にまで洗浄度を高めておくことがカプセル内視鏡の場合は重要である。われわれは、その状態に到達すべく、大腸カプセル内視鏡検査開始に先立ち、内視鏡専属看護師がトイレで排便状況をチェックし、実際に腸管洗浄度が良好になっていることを確認したのちに、大腸カプセル内視鏡検査を開始するようにした。もし、排便状況が良好といえない状態であれば、追加下剤を服用させ、排便状況が完全にクリアな状態になったのを確認した後にカプセル内視鏡検査を開始する。実際には1日法で1例、2日法で3例の症例がカプセル内視鏡服用前の追加下剤としてPEG-ELSを300 ml服用されたが、これら4例はいずれも中央判定でExcellentと評価されている。この結果は、追加下剤が有効に機能していることを示唆する。大腸カプセル内視鏡検査前の内視鏡専属看護師の排便状況の確認は、表面型腫瘍や微細病変のような発見が

困難と思われる病変の検出には欠かせない。また、内視鏡専属看護師が排便状況の確認を行えない体制の場合には1日法を導入すべきではないと、筆者らは考えている。

Boosterは本邦では液状のリン酸ナトリウムは市販されていないため、クエン酸マグネシウム等張液を代替品として取り入れた。これは結果的には正解であった。クエン酸マグネシウム等張液はスポーツドリンク味のため、受診者の受容性を向上させた。一方、リン酸ナトリウムはこれまでに報告されているいくつかの文献<sup>13~15)</sup>によると、合併症の点で問題あり、とされており、この点でもわれわれの提唱する下剤服用法は優れているものと考えられる。

われわれの提案した1日法により2日間の飲水総量は3.8Lであり、これは従来の2日法<sup>5)</sup>の6Lに比較し大幅に抑え込むことに成功した。しかし、3.8Lといっても通常の大腸内視鏡検査の際に服用する量に比較すると、まだかなりの量であることは否めない。さらなる減量に取り組まねばならない。

もうひとつ課題が明らかとなった。バッテリー時間内にカプセル内視鏡が体外に排出される割合が当初の予想を大幅に下回った点である。1日法で71%、2日法で55%であった。意外なことに無症状健常ボランティアの方が、大腸内視鏡検査予定患者よりも排出率は低かった。この傾向は1日法でも2日法でも同様であった。本研究の大半は無症状健常ボランティアであるが、彼らの大半は休日に本試験に参加していただいた若手医師、若手看護師たちである。彼らは検査前および検査中の時間帯のうち、下剤服用と排便以外の時間の大半を終始デスクワークに費やし、ほとんど歩行することがなかったことが原因ではないかと推測している。しかし、正確な理由は不明であり、今後の追加検討が必要と考えられる。少なくとも小腸カプセル内視鏡の際に、患者に検査中の歩行を促すのと同様の声かけを私たちは大腸カプセル内視鏡の際にも行うべきであろう。今回検討に使用

した大腸カプセル内視鏡は第1世代のものであるが、第2世代の大腸カプセル内視鏡は大幅に撮影時間が延長されており、この機器の進歩も排出率向上に大きく寄与してくれるであろう。

本邦の大腸がん検診受診率は1次検診受診率で18.6%と低く<sup>16)</sup>、精密検査受診率も60.1%にすぎない<sup>17)</sup>。大腸がん検診受診率が芳しくない理由のひとつに、大腸検査の負担の大きさや不安・怖いといったイメージの先行があげられる。その点、苦痛なく受けられるイメージのカプセル内視鏡は大腸がん検診の受診率向上のひとつの契機になりうるものと考えられる。本邦においても、大腸カプセル内視鏡の一刻も早い登場が待ち望まれる。

### 文 献

- 1) Eliakim R, Yassin K, Niv Y et al : Prospective multicenter performance evaluation of the second-generation colon capsule compared with colonoscopy. *Endoscopy* 41 : 1026-1031 (2009)
- 2) Eliakim R, Fireman Z, Gralnek IM et al : Evaluation of the PillCam Colon capsule in the detection of colonic pathology: results of the first multicenter, prospective, comparative study. *Endoscopy* 38 : 963-970 (2006)
- 3) Schoofs N, Deviere J, Van Gossum A : PillCam colon capsule endoscopy compared with colonoscopy for colorectal tumor diagnosis: a prospective pilot study. *Endoscopy* 38 : 971-977 (2006)
- 4) Sieg A, Friedrich K, Sieg U : Is PillCam COLON capsule endoscopy ready for colorectal cancer screening? A prospective feasibility study in a community gastroenterology practice. *Am J Gastroenterol* 104 : 848-854 (2009)
- 5) Van Gossum A, Navas MM, Fernandez-Urien I et al : Capsule endoscopy versus colonoscopy for the detection of polyps and cancer. *N Engl J Med* 361 : 264-270 (2009)
- 6) Gay G, Delvaux M, Frederic M et al : Could the Colonic Capsule PillCam Colon Be Clinically Useful for Selecting Patients Who Deserve a Complete Colonoscopy?: Results of Clinical Comparison With Colonoscopy in the Perspective of Colorectal Cancer Screening. *Am J Gastroenterol* (2009)
- 7) Sacher-Huvelin S, Coron E, Gaudric M et al : Colon capsule endoscopy vs. colonoscopy in patients at average or increased risk of colorectal cancer. *Aliment Pharmacol Ther* 32 : 1145-1153 (2010)
- 8) Pilz JB, Portmann S, Peter S et al : Colon Capsule Endoscopy compared to Conventional Colonoscopy under routine screening conditions. *BMC Gastroenterol* 10 : 66 (2010)
- 9) Spada C, Hassan C, Munoz-Navas M et al : Second-generation colon capsule endoscopy compared with colonoscopy. *Gastrointest Endosc* (2011)
- 10) Kakugawa Y, Saito Y, Saito S et al : New reduced volume preparation regimen in colon capsule endoscopy. *World J Gastroenterol* (in press)
- 11) Chiu HM, Lin JT, Wang HP et al : The impact of colon preparation timing on colonoscopic detection of colorectal neoplasms --a prospective endoscopist-blinded randomized trial. *Am J Gastroenterol* 101 : 2719-2725 (2006)
- 12) Parra-Blanco A, Nicolas-Perez D, Gimeno-Garcia A et al : The timing of bowel preparation before colonoscopy determines the quality of cleansing, and is a significant factor contributing to the detection of flat lesions: a randomized study. *World J Gastroenterol* 12 : 6161-6166 (2006)
- 13) Wiberg JJ, Turner GG, Nuttall FQ : Effect of phosphate or magnesium cathartics on serum calcium: observations in normocalcemic patients. *Arch Intern Med* 138 : 1114-1116 (1978)
- 14) Markowitz G, Stokes M, Radhakrishnam J et al : Acute phosphate nephropathy following oral sodium phosphate bowel purgative: an underrecognized cause of chronic renal failure. *J Am Soc Nephrol* 16 : 3389-3396 (2005)
- 15) Wexner SD, Beck DE, Baron TH et al : A consensus document on bowel preparation

before colonoscopy: prepared by a task force from the American Society of Colon and Rectal Surgeons (ASCRS), the American Society for Gastrointestinal Endoscopy (ASGE), and the Society of American Gastrointestinal and Endoscopic Surgeons (SAGES). *Gastrointest Endosc* 63 : 894-909 (2006)

16) 平成18年度地域保健・老人保健事業報告の概

況 (<http://www.mhlw.go.jp/toukei/saikin/hw/c-hoken/06/r8html>)

17) 北川晋二, 宮川国久, 宇都宮尚ほか: 平成18年度消化器がん検診全国集計 I. 胃がん検診全国集計 II. 大腸がん検診全国集計 III. 食道がん検診および肝胆膵検診全国集計. *日本消化器がん検診学会雑誌* 47 : 69-92 (2009)

\*

\*

\*

## THE ROLE OF EUS FOR DIAGNOSIS OF PANCREATIC MALIGNANCIES

### ROLE OF ENDOSCOPIC ULTRASOUND-GUIDED FINE NEEDLE ASPIRATION (EUS-FNA) FOR DIAGNOSIS OF SOLID PANCREATIC MASSES

SHIGETAKA YOSHINAGA, HARUHISA SUZUKI, ICHIRO ODA AND YUTAKA SAITO

*Endoscopic Division, National Cancer Center Hospital, Tokyo, Japan*

Since it was developed in 1992, endoscopic ultrasound-guided fine needle aspiration (EUS-FNA) has been widely used and has been adapted for gastrointestinal and perigastrointestinal lesions. A medical literature review to evaluate the role of EUS-FNA for diagnosis of solid pancreatic masses showed a 78–95% sensitivity, 75–100% specificity, 98–100% positive predictive value, 46–80% negative predictive value and a 78–95% accuracy. The reported complication rates of EUS-FNA for pancreatic solid masses were 0–2%, although the criteria for complications varied among the studies. Because of its high diagnostic yield and low complication rate, EUS-FNA is cost-effective and widely applicable for the diagnosis of solid pancreatic masses, and is the best initial and the preferred secondary method compared with other biopsy techniques, such as endoscopic retrograde cholangiopancreatography-guided biopsy, computed tomography/ultrasound-FNA and surgery. Although EUS-FNA is ‘a nearly perfected procedure,’ controversy remains, such as the most suitable diameter of the needle, the appropriate number of needle passes and the necessity of on-site cytopathological evaluation. Recently investigators reported that using molecular analysis of EUS-FNA samples can achieve a higher diagnostic efficacy. Further research is encouraged to optimize the EUS-FNA procedure to reach its maximum diagnostic yield for solid pancreatic masses.

**Key words:** endoscopic ultrasound-guided fine needle aspiration, solid pancreatic mass, diagnostic efficacy, complications.

#### INTRODUCTION

Since Vilmann *et al.*<sup>1</sup> reported their results with endoscopic ultrasound-guided fine needle aspiration (EUS-FNA) for pancreatic disease, EUS-FNA has been adapted not only for pancreatic lesions but also for other gastrointestinal and perigastrointestinal lesions, such as gastrointestinal submucosal tumors, abdominal and mediastinal lymphadenopathy, ascites and adrenal lesions.<sup>2</sup> Recently, EUS-FNA has been developed as a therapeutic method, for example, for pseudocyst drainage, celiac plexus neurolysis, brachytherapy, delivery of anti-tumor agents, bile duct drainage and more.<sup>3</sup>

We will review the efficacy, complications and economic issues of EUS-FNA to evaluate its role in the diagnosis of solid pancreatic masses.

#### THE PRESENT CONDITION

##### Diagnostic efficacy

In different studies since 2003, the sensitivity, specificity, positive predictive value, negative predictive value and accuracy of EUS-FNA for pancreatic solid masses were reported to be 78–95%, 75–100%, 98–100%, 46–80% and 78–95%, respectively (Table 1).<sup>4–16</sup> There was no significant differentiation in these findings compared with results from the review reported by Eloubeidi *et al.* in 2003.<sup>17</sup> In other words, there was no improvement of the efficacy of EUS-FNA even

though new equipment and procedures have been developed. Of course, one of the reasons is that EUS-FNA has been carried out in many different hospitals and institutes all over the world, at times by relatively inexperienced operators. But the results have been excellent, that is to say, EUS-FNA for diagnosis of solid pancreatic masses is ‘a nearly perfected procedure.’ To reach a higher level of accuracy, it might be necessary to explore different diagnostic dimensions. For example, Napoleon *et al.* concluded the combination of FNA and contrast harmonic echo (CHE) techniques could make EUS the most reliable technique for evaluating solid pancreatic lesions.<sup>16</sup> Fusaroli *et al.* suggested CHE-EUS of solid pancreatic masses increased the accuracy of detection of malignant lesions in difficult cases, such as patients with chronic pancreatitis or biliary stents, and concluded that CHE-EUS helped guide EUS-FNA.<sup>18</sup> Although these techniques might improve the efficacy of EUS-FNA, as Napoleon *et al.* mentioned,<sup>16</sup> further prospective study with a large number of patients is necessary to confirm these results.

##### Complications

According to American Society for Gastrointestinal Endoscopy (ASGE) guidelines, EUS-FNA-induced complications include infections, pancreatitis, hemorrhage and bile peritonitis. In different studies since 2003, the reported complication rates of EUS-FNA for pancreatic solid masses were 0–10.5% (Table 1).<sup>5–7,9,10,12–15</sup> But in Ross *et al.*'s study, some EUS-FNA procedures were carried out on the same day as endoscopic retrograde cholangiopancreatography (ERCP)<sup>10</sup> procedures were carried out; therefore, the complication rate might be higher than that seen in other reports. After excluding data derived from this situation, the reported complication rates of EUS-FNA for pancreatic solid masses were

Correspondence: Shigetaka Yoshinaga, Endoscopy Division, National Cancer Center Hospital, 5-1-1 Tsukiji, Chuo-ku, Tokyo, 104-0045, Japan. Email: shiyoshi@ncc.go.jp

*Conflict of interest:* The authors declare no conflict of interest.

Received 9 December 2010; accepted 20 December 2010.

**Table 1.** Review of endoscopic ultrasound-guided fine needle aspiration of solid pancreatic masses

Author	Year	Target	Number of lesions	Sen (%)	Spe (%)	PPV (%)	NPV (%)	Acc (%)	Complication rate (%)
Agarwal B <i>et al.</i> <sup>4</sup>	2004	Pancreatic cancers	81	89	100	100	56	90	ND
Ryozawa S <i>et al.</i> <sup>5</sup>	2005	Pancreatic and peripancreatic lesions	52	82.1	100	100	79.2	89.4	0
Varadarajulu S <i>et al.</i> <sup>6</sup>	2005	Pancreatic masses	300	89.5	98.4	99.5	ND	91.5	2.3
Wakatsuki T <i>et al.</i> <sup>7</sup>	2005	Pancreatic masses without biliary stricture	53	92.9	100	100	78.6	94.3	0
Horwhat JD <i>et al.</i> <sup>8</sup>	2006	Pancreatic masses	36	84	100	100	73	89	ND
Eloubeidi MA <i>et al.</i> <sup>9</sup>	2007	Suspected pancreatic cancers	547	95	92	98	80	94.1	2
Ross WA <i>et al.</i> <sup>10</sup>	2008	Obstructing periampullary lesions	87	83.3	100	100	60.7	86.7	10.5
Wilson JL <i>et al.</i> <sup>11</sup>	2009	Solid pancreatic masses or distal common bile duct masses	155	87	100	100	52	89	ND
Moller K <i>et al.</i> <sup>12</sup>	2009	Solid pancreatic masses	192	82.9	98.2	99.1	70.9	87.5	0
Hwang CY <i>et al.</i> <sup>13</sup>	2009	Solid pancreatic and peripancreatic lesions	139	81.7	89.5	100	46.3	82.7	0
Toucheffeu Y <i>et al.</i> <sup>14</sup>	2009	Solid pancreatic masses	90	78	75	ND	ND	78	0
Fisher L <i>et al.</i> <sup>15</sup>	2009	Pancreatic solid lesions	100	94.3	100	100	72.2	95	2
Napoleon B <i>et al.</i> <sup>16</sup>	2010	Pancreatic solid lesions	35	79	100	100	54	83	ND

Acc, accuracy; ND, no description; NPV, negative predictive value; PPV, positive predictive value; Sen, sensitivity; Spe, specificity.

0–2%, but we should keep in mind that the criteria for complications varied among those studies. In prospective studies, the important complication rates, including self-limited acute pancreatitis, emergency department visits or hospitalization, were 1.97–2.53%.<sup>17,19</sup> In addition, all complications occurred within 72 h,<sup>17</sup> and there were no statistically significant differences in characteristics between patients experiencing complications and those who did not.<sup>19</sup>

Rates of acute pancreatitis after EUS-FNA were 2% in a prospective study<sup>20</sup> and 0.29% in the pooled analysis of 4904 cases.<sup>21</sup> The authors of the prospective study suggested that a recent episode of pancreatitis (within approximately 6 weeks) might be a risk factor for EUS-FNA-induced pancreatitis.<sup>20</sup> Although no clear risk factors were identified in the pooled analysis, the authors suggested that the procedure is safe when carried out by or under the supervision of experienced endosonographers.<sup>21</sup>

Some EUS-FNA-related deaths associated with gastric wall tumor seeding<sup>22</sup> or bleeding after EUS-FNA with the radial scanning instrument,<sup>23</sup> have been reported, although it was difficult to prove the correlation between EUS-FNA and those unhappy results.

In summary, the complication rate was approximately 2% and we should not forget that the mortality of EUS-FNA was not 0%.

#### Further investigations

To achieve higher diagnostic efficacy, some investigators have used molecular analysis of EUS-FNA samples. Especially, some reports suggested that the presence of *K-ras* gene mutations in tissue obtained by EUS-FNA improved the accuracy of the diagnosis.<sup>24–28</sup> Takahashi *et al.* reported that *K-ras* point mutations were found in 74% of pancreatic cancers and 0% of focal pancreatitis lesions.<sup>25</sup> They also mentioned that analysis for the *K-ras* point mutation in specimens obtained by EUS-guided FNA might enhance diagnostic accuracy in indeterminate cases. Hosoda *et al.* suggested they could achieve a diagnosis from EUS-FNA specimens of invasive ductal carci-

nomas, endocrine tumors and acinar cell tumors by using immunostaining for CK7, CDX2, chromogranin A and synaptophysin with *K-ras* mutation analysis.<sup>28</sup> Deng *et al.* reported the usefulness of immunostaining of S100P;<sup>29</sup> and Giordadze *et al.* reported a mucin panel comprising all four antibodies (MUC1, MUC2, MUC5AC and MUC6) might be helpful in differentiating normal/reactive duodenal and gastric epithelium from neoplastic pancreatic tissue.<sup>30</sup> Those reports might help to improve the efficacy of EUS-FNA for diagnosis of solid pancreatic masses.

Molecular analysis has widened the role of EUS-FNA of solid pancreatic masses into treatment fields. Referring to the correlation between deoxycytidine kinase (dCK) activity and gemcitabine sensitivity,<sup>31</sup> Ashida *et al.* reported dCK mRNA expression in EUS-FNA biopsy specimens might be a predictor for response to gemcitabine in patients with unresectable cancer.<sup>32</sup> Although there was no correlation between the expression levels of human equilibrative nucleoside transporter-1 (hENT-1) and gemcitabine efficacy in Ashida *et al.*'s study, Giovannetti *et al.* suggested hENT-1 expression might be a possible prognostic factor for chemosensitivity of pancreatic cancer to gemcitabine.<sup>33</sup> In addition, Fujita *et al.* reported that quantitative analysis of not only dCK and hENT-1, but also RRM1 and RRM2 mRNA levels in microdissected neoplastic cells from EUS-FNA specimens might be useful in predicting the gemcitabine sensitivity of patients with pancreatic ductal adenocarcinoma.<sup>34</sup> Through these further investigations, EUS-FNA might lead the way to 'tailor made therapies.'

#### Comparison with other examinations

If lesions can be imaged and are accessible to other biopsy techniques, ERCP or computed tomography/ultrasound-guided FNA (CT/US-FNA) are considered to be alternative approaches. Rosch *et al.* reported on a prospective comparative study for the diagnosis of biliary strictures using ERCP-

guided cytology/biopsy and EUS-FNA.<sup>35</sup> In this study, although sensitivity was better for ERCP-based techniques in the subgroup with biliary tumors (ERCP 75% vs EUS 25%), EUS-guided biopsy was superior for pancreatic masses (EUS 60% vs ERCP 38%). In a comparative study for the management of pancreatic mass without biliary stricture, the overall results for the available samples were 92.9% sensitivity and 94.3% accuracy in the EUS-FNA group.<sup>7</sup> In contrast, in the ERCP group, the overall results were 33.3% sensitivity and 46.7% accuracy. In those studies, it seemed that the diagnostic power of EUS-FNA was superior to that of ERCP. But in some cases, a biliary biopsy/cytology by ERCP can detect cancers missed by EUS-FNA,<sup>10</sup> therefore, ERCP is still considered to be a diagnostic partner of EUS-FNA when it is necessary to place stents for biliary strictures. But we should never forget that ERCP has a high complication rate.<sup>36,37</sup>

Horwhat *et al.* reported the results of a prospective, randomized study designed to compare percutaneous CT/US-FNA of pancreas mass lesions with EUS-FNA of those lesions in obtaining a tissue diagnosis of cancer.<sup>8</sup> The sensitivity of CT/US-FNA and EUS-FNA for detecting malignancy was 62% and 84%, and the accuracy was 72% and 89%, respectively. But there was no statistically significant difference between the efficacy of CT/US-FNA and EUS-FNA. Erickson reported that these two techniques have similar diagnostic yields as long as the lesion is accessible and visible.<sup>38</sup> But because of its advantages in imaging pancreatic neoplasms and high diagnostic yields, and the concern over needle-tract seeding with transcutaneous aspiration, EUS-FNA was recommended in the sixth edition of the handbook on cancer staging by the American Joint Committee on Cancer as the preferred sampling technique when available for pancreatic masses.<sup>39</sup>

### Economic concerns

Endoscopic ultrasound-guided fine needle aspiration can provide a cost-effective diagnosis of pancreatic cancer when compared with costs of other biopsy techniques, such as ERCP-guided biopsy, CT/US-FNA and surgery.<sup>40</sup> Especially, because of its high diagnostic accuracy, carrying out EUS-FNA as the first endoscopic procedure in patients suspected to have obstructive jaundice can obviate the need for approximately 50% of ERCP procedures, help direct subsequent therapeutic ERCP and substantially reduce costs in these patients.<sup>41</sup> In addition, Harewood and Wiersema reported that EUS-FNA is the least costly staging strategy in the diagnosis of patients with non-metastatic pancreatic head adenocarcinoma, primarily because confirmation of non-peritumoral lymph node involvement can avoid unnecessary surgery.<sup>42</sup> Hence, a diagnostic strategy based on EUS-FNA is the most cost-effective method in the diagnosis of solid pancreatic masses. Moreover, Nasuti *et al.* suggested on-site cytopathologic evaluation of EUS-FNA specimens further reduced costs by decreasing the overall non-diagnostic rate due to inadequate cellularity.<sup>43</sup>

## CONTROVERSIAL ISSUES

### Which needle we should select?

In retrospective studies, 25 gauge (G) needles seemed to have a higher diagnostic yield and caused less trauma,<sup>44</sup>

required fewer passes and had less contamination with blood<sup>45</sup> compared with 22 G needles. But, in the prospective randomized study reported by Siddiqui *et al.*, the two types of needles had equally high diagnostic yields and required a similar number of passes, although the authors concluded that 25 G needles are an effective alternative to 22 G needles.<sup>46</sup> Sakamoto *et al.* prospectively compared EUS-FNA using 25 G needles and 22 G needles with EUS-guided 19 G Trucut needle biopsy (EUS-TNB) in patients with solid pancreatic masses.<sup>47</sup> In this study, the technical success rates of EUS-TNB for uncinete, head and body/tail lesions were 0%, 33.3% and 83.3%, respectively; those of EUS-FNA for uncinete lesions with 25 G needles and 22 G needles was 100% and 33.3%, respectively. In technically successful cases, the rates of cytological diagnosis were 91.7%, 94.5% and 91.7%, and the rates of histological diagnosis were 45.8%, 78.9% and 83.3% with 25 G needles, 22 G needles and 19 G Trucut needles, respectively. In a prospective randomized controlled trial of EUS-FNA using 22 G and 19 G needles, the diagnostic accuracy excluding technical failures was significantly higher in the 19 G needle group (94.5% vs 78.1%) and the amount of cellular material obtained was significantly greater when using 19 G needles, although the technical success rate of 19 G needles for head lesions was 80.8%.<sup>48</sup>

In summary,

1. Nineteen gauge needles have high diagnostic yields through the sampling of larger amounts of cellular material, but the technical success rates for head lesions are relatively low.

2. Nineteen gauge Trucut needles can achieve good specimens for histological evaluation, although they are disadvantageous for use in uncinete and head lesions.

3. Although 25 G needles cannot provide good specimens for histological evaluation, they are advantageous for use in uncinete lesions and might cause less trauma to the pancreatic parenchyma.

4. Twenty-two gauge needles can be used wherever lesions are located although the technical success rates for uncinete lesions might be lower than those of 25 G needles.

### How many passes is enough?

The answer to this question might depend on whether on-site cytopathological evaluation, which can be used to determine the end of a EUS-FNA procedure, is available. Without a cytopathologist, the endoscopist must check the EUS-FNA specimens to confirm whether or not there is tumor, which can be difficult. In addition, the number of passes is one of the factors associated with an increased odds ratio for a positive diagnostic yield for malignancy in solid pancreatic masses.<sup>49</sup> In prospective studies, Erickson *et al.* concluded that five to six passes should be made for pancreatic masses,<sup>50</sup> and LeBlanc *et al.* recommended that at least seven passes with a fine needle into pancreatic lesions are needed to ensure a high degree of certainty for making a correct diagnosis.<sup>51</sup> In contrast, Moller *et al.* reported only one or two needle passes achieved enough adequate specimens for cytology (93.2%) and histology (85.9%) without on-site assessment.<sup>12</sup> Nguyen *et al.* also reported a more than 95% diagnostic yield was obtained after two passes with a 25 G needle, although five passes were needed to obtain

similar results when using a 22 G needle.<sup>45</sup> Thus, although this issue is still controversial, four to six 'good' passes into masses are generally recommended.<sup>38</sup> But it is certain that more passes make a better diagnostic yield<sup>45,49,51</sup> as long as complications do not occur. There is no evidence to date about an association between the number of needle passes and the rate of complications<sup>21</sup> although the possibility of such a relationship exists.<sup>52</sup>

#### Is an on-site pathological evaluation necessary?

If possible, EUS-FNA should be carried out with an on-site pathological evaluation. Previous studies have shown that without on-site cytopathologists the number of needle passes and the procedure times increase and the rates of definitive cytological diagnosis fall by 10% or more.<sup>8,30,50,53,54</sup> In addition, on-site cytopathologic evaluation of EUS-FNA might be cost-effective.<sup>45</sup> However, some reports have shown high diagnostic yields of EUS-FNA without on-site cytopathologic evaluation.<sup>12,55</sup> It is still a difficult problem, because cytopathologists cannot assist all endoscopists. Because on-site cytopathologic evaluation improves the diagnostic yields of EUS-FNA, more effort should be made to include this assessment during EUS-FNA procedures.

#### CONCLUSION

We reviewed the role of EUS-FNA for the diagnosis of solid pancreatic masses. EUS-FNA is considered to be more useful, more cost-effective and safer than similar biopsy procedures. Further research is encouraged to optimize the EUS-FNA procedure to reach its maximum diagnostic yield for solid pancreatic masses. We hope that this wonderful procedure can be shared all over the world.

#### REFERENCES

- Vilman P, Jacobsen GK, Henriksen FW, Hancke S. Endoscopic ultrasonography with guided fine needle aspiration biopsy in pancreatic disease. *Gastrointest. Endosc.* 1992; **38**: 172-3.
- Yamao K, Sawaki A, Mizuno N, Shimizu Y, Yatabe Y, Koshikawa T. Endoscopic ultrasound-guided fine-needle aspiration biopsy (EUS-FNAB): past, present, and future. *J. Gastroenterol.* 2005; **40**: 1013-23.
- Al-Haddad M, Eloubeidi MA. Interventional EUS for the diagnosis and treatment of locally advanced pancreatic cancer. *JOP* 2010; **11**: 1-7.
- Agarwal B, Abu-Hamda E, Molke KL, Correa AM, Ho L. Endoscopic ultrasound-guided fine needle aspiration and multidetector spiral CT in the diagnosis of pancreatic cancer. *Am. J. Gastroenterol.* 2004; **99**: 845-50.
- Ryozawa S, Kitoh H, Gondo T *et al.* Usefulness of endoscopic ultrasound-guided fine-needle aspiration biopsy for the diagnosis of pancreatic cancer. *J. Gastroenterol.* 2005; **40**: 907-11.
- Varadarajulu S, Tamhane A, Eloubeidi MA *et al.* Yield of EUS-guided FNA of pancreatic masses in the presence or the absence of chronic pancreatitis. *Gastrointest. Endosc.* 2005; **62**: 728-36.
- Wakatsuki T, Irisawa A, Bhutani M *et al.* Comparative study of diagnostic value of cytologic sampling by endoscopic ultrasonography-guided fine needle aspiration and that by endoscopic retrograde pancreatography for the management of pancreatic mass without biliary stricture. *J. Gastroenterol. Hepatol.* 2005; **20**: 1707-11.
- Horwhat JD, Paulson EK, McGrath K *et al.* A randomized comparison of EUS-guided FNA versus CT or US-guided FNA for the evaluation of pancreatic mass lesion. *Gastrointest. Endosc.* 2006; **63**: 966-75.
- Eloubeidi MA, Varadarajulu S, Desai S *et al.* A prospective evaluation of an algorithm incorporating routine preoperative endoscopic ultrasound-guided fine needle aspiration in suspected pancreatic cancer. *J. Gastrointest. Surg.* 2007; **11**: 813-19.
- Ross WA, Wasan SM, Evans DB *et al.* Combined EUS with FNS and ERCP for the evaluation of patients with obstructive jaundice from presumed pancreatic malignancy. *Gastrointest. Endosc.* 2008; **68**: 461-6.
- Wilson JL, Kalade A, Prasad S *et al.* Diagnosis of solid pancreatic masses by endoscopic ultrasound-guided fine-needle aspiration. *Intern. Med. J.* 2009; **39**: 32-7.
- Moller K, Papanikolaou IS, Toerner T *et al.* EUS-guided FNA of solid pancreatic masses: high yield of 2 passes with combined histologic-cytologic analysis. *Gastrointest. Endosc.* 2009; **70**: 60-9.
- Hwang CY, Lee SS, Song TJ *et al.* Endoscopic ultrasound guided fine needle aspiration biopsy in diagnosis of pancreatic and peripancreatic lesions: a single center experience in Korea. *Gut Liver* 2009; **3**: 116-21.
- Toucheffeu Y, Le Rhun M, Coron E *et al.* Endoscopic ultrasound-guided fine-needle aspiration for the diagnosis of solid pancreatic masses: the impact on patient-management strategy. *Aliment. Pharmacol. Ther.* 2009; **30**: 1070-7.
- Fisher L, Segarajasingam DS, Stewart C, Deboer WB, Yusoff IF. Endoscopic ultrasound guided fine needle aspiration of solid pancreatic lesions: performance and outcomes. *J. Gastroenterol. Hepatol.* 2009; **24**: 90-6.
- Napoleon B, Alvarez-Sanchez MV, Gincoul R *et al.* Contrast-enhanced harmonic endoscopic ultrasound in solid lesions of the pancreas: results of a pilot study. *Endoscopy* 2010; **42**: 564-70.
- Eloubeidi MA, Chen VK, Eltoun IA *et al.* Endoscopic ultrasound-guided fine needle aspiration biopsy of patients with suspected pancreatic cancer: diagnostic accuracy and acute and 30-day complication. *Am. J. Gastroenterol.* 2003; **98**: 2663-8.
- Fusaroli P, Spada A, Mancino MG, Caletti G. Contrast harmonic echo-endoscopic ultrasound improve accuracy in diagnosis of solid pancreatic masses. *Clin. Gastroenterol. Hepatol.* 2010; **8**: 629-34.
- Eloubeidi MA, Tamhane A, Varadarajulu S, Wilcox CM. Frequency of major complications after EUS-guided FNA of solid pancreatic masses: a prospective evaluation. *Gastrointest. Endosc.* 2006; **63**: 622-9.
- Gress FG, Michael H, Gelurd D *et al.* EUS-guided fine-needle aspiration of the pancreas: evaluation of pancreatitis as a complication. *Gastrointest. Endosc.* 2002; **56**: 864-7.
- Eloubeidi MA, Gress FG, Savides TJ *et al.* Acute pancreatitis after EUS-guided FNA of solid pancreatic masses: a pooled analysis from EUS center in the United States. *Gastrointest. Endosc.* 2004; **60**: 385-9.
- Paquin AC, Garipey G, Lepanto L, Bourdages R, Raymond G, Sahai AV. A first report of tumor seeding because of EUS-guided FNA of a pancreatic adenocarcinoma. *Gastrointest. Endosc.* 2005; **61**: 610-11.
- Gress FG, Hawes RH, Savides TJ, Ikenberry SO, Lehman GA. Endoscopic ultrasound-guided fine needle aspiration biopsy using linear array and radial scanning endosonography. *Gastrointest. Endosc.* 1997; **45**: 243-50.
- Tada M, Komatsu Y, Kawabe T *et al.* Quantitative analysis of K-ras gene mutation on pancreatic tissue obtained by

- endoscopic ultrasound-guided fine needle aspiration: clinical utility for diagnosis of pancreatic tumor. *Am. J. Gastroenterol.* 2002; **97**: 2263–70.
25. Takahashi K, Yamao K, Okubo K *et al.* Differential diagnosis of pancreatic cancer and focal pancreatitis by using EUS-guided FNA. *Gastrointest. Endosc.* 2005; **61**: 76–9.
  26. Maluf-Filho F, Kumar A, Gerhardt R *et al.* *Kras* mutation analysis of fine needle aspirate under EUS guidance facilitates risk stratification of patients with pancreatic mass. *J. Clin. Gastroenterol.* 2007; **41**: 906–10.
  27. Bourmet B, Souque A, Senesse P *et al.* Endoscopic ultrasound-guided fine needle aspiration biopsy coupled with *KRAS* mutation assay to distinguish pancreatic cancer from pseudotumoral chronic pancreatitis. *Endoscopy* 2009; **41**: 552–7.
  28. Hosoda W, Takagi T, Mizuno N *et al.* Diagnostic approach to pancreatic tumor with the specimens of endoscopic ultrasound-guided fine needle aspiration. *Pathol. Int.* 2010; **60**: 358–64.
  29. Deng H, Shi J, Wilkerson M, Fupree W, Lin F. Usefulness of S100P in diagnosis of adenocarcinoma of pancreas on fine needle aspiration biopsy specimens. *Am. J. Clin. Pathol.* 2008; **129**: 81–8.
  30. Giorgadze TA, Peterman H, Baloch ZW *et al.* Diagnostic utility of mucin profile in fine-needle aspiration specimens of the pancreas. *Cancer Cytopathol.* 2006; **108**: 186–97.
  31. Kroep JR, Loves WJ, van der Wilt CL *et al.* Pretreatment deoxycytidine kinase levels predict *in vivo* gemcitabine sensitivity. *Mol. Cancer Ther.* 2002; **1**: 371–6.
  32. Ashida R, Nakata B, Shigekawa M *et al.* Gemcitabine sensitivity-related mRNA expression in endoscopic ultrasound-guided fine-needle aspiration biopsy of unresectable pancreatic cancer. *J. Exp. Clin. Cancer Res.* 2009; **28**: 83.
  33. Giovannetti E, Del Tacca M, Mey V *et al.* Transcription analysis of human equilibrative nucleoside transporter-1 predicts survival in pancreas cancer patients treated with gemcitabine. *Cancer Res.* 2006; **66**: 3928–35.
  34. Fujita H, Ohuchida K, Mizumoto K *et al.* Gene expression levels as predictive markers of outcome in pancreatic cancer after gemcitabine-based adjuvant chemotherapy. *Neoplasia* 2010; **12**: 807–10.
  35. Rosch T, Hofrichter K, Frimberger E *et al.* ERCP or EUS for tissue diagnosis of biliary strictures? A prospective comparative study. *Gastrointest. Endosc.* 2004; **60**: 390–6.
  36. Christensen M, Matzen P, Schulze S, Rosenberg J. Complications of ERCP: a prospective study. *Gastrointest. Endosc.* 2004; **60**: 721–31.
  37. Chang CL, Sherman S, Watkins JL *et al.* Risk factors for post-ERCP pancreatitis: a prospective multicenter study. *Am. J. Gastroenterol.* 2006; **101**: 139–47.
  38. Erickson RA. EUS-guided FNA. *Gastrointest. Endosc.* 2004; **60**: 267–9.
  39. Evans DB, Catalano P, Charnsangavej C *et al.* Exocrine pancreas. In: Greene FL, Page DL, Flemming ID *et al.* (eds). *AJCC Cancer Staging Handbook*, 6th edn. New York: Springer-Verlag, 2002; 182.
  40. Chen VK, Arguedas MR, Kilgore ML, Eloubeidi MA. A cost minimization analysis of alternative strategies in diagnosing pancreatic cancer. *Am. J. Gastroenterol.* 2004; **99**: 2223–34.
  41. Erickson RA, Garza AA. EUS with EUS-guided fine-needle aspiration as the first endoscopic test for the evaluation of obstructive jaundice. *Gastrointest. Endosc.* 2001; **53**: 475–84.
  42. Harewood GC, Wiersema MJ. A cost analysis of endoscopic ultrasound in the evaluation of pancreatic head adenocarcinoma. *Am. J. Gastroenterol.* 2001; **96**: 2651–6.
  43. Nasuti JF, Gupta PK, Baloch ZW. Diagnostic value and cost-effectiveness of on-site evaluation of fine-needle aspiration specimens: review of 5,688 cases. *Diagn. Cytopathol.* 2002; **27**: 1–4.
  44. Yusuf TE, Ho S, Pavey DA, Gress FG. Retrospective analysis of the utility of endoscopic ultrasound-guided fine-needle aspiration (EUS-FNA) in pancreatic masses, using a 22-gauge or 25-gauge needle system: a multicenter experience. *Endoscopy* 2009; **41**: 445–8.
  45. Nguyen TTH, Lee CE, Whang CS *et al.* A comparison of the diagnostic yields and specimen adequacy between 22 and 25 gauge needles for endoscopic ultrasound guided fine-needle aspiration (EUS-FNA) of solid pancreatic lesions (SPL): is bigger better? *Gastrointest. Endosc.* 2008; **67**: AB100.
  46. Siddiqui UD, Rossi F, Rosenthal LS, Padda MS, Murali-Dharan V, Aslanian HR. EUS-guided FNA of solid pancreatic masses: a prospective, randomized trial comparing 22-gauge and 25-gauge needles. *Gastrointest. Endosc.* 2009; **70**: 1093–7.
  47. Sakamoto H, Kitano M, Komaki T *et al.* Prospective comparative study of the EUS guided 25-gauge FNA needle with the 19-gauge Trucut needle and 22-gauge FNA needle in patients with solid pancreatic masses. *J. Gastroenterol. Hepatol.* 2009; **24**: 384–90.
  48. Song TJ, Kim JH, Lee SS *et al.* The prospective randomized, controlled trial of endoscopic ultrasound-guided fine-needle aspiration using 22G and 19G aspiration needles for solid pancreatic or peripancreatic masses. *Am. J. Gastroenterol.* 2010; **105**: 1739–45.
  49. Savides TJ, Donohue M, Hunt G *et al.* EUS-guided FNA diagnostic yield of malignancy in solid pancreatic masses: a benchmark for quality performance measurement. *Gastrointest. Endosc.* 2007; **66**: 277–82.
  50. Erickson RA, Sayage-Rabie L, Beissner S. Factors predicting the number of EUS-guided fine-needle passes for diagnosis of pancreatic malignancies. *Gastrointest. Endosc.* 2000; **51**: 184–90.
  51. LeBlanc JK, Ciaccia D, Al-Assi MT *et al.* Optimal number of EUS-guided fine needle passes needed to obtain a correct diagnosis. *Gastrointest. Endosc.* 2004; **59**: 475–81.
  52. Al-Haddad M, Wallace MB, Woodward TA *et al.* The safety of fine-needle aspiration guided by endoscopic ultrasound: a prospective study. *Endoscopy* 2008; **40**: 204–8.
  53. Klapman JB, Logrono R, Dye CE, Waxman I. Clinical impact of on-site cytopathology interpretation on endoscopic ultrasound-guided fine needle aspiration. *Am. J. Gastroenterol.* 2003; **98**: 1289–94.
  54. Alsohaibani F, Girgis S, Sandha GS. Does onsite cytopathology evaluation improve the accuracy of endoscopic ultrasound-guided fine-needle aspiration biopsy? *Can. J. Gastroenterol.* 2009; **23**: 26–30.
  55. Cherian PT, Mohan P, Douiri A, Taniere P, Hejmadi RK, Mahon BS. Role of endoscopic ultrasound-guided fine-needle aspiration in the diagnosis of solid pancreatic and peripancreatic lesions: is onsite cytopathology necessary? *HPB* 2010; **12**: 389–95.



