

radiofrequency thermal coagulation therapy used for the treatment of similar conditions. In addition, this method avoids the exposure of the patient to radiation, thereby having no direct influence on the dorsal ramus medial branch of the lumbar nerves and allowing treatment targeted at the tissue surrounding the target joint. In the present study, treatment could be completed without local anesthesia in the 3 latter patients by means of applying low-energy ultrasound to a narrower area of tissue, and this did not result in intense pain during treatment. The post-treatment analgesic effect in these 3 patients was comparable to that in the other patients in whom higher energy ultrasound was applied. In 1 patient, a signal intensity change in the bone was revealed by MRI after treatment was provided under a setting resembling that used for the treatment of bone metastasis. This case highlights the necessity of determining optimum ultrasound energy levels depending on the purpose of using this treatment method. Future studies must aim to confirm the effectiveness and safety of this method in a larger number of patients by evaluating the long-term effects on bones, articular cartilage, etc.

In conclusion, MRgFUS was used to treat patients

with chronic low back pain associated with the facet joint. This therapy was shown to satisfactorily alleviate the pain. The results suggest that MRgFUS is promising as a novel, less invasive, and clinically applicable means of treatment for chronic low back pain.

#### References

- 1) Furusawa H, Namba K, Nakahara H et al : The evolving non-surgical ablation of breast cancer : MR guided focused ultrasound (MRgFUS). *Breast cancer*. 2007 ; 14 : 55-58
- 2) Hynynen K, Darkazanli A, Unger E et al : MRI-guided non-invasive ultrasound surgery. *Med Phys*. 1993 ; 20 : 107-115
- 3) Keller S, Bann CM, Dodd SL et al : Validity of the brief pain inventory for use in documenting the outcomes of patients with noncancer pain. *Clin J Pain*. 2004 ; 20 : 309-318
- 4) Liberman B, Gianfelice D, Inbar Y et al : Pain palliation in patients with bone metastases using MR-guided focused ultrasound surgery : a multicenter study. *Ann Surg Oncol*. 2009 ; 16 : 140-146
- 5) Salaffi F, Stancati A, Silvestri CA et al : Minimal clinically important changes in chronic musculoskeletal pain intensity measured on a numerical rating scale. *Eur J Pain*. 2004 ; 8 : 283-291
- 6) Stewart EA, Gostout B, Rabinovici J et al : Sustained relief of leiomyoma symptoms by using focused ultrasound surgery. *Obstet Gynecol*. 2007 ; 110 : 279-287

## 脊椎手術術前患者における静脈血栓塞栓症

喜安 克仁<sup>1)</sup>, 谷口慎一郎<sup>1)</sup>, 武政 龍一<sup>1)</sup>, 谷 俊一<sup>1)</sup>

脊椎手術の静脈血栓塞栓症 (venous thromboembolism : VTE) の術後発症の対策として, 我々は, 術前に検査技師による超音波エコー検査を行い, 発症因子である深部静脈血栓症 (deep venous thrombosis : DVT) の有無を確認し, リスク因子となるVTEの既往がないかを調査している. 術前に認めたものはワーファリン内服, ヘパリン点滴にて可能な限り縮小させている. 今回, 超音波エコーの結果をもとに, 脊椎手術術前患者におけるDVTを認める患者の割合や, その特徴を調査し, 術前患者の下肢DVT発生危険因子を検討した.

### 対象および方法

2008年1月~2010年3月に, 当院で脊椎手術を受けた患者358例のうち, 術前に超音波エコー検査を受けた326例 (男性174例, 女性152例, 平均年齢64.2歳) を対象とした. 症例を頚椎, 胸椎, 胸腰椎移行部, 腰椎, 全脊椎に分類した (表1). 今回の対象疾患は慢性疾患 (頚椎症性脊髄症, 腰部脊柱管狭窄症など) であり, 急性疾患例は含まなかった. 胸腰椎移行部は全例脊椎圧迫骨折後偽関節症例, 全脊椎は全例脊柱側弯症例とした. 検査結果よりDVTを認めた割合を調べた. また術後VTE発症のリスク因子と言われている因子が, 術前のリスクとなるか, 術後リスク因子 (年齢, 性別, BMI, 既往症, 下肢麻痺)<sup>1)</sup>に加えて, 日常生活動作としてBarthel indexを加えて, 統計ソフトSPSSを用いてロジスティック回帰分析を行い, 術前DVT発生リスク因子を調査した.

### 結 果

術前DVT検出率は, 頚椎6.9%, 胸椎6.7%, 腰椎6.5%と一定の割合であった. 若年の側弯症患者は0%だった. 一方で胸腰椎移行部の脊椎圧迫骨折後偽関節症例では, 32.6%と高率に認めた. 検出部位

表1 対象の内わけ

部 位	症例数	男性	女性	年齢	疾患
頚 椎	101	64	37	67.7	頚椎症性脊髄症など
胸 椎	15	10	5	64.3	胸椎症性脊髄症など
胸腰椎移行部	46	17	29	77.4	脊椎圧迫骨折後偽関節
腰 椎	154	82	72	61.1	腰部脊柱管狭窄症など
全脊椎	10	1	9	17.0	脊柱側弯症
	326	174	152	64.2	

表2 DVT検出率 近位は大腿~膝窩静脈, 遠位はヒラメ静脈, 腓骨静脈, 後脛骨静脈とした. 全例無症候性DVTであった.

部 位	症例数	年齢	DVT(%)	検出部位
頚 椎	101	67.7	6.9%(7例)	遠位(7例)
胸 椎	15	64.3	6.7%(1例)	遠位(1)
胸腰椎移行部	46	77.4	32.6%(15例)	近位(2)遠位(13)
腰 椎	154	61.1	6.5%(10例)	近位(1)遠位(9)
全脊椎	10	17.0	0%(0例)	
	326	64.2	10.1%(33例)	

はほとんどの症例で, ヒラメ静脈などの下腿の静脈であり, 無症候性のDVTであった (表2).

術前後におけるDVT検出率は, 術前と術後両方で超音波エコー検査を施行されていた173例で調査すると, 術前に認めなかった149例のうち, 術後にDVTを検出した例は10例 (6.7%) であり, 術前からDVTを認め, 術後もエコー検査をしていた24例は, 術後にも全例DVTが残存していた. そのうち41.7%にDVTの増大増加傾向を認めた. 術前からDVTを認めていた1症例に弾性ストッキングを使用したにも関わらず術中肺塞栓症が発症した.

術前DVT発症リスク因子としては, Barthel index ( $p=0.000$ ,  $OR=0.958$ ) と年齢 ( $p=0.002$ ,  $OR=1.078$ ) が発生危険因子であった. Barthel indexはDVT陰性で平均 $87.9 \pm 16.7$ 点に対し, 陽性は $65.8 \pm 27.9$ 点と低く, その理由は, 移動や歩行, 階段など

Incidence of venous thromboembolism in spinal surgery : Katsuhito KIYASU et al. (Department of Orthopaedic Surgery, Kochi Medical School)

1) 高知大学医学部整形外科学教室

Key words : Venous thromboembolism, Spinal surgery, Risk factor

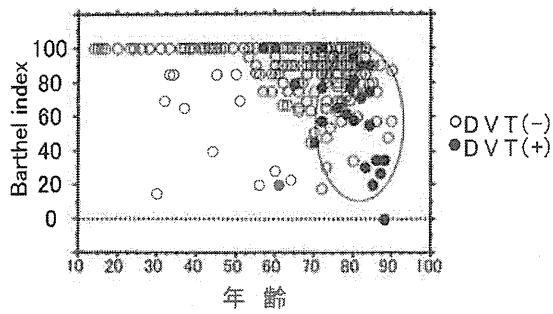


図1 DVT検出の分布 高齢で、Barthel indexが低い場合にDVTが検出されやすい。

に介助が必要なためであった。年齢はDVT陰性で平均 $62.8 \pm 18.4$ 歳に対し、陽性は $77.2 \pm 8.0$ 歳と高く、高齢者に発生率が高い傾向にあった。

#### 考 察

脊椎手術における術後VTE発症リスクは、日本整形外科学会のガイドラインでは中リスクに含まれており、下肢人工関節手術に比べてリスクは低い<sup>1)</sup>。しかし、脊椎手術において術後VTEが発症すると、術後抗凝固療法や血栓溶解療法は硬膜外血腫による麻痺を引き起こすリスクが高くなる問題点があり、まず発症させないような予防が必要である。また、下腿のヒラメ静脈などのDVTは、肺血栓塞栓症の原因となるとの報告もあることから<sup>2)</sup>、下肢DVTを予防することが、術後VTEの予防に重要であると思われる。

今回脊椎手術術前患者におけるDVT検出の割合は10.1%であった。危険因子として、年齢とBarthel indexが挙げられた。高齢で日常生活に介助を要す

る臥床傾向の患者に発症する割合が高かった(図1)。疾患別としては、脊椎圧迫骨折後偽関節症例(胸腰椎移行部)が32.6%と高かった。これは、平均年齢が77.4歳と高齢で、痛みのため日常生活に介助が必要な長期臥床の患者が多かったためと思われる。

術前にDVTを認めた場合、術後にもDVTを認め、41.7%で血栓の増大を認めていた。今回の症例では下腿のヒラメ静脈の無症候性DVTがほとんどであったが、これらの血栓は、術後VTEの危険因子となる可能性が考えられた。

DVT検出リスクの高い患者においては、術前からのスクリーニングと対策が重要と思われ、術前にワーファリン内服やヘパリン点滴による血栓の縮小を図ることや、症例によっては下大静脈フィルターへの挿入も予防の1つと思われる。

#### ま と め

脊椎手術患者における術前DVTの発生率を調査した。術前DVTの危険因子は、高齢、Barthel indexが挙げられ、疾患のために日常生活に介助を要する患者に多く認められた。

#### 文 献

- 1) 日本整形外科学会肺血栓塞栓症/深部静脈血栓症(静脈血栓塞栓症)予防ガイドライン改訂委員会. 日本整形外科学会静脈血栓塞栓症予防ガイドライン. 東京: 南江堂; 2008.
- 2) Ro A, Kageyama N, Tanifuji T, et al. Pulmonary thrombolism: Overview and update from medicolegal aspects. Leg Med (Tokyo) 2008; 10: 57-71.

## 腰椎すべり症における 仰臥位骨盤吊り上げ法を用いた不安定性の評価

木田 和伸<sup>1)</sup>, 阿漕 孝治<sup>2)</sup>, 岡上 裕介<sup>2)</sup>, 小松 誠<sup>2)</sup>

腰椎すべり症における不安定性の評価は、手術適応や手術方法を検討する上で極めて重要である。本研究の目的は、従来の前屈、後屈位での側面レントゲン撮影、いわゆる動態撮影に加え、簡便な新しい不安定性の評価方法を開発することにある。

### 仰臥位骨盤吊り上げ法

今回考案した仰臥位骨盤吊り上げ腰椎単純レントゲン側面像撮影法は、患者さんを仰臥位とし骨盤部にさらしをあて、反張位ギブス巻き用のテーブルで、さらしを用いて約6cmの吊り上げを行い、上肢は挙上、患者さんにリラックスしてもらった状態で腰椎側面像の撮影を行うものである(図1)。さらしは、ほぼ仙骨部に当たるように設定しており、骨盤部吊り上げ力に対抗する力は、すべり椎に対して垂直方向への重力と上半身体軸方向へのけん引力の合力とし働くと考えられた(図2)。

### 対象および方法

対象は男性12例、女性28例の計40例で、年齢は51~85歳、平均71.8歳。対象疾患は変性迂り症38例、分離すべり症2例。すべり椎はL4が32例、L3が5例、L5が2例であった。方法は立位および側臥位での前屈、後屈位での単純レントゲン側面像、仰臥位骨盤吊り上げ単純レントゲン側面像を富士計測ソフトウェアOA-Pを用いて計測した。1、椎間板角(Disc angle) 2、すべり率(%slip) 3、椎間板面積(Normalized disc area)の3つのパラメーターについて検討を加えた。レントゲン計測の方法については、まずソフトウェア上ですべり椎体、およびその下位椎体にA-Fまでの6ポイントをプロットし(図3)、椎間板角Disc angleは線分CD、EFのなす角とし、前方凸を正の値とした。迂り率%slipは点Dより線分EF

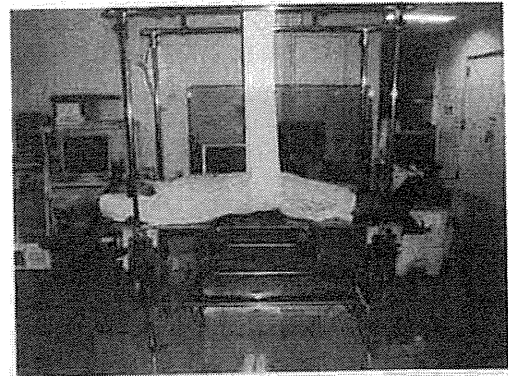


図1 仰臥位骨盤吊り上げ法

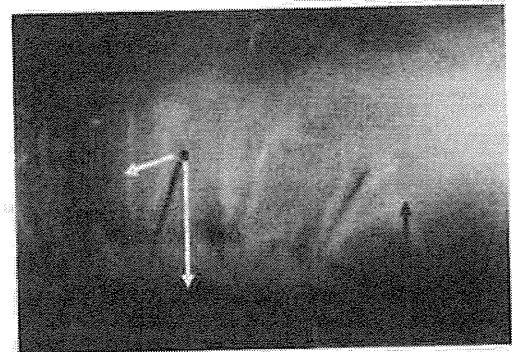


図2 仰臥位骨盤吊り上げレントゲン

におろした垂線の交点を点Gとし、 $GF/EF \times 100\%$ として算出した。椎間板面積Normalized disc areaは点CDEFで囲まれた面積を点ABCDで囲まれた面積で除した値 $\times 100\%$ として算出した。

### 結 果

(各パラメーターにおける体位別平均値間の比較)  
まず椎間板角の各体位における平均値の比較では、臥位前屈で椎間板角は最小、吊り上げにて最大

Radiographic evaluation of the instability in lumbar spondylolisthesis with pulling up the pelvis in supine position :

Kazunobu KIDA et al. (Department of Orthopaedic Surgery, Kochi Medical School)

1) 高知大学医学部整形外科学教室 2) 高知県立幡多けんみん病院整形外科

Key words : Radiographic evaluation, Lumbar spondylolisthesis, Pulling up the pelvis

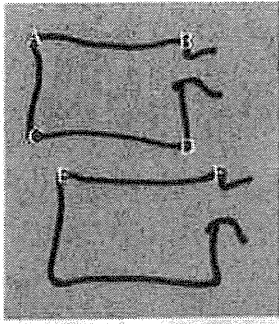


図3 レントゲン計測基準点

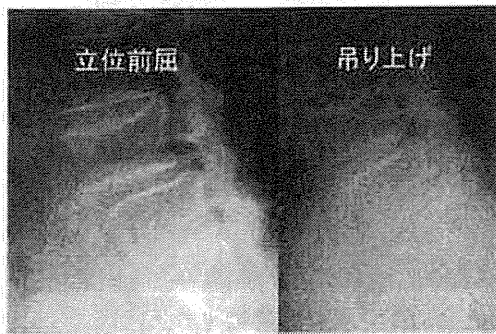


図4 L4変性汙り症例

表1 各パラメーターにおける体位別平均値

	立前屈	臥前屈	立後屈	臥後屈	吊り上げ
椎間板角°	3.3	2.09	7.45	8.35	9.94
すべり率%	20.35	18.3	15.61	14.39	11.01
椎間板面積%	26.76	26.61	29.01	30.32	32.98

であったが各々次点の体位との間で有意差は認められなかった。汙り率については、次点の臥位前屈との間に有意差 ( $P=0.004$ ) を持って立位前屈で最大、次点の臥位後屈との間に有意差 ( $P=0.001$ ) を持って吊り上げで最小であった。椎間板面積については、臥位前屈で最小、最大は臥位後屈との間に有

意差 ( $P=0.031$ ) を持って吊り上げであった (表1)。

(各パラメーターにおける体位間の差の平均値の比較)

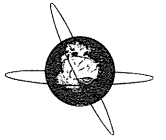
次に椎間板角における体位間の差の平均値の比較について検討してみると、有意差は認められなかったが、吊り上げと臥位前屈の差が最大 ( $7.85^\circ$ ) であった。すべり率においては立位前屈と吊り上げの差が有意差 ( $P=0.004$ ) を持って最大 ( $9.34\%$ ) で、吊り上げにおいて最も整復されていた。椎間板面積においては、吊り上げと臥位前屈の差が最大 ( $6.37\%$ ) であったが有意差は認められなかった。以上の結果から不安定性の計測としては、すべり率では骨盤吊り上げ法と立位前屈位での比較が、椎間板角および椎間板面積では骨盤吊り上げ法と側臥位前屈位の比較が最も有効と考えられた。次にすべり率の差 (立位前屈と吊り上げの差) と椎間板面積の差 (吊り上げと臥位前屈の差) との散布図を見てみると、椎間板面積が増大している症例では、すべりもよく矯正されているように見られる症例が多く、このような相関を示す症例には、椎体間固定を用いて椎間板面積を増すことによりすべりも矯正されるのではと推測された。

#### 症 例

下肢痛を主訴とする72歳のL4変性汙り症例立位前屈で前方すべりが最大で、吊り上げではほぼ完全整復の状態で椎間板面積も良く獲得されていた。このような症例にはTLIFがよい適応であると考えられた。

#### ま と め

腰椎すべり症において、仰臥位骨盤吊り上げ法による、単純レントゲン側面撮影は不安定性評価の簡便な新しい評価法となると考えられ、手術方法の検討に役立つものと思われた。



## Effect of volitional relaxation and motor imagery on F wave and MEP: Do these tasks affect excitability of the spinal or cortical motor neurons?

R. Fujisawa<sup>a,f,\*</sup>, J. Kimura<sup>b</sup>, S. Taniguchi<sup>a</sup>, H. Ichikawa<sup>c</sup>, M. Hara<sup>d</sup>, H. Shimizu<sup>e</sup>, H. Iida<sup>f</sup>, T. Yamada<sup>b</sup>, T. Tani<sup>a</sup>

<sup>a</sup> Department of Orthopaedic Surgery, Kochi Medical School, Kohasu Oko-cho, Nankoku-shi, Kochi 783-8505, Japan

<sup>b</sup> Division of Clinical Electrophysiology, Department of Neurology, University of Iowa College of Medicine, Carver Pavilion, 200 Hawkins Drive, Iowa City, IA 52242, USA

<sup>c</sup> Department of Neurology, Showa University School of Medicine, 1-5-8 Hatanodai, Shinagawa-ku, Tokyo 142-8666, Japan

<sup>d</sup> Department of Rehabilitation Medicine, Teikyo University School of Medicine, 2-11-1 Kaga, Itabashi-ku, Tokyo 173-8606, Japan

<sup>e</sup> Department of Neurology, Tohoku University Hospital, 1-1 Seiryomachi Aoba-ku, Sendai-shi, Miyagi 980-8574, Japan

<sup>f</sup> Department of Orthopaedic Surgery, Kansai Medical University, Fumizono-cho 10-15, Moriguchi-shi, Osaka 570-8506, Japan

### ARTICLE INFO

#### Article history:

Accepted 7 December 2010

Available online 21 January 2011

#### Keywords:

F wave

MEP

Anterior horn cell

Motor neuron excitability

Motor imagery

Volitional relaxation

### ABSTRACT

**Objective:** To test if simple motor imagery, like thumb abduction, preferentially influences the excitability of the spinal or cortical motoneurons.

**Methods:** Ten healthy subjects underwent two separate experiments, each consisting of recording F waves and MEPs from abductor pollicis brevis (APB) in three consecutive sessions: (1) baseline, (2) after immobilizing APB for 3 h, and (3) after brief muscle exercise. During the immobilization, the subjects were instructed to volitionally relax APB in experiment 1 (relaxation task), and mentally simulate thumb abduction without actual movement in experiment 2 (imagery task).

**Results:** Relaxation task suppressed both MEPs and F waves. Motor imagery reduced this suppression, restoring F waves nearly completely (94%) and MEPs only partially (77%). Hence, the rest-induced decline of MEPs in part results from cortical modulation. In contrast, statistical analysis revealed no differences in imagery-induced recovery of motoneuron excitabilities whether assessed by F wave or MEP. Thus, increased excitability of spinal motoneurons responsible for F-wave changes also accounts for recovery of MEPs.

**Conclusions:** Volitional relaxation depresses the spinal and cortical motoneurons, whereas mental simulation counters rest-induced suppression primarily by restoring spinal excitability.

**Significance:** The present findings help elucidate physiologic mechanisms underlying motor imagery.

© 2010 International Federation of Clinical Neurophysiology. Published by Elsevier Ireland Ltd. All rights reserved.

### 1. Introduction

Motor evoked potential (MEP) elicited by transcranial magnetic stimulation (TMS) assesses the excitability of the entire motor system which includes the cortical and the spinal motoneurons (Hess et al., 1986; Marianne and Jørgen, 2002; Okada et al., 2004). In contrast, F-wave characteristics serve as a measure of the spinal excitability per se, which, therefore, can monitor the spinal contribution of MEP changes (Fuchigami et al., 1994; Okada et al., 2004; Taniguchi et al., 2008a,b).

Based on this strategy, most early studies, finding F-wave excitability preserved after limb immobilization, attributed observed MEP changes to cortical modulation (Liepert et al., 1995; Zanette

et al., 1997; Facchini et al., 2002b). A specific instruction to volitionally relax the immobilized muscle, however, resulted in suppression of not only MEPs but also F waves recorded from the target muscle (Okada et al., 2004). These results indicated that MEP changes after muscle relaxation reflect, at least in part, excitability of the anterior horn cells.

More recently, we showed the effect of motor imagery of thumb abduction to counter the rest-induced suppression of F wave (Taniguchi et al., 2008b). This finding suggested that subliminal central drives suffice to maintain the spinal excitability, which would, otherwise, decline with muscle relaxation. In the current study, we postulated that this type of simple motor imagery may not influence the motor cortex, where it originates from, as much as the spinal motor neurons, where it projects to. To test this hypothesis, we compared the excitability changes of MEP versus F wave induced by volitional relaxation and motor imagery during immobilization of the target muscle, as alluded to in a recent editorial (Rivner, 2008).

\* Corresponding author at: Department of Orthopaedic Surgery, Kochi Medical School, Kohasu Oko-cho, Nankoku-shi, Kochi 783-8505, Japan. Tel.: +81 880 2387; fax: +81 880 2388.

E-mail address: [reif565@yahoo.co.jp](mailto:reif565@yahoo.co.jp) (R. Fujisawa).

## 2. Subjects and methods

A total of 10 healthy volunteers (6 men) with a mean age of 36 years (range 29–44) participated in both F wave and MEP studies after signing an informed consent approved by the institutional review board. For both sessions, the subject sat on an arm-chair with the elbow flexed at 90° and the forearm supinated at 90°. Both F waves and MEPs were recorded from the left abductor pollicis brevis (APB) with a pair of round disks attached to the skin with collodion over the belly (E1) and the tendon near the MP joint of the thumb (E2). The skin was prepared with abrasive gel to maintain the impedance below 5 K $\Omega$ . We used a Nihon Koden Neuropack to display the signals with the filter setting at 20 Hz–3 kHz and amplifier gain of 0.2–0.5 mV per division for F waves and 2–5 mV for MEPs.

To elicit F waves, the stimulating electrodes consisted of the cathode placed over the left median nerve 3 cm proximal from the palmar crease of the wrist joint and the anode, 2 cm further proximally (Kimura, 2001). The maximal stimulus was determined by delivering 0.2 ms square-wave pulses of increasing intensity to elicit the largest compound muscle action potentials (CMAPs). Supramaximal shocks, adjusted up to the value of 20% higher than the maximal stimulus, were delivered at 1 Hz for acquisition of F waves.

To evoke MEPs, transcranial magnetic stimulation (TMS) was applied over the right motor cortex using a Magstim Rapid magnetic stimulator (Magstim Company Ltd., Dyfed, UK). A figure-of-8-shaped coil (double 70 mm coil), positioned tangentially to the scalp and held manually with the handle pointing backwards, delivered a stimulus with an intensity of 90–100% of the maximum output. Prior to the recording session, we explored the scalp location for eliciting MEPs, moving the coil over the scalp in steps of 1 cm. The optimal site was then marked with a pen to ensure constant positioning of the coil throughout the experiment.

Both F-wave and MEP studies consisted of two experiments designed to test the effect of volitional relaxation and motor imagery. In each experiment, lasting for 3 h, the left hand was wrapped by an elastic bandage with the arms hanged in front of the chest using a string to immobilize the thumb which helped avoid any inadvertent hand movement. All subjects, familiar with the procedure from prior experience as investigators or volunteers in similar studies, reported that they were able to simulate thumb abduction without actually contracting the muscle. In a practice session, all were able to perform the motor imagery task without muscle contraction, as monitored by surface electromyography with a gain at 10  $\mu$ V/division. To simplify the recording process, therefore, we opted to monitor the absence of muscle contraction only visually without electrophysiological recording during experiments.

### 2.1. Recording of F waves

#### 2.1.1. Experiment 1 for relaxation task

To standardize the baseline, the subject squeezed a sphygmomanometer bulb 100 times to the level of 60–100 mm Hg before recording pre-task F waves with 100 stimuli. The subject was then instructed to relax the APB during the 3-h relaxation task. After recording the post-task F waves with 100 stimuli, the subject squeezed the sphygmomanometer bulb 100 times before recording post-exercise F waves with 100 stimuli.

#### 2.1.2. Experiment 2 for imagery task

The same sequence as in experiment 1 was repeated, but the subject was instructed to mentally simulate thumb abduction approximately once every second without actually contracting the muscle throughout the 3-h immobilization period.

### 2.2. Recording of MEPs

The same sequence was followed as F-wave studies for both experiments 1 and 2 using 50 stimuli to elicit pre-task, post-task and post-exercise MEPs.

### 2.3. Data analysis

F-wave measurements consisted of persistence, or the number of definable F responses per 100 stimuli, onset latency and baseline to peak amplitude averaged in two ways: (1) counting all trials (100) including absent responses as 0  $\mu$ V (trial average), and (2) counting only those trials with detectable responses (response average). MEP measurements comprised onset latency and baseline to peak amplitude counting all trials (50) including absent responses as 0  $\mu$ V.

To quantitate the effectiveness of motor imagery in countering the rest-induced suppression, we devised a measure, post-task ratio, by dividing post imagery values with post relaxation values, both expressed in percentage of the respective baseline. This ratio serves as a measure of effectiveness of motor imagery in countering the rest-induced suppression and can be used to assess whether motor imagery task facilitates F wave and MEP equally or differentially.

Statistical measures, setting the significance level at  $p < 0.05$ , included: (1) two-way ANOVA with Bonferroni corrections for analyzing differences of F-wave and MEP measures among three consecutive sessions and between the experiments 1 and 2, and (2) *t*-test for comparing post-task ratios of F wave and MEP as a measure of imagery-induced facilitation.

To identify possible differences in time course of motoneuron excitabilities measured by F wave and MEP, we also analyzed the group  $\times$  time interaction by two-way ANOVA for repeated measures. If the analysis demonstrates a significant group  $\times$  time interaction, there is a significant group effect over the time effect, indicating a significant difference in time course between the groups. Conversely, an insignificant interaction implies no significant difference between the two.

## 3. Results

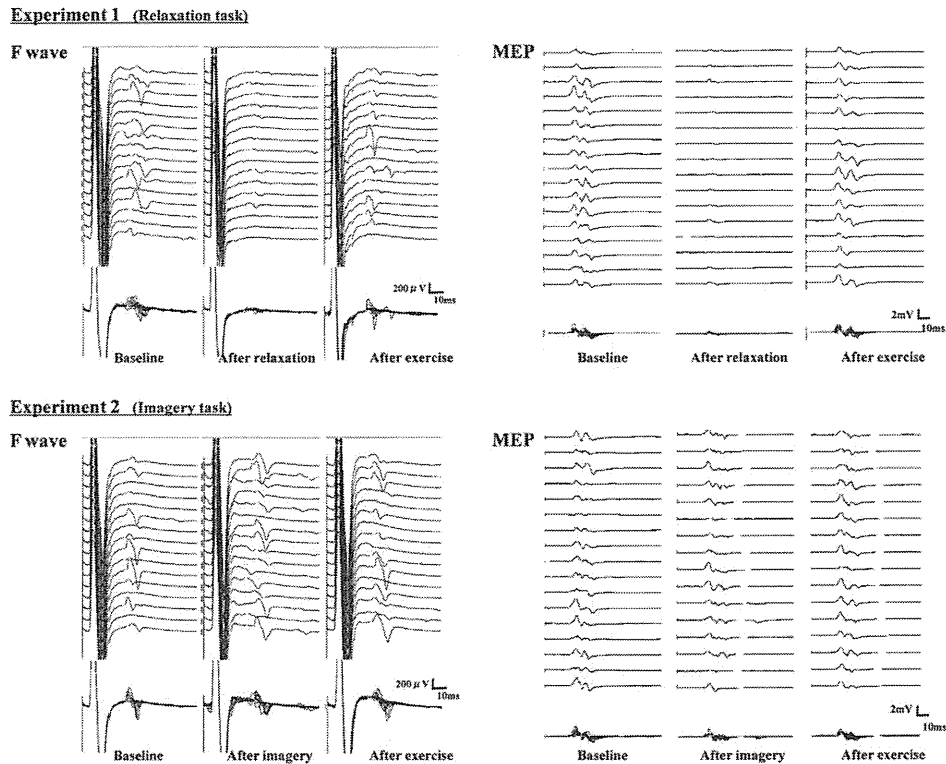
Fig. 1 illustrates a typical example of waveform; Fig. 2 illustrates individual and mean values for F wave and MEP, plotting pre-task, post-task and post-exercise sequence. Table 1 and 2 summarize the results numerically.

### 3.1. F wave data

In experiment 1, F-wave persistence (mean  $\pm$  SEM) decreased from 62.9  $\pm$  4.0% at rest to 45.4  $\pm$  7.1% after volitional relaxation for 3 h ( $p = 0.002$ ) and recovered to 59.0  $\pm$  7.3% following the standardized voluntary contraction ( $p = 0.01$ ). The corresponding values for experiment 2 with motor imagery showed no difference among the three consecutive sessions. Statistical analysis revealed a significant difference between the experiments 1 and 2 for the post-task values ( $p = 0.02$ ), but not for the pre-task or post-exercise values ( $p > 0.05$ ).

F-wave amplitude showed the same tendency as persistence in both experiments. Both trial and response averages of amplitude declined from 125.3  $\pm$  16.6  $\mu$ V and 188.1  $\pm$  15.9  $\mu$ V at rest to 66.5  $\pm$  13.6  $\mu$ V and 134.7  $\pm$  12.8  $\mu$ V after volitional relaxation ( $p < 0.001$  and  $p = 0.004$ ) and recovered to 109.1  $\pm$  21.5  $\mu$ V and 172.5  $\pm$  22.7  $\mu$ V after voluntary muscle contraction ( $p = 0.004$  and  $p = 0.045$ ). The corresponding measures after motor imagery remained unchanged among the three consecutive sessions ( $p > 0.05$ ). For both trial and response averages, statistical analysis





**Fig. 1.** Temporal changes of F-waves (left half) and MEPs (right half) before and after 3 h immobilization of APB and after brief exercise in a 33-year-old healthy woman. F-wave analysis of 100 traces showed a change from 62% to 44% and 66% in persistence and from 108.8  $\mu$ V to 60.8  $\mu$ V and 87.2  $\mu$ V in trial average of amplitude with relaxation task (left top). Corresponding values consisted of 65%, 60% and 58%, and 84.2  $\mu$ V, 112.7  $\mu$ V and 61.3  $\mu$ V with motor imagery task (left bottom). MEP analysis of 50 traces showed a change from 2.0 mV to 0.7 mV and 1.9 mV in amplitude with relaxation task (right top). Corresponding values consisted of 1.6 mV, 1.6 mV and 1.6 mV with motor imagery task (right bottom).

revealed a significant difference between experiments 1 and 2 for the post-task values ( $p = 0.003$  and  $p = 0.03$ ), but not for the pre-task or post-exercise values ( $p > 0.05$ ).

F-wave latencies showed no change among the three consecutive sessions in each experiment except for the post-exercise values in experiment 1, which shortened significantly ( $p = 0.045$ ). Statistical analysis revealed no difference between the experiments 1 and 2 ( $p > 0.05$ ).

### 3.2. MEP data

In experiment 1, MEP amplitude decreased from  $2.1 \pm 0.5$  mV at rest to  $1.1 \pm 0.3$  mV after volitional relaxation for 3 h ( $p = 0.0009$ ) and recovered to  $1.9 \pm 0.5$  mV following the standardized voluntary contraction ( $p = 0.003$ ). The corresponding values for experiment 2 with motor imagery showed no difference among the three consecutive sessions ( $p > 0.05$ ). Statistical analysis revealed no significant difference between the experiments 1 and 2 for all three amplitude measures ( $p > 0.05$ ).

MEP latencies changed from  $21.7 \pm 0.5$  ms at rest to  $22.7 \pm 0.5$  ms after volitional relaxation, showing a significant difference ( $p = 0.01$ ), and to  $22.0 \pm 0.5$  ms after voluntary muscle contraction, showing no difference ( $p > 0.05$ ). The corresponding measures for motor imagery task remained unchanged among the three consecutive sessions ( $p > 0.05$ ). Statistical analysis revealed no significant difference between experiments 1 and 2 for all three latency measures ( $p > 0.05$ ).

### 3.3. Post-task ratio of F wave and MEP

Fig. 3 shows post-task ratios as a measure of imagery-induced facilitation of F wave and MEP. Statistical analysis showed no dif-

ference ( $p > 0.05$ ) between MEP amplitude ( $1.60 \pm 0.24$ ) and F-wave persistence ( $1.74 \pm 0.37$ ), or trial ( $2.55 \pm 0.5$ ) or response average of amplitude ( $1.49 \pm 0.14$ ).

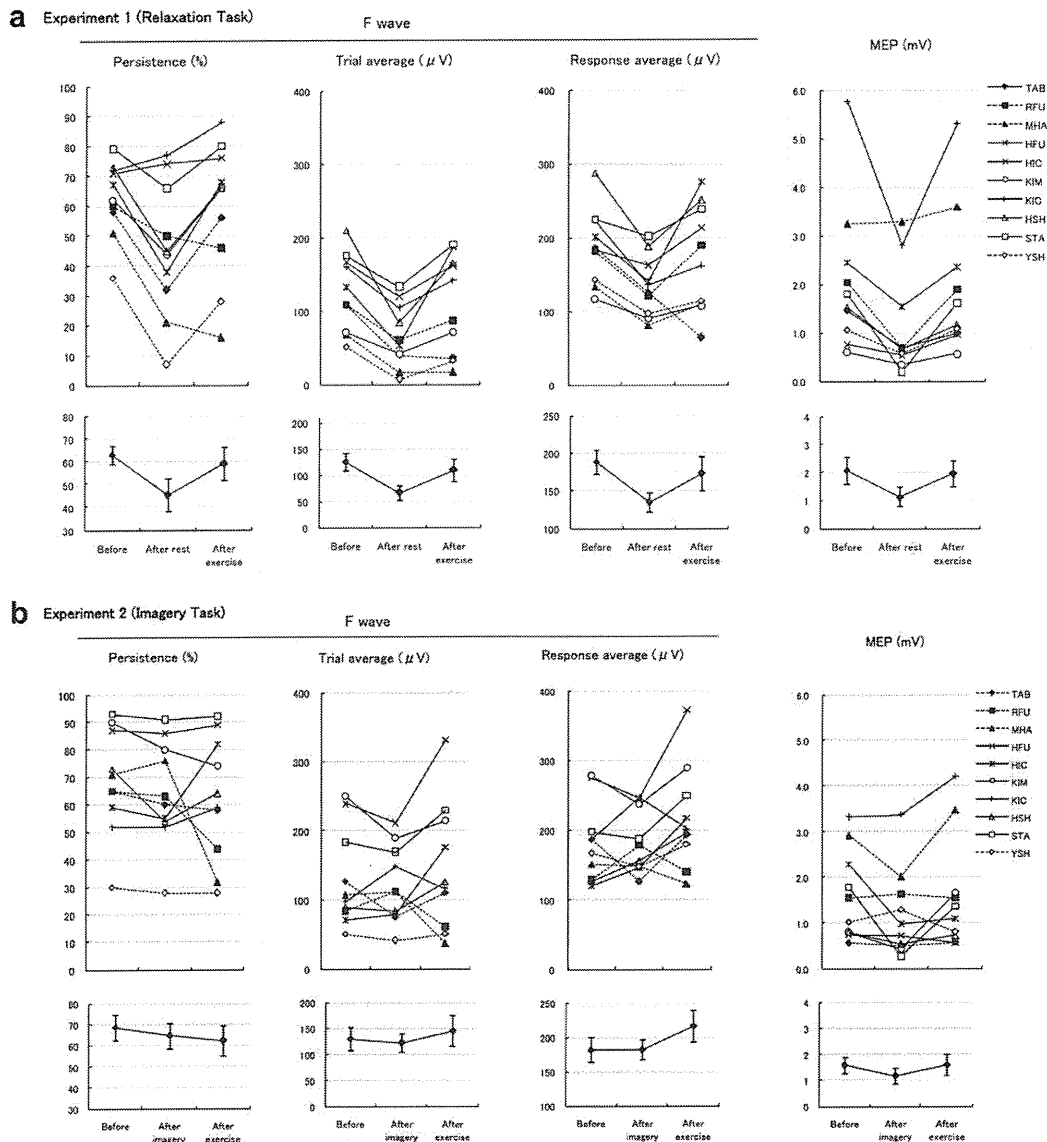
With consecutive stimulation, MEP varied considerably reflecting the ongoing random fluctuation of excitability involving the cortical and spinal motoneurons, unrelated to the experimental tasks. This variability also affected the post-task ratios, which compared the measures of experiments 1 and 2 conducted on two separate occasions.

Although the subject with a high MEP post-task ratio tended to have a high F-wave ratio, the correlation coefficient was low between the two measures. One subject (YSH in Fig. 2a and b) showed an extreme suppression of F wave with relaxation task and a complete preservation with an imagery task, deriving an exceptionally high post-task ratio. Excluding this subject as an outlier, the correlation coefficient between MEP and F-wave post-task ratio achieved 0.41.

### 3.4. Differences in time course of motoneuron excitability measured by F wave and MEP

Comparison between F-wave persistence and MEP amplitude, expressed in percentage of baseline (Table 3), showed no significant group (F wave vs. MEP)  $\times$  time interaction in either experiment 1 ( $F = 1.51$ ,  $p = 0.25$ ) or experiment 2 ( $F = 1.34$ ,  $p = 0.29$ ). Similarly, comparison between trial average of F-wave amplitude and MEP amplitude showed no significant group  $\times$  time interaction in either experiment 1 ( $F = 0.69$ ,  $p = 0.51$ ) or experiment 2 ( $F = 0.44$ ,  $p = 0.65$ ). These findings indicate that the time course of excitability changes induced by rest and motor imagery is not statistically different whether tested by F wave or MEP.





**Fig. 2.** (a) Experiment 1 (Relaxation task): Individual (top) and mean values (bottom) of F-wave persistence and trial and response averages of amplitude, and MEP in 10 healthy subjects. All measures showed significant changes among three sessions. (b) Experiment 2 (Imagery task): Corresponding values for experiment 2 with imagery task in the same 10 subjects showing no significant changes among three sessions.

#### 4. Discussion

Previous studies demonstrated a higher sensitivity of H reflex than F wave in measuring spinal motor neuron excitability (Espiritu and Lin, 2003; Hultborn and Nielsen, 1996). In the range tested in our experimental design, however, the H reflex recorded from the soleus muscle (Yanagisawa et al., 2006) and the F wave from the abductor pollicis brevis (Okada et al., 2004; Taniguchi et al., 2008) showed a very similar time course. These findings provide a rationale for the use of F wave as a solitary measure of excitability for abductor pollicis brevis, which is not accessible to reflex testing at rest. Earlier studies also showed that MEP and H reflex are not equally sensitive to voluntary motor commands because background components are different (Kasai et al., 1997b). The same may apply to the comparison between MEP and F wave. To circumvent this issue we used persistence, or the number of F wave per 100 stimuli, as the measure of excitability in addition to the trial average of F-wave amplitude, which, counting absent responses as 0 μV, showed, as expected,

a similar pattern as persistence. In contrast, the response average of amplitude, disregarding absent responses, measures average size of elicited F waves. As such, it relates more to the type of motoneuron excited than the general excitability of the motoneuron pool.

In earlier studies (Liepert et al., 1995; Facchini et al., 2002b), a reduction in MEP amplitude after limb immobilization without alteration in F waves led most authors to conclude that the observed changes may be solely attributable to cortical modulation. More recent studies in healthy volunteers (Fuchigami et al., 1994; Okada et al., 2004; Taniguchi et al., 2008a), however, demonstrated a progressive suppression of F waves after volitional muscle relaxation and quick recovery following voluntary muscle contraction. These findings imply that MEP changes seen after voluntary muscle relaxation, at least in part, reflect the excitability of the spinal motoneurons. Further studies revealed that the rest-induced F wave suppression selectively involves the target muscle, sparing the neighboring control muscle, which shares the common innervation (Taniguchi et al., 2008a).

**Table 1**  
F-wave changes after relaxation versus motor imagery tasks (mean ± SEM).

	Experiment 1 (relaxation task)		Experiment 2 (imagery task)	
<b>Persistence (%)</b>				
Baseline	62.9 ± 4.0		68.5 ± 6.1	
After the task	45.4 ± 7.1	0.002**	64.5 ± 6.0	N.S.
After exercise	59.0 ± 7.3	0.01**	62.2 ± 7.1	N.S.
<b>Amplitude (trial average) (µV)</b>				
Baseline	125.3 ± 16.6		130.2 ± 22.2	
After the task	66.5 ± 13.6	<0.001***	122.5 ± 17.5	N.S.
After exercise	109.1 ± 21.5	0.004**	145.4 ± 29.4	N.S.
<b>Amplitude (response average) (µV)</b>				
Baseline	188.1 ± 15.9		182.2 ± 17.9	
After the task	134.7 ± 12.8	0.004**	182.2 ± 14.5	N.S.
After exercise	172.5 ± 22.7	0.045*	216.4 ± 23.0	N.S.
<b>Latency (ms)</b>				
Baseline	26.7 ± 0.5		26.9 ± 0.5	
After the task	26.9 ± 0.7	N.S.	26.5 ± 0.5	N.S.
After exercise	26.0 ± 0.5	0.045*	26.2 ± 0.6	N.S.

N.S. not significant.  
\* P < 0.05.  
\*\* P < 0.01.  
\*\*\* P < 0.001.

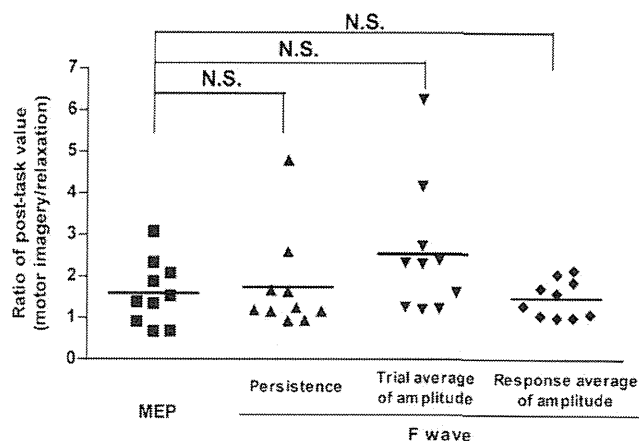
Various attempts to elucidate the effect of motor imagery have produced inconsistent results. Crews and Kamen (2006) reported that mental stimulation of 300 trials a day failed to counter MEP suppression induced by limb immobilization. Most other authors showed MEP enhancement without demonstrable change in simultaneously recorded F waves or H reflex during motor imagery (Izumi et al., 1995; Kasai et al., 1997a; Kiers et al., 1997; Hashimoto and Rothwell, 1999; Yahagi and Kasai, 1999; Tremblay et al., 2001; Facchini et al., 2002a; Stinear et al., 2006). Still others documented facilitatory effect of motor imagery on the F wave (Rossini et al., 1999; Taniguchi et al., 2008b; Ichikawa et al., 2009; Hara et al., 2010), and H reflex (Gandevia et al., 1997; Cowley et al., 2008), as predicted by the effect of subthreshold TMS timed to collide on the spinal motoneurons to enhance F waves (Mercuri et al., 1996). These inconsistencies may result in part from difficulties to maintain mental simulation for an extended period because of fatigue and lapse of concentration.

In the current study, we were able to confirm the effect of volitional relaxation and motor imagery on the F waves and MEPs. In addition, we compared the excitability change of F wave and MEP using an identical experimental design applied to both recordings. Motor imagery, which countered rest-induced suppression, restored F waves nearly completely (94%) and MEP to a lesser extent (77%) (Fig. 2b). This finding suggests that the decreased excitability of the anterior horn cells predominantly, but not exclu-

**Table 2**  
MEP changes after relaxation versus motor imagery tasks (mean ± SEM).

	Experiment 1 (relaxation task)		Experiment 2 (imagery task)	
<b>Amplitude (mV)</b>				
Baseline	2.1 ± 0.5		1.7 ± 0.3	
After the task	1.1 ± 0.3	0.0009***	1.2 ± 0.3	N.S.
After exercise	1.9 ± 0.5	0.003**	1.7 ± 0.4	N.S.
<b>Latency (ms)</b>				
Baseline	21.7 ± 0.5		22.2 ± 0.5	
After the task	22.7 ± 0.5	0.01**	22.4 ± 0.3	N.S.
After exercise	22.0 ± 0.5	N.S.	22.0 ± 0.4	N.S.

N.S. not significant.  
\* P < 0.05.  
\*\* P < 0.01.  
\*\*\* P < 0.001.



**Fig. 3.** Post-task ratios, or values after motor imagery divided by values after relaxation, which measure the effectiveness of motor imagery in countering rest-induced suppression. Statistical analysis showed no difference ( $p > 0.05$ ) between MEP and F wave.

sively, account for the observed change of MEP, which in part results from cortical modulation. In contrast, comparison of the post-task ratios, as a measure of effectiveness, indicated that motor imagery counters the rest-induced suppression of MEP and F wave to the same degree, showing no statistical differences (Fig. 3). Moreover, F-wave persistence and MEP showed no significant group × time interaction, indicating that imagery induced change is the same whether tested by MEP or F-wave, which solely reflects the excitability of spinal motoneurons. These findings suggest that, for the type of simple motor imagery employed in our study, recovery of the spinal motor neurons alone can account for the observed alteration of MEPs, with no need to implicate additional cortical modulation.

We can only speculate on physiological mechanisms underlying mental simulation of thumb abduction which facilitates spinal but not necessarily cortical motor neurons. Despite the traditional emphasis of motor imagery modulating the primary motor cortex (Decety et al., 1988; Porro et al., 1996; Pfurtscheller and Neuper, 1997; Lotze et al., 1999; Rossini et al., 1999), a task with less cognitive component may have insufficient effect on cortical neurons (Ryan and Simons, 1981; Driskell et al., 1994). Our results indicate that subliminal central drive induced by simple mental simulation, as thumb abduction, has a much greater facilitatory effect at the spinal level, where it projects to, than at the cortical level, where it originates from. The changes occurring in the spinal excitability could be the result of more complex interactions mediated by the primary motor cortex. Based on the currently available data, we are unable to speculate further on the complex network of excitability changes taking place at the cortical level during motor imagery. The use of fMRI may supplement physiologic studies to assess the common areas of brain activation during imaged finger movement.

**Table 3**  
Change of motoneuron excitabilities assessed by F wave and MEP (mean ± SEM).

	F wave (%)		MEP (%)
	Persistence	Trial average of amplitude	Amplitude
<b>Experiment 1 (relaxation task)</b>			
Baseline	100	100	100
After the task	68.3 ± 8.6	48.6 ± 6.5	53.4 ± 7.5
After exercise	91.1 ± 7.9	81.5 ± 10.9	94.5 ± 5.2
<b>Experiment 2 (imagery task)</b>			
Baseline	100	100	100
After the task	94.2 ± 2.8	99.3 ± 8.6	76.9 ± 10.6
After exercise	91.9 ± 7.9	115.0 ± 17.9	102.4 ± 13.8

In summary, the present data confirm a rest-induced reduction of anterior horn cell excitability as measured by F waves and facilitatory effect of motor imagery to prevent this suppression. Volitional relaxation and motor imagery also induces a similar change in amplitude of MEPs. Percentage comparison indicates that the decreased spinal excitability measured by F wave during volitional relaxation accounts for the observed MEP changes mostly, but not entirely. In contrast, post-task ratio calculated as a measure of imagery effectiveness showed no difference between MEPs and F waves. Additionally, these two measures of motoneuron excitability showed no significant group  $\times$  time interaction, indicating that the time course of imagery-induced recovery showed no difference whether tested by F wave or MEP. Thus, motor imagery of thumb abduction counters the rest-induced suppression of MEPs primarily by restoring the excitability of the anterior horn cells as evidenced by F-wave changes.

## Reference

- Cowley PM, Clark BC, Ploutz-Snyder LL. Kinesthetic motor imagery and spinal excitability: the effect of contraction intensity and spatial localization. *Clin Neurophysiol* 2008;119:1849–56.
- Crews RT, Kamen G. Motor-evoked potentials following imagery and limb disuse. *Int J Neurosci* 2006;116:639–51.
- Decety J, Philippon B, Ingvar DH. rCBF landscapes during motor performance and motor ideation of a graphic gesture. *Eur Arch Psychiatry Neurol Sci* 1988;238:33–8.
- Driskell JE, Copper C, Moran A. Does mental practice enhance performance? *J Appl Psychol* 1994;79:481–92.
- Espiritu MG, Lin CS, Burke D. Motoneuron excitability and the F wave. *Muscle Nerve* 2003;27:720–7.
- Facchini S, Muellbacher W, Battaglia F, Boroojerdi B, Hallett M. Focal enhancement of motor cortex excitability during motor imagery: a transcranial magnetic stimulation study. *Acta Neurol Scand* 2002a;105(3):146–51.
- Facchini S, Romani M, Tinazzi M, Aglioti SM. Time-related changes of excitability of the human motor system contingent upon immobilization of the ring and little fingers. *Clin Neurophysiol* 2002b;113(3):367–75.
- Fuchigami Y, Kawai S, Omote K. Magnetic stimulation in continuous intentional paresis (simulation). *J Electrodiagnosis Spinal Cord* 1994;16:82–5.
- Gandevia SC, Wilson LR, Inglis JT, Burke D. Mental rehearsal of motor tasks recruits alpha-motoneurons but fails to recruit human fusiform neurons selectively. *J Physiol* 1997;505:259–66.
- Hara M, Kimura J, Walker DD, Taniguchi S, Ichikawa H, Fujisawa R, et al. Effect of motor imagery and voluntary muscle contraction on the F wave. *Muscle Nerve* 2010;42:208–12.
- Hashimoto R, Rothwell JC. Dynamic changes in corticospinal excitability during motor imagery. *Exp Brain Res* 1999;125:75–81.
- Hess CW, Mills KR, Murray NM. Magnetic stimulation of the human brain: facilitation of motor responses by voluntary contraction of ipsilateral and contralateral muscles with additional observations on an amputee. *Neurosci Lett* 1986;71:235–40.
- Hultborn H, Nielsen JB. Comments: methodological problems of comparing F responses and H reflexes. *Muscle Nerve* 1996;19:1347–8.
- Ichikawa H, Kimura J, Taniguchi S, Hara M, Fujisawa R, Shimizu H, Yamada T, Kawamura M. Motor imagery facilitates the spinal motor neurons without hemispheric asymmetry. *J Clin Neurophysiol* 2009;26:358–65.
- Izumi S, Findley TW, Ikai T, Andrews J, Daum M, Chino N. Facilitatory effect of thinking about movement on motor-evoked potentials to transcranial magnetic stimulation of the brain. *Am J Phys Med Rehabil* 1995;74:207–13.
- Kasai T, Kawai S, Kawanishi M, Yahagi S. Evidence for facilitation of motor evoked potentials (MEPs) induced by motor imagery. *Brain Res* 1997a;744:147–50.
- Kasai T, Toyoda Y, Yahagi S. Motor evoked potentials (MEPs) and H-reflexes are not equally sensitivity to voluntary motor commands. *Brain Res* 1997b;764:273–6.
- Kiers L, Fernando B, Tomkins D. Facilitatory effect of thinking about movement on magnetic motor-evoked potentials. *Electroencephalogr Clin Neurophysiol* 1997;105:262–8.
- Kimura J. *Electrodiagnosis in disease of nerve and muscle. Principles and practice*, 3rd ed. NY: Oxford University Press; 2001.
- Liepert J, Tegenthoff M, Malin JP. Changes of cortical motor area size during immobilization. *Electroencephalogr Clin Neurophysiol* 1995;97:382–6.
- Lotze M, Montoya P, Erb M, Hülsmann E, Flor H, Klose U, et al. Activation of cortical and cerebellar motor areas during executed and imagined hand movements: an fMRI study. *J Cogn Neurosci* 1999;11:491–501.
- Marianne L, Jørgen N. Post-exercise facilitation and depression of M wave and motor evoked potentials in healthy subjects. *Clin Neurophysiol* 2002;113:1092–8.
- Mercuri B, Wassermann EM, Manganotti P, Ikoma K, Samii A, Hallett M. Cortical modulation of spinal excitability: an F-wave study. *Electroencephalogr Clin Neurophysiol* 1996;101(1):16–24.
- Okada F, Kimura J, Yamada T, Shinozuka M, Ueno H. Effect of sustained volitional muscle relaxation on the excitability of the anterior horn cells: comparison between the F wave and transcranial motor evoked potential (MEP). *Jpn J Clin Neurophysiol* 2004;32(3):213–9.
- Pfurtscheller G, Neuper C. Motor imagery activates primary sensorimotor area in humans. *Neurosci Lett* 1997;239:65–8.
- Porro CA, Francescato MP, Cettolo V, Diamand ME, Baraldi P, Zuiani C, et al. Primary motor and sensory cortex activation during motor performance and motor imagery: a functional magnetic resonance imaging study. *J Neurosci* 1996;16:7688–98.
- Rivner MH. The use of F-waves as a probe for motor cortex excitability. *Clin Neurophysiol* 2008;119(6):1215–6.
- Rossini PM, Rossi S, Pasqualetti P, Tecchio F. Corticospinal excitability modulation to hand muscles during movement imagery. *Cereb Cortex* 1999;9:161–7.
- Ryan ED, Simons J. Cognitive demand, imagery, and frequency of mental rehearsal as factors influencing acquisition of motor skills. *J Sport Psychol* 1981;3:35–45.
- Stinear CM, Fleming MK, Byblow WD. Lateralization of unimanual and bimanual motor imagery. *Brain Res* 2006;1095(1):139–47.
- Tremblay F, Tremblay LE, Colcer DE. Modulation of corticospinal excitability during imagined knee movements. *J Rehabil Med* 2001;33(5):230–4.
- Taniguchi S, Kimura J, Yanagisawa T, Okada F, Yamada T, Taniguchi S, et al. Rest-induced suppression of anterior horn cell excitability as measured by F waves: comparison between volitionally inactivated and control muscles. *Muscle Nerve* 2008a;37:343–9.
- Taniguchi S, Kimura J, Yamada T, Ichikawa H, Hara M, Fujisawa R, et al. Effect of motion imagery to counter rest-induced suppression of F wave as a measure of anterior horn cell excitability. *Clin Neurophysiol* 2008b;119:1346–52.
- Yahagi S, Kasai T. Motor evoked potentials induced by motor imagery reveal a functional asymmetry of cortical motor control in left- and right-handed human subjects. *Neurosci Lett* 1999;276(3):185–8.
- Yanagisawa T, Kimura J, Azuma Y, Ogushi M, Taniguchi S. Excitability of the anterior horn cells after volitional inactivity of soleus muscle: H reflex study. *Jpn J Clin Neurophysiol* 2006;34:89–96.
- Zanette G, Tinazzi M, Bonato C, di Summa A, Manganotti P, Polo A, et al. Reversible changes of motor cortical outputs following immobilization of the upper limb. *Electroencephalogr Clin Neurophysiol* 1997;105(4):269–79.

# Factors predicting progression in early degenerative lumbar scoliosis

Shinsuke Kohno, Masahiko Ikeuchi, Shinichirou Taniguchi, Ryuichi Takemasa, Hiroshi Yamamoto, Toshikazu Tani  
Department of Orthopaedic Surgery, Kochi Medical School, Kohasu Oko-cho, Nankoku City, Kochi, Japan

---

## ABSTRACT

**Purpose.** To review early radiographs of patients with *de novo* degenerative lumbar scoliosis to determine factors predicting early scoliosis progression.

**Methods.** Standing anteroposterior and lateral radiographs of 7 men and 20 women aged 48 to 83 (mean, 63) years with Cobb angles between  $>5^\circ$  and  $<20^\circ$  were reviewed. They were followed up for a mean of 12 (range, 10–18) years. Radiographic variables measured included (1) the Cobb angle, (2) the grade of rotation of the apical lumbar vertebra, (3) the presence of a lateral vertebral translation of  $\geq 3$  mm, (4) the degree of osteoporosis, and (5) the Harrington factor (the degree of scoliosis divided by the number of vertebrae involved).

**Results.** During the follow-up period, the mean Cobb angle increased  $5.3^\circ$  from  $10.1^\circ$  to  $15.4^\circ$ , representing an increase of  $0.4^\circ$  per year. In initial radiographs, the apical vertebral rotation was rated as grade 0 in 3 patients, grade 1 in 19, grade 2 in 4, and grade 3 in one. A lateral vertebral translation of  $\geq 3$  mm was

noted in 9 patients. The degree of osteoporosis was rated as grade 0 in 9 patients, grade 1 in 11, grade 2 in 5, and grade 3 in 2. The mean Harrington factor was 2.4. In the multiple regression analysis, only the grade of apical vertebral rotation was significantly correlated with scoliosis progression (regression coefficient=0.502,  $p=0.009$ ).

**Conclusion.** Apical vertebral rotation may help predict the scoliosis progression and determine the timing of surgical intervention in patients with early degenerative lumbar scoliosis.

**Key words:** lumbar vertebrae; risk factors; scoliosis

---

## INTRODUCTION

Degenerative lumbar scoliosis in elderly patients usually manifests as a combination of disabling low-back pain, radicular symptoms, and neurogenic claudication. The severity of the scoliosis affects not only the symptoms<sup>1</sup> but also the treatments.<sup>2,3</sup> Surgical procedures vary from short-segment decompression alone to more aggressive options such as long-segment

fusion to correct the spinal deformity.<sup>4-6</sup> Extensive surgery can be avoided if patients are treated before the deformity becomes severe.<sup>7</sup>

There are 2 types of scoliosis in adults: *de novo* degenerative (which progresses faster) and adolescent onset.<sup>8-11</sup> Previous studies on risk factors of scoliosis progression usually included both types of patients with severe scoliosis and relatively short follow-up.<sup>12-14</sup> We reviewed early radiographs of patients with *de novo* degenerative lumbar scoliosis to determine factors predicting scoliosis progression.

## MATERIALS AND METHODS

Standing anteroposterior and lateral radiographs of 7 men and 20 women aged 48 to 83 (mean, 63) years with Cobb angles between  $>5^\circ$  and  $<20^\circ$  were reviewed. They were followed up for a mean of 12 (range, 10-18) years. Patients who had adolescent-onset scoliosis, previous spine surgery, a history of scoliosis, or a Cobb angle of  $\geq 20^\circ$  were excluded.

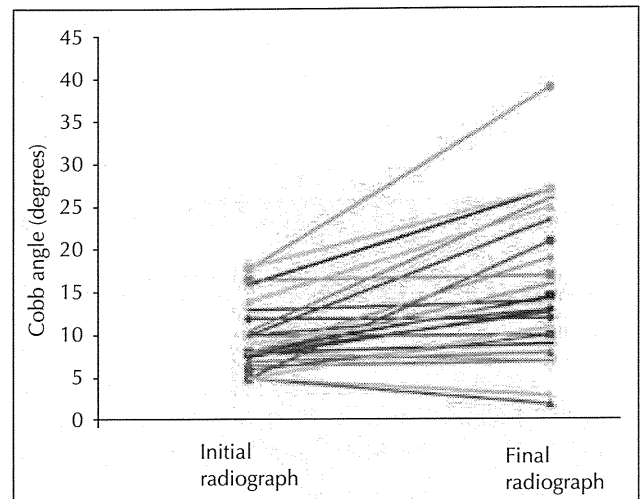
Radiographic variables measured included (1) the Cobb angle (standing), (2) the grade of rotation of the apical lumbar vertebra,<sup>15</sup> (3) the presence of a lateral vertebral translation of  $\geq 3$  mm, (4) the degree of osteoporosis semi-quantitated by the Jikei method<sup>16</sup> assigning grades from 0 to 3, and (5) the Harrington factor<sup>17</sup> (the degree of scoliosis divided by the number of vertebrae involved). The Cobb angle was measured twice by one orthopaedic surgeon using the same protractor. All variables were analysed using a multivariable linear regression model. A p value of  $<0.05$  was considered statistically significant.

## RESULTS

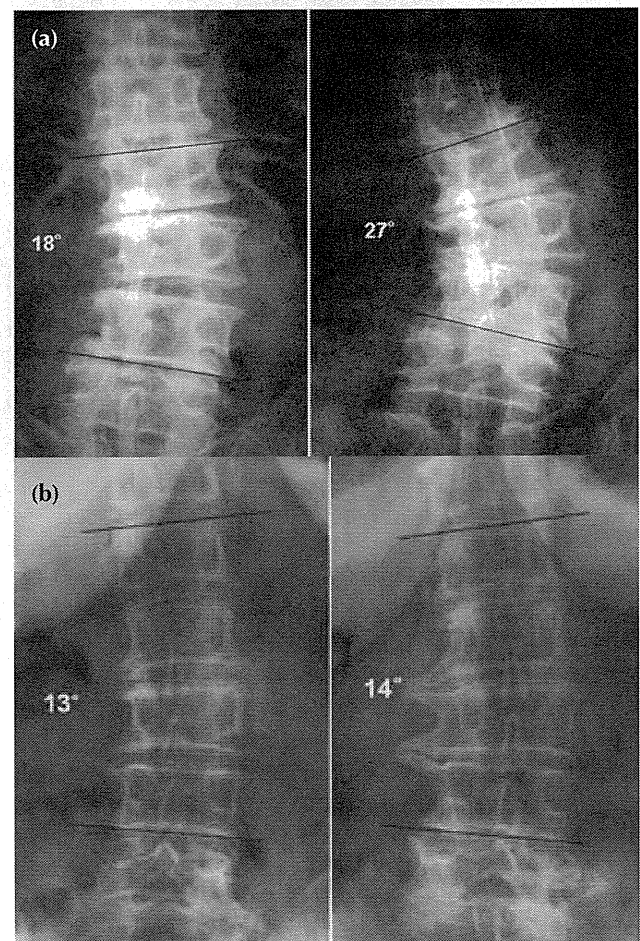
During the follow-up period, the mean Cobb angle increased  $5.3^\circ$  (range,  $-8^\circ$ - $21^\circ$ ) from  $10.1^\circ$  (standard deviation [SD],  $4.3^\circ$ ; range,  $5^\circ$ - $19^\circ$ ) to  $15.4^\circ$  (SD,  $8.7^\circ$ ; range,  $2^\circ$ - $39^\circ$ ), representing an increase of  $0.4^\circ$  (range,  $-0.8^\circ$ - $1.3^\circ$ ) per year (Figs. 1 and 2). The intra-observer agreement was 0.95.

In initial radiographs, the apical vertebral rotation was rated as grade 0 in 3 patients, grade 1 in 19, grade 2 in 4, and grade 3 in one. A lateral vertebral translation of  $\geq 3$  mm was noted in 9 patients. The degree of osteoporosis was rated as grade 0 in 9 patients, grade 1 in 11, grade 2 in 5, and grade 3 in 2. The mean Harrington factor was 2.4 (SD, 1.1; range, 1.2-5.5).

In the multiple regression analysis, only the grade of apical vertebral rotation was significantly correlated with scoliosis progression (regression



**Figure 1** Changes of the Cobb angle in 27 patients with *de novo* degenerative lumbar scoliosis over a mean of 12 years.



**Figure 2** (a) The Cobb angle of a 68-year-old woman increases from  $18^\circ$  to  $27^\circ$  over 10 years. The apical vertebral rotation on the initial radiograph is grade 2. (b) The Cobb angle of a 52-year-old woman increases slightly from  $13^\circ$  to  $14^\circ$  over 12 years. The apical vertebral rotation on the initial radiograph is grade 1.

**Table**  
**Multivariable regression analysis of scoliosis progression**

Variable	Regression coefficient	Standard error (95% CI)	p Value
Cobb angle	-0.04	0.05 (-0.14 to 0.06)	0.431
Apical vertebral rotation	0.502	0.17 (0.14 to 0.86)	0.009
Lateral vertebral translation	0.054	0.19 (-0.34 to 0.45)	0.777
Harrington factor	-0.01	0.19 (-0.4 to 0.38)	0.959
Osteoporosis	0.189	0.1 (-0.03 to 0.4)	0.081
Follow-up period	0.006	0.02 (-0.03 to 0.05)	0.754

coefficient=0.502,  $p=0.009$ , Table). Even after eliminating the explanatory variables (the Harrington factor and the lateral vertebral translation), osteoporosis was still not a significant factor ( $p=0.067$ ).

## DISCUSSION

Osteoporosis was initially considered to be the cause of degenerative lumbar scoliosis in adults,<sup>18,19</sup> but such association was not found.<sup>20</sup> Our findings also suggested that the degree of osteoporosis does not play a role in scoliosis progression. Factors predicting scoliosis progression are a Cobb angle of  $\geq 30^\circ$ , an apical vertebral rotation of  $\geq$  grade 2, a lateral vertebral translation of  $\geq 6$  mm, and an intercrest line through the L5 vertebra.<sup>12,14</sup> Nonetheless, these studies included both *de novo* degenerative and adolescent-onset lumbar scoliosis types, as the range of scoliosis was wide ( $14^\circ$  to  $60^\circ$ <sup>12</sup> and  $12^\circ$  to  $50^\circ$ <sup>14</sup>). In a study using multivariate logistic regression analysis,<sup>13</sup> lateral spondylolisthesis of the apical vertebra, the Harrington factor, and disc index<sup>21</sup> were all associated with scoliosis progression. Yet patients with a Cobb angle of  $>30^\circ$  were also included, and the follow-up period was only 2 to 4.5 years.

In our study, only patients with early adult-onset degenerative lumbar scoliosis were included and followed up for at least 10 years. This may have excluded patients with more advanced degenerative lumbar scoliosis, but would not affect our analysis of scoliosis progression in its early stages. Conceivably there may have been a selection bias, as patients with rapid scoliosis progression or those followed up for  $<10$  years were excluded. However, only 3 such patients were excluded; their Cobb angles ranged from  $5^\circ$  to  $12^\circ$  initially and progressed to  $18^\circ$  to  $23^\circ$  over 3 to 6 years.

An interesting concept of spinal column buckling was developed, in which rotation about one axis of the vertebral column was coupled with translation along a second axis.<sup>22-24</sup> Vertebral rotation

would then be the primary, not the secondary, deformity of idiopathic scoliosis. Similarly, lateral spondylolisthesis in idiopathic lumbar scoliosis is not 'true' spondylolisthesis and is due to rotation of the lumbar vertebrae.<sup>25</sup> As for the *de novo* degenerative lumbar scoliosis, increased lateral spondylolisthesis is associated with increased intervertebral rotation.<sup>26</sup> In a retrospective study on the natural course of progressive adult scoliosis,<sup>11</sup> rotatory subluxation seems to be the initial event in *de novo* degenerative lumbar scoliosis, whereas it also occurs during progression in adolescent-onset scoliosis in adults.

Therefore, rotational instability plays an essential role in degenerative lumbar scoliosis, and shares a similar pathogenesis to idiopathic scoliosis. Apical vertebral rotation may help predict the scoliosis progression and determine the timing of surgical intervention in patients with early degenerative lumbar scoliosis (not responding to conservative therapy).

One limitation to our study was that scoliosis may increase during the day, and there was no control on how long patients were upright before radiographic examinations. The follow-up period varied from 10 to 18 years, although there was no correlation between the follow-up period and scoliosis progression. A lack of yearly radiography may have affected the results (e.g. scoliosis remained stable for  $>10$  years and then rapidly deteriorated over a few years). The extent of apical vertebral rotation should have been more quantitatively evaluated using the torsion meter<sup>27</sup> or computed tomography. The sample size was small and hence statistical power may be inadequate; some significant factors predictive of scoliosis progression in addition to apical vertebral rotation may have been missed.

## ACKNOWLEDGMENTS

We thank Ms N Kumagai from Clinical Research Center, Kochi Medical School Hospital for statistical assistance.

## REFERENCES

1. Germeaux V, Casillas JM, Fabbro-Peray P, Pelissier J, Herisson C, Perennou D. Analysis of low back pain in adults with scoliosis. *Spine (Phila Pa 1976)* 2008;33:402–5.
2. Cho KJ, Suk SI, Park SR, Kim JH, Kim SS, Choi WK, et al. Complications in posterior fusion and instrumentation for degenerative lumbar scoliosis. *Spine (Phila Pa 1976)* 2007;32:2232–7.
3. Ploumis A, Transfeldt EE, Denis F. Degenerative lumbar scoliosis associated with spinal stenosis. *Spine J* 2007;7:428–36.
4. Simmons ED. Surgical treatment of patients with lumbar spinal stenosis with associated scoliosis. *Clin Orthop Relat Res* 2001;384:45–53.
5. Tribus CB. Degenerative lumbar scoliosis: evaluation and management. *J Am Acad Orthop Surg* 2003;11:174–83.
6. Akbarnia BA, Ogilvie JW, Hammerberg KW. Debate: degenerative scoliosis: to operate or not to operate. *Spine (Phila Pa 1976)* 2006;31(19 Suppl):S195–201.
7. Brooks HL, Azen SP, Gerberg E, Brooks R, Chan L. Scoliosis: a prospective epidemiological study. *J Bone Joint Surg Am* 1975;57:968–72.
8. Schwab FJ, Smith VA, Biserni M, Gamez L, Farcy JP, Pagala M. Adult scoliosis: a quantitative radiographic and clinical analysis. *Spine (Phila Pa 1976)* 2002;27:387–92.
9. Schwab F, el-Fegoun AB, Gamez L, Goodman H, Farcy JP. A lumbar classification of scoliosis in the adult patient: preliminary approach. *Spine (Phila Pa 1976)* 2005;30:1670–3.
10. Oskouiian RJ Jr, Shaffrey CI. Degenerative lumbar scoliosis. *Neurosurg Clin N Am* 2006;17:299–315.
11. Marty-Poumarat C, Scattin L, Marpeau M, Garreau de Loubresse C, Aegerter P. Natural history of progressive adult scoliosis. *Spine (Phila Pa 1976)* 2007;32:1227–35.
12. Pritchett JW, Bortel DT. Degenerative symptomatic lumbar scoliosis. *Spine (Phila Pa 1976)* 1993;18:700–3.
13. Korovessis P, Piperos G, Sidiropoulos P, Dimas A. Adult idiopathic lumbar scoliosis. A formula for prediction of progression and review of the literature. *Spine (Phila Pa 1976)* 1994;19:1926–32.
14. Sapkas G, Efstathiou P, Badekas AT, Antoniadis A, Kyrtzoulis J, Meleteas E. Radiological parameters associated with the evolution of degenerative scoliosis. *Bull Hosp Jt Dis* 1996;55:40–5.
15. Nash CL Jr, Moe JH. A study of vertebral rotation. *J Bone Joint Surg Am* 1969;51:223–9.
16. Inoue T, Kusida K, Miyamoto S, Sumi Y, Orimo H, Yamashita G. Quantitative assessment of bone density on X-ray picture. *Nippon Seikeigeka Gakkai Zasshi* 1983;57:1923–36.
17. Yamauchi Y, Yamaguchi T, Asaka Y. Prediction of curve progression in idiopathic scoliosis based on initial roentgenograms. A proposal of an equation. *Spine (Phila Pa 1976)* 1988;13:1258–61.
18. Vanderpool DW, James JJ, Wynne-Davies R. Scoliosis in the elderly. *J Bone Joint Surg Am* 1969;51:446–55.
19. Velis KP, Healey JH, Schneider R. Osteoporosis in unstable adult scoliosis. *Clin Orthop Relat Res* 1988;237:132–41.
20. Robin GC, Span Y, Steinberg R, Makin M, Menczel J. Scoliosis in the elderly: a follow-up study. *Spine (Phila Pa 1976)* 1982;7:355–9.
21. Shiraishi H, Kumon H. The retrospective study of progression in idiopathic scoliosis: the factor of intervertebral wedging [in Japanese]. *Rinsho Seikeigeka* 1982;17:125–9.
22. Dickson RA, Lawton JO, Butt WP. The pathogenesis of idiopathic scoliosis. In: Dickson RA, Bradford DS, editors. *Management of spinal deformities*. London: Butterworths; 1984:1–37.
23. Dickson RA, Archer IA. The biomechanics of spinal deformity. *J Bone Joint Surg Br* 1986;68:682.
24. Dickson RA. The aetiology of spinal deformities. *Lancet* 1988;1:1151–5.
25. Velis KP, Throne RP. Lateral spondylolisthesis in idiopathic scoliosis. *Orthop Trans* 1979;3:282–6.
26. Ploumis A, Transfeldt EE, Gilbert TJ Jr, Mehbod AA, Dykes DC, Perra JE. Degenerative lumbar scoliosis: radiographic correlation of lateral rotatoryolisthesis with neural canal dimensions. *Spine (Phila Pa 1976)* 2006;31:2353–8.
27. Perdriolle R, Vidal J. Thoracic idiopathic scoliosis curve evolution and prognosis. *Spine (Phila Pa 1976)* 1985;10:785–91.



研究成果の刊行に関する一覧表  
【H21. 4. 1～H24. 3. 31】

書籍

著者氏名	論文タイトル名	書籍全体の編集者名	書籍名	出版社名	出版地	出版年	ページ

雑誌

発表者氏名	論文タイトル名	発表誌名	巻号	ページ	出版年
渡辺航太, 千葉一裕.	透析患者さんと腰椎疾患 - 腰部脊柱管狭窄症と破壊性脊椎関節症 -	腎不全を生きる	42	42-49	2010
渡辺航太, 戸山芳昭, 千葉一裕, 松本守雄.	脊柱管狭窄症に対する棘突起縦割式椎弓切除術.	OS NOW Instruction		17-27	2011
渡辺航太, 戸山芳昭, 千葉一裕, 松本守雄.	腰部脊柱管狭窄症に対する腰椎棘突起縦割式椎弓切除術の有効性.	別冊 整形外科59 運動器疾患に対する最小侵襲手術.	59	103-107	2011
渡辺航太, 千葉一裕.	腰椎棘突起縦割式椎弓切除術.	臨床整形外科		507-13	2011
渡辺航太, 戸山芳昭, 千葉一裕, 松本守雄.	腰部脊柱管狭窄症に対する低侵襲除圧術の問題点とその対策.	整形・災害外科. [特集].	54(9)	1059-65	2011
石井賢, 千葉一裕.	内科医のための腰部脊柱管狭窄症の必須知識 2. 保存的治療: プライマリ・ケア医としての薬物療法.	Modern Physician.		1063-6	2011
渡辺航太, 細金直文, 辻崇, 石井賢, 中村雅也, 千葉一裕, 戸山芳昭, 松本守雄.	腰椎変性すべり症に対する棘突起縦割式椎弓切除術の治療成績.	東日本整形災害外科学会雑誌	23(1)	9-14	2011

Matsumoto M, Watanabe K, Tsuji T, Ishii K, Takaiishi H, Nakamura M, Toyama Y, Chiba K, Michikawa T, Nishiwaki Y.	Nocturnal leg cramps: a common complaint in patients with lumbar spinal canal stenosis.	Spine (Philadelphia 1976)	34-5	E189-94.	2009
Watanabe K, Matsumoto M, Ikegami T, Nishiwaki Y, Tsuji T, Ishii K, Ogawa Y, Takaiishi H, Nakamura M, Toyama Y, Chiba K.	Reduced postoperative wound pain after lumbar spinous process-splitting laminectomy for lumbar canal stenosis: a randomized controlled study.	Journal of Neurosurgery: Spine.	14(1)	51-8	2011
Miyamoto M, Fukui M, Kanamori M, Chiba K, Kawakami M, Nakai S, Shimamura T, Taguchi T, Takeshita K, Tanaka Y, Taniguchi T, Wada E, Yonenobu K.	Japanese orthopaedic association back pain evaluation questionnaire (JOABPEQ): an association study in patients with lumbar disc herniation and lumbar spinal canal stenosis.	Journal of Spine Research.	2(2)	278-81	2011
Cui G, Watanabe K, Miyauchi Y, Hosogane N, Tsuji T, Ishii K, Nakamura M, Toyama Y, Chiba K, Miyamoto T, Matsumoto M.	Matrix metalloproteinase 13 in the ligamentum flavum from lumbar spinal canal stenosis patients with and without diabetes mellitus.	Journal of Orthopaedic Science.	16	785-90.	2011

# 透析患者さんと腰椎疾患

—腰部脊柱管狭窄症と破壊性脊椎関節症—

渡辺 航太 千葉 一裕\*

慶應義塾大学医学部 整形外科教室 先進脊椎脊髄病治療学・医師

\*同 整形外科・医師

36-2 患者さんのための  
腎臓病学入門講座

はじめに

長い期間透析を受けている患者さんは、さまざまな合併症を起こしますが、その中でも、背骨の合併症は生活の質の低下を招く可

能性が高い重大な疾患です。ここではその中でも、多くの人にみられる透析アミロイドーシスが原因となる腰椎（背骨の腰の部分）の合併症、

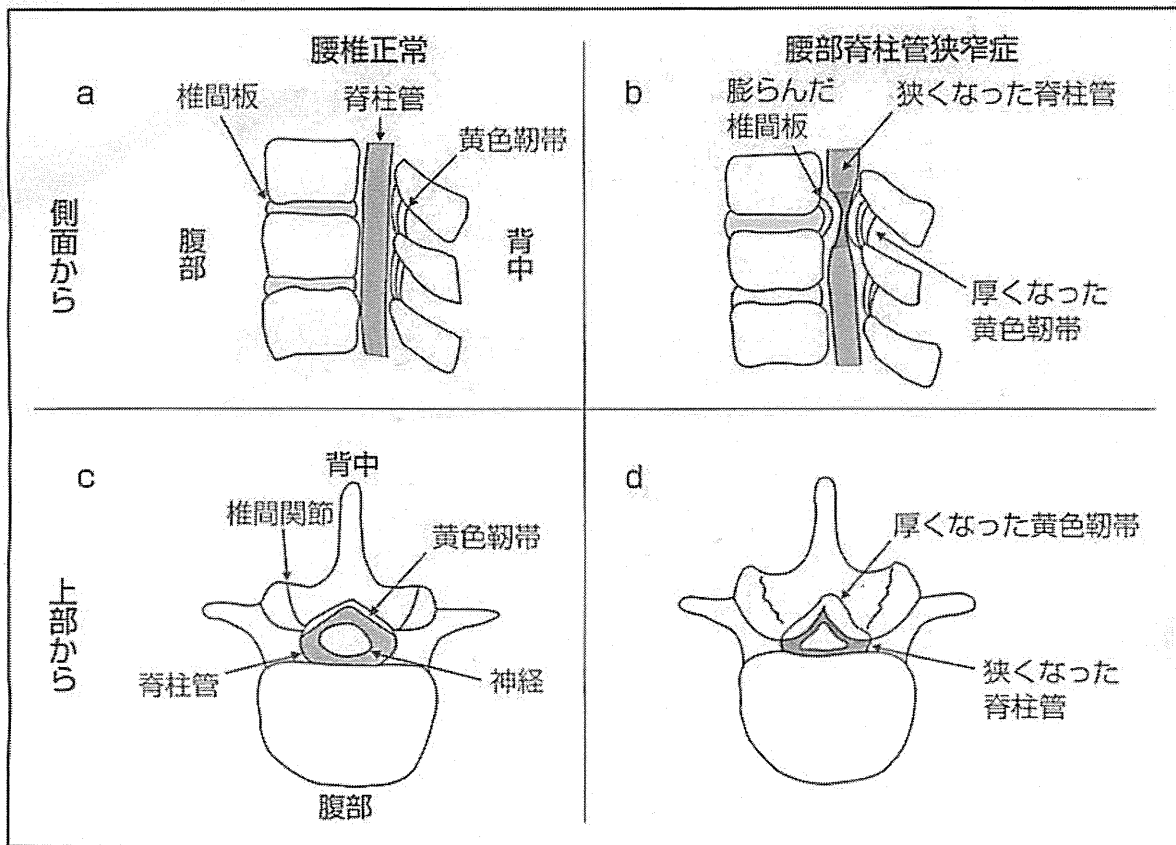


図1 腰部脊柱管狭窄症

厚くなった黄色靱帯、膨らんだ椎間板によって、複数の場所で脊柱管が狭くなり、その結果、脊柱管内を通る神経組織が圧迫されて、腰部脊柱管狭窄症を引き起こします (b, d)。

①腰部脊柱管狭窄症 (図 1)

②破壊性脊椎関節症 (図 2)

の病気の状態と治療について説明します。

### 原因としての透析アミロイドーシス

腰部脊柱管狭窄症と破壊性脊椎関節症は、透析アミロイドーシスが一因といわれています。透析アミロイドーシスでは、主にリンパ球で作られた $\beta_2$ -マイクログロブリンというタンパク質の血液中の濃度が上昇します。通常、この $\beta_2$ -マイクログロブリンは腎臓で濾過されて分解されますが、透析患者さん

では、腎臓の働きがないために血液中の濃度が上昇するのです。そして、この $\beta_2$ -マイクログロブリンが、最終的にアミロイドというタンパク質として骨関節組織にくっついて炎症を引き起こすことから、靭帯が厚くなったり、骨や関節の破壊を引き起こします<sup>3)</sup>。

透析アミロイドーシスにより生じる骨・関節の合併症は、

①腰部脊柱管狭窄症

②破壊性脊椎関節症

の他に、

③手根管症候群

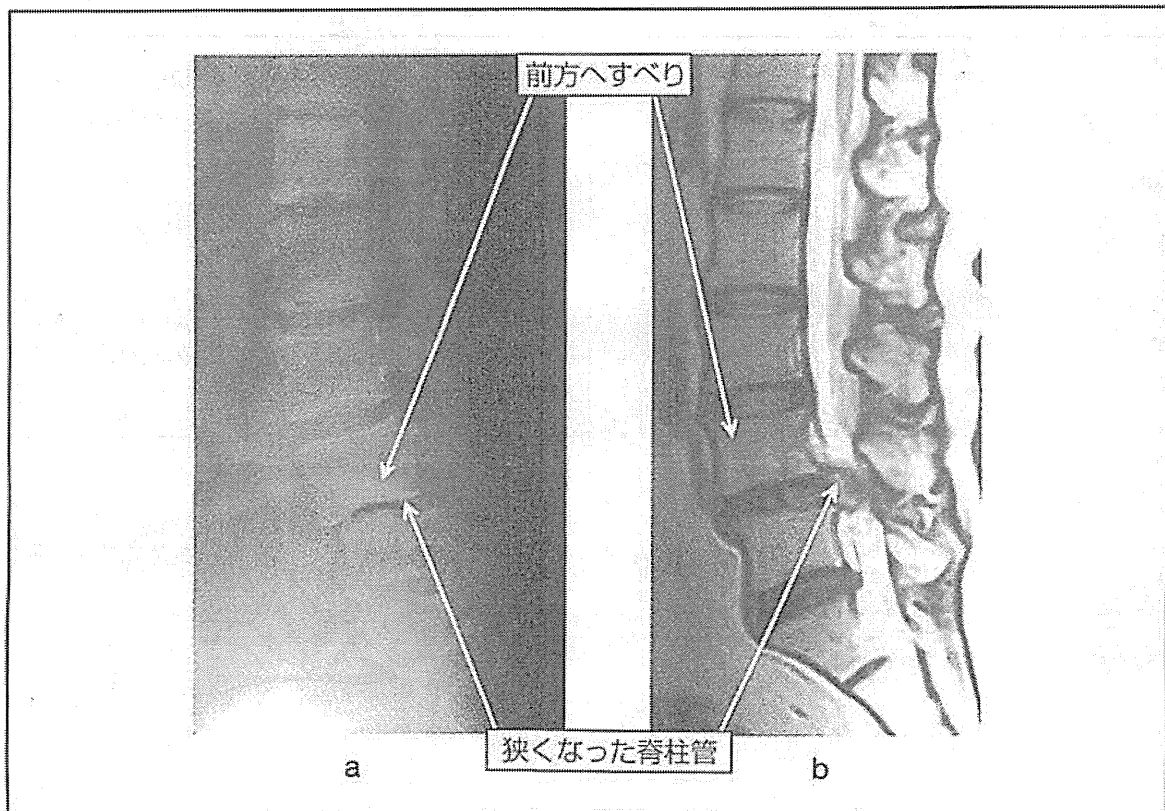


図 2 破壊性脊椎関節症

a : レントゲン側面像 第 4 腰椎と第 5 腰椎間の椎間板が狭く小さくなったことが確認できます。そして、同じ場所において第 4 腰椎の前方へのすべりがあります。b : MRI 矢状断像 第 4 椎体と 5 椎体の間で著しく脊柱管が狭くなっています。

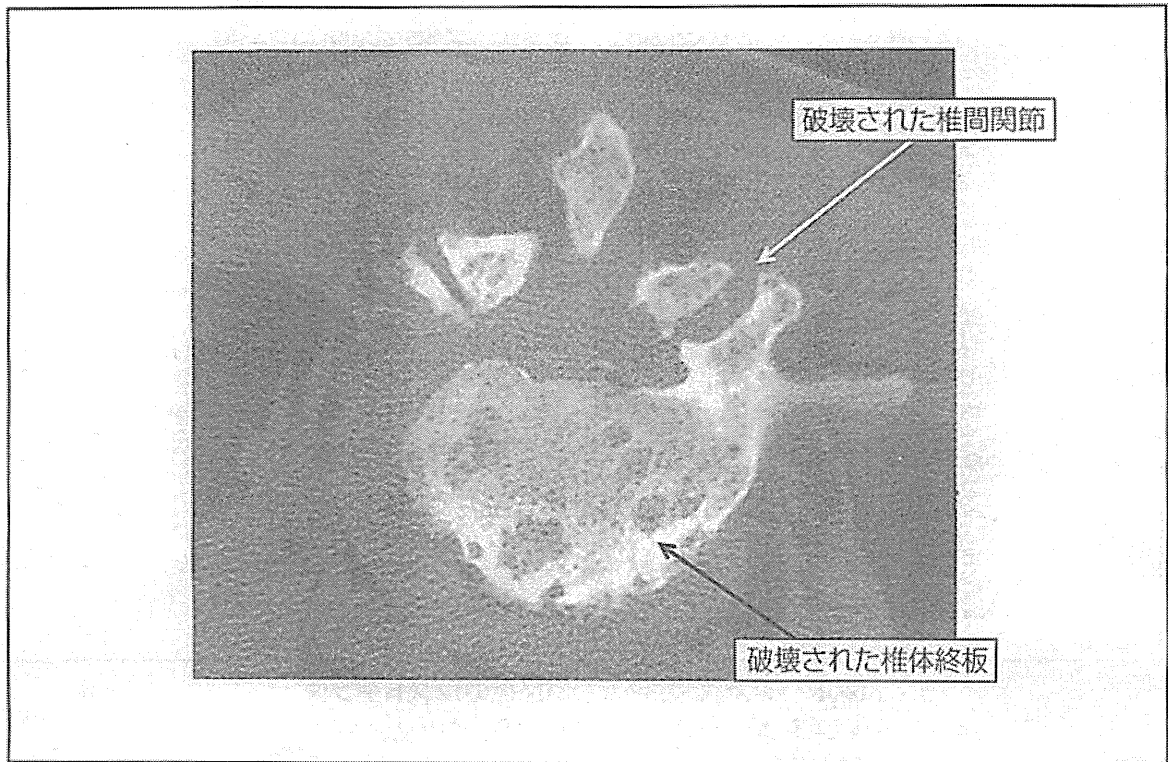


図3 破壊性脊椎関節症のCT（水平断像）  
破壊された椎体終板と椎間関節があります。

④破壊性関節症<sup>はかいせいかんせつしょう</sup>

⑤弾発指<sup>ばねゆび</sup>

⑥病的骨折

などがあります。これらの合併症は透析年数が長くなるにつれて増える傾向にあり、4～7年で50%、13年以上で100%の患者さんが透析アミロイドーシスを発症するといわれています<sup>1)</sup>。

腰部脊柱管狭窄症とは

腰部脊柱管狭窄症とは、下半身や脚に行く神経組織の通り道である腰椎の脊柱管がさまざまな原因によって狭くなり、下肢の痛み・しびれ、腰痛、筋力低下などの症状を引き起

こす疾患です。

特徴的な症状として、立ち続けたり歩いていると下肢の痛み・しびれや脱力が強くなり、それ以上立っていられなくなる、あるいは歩けなくなるが、短時間前かがみで休むと症状が楽になり再び立ったり歩いたりできるようになる「間欠跛行」<sup>かんけつぱこう</sup>がよく知られています。長期透析患者さんでは、後縦靭帯<sup>こうじゅうじんたい</sup>、黄色靭帯<sup>おうしょくじんたい</sup>、硬膜外腔<sup>こうまくがいこう</sup>や椎間板<sup>ついかんばん</sup>にアミロイドがくっついて、そこで生じる炎症反応によって上記の靭帯や椎間板などの結合組織が増えて大きくなり、脊柱管が狭くなります（図1）。その結果、脊柱管内を通る神経組織が圧迫されて、腰部脊柱管狭窄症を引き起こすので