

Table 2. Multivariate-adjusted odds ratios for the new onset of low back pain with work disability

Factors	Adjusted OR ^a	95%CI
Previous episodes of low back pain		
No	1.00	
Yes	3.25	1.53-6.91
Lifting		
Not frequent	1.00	
Frequent	3.77	1.16-12.3
Monotonous work		
Not monotonous	1.00	
Monotonous	2.21	0.99-4.94
Interpersonal stress at work		
No stress	1.00	
Stress	2.42	1.08-5.43

OR: Odds ratio, CI: Confidence interval

^a Adjusted for previous episodes of low back pain, lifting, monotonous work, interpersonal stress at work, age and gender.

分子リウマチ治療

別刷

発行：株式会社 先端医学社
〒103-0007 東京都中央区日本橋浜町 2-17-8 KDX 浜町ビル

運動器疾患における神経障害性疼痛

竹下克志

TAKESHITA Katsushi

東京大学大学院医学系研究科整形外科学

Key Words ▶▶▶▶ ■ 神経障害性疼痛 ■ 中枢性感作 ■ 変形性関節症 ■ 後縦靭帯骨化症
■ プレガバリン

神経障害性疼痛は国際疼痛学会で「体性感覚系に対する損傷や疾患の直接的結果として生じている疼痛」と定義され、痛覚過敏やアロディニアを特徴とする非ステロイド性抗炎症薬抵抗性の痛みである。神経根症など脊椎疾患の多くにみられ、四肢運動器の障害においても生じている可能性がある。

■ はじめに—神経障害性疼痛とは？—

現在、痛みは①侵害受容性疼痛、②神経障害性疼痛、③心因性疼痛（または機能的疼痛）に分類される。①の侵害受容性疼痛は、痛み情報が皮膚などの侵害受容器から脊髄後角を経て外側視床路を通る上向路を中心とした、生体へのさまざまな有害な外的侵襲に対する生理的反応である。また、③の心因性疼痛は身体表現性疼痛とほぼ同義で、身体の障害から予測される痛みをはるかに超える痛みがあり、心理的要因が原因の過半であると診断された場合に用いられる。

神経障害性疼痛は知覚神経の障害による痛みであり、痛覚過敏や通常は痛くない程度の刺激を痛みと感じるアロディニア、神経障害で妥当と思われる部位への電撃痛や刺すような痛み、焼けるような痛みなどを特徴とする。末梢から脊髄後角そして脳に至る感覚神経系のさまざまなレベルで生じると想定されており、国際疼痛学会（International Association for the Study of Pain：IASP）において「体性感覚系に対する損傷や疾患の直接的結果

として生じている疼痛¹⁾と定義されている。診断ではIASPから診断アルゴリズム²⁾が提唱され、スクリーニングとして神経障害性疼痛用調査票が各国で作成されている。われわれはpainDETECT³⁾を用いている。ただ、臨床では侵害受容性疼痛と神経障害性疼痛が併発している場合が多い。また痛み刺激は内側脊髄視床路を通り前帯状回や扁桃体に至る痛みの情動系も賦活化するため、抑うつや不安といった情動障害が起こりやすい。すなわち、上記3種類の痛みはほとんどの臨床例でオーバーラップして表出されていることを認識する必要がある。治療の観点からは各種薬剤の効果が異なることが重要であり、侵害受容性疼痛では非ステロイド性抗炎症薬（non-steroidal anti-inflammatory drugs：NSAIDs）が比較的有効であるが、神経障害性疼痛ではNSAIDsの効果はきわめて限定的であり、抗けいれん薬や抗うつ薬が有効である。

神経障害性疼痛用調査票を用いた疫学調査では一般人の7～8%⁴⁾に神経障害性疼痛がある。また、運動器疾患を担当する整形外科の慢性疼痛外来患者の39～43%⁵⁾に

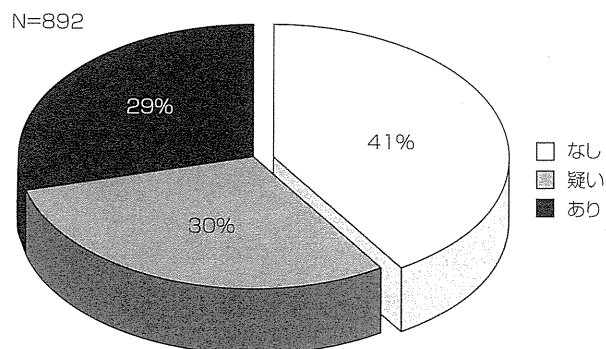
みられるとされる。外傷や腫瘍性疾患などでも神経障害性疼痛の関与はあると思われるが、本稿では脊椎と四肢変性疾患について触れる。

1. 脊椎変性疾患における神経障害性疼痛

脊椎症において神経障害は以前から脊椎疾患の主たる課題である。ただし運動障害すなわち麻痺に大部分の関心が注がれてきた点は否めない。欧州の腰痛患者に対する調査では25~30%に神経障害性疼痛の関与があると報告されている⁹⁾。われわれが厚生労働省研究班でおこなった2010年の頸椎後縦靭帯骨化症に対する調査では神経障害性疼痛のある患者が29.8%を占め、疑いを含むと6割にみられた(図①)。また2011年におこなった腰部脊柱管狭窄症に対する調査では神経障害性疼痛のある患者が13.8%、疑いを含むと5割にみられた。

神経障害性疼痛の代表としては腰椎椎間板ヘルニアにみられる腰部神経根症(根性坐骨神経痛)や変形性頸椎症に伴う頸部神経根症がある。いずれも強烈な痛みを起こしうる病態であり、即効的な疼痛緩和には大量ステロイドの短期内服やブロック治療が望ましい。より有害事象の少ない治療として2010年から使用可能となったプレガバリンがよい。ただし、めまいやふらつきが一時的に出現することが多いため、処方開始時からすぐに有効量を投与することはむずかしい。運動障害が高度あるいは進行する例や、上記保存治療で痛みを緩和できない場合には圧迫部位の解除すなわち除圧手術が必要である。プレガバリンはきわめて有効な場合があり、手術が回避できた例がしばしばある。

また、手術で圧迫を解除しても神経障害性疼痛が治癒しない場合も少なくない。われわれが2007年におこなった調査では脊椎手術を受けた患者においても2割程度の患者は日常生活に支障をきたすような痛みが残存していた¹⁰⁾。また腰部脊柱管狭窄症後の足底部のしびれが残りやすいことが知られており、治療満足度にも影響する¹¹⁾。腰椎椎間板ヘルニアの術後にプレガバリンを投与すると残存する痛みが緩和され治療成績が向上した報告があり¹²⁾、手術治療をおこなう患者でも神経障害性疼痛を意識して治療に臨む必要がある。



図① 後縦靭帯骨化症の神経障害性疼痛

2. 変形性関節症における神経障害性疼痛

四肢の変形性関節症(osteoarthritis: OA)における痛みの主体は何であろうか? 変性は関節軟骨の変性、磨耗からはじまるとされているが、神経終末がないため正常軟骨に痛みが生じることはない。軟骨変性から軟骨下骨の障害、それに引きつづいて生じる骨棘形成や滑膜炎が原因とされる侵害受容性疼痛と考えられており、病期によっては炎症性疼痛が主体となる。しかし近年、侵害受容性疼痛と炎症性疼痛のみではなく、神経障害性疼痛の関与があることがしだいに明らかになってきた。関節組織が障害を受けると、マクロファージやリンパ球などから各種 nerve growth factor やサイトカインが放出され、神経終末の刺激に対する閾値を低下させる。こうした、いわゆる末梢性感作が脊髄後角にある痛み伝播を増幅させ修飾させると中枢性感作が生じ⁶⁾、さらに痛みにも病的に敏感な状態、すなわち神経障害性疼痛となる。高齢者の膝 OA に対する調査票の研究では28%に神経障害性疼痛の要素があったとされる⁷⁾。また、Caチャンネル $\alpha_2\delta$ サブユニットをブロックするプレガバリンは三環系抗うつ薬とならんで神経障害性疼痛の第一選択薬であるが、人工膝関節手術の術後投与によって痛みが緩和され治療成績が向上したことがランダム比較試験で示されている⁸⁾。このように神経障害性疼痛は四肢関節変性疾患においても重要な病態であると認識されはじめています。

おわりに

神経障害性疼痛の代表的な疾患は線維筋痛症や複合性

局所疼痛症候群，脊髄障害性疼痛症候群であるが，運動器疾患に広くみられる病態である可能性が高くなっている。今後，運動器疾患の診療においては神経障害性疼痛を念頭に置いてあたる必要があるだろう。

文献

- 1) Loeser JD *et al* : The Kyoto protocol of IASP Basic Pain Terminology. *Pain* **137** : 473-477, 2008
- 2) Treede RD *et al* : Neuropathic pain : redefinition and a grading system for clinical and research purposes. *Neurology* **70** : 1630-1635, 2008
- 3) 住谷昌彦ほか : 痛みのマネジメント—痛みの分類と神経障害性疼痛の定義・診断・治療について—, エルゼビア・ジャパン社, Excerpta Medica 2010, pp. 1-28
- 4) Bouhassira D *et al* : Prevalence of chronic pain with neuropathic characteristics in the general population. *Pain* **136** : 380-387, 2008
- 5) Jespersen A *et al* : Is neuropathic pain underdiagnosed in musculoskeletal pain conditions? The Danish PainDETECTive study. *Curr Med Res Opin* **26** : 2041-2045, 2010
- 6) Im HJ *et al* : Alteration of sensory neurons and spinal response to an experimental osteoarthritis pain model. *Arthritis Rheum* **62** : 2995-3005, 2010
- 7) Hochman JR *et al* : Neuropathic pain symptoms in a community knee OA cohort. *Osteoarthritis Cartilage* **19** : 647-654, 2011
- 8) Buvanendran A *et al* : Perioperative oral pregabalin reduces chronic pain after total knee arthroplasty : a prospective, randomized, controlled trial. *Anesth Analg* **110** : 199-207, 2010
- 9) Freynhagen R *et al* : The evaluation of neuropathic components in low back pain. *Curr Pain Headache Rep* **13** : 185-190, 2009
- 10) 藤原奈佳子ほか : 後縦靭帯骨化症の痛みとしびれの実態と痛みに影響する要因. 厚生労働省特定疾患対策研究平成19年度研究報告書 脊柱靭帯骨化症に関する調査研究, 2008, pp. 17-38
- 11) Hara N *et al* : Predictors of residual symptoms in lower extremities after decompression surgery on lumbar spinal stenosis. *Eur Spine J* **19** : 1849-1854, 2010
- 12) Burke SM *et al* : Perioperative pregabalin improves pain and functional outcomes 3 months after lumbar discectomy. *Anesth Analg* **110** : 1180-1185, 2010

Is a Right Pedicle Screw Always Away From the Aorta in Scoliosis?

Katsushi Takeshita, MD,* Toru Maruyama, MD,† Shurei Sugita, MD,* Yasushi Oshima, MD,* Jiro Morii, MD,* Hiroataka Chikuda, MD,* Takashi Ono, MD,* and Kozo Nakamura, MD*

Study Design. Retrospective analysis.

Objective. We evaluated the aorta safety in placement of a right pedicle screw in scoliotic patients.

Summary of Background Data. Past reports emphasized the aorta risk in placing pedicle screws on the concave left side in right thoracic scoliosis. However, risk on the right side has drawn limited interest.

Methods. Thirty-four scoliotic patients with an average age of 18.0 years were evaluated. The Cobb angle averaged $59.0^\circ \pm 14.0^\circ$. From computed tomographic data, we evaluated the aorta location relative to the spine at each level from T4 to L4 and simulated placement of a right pedicle screw with a direction different from the ideal trajectory. Sensitivity analysis was performed independently by variable direction errors and screw length: the maximum error of trajectory was set to 5° in the medial direction and to 5° , 10° , or 20° in the lateral direction, and a screw length was set at 40, 45 or 50 mm. We defined "aorta-at-risk" when a patient has some level where a simulated pedicle screw involves the aorta, and compared the curve characteristics (the apical vertebral translation, the Cobb angle and the Nash-Moe grade) between the aorta-at-risk cases and the aorta-no-risk cases.

Results. In left thoracic or lumbar curves, the aorta often resided in front of right pedicles at the periapical level. In a scenario of a simulated pedicle screw with a maximum error of 20° in the lateral direction and a screw length of 50 mm, the aorta was at risk in 7 (33%) of 21 left lumbar curves. Curve characteristics of the aorta-at-risk cases at L1 were a larger apical vertebral translation ($P = 0.003$), a larger Cobb angle ($P = 0.006$), and a larger Nash-Moe grade ($P = 0.017$) compared with those of the aorta-no-risk cases.

From the *Department of Orthopaedic Surgery, the University of Tokyo, Tokyo, Japan; †Department of Orthopaedic Surgery, the Saitama Medical Center, Saitama, Japan.

Acknowledgment date: April 7, 2010. First revision date: September 6, 2010. Second revision date: December 22, 2010. Acceptance date: January 8, 2011.

The manuscript submitted does not contain information about medical device(s)/drug(s).

No funds were received in support of this work. No benefits in any form have been or will be received from a commercial party related directly or indirectly to the subject of this manuscript.

Correspondence and reprint requests to Katsushi Takeshita, MD, Department of Orthopaedic Surgery, Faculty of Medicine, The University of Tokyo, 7-3-1, Hongo, Bunkyo-ku, Tokyo 113-8655, Japan; E-mail: Takeshita-ort@h.u-tokyo.ac.jp

DOI: 10.1097/BRS.0b013e31820f8e6b

Spine

Conclusion. Surgeons need to pay attention to the position of the aorta in placing a pedicle screw on the right at the periapical level of a left curve either in thoracic or lumbar spine.

Key words: scoliosis, aorta, pedicle, screw. **Spine 2011;36:E1519–E1524**

One of the disadvantages of a pedicle screw is the possibility of aorta involvement. The aorta is located on the left side of the thoracic spine and stays in front of the lumbar spine in normal subjects,¹ and past reports emphasized the aorta risk in placing a screw on the concave side, which is usually left in right thoracic scoliosis.^{2,3} On the contrary, risk on the right side in scoliosis has drawn limited interest. The purpose of this study was to evaluate the safety of the aorta in placement of a right pedicle screw in scoliosis surgery.

MATERIALS AND METHODS

A total of 34 patients with scoliosis were evaluated after excluding congenital scoliosis and soft-tissue related disease such as Marfan syndrome. The average age at a computed tomographic examination was 18.0 years (range = 10–30), and there were 4 males and 30 females. Scoliosis was idiopathic in 30 patients, Chiari-syrinx in 2, multiple epiphyseal dysplasia in 1, and Noonan syndrome in 1. There were 29 thoracic curves and 24 lumbar curves, and the Cobb angle averaged $59.0^\circ \pm 14.0^\circ$ (28° to 100° ; Table 1).

Computed tomography (CT) was taken for surgical planning with a thickness of 1.25 mm, and data were transferred to a personal computer for analysis (ExaView LITE; Ziosoft, Tokyo, Japan). In the thoracic spine, we selected the middle of the base of the right superior facet where a pedicle screw is placed as the point of origin of the coordinate system (Figure 1A). A line connecting both of the middle points of bases of the superior facets was defined as the X-axis. In the lumbar spine, we drew a line between both the medial edges of superior facets as the X-axis (Figure 1B). The Y-axis was drawn perpendicular to the X-axis starting from the dorsal edge of the right superior facet. In thoracic and lumbar spine, the angle formed by the Y-axis and a line connecting the origin and the center of the aorta was defined as the right pedicle-aorta angle, and length of a line connecting the origin and the edge of the aorta as the right pedicle-aorta distance. From the repeatability test in our

www.spinejournal.com E1519

Copyright © 2011 Lippincott Williams & Wilkins. Unauthorized reproduction of this article is prohibited.

TABLE 1. Properties of Scoliosis

ID	Diagnosis	Age (yr)	Sex	Th Side	Th Cobb (degrees)	Th Apex	L Side	L Cobb (degrees)	L Apex
8	idio	17	F	R	53	T9	n.d.	n.d.	n.d.
11	idio	19	F	R	63	T10	n.d.	n.d.	n.d.
12	idio	19	F	R	83	T9	n.d.	n.d.	n.d.
13	idio	20	F	R	51	T7	L	28	L1/2
14	idio	16	F	n.d.	n.d.	n.d.	R	50	L1
15	idio	19	F	R	57	T8	L	49	L2
19	idio	29	F	n.d.	n.d.	n.d.	L	71	L1
21	idio	12	F	R	87	T9/T10	n.d.	n.d.	n.d.
23	idio	17	F	R	57	T8	L	62	L2
24	Chiari	15	F	R	62	T4/T5	L	88	L1/2
26	idio	16	F	R	54	T7/T8	L	54	L2
27	idio	16	F	R	52	T8/T9	L	42	L2
28	idio	20	F	R	54	T7	L	37	L2
29	idio	18	M	R	50	T8/T9	L	31	L2
30	idio	18	F	R	58	T9	n.d.	n.d.	n.d.
32	idio	13	F	R	58	T8/T9	L	40	L2
33	idio	11	F	L	79	T5	R	100	L1
34	Chiari	12	M	R	52	T8/T9	L	65	L4
35	idio	29	F	R	54	T8	L	67	L2
37	idio	15	F	R	68	T9	n.d.	n.d.	n.d.
39	idio	19	F	R	57	T10	n.d.	n.d.	n.d.
40	idio	23	F	R	63	T9/T10	n.d.	n.d.	n.d.
41	idio	10	F	R	61	T10	L	35	L3
44	Noonan	23	F	R	78	T9	n.d.	n.d.	n.d.
46	idio	13	M	R	83	T9/T10	L	63	L2/3
48	MED	16	M	R	62	T9	L	42	L2/3
49	idio	21	F	n.d.	n.d.	n.d.	L	56	L1
50	idio	19	F	L	63	T5	R	64	T12
51	idio	17	F	R	66	T7	L	67	L1
53	idio	30	F	n.d.	n.d.	n.d.	L	55	L2
54	idio	13	F	R	57	T8	L	55	L2
56	idio	29	F	R	50	T7	L	55	L3
57	idio	16	F	R	58	T9	n.d.	n.d.	n.d.
58	idio	13	F	n.d.	n.d.	n.d.	L	60	L3

Dx indicates diagnosis of scoliosis; idio, idiopathic; L side, convex side of a lumbar curve; L Cobb, Cobb angle of a lumbar curve; L Apex, apex level of a lumbar curve; MED, multiple epiphyseal dysplasia; n.d., not deformed; T side, convex side of a thoracic curve; T Cobb, Cobb angle of a thoracic curve; T Apex, apex level of a thoracic curve.

previous study,⁴ interclass correlation coefficients were 0.922 to 0.957 in the intraobserver measurement and 0.896 to 0.929 (0.864–0.961) in the interobserver measurement.

We evaluated the location of the aorta relative to the spine at each level from T4 to L4 and simulated placement of a right pedicle screw with a direction different from the ideal

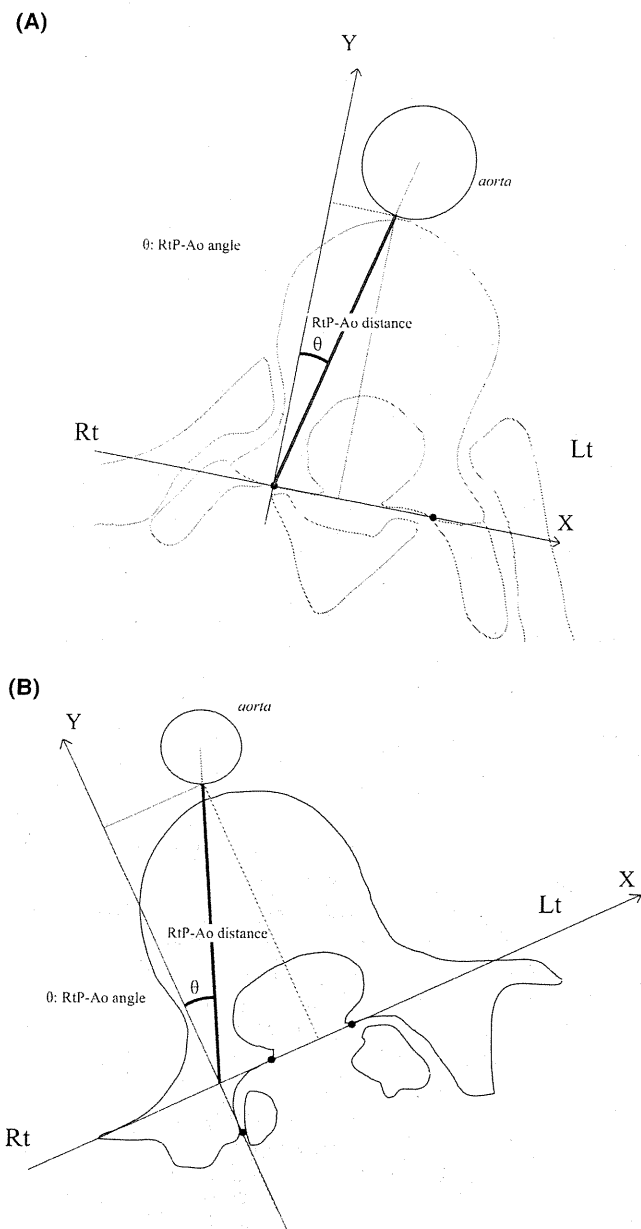


Figure 1. Measurement of two aorta parameters: right pedicle-aorta distance (Rt P-Ao distance) and right pedicle-aorta angle (Rt P-Ao angle). A, Schematic drawing in a thoracic curve. The origin was set at the middle point of the base of a right superior facet, and the X-axis was determined by connecting the middle point of the base of a left superior facet and the origin. B, Schematic drawing in a lumbar curve. The X-axis was determined first by connecting both the medial edges of the superior facets; the Y-axis was drawn perpendicular to the X-axis from the dorsal edge of a left superior facet, and the origin was determined.

trajectory. Sensitivity analysis was performed by variable direction errors and a screw length independently. We defined “aorta-at-risk” when a patient has some level where the simulated pedicle screw involves the aorta. As preliminary analysis had shown that the aorta-at-risk level was observed mostly in the lumbar spine, the maximum error of trajectory was set to

Spine

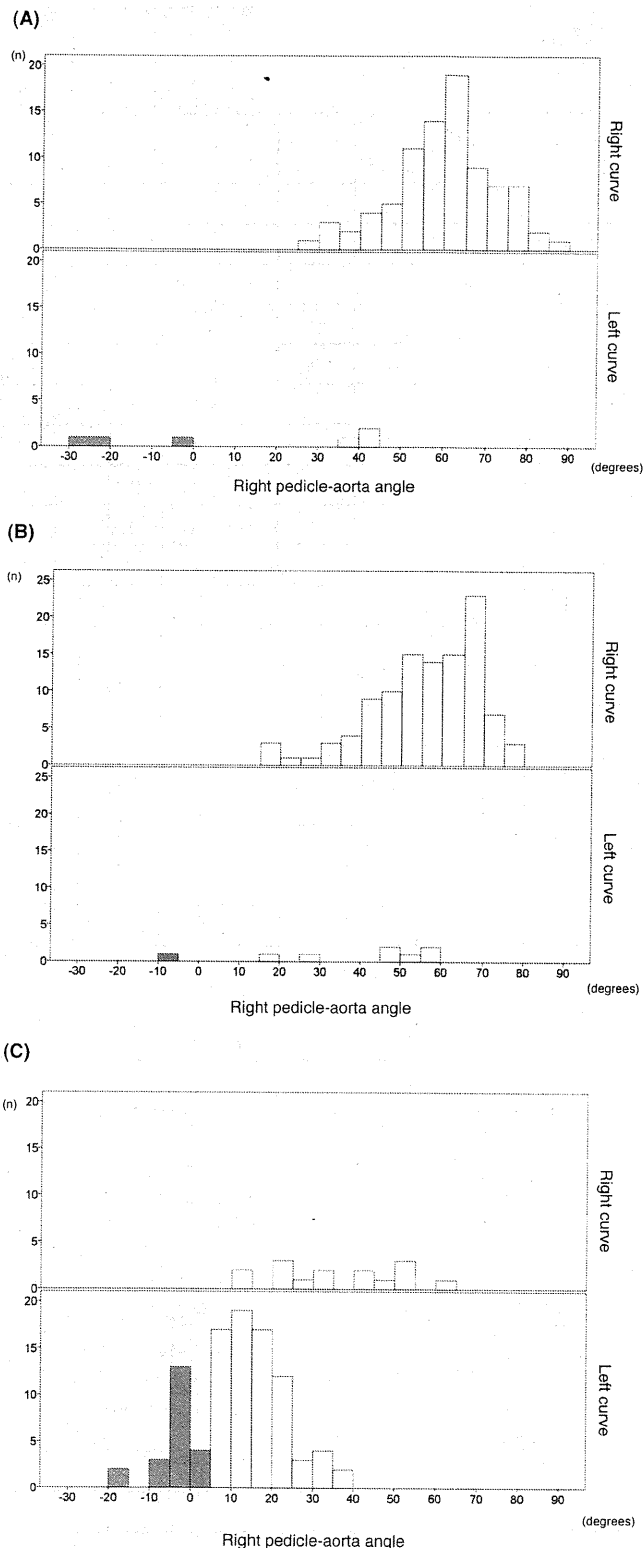


Figure 2. Distribution of right pedicle-aorta angles at 385-spine level. Bar is shaded if a right pedicle-aorta angle was below 5°. A, Histogram at T4 to T7. Upper: right curves, lower: left curves. B, Histogram at T8 to T11. Upper: right curves, lower: left curves. C, Histogram at T12 to L4. Upper: right curves, lower: left curves.

TABLE 2. Distribution of the Aorta-At-Risk Cases With Left Lumbar Curves in Simulated Scenarios

Angle (degree)	Length (mm)	Level	T4 to T11	T12	L1	L2	L3	L4
		Total	147	21	21	21	20	13
5	40	%	0	0	0	0	0	0
		No	0	0	0	0	0	0
5	45	%	0	0	14	5	0	0
		No	0	0	3	1	0	0
5	50	%	0	5	24	29	10	0
		No	0	1	5	6	2	0
10	40	%	0	0	0	0	0	0
		No	0	0	0	0	0	0
10	45	%	0	0	14	10	0	0
		No	0	0	3	2	0	0
10	50	%	0	5	29	33	10	0
		No	0	1	6	7	2	0
20	40	%	0	5	5	0	0	0
		No	0	1	1	0	0	0
20	45	%	0	5	19	10	0	0
		No	0	1	4	2	0	0
20	50	%	0	10	33	33	10	0
		No	0	2	7	7	2	0

The maximum error of medial trajectory of a pedicle screw was 5° in all scenarios.

Angle indicates the maximum error of lateral trajectory of a pedicle screw; Length, simulated screw length; No, number of the aorta-at-risk cases.

5° in the medial direction and to 5°, 10°, or 20° in the lateral direction, and the length of the screw was set at 40, 45 or 50 mm. We compared the curves between the aorta-at-risk cases and the aorta-no-risk cases. Analyzed curve characteristics were the apical vertebral translation (AVT), the Cobb angle and the Nash-Moe grade.

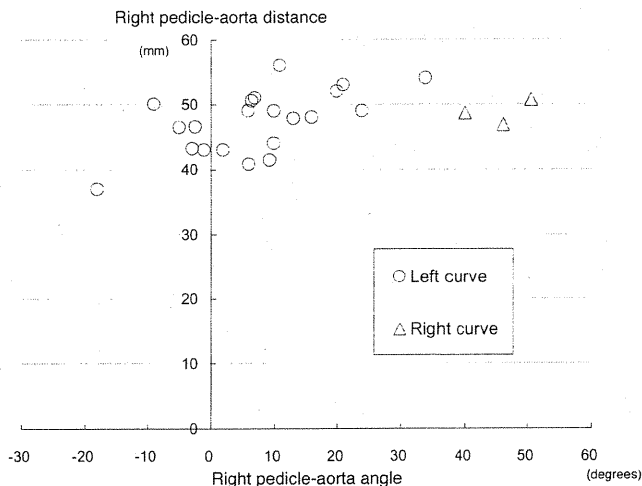


Figure 3. Scatter graph of the aorta location at 1st lumbar level. A circle denotes a case with a left lumbar curve and a triangle denotes a case with a right lumbar curve.

RESULTS

A total of 385 spines were evaluated to locate the aorta position relative to the spine. The aorta often resided in front of a right pedicle at periapical level in left curves (Figure 2). The number of levels where the right pedicle-aorta angle was below 5° was 1 of 2 left thoracic curves and 7 (33%) of 21 left lumbar curves (Table 2). On the contrary, there was no level where the right pedicle-aorta angle was below 5° in 27 right thoracic curves and in three right lumbar curves.

Distribution of the aorta-at-risk cases in nine simulated scenarios indicated that a simulated pedicle screw with a length of 50 mm at L1 or L2 posed potential risk (24%–44%) irrespective of trajectory errors among patients with left lumbar curves (Table 3). Curve characteristics of the aorta-at-risk cases at L1 (Figure 3) were a larger AVT ($P = 0.003$), a larger Cobb angle ($P = 0.006$), and larger Nash-Moe grade ($P = 0.017$) compared with those of the aorta-no-risk cases. AVT, the Cobb angle and Nash-Moe grade were highly correlated with each other: correlative coefficient was 0.814 ($P = 0.000$) between AVT and the Cobb angle, 0.737 ($P = 0.000$) between AVT and Nash-Moe grade, and 0.602 ($P = 0.004$) between the Cobb angle and Nash-Moe grade.

TABLE 3. Past Reports of Aortic Abutment by Thoracic Pedicle Screws Analyzed by Computed Tomography in Patients With Scoliosis

First Author	No. of patients	Follow-up Period (months)	No. of Pedicle Screws	No. of Screw with Aorta Abutment	Left /Right
Liljenqvist ⁶	32	na	110	1 (0.9%)	1/0
Smorgick ⁷	25	na	112	2 (1.8%)	2/0
Sarlak ⁸	19	35.9	185	7 (3.8%)	na*
Total	76		1442	13 (2.5%)	3/0

na indicates not available.

**Reported with convex/concave. One screw of 7 screws was at the convex side.*

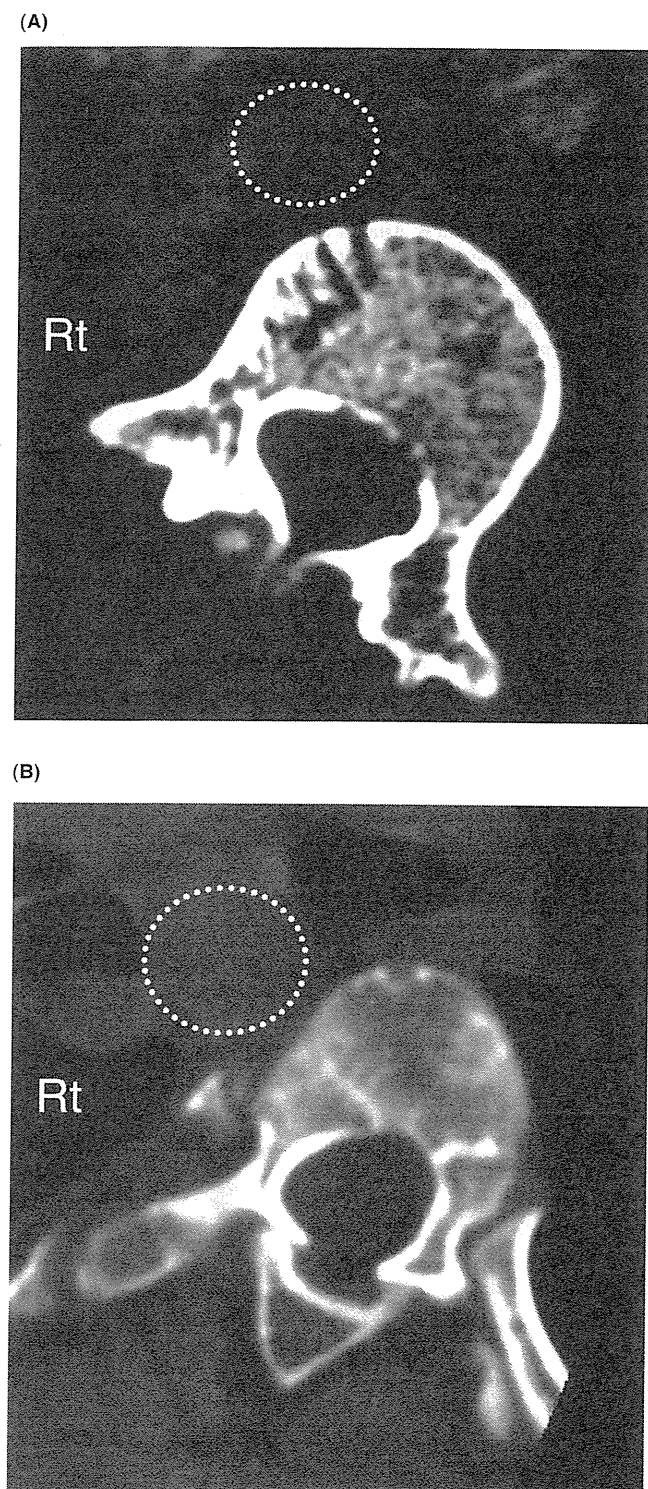


Figure 4. Representative cases in which the aorta resided laterally to the right of the spine. Dotted line circles the aorta. **A,** A 1st lumbar level in a left 88° lumbar curve. **B,** A 6th thoracic level in a left 100° thoracic curve.

DISCUSSION

We investigated lumbar curves in addition to thoracic curves, and found that the aorta moved to the right side of the

vertebral body in a left curve, and the safety of the aorta from a long pedicle screw decreased either in the thoracic spine or in the lumbar spine. In a case with a large left curve, the aorta shifted to the right lateral side of the vertebral body, and a lateral deviation from an ideal trajectory could result in aorta indentation even by a pedicle screw of a moderate length (Figure 4).

Many spine surgeons prefer to use pedicle screws in thoracic or lumbar spine because of its easiness of placement inside the bony structure and its sound capability in correction and stabilization. However, Kakkos and Shepard⁵ reviewed the delayed aorta injury by pedicle screws in five patients including three deformity cases. They stated, “The true incidence of this complication is probably under-reported” in their conclusion. We found three past studies,^{6–8} which analyzed thoracic curves exclusively by computed-tomography postoperatively (Table 3), and the aorta involvement in 6 (2.5%) of the 1442 screws is substantial. Though the true risk of aortic abutment is unknown, a screw will stay just next to the aorta in such a young generation and it is impractical to monitor such patients closely for over tens of years. In fact, 6 of 76 patients of the past three reports had reoperation.

The aorta resides on the left side of the normal thoracic spine,¹ and past reports dealt with a thoracic pedicle screw on the concave side which is usually the left side of the thoracic curve.^{2,3,7} In scoliosis, a three-dimensional spinal deformity changes the spatial relationship between the aorta and the spine depending on the severity of scoliosis, and the aorta might reside on the right side of a vertebral body. Only one past report by Milbrandt and Sucato⁹ discussed the aorta risk on the right side. They analyzed left thoracic scoliosis and stated “the aorta was in a high-risk position for a (right) posterior screw that exit the lateral border of the pedicle or body in the largest curve of our series.” Our present study confirmed the aorta risk by a right pedicle screw in left thoracic or lumbar scoliosis. We believe a deliberate planning by multiplanar reconstructed images of multidetector-CT is most crucial to prevent an annoying situation. Moreover, we prefer to use a computer-navigation system by preoperative CT for safe placement of pedicle screws.

Judging from high correlations between curve characteristics and the aorta risk in the present study, surgeons need to pay attention to the position of the aorta in placing a pedicle screw on the right in a left curve either in a thoracic or lumbar spine.

➤ Key Points:

- ❑ The aorta is often located in front of right pedicles at the periapical level in left thoracic or lumbar curves.
- ❑ Curve characteristics of the aorta-at-risk cases were a larger apical vertebral translation, a larger Cobb angle, and a larger Nash-Moe grade.
- ❑ Surgeons need to pay attention to the position of the aorta in placing a pedicle screw on the right at the periapical level of a left curve either in thoracic or lumbar spine.

References

1. Moore KL. The thoracic and abdominal aorta. In: Moore KL, ed. *Clinically Oriented Anatomy*. 6th ed. Baltimore, MD: Williams & Wilkins; 2010:167–313.
2. Sucato DJ, Duchene C. The position of the aorta relative to the spine: a comparison of patients with and without idiopathic scoliosis. *J Bone Joint Surg Am* 2003;85-A:1461–9.
3. Takeshita K, Maruyama T, Ono T, et al. New parameters to represent the position of the aorta relative to the spine for pedicle screw placement. *Eur Spine J* 2010;19:815–20.
4. Takeshita K, Maruyama T, Chikuda H, et al. Diameter, length, and direction of pedicle screws for scoliotic spine—analysis by multiplanar reconstruction of computed tomography. *Spine* 2009;34:798–803.
5. Kakkos SK, Shepard AD. Delayed presentation of aortic injury by pedicle screws: report of two cases and review of the literature. *J Vasc Surg* 2008;47:1074–82.
6. Liljenqvist UR, Halm HF, Link TM. Pedicle screw instrumentation of the thoracic spine in idiopathic scoliosis. *Spine* 1997;22:2239–45.
7. Smorgick Y, Millgram MA, Anekstein Y, et al. Accuracy and safety of thoracic pedicle screw placement in spinal deformities. *J Spinal Disord Tech* 2005;18:522–6.
8. Sarlak AY, Tosun B, Atmaca H, et al. Evaluation of thoracic pedicle screw placement in adolescent idiopathic scoliosis. *Eur Spine J* 2009;18:1892–7.
9. Milbrandt TA, Sucato DJ. The position of the aorta relative to the spine in patients with left thoracic scoliosis: a comparison with normal patients. *Spine* 2007;32:E348–53.

Acute Cervical Spinal Cord Injury Complicated by Preexisting Ossification of the Posterior Longitudinal Ligament

A Multicenter Study

Hirota Chikuda, MD, PhD,* Atsushi Seichi, MD, PhD,† Katsushi Takeshita, MD, PhD,*
Shunji Matsunaga, MD, PhD,‡ Masahiko Watanabe, MD, PhD,§ Yukihiro Nakagawa, MD, PhD,¶
Kazuya Oshima, MD, PhD,|| Yutaka Sasao, MD, PhD,** Yasuaki Tokuhashi, MD, PhD,††
Shinnosuke Nakahara, MD,‡‡ Kenji Endo, MD, PhD,§§ Kenzo Uchida, MD, PhD,¶¶ Masahiko Takahata, MD,|||
Toru Yokoyama, MD,*** Kei Yamada, MD, PhD,††† Yutaka Nohara, MD,‡‡‡ Shiro Imagama, MD,§§§
Hideo Hosoe, MD,¶¶¶ Hiroshi Ohtsu, MS,|||| Hiroshi Kawaguchi, MD, PhD,* Yoshiaki Toyama, MD, PhD,****
and Kozo Nakamura, MD, PhD,*

From the *Department of Orthopaedic Surgery, Faculty of Medicine, the University of Tokyo, Tokyo, Japan; †Department of Orthopaedics, Jichi Medical University, Tochigi, Japan; ‡Department of Orthopaedic Surgery, Imakiire General Hospital, Kagoshima, Japan; §Department of Orthopaedic Surgery, Surgical Science Tokai University School of Medicine, Kanagawa, Japan; ¶Department of Orthopaedic Surgery, Wakayama Medical University, Wakayama, Japan; ||Department of Orthopaedic Surgery, Osaka University Graduate School of Medicine, Osaka, Japan; **Department of Orthopaedic Surgery, St. Marianna School of Medicine, Kanagawa, Japan; ††Department of Orthopaedic Surgery, Nihon University School of Medicine, Tokyo, Japan; ‡‡Department of Orthopaedic Surgery, National Okayama Medical Center, Okayama, Japan; §§Department of Orthopaedic Surgery, Tokyo Medical University, Tokyo, Japan; ¶¶Department of Orthopaedics and Rehabilitation Medicine, Fukui University Faculty of Medical Sciences, Fukui, Japan; ||||Department of Orthopaedic Surgery, Graduate School of Medicine, Hokkaido University, Hokkaido, Japan; ***Department of Orthopaedics Surgery, Hirosaki University Graduate School of Medicine, Aomori, Japan; †††Department of Orthopaedic Surgery, Kurume University, Fukuoka, Japan; ‡‡‡Department of Orthopaedic Surgery, Dokkyo Medical University, Tochigi, Japan; §§§Department of Orthopaedic Surgery, Nagoya University Graduate School of Medicine, Aichi, Japan; ¶¶¶Department of Orthopaedic Surgery, Gifu University School of Medicine, Gifu, Japan; |||||Department of Clinical Trial Data Management, Graduate School of Medicine, the University of Tokyo, Tokyo, Japan; and ****Departments of Orthopaedic Surgery, School of Medicine, Keio University, Tokyo, Japan.

Acknowledgment date: March 30, 2010. Revision date: July 19, 2010. Acceptance date: July 20, 2010.

The manuscript submitted does not contain information about medical device(s)/drug(s).

No benefits in any form have been or will be received from a commercial party related directly or indirectly to the subject of this manuscript.

This study was performed with the aid of the Investigation Committee on the Ossification of the Spinal Ligaments of the Japanese Ministry of Health, Labor and Welfare.

Address correspondence and reprint requests to Hirota Chikuda, MD, PhD, Department of Orthopaedic Surgery, Faculty of Medicine, the University of Tokyo, 7-3-1 Hongo, Bunkyo-ku, Tokyo 113-8655, Japan; E-mail: chikuda-ky@umin.ac.jp

DOI: 10.1097/BRS.0b013e3181f49718

Spine

Copyright © 2011 Lippincott Williams & Wilkins. Unauthorized reproduction of this article is prohibited.

www.spinejournal.com 1453

Study Design. Retrospective multicenter study.

Objective. To review the clinical characteristics of traumatic cervical spinal cord injury (SCI) associated with ossification of the posterior longitudinal ligament (OPLL).

Summary of Background Data. Despite its potentially devastating consequences, there is a lack of information about acute cervical SCI complicated by OPLL.

Methods. This study included consecutive patients with acute traumatic cervical SCI (Frankel A, B, and C) who were admitted within 48 hours of injury to 34 spine institutions across Japan. For analysis of neurologic outcome, patients who had completed at least a 6-month follow-up were included. Neurologic improvement was defined as at least one grade conversion in Frankel grade.

Results. A total of 453 patients were identified (367 men, 86 women; mean age, 59 years). OPLL was found in 106 (23%) patients (87 men, 19 women; mean age, 66 years). Most of the patients with OPLL (94 of 106) were without bone injury, presenting with incomplete SCI. The prevalence of OPLL reached 34% in SCI without bone injury. The cause of SCI was predominantly falls (74%). Only 25% of the patients were aware of OPLL. Half of the OPLL patients reported gait disturbance before injury. Forty-eight (52%) OPLL patients without bone injury underwent surgery (median, 13.5 days after injury), mostly laminoplasty. Overall, no significant difference was noted in neurologic improvement between surgery group and conservative group. However, further stratification showed that surgery was associated with greater neurologic recovery in patients who had gait disturbance before injury ($P = 0.04$).

Conclusion. Prevalence of OPLL among cervical SCI was alarmingly high, especially in those without bone injury. Most of cervical SCI associated with OPLL were incomplete, without bone injury, and caused predominantly by low-energy trauma. The majority of the patients were unaware of OPLL. Surgery produced better neurologic recovery in patients who had gait disturbance before injury.

Key words: canal stenosis, myelopathy, ossification of the posterior longitudinal ligament, patient awareness, spinal cord injury, surgery, trauma, treatment. **Spine 2011;36:1453–1458**

ossification of the posterior longitudinal ligament (OPLL) affects about 2% of Japanese^{1,2} and is a major cause of cervical canal stenosis in Japan. Although individuals with OPLL often remain asymptomatic, chronic cord compression may lead to myelopathy, especially in those with severe canal compromise.

OPLL is also known to predispose these individuals to severe neurologic deterioration after trauma. Despite its potentially devastating consequences, there is a lack of information about acute cervical spinal cord injury (SCI) complicated by OPLL. Except for a few case series, reports on this subgroup of SCI patients remain largely anecdotal.^{3,4} The prevalence of OPLL among patients with acute cervical SCI has not been determined, and the clinical characteristics of SCI patients with OPLL remain unclear as well. In particular, little attention has been paid to a patient's status before injury such as his or her awareness of OPLL. In addition, optimum treatment of SCI complicated by OPLL remains controversial; a dilemma reflected by the wide variations in current treatment options, ranging from emergency surgery to conservative treatment. Although surgical decompression is widely believed to have a beneficial role for those with persistent cord compression, there is no comparative study supporting this hypothesis.

Here, we conducted a retrospective multicenter study to determine the prevalence of OPLL among cervical SCI and clarify the clinical characteristics of SCI patients with OPLL, and further evaluated the efficacy of surgical treatment.

MATERIALS AND METHODS

This multicenter study was conducted by a Research Group for Ossification of the Spinal Ligament sponsored by the Japanese Ministry of Health, Labor and Welfare. This study included all consecutive patients with acute traumatic cervical SCI (Frankel A, B, and C) who were admitted within 48 hours of injury from January 2000 to June 2006. Thirty-four institutions to which the members of the research group belong joined this study. Severity of SCI was assessed by Frankel grade classification.⁵ Presence of OPLL was confirmed using plain radiographs or computed tomography (CT). On the basis of the criteria established by the Japanese Ministry of Public Health and Welfare, OPLL was classified into the following types: continuous, segmental, localized, and mixed.⁶ The maximum percentage of spinal canal stenosis was evaluated using plain radiographs as previously reported.⁷

To assess patients' medical status at admission and complications after the injury, we consulted medical charts and nursing summaries. Complications that occurred within 1 month after injury were included in this study. The charts were also evaluated for patient status before injury including awareness of OPLL and preexisting gait disturbance. For analysis of neurologic recovery, patients who had completed a 6-month follow-up were included.

Neurologic improvement was defined as one grade or greater improvement in Frankel grade. The ratio of patients who achieved neurologic improvement was calculated. Patients were stratified by whether they had gait disturbance before injury.

Continuous variables were compared using Student *t* test or Dunnett test, and categorical data were analyzed using the χ^2 test. Fisher exact test was used when appropriate. All statistics were calculated using SPSS, version 13.0 (SPSS Inc, Chicago, IL). Values were considered statistically significant for *P* less than 0.05.

RESULTS

A total of 453 patients were initially identified (Table 1), including 367 men and 86 women with a mean age of 59 years. OPLL was found in 106 patients (87 men, 19 women; mean age: 66 years), accounting for 23% of all patients. Peak incidence of SCI in patients with OPLL occurred between 70 and 75 years of age, and about 80% of OPLL-associated SCI patients (85 of 106) were classified as incomplete. Of the 453 patients, 274 (60%) were without bone injury, such as fracture or dislocation, and nearly 90% of the patients with OPLL (94 of 106) were also without bone injury. The prevalence of OPLL was 34% among this subgroup of patients.

Clinical characteristics of SCI patients with OPLL were further examined (Table 2). The primary cause of SCI in OPLL patients was predominantly falls, followed by motor vehicle accidents. Influence of alcohol use was reported in 19 patients (18%). Of note, among patients who were aware of OPLL, only one was under the influence of alcohol at the time of injury. Concurrent fractures at other sites or visceral organ injuries were relatively rare in this subgroup of SCI patients. Only 25% of patients were aware of OPLL before their injury, and even fewer patients (17%) were regularly visiting a physician

TABLE 1. Characteristics of Enrolled Patients

	SCI With OPLL	SCI Without OPLL	Total
No. (% of total) of patients	106 (23%)	347	453
Sex (men/women)	87/19	280/67	367/86
Mean age at injury (yrs, mean \pm SD)	66.2 \pm 11.5*	57.0 \pm 18.6	59.2 \pm 17.6
Frankel grade at admission			
A	21	125	146
B	29	76	105
C	56	146	202
SCI without fracture or dislocation (%)	94 (34%)	180	274
*Between-group difference was significant (<i>P</i> < 0.01).			
SCI indicates spinal cord injury; OPLL, ossification of the posterior longitudinal ligament; SD, standard deviation.			

TABLE 2. Clinical Characteristics of SCI Patients With OPLL

	SCI Patients With OPLL (n = 106)
Cause of SCI	
Falling (% of total)	78 (74%)
Falling on one's rear	9
Falling on a flat surface	42
Falling down stairs	16
Falling from a height	11
Motor vehicle accident	19
Sports-related	3
Not specified	6
Alcohol involvement (% of total)	19 (18%)
Concurrent fracture at other site	4
Concurrent visceral organ injury	2
Awareness of OPLL before injury (% of total)	26 (25%)
Regular doctor visit for OPLL (% of total)	18 (17%)
Gait disturbance before injury (% of total)	47 (44%)
SCI indicates spinal cord injury; OPLL, ossification of the posterior longitudinal ligament.	

for OPLL at the time of injury. Approximately half of patients (44%) reported preexisting gait disturbance of varying degrees.

On radiographic evaluation, ossification type was found to be continuous in 46 patients, mixed in 38, segmental in 12, localized in 5, and unclassified in 5. Mean maximum percentage of spinal canal stenosis was $46 \pm 13\%$ (mean \pm SD; range: 19%–85%). No significant difference was noted in maximal canal compromise between Frankel grade groups at admission (Dunnnett test).

We also evaluated the use of corticosteroids for treatment of SCI. Of the 106 SCI patients with OPLL, 76 (72%) received intravenous administration of corticosteroids. The Second National Acute Spinal Cord Injury Study protocol⁸ was applied in 57 patients, whereas intermittent administration of a lower dosage was performed in the remaining 19. Complications associated with intravenous corticosteroid administration were reported in 10 patients, including gastrointestinal bleeding or ulcer in 6, pulmonary complications in 2, and wound infection and exacerbation of diabetes mellitus in 1 each.

We then examined the efficacy and safety of surgical treatment, focusing on patients without bone injury (Table 3). Of the 94 patients in this category, 48 (52%) underwent surgery (median: 13.5 days after injury) whereas the remaining 46 received some form of nonoperative treatment. Clinical characteristics of the two groups were comparable with regard to age, sex, maximum canal stenosis, and severity of SCI. Most of the surgery group patients (43 of 48) received laminoplasty.

TABLE 3. Characteristics and Complications* of OPLL Patients Without Bone Injury

	Surgery Group (n = 48)	Conservative Group (n = 46)
Age (yrs; mean [SD])	64 (10)	68 (13)
Sex (men/women)	38/10	40/6
Severity of SCI (no. of patients [%])		
Complete	8 (17)	8 (17)
Incomplete	40 (83)	38 (83)
Maximum canal stenosis (%; mean [SD])	46 (13)	46 (14)
Corticosteroid (no. of patients [%])	29 (60)	39 (85) [†]
Complications		
Tracheotomy	7 (15)	6 (13)
Pneumonia	9 (19)	11 (24)
Sepsis	2 (7)	3 (7)
Gastrointestinal bleeding	3 (6)	2 (4)
Urinary tract infection	8 (17)	13 (28)
Wound infection	3 (6)	2 (4)

*Complications occurring within 1 month of injury were included.

[†]significantly higher in conservative group ($P < 0.01$); continuous variables were compared using Student *t* test; categorical data were analyzed using Fischer exact test.

The conservative group was more likely to receive intravenous corticosteroids ($P < 0.01$). No significant difference was noted in documented complications between the surgery and conservative groups.

Neurologic improvement was then examined in patients who had completed at least 6 months of follow-up (Table 4). Overall, 72 of the 106 patients with OPLL underwent follow-up at 6 months postinjury. Of the 94 OPLL patients presented with SCI without bone injury, 64 (68%) were followed up for at least 6 months after injury (mean: 25 months; range: 6–27 months). Of these 64 patients, 41 showed neurologic recovery at follow-up, as defined by one grade or greater improvement in Frankel grade. No significant difference was noted in neurologic improvement between the surgery and conservative groups (surgery group: 71%, conservative group: 52%; $P = 0.13$).

We then stratified patients according to presence or absence of gait disturbance before injury (Table 5). In this preplanned analysis, surgery was associated with better neurologic recovery in those who had gait disturbance before injury (surgery group: 82%, conservative group: 44%; $P = 0.04$).

DISCUSSION

Our study had three major findings. First, we found an alarmingly high prevalence of OPLL among cervical SCI, particularly in those without bone injury. Second, we also identified

TABLE 4. Neurological Outcome of OPLL Patients Without Bone Injury*

Surgery (n = 41)						Conservative (n = 23)					
	Grade at follow-up						Grade at follow-up				
	A	B	C	D	E		A	B	C	D	E
Grade at admission						Grade at admission					
A	3	2	2			A	3			1	
B		3	5	4	1	B			1	2	
C		1	5	11	4	C		2	6	8	

Frankel grade was used as outcome measure.
*Patients who had completed at least 6 mo of follow-up were included.

the clinical characteristics of these patients: most of cervical SCI associated with OPLL were incomplete, without bone injury, and caused primarily by low-energy trauma. The vast majority of patients were elderly and unaware of OPLL. Last, we also found that surgery was associated with greater neurologic recovery than conservative treatment in patients who had gait disturbance before injury.

In this study, we focused on patients who had lost ambulatory ability immediately after injury (Frankel A, B, and C). From a practical point of view, traumatic SCI is intellectually indistinguishable from aggravation of preexisting myelopathy in individuals with OPLL, particularly when presented with mild

symptoms. Our sample of more than 100 patients with OPLL represents the largest study of its subject matter ever reported.

OPLL was found to be highly prevalent in patients with acute traumatic cervical SCI: in particular, OPLL was found in 34% of cervical SCI patients without bone injury. Our findings underscore the important role of OPLL in occurrence of acute traumatic cervical SCI. In line with our present finding, Koyanagi *et al*⁹ also previously reported that OPLL was highly prevalent (38%) in SCI patients without bone injury. The prevalence of OPLL among cervical SCI patients appears to be increasing because prevalence values reported in earlier studies have historically been less than 10%.^{3,10}

TABLE 5. Neurological Outcome of Patients Stratified by Presence of Gait Disturbance Before Injury*

Patients who had gait disturbance before injury (n = 31)											
Surgery (n = 19)						Conservative (n = 12)					
	Grade at follow-up						Grade at follow-up				
	A	B	C	D/E			A	B	C	D	
Grade at admission						Grade at admission					
A	3	1	1			A	2			1	
B		3	1	2		B				2	
C		1	1	6		C		2	2	3	

Patients without gait disturbance before injury (n = 31)											
Surgery (n = 22)						Conservative (n = 9)					
	Grade at follow-up						Grade at follow-up				
	A	B	C	D			A	B	C	D	
Grade at admission						Grade at admission					
A		1	1			A	1				
B			4	3		B			1		
C			4	9		C			4	3	

Frankel grade was used as outcome measure.
*Patients who had completed at least 6 mo of follow-up were included.

We also sought to clarify the clinical characteristics of SCI patients with OPLL. The majority of such patients were elderly with the peak incidence in those occurring between 70 and 75 years of age. Most of these patients were without bone injury and presented with incomplete SCI. Concomitant injuries were relatively rare, and the primary cause of SCI was minor trauma, such as a fall (74%). Patients suffered severe neurologic deficit after experiencing even subtle trauma such as falling from a standing height or falling onto one's rear, underscoring the fact that individuals with OPLL are extremely vulnerable to trauma.

Despite its potential role in preventing SCI, patient awareness of OPLL has not been fully investigated. We found that the vast majority of SCI patients with OPLL were unaware of OPLL before injury. An earlier study has suggested that once patients are made aware of OPLL and its potential risk, they are expected to more carefully avoid high-risk behaviors such as walking on a slippery slope or drinking too much alcohol.⁷ Indeed, in this study, SCI associated with alcohol ingestion was significantly decreased when patients had been made aware of OPLL. This finding underscores the importance of patient awareness and indicates the effectiveness of patient education in reducing cervical SCI in those with OPLL.

The efficacy of decompressive surgery in treating cervical SCI remains controversial,^{11,12} particularly in patients without bone injury. Some authors recommend surgery for patients with preexisting canal stenosis, as persistent cord compression may hinder neurologic improvement.¹³⁻¹⁵ In contrast, other researchers have reported no additional benefit with surgery in comparison to conservative treatment.^{16,17}

In this study, we evaluated the safety and efficacy of surgical treatment in patients with OPLL. Most of the surgeries we conducted here were classified as "late surgery," with a median interval of 2 weeks from injury to surgery. The surgery and conservative groups were comparable with regard to age, maximum canal compromise, and initial severity of neurologic injury (Table 3), and both groups had similar rates of complications. Overall, no significant difference was noted between the groups in neurologic recovery as defined by improvement in Frankel grade (surgery group: 71%, conservative group: 52%). However, further stratification showed that surgery was associated with better neurologic recovery in those who had gait disturbance before injury (surgery group: 82%, conservative group: 44%).

The reason why surgery benefitted patients with preexisting gait disturbance is not clear. In most patients, presence of gait disturbance indicated that the patient had already developed myelopathy. Contrary to our initial hypothesis, however, our results indicated that this subgroup of patients experienced improved neurologic recovery after decompressive surgery.

Two distinct factors must be considered in understanding the pathomechanism of SCI in patients with OPLL: direct injury by traumatic force, which is believed to be irreversible; and preexisting cord compromise because of long-standing compression. The relative contribution of these two factors may vary among patients. Decompressive surgery may have

little or no benefit on primary cord injury caused by traumatic force, but may in turn benefit cord compromise brought on by persistent compression. Presumably, the contribution of traumatic force, an irreversible factor, may be smaller in patients with gait disturbance before injury than in those without gait disturbance. Patients with preexisting cord compromise may be particularly vulnerable and may easily become paraplegic on suffering minor trauma. In this study, we assumed that the variable contribution of these two factors accounts for the seemingly perplexing results obtained here. Further research in this field may provide valuable information for predicting neurologic recovery after decompressive surgery in SCI patients with preexisting canal stenosis.

Several limitations to our study warrant mention. First, the follow-up period was relatively short. Although significant improvement in motor function is known to be achieved within 6 months after injury, longer term follow-up studies may yield additional information.¹⁴ Our follow-up rate was 68% at 6 months postinjury. This could have influenced the validity of our conclusion, although we found no apparent bias in the patients who were lost to follow-up within 6 months. Reasons for the dropout are not specified and can vary. This study was carried out at academic tertiary referral centers serving a relatively large area. SCI patients admitted to these medical centers are subsequently transferred to local hospitals near their residence after the acute phase. Presumably, some patients, especially who remained nonambulatory, required a great deal of assistance for transport. These patients might have found it difficult to travel a long distance from their residence to the hospital. We can also speculate that some patients, especially elderly patients, might have been suffering from complications after injury or comorbidities. These medically fragile patients might have been in poor or deteriorated health status and unable to show up at prescheduled check-up. The conclusions of this study need to be verified by future prospective studies. Second, Frankel grade was used as an outcome measure. Frankel grade has been widely used to rank severity of SCI in the literature despite its low discriminative ability. We therefore may have underestimated the neurologic recovery of the patients. Other validated outcome measures with high-discriminative ability may provide more detailed information. In addition, the indications and timing of surgery were not standardized between institutions, and thus selection bias cannot be entirely discounted. Despite these limitations, however, we feel that our study contains valuable information of clinical importance, providing a basis for future research.

CONCLUSION

In conclusion, our results underscore the importance of OPLL in the occurrence of acute traumatic cervical SCI in Japan, particularly in patients without bone injury. Our data indicate that patient awareness of OPLL may aid in preventing cervical SCI. Furthermore, our results suggest the efficacy of surgical decompression in patients with preexisting gait disturbance. These findings may aid in implementing an action plan aimed at prevention and better treatment of cervical SCI complicated by OPLL.

➤ Key Points

- ❑ OPLL was highly prevalent in patients with acute SCI, particularly in those without bone injury.
- ❑ Most of cervical SCI associated with OPLL were incomplete, without bone injury, and caused primarily by low-energy trauma. Majority of these patients was elderly and unaware of OPLL before injury.
- ❑ Decompression surgery was associated with better neurologic recovery compared with conservative treatment in patients who had gait disturbance before injury.

References

1. Iwasaki M, Yonenobu K. Ossification of the posterior longitudinal ligament. In: Herkowitz H, Garfin S, Eismont F, et al. eds. *Rothman-Simeone The Spine*. 5th ed. Philadelphia, PA: Saunders; 2006: 896–912.
2. Matsunaga S, Sakou T. OPLL: disease entity, incidence, literature search, and prognosis. In: Yonenobu K, Nakamura K, Toyama Y, eds. *OPLL Ossification of the Posterior Longitudinal Ligament*. 2nd ed. Tokyo, Japan: Springer; 2006:11–17.
3. Endo S, Shimamura T, Nakae H, et al. Cervical spinal cord injury associated with ossification of the posterior longitudinal ligament. *Arch Orthop Trauma Surg* 1994;113:218–21.
4. Koyanagi I, Iwasaki Y, Hida K, et al. Acute cervical cord injury associated with ossification of the posterior longitudinal ligament. *Neurosurgery* 2003;53:887–91; discussion 91–2.
5. Frankel HL, Hancock DO, Hyslop G, et al. The value of postural reduction in the initial management of closed injuries of the spine with paraplegia and tetraplegia. I. *Paraplegia* 1969;7:179–92.
6. Tsuyama N. Ossification of the posterior longitudinal ligament of the spine. *Clin Orthop Relat Res* 1984;71–84.
7. Matsunaga S, Sakou T, Hayashi K, et al. Trauma-induced myelopathy in patients with ossification of the posterior longitudinal ligament. *J Neurosurg* 2002;97:172–5.
8. Bracken MB, Shepard MJ, Collins WF, et al. A randomized, controlled trial of methylprednisolone or naloxone in the treatment of acute spinal-cord injury. Results of the Second National Acute Spinal Cord Injury Study. *N Engl J Med* 1990;322:1405–11.
9. Koyanagi I, Iwasaki Y, Hida K, et al. Acute cervical cord injury without fracture or dislocation of the spinal column. *J Neurosurg* 2000;93:15–20.
10. Mihara K, Torigoe Y, Konishi H. Cervical spinal cord injury associated with ossification of the posterior longitudinal ligament [in Japanese]. *Orthop Traumatol* 1991;40:763–5.
11. Fehlings MG, Sekhon LH, Tator C. The role and timing of decompression in acute spinal cord injury: what do we know? What should we do? *Spine (Phila Pa 1976)* 2001;26:S101–10.
12. Fehlings MG, Skaf G. A review of the pathophysiology of cervical spondylotic myelopathy with insights for potential novel mechanisms drawn from traumatic spinal cord injury. *Spine (Phila Pa 1976)* 1998;23:2730–7.
13. Bose B, Northrup BE, Osterholm JL, et al. Reanalysis of central cervical cord injury management. *Neurosurgery* 1984;15:367–72.
14. Chen L, Yang H, Yang T, et al. Effectiveness of surgical treatment for traumatic central cord syndrome. *J Neurosurg Spine* 2009;10:3–8.
15. Guest J, Eleraky MA, Apostolides PJ, et al. Traumatic central cord syndrome: results of surgical management. *J Neurosurg* 2002;97:25–32.
16. McKinley W, Meade MA, Kirshblum S, et al. Outcomes of early surgical management versus late or no surgical intervention after acute spinal cord injury. *Arch Phys Med Rehabil* 2004;85:1818–25.
17. Pollard ME, Apple DF. Factors associated with improved neurologic outcomes in patients with incomplete tetraplegia. *Spine (Phila Pa 1976)* 2003;28:33–9.

Aorta Movement in Patients With Scoliosis After Posterior Surgery

Katsushi Takeshita, MD,* Toru Maruyama, MD,† Yusuke Nakao, MD,† Takashi Ono, MD,*
Yuki Taniguchi, MD,* Hirotaka Chikuda, MD,* Naoki Shoda, MD,* Yasushi Oshima, MD,*
Akiro Higashikawa, MD,* and Kozo Nakamura, MD*

Study Design. Retrospective analysis.

Objective. To evaluate movement of the aorta in patients with scoliosis who have undergone the posterior correction and fusion.

Summary of Background Data. Surgeons check preoperative imaging for pedicle screw placement, but past analyses indicated that the aorta shifts after scoliosis surgery. Few studies, however, evaluated the aorta movement in detail.

Methods. A total of 22 patients with a right thoracic curve underwent posterior instrumentation and fusion. The average age at surgery was 17.2 years. The average of the preoperative Cobb angle was 65.2° which decreased to 20.0°.

Computed-tomographic data were analyzed by multiplanar reconstruction. In our coordinate system, the middle of the base of the left superior facet was set as the origin and a line connecting the middle points of both bases of the superior facets was defined as the X-axis. We defined the angle and the distance to describe the aorta position and analyzed the movement of the aorta relative to the spine. Deformity parameters were examined to determine their correlation with the aorta parameters.

We simulated variable pedicle screw placement and defined a warning pedicle when the aorta enters the expected area of the screw and examined them in 24 scenarios.

Results. The aorta moved 4.7 ± 3.0 mm on an average. The aorta had a tendency to migrate in the anteromedial direction and this movement correlated with preoperative apical vertebral translation, preoperative sagittal alignment, and change of sagittal alignment. The ratio of warning pedicles at the middle thoracic level (T7–T9) increased after deformity correction.

Conclusion. The aorta moved anteromedially relative to the spine after the posterior correction and the risk of the aorta by a pedicle screw increased by correction of the deformity at the middle thoracic spine. Surgeons are recommended to anticipate the aorta movement in the surgical planning.

Key words: scoliosis, pedicle screw, aorta, computed tomography. **Spine 2010;35:E1571–E1576**

Posterior correction and fusion by instrumentation is popular in the deformity surgery and pedicle screws have been the dominant anchors for the last decade. However, several authors^{1–3} reported a possible risk of aorta injury by a pedicle screw. Although surgeons use preoperative radiographic imaging in placing pedicle screws to prevent the aorta containment, the aorta may move after surgical correction of the spinal deformity. Few analyses of the movement of this organ after posterior surgery have been reported. The purpose of the present study was to evaluate the aorta movement after the posterior correction and fusion in scoliosis surgery.

Materials and Methods

A total of 37 patients with scoliosis underwent posterior instrumentation and fusion at the University Hospital between 2005 and 2007 and 22 patients with a right thoracic curve were included in this study. Scoliosis was idiopathic in 18 patients, Chiari-syrinx in 2, multiple epiphyseal dysplasia in 1, and Noonan syndrome in 1. A total of 15 patients were excluded: 5 patients with congenital scoliosis, 4 with idiopathic scoliosis with no thoracic curve, 3 with Marfan syndrome who might have had abnormal vascular movement, 2 with idiopathic scoliosis with left thoracic curve, and 1 with tubular sclerosis with left thoracic curve. Patient age at surgery was 10 to 29 (mean, 17.2) years old and 18 were women and 4 were men. Lenke's classification of scoliosis was type 1 in 8 patients, type 2 in 5, type 3 in 1, type 4 in 4, type 5 in 1, and type 6 in 3. The preoperative Cobb angle averaged $65.2^\circ \pm 11.6^\circ$ (range, 50°–88°) and corrected to $36.3^\circ \pm 12.0^\circ$ (range, 18°–70°) on bending films, and to $26.6^\circ \pm 10.0^\circ$ (range, 13°–44°) on fulcrum-bending films.⁴ The apex vertebra of the thoracic curve ranged from T5–T10 (T5:1, T7:2, T8:6, T9:5, T10:8). All patients were treated by posterior correction and fusion by pedicle screw instrumentation. The average number of instrumented vertebrae was 12.2 ± 1.6 (9–16 vertebrae). Postoperative Cobb angle averaged $20.0^\circ \pm 7.7^\circ$ (range, 11°–39°) and correction rate was $69.6\% \pm 8.5\%$ (53%–83.1%). Cincinnati correction index⁵ was 1.74 ± 0.57 (0.95–3.38) and Fulcrum bending correction index⁶ was 1.18 ± 0.16 (0.78–1.48).

The patients were evaluated by computed tomography (CT) before and after surgery. Preoperative examination was for the computer-assisted placement of pedicle screws and the postoperative one was to confirm the location of pedicle screws. There was no need to replace any screw. The preoperative CT was obtained from the upper thoracic to the lower lumbar spine with a width of 1.25 mm as directed by a naviga-

From the *Department of Orthopaedic Surgery, the University of Tokyo, Tokyo, Japan; and the †Department of Orthopaedic Surgery, the Saitama Medical Center, Saitama, Japan.

Acknowledgment date: April 17, 2009. First revision date: August 8, 2009. Second revision date: November 23, 2009. Third revision date: November 30, 2009. Acceptance date: December 1, 2009.

The manuscript submitted does not contain information about medical device(s)/drug(s).

No funds were received in support of this work. Although one or more of the author(s) has/have received or will receive benefits for personal or professional use from a commercial party related directly or indirectly to the subject of this manuscript, benefits will be directed solely to a research fund, foundation, educational institution, or other non-profit organization which the author(s) has/have been associated.

Address correspondence and reprints requests to Katsushi Takeshita, MD, Department of Orthopaedic Surgery, The University of Tokyo, 7–3–1, Hongo, Bunkyo-ku, Tokyo, Japan 113–8655; E-mail: Takeshita-ort@h.u-tokyo.ac.jp

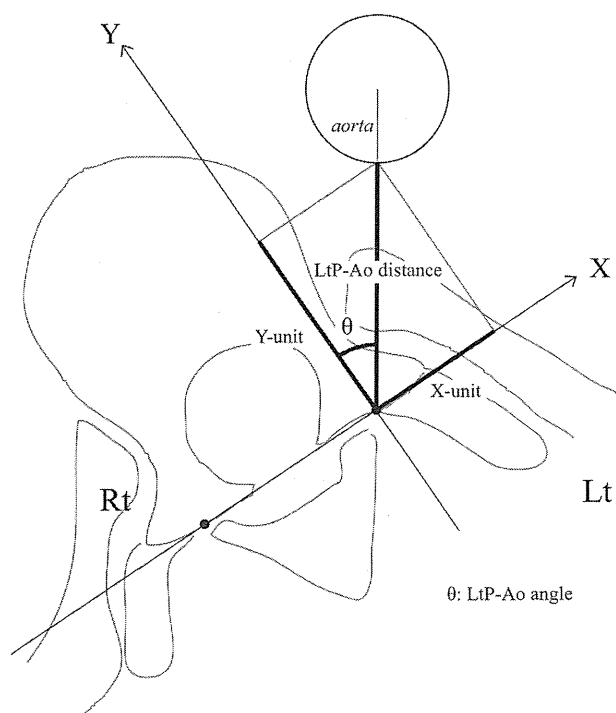


Figure 1. Aorta parameters. The origin is set in the middle of the base of the left superior facet. A line connecting the 2 middle points of both bases of the superior facets is defined as X-axis. LtP-Ao distance indicates the left pedicle-aorta distance; LtP-Ao angle, the left pedicle-aorta angle.

tion protocol, and the postoperative CT was obtained with a helical scan and developed with a width of 1.00 mm less than 2 weeks after surgery. All Digital Imaging and Communication in Medicine data were transferred to a personal computer and analyzed by Digital Imaging and Communication in Medicine or DICOM software (ExaView LITE; Ziosoft, Tokyo, Japan). In the present study, we used our original Cartesian coordinate system and measured parameters describing the location of the aorta from T4 to L4 of the 22 patients. We selected the middle of the base of the left superior facet as the point of origin of this coordinate system

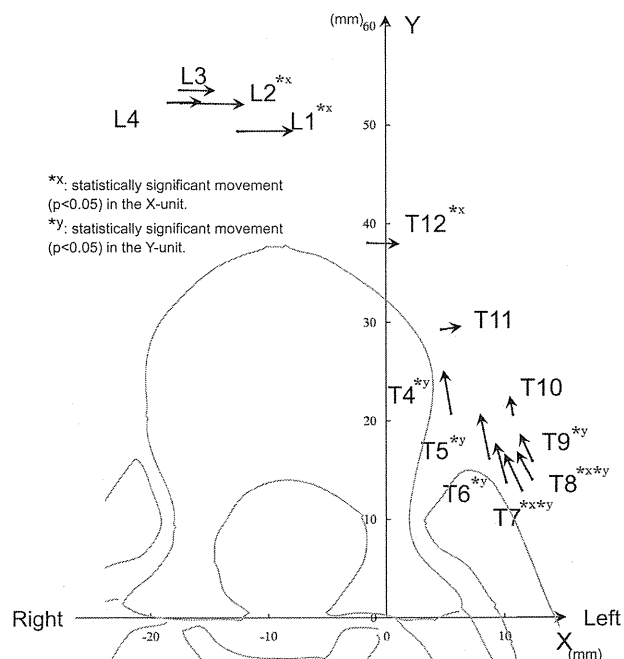


Figure 2. The aorta movement relative to the spine before and after posterior correction and fusion in our Cartesian coordinate system. The aorta moved to the anterior direction at the upper and middle thoracic levels and to the medial direction at the lower thoracic and lumbar levels.

(Figure 1) because the most probable threat to the aorta is by a pedicle screw on the left side at the thoracic spine. A line connecting the 2 middle points of both bases of the superior facets was defined as the X-axis; the Y-axis is determined to be parallel to the upper endplate of each vertebral body. The angle formed by the Y-axis and a line connecting the origin and the center of the aorta was defined as the left pedicle-aorta (LtP-Ao) angle and length of a line connecting the origin and the edge of the aorta as the LtP-Ao distance. Two parameters and the X- and Y-units of the LtP-Ao distance at 240 vertebral bodies were measured pre- and postsurgery after excluding vertebrae with incomplete data. From the repeatability test from our previous study,⁷ interclass corre-

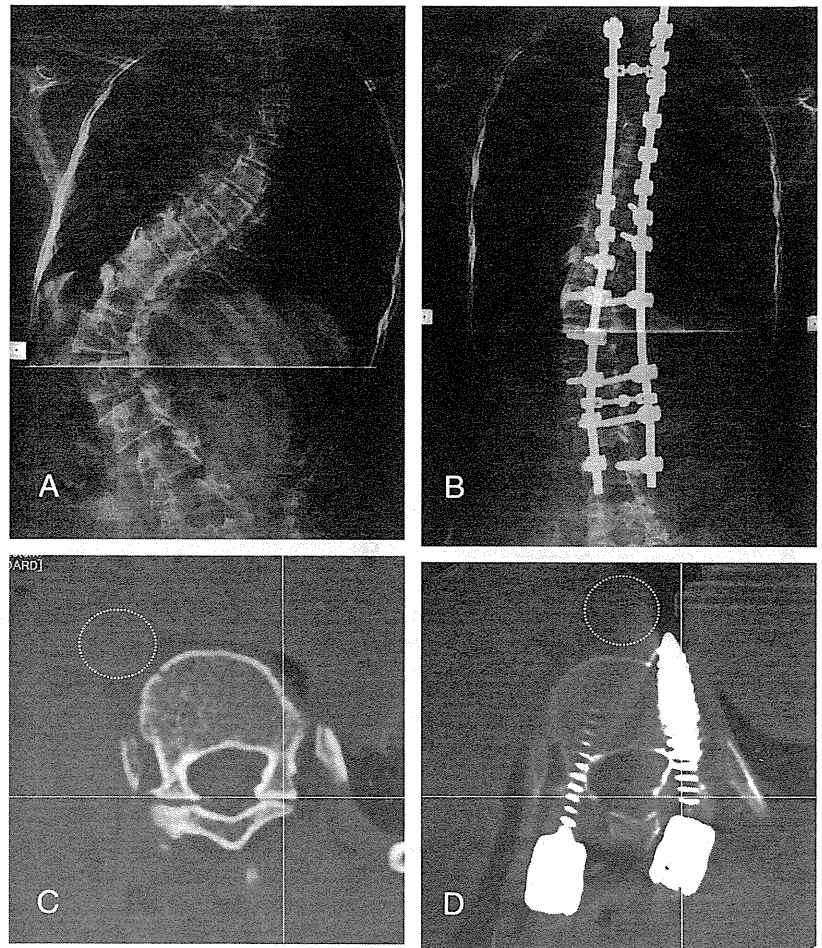
Table 1. Aorta Parameters Before and After Surgery

Level	n	LtAo-Angle (deg)			LtAo-Distance (mm)			Movement (mm)
		Preop	Postop	Change	Preop	Postop	Change	
T4	6	22.3 ± 30.9 (-6 to 65)	16.2 ± 24.6 (-18 to 55)	-4.1 ± 13.0 (-28 to 9)	22.0 ± 8.4 (11 to 32)	25.8 ± 8.3 (14 to 39)	3.6 ± 3.1* (-1 to 8)	5.9 ± 4.2 (1 to 12)
T5	20	30.8 ± 21.0 (-1 to 78)	23.8 ± 18.0 (-10 to 67)	-7.2 ± 8.9* (-23 to 12)	19.9 ± 4.7 (12 to 32)	23.6 ± 6.0 (14 to 37)	4.3 ± 3.7* (-1 to 14)	5.4 ± 2.9 (1 to 13)
T6	22	37.3 ± 16.8 (9 to 74)	30.2 ± 14.2 (3 to 59)	-7.1 ± 9.1* (-22 to 8)	18.1 ± 3.7 (13 to 28)	20.7 ± 5.0 (11 to 33)	2.6 ± 2.7* (-2 to 9)	4.6 ± 2.7 (1 to 13)
T7	22	42.3 ± 14.0 (17 to 74)	32.6 ± 11.4 (12 to 59)	-10.0 ± 7.7* (-22 to 3)	17.9 ± 3.7 (12 to 26)	19.7 ± 4.5 (12 to 33)	1.9 ± 2.6* (-3 to 7)	4.1 ± 2.6 (0 to 9)
T8	22	42.4 ± 11.1 (16 to 65)	34.5 ± 8.5 (20 to 55)	-7.9 ± 7.1* (-20 to 4)	19.2 ± 4.3 (13 to 30)	20.2 ± 3.7 (14 to 29)	1.0 ± 2.6 (-6 to 4)	3.9 ± 2.1 (1 to 8)
T9	22	39.2 ± 11.5 (13 to 53)	32.5 ± 8.8 (9 to 46)	-6.8 ± 7.0* (-23 to 7)	20.8 ± 4.9 (14 to 32)	21.8 ± 4.2 (16 to 31)	1.0 ± 2.4 (-6 to 5)	3.8 ± 2.2 (1 to 9)
T10	22	29.9 ± 14.1 (-13 to 51)	27.1 ± 10.3 (0 to 49)	-2.7 ± 7.5 (-15 to 13)	24.1 ± 6.3 (15 to 36)	25.0 ± 5.2 (17 to 34)	0.9 ± 3.2 (-5 to 6)	4.3 ± 2.8 (0 to 10)
T11	22	13.0 ± 20.4 (-46 to 44)	13.9 ± 13.6 (-21 to 37)	0.8 ± 10.0 (-17 to 25)	31.8 ± 8.0 (19 to 46)	31.3 ± 6.7 (20 to 43)	-0.5 ± 3.1 (-7 to 4)	5.1 ± 4.4 (0 to 19)
T12	21	0.4 ± 16.2 (-26 to 28)	3.7 ± 13.2 (-18 to 34)	3.3 ± 6.4* (-10 to 13)	39.4 ± 8.1 (25 to 52)	38.2 ± 7.4 (25 to 55)	-1.0 ± 2.5 (-7 to 4)	5.0 ± 3.0 (1 to 10)
L1	21	-12.6 ± 14.1 (-36 to 13)	-8.0 ± 10.6 (-29 to 9)	4.8 ± 5.5* (-8 to 12)	50.3 ± 6.8 (36 to 63)	49.0 ± 6.2 (39 to 59)	-1.5 ± 3.3* (-7 to 6)	6.0 ± 3.1 (1 to 13)
L2	21	-16.0 ± 10.3 (-38 to 2)	-12.0 ± 8.8 (-28 to 3)	4.1 ± 4.6* (-3 to 14)	54.5 ± 4.5 (44 to 61)	52.8 ± 4.4 (44 to 61)	-1.6 ± 1.5* (-7 to 2)	5.2 ± 3.2 (2 to 14)
L3	14	-17.6 ± 5.2 (-27 to -10)	-14.0 ± 5.3 (-23 to -5)	2.6 ± 4.0* (-4 to 8)	55.4 ± 4.5 (47 to 63)	54.4 ± 4.3 (48 to 62)	-1.0 ± 2.9 (-5 to 4)	4.4 ± 2.6 (1 to 8)
L4	5	-19.6 ± 5.9 (-28 to -12)	-17.0 ± 4.6 (-25 to -13)	2.4 ± 3.0 (-1 to 7)	53.2 ± 3.3 (48 to 57)	53.2 ± 4.7 (48 to 59)	0.0 ± 3.1 (-3 to 4)	3.9 ± 2.0 (2 to 7)
Total	240	17.9 ± 27.4 (-46 to 78)	15.4 ± 21.6 (-29 to 67)	-2.5 ± 9.1 (-28 to 25)	31.3 ± 15.3 (11 to 63)	31.9 ± 13.9 (11 to 62)	0.7 ± 3.3 (-7 to 14)	4.8 ± 3.2 (0 to 20)

*P < 0.01.

LtAo-Angle indicates left pedicle-aorta angle; LtAo-Distance, left pedicle-aorta distance; Preop, preoperative; Postop, postoperative.

Figure 3. **A**, Standing anteroposterior spinal radiograph of a 14-year-old girl with a 69° right thoracic curve and 88° left lumbar curve. She had only 11 thoracic vertebrae (no T12) and the apical vertebral translation was 69.5 mm. She had had foraminal magnum decompression and duroplasty 16 months before spinal surgery. **B**, Standing coronal radiograph 2 weeks after segmental pedicle screw instrumentation from T2 to L4 demonstrating thoracic curve correction to 19° and lumbar curve correction to 25°. The apical vertebral translation decreased to 30.1 mm. **C**, Preoperative computed tomography by multiplanar reconstruction at T11. The aorta (dotted circle) located in front of the right side of the vertebral body. **D**, Postoperative computed tomography adjusted by multiplanar reconstruction to match the preoperative imaging. The aorta (dotted circle) had moved 19.5 mm to the bicortical pedicle screw of the left side.



lation coefficients were 0.922 to 0.957 in the intraobserver measurement and 0.896 to 0.929 (0.864–0.961) in the interobserver measurement.

We analyzed the movement of the aorta relative to the spine in each level. To determine the relationship between the thoracic main curve and thoracic coronal/sagittal alignment, we selected patients who had their main curve in the thoracic spine. In the 17 selected patients, we measured the Cobb angle and the apical vertebral translations (AVT) of the main curve, and the sagittal alignment (the Cobb angle at T5–T12) before and after surgery. These deformity parameters were examined for their correlation, with the maximum movement of the aorta in the main thoracic curve. Statistical analysis was performed by SPSS 17.0 (SPSS Inc., Chicago, IL).

We simulated placement of the pedicle screw with a direction different from the ideal trajectory. Sensitivity analysis was performed by varying the direction error and the length of the screw independently. The direction error started from 10° up to 30° with 10° increments (3 scenarios). The length of the screw started from 25 to 40 mm with increments of 5 mm (4 scenarios). Therefore, we set up total of 24 scenarios in the preoperative or postoperative state. We defined a warning pedicle as being when the aorta enters the expected area of the screw. Ratio between the number of warning pedicles and the number of the examined pedicles at 1 spine level was calculated from T4 to L4 in every scenario.

■ Results

The LtP-Ao angle changed significantly from T5 to T9 and from T12 to L3 (*t* test, $P < 0.01$) (Table 1), whereas the LtP-Ao distance changed significantly from T4–T7, L1 and L2. The average of the aorta movement in the examined 240 vertebrae was 4.7 ± 3.0 mm. The aorta moved more than 10 mm in 14 vertebrae (5.8%), and had a tendency to migrate in the anteromedial direction (Figure 2). A representative case is shown in Figure 3.

In the 17 patients who had the main curve in the thoracic spine, the maximum movement of the aorta in the main thoracic curve was 8.9 ± 3.5 mm (range, 3.9–14.9). Level of the maximum movement was T4 in 1 case, T5 in 1, T6 in 1, T7 in 2, T9 in 1, T10 in 3, T11 in 1, T12 in 1, L1 in 3, L2 in 2, L3 in 0, and L4 in 1. Level of the maximum movement was periapical (± 1 vertebra of the apex) in 8 cases. The maximum movement of the aorta correlated with the preoperative AVT (Pearson correlation coefficient, -0.55 ; $P = 0.02$), preoperative sagittal alignment (-0.52 , $P = 0.03$), and change of the sagittal alignment (0.57 , $P = 0.02$) (Figure 4).

Sensitivity analysis (Tables 2–4) revealed that long pedicle screw (40 mm) with moderate direction error