

patient's blood with normal donor blood, was introduced in 1958¹⁹ and prevailed until the 1970s. This method aimed to concomitantly correct the two main abnormalities (clotting factor depletion and coma); however, its effectiveness was discredited by a small scale RCT in 1973.³

In 1967 a beneficial effect of PE for FHF was reported.²⁰ PE was aimed at more efficient correcting the coagulation abnormalities and coma of FHF than WBET, and a significant improvement in survival rates was reported in a case series.^{21, 22}

Our own experience with PE treatment for FHF showed an overall survival rate of approximately 30%,²³ and although PE is effective in the replenishment of depleted plasma components, it is of a limited value in the removal of substances with large body pool.²⁴ The concentrations of most of amino acids were not changed by high-volume PE.²⁵ Consequently, patients with FHF who are receiving PE seldom bleed, but their coma progressively deepens despite daily exchange. This prompted the idea that combining PE with an adequate method to remove toxic substances with large body pool may provide an improved ALS system.²⁶ PE alone sometimes causes adverse events such as hypernatremia, metabolic alkalosis and sharp decrease in colloid osmotic pressure; however, PE in combination with CHDF²⁷ (Figure 1) or HDF²⁶ can reduce these adverse events.

Attempts have been made since the 1950s to remove toxic substances from patients with FHF by perfusing the patient's blood through adsorbents, with the introduction of HP through resin, which experimentally adsorbs bilirubin and bile acid.²⁸ However, resin HP showed little clinical effect. Rather, it suffered from poor biocompatibility manifested by severe thrombocytopenia.

In 1974, the King's College group reported a favorable clinical effect of HP through 160 g of coated activated charcoal.²⁹ At the same time, a Japanese group attempted plasma perfusion (PP) through uncoated charcoal;³⁰ however, a survival rate as low as 19.2% (5/26) was reported with this method.³¹ The problem with charcoal PP was its low bio-

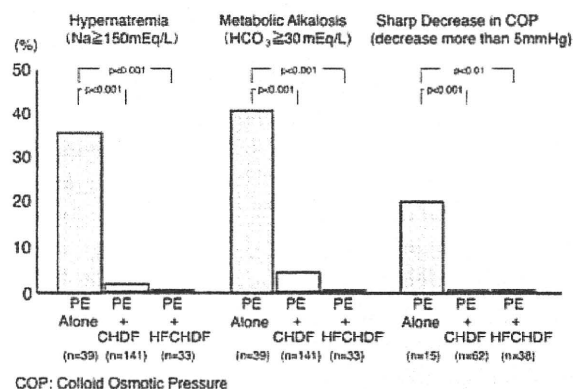


Figure 1.—Incidence of hypernatremia, metabolic alkalosis and sharp decrease in colloid osmotic pressure during ALS treatments. PE: plasma exchange; CHDF: continuous hemodiafiltration; HFCHDF: high flow continuous hemodiafiltration.

compatibility, and the induction of disseminated intravascular coagulation (DIC).³² The King's College group later assessed the effect of their own charcoal HP in a RCT, and reported no significant beneficial effect.⁴ The Japanese groups thus discontinued using charcoal PP, and switched to PE as their method of choice for an ALS system.

The BioLogic-DT system includes a cellulose plate dialyzer with a suspension of powdered activated charcoal and cation exchangers as dialysate.⁶ An early study indicated encouraging results in a small trial of ACLF;⁹ however, a subsequent study in acute liver failure did not confirm the benefit of this device.⁷

MARS (Teraklin AG, Rostock, Germany) is a closed-loop system that allows passage of albumin-bound toxins up to 50 kDa in diameter to pass from patients' blood to 20% albumin within the circuit. The albumin is then refreshed by passage through charcoal and anion-exchange resin columns. However, there is no evidence that toxins bound to the albumin are effectively delivered to the charcoal and resin. Novelli *et al.* reported 14 patients with acute liver failure successfully supported with MARS before receiving an orthotopic liver transplantation.³³ Tan also reported a beneficial effect of MARS; however, he admitted the necessity of a RCT for MARS.³⁴ Subsequent RCTs for MARS did not confirm the favorable effect.^{11, 12} Prometheus

(Fresenius Medical Care AG, Bad Homburg, Germany) is also a variant of albumin dialysis like MARS removes mainly protein-binding toxic substances. Removal of water-soluble substances is very limited by albumin dialysis as their first step of blood purification.

Instead of perfusing the patient's blood or plasma using adsorbents, other researchers have tried HDF using membranes with larger pores than those used in renal dialysis under the assumption that middle-range molecular substances (MMS) are responsible for the coma in FHF and are not removed by renal dialysis.³⁵ In 1978 a French group reported a beneficial effect of HDF using polyacrylonitril (PAN) membrane, which was claimed to be superior in removing MMS than standard kidney dialysis.³⁶ These findings were not confirmed, however, by a later study,³⁷ possibly due to the low permeability for MMS of the PAN membrane used in the 1970s.

For the safe and efficient removal of MMS we developed HDF using a larger pore polymethyl methacrylate (PMMA) membrane originally developed for the removal of β 2 microglobulin (MW 11 800).³⁸ The efficacy of this ALS system has been repeatedly reported,^{16, 38, 39} and is widely recognized in Japan.⁴⁰⁻⁴² In the 1990s CHDF using the same PMMA was introduced, and this HDF treatment is used extensively in Japan.⁴³⁻⁴⁶ This technique has been improved by the development of new high performance membranes in Japan.

History of biological and bioartificial liver support

Since Eisman performed HP through porcine liver in patients with chronic liver failure,^{47, 48} several attempts have been made to sustain patients with FHF and chronic liver failure by HP through animal^{1, 2, 14, 49} and cadaver liver;⁵ however, most of these attempts were unsuccessful. Recent developments in tissue engineering have improved cell viability, opening the way for biological liver (BL) and BAL systems that have replaced HP through whole livers.

The HepatAssist BAL uses a column of 300

g of charcoal and 50 g of porcine hepatocytes housed within a hollow fiber bioreactor. Although the BAL was expected to have both synthesis and detoxification capabilities, subsequent clinical trials did not show any favorable effects of the BAL.^{15, 45} Xenogenic infections and zoonosis are major drawbacks that hamper use of porcine hepatocyte for BAL.^{50, 51}

ELAD uses cells derived from a human hepatoblastoma cell line (C3A) cultured within the extracapillary space of a dialysis cartridge. ELAD is also expected to have both synthesis and detoxification capabilities; however, neither a PCT¹⁴ nor a recent study using a newer version of ELAD⁴⁹ demonstrated these features, although they did confirm the safety of ELAD.

In general, bioartificial systems have failed to show any significant benefits in the synthesis of liver-related compounds and have only shown limited detoxifying functions. The first major hurdle for a beneficial BAL support system is to build a bio-component which includes hepatocytes with excellent synthesis and detoxifying abilities, and non-parenchymal liver cells.

Artificial liver support currently prevailing in Japan

The objective of an ALS or BAL systems is to compensate for deficient liver function in liver failure. Therefore, the efficacy of ALS and BAL systems can be judged by assessing to what extent deficient liver function can be compensated. Since the ALS system is a symptomatic treatment for liver failure, the primary end-point of assessment should not be the survival rate, but the potential to completely reverse the symptoms of liver failure in the severest FHF, comparable to an ahepatic state.

Charcoal and resin have been widely used adsorbents and although they have a large capacity to adsorb a wide variety of substances, their capacity is limited when dealing with the accumulation of toxic substances in FHF. For example, the serum level of glutamine, which becomes toxic by releasing

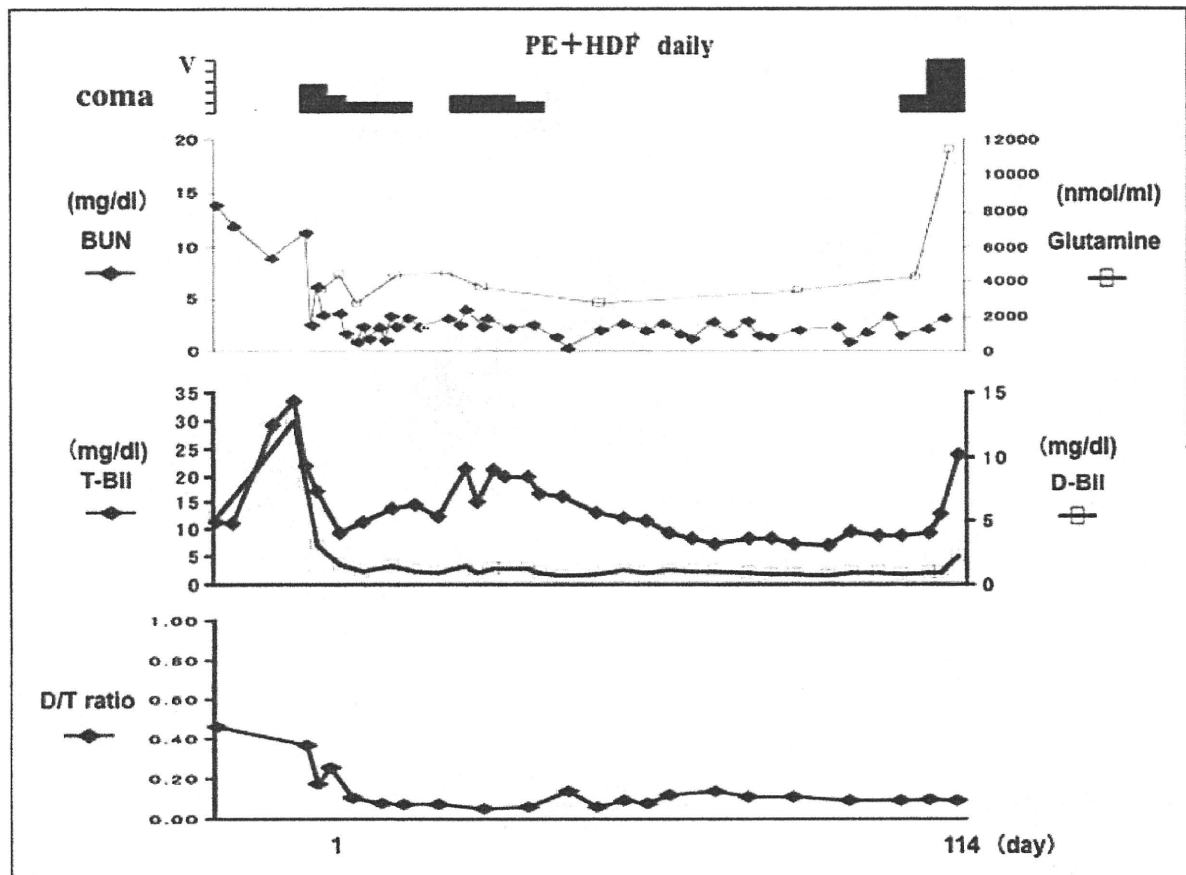


Figure 2.—Clinical course of a 30-year-old female patient with fulminant hepatic failure. Etiology of this case was undetermined. The patient has survived for 114 days under the treatment of artificial liver support consist of plasma exchange and hemodiafiltration using high performance membrane in spite of ahepatic state. Liver weight at autopsy was 210 g.

ammonia, can exceed 10 000 nmol/mL (normal range 422-703 nmol/mL) in a severe case of FHF which is comparable to an ahepatic state (Figure 2). The poor efficiency of BioLogic-DT, MARS, BAL, and ELAD in the removal of toxic substances is illustrated by the poor improvement in encephalopathy shown in the meta-analysis.²

PE using high volumes of FFP was shown to be effective for FHF in a number of case studies.^{25, 52-56} However, PE using up to 8 L of fresh plasma (high-volume plasma apheresis) is of limited value in removing amino acids such as glutamine with a large body pool.²⁵ The use of high volumes of plasma is expensive and wastes a limited resource. Therefore, we attempted to remove the MMS as efficiently as possible by an alternative method. We selected high-volume HDF using 70-kDa cut-off PMMA, cellulose triacetate (CTA), and

polysulfone (PS), which are three times more efficient in removing inulin than the PAN membrane used by the French group.⁵⁶ The HDF removes not only MMS but also lower molecular weight substances such as glutamine effectively.

PE in combination with high-volume HDF as an ALS system has been already established.⁵⁵ PE starts with 40 packs (3.2 L) of FFP, which is then adjusted from 20-60 packs to keep the minimum prothrombin time (PT) above 30% of the normal level throughout the treatment course. Hemofiltration starts with 20 L of bicarbonate buffer (Sublood-B, Fuso Pharmaceutical Industries, Ltd., Osaka, Japan) running rapidly for 4 hours. Dialysis is performed concomitantly at a flow rate of 500 mL/min using bicarbonate buffer (Kindaly Solution AF-2, Fuso Pharmaceutical Industries, Ltd., Osaka, Japan). Thus, patient's blood is

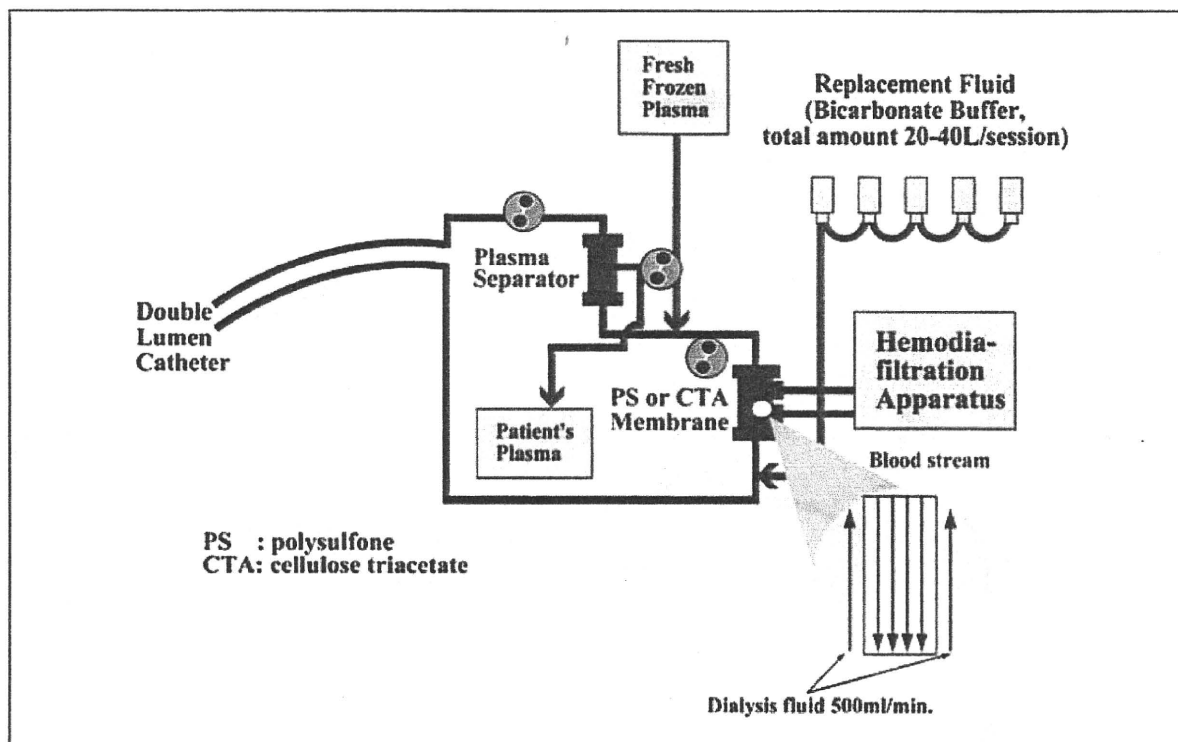


Figure 3.—Circuit diagram for the artificial liver support system currently prevailing in Japan. This system works by plasma exchange using membrane separation and hemodiafiltration with a postdilution method. Flow rate of dialysis buffer is 500 mL/min and volume of filtration buffer is 20–40 L infusing at 5 L/h.

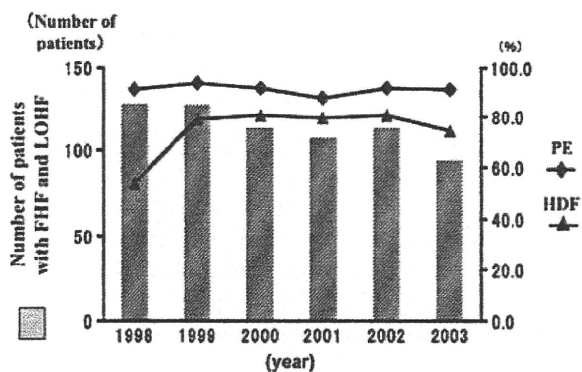


Figure 4.—Number of patients with fulminant hepatic failure and late onset hepatic failure from 1998 to 2003. Use of plasma exchange and hemodiafiltration annually during the period.

cleansed by 170 L of buffer at the start. The volume of filtrate is increased up to 40 L through post-dilution route depending upon the patient's response, and thus the patient blood is cleansed maximally by a significantly large volume of 340 L of buffer per session (Figure 3).

In 1986, we first reported complete recovery from deep coma in a patient with severe FHF caused by hepatic vein obstruction.²⁶ The efficacy of this ALS system was further substantiated in studies of 27 and 67 patients with FHF, which gave surprisingly high rates of recovery (92.6% and 97%, respectively) from the initial coma.^{16, 39} Brain edema and renal failure are observed in 19%, and 11% of cases on admission, respectively and most of the cases recovered. The effectiveness of this ALS system is now widely recognized in Japan.^{40–42} Some investigators have modified the rapid HDF to continuous HDF (CHDF) with also good results.^{43–46} A national annual surveillance study supported by the Ministry of Health, Welfare and Labor of Japan, which collected data from 1998 to 2003, reported the use of PE and HDF/CHDF in 91.5% (637/696) and 74.6% (519/696) of patients with FHF or late-onset hepatic failure, respectively⁵⁷ (Figure 4). Recently, recovery from brain edema in severe FHF was reported using this methods of ALS system.⁵⁸ The

beneficial effect was explained by the efficient removal of small molecules such as ammonia and glutamine (Gln), which contribute to brain edema along with MMS.^{59,60} Brain edema is a lethal complication of FHF and HDF using high volume of buffers is an essential tool to manage brain edema effectively. We also measured the level of Gln in the discarded buffer and also estimated the distribution volume of Gln. In a patient with an ahepatic state who underwent ALS using over 300 L of buffer, the total amount of removed Gln ranged from 188 947 μmol to 41 165 μmol . The estimated distribution volume of Gln ranged from 30 L to 60 L. There is a significant relationship between total buffer volume and estimated distribution of Gln. Huge amount of buffer can remove huge amount of Gln.⁶¹ These results indicate that HDF using high-volume buffer can remove Gln not only from extracellular fluid but from intracellular fluid. Under the HDF using high-volume buffers, monitoring of intracranial pressure and cerebral blood flow becomes unnecessary. It also provides the clinician with enough time to judge whether liver transplantation is indicated and can avoid unnecessary liver transplantation.

Consensus in Japan was reached at the recent symposium of the Japanese Society for Apheresis held in Ohtsu, Shiga on July 28, 2006 that the effectiveness of the ALS system depends on the volume of buffer used, regardless of whether HDF is performed rapidly or continuously. In addition to the successful 114-day sustainment of a patient with subacute FHF non-A~non-B infection, whose liver failure was judged to be as severe as an hepatic state because of the loss of bilirubin conjugation capacity and urea cycle activity, as well as severe liver atrophy (liver weight 210 g at autopsy) (Figure 2),³⁹ Inoue reported another five patients with hyperacute FHF due to hepatitis B virus infection who were also judged to be ahepatic that were sustained alive for a long term.⁶² One patient subsequently received a successful live donor liver transplant.⁶³ Two similar hyperacute cases have been also reported,⁶⁴ suggesting that PE in combination with high-volume HDF can sustain patients with the

severest liver failure, comparable to an hepatic state, who otherwise would not survive, until liver transplantation is possible.

These results suggest that PE in combination with high-volume HDF or CHDF is the only reliable ALS system for Japanese clinicians who are routinely attempting to sustain patients with FHF and related severe liver diseases, although the efficacy of the method has not been ascertained by RCT.⁵⁵ A small randomized trial comparing low-volume and high-volume buffer for HDF in a safety manner may be helpful to evaluate the effectiveness of the therapy.

Conclusions

PE in combination with high-volume HDF or high-flow CHDF has become a standard ALS system in Japan. It is rare for only one system of ALS to be used throughout one country. The rationale of the system is simple. While PE replenishes depleted plasma components, toxic substances of middle molecular weight are removed more safely and efficiently than other previous methods by HDF or CHDF using high-volume buffers. This treatment system not only sustain the patient in good condition until the liver recovers or an adequate donor is found, but may also make perioperative care simpler.

Riassunto

Sistemi di supporto epatico come trattamento perioperatorio nel trapianto di fegato – prospettiva storica e recenti progressi in Giappone

Una meta-analisi sull'efficacia dei sistemi di supporto epatico artificiale (*artificial liver support*, ALS) nei casi di insufficienza epatica fulminante (*fulminant hepatic failure*, FHF) eseguita dal gruppo Cochrane Hepato-Biliary Group ha dimostrato che tutti i sistemi di ALS precedentemente sviluppati erano inefficaci nei pazienti affetti da FHF. Questo supporta la teoria che l'unico trattamento di elezione per la FHF sia il trapianto di fegato immediato. Lo scambio di plasma, in combinazione con emodialisi ad alto volume o emodialisi ad alto flusso continuo utilizzando membrane a pori larghi, che era stato escluso dalla meta-analisi di Cochrane a causa della mancanza di trial di controllo randomizzati, è invece

diventato un sistema ALS standard in Giappone. Questo sistema risulta sicuro e rimuove in maniera efficiente più sostanze tossiche di medio e basso peso molecolare degli altri metodi, utilizzando grandi volumi di tamponi (più di 200 litri per sessione), con il risultato di un risveglio dal coma nei pazienti con FHF grave comparabile a uno stato anepatico. Questi sistemi di supporto epatico artificiale rappresentano strumenti efficaci per mantenere i pazienti affetti da FHF in una condizione favorevole finché il fegato non riprende la sua funzione o non diventa disponibile un trapianto di fegato.

Parole chiave: Fegato - Insufficienza epatica - Emodiafiltrazione - Scambio di plasma.

References

1. Kjaergard LL, Liu J, Als-Nielsen B, Gluud C. Artificial and bioartificial support systems for acute and acute-on-chronic liver failure: a systematic review. *JAMA* 2003;289:217-22.
2. Liu JP, Gluud LL, Als-Nielsen B, Gluud C. Artificial and bioartificial support systems for liver failure. *The Cochrane Database of Systematic Reviews* 2004;Art. No.:CD003628.
3. Redeker AG, Yamahiro HS. Controlled trial of exchange-transfusion therapy in fulminant hepatitis. *Lancet* 1973;1:3-6.
4. O'Grady JG, Gimson AE, O'Brien CJ, Pucknell A, Hughes RD, Williams R. Controlled trials of charcoal hemoperfusion and prognostic factors in fulminant hepatic failure. *Gastroenterology* 1988;94:1186-92.
5. He JQ, Chen CY, Deng JF, Qi HX, Zang ZQ, Chen JQ. Charcoal hemoperfusion in the treatment of fulminant hepatic failure. *Chinese Crit Care Med* 2000;12:105-8.
6. Hughes RD, Pucknell A, Routley D, Langley PG, Wendon JA, Williams R. Evaluation of the BioLogic-DT sorbent-suspension dialyser in patients with fulminant hepatic failure. *Int J Artif Organs* 1994;17:657-62.
7. Mazariogis GV, Ash SR, Patzer JF. Preliminary results: randomized clinical trial of the BioLogic-DT in treatment of acute hepatic failure (AHF) with coma. *Artif Organs* 1997;21:43-50.
8. Kramer L, Gendo A, Madl C, Mullen K, Kaminski-Russ K, Zauner C. A controlled study of the BioLogic-DT system in chronic hepatic encephalopathy. *Hepatology* 1998;28:401.
9. Wilkinson AH, Ash SR, Nissensohn AR. Hemodiafiltration in treatment of hepatic failure. *J Transpl Coord* 1998;8:43-50.
10. Ellis AJ, Hughes RD, Nicholl D, Langley PG, Wendon JA, O'Grady JG, Williams R. Temporary extracorporeal liver support for severe acute alcoholic hepatitis using the BioLogic-DT. *Int J Artif Organs* 1999;22:27-34.
11. Mitzner SR, Stange J, Klammt S, Risler T, Erley CM, Bader BD, Berger ED *et al*. Improvement of hepatorenal syndrome with extracorporeal albumin dialysis MARS: results of a prospective, randomized, controlled clinical trial. *Liver Transpl* 2000;6:277-86.
12. Heemann U, Treichel U, Loock J, Philipp T, Gerken G, Malago M, Klammt S *et al*. Albumin dialysis in cirrhosis with superimposed acute liver injury: a prospective, controlled study. *Hepatology* 2002;36:949-58.
13. Stevens C, Busuttil R, Han S, Baquerizo A, Fair J, Shrestha R *et al*. An interim analysis of phase II/III prospective randomized multicenter controlled trial of the Hepat Assist Bioartificial Liver Support System for the treatment of fulminant hepatic failure (abstract). *Hepatology* 2001;34:299A.
14. Ellis AJ, Hughes RD, Wendon JA, Dunne J, Langley PG, Kelly JH *et al*. Pilot-controlled trial of the extracorporeal liver assist device in acute liver failure. *Hepatology* 1996;24:1446-51.
15. Larsen FS, Hansen BA, Jorgensen LG, Secher NH, Bondesen S, Linkis P *et al*. Cerebral blood flow velocity during high volume plasmapheresis in fulminant hepatic failure. *Int J Artif Organs* 1994;17:353-61.
16. Yoshihara M, Inoue K, Sekiyama K, Koh I. Favorable effect of new artificial liver support on survival of patients with fulminant hepatic failure. *Artif Organs* 1996;20:1169-72.
17. Kiley JE, Welch HF, Pender JC, Welch CS. Removal of blood ammonia by hemodialysis. *Proc Soc Exp Biol Med* 1956;91:489-90.
18. Sherlock S. Hepatic coma. *Gastroenterology* 1961;41:1-8.
19. Lee C, Tink A. Exchange transfusion in hepatic coma: report of a case. *Med J Aust* 1958;45:40-2.
20. Lepore MJ, Martel AJ. Plasmapheresis in hepatic coma. *Lancet* 1967;290:771-2.
21. Buckner CD, Clift RA, Volwiler W, Donohue DM, Burnell JM, Saunders FC *et al*. Plasma exchange in patients with fulminant hepatic failure. *Arch Intern Med* 1973;132:487-92.
22. Freeman JG, Matthewson K, Record CO. Plasmapheresis in acute liver failure. *Int J Artif Organs* 1986;9:433-8.
23. Inoue N, Yoshihara M, Yamazaki Z, Sakai T, Sanjo K, Okada K *et al*. Continuous flow membrane plasmapheresis utilizing cellulose acetate hollow fiber in hepatic failure. In: Brunner G, Schmidt F, editors. *Artificial liver support*. Berlin: Springer-Verlag; 1981. p. 175-80.
24. Yoshihara M, Inoue N, Sanjo T, Yamazaki Z, Okada Y, Oda T. Plasmapheresis in acute liver failure. In: Nose Y, Malchelsky P, Smith J, Krakauer R, editors. *Plasmapheresis therapeutic applications and new techniques*. New York, NY: Raven Press; 1983. p. 399-406.
25. Clemmesen JO, Kondrup J, Nielsen LB, Larsen FS, Ott P. Effects of high-volume plasmapheresis on ammonia, urea, and amino acids in patients with acute liver failure. *Am J Gastroenterol* 2001;96:1217-23.
26. Yoshihara M, Yamada H, Yoshikawa Y, Fujiwara K, Toda G, Oka H, Sanjo T *et al*. Hemodiafiltration treatment of deep hepatic coma by protein passing membrane: case report. *Artif Organs* 1986;10:417-9.
27. Sadahiro T, Hirasawa H, Oda S, Shiga H, Nakanishi K, Kitamura N *et al*. Usefulness of plasma exchange plus continuous hemodiafiltration to reduce adverse effects associated with plasma exchange in patients with acute liver failure. *Crit Care Med* 2001;29:1386-92.
28. Schechter DC, Nealon TF Jr, Gibbon JH Jr. A simple extracorporeal device for reducing elevated blood ammonia levels: preliminary report. *Surgery* 1958;44:892-7.
29. Gazzard BG, Weston MJ, Murray-Lyon IM, Flax H, Record CO, Williams R *et al*. Charcoal haemoperfusion in the treatment of fulminant hepatic failure. *Lancet* 1974;1:1301-7.
30. Yamazaki Z, Fujimori Y, Sanjo K, Kojima Y, Sugiura M, Wada T *et al*. New artificial liver support (Plasma perfusion detoxification) for hepatic coma. *Artif Organs* 1977;2:273-6.
31. Sakai T, Fujiwara K, Yoshihara M, Torii M, Hayashi S, Takatsuki K *et al*. Treatment of fulminant hepatitis with charcoal plasma perfusion. *Saishin Igaku* 1979;34:2542-7.

32. Yoshiba M, Sanjo K, Yamazaki Z, Inoue N, Sakai T, Okada Y. Aggravation of coagulation abnormality by charcoal plasma perfusion in dogs with experimental acute liver failure. *Acta Hepatol Jpn* 1983;24:426-31.
33. Novelli G, Rossi M, Pretagostini R, Poli L, Novelli L, Berloco P *et al*. MARS (Molecular Adsorbent Recirculating System): experience in 34 cases of acute liver failure. *Liver* 2002;22(Suppl 2):43-7.
34. Tan HK. Molecular adsorbent recirculating system (MARS). *Ann Acad Med Singapore* 2004;33:329-35.
35. Opolon P. Significance of middle molecules in the pathogenesis of hepatic encephalopathy. In: Kleinberger G, editor. *Advances in hepatic encephalopathy and urea cycle diseases*. Basel: Karger, 1984. p. 310-3.
36. Denis J, Opolon P, Nusinovic V, Granger A, Darnis F. Treatment of encephalopathy during fulminant hepatic failure by haemodialysis with high permeability membrane. *Gut* 1978;19:787-93.
37. Silk DB, Trewby PN, Chase RA, Mellon PJ, Hanid MA, Davies M *et al*. Treatment of fulminant hepatic failure by polyacrylonitrile-membrane haemodialysis. *Lancet* 1977;2:1-3.
38. Kunitomo T. Development of new artificial kidney systems (Carl W. Walter). *Am J Surg* 1984;148:594-8.
39. Yoshiba M, Sekiyama K, Iwamura Y, Sugata E. Development of reliable artificial liver support (ALS) — plasma exchange in combination with hemodiafiltration using high-performance membranes. *Dig Dis Sci* 1993;38:469-76.
40. Inaba S, Kishikawa T, Zaito A, Ishibashi H, Kudo J, Ogawa R, Yoshiba M. Continuous haemoperfusion for fulminant hepatic failure. *Lancet* 1991;338:1342-3.
41. Iizuka K, Kanesaka S, Akizawa T, Niikura K, Kadokawa M, Takahashi Y *et al*. Artificial liver support for the treatment of fulminant viral hepatic failure. *Jpn J Apheresis* 1995;14:13-5.
42. Sekido H, Matsuo K, Takeda K, Ueda M, Morioka D, Kubota T, Tanaka K *et al*. Usefulness of artificial liver support for pretransplant patients with fulminant hepatic failure. *Transplant Proc* 2004;36:2355-6.
43. Matsuhara S, Okabe K, Ouchi K, Miyazaki Y, Yajima Y, Suzuki H *et al*. Continuous removal of middle molecules by hemofiltration in patients with acute liver failure. *Crit Care Med* 1990;18:1331-8.
44. Yonekawa C, Nakae H, Tajimi K, Asanuma Y. Effectiveness of combining plasma exchange and continuous hemodiafiltration in patients with postoperative liver failure. *Artif Organs* 2005;29:324-8.
45. Nakae H, Yonekawa C, Wada H, Asanuma Y, Sato T, Tanaka H. Effectiveness of combining plasma exchange and continuous hemodiafiltration (combined modality therapy in a parallel circuit) in the treatment of patients with acute hepatic failure. *Ther Apher* 2001;5:471-5.
46. Nakae H, Asanuma Y, Tajimi K. Cytokine removal by plasma exchange with continuous hemodiafiltration in critically ill patients. *Ther Apher* 2002;6:419-24.
47. Eiseman B, Liem DS, Raffucci F. Heterologous liver perfusion in treatment of hepatic failure. *Ann Surg* 1965;162:329-45.
48. Demetriou AA, Brown RS Jr, Busuttil RW, Fair J, McGuire BM, Rosenthal P *et al*. Prospective, randomized, multicenter, controlled trial of a bioartificial liver in treating acute liver failure. *Ann Surg* 2004;239:660-7; discussion 667-70.
49. Millis JM, Cronin DC, Johnson R, Conjeevaram H, Conlin C, Trevino S *et al*. Initial experience with the modified extracorporeal liver-assist device for patients with fulminant hepatic failure: system modifications and clinical impact. *Transplantation* 2002;74:1735-46.
50. Rozga J, Podesta L, LePage E, Morsiani E, Moscioni AD, Hoffman A *et al*. A bioartificial liver to treat severe acute liver failure. *Ann Surg* 1994;219:538-44; discussion 536-44.
51. Kuddus R, Patzer JF 2nd, Lopez R, Mazariegos GV, Meighen B, Kramer DJ *et al*. Clinical and laboratory evaluation of the safety of a bioartificial liver assist device for potential transmission of porcine endogenous retrovirus. *Transplantation* 2002;73:420-9.
52. Mazzoni A, Pardi C, Bortoli M, Uncini Manganello C, Vanacore R, Urciuoli P, Biancofiore G *et al*. High-volume plasmaexchange: an effective tool in acute liver failure treatment. *Int J Artif Organs* 2002;25:814-5.
53. Shin K, Nagai Y, Hirano C, Kataoka N, Ono I, Yamamura E *et al*. Survival rate in children with fulminant hepatitis improved by a combination of twice daily plasmapheresis and intensive conservative therapy. *J Pediatr Gastroenterol Nutr* 1989;9:163-6.
54. Biancofiore G, Bindi LM, Urbani L, Catalano G, Mazzoni A, Scatena F *et al*. Combined twice-daily plasma exchange and continuous veno-venous hemodiafiltration for bridging severe acute liver failure. *Transplant Proc* 2003;35:3011-4.
55. Chapman RW, Forman D, Peto R, Smallwood R. Liver transplantation for acute hepatic failure? *Lancet* 1990;335:32-5.
56. Peters RL. Viral hepatitis: a pathologic spectrum. *Am J Med Sci* 1975;270:17-31.
57. Fujiwara K. The annual report of fulminant hepatitis and late onset hepatic failure 1998-2003. The report from the Committee for Intractable Liver Diseases supported by the Ministry of Health and Labor of Japan 2005;93-107.
58. Sadamori H, Yagi T, Inagaki M, Shima Y, Matsuda H, Tanaka N *et al*. High-flow-rate haemodiafiltration as a brain-support therapy preceding to liver transplantation for hyperacute fulminant hepatic failure. *Eur J Gastroenterol Hepatol* 2002;14:435-9.
59. Butterworth RF. Brain edema in acute liver failure. *Indian J Gastroenterol* 2003;22(Suppl 2):559-61.
60. Norenberg MD, Rao KV, Jayakumar AR. Mechanisms of ammonia-induced astrocyte swelling. *Metab Brain Dis* 2005;20:303-18.
61. Inoue K, Kourin A, Watanabe T, Yamada M, Yasuda H, Yoshiba M. Plasma exchange in combination with online-hemodiafiltration as a promising method for purifying the blood of fulminant hepatitis patients. *Hepatol Res* [In press].
62. Inoue K, Yoshiba M. Apheresis treatment of hyperacute type of fulminant hepatitis. *Japanese Journal of Apheresis* 2006;25(Suppl.):72.
63. Inoue K, Yoshiba M. Liver transplantation and apheresis treatment in the treatment of fulminant hepatic failure. *Japanese Journal of Apheresis* 2006;25(Suppl.):109.
64. Inoue J, Ueno Y, Kanno N, Anzai H, Kondo Y, Moritoki Y *et al*. Living related liver transplantation for acute fulminant hepatitis B: experience from two possible hyper-acute cases. *Tohoku J Exp Med* 2005;205:197-204.



Japanese-Style Intensive Medical Care Improves Prognosis for Acute Liver Failure and the Perioperative Management of Liver Transplantation

K. Inoue, T. Watanabe, N. Maruoka, Y. Kuroki, H. Takahashi, and M. Yoshiba

ABSTRACT

The Japanese style of intensive medical care for acute liver failure has yielded high survival rates. The care system comprises artificial liver support (ALS) together with treatment for the underlying disease. Plasma exchange in combination with high-volume hemodiafiltration using an high performance membrane has become the standard ALS system. It is safe, efficiently removing more low and middle molecular weight toxic substances than other methods because of the large volumes of buffer (more than 200 L per session), resulting in recovery from coma in patients with severe fulminant hepatitis, a status comparable with the hepatic state. This ALS is therefore an effective tool to sustain patients with fulminant hepatitis in a favorable condition until liver function recovers or liver transplantation becomes available. The accompanying treatment for underlying disease serves to limit the liver destruction that hampers regeneration. The treatment has remarkably improved the prognosis for patients with subacute types of fulminant hepatitis, which generally carry a less favorable prognosis than the acute type. This treatment system thus provides more time for physicians to assess the indications for liver transplantation as well as giving the patient a greater chance of undergoing transplantation.

THE LIVER has a great capacity for regeneration, matched only by bone marrow and skin. Vigorous regenerative activity is illustrated by the fact that the liver almost regains its original size within a month after extensive hepatectomy. Thus, living-donor liver transplantation (LDLT) has been successfully performed as an alternative to cadaveric donor liver transplantation (CDLT). In recent years, adult patients with end-stage liver diseases have received grafts containing approximately two thirds of the whole liver.¹

Fulminant hepatitis (FH) is characterized by sudden, severe liver dysfunction leading to coagulopathy and hepatic encephalopathy despite no known underlying liver disease. In Western countries the onset of coma within 8 weeks from the first sign of symptoms is a widely accepted diagnostic criterion.² Many therapeutic efforts have obtained high survival rates in FH, although orthotopic liver transplantation (OLT) including LDLT is currently the only reliable treatment; it results in 60% to 80% survival rates.³ However, OLT is expensive, and recipients shoulder the adverse effects of life-long immunosuppression. In cases of LDLT, donors also often experience serious physical and

mental stress.⁴ Furthermore, the increasing incidence of end-stage liver disease has meant that the number of patients awaiting liver transplantation has far outgrown the number of available grafts. Priority for graft distribution has always been based on urgency. Patients with FH are ranked first; therefore, it is essential to avoid unnecessary liver transplantation.

In Japan, intensive medical care for FH was developed originally to meet specific circumstances. The major principle of this care system is an artificial liver support (ALS) system comprising plasma exchange and hemodiafiltration using huge buffer volume.⁵ ALS is effective for safely sustaining patients in good condition; Over 90% of patients treated in this fashion regain consciousness.⁶ After establishing the ALS, we also developed a treatment regime for the underlying hepatitis, which is often neglected except for

From the Division of Gastroenterology, Showa University Fujigaoka Hospital, Yokohama, Japan.

Address reprint requests to Kazuaki Inoue, MD, PhD, Showa University Fujigaoka Hospital, 1-30 Fujigaoka, Aoba-ku 227-8501, Yokohama, Japan. E-mail: kazu-inoue@med.showa-u.ac.jp

Table 1. Survival Rate of Fulminant Hepatitis by Intensive Medical Care

Type	Cause	HAV, n (%)	HBV (acute), n (%)	HBV (carrier), n (%)	Non-A~Non-G, n (%)	Drug, n (%)	Autoimmune Hepatitis (AIH), n (%)	Total, n (%)
Hyper-acute			0/3 (0)					0/3 (0)
Acute		17/18 (94)	15/18 (83)	0/1 (0)	3/4 (75)	1/1 (100)		36/42 (86)
Subacute		1/1 (100)	3/3 (100)	10/11 (91)	14/22 (64)	2/4 (50)	2/4 (50)	32/45 (71)
Subtotal		18/19 (95)	18/24 (75)	10/12 (83)	17/26 (65)	3/5 (60)	2/4 (50)	68/90 (76)
LOHF				1/1 (100)	5/12 (42)	1/1 (100)	1/2 (50)	8/16 (50)
Severe acute hepatitis		6/6 (100)	10/10 (100)	15/15 (100)	14/16 (86)	4/4 (100)	2/2 (100)	51/53 (96)
Total		26/28 (93)	28/36 (78)	34/64 (53)	36/54 (67)	8/10 (80)	5/8 (63)	137/200 (69)

NOTE: One of 3 hyper-acute type underwent living donor liver transplantation and survived. Four of 13 patients with fulminant hepatitis subacute type who failed to respond intensive medical care underwent living donor liver transplantation and 2 of 4 survived.
HAV, hepatitis A virus; HBV, hepatitis B virus; LOHF, late-onset hepatic failure.

the administration of N-acetylcysteine (NAC) in cases of paracetamol intoxication. When liver destruction is progressive or persistent, the liver never regenerates despite its inherent regenerative capability.⁷

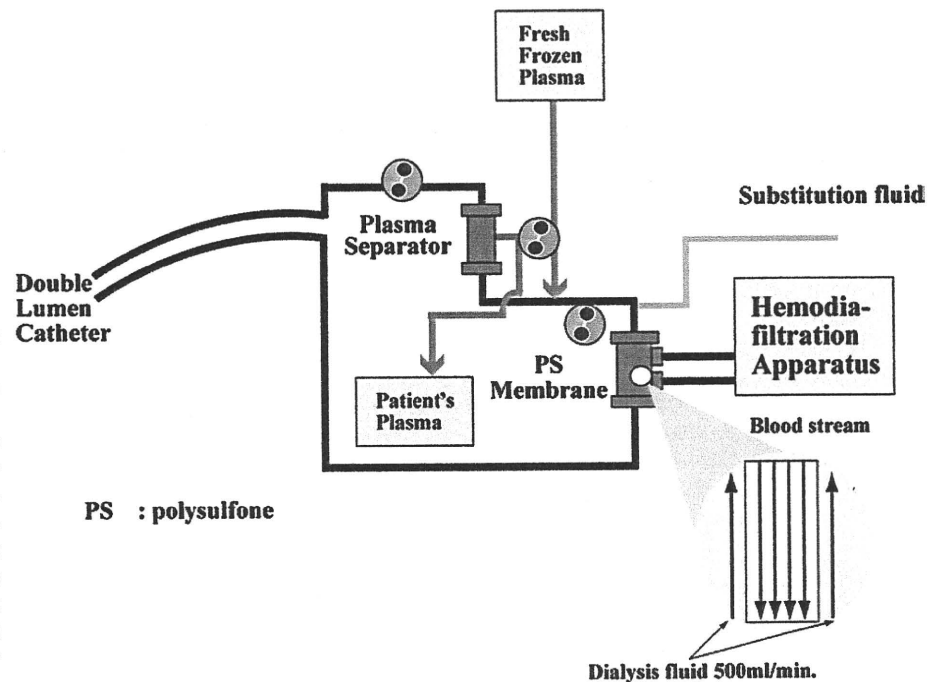
Herein, we have reported excellent outcome of the Japanese intensive medical care system for patients with FH. This study also evaluated physicians' ability to assess indications for OLT in FH to ensure appropriate use of the limited organs available.

PATIENTS AND METHODS

Our study group of 159 patients comprised 90 cases of FH, 16 of late-onset hepatic failure (LOHF), and 53 of severe acute hepatitis (SAH). FH was defined by the development of coagulopathy (equal to or less than 40% of prothrombin time) and hepatic encephalopathy (HE; grade II or greater) within 8 weeks of symptom onset among patients without a known underlying liver disease. Development of HE within 10 days was defined as FH acute type and, after 11 days, as FH subacute type. We also

defined a FH hyper-acute type, namely liver failure comparable with an ahepatic state that developed within 5 days of the initial symptom. The ahepatic state was characterized by severe impairment of urea cycle and bilirubin conjugation, requiring a blood urea nitrogen less than 1 mg/dL and direct bilirubin to total bilirubin ratio less than 0.1. LOHF was defined by the development of the same HE and coagulopathy as FH within 8 to 24 weeks of symptom onset. SAH was defined by the same coagulopathy as FH but without or with grade I HE (Table 1). Immediately after the onset of hepatic coma, patients were placed on ALS involving plasma exchange and hemodiafiltration using high-performance membranes and huge volumes of buffer (Fig 1). Treatment for underlying hepatitis consisted of immunosuppressive therapy using a methylprednisolone pulse followed by withdrawal and continuous infusion of cyclosporine (Fig 2). Antiviral treatment comprised interferon beta (IFN- β) and/or Entecavir (ETV). The indication for IFN- β was a patient whose underlying disease entailed persistent viral replication including indeterminate cases when autoimmunity or drugs had been excluded as the etiology. The indication for ETV was a

Fig 1. Circuit diagram of plasma exchange in combination with hemodiafiltration using high-performance polysulfone membrane. Substitution fluid comprising ultra-pure water and high-quality concentrate was infused in the predilution mode at 15 to 20 L/h concomitantly with dialysate at a flow rate of 500 mL/min. The substitution fluid was supplied through a hygienic flow path. The hemodiafilter used was Toraysulfone TS-BP1.8L (Toray Medical Co, Tokyo, Japan). The anticoagulant for the artificial liver support was nafamostat mesilate (Futhan; Torii, Tokyo, Japan) at a priming dose of 30 mg and at a continuous dose of 30 mg/h.



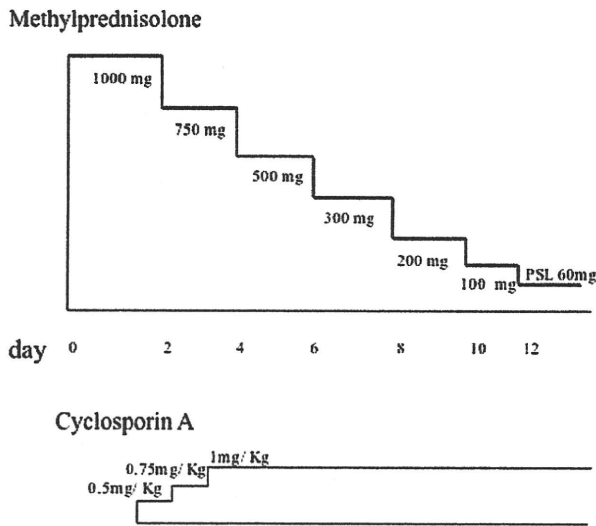


Fig 2. Immunosuppressive protocol comprised a methylprednisolone pulse followed by a slow withdrawal and continuous infusion of cyclosporin A. The target level of cyclosporin A was 250 to 350 ng/mL.

patient whose underlying disease was persistent hepatitis B virus (HBV) replication (Fig 3).

RESULTS

Of the 90 FH cases, 3 were the hyper-acute type; all had acute hepatitis B virus (HBV) infections and had progressed to severe liver failure comparable with an ahepatic state. They were immediately placed on ALS including PE and HDF, which sustained them in a good condition. One of the 3 patients subsequently survived LDLT. Although the ALS system sustained the other 2 patients in favorable condition for more than 2 weeks, they subsequently died because an organ donor could not be found.

Other FH cases included 42 acute-type FH, most of whom had acute infections with hepatitis A virus or HBV; among them, 36/42 (86%) survived ALS. The remaining 45 patients were FH subacute type with 32 (71%) surviving after placement on the ALS system and undergoing treatment for the underlying liver disease. Among the remaining 13 patients four underwent LDLT and 2 were survivors. The survival rate of LOHF patients under the same treatment as FH subacute type was 50% (8/16). Among the 53 SAH patients, 51 survived (96%) with 2 succumbing to a fungal infection or aggravation of malignant lymphoma. After several ALS sessions, 109 of 116 (94%) patients regained consciousness. The 2-week survival rate was 107 of 116 (92%). Brain edema observed in a few cases was reversible by several sessions of ALS in most cases.

DISCUSSION

We attained high survival rates among FH patients using the Japanese style of intensive medical care. Several blood purification methods have been developed in Japan since

the late 1970s. The first method of PE was effective to replenish depleted plasma components, especially coagulation factors, but was of limited effectiveness to remove substances displaying a large body pool such as glutamine (Gln), which causes brain edema.⁸ For the efficient, safe removal of low and middle molecular substance with large body pools, we developed HDF using large-pore high-performance membranes. More than 90% of unselected patients treated in this way regained full alertness. Brain edema and renal failure are regarded as destined complications of FHF. They are seen in only a few percent of patients and are mostly reversible. Our ALS system uses more than 200 L of buffer per session to cleanse the patient's blood. Removal of Gln clearly depends on the buffer volume per session. Under HDF using high-volume buffers, monitoring of intracranial pressure and cerebral blood flow becomes unnecessary. This strategy also increases the time for clinicians to judge whether liver transplantation is indicated, thus avoiding unnecessary procedures.

We divided cases of FH into transient and persistent types based on the mode of infection. The Transient type is characterized by a rapid eradication of causal viruses like HAV and acute HBV infection. The persistent type is typified by persistent or even chronic replication of causal viruses such as in HBV carriers because of HCV, HDV, and presumably non-A-non-G virus. Interestingly, the majority of patients with acute type of FH according to the Japanese criteria, namely, coma occurring within 10 days of first onset of symptoms, was of the transient type; whereas most subacute-type FH patients were the persistent type.

Hepatitis treatment differs between the transient and persistent type. In FH acute type, effective ALS causes liver destruction to cease spontaneously with eradication of the causal virus resulting in rapid recovery and survival. Among our 42 patients, 36 patients (86%) survived without liver transplantation. Exceptional cases are the hyper-acute type whose liver progresses into an ahepatic state as exemplified by a rapid loss of direct bilirubin and blood urea nitrogen. PE in combination with HDF was an effective tool to sustain patients in a favorable condition allowing physicians time to find a donor organ. In the present study, 1 patient of this type was fortunate enough to receive an LDLT in time. In the persistent type, which corresponds to the FH subacute condition, liver damage must be limited to prevent destruction beyond the limit of regeneration. In our experience between 1986 and 1993, only 38% of patients with

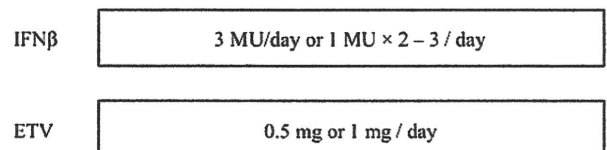


Fig 3. Antiviral treatment comprised interferon β and Entecavir. Interferon β was administered 3 MU daily or 2 or 3 times of 1 MU daily. Entecavir was administered 0.5 mg or 1 mg daily. IFN, interferon; ETV, Entecavir.

the persistent type finally survived despite more than 90% of them regaining full alertness (data not shown). Confronted by this insufficient result, we originally elaborated the treatment to terminate liver destruction of the latter type. Because viral replication is persistent in this type, we have administered IFN universally for cases presumed to be viral hepatitis and a nucleotide/nucleoside analogue for FH because of persistent HBV infection. For the indeterminate cases, we administered IFN on the assumption that it was related to a viral infection of some type. In combination with antivirals, we administer immunosuppressive agents that dampen host cytotoxic immunologic reactions in FH. Figure 2 illustrates the scheme of our immunosuppressive treatment, for which we have already presented some preliminary results.⁷ The combination therapy seeks to rapidly reduce transaminase levels. After establishing the treatment for the underlying disease, the survival rate among patients with the persistent type of FH increased to 71% (32/45) in the present study.

In conclusion, The Japanese treatment system remarkably improved the prognosis of acute liver failure. The treatment system sustained patients in good condition until

the liver recovered or an adequate donor was found, allowing more appropriate perioperative management and determination of organ allocation.

REFERENCES

1. Liu CL, Fan ST, Lo CM, et al: Right-lobe live donor liver transplantation improves survival of patients with acute liver failure. *Br J Surg* 89:317, 2002
2. Trey C, Davidson CS: The management of fulminant hepatic failure. *Prog Liver Dis* 3:282, 1970
3. Sass DA, Shakil AO: Fulminant hepatic failure. *Liver Transpl* 11:594, 2005
4. Northup PG, Berg CL: Living donor liver transplantation: the historical and cultural basis of policy decisions and ongoing ethical questions. *Health Policy* 72:175, 2005
5. Inoue K, Kourin A, Watanabe T, et al: Artificial liver support system using large buffer volumes removes significant glutamine and is an ideal bridge to liver transplantation. *Transplant Proc* 41:259, 2009
6. Yoshihara M, Inoue K, Sekiyama K, et al: Favorable effect of new artificial liver support on survival of patients with fulminant hepatic failure. *Artif Organs* 20:1169, 1996
7. Yoshihara M: Recent progress in the treatment of fulminant hepatic failure in Japan. *J Infect Chemother* 4:41, 1998
8. Blei AT: Pathophysiology of brain edema in fulminant hepatic failure, revisited. *Metab Brain Dis* 16:85, 2001

Detection of Hepatitis B and C Viruses in Almost All Hepatocytes by Modified PCR-Based *In Situ* Hybridization[▽]

Hideko Nuriya,¹ Kazuaki Inoue,^{1,2} Takeshi Tanaka,³ Yukiko Hayashi,⁴ Tsunekazu Hishima,⁴ Nobuaki Funata,⁴ Kyosuke Kaji,⁵ Seishu Hayashi,³ Shuichi Kaneko,⁵ and Michinori Kohara^{1*}

Department of Microbiology and Cell Biology, Tokyo Metropolitan Institute of Medical Science, 2-1-6 Kamikitazawa, Setagaya-ku, Tokyo 156-0057, Japan¹; Division of Gastroenterology, Showa University Fujigaoka Hospital, 1-30 Aoba-ku, Fujigaoka, Yokohama 227-8501, Japan²; Liver Unit, Tokyo Metropolitan Komagome Hospital, 3-18-22 Honkomagome, Bunkyo-ku, Tokyo 113-8613, Japan³; Department of Pathology, Tokyo Metropolitan Komagome Hospital, 3-18-22 Honkomagome, Bunkyo-ku, Tokyo 113-8613, Japan⁴; and Department of Gastroenterology, Kanazawa University Graduate School of Medical Science, Ishikawa 920-8641, Japan⁵

Received 28 February 2010/Returned for modification 22 April 2010/Accepted 16 August 2010

Although PCR-based *in situ* hybridization (PCR-ISH) can be used to determine the distribution and localization of pathogens in tissues, this approach is hampered by its low specificity. Therefore, we used a highly specific and sensitive PCR-ISH method to reveal the lobular distribution and intracellular localization of hepatitis B virus (HBV) and HCV in chronic liver disease and to clarify the state of persistent HBV and HCV infection in the liver. HBV genomic DNA was detected in almost all hepatocytes, whereas HBV RNA or protein was differentially distributed only in a subset of the HBV DNA-positive region. Further, HCV genomic RNA was detected in almost all hepatocytes and was localized to the cytoplasm. HCV RNA was also detected in the epithelium of the large bile duct but not in endothelial cells, portal tracts, or sinusoidal lymphocytes. In patients with HBV and HCV coinfection, HCV RNA was localized to the noncancerous tissue, whereas HBV DNA was found only in the cancerous tissue. Using this novel PCR-ISH method, we could visualize the staining pattern of HBV and HCV in liver sections, and we obtained results consistent with those of real-time detection (RTD)-PCR analysis. In conclusion, almost all hepatocytes are infected with HBV or HCV in chronic liver disease; this finding implies that the viruses spread throughout the liver in the chronic stage.

Hepatitis B virus (HBV) and hepatitis C virus (HCV) are the primary causative agents of chronic liver disease (2, 9, 17). HBV infection remains a global health problem; it is estimated that 350 million individuals are persistently infected with the virus and that approximately 15% to 25% of these individuals will die due to the sequelae of the infection (23, 29). Further, more than 170 million people are infected with HCV worldwide (21). HCV has a single-stranded RNA genome (8, 19), does not have canonical oncogenes, and can easily establish chronic infection without integration into the host genome (3, 20), resulting in hepatic steatosis and hepatocellular carcinoma (HCC) (28). The viruses share a similar route of transmission, such as via the transfusion of infected blood or body fluids or use of contaminated needles.

Several studies have shown that 10% to 35% of the individuals infected with HBV also have HCV infection, although the prevalence varies depending on the population studied (4, 32, 34). The relationship between coinfection and acceleration of malignant transformation remains unclear, but HBV and HCV coinfection seems to alter the natural history of both HBV-related and HCV-related liver disease (2, 12). HCV has been shown to inhibit HBV gene expression (7, 15). The high prevalence of occult HBV infection may indicate that HCV also

inhibits HBV replication (34). Most epidemiological studies of HBV have been performed by using diagnostic serological assays (16). We recently used a novel, highly sensitive diagnostic PCR method to demonstrate that the HBV genome is detectable in the sera of a substantial proportion of patients with chronic HCV infection who are seronegative for the standard HBV-related markers (1, 34). Further, we reported the levels of HBV DNA and HCV RNA in cancerous and noncancerous liver tissue using real-time detection (RTD)-PCR (34). RTD-PCR is an accurate assay method, but it can determine the levels of genomic DNA and RNA only in homogenized tissue. In this study, we developed a PCR-based *in situ* hybridization (PCR-ISH) method for detecting and visualizing HBV DNA, HBV RNA, and HCV RNA and comparing their protein expression patterns, with the aim to reveal the lobular distribution and intracellular localization of HBV and HCV in chronic liver disease and to clarify the state of persistent HBV and HCV infection in the liver.

MATERIALS AND METHODS

Patients. Twenty-nine patients were admitted to Tokyo Metropolitan Komagome Hospital for the treatment of hepatic tumors. Of these patients, 14 were considered to have chronic HCV infection (persistently positive results for HCV antibody), 8 were diagnosed with chronic hepatitis B (persistently positive results for HBV surface antigen [HBsAg]), and 7 showed negative results for both viral markers but had metastatic liver cancer (6 with colonic cancer and 1 with gastric cancer). We used four samples from seven patients as controls for PCR-ISH and four samples from seven patients as controls for reverse transcriptase PCR (RT-PCR)-ISH (Table 1). Of the 14 patients with chronic hepatitis C, two showed positive results for HBV DNA by RTD-PCR. HBsAg and second-generation HCV antibody were measured by using enzyme-linked immunosor-

* Corresponding author. Mailing address: Department of Microbiology and Cell Biology, The Tokyo Metropolitan Institute of Medical Science, 2-1-6, Kamikitazawa, Setagaya-ku, Tokyo 156-8506, Japan. Phone: 81-3-5316-3232. Fax: 81-3-5316-3137. E-mail: kohara-mc@igakuken.or.jp.

[▽] Published ahead of print on 25 August 2010.

TABLE 1. Patient profiles and results of the present study

Patient no.	Age (yr)	Gender ^a	HCV antibody	HBs Ag	Liver histology	RT-PCR-ISH HCV	PCR-ISH HBV	Serum HBV DNA (copies/ml) ^b	Serum HCV RNA		IFN treatment	Note
									Copies/ml	KIU/ml ^d		
1	53	M	-	+	A2F3		+	1.1 × 10 ²			-	
2	42	M	-	+	A2F2		+	4.0 × 10 ⁵			-	Fig. 2A
3	43	M	-	+	A2F3		+	1.6 × 10 ⁷			-	
4	53	M	-	+	A2F4		+	6.4 × 10 ³			-	Fig. 1A
5	55	M	-	+	A2F3		+	1.0 × 10 ³			-	Fig. 3A
6	54	M	-	+	A2F4	-	+	NT ^c			-	
7	31	M	-	+	A3F3		+	3.0 × 10 ⁹			+	
8	61	F	-	+	A3F3		+	NT			-	
9	63	M	+	-	A3F4	+	-		5.6 × 10 ⁶		-	Fig. 4D
10	56	M	+	-	A2F3	+	-		NT		+	
11	67	F	+	-	A3F4	-	-		NT		-	
12	73	M	+	-	A2F4	+	-		1.2 × 10 ⁶		-	Fig. 1B
13	68	F	+	-	A3F4	+	-		1.1 × 10 ⁶		-	
14	76	F	+	-	A2F4	+	-		9.5 × 10 ⁵		-	Fig. 4A
15	62	M	+	-	A2F3	+	-		7.2 × 10 ⁵		-	
16	65	M	+	-	A3F4	+	-		NT		-	
17	60	F	+	-	A3F4	+	-			41	-	
18	48	F	+	-	A2F1	+	-		7.6 × 10 ⁶	>850	-	Fig. 4C
19	43	M	+	-	A2F3	+	-			389	-	
20	59	M	+	-	A2F3	+	-			>850	-	
21	72	F	+	-	A2F4	+	+	3.9 × 10 ¹	5.0 × 10 ⁷			Fig. 5
22	69	M	+	-	A2F3	+	+	5.0 × 10 ¹	3.0 × 10 ⁷			
23	69	M	-	-	Normal	-	-					Gastric cancer
24	58	M	-	-	Normal	-	-					Colon cancer
25	58	M	-	-	Normal	-	-					Colon cancer
26	59	F	-	-	Normal	-	-					Colon cancer
27	65	M	-	-	Normal	-	-					Colon cancer
28	47	M	-	-	Normal	-	-					Colon cancer
29	81	F	-	-	Normal	-	-					Colon cancer

^a M, male; F, female.^b Serum HBV DNA was positive in patients 21 and 22.^c NT, not tested.^d KIU, kilo international units.

bent assay (ELISA) kits (Abbott Laboratories, Chicago, IL, and International Reagent Corp., Kobe, Japan, respectively). All 29 patients underwent hepatic resection. Histological evaluation of the liver was carried out according to the METAVIR scoring system (3).

Ethical approval. The Institutional Review Board of Tokyo Metropolitan Komagome Hospital approved the study. Written informed consent was obtained from all the subjects.

Sample preparation. The liver tissue samples for HBV DNA detection were fixed in 10% buffered formalin (pH 7.4) for 18 h, embedded in paraffin, cut into 6- μ m-thick sections, and mounted on silane-coated glass slides for use with a GeneAmp *in situ* PCR system 1000 unit (Applied Biosystems, Foster City, CA). The slides were washed thrice in xylene for 8 min at each washing, rinsed thrice in 99.5% ethanol and 75% ethanol for 5 min at each rinsing, and rehydrated in distilled water for deparaffinization. For detecting HBV mRNA and HCV RNA, OCT-embedded frozen liver tissue samples were cut into 10- μ m-thick sections and mounted on silane-coated glass slides. They were then fixed in 10% buffered formalin (pH 7.4) for 17 to 21 h, rinsed twice in distilled water treated with 0.01% diethylpyrocarbonate (DEPC) for 2 min at each rinse, rinsed in 99.5% ethanol for 1 min, and then air dried and stored at -80°C until use. The tissue sections on the glass slides were digested with proteinase K (1 to 30 μ g/ml and 1 to 200 μ g/ml for the noncancerous and cancerous regions of the paraffin-embedded sections, respectively; 0.008 to 1.0 μ g/ml for the frozen sections) in 50 mM Tris (pH 7.5) at 37°C for 30 min in a humidified chamber. Subsequently, proteinase K was inactivated at 97°C for 10 min, and then the sections were rinsed with distilled water, dehydrated in 99.5% ethanol, and air dried.

Primers and probes for PCR-ISH and RT-PCR-ISH. The primers used to amplify the S and X regions of HBV and the 5' untranslated region (5'-UTR) of HCV as well as the corresponding probes are listed in Table 2. We created a

digoxigenin (DIG)-dUTP tail at the 3' end of the 5'-DIG probe using a DNA tailing kit (Roche, Basel, Switzerland).

PCR-ISH for detecting HBV DNA. PCR was performed by using one of two sets of antisense and sense primers complementary to the sequences located in the S and X regions of HBV. The PCR mixture contained 10 mM Tris-HCl (pH 8.3), 50 mM KCl, 3.0 mM MgCl₂, 0.8 mM each primer, 197 mM deoxynucleoside triphosphates (dNTPs), and 10 U/50 μ l *Taq* DNA polymerase (AmpliTaq Gold; Applied Biosystems).

The tissue slides were warmed to 70°C, and 50 μ l of the PCR mixture was overlaid onto the proteinase K-treated tissue specimens. An Ampli cover disc with Ampli cover clips (Applied Biosystems) was attached to each specimen. The slides were placed in the GeneAmp *in situ* PCR system 1000 unit at 70°C. PCR was performed at 95°C for 10 min, followed by 35 to 55 cycles at 95°C for 30 s and 60°C for 2 min and a final extension at 72°C for 10 min. Immediately after the PCR, the slides were fixed in 4% paraformaldehyde in phosphate-buffered saline (PBS) for 10 min at 37°C, washed in 2 \times SSC (1 \times SSC is 0.15 M NaCl plus 0.015 M sodium citrate) for 2 min, rinsed with distilled water for 2 min, dehydrated in 99.5% ethanol for 1 min, and then air dried. ISH was performed by mixing the DIG-labeled probe (final concentration, 100 ng/ml) with 65 μ l of hybridization buffer (50% deionized formamide, 4 \times SSC, 1 \times Denhardt's solution [0.2% bovine serum albumin {BSA}, 0.2% polyvinyl pyrrolidone, 0.2% Ficoll 400], 100 μ g/ml denatured salmon sperm DNA, 100 μ g/ml yeast RNA, and 1 mM EDTA) and then adding the mixture to each section, heating to 97°C for 10 min, and cooling to 37°C in decrements of 1°C/min (27). Hybridization was carried out overnight at 37°C. Stringency washes were conducted with the following: 2 \times SSC twice for 10 min at 37°C, 0.03 \times SSC for 10 min at 50°C, 0.1% Triton X-100 in TBS (0.1 M Tris [pH 7.5], 0.1 M NaCl) for 10 min at room temperature, and TBS for 5 min at room temperature. After incubation in blocking reagent (0.1 M Tris

TABLE 2. Primers and probes for PCR-ISH and RT-PCR

Technique	Virus or protein (region)	Type	Description, nucleotides	Primer or probe	Sequence
PCR-ISH	HBV (HBs)	Primer	Forward (HB-166-S21), 166-186	5'-CACATCAGGATTCCTAGGACC-3'	
		Reverse (HB-344-R20), 344-325	5'-AGGTTGGTGGAGTGGATTGGAG-3'		
	HBV (HBx)	Probe	(HB-242-S45D), 242-286	5'-(DIG)-CAGAGTCTAGACTCGTGTGGACTTCTCAATTTTCTAAGGGGA-(DIG)n-3'	
		Primer	Forward (HB-1584-S21), 1584-1604	5'-CTTGGCTTCACTCTGCAACGT-3'	
RT-PCR-ISH	HCV (5'-UTR)	Probe	Reverse (HB-1744-R22), 1744-1722	5'-CCTGCTCTCCAGTCTTAA-3'	
		Primer	(HB-1705-R45D), 1705-1661	5'-(DIG)-TATGCTCTCAAGGTCGTTGACATTGCTGAGAGTCCAAAGAGTC-(DIG)n-3'	
TaqMan	HBV (S) HBV (X) HCV (5'-UTR)	Primer	Forward (R6-129-S19), 129-147	5'-CCGGGAGAGCCATAGTGGT-3'	
		Probe	Reverse (R6-290-R19), 290-272	5'-AGTACCAAGGCGCTTCC-3'	
		Probe	(R6-225-S45D), 225-269	5'-(DIG)-ATTGGGCGCTGCCCCCGGAGACTGCTAGCCGAGTACTGTTGGGT-(DIG)n-3'	
		Probe	Forward (HB-242-S26FT), 242-267	5'-CAGAGTCTAGACTCGTGTGGACTTC-3'	
		Probe	Forward (HB-1681-S25FT), 1681-1705	5'-TGTCAAGCAGCCGACCTTGAAGGCATA-3'	
		Primer	Forward (R6-130-S17), 130-146	5'-CGGAGAGCCATATGG-3'	
		Primer	Reverse (R6-290-R19), 290-272	5'-AGTACCAAGGCGCTTCC-3'	
		Probe	Forward (R6-148-S21FT), 148-168	5'-CTGGCGGAACCGGTGAGTACAC-3'	
		Primer	Forward (R6-ACT-1998-S20), 1998-2017	5'-CAATGTACATGTTGCATCT-3'	
		Probe	Reverse (R6-CT-2246-R24), 2246-2223	5'-GTGAGGATCTTCATGAGGATGCA-3'	
GAPDH	β-Actin (genomic DNA)	Primer	Forward (β-ACT-2063-S22FT), 2063-2084	5'-ACGTTGCTATCCAGGCTGTGCT-3'	
		Probe	Forward (GAPDH-514-S24), 514-537	5'-TGCAACCAACCACTGACCTTAACCC-3'	
		Primer	Reverse (GAPDH-837-R24), 837-814	5'-CTTGATGTCATCATATTTGGCAGG-3'	
		Probe	Forward (GAPDH-584-S23FT), 584-608	5'-TGACCAACAGTCCATGCCATCCTGC-3'	

[pH 7.5], 0.1 M NaCl, 10% sheep serum, 3% BSA) at room temperature for 15 min, the slides were covered with 100 μl anti-DIG antibody conjugated with alkaline phosphatase (Roche) and diluted at 1:900 with 1% BSA in TBS at 37°C for 60 min. After this reaction, the slides were washed twice (3 min each) with 0.1% Triton X-100 in TBS, then with TBS alone, and finally with APS (0.1 M Tris [pH 9.0], 0.1 M NaCl, 50 mM MgCl₂) at room temperature. The slides were incubated in 100 μl dye solution (338 μg/ml nitroblue tetrazolium chloride [NBT], 175 μg/ml 5-bromo-4-chloro-3-indolyl-phosphate 4-toluidine salt [BCIP], and 450 μM Levamisole [Vector Labs, Burlingame, CA] in APS) at 37°C in the dark. After sufficient color development, they were washed with deionized water for 1 min and then mounted with aqueous mounting medium.

RT-PCR-ISH for detecting HBV RNA. The OCT-embedded frozen sections were placed on glass slides. After proteinase K treatment, the tissue sections were digested with RNase-free DNase I (Roche; diluted to 3 U/μl in 0.1 M sodium acetate and 5 mM MgSO₄). The DNase I reaction mixture (66 μl) was overlaid onto the tissue sections, which were then enclosed in a frame. The slides were reacted in an aluminum box at 37°C for 20 min and inactivated at 97°C for 10 min. They were then washed in DEPC-treated water, dehydrated in 99.5% ethanol, and air dried.

Moloney murine leukemia virus (MMLV) reverse transcriptase (10 U/μl; Invitrogen, Carlsbad, CA) was used in a reaction mixture containing 10 mM Tris-HCl (pH 8.3), 50 mM KCl, 5.0 mM MgCl₂, 1 μM antisense primer, 1 mM dNTPs, 2 U/μl RNase inhibitor (Takara, Otsu, Japan), and 10 mM dithiothreitol (DTT). The specimens were then overlaid with the mixture, reacted at 42°C for 60 min, washed with distilled water, dehydrated in 99.5% ethanol, and air dried. The subsequent procedures were the same as described for PCR-ISH.

Immunohistochemical staining for detecting HBV proteins. Deparaffinized formaldehyde-fixed sections or fixed frozen liver tissue sections on glass slides were soaked in distilled water, digested with 0.1% pronase (protease P8038 XXIV; Sigma-Aldrich, Tokyo, Japan) for 1 min, and washed with PBS at room temperature. After 30 min of incubation in blocking reagent (1% BSA and 2.5 mM EDTA in PBS) at room temperature, the slides were reacted with 100 μl of anti-HBs and anti-HBc polyclonal antibody solutions for 3 h at room temperature and then overnight at 4°C. The following polyclonal antibodies were used: anti-HBs rabbit polyclonal antibody anti-HBc rabbit polyclonal antibody (Novocastra Laboratories, Newcastle, United Kingdom), or normal rabbit serum diluted in blocking reagent. After the reaction, the slides were washed four times with PBS at room temperature and incubated for 60 min at room temperature in 100 μl anti-rabbit IgG conjugated with peroxidase (Amersham ECL; GE Healthcare, Piscataway, NJ) diluted to 1:100 in blocking reagent. The slides were then washed four times with PBS at room temperature and stained by using 3,3'-diaminobenzidine tetrahydrochloride (DAB) (Vector Labs). Following counterstaining with Mayer's hematoxylin solution, the tissue specimens were dehydrated in 99.5% ethanol and 80% xylene. The slides were sealed by using Bioleil (Oken Shoji, Tokyo, Japan).

RT-PCR-ISH for detecting HCV RNA. HCV RNA was detected by using methods similar to those used for detecting HBV RNA except for the following steps: the DNase I step was omitted, and 1.5 mM MgCl₂ was used in the PCR mixture.

Primers and probe sets in RTD-PCR for quantifying HBV DNA, HCV RNA, β-actin DNA, and GAPDH mRNA. The primer sets to quantify the S and X regions of HBV were the same as those used for PCR-ISH. The TaqMan probes for these regions, the primers and probe designed to quantify the 5'-UTR of HCV (33), and those used to quantify β-actin genomic DNA and GAPDH (glyceraldehyde-3-phosphate dehydrogenase) mRNA (internal control) are shown in Table 2. Each PCR comprised 50 cycles (95°C for 30 s, 60°C for 40 s, and 72°C for 30 s) in a real-time PCR system (ABI Prism 7700 sequence detector system; Applied Biosystems).

Amplicor monitor assays. The Amplicor monitor assays were performed as described previously (22, 24, 33, 36).

HE staining. HBV- or HCV-infected deparaffinized formaldehyde-fixed sections or fixed frozen liver tissue sections were stained with hematoxylin and eosin (HE).

LCM of liver tissue. A frozen liver tissue sample was sectioned by using a cryostat and fixed in acetone, followed by HE staining. Laser capture microdissection (LCM) was performed by using an LM 200 system (Olympus, Tokyo, Japan) as described previously (6, 11). This procedure produced approximately 30 hepatocytes from each of three areas (perivenular, intermediate, and periportal) in the section. Total RNA was extracted from the LCM samples, and HCV RNA and GAPDH mRNA were quantified by RTD-PCR.

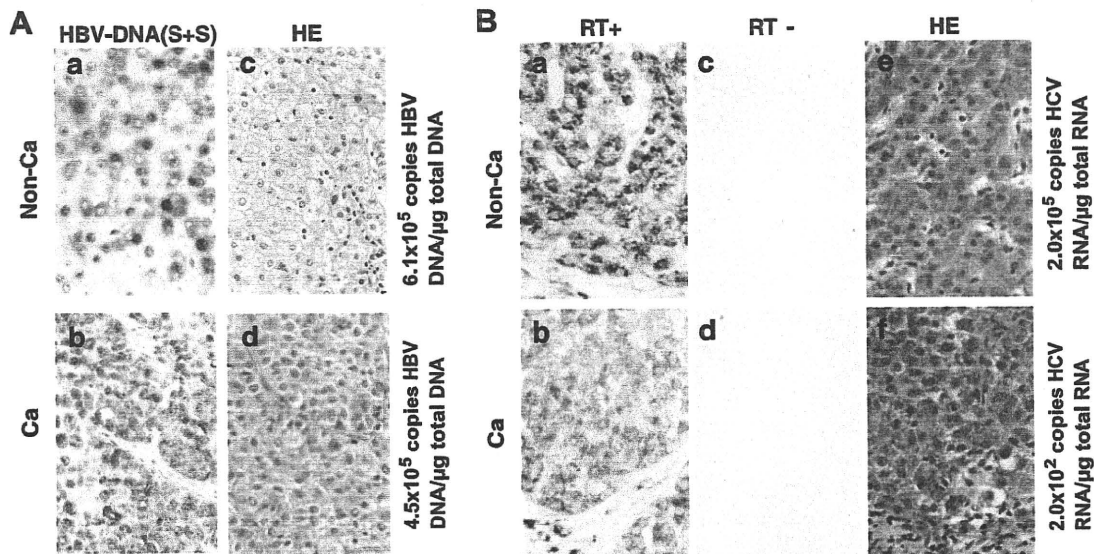


FIG. 1. (A) Panels a and b, HBV DNA detected by PCR-ISH and immunohistochemical staining in noncancerous (Non-Ca) (panel a) and cancerous (Ca) (panel b) liver tissues obtained from a patient infected with HBV. The numbers of PCR cycles were 37 and 42, respectively. Panels c and d, serial sections were stained with HE. Magnification, $\times 400$. S+S, primers and probe targeting the S region of HBV DNA. (B) Panels a and b, HCV RNA detected by RT-PCR-ISH (45 cycles of PCR) in noncancerous (panel a) and cancerous (panel b) tissues obtained from a patient infected with HCV. Panels c and d, no HCV RNA was detected in the RT-negative controls. Panels e and f, serial sections were stained with HE. Magnification, $\times 400$.

RESULTS

Sensitivity and specificity of PCR-ISH versus RTD-PCR for detecting HBV DNA and HCV RNA. PCR-ISH showed positive results for HBV DNA in 10 tissue specimens from eight HBsAg-seropositive patients and two patients whose serum HBV DNA was barely detected by RTD-PCR despite being their HBsAg negative (patients 21 and 22) (Table 1). PCR-ISH yielded negative results for four patients who were negative for serum HBsAg and HCV antibody (patients 23, 24, 28, and 29) and three patients who were negative for serum HBsAg but positive for HCV antibody (patients 9 to 11).

Thirteen of the 14 tissue specimens from the patients with serum HCV antibody had a positive result for HCV RNA by RT-PCR-ISH (sensitivity, 92.9%). In contrast, HCV RNA was not detected by RT-PCR-ISH in four tissue specimens from the patients negative for both HCV antibody and HBsAg (patients 23, 25, 26, and 27) or in the sample from an HBsAg-positive and HCV antibody-negative patient (patient 6).

We performed PCR-ISH and RT-PCR-ISH on the same HBV- or HCV-infected samples from noncancerous and cancerous regions in which we had previously quantitated viral genomic DNA or RNA by RTD-PCR (34). The noncancerous tissue contained 6.1×10^5 copies of HBV DNA/ μg total DNA, and the cancerous regions included 4.5×10^5 copies/ μg total DNA. Equivalent numbers of cells in the noncancerous and cancerous tissues stained positive for HBV on PCR-ISH (patient 4; Fig. 1A). The PCR-ISH results were consistent with the HBV DNA copy number previously determined by RTD-PCR (34).

Noncancerous tissue from an HCV-positive patient contained 2.0×10^5 copies HCV RNA/ μg total RNA, whereas cancerous tissue contained 2.0×10^2 copies/ μg total RNA

(patient 12; Fig. 1B). HCV RNA was observed by RT-PCR-ISH in hepatocytes of the liver tissue sections from an HCV-infected patient (Fig. 1B). In the noncancerous tissue, an intense hybridization signal was found at the perinuclear sites of almost all the hepatocytes in the section (Fig. 1B, panel a). In contrast, in the cancerous tissue, there was only a weak HCV RNA hybridization signal in the hepatocytes (Fig. 1B, panel b). When the RT step was omitted (control), no HCV RNA was detected in the noncancerous or cancerous tissue sections (Fig. 1B, panels c and d). These results were consistent with the previous quantitation of HCV RNA copy number by RTD-PCR (34).

Detection of HBV DNA by PCR-ISH. HBV DNA was detected by PCR-ISH in the tissue sections obtained from an HBV DNA-seropositive patient. Amplified PCR products were detected by using a probe for either the S or the X region (Fig. 2A, panels a to d) but were not detected by using a heterologous probe (Fig. 2A, panels e and f). Amplification of either the S or the X region of HBV DNA gave the same pattern of hybridization (Fig. 2A, panels a to d). HBV DNA was detected by PCR-ISH in almost all hepatocytes (Fig. 2A, panels a to d) and was very obvious even under low magnification (Fig. 2A, panels a and c). An intense hybridization signal was observed predominantly at the perinuclear site under high magnification (Fig. 2A, panels b and d). In contrast, HBV DNA was not detected by using HBs- and HBx-matched primer and probe combinations in sections obtained from an HBV DNA-seronegative patient (data not shown). DNA fragments amplified by using the S and X region primer sets were 179 bp and 161 bp, respectively (Fig. 2B). Sections from an HBV DNA-seronegative patient were negative in the PCR analysis (data not shown).

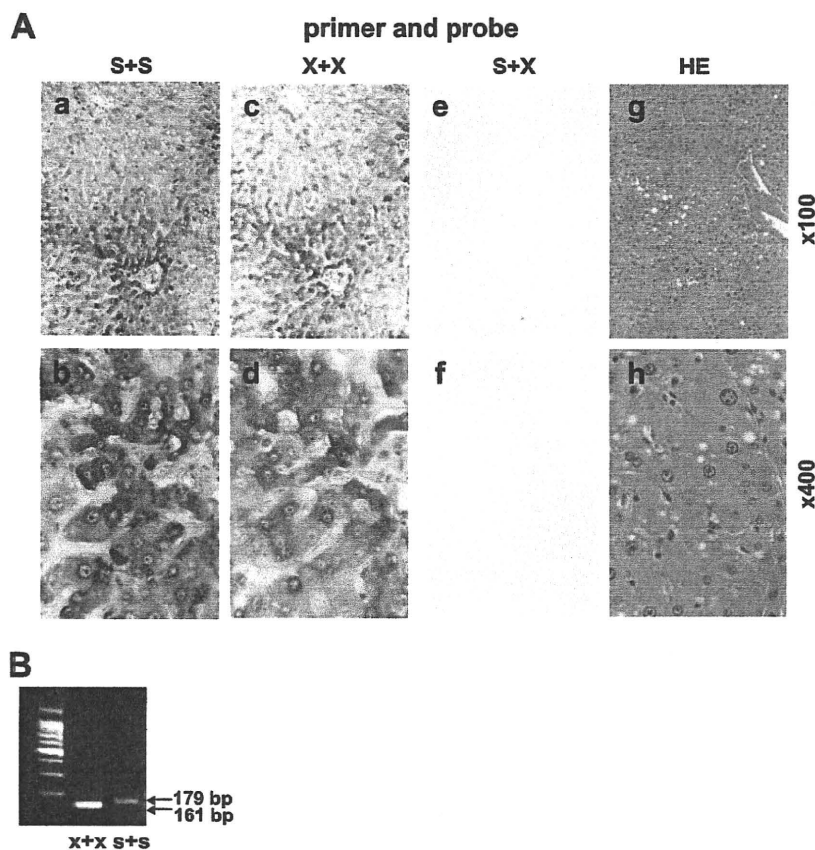


FIG. 2. (A) Panels a to f, HBV DNA detected in liver tissue sections from a patient with chronic hepatitis B by PCR-ISH (42 cycles of PCR). Panels g and h, serial sections were stained with HE. Magnifications, $\times 100$ (panels a, c, e, and g) and $\times 400$ (b, d, f, and h). S+S, primers and probe targeting the S region; X+X, primers and probe targeting the X region; S+X, primers and probe targeting the S and X regions, respectively. (B) Amplified DNA fragments in the PCR mixture of the section in panel A visualized by 3% agarose gel electrophoresis. The PCR product of the X region was 161 bp, and that of the S region was 179 bp.

Localization of HBV DNA, HBV RNA, HBsAg, and HBcAg in liver tissue. HBV DNA, HBV RNA, HBsAg, and HBcAg were detected by PCR-ISH, RT-PCR-ISH, and immunohistochemical staining of serial sections from an HBV-infected patient (patient 5; Fig. 3A, panels a to h). HBV DNA was detected in almost all the hepatocytes by PCR-ISH, although there was wide variation in the hybridization signal intensity between different areas of the section (Fig. 3A, panels a and b). The staining pattern of HBV RNA was similar to that of HBV DNA (Fig. 3A, panels c and d). Intracytoplasmic and intranuclear staining for HBsAg and HBcAg, respectively, was found in some hepatocytes (Fig. 3A, panels f and h). PCR and RT-PCR results were confirmed by gel electrophoresis of the amplified products in the supernatant from the tissue section (Fig. 3B, panels a and b).

Detection of HCV RNA by RT-PCR-ISH. HCV RNA could be detected by RT-PCR-ISH in almost all the hepatocytes in the liver sections obtained from an HCV RNA-seropositive patient (Fig. 4A, panels a and b). Under high magnification, a strong HCV RNA signal was detected in the perinuclear area (Fig. 4A, panel b). A negative-control test (no RT) did not detect any HCV RNA (Fig. 4A, panels c and d). The expected 162-bp DNA fragment amplified by RT-PCR in the supernatant from the tissue section was detected (Fig. 4B, lane 2). In

contrast, HCV RNA was not detected in the liver section obtained from an HCV RNA-seronegative patient, regardless of whether RT was used (data not shown).

Isolation of HCV RNA in hepatocytes by LCM. Hepatocyte groups were captured from the perivenular, intermediate, and periportal areas by LCM (Fig. 4C, panel a). HCV RNA was quantified by RTD-PCR in approximately 30 hepatocytes captured by LCM and normalized against the picogram weight of GAPDH mRNA (Fig. 4C, panels b to d); the HCV RNA levels were equivalent in all three regions (Fig. 4C, panel d).

Detection of HCV RNA in the epithelium of the large bile duct. HCV RNA was detected by RT-PCR-ISH in the epithelium of the large bile duct, which was surrounded by dense fibrous and elastic tissue (Fig. 4D, panels a and b). In contrast, no HCV RNA was detected in the epithelium of the small bile duct. Further, HCV RNA was not detected in the portal vein or its branches (Fig. 4D, panel a).

Detection of HBV DNA and HCV RNA in noncancerous and cancerous liver tissue sections obtained from a patient with HBV and HCV coinfection. Figure 5 shows the results for HBV DNA and HCV RNA in liver samples from a patient with HCC having HCV and HBV coinfection. The amounts of serum HBV DNA and HCV RNA were 39 copies/ml and 5×10^7 copies/ml, respectively (patient 21) (34). In the noncancerous

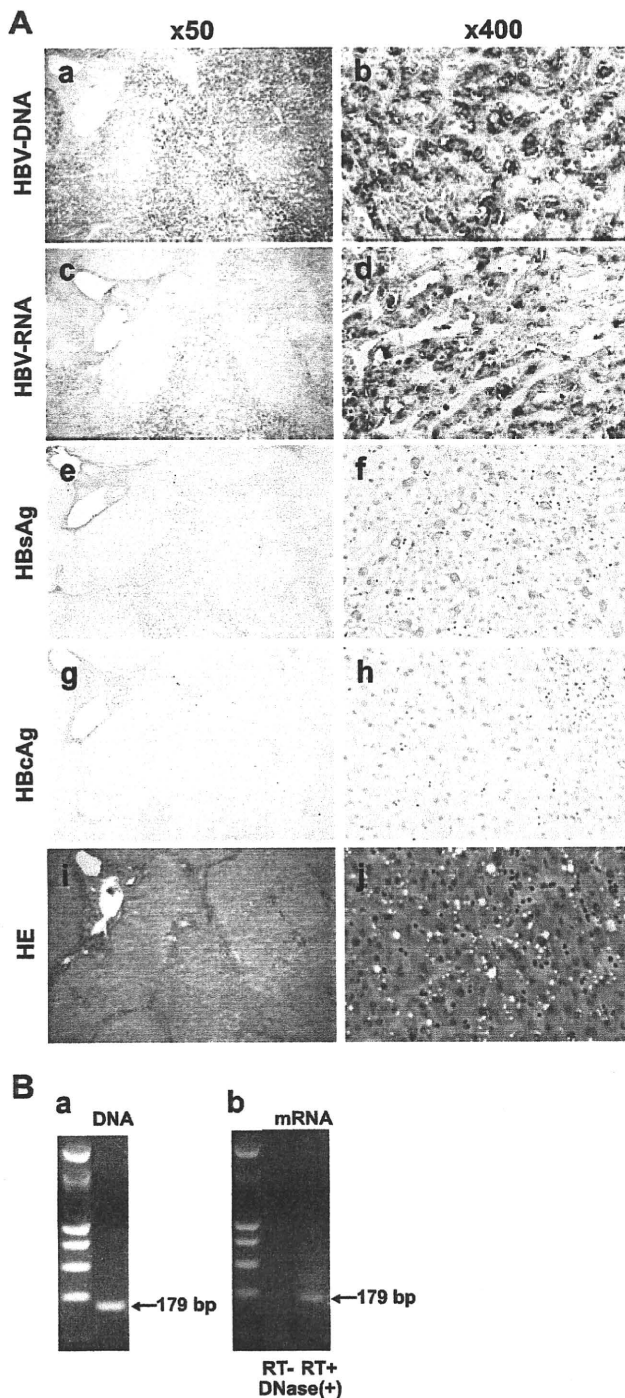


FIG. 3. (A) Panels a to h, HBV DNA, HBV RNA, HBsAg, and HbcAg detected in OCT-embedded frozen liver tissue from a patient with chronic hepatitis B by PCR-ISH (panels a and b), RT-PCR-ISH (panels c and d), and immunohistochemical staining (panels e to h). Panels i and j, HE staining of serial sections. The primers and probe targeted the S region to detect HBV DNA and HBV RNA. Antibodies to the envelope and core proteins were used to detect HBsAg and HbcAg, respectively. Magnifications, $\times 50$ (panels a, c, e, g, and i) and $\times 400$ (panels b, d, f, h, and j). The number of PCR cycles was 42. (B) Amplified DNA fragments in the PCR mixture of the section in panel A. Panel a, the DNA fragments amplified by 42 cycles of PCR were visualized by 3% agarose gel electrophoresis. Panel b, RT-PCR after DNase I treatment (3 U/ μ l) and negative controls (no RT).

tissue from the patient with HBV and HCV coinfection, there was an intense hybridization signal for HCV RNA on RT-PCR-ISH in almost all the hepatocytes (Fig. 5A, panel b). There was also a positive but weak RT-PCR-ISH signal for HCV RNA in the tumor hepatocytes (Fig. 5B, panel b). Few hepatocytes in the cancerous tissue were positive for HBV DNA by PCR-ISH (Fig. 5B, panel a), and no HBV DNA hybridization signal was detected in the noncancerous tissue (Fig. 5A, panel a).

DISCUSSION

The standard assay for detecting replication of HBV and HCV in tissue is ISH, but results are often inconsistent and sometimes difficult to reproduce. The specificity of ISH is high but its sensitivity low, and it is difficult to detect low copy numbers of the HBV or HCV genome in tissue. PCR technology has been adapted to *in situ* amplification of viral genomes or their replicative intermediates in liver tissue sections, but sensitivity and specificity remain major challenges to the application of this approach (13, 18, 23, 25, 26, 30, 31). Here, we describe the use of a novel, highly specific and sensitive PCR-ISH method to determine the distribution and localization of HBV DNA, HBV RNA, and HCV RNA in both normal and cancerous liver tissues.

PCR-ISH is the most sensitive technology currently available for the detection of viral genomes, but a major potential limitation of this approach is the low specificity. We were able to improve the specificity of PCR-ISH by careful optimization of certain steps. PCR was performed using sets of antisense and sense primers that were complementary to the sequences located in the S and X regions of HBV and the 5'-UTR upstream of the core region of HCV. We added PCR templates to the HBV- or HCV-negative tissue sections. The slides were placed in the GeneAmp *in situ* PCR system 1000 unit, and PCR-ISH was performed as described in Materials and Methods. Following these results, we selected the primer and probe set that did not stain the HBV- or HCV-negative tissue sections by PCR-ISH. Second, the type and concentration of protease and the treatment time were adjusted to optimize permeabilization of membranes and release of protein-nucleic acid cross-linking while avoiding overdigestion. Third, to improve the specificity for detecting viral genomes, we limited the number of PCR cycles and fixed the liver tissue sections in 4% paraformaldehyde immediately after PCR amplification. This step is essential to avoid diffusion of PCR products into neighboring cells, a phenomenon known as the diffusion artifact. Limiting the number of PCR cycles was also important for eliminating the background staining, as too many cycles resulted in high background staining and loss of tissue morphology. Fourth, we added a DIG-dUTP tail at the 3' ends of the probes for PCR-ISH and RT-PCR-ISH. These 45-mer probes were optimized to improve their sensitivity without impairing the specificity.

HBV DNA was detected by PCR-ISH in a large number of hepatocytes in tissue sections from an HBV DNA-seropositive patient (Fig. 1A, panel a). HBV DNA was also observed by PCR-ISH in tumor hepatocytes in a section of cancerous tissue from the same patient (Fig. 1A, panel b). As shown in Fig. 2A,

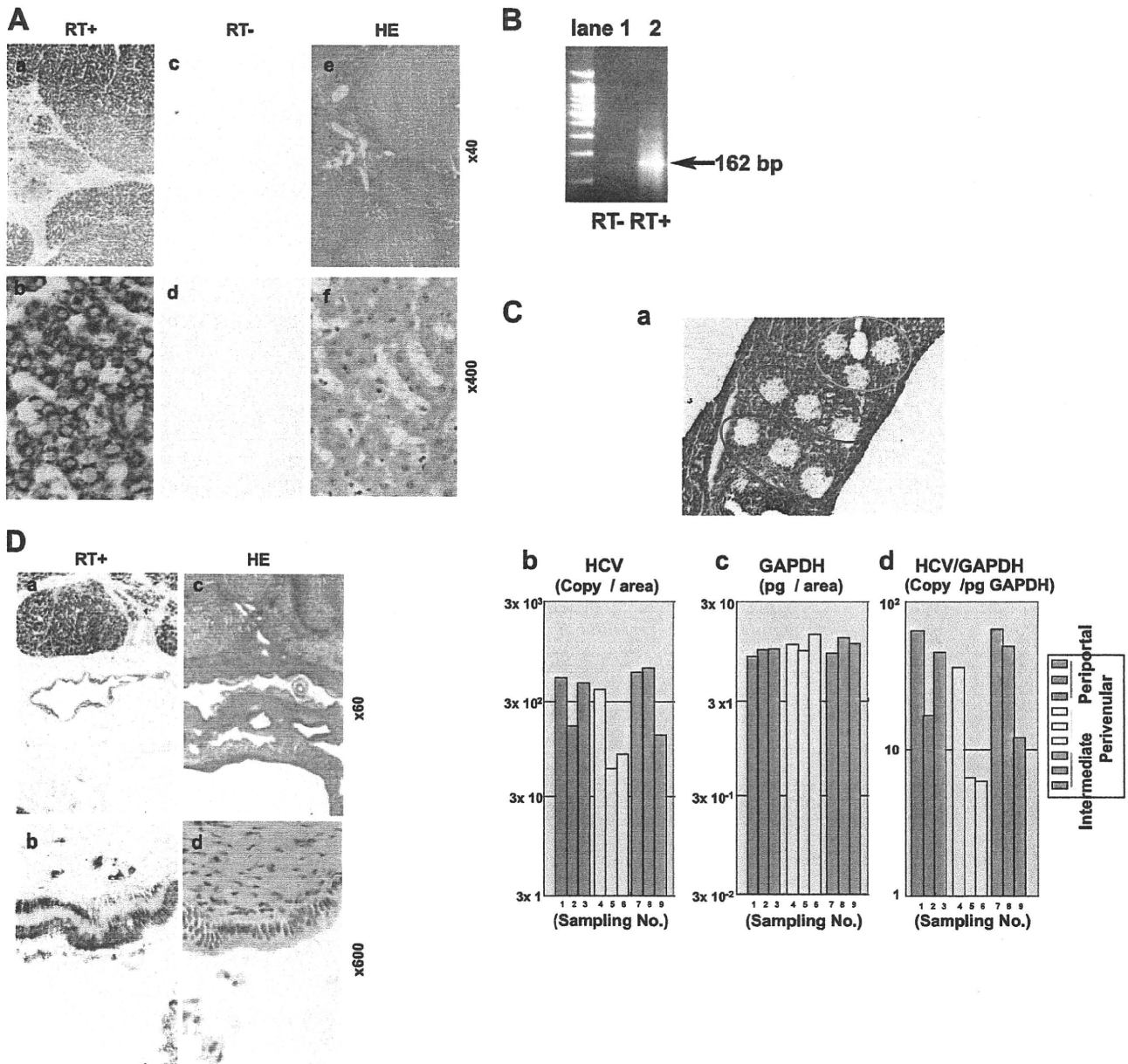


FIG. 4. (A) Panels a and b, HCV RNA detected in liver tissue samples from a patient with chronic hepatitis C by RT-PCR-ISH. Panels c and d, HCV RNA was not detected in a negative control (no RT). The number of PCR cycles was 45. Panels e and f, serial sections were stained with HE. Magnifications, $\times 40$ (panels a, c, and e) and $\times 400$ (panels b, d, and f). (B) DNA fragments in the PCR mixture of the section in panel A were amplified with the RT step and detected by 3% agarose gel electrophoresis. Amplification without the RT step resulted in no detection of DNA fragments. (C) Panel a, after LCM of nine areas, sections of liver tissue obtained from a patient with chronic hepatitis C were stained with HE. Panels b and c, HCV RNA and GAPDH mRNA in each of the areas were quantified by RTD-PCR, and the results are expressed as copy number per LCM area. Panel d, the copy number of HCV RNA was corrected by using the picogram weight of GAPDH. (D) Panels a and b, HCV RNA detected in the epithelium of the large bile duct by RT-PCR-ISH. The number of PCR cycles was 45. Panels c and d, serial sections were stained with HE. Magnifications, $\times 60$ (a and c) and $\times 600$ (b and d).

we obtained clear and reproducible patterns of distribution or localization of the viral genomes in the tissue sections. The visual patterns of HBV DNA distribution were similar, irrespective of the primer sets and probes (Fig. 2A, panels a to d). These data indicate that our technique is highly specific and reproducible for the detection of HBV DNA.

The staining pattern of HBV RNA was similar to that of

HBV DNA (Fig. 3A, panels c and d). HBV DNA was also observed by PCR-ISH in tumor hepatocytes in a section of cancerous tissue from an HBV DNA-seropositive patient (Fig. 1A, panel b), but neither HBsAg nor HBcAg was detected in this section (data not shown). As shown in Fig. 3, the intensity of HBV DNA by PCR-ISH was almost the same as that of HBV RNA by RT-PCR-ISH but did not coincide with the

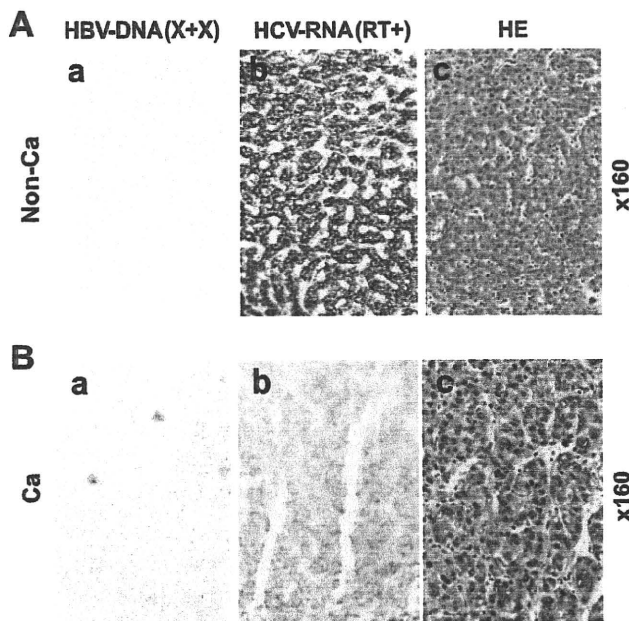


FIG. 5. Panels a and b, HBV DNA (panels a) and HCV RNA (panels b) in noncancerous (non-Ca) (A) and cancerous (Ca) (B) liver tissue obtained from a patient coinfecting with HBV and HCV were detected by PCR-ISH (55 cycles of PCR) and RT-PCR-ISH (45 cycles of PCR), respectively. Panels c, serial sections were stained with HE. Magnification, $\times 160$.

intensity of HBV protein expression. HBV has four overlapping open reading frames regulated by two enhancer elements and four promoters (14).

We had reported previously that HCV RNA and HCV core protein levels are relatively stable irrespective of fibrosis (33, 35). In the present study, HCV RNA was detected in almost all hepatocytes in all sections. Furthermore, we emphasize the similar staining pattern of almost all hepatocytes at the cellular level. HCV RNA was detected in the cytoplasm but not in the nucleus. The detection of an intense signal at the perinuclear site may reflect the replication process of HCV (10). HCV RNA was also detected in the epithelium of the large bile duct but not in the endothelial cells, portal tracts, or sinusoidal lymphocytes, which is consistent with the results of previous studies (5, 8). Thus, the epithelium of the large bile duct, but not that of the small duct, can support HCV replication.

We confirmed the specificity for detecting the HCV RNA copy number by quantification in a small area of an LCM section (Fig. 4C); similar amounts of HCV RNA were detected in each area. The detection of HCV RNA in each area by LCM and RTD-PCR excluded the possibility of diffusion of the PCR product by RT-PCR-ISH.

Recent molecular biological techniques have demonstrated low-level HBV viremia in some patients with chronic hepatitis C who were negative for all serological HBV markers. In these cases, HBV DNA not only is integrated in the human chromosomes but also replicates in hepatocytes (34). In the previous study, we measured the levels of HBV DNA and HCV RNA using RTD-PCR with singly infected or coinfecting noncancerous and cancerous liver tissues (34). In the case of coinfection, HCV replication was dominant in the noncancerous

tissue whereas HBV replication was dominant in the cancerous tissue. Some studies have shown that HCV inhibits HBV gene expression and replication (7, 15).

Using this novel, highly specific and sensitive PCR-ISH method, we could visualize the tissue staining patterns of HBV and HCV, which were consistent with those seen by RTD-PCR. This revealed the novel finding that almost all hepatocytes are infected with HBV or HCV in patients with chronic liver disease, suggesting that the viruses spread throughout the liver in the chronic stage. However, further study with a large number of samples from each stage of infection is needed to clarify the mechanism of persistent infection via our assay method.

ACKNOWLEDGMENTS

We are grateful to Yuichi Hirata of the Tokyo Metropolitan Institute of Medical Science and Kyoko Kohara of Kumamoto University for their critical comments and helpful discussions.

This study was supported by grants from the Ministry of Education, Culture, Sports, Science and Technology of Japan, the Program for Promotion of Fundamental Studies in Health Sciences of the Pharmaceuticals and Medical Devices Agency of Japan, and the Ministry of Health, Labor and Welfare of Japan.

REFERENCES

- Abe, A., K. Inoue, T. Tanaka, J. Kato, N. Kajiyama, R. Kawaguchi, S. Tanaka, M. Yoshida, and M. Kohara. 1999. Quantitation of hepatitis B virus genomic DNA by real-time detection PCR. *J. Clin. Microbiol.* 37:2899–2903.
- Beasley, R. P., L. Y. Hwang, C. C. Lin, and C. S. Chien. 1981. Hepatocellular carcinoma and hepatitis B virus. A prospective study of 22 707 men in Taiwan. *Lancet* ii:1129–1133.
- Bedossa, P., and T. Poynard. 1996. An algorithm for the grading of activity in chronic hepatitis C. The METAVIR Cooperative Study Group. *Hepatology* 24:289–293.
- Benvenuto, L., G. Fattovich, F. Noventa, F. Tremolada, L. Chemello, A. Cecchetto, and A. Alberti. 1994. Concurrent hepatitis B and C virus infection and risk of hepatocellular carcinoma in cirrhosis. A prospective study. *Cancer* 74:2442–2448.
- Boletis, J. N., J. K. Delladetsima, F. Makris, H. Theodoropoulou, S. Vgenopoulou, A. Kostakis, and A. Hatzakis. 2000. Cholestatic syndromes in renal transplant recipients with HCV infection. *Transpl. Int.* 13(Suppl. 1):S375–S379.
- Bonner, R. F., M. Emmert-Buck, K. Cole, T. Pohida, R. Chuaqui, S. Goldstein, and L. A. Liotta. 1997. Laser capture microdissection: molecular analysis of tissue. *Science* 278:1481–1483.
- Chen, S. Y., C. F. Kao, C. M. Chen, C. M. Shih, M. J. Hsu, C. H. Chao, S. H. Wang, L. R. You, and Y. H. Lee. 2003. Mechanisms for inhibition of hepatitis B virus gene expression and replication by hepatitis C virus core protein. *J. Biol. Chem.* 278:591–607.
- Delladetsima, J. K., F. Makris, M. Psychogiou, A. Kostakis, A. Hatzakis, and J. N. Boletis. 2001. Cholestatic syndrome with bile duct damage and loss in renal transplant recipients with HCV infection. *Liver* 21:81–88.
- Di Bisceglie, A. M., S. E. Order, J. L. Klein, J. G. Waggoner, M. H. Sjogren, G. Kuo, M. Houghton, Q. L. Choo, and J. H. Hoofnagle. 1991. The role of chronic viral hepatitis in hepatocellular carcinoma in the United States. *Am. J. Gastroenterol.* 86:335–338.
- El-Hage, N., and G. Luo. 2003. Replication of hepatitis C virus RNA occurs in a membrane-bound replication complex containing nonstructural viral proteins and RNA. *J. Gen. Virol.* 84:2761–2769.
- Emmert-Buck, M. R., R. F. Bonner, P. D. Smith, R. F. Chuaqui, Z. Zhuang, S. R. Goldstein, R. A. Weiss, and L. A. Liotta. 1996. Laser capture microdissection. *Science* 274:998–1001.
- Fattovich, G. 2003. Natural history and prognosis of hepatitis B. *Semin. Liver Dis.* 23:47–58.
- Fragulidis, G. P., R. E. Cirocco, D. Weppler, M. Berho, G. Gillian, M. Markou, A. Viciano, V. Esquenazi, J. R. Nery, J. Miller, K. R. Reddy, and A. G. Tzakis. 1998. In situ enzymatic oligonucleotide amplification of hepatitis C virus-RNA in liver biopsy specimens (reverse transcriptase in situ polymerase chain reaction) after orthotopic liver transplantation for hepatitis C-related liver disease. *Transplantation* 66:1472–1476.
- Ganem, D., and A. M. Prince. 2004. Hepatitis B virus infection—natural history and clinical consequences. *N. Engl. J. Med.* 350:1118–1129.
- Guo, H., T. Zhou, D. Jiang, A. Cucconati, G.-H. Xiao, T. M. Block, and J.-T. Guo. 2007. Regulation of hepatitis B virus replication by the phosphatidylinositol 3-kinase-akt signal transduction pathway. *J. Virol.* 81:10072–10080.

16. Holland, P. V., and H. J. Alter. 1975. The clinical significance of hepatitis B virus antigens and antibodies. *Med. Clin. North Am.* **59**:849–855.
17. Kiyosawa, K., T. Sodeyama, E. Tanaka, Y. Gibo, K. Yoshizawa, Y. Nakano, S. Furuta, Y. Akahane, K. Nishioka, R. H. Purcell, et al. 1990. Interrelationship of blood transfusion, non-A, non-B hepatitis and hepatocellular carcinoma: analysis by detection of antibody to hepatitis C virus. *Hepatology* **12**:671–675.
18. Komminoth, P., A. A. Long, R. Ray, and H. J. Wolfe. 1992. In situ polymerase chain reaction detection of viral DNA, single-copy genes, and gene rearrangements in cell suspensions and cytopins. *Diagn. Mol. Pathol.* **1**:85–97.
19. Kuo, G., Q. L. Choo, H. J. Alter, G. L. Gitnick, A. G. Redeker, R. H. Purcell, T. Miyamura, J. L. Dienstag, M. J. Alter, C. E. Stevens, et al. 1989. An assay for circulating antibodies to a major etiologic virus of human non-A, non-B hepatitis. *Science* **244**:362–364.
20. Large, M. K., D. J. Kittleesen, and Y. S. Hahn. 1999. Suppression of host immune response by the core protein of hepatitis C virus: possible implications for hepatitis C virus persistence. *J. Immunol.* **162**:931–938.
21. Leone, N., and M. Rizzetto. 2005. Natural history of hepatitis C virus infection: from chronic hepatitis to cirrhosis, to hepatocellular carcinoma. *Minerva Gastroenterol. Dietol.* **51**:31–46.
22. Navas, S., and V. Carreno. 1995. Semiquantification by Amplicor assay of hepatitis C virus genome during therapy. *J. Hepatol.* **22**:115–117.
23. Negro, F. 1998. Detection of hepatitis C virus RNA in liver tissue: an overview. *Ital. J. Gastroenterol. Hepatol.* **30**:205–210.
24. Nolte, F. S., C. Thurmond, and M. W. Fried. 1995. Preclinical evaluation of AMPLICOR hepatitis C virus test for detection of hepatitis C virus RNA. *J. Clin. Microbiol.* **33**:1775–1778.
25. Nuovo, G. J., F. Gallery, P. MacConnell, J. Becker, and W. Bloch. 1991. An improved technique for the in situ detection of DNA after polymerase chain reaction amplification. *Am. J. Pathol.* **139**:1239–1244.
26. Nuovo, G. J., P. MacConnell, A. Forde, and P. Delvenne. 1991. Detection of human papillomavirus DNA in formalin-fixed tissues by in situ hybridization after amplification by polymerase chain reaction. *Am. J. Pathol.* **139**:847–854.
27. Sansonno, D., V. Cornacchiulo, V. Racanelli, and F. Dammacco. 1997. In situ simultaneous detection of hepatitis C virus RNA and hepatitis C virus-related antigens in hepatocellular carcinoma. *Cancer* **80**:22–33.
28. Schluger, L. K., P. A. Sheiner, S. N. Thung, J. Y. Lau, A. Min, D. C. Wolf, I. Fiel, D. Zhang, M. A. Gerber, C. M. Miller, and H. C. Bodenheimer, Jr. 1996. Severe recurrent cholestatic hepatitis C following orthotopic liver transplantation. *Hepatology* **23**:971–976.
29. Seeger, C., and W. S. Mason. 2000. Hepatitis B virus biology. *Microbiol. Mol. Biol. Rev.* **64**:51–68.
30. Shieh, B., S.-E. Lee, Y.-C. Tsai, I.-J. Su, and C. Li. 1999. Detection of hepatitis B virus genome in hepatocellular carcinoma tissues with PCR-in situ hybridization. *J. Virol. Methods* **80**:157–167.
31. Shin, Y. J., S. W. Cho, K. B. Hahn, Y. S. Kim, J. H. Kim, K. H. Park, and S. I. Lee. 1998. Localization of hepatitis B virus DNA in hepatocellular carcinoma by polymerase chain reaction in situ hybridization. *J. Korean Med. Sci.* **13**:377–382.
32. Shiratori, Y., S. Shiina, P. Y. Zhang, E. Ohno, T. Okudaira, D. A. Payawal, S. K. Ono-Nita, M. Imamura, N. Kato, and M. Omata. 1997. Does dual infection by hepatitis B and C viruses play an important role in the pathogenesis of hepatocellular carcinoma in Japan? *Cancer* **80**:2060–2067.
33. Takeuchi, T., A. Katsume, T. Tanaka, A. Abe, K. Inoue, K. Tsukiyama-Kohara, R. Kawaguchi, S. Tanaka, and M. Kohara. 1999. Real-time detection system for quantification of hepatitis C virus genome. *Gastroenterology* **116**:636–642.
34. Tanaka, T., K. Inoue, Y. Hayashi, A. Abe, K. Tsukiyama-Kohara, H. Nuriya, Y. Aoki, R. Kawaguchi, K. Kubota, M. Yoshida, M. Koike, S. Tanaka, and M. Kohara. 2004. Virological significance of low-level hepatitis B virus infection in patients with hepatitis C virus associated liver disease. *J. Med. Virol.* **72**:223–229.
35. Tanaka, T., J. Y. Lau, M. Mizokami, E. Orito, E. Tanaka, K. Kiyosawa, K. Yasui, Y. Ohta, A. Hasegawa, S. Tanaka, et al. 1995. Simple fluorescent enzyme immunoassay for detection and quantification of hepatitis C viremia. *J. Hepatol.* **23**:742–745.
36. Zeuzem, S., B. Riester, and W. K. Roth. 1994. Clinical evaluation of a new polymerase chain reaction assay (Amplicor HCV) for detection of hepatitis C virus. *Z. Gastroenterol.* **32**:342–347.