

特集 第62回日本臨床眼科学会講演集 原著

# 眼部帯状疱疹の涙液中の水痘・帯状疱疹ウイルス DNA 量

山本紗也香 杉田 直 森尾 友宏 清水 則夫 望月 學

臨 床 眼 科

第63巻 第5号 別刷

2009年5月15日 発行

医学書院

# 眼部帯状疱疹の涙液中の水痘・帯状疱疹ウイルス DNA 量

山本紗也香<sup>\*1,2</sup> 杉田 直<sup>\*1</sup> 森尾 友宏<sup>\*3</sup>  
清水 則夫<sup>\*4</sup> 望月 學<sup>\*1</sup>

<sup>\*1</sup> 東京医科歯科大学大学院医歯学総合研究科眼科学分野 <sup>\*2</sup> 柏市立柏病院眼科  
<sup>\*3</sup> 東京医科歯科大学細胞治療センター <sup>\*4</sup> 東京医科歯科大学難治疾患研究所フロンティア研究室ウイルス治療学

**要約 目的:** 眼部帯状疱疹の涙液中の水痘・帯状疱疹ウイルス (varicella zoster virus: VZV)-DNA 量の報告。**対象と方法:** 対象は眼部帯状疱疹に伴う角結膜炎患者 6 例。両眼から涙液を採取し、マルチプレックス定性 PCR でヘルペスウイルス属をスクリーニングし、リアルタイム PCR で VZV-DNA 量を測定した。**結果:** 患眼の涙液 (n=6) から高値の VZV-DNA (平均  $2.4 \times 10^9$  copy/ml) が検出された。僚眼の涙液 (n=4) から VZV-DNA (平均  $1.0 \times 10^6$  copy/ml) が検出された。患眼のウイルス量は僚眼より有意に高値を示した。涙液中のウイルス量と眼所見とに有意な関係はなかった。**結論:** 眼部帯状疱疹で、患眼および僚眼の涙液から高値の VZV-DNA が検出された。患眼のウイルス量は僚眼より有意に高かった。

## DNA level of varicella zoster virus in the tear fluid in patients with herpes zoster ophthalmicus

Sayaka Yamamoto<sup>\*1,2</sup> Sunao Sugita<sup>\*1</sup> Tomohiro Morio<sup>\*3</sup>  
Norio Shimizu<sup>\*4</sup> Manabu Mochizuki<sup>\*1</sup>

<sup>\*1</sup> Dept of Ophthalmol and Vis Sci, Tokyo Med and Dent Univ Grad Sch of Med  
<sup>\*2</sup> Dept of Ophthalmol, Kashiwa City Hosp <sup>\*3</sup> Cent for Cell Ther, Tokyo Med and Dent Univ  
<sup>\*4</sup> Virus Res Unit, Frontier Res Unit, Med Res Inst, Tokyo Med and Dent Univ

**Abstract. Purpose:** To report the DNA level of varicella zoster virus (VZV) in the tear fluid of patients with herpes zoster ophthalmicus. **Cases and Method:** This study was made on 6 consecutive patients with keratoconjunctivitis as manifestation of herpes zoster ophthalmicus. Genomic DNA of human herpes virus was quantitated in the tear fluid by two polymerase chain reaction (PCR) assays: qualitative multiplex PCR and quantitative real-time PCR. **Results:** Real-time PCR showed an average of  $2.4 \times 10^9$  copy/ml of VZV-DNA in the tear fluid of 6 affected eyes. The uninfected fellow eyes of 4 patients showed an average of  $1.0 \times 10^6$  copy/ml in the tear fluid. The difference was significant ( $p=0.019$ ). **Conclusion:** VZV-DNA was detected in the tear fluid in affected and nonaffected eyes of patients with herpes zoster ophthalmicus. The titer was significantly higher in the infected than noninfected fellow eyes.

Rinsho Ganka (Jpn J Clin Ophthalmol) 63(5): 707-710, 2009

### 緒言

水痘・帯状疱疹ウイルス (varicella zoster virus: 以下, VZV) はヒトヘルペスウイルス属の 3 番目のウイルスで、水痘として初感染し、三叉神経や脊髄後根の神経節中に潜伏感染することが知られ

ている<sup>1)</sup>。ウイルスの再活性化により三叉神経第 1 枝・第 2 枝支配領域に発症するものを眼部帯状疱疹と呼んでおり、眼瞼炎、結膜炎、強膜炎、虹彩毛様体炎、続発緑内障、網膜疾患、外眼筋麻痺といったさまざまな眼合併症を引き起こす<sup>2)</sup>。

これまでに眼部帯状疱疹の涙液中 VZV-DNA

別刷請求先: 山本紗也香 (やまもと・さやか) 〒113-8519 東京都文京区湯島 1-5-45 東京医科歯科大学大学院医歯学総合研究科眼科学分野

Reprint requests to: Sayaka Yamamoto Department of Ophthalmology and Visual Science, Tokyo Medical and Dental University Graduate School of Medicine. 1-5-45 Yushima Tokyo 113-8519, JAPAN

表 1 眼部帯状疱疹に伴う角結膜炎患者の涙液中 VZV-DNA 量と初診時所見

症例	性別	年齢	検体採取前 の治療	VZV-DNA (copy/ml)		眼圧 (mmHg)		濾胞性 結膜炎	角膜炎	鼻尖部 発疹	虹彩 毛様体炎
				患眼	僚眼	患眼	僚眼				
1	男性	68	-	$7.1 \times 10^7$	$4.0 \times 10^5$	未測定	未測定	+	点状表層	+	-
2	女性	60	-	$3.6 \times 10^7$	$3.3 \times 10^3$	21	15	+	偽樹枝状 点状表層	-	-
3	男性	39	-	$4.0 \times 10^8$	未測定	24	17	+	点状表層	-	-
4	男性	66	+	$1.1 \times 10^6$	未測定	17	17	+	点状表層	+	+
5	男性	63	-	$1.4 \times 10^{10}$	$3.9 \times 10^6$	18	16	+	点状表層	+	-(->+)
6	男性	74	-	$1.2 \times 10^7$	$4.0 \times 10^3$	17	15	+	点状表層	-	-

量を測定した報告は稀であり<sup>3)</sup>、ウイルス量と眼所見との関連性についての報告はみられていない。

今回、筆者らは眼部帯状疱疹の両眼から涙液を採取して VZV-DNA 量を測定し、眼所見との関連性についても検討した。

## 対象と方法

対象は、2005 年 10 月～2008 年 4 月に東京医科歯科大学病院眼科を受診し、眼部帯状疱疹による角結膜炎を生じ、涙液を採取した 6 例 10 眼である。初診時年齢は 39～74 歳 (平均 63 歳)、男性 5 例、女性 1 例であった。対照検体として、帯状疱疹やヘルペス性眼疾患の既往のない白内障術前患者 5 例 10 眼 (年齢は 60～94 歳、平均 76 歳)、男性 1 例、女性 4 例からも同様の方法で涙液を採取した。検体はインフォームド・コンセントを行ったうえで採取した。

涙液は、生理食塩水 500  $\mu$ l を用いて眼表面 (角膜・結膜) を洗眼して滅菌注射器に回収する eye wash 法で採取した。検体は、LightCycler™ (Roche 社) を用いたマルチプレックス定性 PCR (polymerase chain reaction) でヒトヘルペスウイルス 1～8 型 DNA (HHV1～8) のスクリーニングを行い、陽性検体のみリアルタイム定量 PCR でそのウイルス量を測定した。

6 例中 3 例で、初診時に血清中の抗 VZV-IgG、VZV-IgM 抗体価を酵素免疫測定法 (enzyme immunoassay : EIA) で測定した。有意差解析には Mann-Whitney U 検定を用いた。

## 結果

### 1. 眼部帯状疱疹に伴う角結膜炎患者の涙液中の VZV-DNA 量

眼部帯状疱疹に伴う角結膜炎がみられた 6 名の患者の性、年齢、および採取された涙液中の VZV-DNA 量と採取時の治療開始の有無について表 1 にまとめた。

マルチプレックス定性 PCR で測定した患眼すべての涙液で VZV-DNA が陽性であった。リアルタイム定量 PCR では VZV-DNA が多く検出され、平均ウイルス量は  $2.4 \times 10^9$  copy/ml であった。4 例の僚眼からも涙液を採取し、その全例から VZV-DNA が検出され、ウイルス量は平均  $1.0 \times 10^6$  copy/ml であった。患眼と僚眼のウイルス量を比較すると、患眼が僚眼よりも有意に高値を示した ( $p=0.019$ )。VZV 以外のヒトヘルペスウイルス (HSV-1, HSV-2, EBV, CMV, HHV6, HHV7, HHV8) はすべて陰性であった。

対照の 5 例 10 眼から採取された涙液中のヒトヘルペスウイルス 1～8 型 DNA は、VZV も含めすべて陰性であった。

血清ウイルス抗体価を初診時に測定した 3 症例では、血清 VZV-IgM 抗体陰性、VZV-IgG 抗体陽性の既感染パターンを示した。

### 2. 眼所見

眼部帯状疱疹に伴う角結膜炎がみられた 6 例の患者の初診時眼所見では、全例に濾胞性結膜炎と角膜炎を認め、角膜炎は主に点状表層角膜炎であったが、症例 2 では偽樹枝状角膜炎がみられた (表 1)。初診時の眼圧は、患眼平均 19 mmHg、

僚眼平均 16 mmHg で、患眼で有意な上昇がみられた ( $p=0.023$ )。鼻尖部の発疹は 6 例中 3 例 (50%) にみられ、そのうち 2 例では虹彩毛様体炎が経過中にみられた。涙液中の最もウイルス量の少なかった症例 4 では、前医で眼部帯状疱疹と虹彩炎に対し抗ウイルス薬治療が開始されていた。最もウイルス量の多い症例 5 では、初診時には眼内炎症所見はなかったが、経過観察中に虹彩炎が出現し、涙液だけではなく前房水からも VZV-DNA が  $3.7 \times 10^4$  copy/ml と高コピー数検出された。

治療は全症例で抗ウイルス薬 (アシクロビル) の点滴静注と眼軟膏、ステロイド点眼を行い、比較的良好な経過で、眼瞼炎、結膜炎、角膜炎などは消退した。

## ■ 考 按

今回の検討では、眼部帯状疱疹に伴う角結膜炎患者の涙液中のウイルス量を測定し、患眼全例から非常に高いウイルス量の VZV-DNA が検出された。涙液中に VZV-DNA が検出される機序として、涙腺は三叉神経節から出る三叉神経第 1 枝である眼神経、三叉神経第 2 枝である上顎神経、顔面神経、頸部神経節由来の交感神経に支配されており、三叉神経節に潜伏感染した VZV が再活性化により下行性に涙液中に到達した経路が考えられた。また、感染した角結膜の細胞由来の VZV も含まれている可能性が考えられた。

眼部帯状疱疹の僚眼からも涙液中に高いウイルス量の VZV-DNA が検出された。これまでの報告では、Robert ら<sup>3)</sup>が眼部帯状疱疹の 4 例中、患眼 4 眼中 4 眼 (100%)、僚眼 4 眼中 1 眼 (25%) の涙液から VZV-DNA が検出されたと報告しているが、僚眼からは 1 例と少ないことから、コンタミネーションの可能性が否定できないと考察している。しかし、筆者らは測定した僚眼すべてから高コピー数の DNA が検出されたため、単なるコンタミネーションの可能性は低いと考えた。

単純ヘルペスウイルスでは、病変形成を伴うことなく涙液や唾液中などにウイルスが排泄される無症候性排泄が知られており、下村<sup>4)</sup>は HSV-1 では無症候性排泄が 12.4% みられたと報告している。一方、健常人における涙液中の VZV-DNA 検

出率は、Robert ら<sup>3)</sup>の報告では 162 眼中 0 眼 (0%)、本検討でも 10 眼中 0 眼 (0%) と検出されておらず、無症候性排泄により健眼の涙液中 VZV-DNA が高コピー数を示した可能性は低いと考えた。

眼部帯状疱疹の僚眼から涙液中に VZV-DNA が検出されたこれまでの報告としては、弘重ら<sup>5)</sup>は Ramsay Hunt 症候群 (第 7・8 脳神経領域の帯状疱疹) の 15 症例の涙液と唾液における VZV-DNA の検討で、涙液と唾液から VZV-DNA が検出され、患側だけでなく健側からも検出されたことを報告している。本検討の結果と合わせ、帯状疱疹患者では患側だけでなく健側でも VZV の再活性化が生じている可能性も示された。

帯状疱疹は一般的に加齢、ストレス、悪性腫瘍など VZV に対する特異的な細胞性免疫が低下したときに VZV の局所での再活性化が生じ、患側の皮膚や神経に炎症が出現すると考えられている<sup>1)</sup>。

僚眼からも涙液中に VZV-DNA が検出されるもう 1 つの可能性として、帯状疱疹発症前後に VZV が DNA レベル (あるいはウイルス粒子レベル) で感覚神経内を逆向性に軸索流に乗って伝播し、三叉神経は中枢レベルで交叉するため反対側へ到達し、僚眼涙液中に分泌されるという機序が考えられた。実際、患側に比べて  $10^3 \sim 10^4$  レベルで DNA コピー数が少なく、ウイルス量が少ないため健側では発症しないのではないかと推測された。

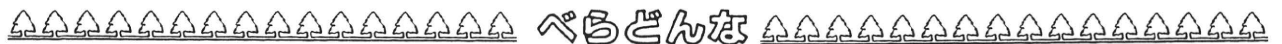以上から、眼部帯状疱疹患者では、患眼涙液中に多量のウイルス DNA が検出され、その炎症の病態形成に関与していると思われた。また、患眼だけではなく僚眼からも涙液中に VZV-DNA が検出されていたが、患眼よりも低いウイルス量であった。今後、症例数を増やしてさらなる検討が必要と考えられた。

## ■ 文 献

- 1) 田川義継：帯状ヘルペスウイルス. 大橋裕一・望月 學 (編)：眼微生物事典. 24-29, メジカルビュー社, 東京, 1996
- 2) 福田昌彦：帯状ヘルペスウイルスによる前眼部病変について教えてください. あたらしい眼科 17 : 145-147, 2000

- 3) Robert PY, Traccard I, Adenis JP et al : Multiplex detection of herpesviruses in tear fluid using the "stair primers" PCR method : prospective study of 93 patients. J Med Virol 66 : 506-511, 2002
- 4) 下村嘉一 : ヘルペスの潜伏感染, 再発, 新治療法.

- 日眼会誌 112 : 247-265, 2008
- 5) 弘重光一, 池田 稔, 本藤 良 : Ramsay Hunt 症候群の涙液および唾液における水痘・带状疱疹ウイルス DNA の検出. 日本耳鼻咽喉科学会雑誌 103 : 928-936, 2000



## 墨汁

6・3・3の新学制は昭和22年に始まったが、そのときに占領軍から指令が出た。「道」がつく科目はすべて学校から追放せよというのである。

剣道や柔道ならわかるが、書道もこれに該当することになった。やっと昭和28年から小中学校で書道を教えることが認められたが、それよりも前の世代の方々は筆でものを書くことを習わなかったのである。

眼科は墨とかなりの縁がある。網膜の動脈には約30μmの幅の無血管帯があることや、網膜の血管そのものが2層ないし3層で層状になっていることは、眼科医の常識になっている。

これを見事に証明したのはマイケルソン (Isaac C. Michaelson) である。哺乳類の網膜の血管構築を論じた“Retinal Circulation in Man and Animals” (1954) は、146ページの小さな本であるが、現在でも精読する価値がある名著である。

マイケルソンは、網膜の血管構築を検索する手段として India ink 法を使った。摘出した眼球の血管に墨汁を注入し、これを伸展標本として顕微鏡で観察するのである。

ずっと長いあいだ、インドには特殊な墨がある

のだと思っていたが、そうではなかった。墨は中国と日本の特産品だからである。マイケルソン先生も中国製の墨を使っただけだ。

東洋から渡来したものには「インド」と呼ぶ習慣があった。コンサイスに使う薄い紙は、インドとは関係がないのに India paper である。サツマイモを唐芋、カボチャを南瓜と言うのと似ている。

西洋でも羊皮紙などに字を書くときにはインクを使った。煤よりも蛸や烏賊の墨が愛用されたい。淡い黒褐色のことをセピアというのは、ラテン語の「烏賊の墨」からきている。イタリア語の seppia は「烏賊そのもの」である。

日本では ink のことをインキまたはインクという。「インク」のほうが正しそうだが、「大日本インキ化学工業」など、会社名ではインキが圧倒的に多い。

これはどうも日本語の癖らしい。ヨードチンキもその例である。これは英語の tincture に相当する。この系統の単語は多く、stain, extinct などその例だし、赤ワインもスペインでは vino tinto である。どれもラテン語の動詞 tingere 「染める」から来ている。

GEN



# Concurrent administration of intravenous systemic and intravitreal methotrexate for intraocular lymphoma with central nervous system involvement

Yusuke Nakauchi · Hiroshi Takase · Sunao Sugita · Manabu Mochizuki · Satoko Shibata · Yasuyoshi Ishiwata · Yuka Shibuya · Masato Yasuhara · Osamu Miura · Ayako Arai

Received: 22 March 2010/Revised: 21 April 2010/Accepted: 22 April 2010/Published online: 13 May 2010  
© The Japanese Society of Hematology 2010

**Abstract** Intraocular lymphoma (IOL) is rare lymphoma that frequently infiltrates the central nervous system (CNS). An optimal treatment has not been established, and its prognosis is quite poor. We treated three IOL patients with CNS involvement by concurrent administration of intravenous and intravitreal methotrexate (MTX) injection. The intraocular lesion responded in all patients. One patient achieved complete response (CR), whereas the other 2 patients were in partial response for CNS lesion, added whole brain radiation and achieved CR. In 3 eyes of 2 patients, an intravitreal MTX injection (vMTX) was administered 2 h after a systemic MTX injection (sMTX) and the intravitreal MTX concentration was measured twice: 2 h after sMTX and 24 h after vMTX. The half-life of MTX in the vitreous fluid was estimated to be 12.4–21.5 h by assuming the first-order elimination kinetics. Although the concentration was still high 24 h after vMTX (69.94–82.89  $\mu\text{M}$ ), there were no ocular complications. The serum MTX concentration was not influenced by adding vMTX to sMTX. Grade 3 adverse event, leukocytopenia, was observed in only 1 patient. No grade 4 event was observed. Although further evaluation is required,

concurrent sMTX and vMTX may be effective for IOL with CNS involvement.

**Keywords** Intraocular lymphoma · Central nervous system · Methotrexate · Intravitreal methotrexate injection

## 1 Introduction

Intraocular lymphoma (IOL) is an extranodal non-Hodgkin lymphoma (NHL) in which the lesion is in the eyeball, involving the retina, the uvea, and the vitreous body. Primary IOL (PIOL) in which lesions are confined to the eyes is very rare, and its rate of occurrence is approximately 1–2% of all extranodal NHL [1]. It is quite difficult to make pathological diagnosis of IOL because the eye is too important and too small to obtain sufficient materials. Recently the ratio of intravitreal IL-10/IL-6 >1 has been used as a diagnostic marker of IOL [2]. Detection of rearrangement of the immunoglobulin heavy chain gene by polymerase chain reaction (PCR) is also used for confirmation of monoclonality, because most IOLs are B cell type [3]. However, the diagnosis is still difficult, and the median duration from the onset to diagnosis is 12.5 months (4–60 months) [4]. In addition, IOL has central nervous system (CNS) involvement at a high frequency (60–80%) during the clinical course [3]. There is a close relationship between CNS lymphoma (CNSL) and IOL and it has been also reported that 15–25% of patients with CNSL, which is multifocal in most cases, have ocular diseases [5]. These facts make the prognosis of IOL extremely poor, and the median survival is approximately 12–20 months [5].

An optimal treatment for IOL has not been established. Recently, the effectiveness of an intravitreal methotrexate

Y. Nakauchi · O. Miura · A. Arai (✉)  
Department of Hematology,  
Tokyo Medical and Dental University,  
1-5-45 Yushima, Bunkyo-ku, Tokyo 113-8519, Japan  
e-mail: ara.hema@tmd.ac.jp

H. Takase · S. Sugita · M. Mochizuki  
Department of Ophthalmology,  
Tokyo Medical and Dental University, Tokyo, Japan

S. Shibata · Y. Ishiwata · Y. Shibuya · M. Yasuhara  
Department of Pharmacokinetics and Pharmacodynamics,  
Hospital Pharmacy, Tokyo Medical and Dental University,  
Tokyo, Japan

(MTX) injection for ocular lesions of IOL has been reported [6, 7]. However, it is insufficient for control or prevention of CNS involvement [6]. Meanwhile, the standard treatment for CNSL is a systemic intravenous injection of MTX (sMTX), but the effect of sMTX on ocular lesions is reportedly insufficient [8]. Thus, concurrent sMTX and intravitreal MTX injections (vMTX) are considered effective for IOL, especially for the patients accompanied by CNS involvement.

We experienced 3 IOL patients with rapidly progressive CNS involvement and treated them with concurrent sMTX and vMTX. We also examined and monitored the MTX concentration in the vitreous fluid after sMTX and vMTX in 2 cases (total 3 eyes). In this study, we report the clinical courses of these patients and the effects of concurrent sMTX and vMTX treatment on their diseases.

## 2 Materials and methods

### 2.1 Diagnosis of IOL

We diagnosed IOL in patients by observing lymphoma cells in the vitreous fluid or by confirming IgH gene clonality using the PCR assay or deviation of the surface light chain expression using flow cytometry. In addition, we considered the elevation in interleukin (IL)-10 in the vitreous fluid along with the IL-10/IL-6 > 1 ratio as a characteristic feature of IOL using enzyme-linked immunosorbent assay (R&D systems, Minneapolis, MD, USA).

DNA was extracted from a vitreous sample to detect rearrangement in the VDJ region of the IgH gene. PCR was performed according to a previously reported procedure [9].

### 2.2 Systemic chemotherapy

Chemotherapy was administered according to the report of Abrey et al. [10]. In brief, MTX was administered 5 times every 2 weeks at 3,500 mg/m<sup>2</sup>/day, vincristine (VCR), 5 times every 2 weeks at 1.0 mg/m<sup>2</sup>/day, and procarbazine (PCZ) at 100 mg/m<sup>2</sup>/day for 7 days 3 times at odd times of MTX and VCR administration.

### 2.3 Measurement of MTX concentration

Concentrations of MTX in serum and vitreous fluid were measured using the fluorescence polarization immunoassay method with a TDx assay system (Abbott Laboratories, Chicago, IL, USA).

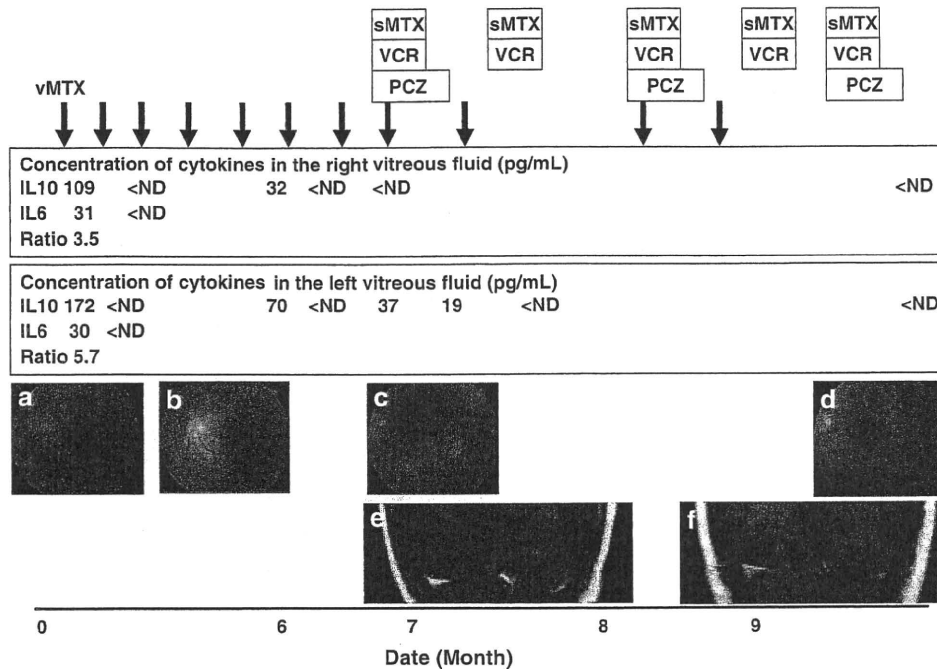
The work complied with the principles of the Declaration of Helsinki. The studies for the PCR assay, cytokine measurements, and vMTX were approved by the ethical

committee of Tokyo Medical and Dental University, and written informed consent was obtained from each patient.

## 3 Case reports

### 3.1 Case 1

A 74-year-old woman was admitted to our hospital because of bilateral blurred vision. Severe vitreous opacity was detected in the left (Fig. 1a) and the right (data not shown) eyes. She had a history of pulmonary tuberculosis and chronic hepatitis C. Vitrectomy on the left eye was performed first. Although cytological diagnosis was class 3, a monoclonal band for the IgH gene was detected using the PCR assay. In addition, concentrations of intravitreal IL-10 and IL-6 (normal is undetectable level) were elevated (Fig. 1) with the IL-10/IL-6 ratio of 5.7. Vitrectomy on the right eye was also performed in succession, and atypical class 5 lymphoid cells were detected. IL-10 and IL-6 concentrations were also elevated (Fig. 1), and the IL-10/IL-6 ratio was 3.5. Thus, she was diagnosed with IOL. Magnetic resonance imaging (MRI), lumbar puncture, f-fluorodeoxy glucose positron emission tomography/computerized tomography (FDG-PET/CT), bone marrow aspiration and biopsy were performed and no additional lesions were revealed. Thus, we finally diagnosed her with PIOL. Treatment with 400 µg vMTX for each eye was started. It was effective and vitreous opacity and ocular fundus findings improved rapidly and markedly (Fig. 1b). The IL-10 level in the vitreous fluid decreased rapidly and was undetectable after 2 and one time vMTX in right and left eye, respectively (Fig. 1). No adverse events occurred, although the patient had chronic hepatitis. vMTX was administered once a month; however, 6 months after diagnosis, the IL-10 level in the vitreous fluid increased again (Fig. 1). In addition, some white spots developed on the retina of the left eye (Fig. 1c). There were no neurological symptoms, but an enhancing lesion was detected in the left lateral lobe bordering on the posterior horn of the ventricle by brain MRI (Fig. 1e). Taken together, we diagnosed a recurrence of IOL with CNS involvement. The cytology of the spinal fluid was class 2, and a systemic survey revealed no other involvement. We started systemic chemotherapy as described in "Materials and methods". Because of chronic hepatitis, however, we reduced the doses of PCZ and VCR to 100 and 1 mg/day, respectively. MTX was administered to the vitreous cavities of both eyes on days 2, 13, 22, and 34. Grade 3 leukocytopenia was the only adverse effect greater than grade 2, and no ocular complications were observed. After the treatment, the vitreous IL-10 level was undetectable, and the ophthalmological findings improved (Fig. 1d). Finally, the CNS



**Fig. 1** Clinical course of Case 1. *vMTX* intravitreal methotrexate injection. *Black arrows* indicate each *vMTX*. *sMTX* systemic intravenous injection of methotrexate, *VCR* vincristine, *PCZ* procarbazine, *ND* not detected. **a** Left fundus findings at diagnosis. Severe opacity of the vitreous was detected. **b** Opacity was improved significantly after the first intravitreal MTX injection. **c** Recurrence of ocular lesion. Subretinal white masses were detected. **d** The opacity

and white mass disappeared after finishing systemic intravenous and intravitreal injection of methotrexate. **e** Magnetic resonance imaging of the brain at recurrence of ocular lesion, gadolinium contrast, T1-weighted image. The enhanced lesion was detected at the posterior angle of the left lateral ventricle. **f** The lesion disappeared after finishing systemic intravenous and intravitreal injection of methotrexate

lesion disappeared (Fig. 1f) and was considered complete response. There has been no recurrence for more than 1 year.

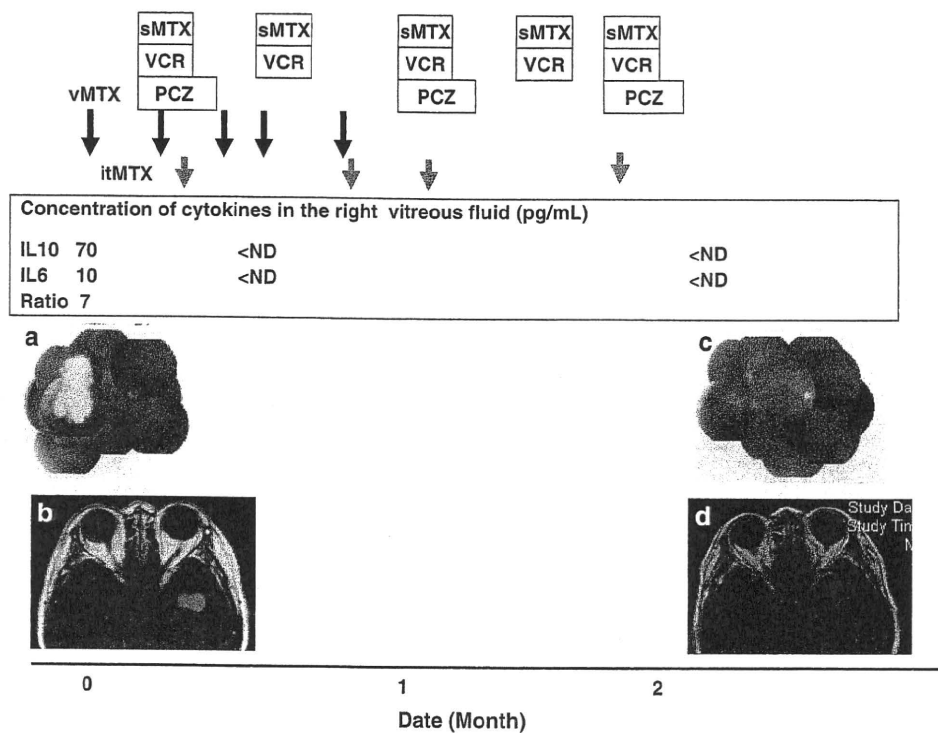
### 3.2 Case 2

A 59-year-old woman was admitted to our hospital because of blurred vision in the right eye. She was congenitally blind in her left eye because of vitreous opacity by an unknown etiology. An ophthalmological examination revealed uveitis and a white subretinal mass in the right eye (Fig. 2a). Vitrectomy on the right eye was performed, and the cytology was class 1. However, a monoclonal band for the IgH gene was detected by the PCR assay, and intravitreal concentrations of IL-10 and IL-6 were elevated (Fig. 2). The IL-10/IL-6 ratio was 7, and she was diagnosed with IOL. No abnormal lesions were detected by FDG-PET/CT or bone marrow aspiration and biopsy. However, soon after vitrectomy, she developed short memory disturbance and dysarthria. Brain MRI revealed a mass lesion in the left temporal lobe (Fig. 2c). Lumbar puncture was performed, and the number of cells was slightly elevated at 13/ $\mu$ L (class 3). We started *vMTX* followed by concurrent *sMTX* and *vMTX* administered into the right vitreous body on days 5, 11, 18, and 25. There

were no adverse events during the treatment. After the third *vMTX* treatment, the IL-10 level in the vitreous fluid was undetectable, and ocular findings had significantly improved (Fig. 2b). MRI confirmed improvement of the CNS lesion (Fig. 2d). After additional radiation therapy to the whole brain (total 40 Gy), the CNS lesion disappeared, and there has been no recurrence for more than 1 year.

### 3.3 Case 3

A 53-year-old woman was admitted to our hospital because of bilateral blurred vision. Severe vitreous opacity was detected in the both eyes (Fig. 3a). She was diagnosed with uveitis. However, IOL was suspected because her lesions were refractory to steroid. She was admitted and vitrectomy on the right eye was performed. Cytological diagnosis could not be made because cells were highly degenerated. However, a monoclonal band for the IgH gene was detected by the PCR assay. In addition, a predominance of infiltrated cells for a  $\kappa$ -light chain expression was detected by flow cytometry (Fig. 3c). Intravitreal IL-10 and IL-6 concentrations were markedly elevated, and the IL-10/IL-6 ratio was 36.7 (Fig. 3). Thus, she was diagnosed with IOL. Vitrectomy on the left eye was performed in succession. IL-6 was slightly elevated without



**Fig. 2** Clinical course of Case 2. *vMTX* intravitreal methotrexate injection. *Black arrows* indicate each *vMTX*. *sMTX* systemic intravenous injection of methotrexate, *itMTX* intrathecal methotrexate injection. *Gray arrows* indicate each *itMTX*. *VCR* vincristine, *PCZ* procarbazine, *ND* not detected. **a** Right fundus findings at diagnosis. A subretinal white mass was detected in the right fundus.

**b** White mass was reduced in size after finishing systemic intravenous and intravitreal injection of methotrexate. **c** Magnetic resonance imaging of the brain at diagnosis, gadolinium contrast, T1-weighted image. The enhanced lesion was detected at the left lateral lobe. **d** The lesion was improved significantly after finishing systemic intravenous and intravitreal injection of methotrexate

detection of IL-10. The rearrangement of IgH gene was detected. However, at the time when the second surgery was performed, she developed a rapidly progressive motor aphasia and loss of muscle strength in the right superior limb. Her brain MRI revealed multiple mass lesions in both parietal lobes (Fig. 3d). Lumbar puncture was normal. FDG-PET/CT, bone marrow aspiration, and biopsy were also normal. We started *vMTX* followed by concurrent *sMTX* and *vMTX* administered into the both vitreous cavities on days 8, 15, 29, and 48. All adverse events were grade 2 or less during the treatment, and no ocular complications occurred. After *vMTX* treatment (right eye, 2 times *vMTX*; left eye, 1 time *vMTX*), the IL-6 and the IL-10 in the vitreous fluid became undetectable, and the ocular (Fig. 3b) and brain MRI findings (Fig. 3e) improved. After additional radiation therapy to the whole brain (total 40 Gy), the CNS lesion disappeared, and there has been no recurrence for more than 5 months.

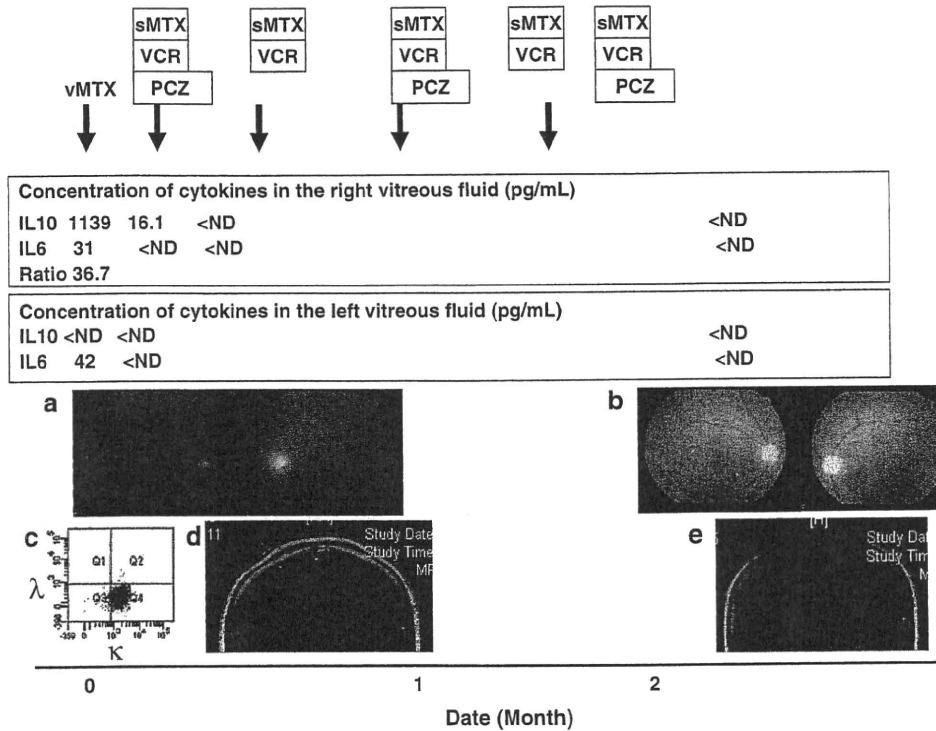
### 3.4 MTX concentrations and its half-life in the vitreous fluid

Among our patients, 2 (cases 2 and 3) received *sMTX* (second administration) followed by *vMTX* 2 h later. We

measured intravitreal MTX concentrations in 3 eyes of these 2 patients at 2 time points; 2 h after *sMTX* (just before *vMTX*) and 24 h after adding *vMTX* to *sMTX*. The results were summarized in Table 1. The intravitreal MTX concentration 2 h after *sMTX* ranged widely in cases 2 and 3, which might be caused by differences of the time of administration. In addition, we analyzed the pharmacokinetics of MTX in the vitreous fluid. Since the vitreous volume was considered 4–5 mL, the MTX concentration just after intravitreal administration of 400  $\mu\text{g}$  was estimated at 176–220  $\mu\text{M}$ . By assuming the first-order elimination kinetics, the half-life of MTX in the vitreous fluid is estimated to be 12.4–14.8 h in case 2, 14.8–18.4 h in the right eye of case 3, and 16.8–21.5 h in the left eye of case 3.

## 4 Discussion

The optimal treatment for IOL has not been established, but local ocular irradiation achieves remission in most cases. However, complications such as retinopathy, keratitis, cataract, and optic nerve disturbances are inevitable [11]. In contrast, *vMTX* is highly effective and safe



**Fig. 3** Clinical course of Case 3. *vMTX* intravitreal methotrexate injection. *Black arrows* indicate each *vMTX*. *sMTX* systemic intravenous injection of methotrexate, *VC* vincristine, *PCZ* procarbazine, *ND* not detected. **a** Bilateral fundus findings at diagnosis. Severe opacity of the vitreous was detected. **b** Opacity was cleared after finishing systemic intravenous and intravitreal injection of methotrexate. **c** Flow cytometry of the right vitreous fluid. Dominant

expression of  $\kappa$ -light chain on surface of the infiltrated cells was detected. **d** Magnetic resonance imaging of the brain at diagnosis, gadolinium contrast, T1-weighted image. The enhanced lesion was detected at the left lateral lobe. **e** The lesion was significantly improved after finishing systemic intravenous and intravitreal injection of methotrexate

**Table 1** Concentration of methotrexate

	Vitreous 2 h after sMTX ( $\mu$ M)	Vitreous 24 h after adding <i>vMTX</i> to sMTX ( $\mu$ M)	Serum sMTX without <i>vMTX</i>	Serum sMTX with <i>vMTX</i>
Case 2	11.86	60.94	1.14 $\mu$ M (24 h) 0.12 $\mu$ M (48 h)	1.47 $\mu$ M (24 h) 0.09 $\mu$ M (48 h)
Case 3 right	1.91	72.11	0.99 $\mu$ M (24 h) 0.16 $\mu$ M (48 h)	1.07 $\mu$ M (24 h) 0.16 $\mu$ M (48 h)
Case 3 left	3.39	82.89		

*MTX* methotrexate, *sMTX* systemic intravenous MTX injection, *vMTX* intravitreal MTX injection

compared to irradiation. De Smet et al. investigated the effect of *vMTX* for 18 IOL patients. Among them, 16 were treated with 400  $\mu$ g/dose of *vMTX* alone; the injection was initially given twice a week, followed by once a week for 1 month, and then monthly for 9 months to 1 year [6]. They reported that response rate was 100% (16/16) and that most complications were transient and reversible. However, it was written that most patients developed the CNS involvement. The results are summarized in Table 2. Ocular recurrences occurred 19% (3/16), but they responded well to a reinjection of *vMTX*. Recently, Frenkel et al. [7] reviewed the clinical courses of 26 IOL patients with or without CNS involvement treated by *vMTX*. They also

concluded that IOL could be controlled effectively by *vMTX* with 95% of response rate for the local lesions without serious adverse event. No local recurrence was observed. However, they reported that 14 patients died of the CNS or systemic involvement. This might mean that *vMTX* was unable to control the CNS involvement. Actually, our case 1 developed a CNS relapse after achieving ocular response with clearance of IL-10 in the vitreous fluid by *vMTX*. On the other hand, Batchelor and colleagues [8] investigated the effect of *sMTX* on IOL. Nine patients (IOL alone in 1, IOL accompanied by CNS disease in 8) with IOL were treated with *sMTX* (8 g/m<sup>2</sup> MTX administered every 28 days for 11 doses). As shown

**Table 2** Response of methotrexate administration in the reported cases

Administration	Patients	RR of ocular lesion	Ocular recurrence	RR of CNS lesion	CNS recurrence	Reference
vMTX	16	100%	19% (3/16)	ND	Most patients	[6]
vMTX	44 eyes of 26 patients (16 with CNS and systemic)	95% (CR 91%)	0	ND	ND	[7]
sMTX	9	78% (CR 67%)	86% (6/7)	100%	ND	[8]

MTX methotrexate, sMTX systemic intravenous MTX injection, vMTX intravitreal MTX injection, CNS central nervous system, RR response rate, CR complete response, ND not described

in Table 2, response rate for ocular lesion was 78% (7/9), which was lower than that of vMTX in the other reports, and the recurrence rate was 86% (6/7), which was distinctively higher than that of vMTX. Taken together, although sMTX was quite effective for CNS lesions, it was insufficient for most patients who had intraocular involvement.

To the best of our knowledge, there have been no reported cases in which systemic and intravenous MTX was administered simultaneously. Grim et al. [12] analyzed 176 patients with primary CNSL and ocular lesions. They concluded that median progression-free survival was prolonged in patients who were treated for both CNS and ocular involvement compared with those who did not receive dedicated ocular therapy, whereas overall survival was not [12]. However, CNS treatment in the report included not only MTX-based regimen but also CHOP and radiation therapy. From our results, concurrent administration of vMTX and sMTX may be appropriate and effective for IOL with CNS involvements, and study should be added to evaluate that.

We measured intravitreal MTX concentrations in 3 eyes of 2 patients at 2 different time points. As shown in Table 1, those who received sMTX had widely ranging values from 1.91 to 11.86  $\mu\text{M}$ . Since it has been reported that the effective MTX concentration for lymphoma is  $>1 \mu\text{M}$ , these concentrations were high enough to control lymphoma cells despite the wide range. Batchelor et al. [8] measured serum and vitreous levels of MTX and determined that intravitreal MTX concentrations 4 h after sMTX also ranged widely (1.46–24.0  $\mu\text{M}$ ). However, they concluded that there was no significant correlation between treatment effectiveness and the MTX concentration. The reason for this wide range in intravitreal MTX concentrations after sMTX has not been clarified. The wide range of intravitreal MTX concentration 2 h after sMTX in cases 2 and 3 in the present report may have been caused because of differences in the duration of infusion. We administered systemic MTX for 6 h in case 2 and for 2 h in case 3. It is also notable that severe subretinal lesion was detected in case 2. The disease status, including a rupture of blood-retinal barrier, might have also caused the difference.

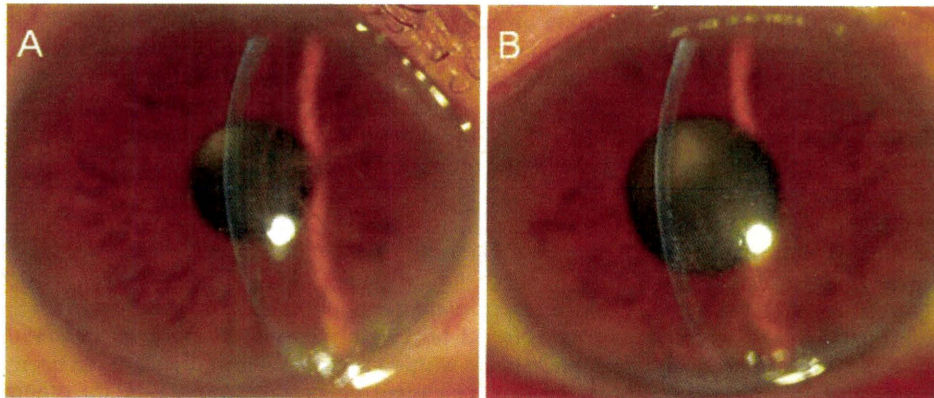
There have been a report analyzing pharmacokinetics of MTX in the vitreous fluid. De Smet and colleagues [13] reported a case with IOL who underwent repeated intravitreal injections of MTX and thiotepa. In the report vitreous samples were taken before each injection and MTX concentrations were determined. Then, they analyzed kinetics of MTX in the vitreous fluid by evaluating the correlation between time after previous injection and the concentration of MTX. They found a linear relationship between time and logarithmic plot of the concentration, suggesting a first-order elimination kinetics of MTX. According to this, the half-life of MTX in the vitreous fluid was estimated to be 12.4–21.5 h in our cases, which was much longer than that of blood level. Because there have been reported few eye complications [14], it was considered that the tolerability for vMTX was very high. Although the previous report demonstrated that MTX concentration in the vitreous fluid and its effect did not correlate with each other [8], administration strategies can be arranged in the future to obtain optimal effects, for instance by increasing intensity or density of vMTX.

In summary, our cases reveal that concurrent treatment with sMTX and vMTX may be effective for IOL with CNS involvement. More study is needed in order to examine efficacy as well as safety and to establish the optimal treatment for the disease.

## References

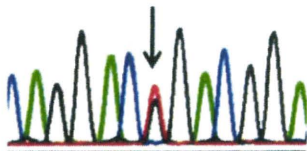
1. Bardenstein DS. Intraocular lymphoma. *Cancer Control*. 1998;5:317–25.
2. Whitcup SM, Stark-Vancs V, Wittes RE, Solomon D, Podgor MJ, Nussenblatt RB, et al. Association of interleukin 10 in the vitreous and cerebrospinal fluid and primary central nervous system lymphoma. *Arch Ophthalmol*. 1997;115:1157–60.
3. Chan CC. Molecular pathology of primary intraocular lymphoma. *Trans Am Ophthalmol Soc*. 2003;101:275–92.
4. Hormigo A, Abrey L, Heinemann MH, DeAngelis LM. Ocular presentation of primary central nervous system lymphoma: diagnosis and treatment. *Br J Haematol*. 2004;126:202–8.
5. Coupland SE, Heimann H, Bechrakis NE. Primary intraocular lymphoma: a review of the clinical, histopathological and

- molecular biological features. *Graefes Arch Clin Exp Ophthalmol.* 2004;242:901–13.
6. de Smet MD. Management of non Hodgkin's intraocular lymphoma with intravitreal methotrexate. *Bull Soc Belge Ophthalmol.* 2001;279:91–5.
  7. Frenkel S, Hendler K, Siegal T, Shalom E, Pe'er J. Intravitreal methotrexate for treating vitreoretinal lymphoma: 10 years of experience. *Br J Ophthalmol.* 2008;92:383–8.
  8. Batchelor TT, Kolak G, Ciordia R, Foster CS, Henson JW. High-dose methotrexate for intraocular lymphoma. *Clin Cancer Res.* 2003;9:711–5.
  9. Chhanabhai M, Adomat SA, Gascoyne RD, Horsman DE. Clinical utility of heteroduplex analysis of TCR gamma gene rearrangements in the diagnosis of T-cell lymphoproliferative disorders. *Am J Clin Pathol.* 1997;108:295–301.
  10. Abrey LE, Yahalom J, DeAngelis LM. Treatment for primary CNS lymphoma: the next step. *J Clin Oncol.* 2000;18:3144–50.
  11. Ferreri AJ, Blay JY, Reni M, Pasini F, Gubkin A, Tirelli U, et al. Relevance of intraocular involvement in the management of primary central nervous system lymphomas. *Ann Oncol.* 2002;13:531–8.
  12. Grimm SA, McCannel CA, Omuro AM, Ferreri AJ, Blay JY, Neuwelt EA, et al. Primary CNS lymphoma with intraocular involvement: International PCNSL Collaborative Group Report. *Neurology.* 2008;71:1355–60.
  13. de Smet MD, Vancs VS, Kohler D, Solomon D, Chan CC. Intravitreal chemotherapy for the treatment of recurrent intraocular lymphoma. *Br J Ophthalmol.* 1999;83:448–51.
  14. Sugita S, Takase H, Sugamoto Y, Arai A, Miura O, Mochizuki M. Diagnosis of intraocular lymphoma by polymerase chain reaction analysis and cytokine profiling of the vitreous fluid. *Jpn J Ophthalmol.* 2009;53:209–14.



**Figure 1A, B.** Slit-lamp photographs demonstrating the corneal findings. **A** Several bifurcating, thick lattice lines in the superficial stroma are noted in the right eye. **B** Discrete and nodular opacities are noted in the deep stroma of the central cornea in the patient's left eye.

C A G G A C T G A C G G /  
133



**Figure 2.** Results of the direct sequencing of exon 12 in the *TGFBI* gene. A heterozygous L527R mutation (CTG→CGG) is detected.

with the L527R mutation is unique in terms of its late onset, sporadic occurrence, and regional idiosyncrasy. It has been reported that the L527R mutation is descended from a founder mutation that occurred in a single Japanese ancestor.<sup>5</sup> Therefore, additional data are required to elucidate the clinical and genetic manifestations of lattice corneal dystrophy associated with the L527R mutation.

**Keywords:** lattice corneal dystrophy, L527R mutation, *TGFBI* gene

Takako Ohnishi, Tohru Sakimoto, and Mitsuru Sawa  
Department of Ophthalmology, Division of Visual Science, Nihon University School of Medicine, Tokyo, Japan

Received: April 30, 2010 / Accepted: July 29, 2010

Correspondence to: Tohru Sakimoto, Department of Ophthalmology, Division of Visual Science, Nihon University School of Medicine, 30-1 Oyaguchi Kamimachi, Itabashi-ku, Tokyo 173-8610, Japan  
e-mail: torusaki@gmail.com

DOI 10.1007/s10384-010-0882-1

## References

1. Fujiki K, Hotta Y, Nakayasu K, et al. A new L527R mutation of the  $\beta$ IGH3 gene in patients with lattice corneal dystrophy with deep stromal opacities. *Hum Genet* 1998;103:286–289.
2. Kawashima M, Yamada M, Funayama T, Mashima Y. Six cases of late-onset lattice corneal dystrophy associated with the transforming growth factor beta induced gene mutations [in Japanese] *Nippon Ganka Gakkai Zasshi* 2005;109:93–100.
3. Afshari NA, Bahadur RP, Eifrig DE Jr, et al. Atypical asymmetric lattice corneal dystrophy associated with a novel homozygous mutation (Val624Met) in the *TGFBI* gene. *Mol Vis* 2008;14:495–499.
4. Funayama T, Mashima Y, Kawashima M, et al. Lattice corneal dystrophy type III in patients with a homozygous L527R mutation in the *TGFBI* gene. *Jpn J Ophthalmol* 2006;50:62–64.
5. Fukuoka H, Kawasaki S, Yamasaki K, et al. Lattice corneal dystrophy type IV (p.Leu527Arg) was caused by a founder mutation of the *TGFBI* gene in a single Japanese ancestor. *Invest Ophthalmol Vis Sci* 2010;51:4523–4530.

## Endogenous Candida Chorioretinitis in a Healthy Infant

Endogenous *Candida* endophthalmitis is often observed in patients with a history of recent major surgery, bacterial sepsis, use of systemic antibiotics, placement of central venous catheters, or a combination of these. Newborns, especially those born prematurely, do not have a sufficiently developed immune system against pathogens; however, they rarely develop endogenous fungal infections. Several infants with *Candida* chorioretinitis have been reported so far, all of whom had undergone surgery or total parenteral alimentation, received antibiotics, or were not full-term babies.<sup>1</sup> We report a case of a healthy infant with endogenous *Candida* chorioretinitis who had no risk factors for an opportunistic infection.

## Case Report

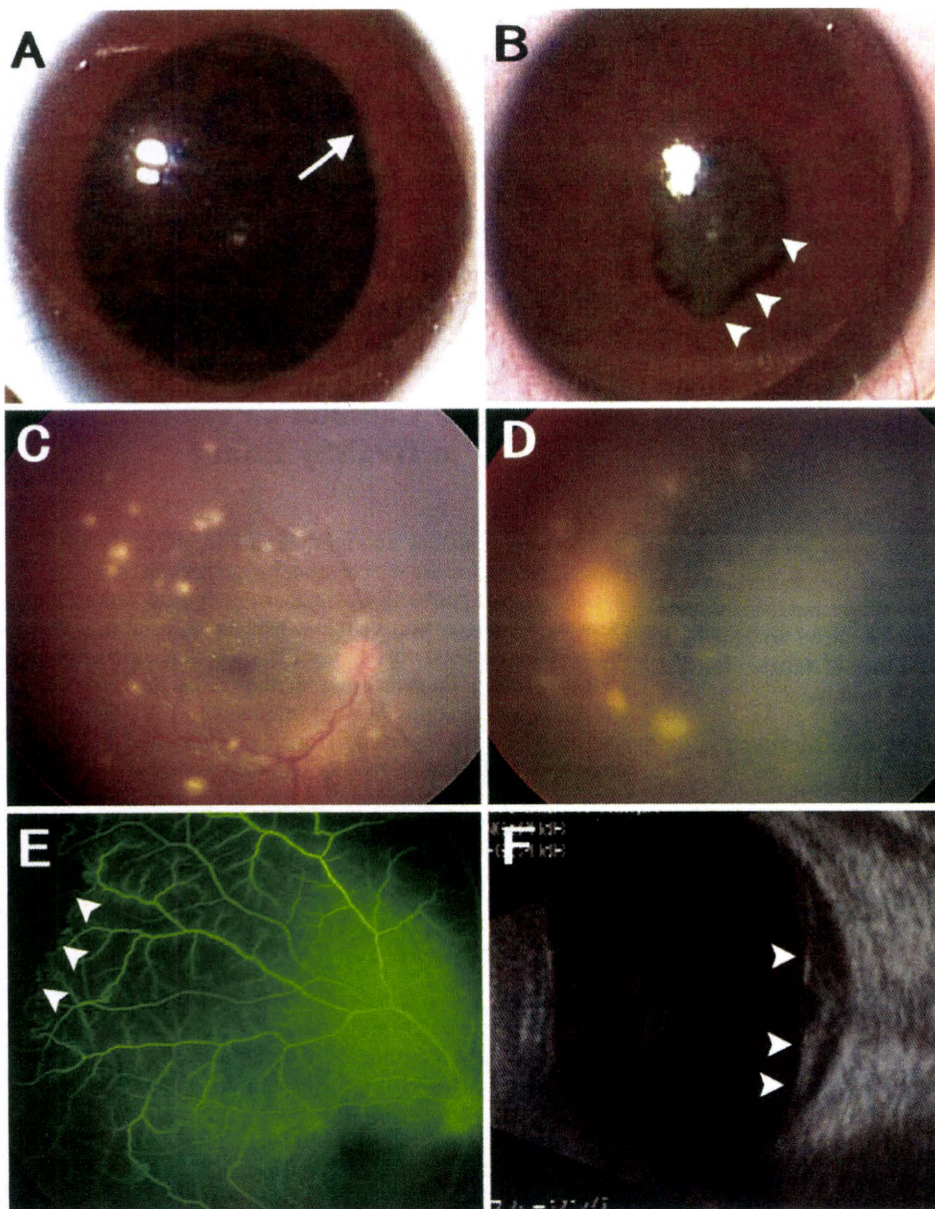
A 41-week-gestation female infant (body weight, 2910 g) was delivered by Caesarean section because of delayed labor. No problems occurred during the developmental and perinatal periods. At 6 months of age, she became transiently febrile with temperatures above 38°C despite a lack of other systemic symptoms and was hospitalized for administration of transvenous antibiotics (piperacillin for 3 days and panipenem/betamipron for 10 days). After 2 weeks, she became

afebrile, and a prominent conjunctival injection developed bilaterally. Slit-lamp biomicroscopy identified posterior synechiae and nodules in the iris of the left eye. Ophthalmoscopy identified multiple white lesions along the retinal vessels bilaterally and an exudative total retinal detachment in the left eye (Fig. 1). Fluorescein angiography (FA) showed anastomosis of the vessels and an avascular area in the peripheral retina of the right eye (Fig. 1). Whole-body computed tomography and biochemical, immunological, and culture examinations of blood and cerebrospinal fluid failed to detect any abnormalities. Polymerase chain reaction (PCR) analysis detected *Candida* DNA in the cerebrospinal fluid ( $2.4 \times 10^2$  copies/ml) and vitreous ( $9.4 \times 10^4$  copies/ml) obtained by needle aspiration. Immunological and culture examinations

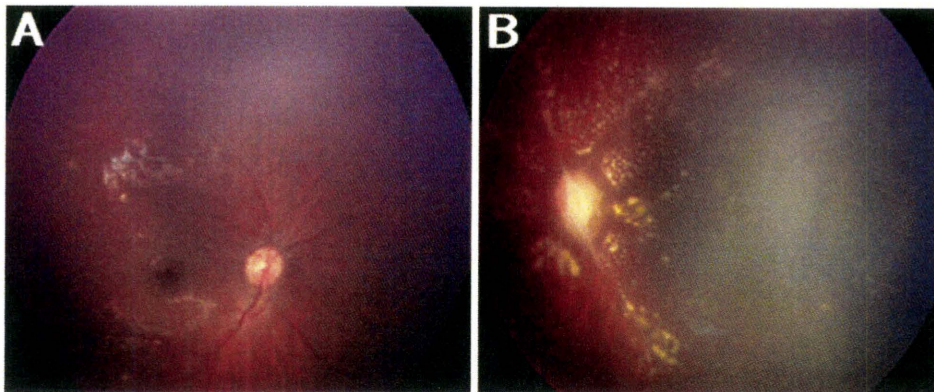
of blood and vaginal secretion from the mother failed to identify any signs of *Candida* infection. After administration of fluconazole (intravenous injection of 100 mg for 3 weeks, then 50 mg orally for 3 months), the retina of the left eye reattached and the volume of white lesions decreased, resulting in residual retinal scars (Fig. 2).

### Comment

Endogenous *Candida* endophthalmitis is commonly seen in compromised hosts. Only two adult cases of *Candida* endophthalmitis without severe systemic disease have been reported, one in a patient with a common cold and the other



**Figure 1A–F.** Chorioretinitis before treatment. Photographs of the anterior segment (**A**, **B**) and fundus (**C**, **D**); fluorescein angiogram (**E**); and ultrasonogram (**F**). **A**, **C**, **E** Right eye; **B**, **D**, **F** left eye. **A** A slight posterior synechia of the iris margin (*arrow*) was observed. **B** An entire posterior synechia and nodules of the iris (*arrowheads*). **C** Multiple white lesions were seen along the retinal vessels. **D** Exudative retinal detachment and multiple white lesions were observed along the retinal vessels. **E** An avascular area in the peripheral retina (*arrowheads*) and anastomosis of vessels and leakage from retinal veins were observed, despite no staining of the white lesions. **F** Retinal detachment (*arrowheads*) was detected by ultrasonography.



**Figure 2A, B.** Fundus photographs of the **A** right and **B** left eyes 1 month after administration of fluconazole. **A** The size of the white lesions had decreased significantly. **B** Retinal reattachment with hard exudates, white vessels, and optic disc pallor were observed.

in a patient with *Candida* vaginitis and onychomycosis; both patients were treated with antibiotics.<sup>2,3</sup> The current patient had no systemic abnormalities but evidently had endogenous *Candida* endophthalmitis because PCR analysis detected sufficient quantities of *Candida* DNA in the vitreous and the cerebrospinal fluid to diagnose the infection. FA findings of abnormal vasculature in the peripheral retina are usually seen in eyes with retinopathy of prematurity or familial exudative vitreoretinopathy, which prompted us to suspect that the *Candida* infection in the present case was congenital. Generally, a congenital *Candida* infection occurs by vertical transmission through the uterus or vagina and is associated with systemic involvement, including dermatitis, meningitis, anomaly of the brain, and oral mucositis.<sup>4</sup> However, the patient was delivered by Caesarean section, and no signs of *Candida* infection were detected in the mother. Thus, acquired *Candida* infection was the most likely diagnosis in the present case. Intravenous antibiotics delivered 2 weeks before the onset of bilateral endophthalmitis likely caused iatrogenic *Candida* infection because of inadvertent manipulation. Possible insufficient growth of the retinal vasculature might have facilitated the proliferation of *Candida* in the patient's retina.

To diagnose and treat such a difficult case, broad-range PCR for the 18S ribosomal RNA sequence is a good screening tool.<sup>5</sup> Moreover, real-time PCR can examine the quantity of the pathogen and determine its relation to the endophthalmitis. Early treatment of infectious endophthalmitis is essential in infants, in whom vision develops rapidly. Thus, a broad-range, real-time PCR system using ocular samples is useful when the patient has uveitis or endophthalmitis of unknown origin.

**Keywords:** *Candida* chorioretinitis, *Candida* infection, polymerase chain reaction

Makiko Ito<sup>1</sup>, Tadashi Yokoi<sup>1</sup>, Sunao Sugita<sup>2</sup>, Naomi Shinohara<sup>3</sup>, Sachiko Nishina<sup>1</sup>, and Noriyuki Azuma<sup>1</sup>

<sup>1</sup>Department of Ophthalmology, National Center for Child Health and Development, Tokyo, Japan; <sup>2</sup>Department of Ophthalmology and Visual Science, Tokyo Medical and Dental University Graduate School of Medicine and Dental Sciences, Tokyo, Japan; <sup>3</sup>Department of Pediatrics, Tokyo Dental College Ichikawa General Hospital, Chiba, Japan

Received: January 14, 2010 / Accepted: June 8, 2010

Correspondence to: Noriyuki Azuma, Department of Ophthalmology, National Center for Child Health and Development, 2-10-1 Okura, Setagaya-ku, Tokyo 157-8535, Japan  
e-mail: azuma-n@ncchd.go.jp

DOI 10.1007/s10384-010-0871-4

## References

1. Palmer EA. Endogenous *Candida* endophthalmitis in infants. *Am J Ophthalmol* 1980;89:388–395.
2. Williams MA, McMullan R, Hedderwick S, Mulholland DA, Best RM. Diagnosis and treatment of endogenous fungal endophthalmitis. *Ophthalmologica* 2006;220:134–136.
3. Kostick DA, Foster RE, Lowder CY, Meyers SM, McHenry MC. Endogenous endophthalmitis caused by *Candida albicans* in a healthy woman. *Am J Ophthalmol* 1992;113:593–595.
4. Michael JM. Fungal infections. In: Remington JS, Klein JO, editors. *Infectious diseases of the fetus and newborn infant*. Philadelphia: WB Saunders; 1983. p. 466–469.
5. Jaeger EEM, Carroll NM, Choudhury S, et al. Rapid detection and identification of *Candida*, *Aspergillus*, and *Fusarium* species in ocular samples using nested PCR. *J Clin Microbiol* 2000;38:2902–2908.

## Choroidal Neovascularization in a Child Following Laser Pointer-Induced Macular Injury

Laser pointer-induced macular injury is characterized by a decrease in visual acuity and metamorphopsia.<sup>1</sup> High-energy lasers can cause chorioretinal damage, which can lead to choroidal neovascularization (CNV) in animals.<sup>2</sup> Case reports of the development of a CNV following laser-induced macular injury have also been published.<sup>3,4</sup> We report the case of a child with a CNV that developed following a macular injury caused by repeated exposure to a green laser pointer. The prevalence of CNV in children is low, but it is still an important cause of visual impairment.<sup>5</sup> To the best of our knowledge, this is the first report of a child developing CNV following a macular injury caused by exposure to a green laser pointer.

# 角膜炎を伴わない単純ヘルペスウイルス1型 虹彩毛様体炎の3例

山本紗也香<sup>\*1,2</sup> 杉田 直<sup>\*1</sup> 堀江真太郎<sup>\*1</sup> 清水則夫<sup>\*3</sup> 森尾友宏<sup>\*4</sup> 望月 學<sup>\*1</sup>

<sup>\*1</sup> 東京医科歯科大学大学院医歯学総合研究科眼科学分野    <sup>\*2</sup> 柏市立柏病院眼科    <sup>\*3</sup> 東京医科歯科大学難治疾患研究所  
フロンティア研究室ウイルス治療学    <sup>\*4</sup> 東京医科歯科大学細胞治療センター

Three Cases of Herpes Simplex Virus-1 Anterior Uveitis in the Absence of Keratitis

Sayaka Yamamoto<sup>1,2)</sup>, Sunao Sugita<sup>1)</sup>, Shintaro Horie<sup>1)</sup>, Norio Shimizu<sup>3)</sup>,  
Tomohiro Morio<sup>4)</sup> and Manabu Mochizuki<sup>1)</sup>

<sup>1)</sup> Department of Ophthalmology & Visual Science, Tokyo Medical and Dental University Graduate School of Medicine,

<sup>2)</sup> Department of Ophthalmology, Kashiwa City Hospital, <sup>3)</sup> Virus Research Unit, Frontier Research Unit, Medical  
Research Institute, <sup>4)</sup> Center for Cell Therapy, Tokyo Medical and Dental University

---

あたらしい眼科 *Atarashii Ganka (J. Eye)*  
Vol. 27 No. 2 2010 別刷

---

(株) メディカル葵出版

# 角膜炎を伴わない単純ヘルペスウイルス1型虹彩毛様体炎の3例

山本紗也香<sup>\*1,2</sup> 杉田 直<sup>\*1</sup> 堀江真太郎<sup>\*1</sup> 清水則夫<sup>\*3</sup> 森尾友宏<sup>\*4</sup> 望月 學<sup>\*1</sup>

<sup>\*1</sup>東京医科歯科大学大学院医歯学総合研究科眼科学分野 <sup>\*2</sup>柏市立柏病院眼科 <sup>\*3</sup>東京医科歯科大学難治疾患研究所  
フロンティア研究室ウイルス治療学 <sup>\*4</sup>東京医科歯科大学細胞治療センター

## Three Cases of Herpes Simplex Virus-1 Anterior Uveitis in the Absence of Keratitis

Sayaka Yamamoto<sup>1,2)</sup>, Sunao Sugita<sup>1)</sup>, Shintaro Horie<sup>1)</sup>, Norio Shimizu<sup>3)</sup>, Tomohiro Morio<sup>4)</sup> and Manabu Mochizuki<sup>1)</sup>

<sup>1)</sup> Department of Ophthalmology & Visual Science, Tokyo Medical and Dental University Graduate School of Medicine,

<sup>2)</sup> Department of Ophthalmology, Kashiwa City Hospital, <sup>3)</sup> Virus Research Unit, Frontier Research Unit, Medical Research Institute, <sup>4)</sup> Center for Cell Therapy, Tokyo Medical and Dental University

虹彩毛様体炎患者の前房水より単純ヘルペスウイルス1型 (HSV-1) DNA が polymerase chain reaction (PCR) 法で高値を示し、HSV-1 による虹彩毛様体炎と考えられたが、経過中に角膜病変がみられなかった3例を経験した。3例ともに虹彩毛様体炎のため東京医科歯科大学眼科を受診し、PCR 検査で前房水より高コピー数の HSV-1 DNA が検出された。角膜知覚低下が全例に、高眼圧と隅角色素沈着が3例中2例にみられた。いずれの症例もバラシクロビル内服、アシクロビル眼軟膏、ステロイド点眼、眼圧降下薬で軽快したが、経過観察中に角膜病変および虹彩萎縮はみられなかった。ヘルペスウイルスは虹彩毛様体炎の重要な原因ウイルスであるが、角膜病変や虹彩萎縮などの特徴的な所見がない場合、診断に苦慮することも少なくない。その疑いがあるときには、早期から眼内液のウイルス学的な検査が重要であると思われた。

Herpes simplex virus (HSV) is well known as causing unilateral anterior uveitis characterized by keratitis, mutton-fat precipitates, iridocyclitis, ocular hypertension and iris atrophy. We report here on 3 cases of unusual unilateral anterior uveitis caused by HSV. Polymerase chain reaction was performed to determine the genomic DNA of the human herpes virus in the aqueous humor; HSV-1 DNA was detected in all 3 patients. All patients reported diminished corneal sensation, 2 of the 3 also showing intraocular pressure elevation and moderate pigmentation. However, none showed iris atrophy or keratitis. They were treated with oral valacyclovir, topical acyclovir and corticosteroids. Unilateral anterior uveitis may result from infection by HSV-1 even in the absence of keratitis and iris atrophy. Virological analysis of intraocular fluid, followed by anti-viral treatment, is therefore recommended from the early stage of this disease.

(Atarashii Ganka (Journal of the Eye) 27(2) : 252~255, 2010)

**Key words** : ポリメラーゼ連鎖反応, 単純ヘルペスウイルス1型, 虹彩毛様体炎, 角膜炎, polymerase chain reaction (PCR), herpes simplex virus-1 (HSV-1), iridocyclitis, keratitis.

### はじめに

ヘルペス性虹彩毛様体炎は、前部ぶどう膜炎の約5~10%を占めるとされており<sup>1)</sup>、原因ウイルスとして、単純ヘルペスウイルス (HSV)、水痘・帯状疱疹ウイルス (VZV)、サイトメガロウイルス (CMV) が報告されている<sup>2,3)</sup>。HSVは角膜、前房、虹彩、線維柱帯など多くの眼内組織に炎症を起こすことが知られており、角膜に樹枝状角膜炎や角膜内皮炎などの炎症を伴う場合は角膜ぶどう膜炎 (keratouveitis) とよ

ばれる。HSVはHSV-1とHSV-2の2つのサブタイプが存在するが、この角膜ぶどう膜炎の原因ウイルスはほとんどがHSV-1と考えられている。一方、VZVが原因の前部ぶどう膜炎では角膜に炎症所見はなく経過中に虹彩萎縮や麻痺性散瞳などの合併症を伴うことが多い。HSVによる虹彩毛様体炎でもこのような虹彩萎縮がみられることがある。近年、CMVが前部ぶどう膜炎に関与することを示す報告<sup>3,4)</sup>があり、このような症例ではPosner-Schlossman症候群に類似

〔別刷請求先〕 山本紗也香 : 〒113-8519 東京都文京区湯島1-5-45 東京医科歯科大学大学院医歯学総合研究科眼科学分野  
Reprint requests : Sayaka Yamamoto, M.D., Department of Ophthalmology & Visual Science, Tokyo Medical and Dental University Graduate School of Medicine, 1-5-45 Yushima, Bunkyo-ku, Tokyo 113-8519, JAPAN

した高眼圧を伴う虹彩炎か角膜炎の所見を示す。このように、ヘルペスウイルスが原因の前部ぶどう膜炎は、経過中に角膜病変や虹彩萎縮といった特徴的な所見を伴わない場合、臨床的な診断に苦慮することも少なくない。今回筆者らは、経過中に角膜病変や虹彩萎縮などのHSVに特徴的とされる眼所見を伴わない虹彩毛様体炎の前房水よりHSV-1 DNAがpolymerase chain reaction (PCR) 検査で陽性を示し、HSV-1 虹彩毛様体炎と考えられた3症例を経験したので報告する。

## I 症 例

2007年2月から2008年3月の期間に、東京医科歯科大学病院眼科（以下、当科）を受診し、虹彩毛様体炎の前房水よりHSV-1 DNAが検出され、HSV-1 虹彩毛様体炎と考えられた3症例。

〔症例1〕 58歳，女性。

現病歴：左眼の視力低下，充血，霧視が出現したため近医を受診し，左眼視力低下（0.6），眼圧上昇（36mmHg），虹彩炎のためフルオロメトロン点眼，アセタゾラミド内服を開始されたが，改善しないため2007年2月に当科紹介受診となった。

初診時眼所見：視力は右眼0.9（ $1.2 \times +0.25D \text{cyl} -0.75D \text{Ax}70^\circ$ ），左眼0.15（ $0.7 \times -1.25D \text{cyl} -1.00D \text{Ax}75^\circ$ ），眼圧は右眼15mmHg，左眼25mmHg。左眼の前眼部に多数の色素を含む豚脂様角膜後面沈着物，cell 2+程度の中等度の虹彩炎がみられたが，角膜炎はみられなかった（図1）。中間透光体，眼底に異常所見はなく，患眼の隅角に軽度の色素沈着がみられた。角膜知覚は健眼と比べて患眼で低下を示していた。上記の特徴的な眼所見に加えステロイド点眼で改善

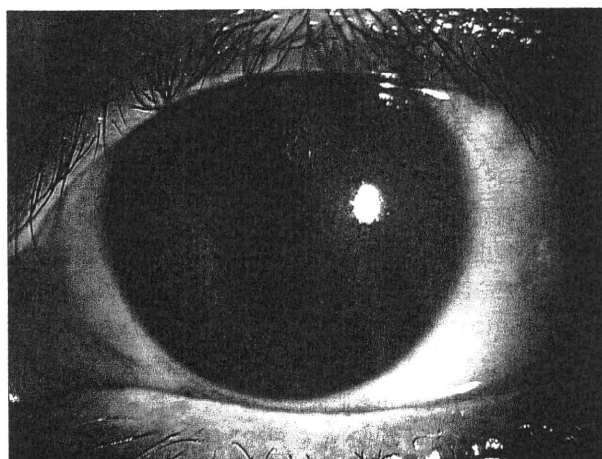


図1 症例1の初診時前眼部写真

多数の色素を含む豚脂様角膜後面沈着物と虹彩炎がみられていた。

しないことよりヘルペス性虹彩毛様体炎を疑い，インフォームド・コンセントのもと前房水を0.1ml採取し，定性PCRでヘルペスウイルス1型から8型のスクリーニングを行った。その結果，HSV-1 DNAが陽性を示し，定量PCRでDNAコピー数を測定したところ $1.7 \times 10^6 \text{copy/ml}$ と高コピー数検出された。

経過：治療はバラシクロビル1,000mg/日の内服を3週間，アシクロビル眼軟膏1日5回，ベタメタゾン点眼1日4回で徐々に改善し，眼圧上昇はアセタゾラミド1日750mg内服で速やかに軽快した。経過中に角膜炎，虹彩萎縮，麻痺性散瞳の出現はみられず，右眼視力（ $1.5 \times +0.50D \text{cyl} -0.50D \text{Ax}70^\circ$ ）に改善した。

〔症例2〕 57歳，男性。

現病歴：前日から右眼の充血，頭痛が出現し，増悪したため2007年2月当科を受診した。

初診時眼所見：視力は右眼0.2（ $0.4 \times -0.50D \text{cyl} -1.00D \text{Ax}110^\circ$ ），左眼0.7（ $1.2 \times +0.50D \text{cyl} -1.00D \text{Ax}20^\circ$ ），眼圧は右眼47mmHg，左眼18mmHg。右眼に強い毛様充血，cell 1+の軽い虹彩炎がみられたが，角膜炎や角膜後面沈着物はみられなかった（図2）。中間透光体，眼底に異常所見はなく，隅角所見に左右差はみられなかったが，角膜知覚は患眼で低下していた。3年前に外眼角部のヘルペスの既往がありヘルペス性虹彩毛様体炎を疑い，前房水を採取し同様にPCRを試行した。その結果HSV-1 DNAが $1.2 \times 10^4 \text{copy/ml}$ と高コピー数検出された。

経過：治療はバラシクロビル1,000mg/日の内服を4週間，アシクロビル眼軟膏1日3回，ベタメタゾン点眼1日4回で徐々に改善し，眼圧上昇はD-マンニトールの点滴静注，アセタゾラミド1日750mg内服で速やかに軽快した。経過中

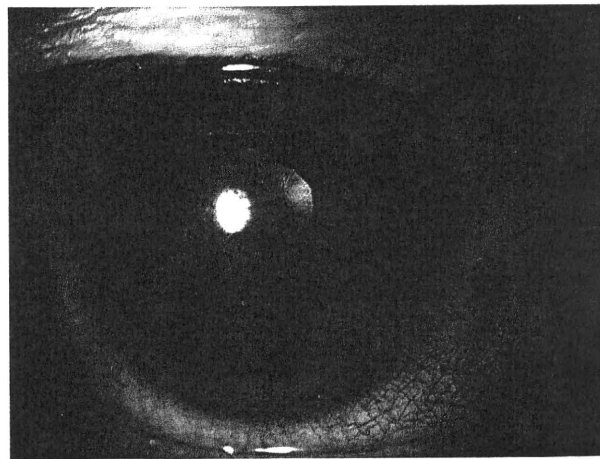


図2 症例2の初診時前眼部写真

強い毛様充血，軽度の虹彩炎がみられたが，角膜炎や角膜後面沈着物はみられなかった。

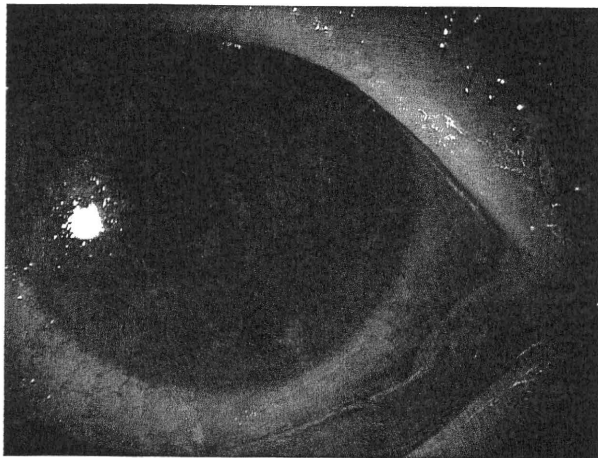


図3 症例3の初診時前眼部写真  
強い毛様充血、大型の豚脂様角膜後面沈着物を伴う虹彩炎、  
虹彩後癒着がみられた。

に角膜炎、虹彩萎縮、麻痺性散瞳の出現はみられず、右眼視力(1.5×+0.50D○cyl-1.25D Ax130°)に改善した。

〔症例3〕 56歳、女性。

現病歴：1週間前からの左眼の充血、異物感、霧視、眼痛があり近医を受診した。左眼に肉芽腫性前部ぶどう膜炎がみられたため、ベタメタゾン点眼、デキサメタゾン結膜下注射を連日施行するも改善しないため2008年3月当科を紹介受診した。

初診時眼所見：視力は右眼0.3(0.8×+2.75D○cyl-5.00D Ax10°)、左眼0.6(0.7×+1.75D○cyl-0.50D Ax130°)、眼圧は右眼12mmHg、左眼14mmHg。右眼に強い毛様充血、大型の豚脂様角膜後面沈着物、cell 4+の虹彩炎、虹彩後癒着がみられたが、角膜炎はみられなかった(図3)。白内障のほかに中間透光体、眼底に異常所見はみられなかった。隅角は患眼のみに色素沈着がみられ、角膜知覚検査では患眼で低下を示していた。ステロイド点眼に抵抗する虹彩毛様体炎よりヘルペス性を疑い、前房水を採取し同様にPCRを試行した結果、HSV-1 DNAが $1.3 \times 10^7$  copy/mlと高コピー数検出された。

経過：治療はアシクロビル眼軟膏1日5回、ベタメタゾン点眼1日4回を開始したが、前眼部炎症が遷延したため、バラシクロビル1,000mg/日の内服を開始したところ徐々に改善した。経過中に角膜炎、虹彩萎縮、麻痺性散瞳の出現はなく、右眼視力(1.0×+1.50D○cyl-0.75D Ax110°)に改善した。

## II 考 按

単純ヘルペスウイルス(HSV)は初感染後に三叉神経節を中心に、中脳、上頸部交感神経節、網膜、角膜に潜伏感染して

いることが報告されている<sup>6)</sup>。HSVはさまざまな刺激により神経節に潜伏感染中のウイルスが再活性化し遠心性に眼組織に到達、もしくは末梢に潜伏感染するウイルスの活性化により、眼瞼炎、角結膜炎、角膜炎(上皮型、実質型、内皮型)、線維柱帯炎、角膜ぶどう膜炎、虹彩毛様体炎、急性網膜壊死といった眼疾患をひき起こす重要な原因ウイルスである。

今回の3症例では、虹彩毛様体炎の程度は軽度から高度までさまざまであり、3例中2例に高眼圧と隅角の色素沈着、角膜知覚低下を全例にみられたが、角膜炎と虹彩萎縮は経過中にみられなかった。HSV虹彩毛様体炎で典型的な角膜上皮炎や角膜内皮炎などがみられなく、片眼性の高眼圧を伴う虹彩炎の場合、Posner-Schlossman症候群(PSS)などとの鑑別が困難であり、原因不明のくり返す虹彩毛様体炎と診断されていることが多いと推測される。

Van der Lelijら<sup>7)</sup>は虹彩萎縮を伴うが角膜病変はみられない特発性前部ぶどう膜炎患者31名中24名の前房水をPCRまたは抗体率で検討した結果、20名がHSV、4名がVZVと考えられたと報告している。この報告では90%に眼圧上昇がみられ、32%は角膜知覚が低下しており、20%は当初PSSと診断されていた。今回の3例中2例でも眼圧上昇がみられており、片眼性の虹彩毛様体炎で高眼圧症がみられた場合には、経過中に角膜炎がなくてもヘルペス感染を疑う必要があると思われた。今回の3症例では全例で角膜知覚は低下しており、検眼鏡的に角膜病変はみられなかったが、角膜に分布する神経内でヘルペスウイルスが活性化している可能性が考えられた。HSVやVZVによる虹彩毛様体炎による虹彩萎縮は一般的に発症後数カ月経過してから出現することが多いとされており、今回の3症例でも、早期から抗ヘルペス薬による適切な治療が行われなかったならば虹彩萎縮が出現していた可能性があると思われた。

以前よりPSSにはヘルペス感染の関与が示されているが、Yamamotoら<sup>8)</sup>は片眼性に軽度の虹彩毛様体炎を伴う高眼圧発作をくり返しPSSと診断された症例の前房水を採取し、HSV、VZV、CMVに対するPCRを施行し、HSV DNAが陽性であったと報告している。最近のいくつかの報告のように<sup>4-6)</sup>、PSS類似の片眼性の虹彩毛様体炎からCMV DNAやCMV特異抗体が検出されることがある。これらは免疫不全のない健康人にみられ、発作性の高眼圧を伴う片眼性の虹彩毛様体炎を診た場合、HSV、VZV、CMVなどのヘルペス感染を念頭において診察する必要があると思われる。

杉田ら<sup>9)</sup>は、1999年から2007年の間に当科を受診したぶどう膜炎患者100例から眼内液を採取し、ヒトヘルペスウイルス1型から8型のDNAをPCRで検討した結果を報告しており、角膜病変を伴いHSV虹彩毛様体炎と考えられた7症例中2例でHSV DNAが陽性であり、VZV虹彩毛様体炎と考えられた16例中10例でVZV DNAが陽性であった。

角膜病変を伴う症例では角膜内でのウイルス増殖が中心となり、前房水中にウイルスが検出されにくく、角膜病変を伴わない虹彩毛様体炎では虹彩内でのウイルス増殖が中心となり、前房水中にウイルスが検出されやすいのではないかと思われた。

HSV 虹彩毛様体炎の治療は、アシクロビルやバラシクロビルといった抗ウイルス薬の局所、全身投与が基本となる。症例1と症例3ではステロイド治療のみでは改善せず、ステロイド治療抵抗性や再発性の場合には、ヘルペス性虹彩毛様体炎を考える必要があると思われた。また、抗ウイルス薬の治療は、症例3では当初抗ウイルス薬の局所投与だけでは改善が乏しく、内服を開始したところ改善がみられた。ヘルペス性虹彩毛様体炎では、症例によっては抗ウイルス薬は局所投与だけでなく内服を併用する必要があると考えられた。

以上より片眼性の高眼圧を伴う虹彩毛様体炎の鑑別疾患として、角膜病変や虹彩萎縮などのヘルペスウイルスに特徴的な所見がなくてもHSV 虹彩毛様体炎を考える必要があると思われた。

#### 文 献

1) Cunningham ET Jr : Diagnosing and treating herpetic anterior uveitis. *Ophthalmology* **107** : 2129-2130, 2000

2) Van der Lelij A, Ooijman FM, Kijlstra A et al : Anterior uveitis with sectoral iris atrophy in the absence of keratitis. *Ophthalmology* **107** : 1164-1170, 2000

3) Markomichelakis NN, Canakis C, Zafirakis P et al : Cytomegalovirus as a cause of anterior uveitis with sectoral iris atrophy. *Ophthalmology* **109** : 879-882, 2002

4) Chee SP, Bacsal K, Jap A et al : Clinical features of cytomegalovirus anterior uveitis in immunocompetent patients. *Am J Ophthalmol* **145** : 834-840, 2008

5) Van Boxtel LA, Van der Lelij A, Van der Meer J et al : Cytomegalovirus as a cause of anterior uveitis in immunocompetent patients. *Ophthalmology* **114** : 1358-1362, 2007

6) 下村嘉一 : ウイルス性状, 潜伏感染と再活性化, 伝播と播種. 月刊眼科診療プラクティス **92** : 98-102, 2003

7) Van der Lelij A, Ooijman FM, Kijlstra A et al : Anterior uveitis with sectoral iris atrophy in the absence of keratitis : a distinct clinical entity among herpetic eye diseases. *Ophthalmology* **107** : 1164-1170, 2000

8) Yamamoto S, Pavan-Langston D, Tada R et al : Possible role of herpes simplex virus in the origin of Posner-Schlossman syndrome. *Am J Ophthalmol* **119** : 796-798, 1995

9) Sugita S, Shimizu N, Watanabe K et al : Use of multiplex PCR and real-time PCR to detect human herpes virus genome in ocular fluids of patients with uveitis. *Br J Ophthalmol* **92** : 928-932, 2008

\* \* \*