

Omori Y, Katoh K, Kajimura N, Sato S, Chaya T, Muraoka K, Ueno S, Koyasu T, Kondo M,	Negative regulation of ciliary length by ciliary kinase Mak is required for retinal photoreceptor survival.	Proc Natl Acad Sci U S A	107	22671-22676	2010
Ishikawa K, Nishihara H, Ozawa S, Piao CH, Ito Y, Kondo M, Terasaki H	Focal macular electroretinograms after photodynamic therapy combined with intravitreal bevacizumab	Graefes Arch Clin Exp Ophthalmol	108	in press	2011
Kondo H, Saito K, Urano M, Sagara Y, Uchio E, Kondo M	A case of Fukuyama congenital muscular dystrophy associated with negative electroretinograms	Jpn J Ophthalmol	55	in press	2011
Yasuda S, Kondo M, Kachi S, Ito Y, Terui T, Ueno S, Terasaki H	Focal macular electroretinograms after photodynamic therapy combined with intravitreal bevacizumab	Retina	31	in press	2011
Terui T, Kondo M, Sugita T, Ito Y, Kondo N, Ota I, Miyake K, Terasaki H	Changes in the area of capillary nonperfusion before and after intravitreal injection of bevacizumab in eyes with branch retinal vein occlusion	Retina	31	243-245	2011
EXTEND-I Study Group	EXTEND-I: safety and efficacy of ranibizumab in Japanese patients with subfoveal choroidal neovascularisation secondary to age-related macular degeneration.	Acta Ophthalmologica	88	309-16	2010
Masanori Mizote, Tetsuya Baba, Kazuyuki Hirooka, Hidetaka Yamaji, Fumio Shiraga.	Vascular endothelial growth factor concentrations in aqueous humor before and after subconjunctival injection of bevacizumab for neovascular glaucoma.	Jpn J Ophthalmol	54	242-4	2010
Mitsuyo Kageyama, Kazuyuki Hirooka, Tetsuya Baba, and Fumio Shiraga.	Comparison of ICare Rebound Tonometer with Noncontact Tonometer in Healthy Children.	J Glaucoma	20	63-6	2011

Kouki Fukuda, Kazuyuki Hirooka, Masanori Mizote, Takehiro Nakamura, Toshifumi Itano, Fumio Shiraga.	Neuroprotection Against Retinal Ischemia-Reperfusion Injury by Blocking the Angiotensin II Type 1 Receptor.	Invest Ophthalmol Vis Sci	51	3629-38	2010
Hidetaka Yamaji, Fumio Shiraga, Chieko Shiragami, Hiroyuki Nomoto, Tomonori Fujita, and Kouki Fukuda	Reduction in dosage of intravitreal bevacizumab before vitrectomy for proliferative diabetic retinopathy.	Arch Ophthalmol	129	106-107	2011
Oshima Y, Kadonosono K, Yamaji H, Inoue M, Yoshida M, Kimura H, Ohji M, Shiraga F, Hamasaki T.	Multicenter Survey with a Systematic Overview of Acute-Onset Endophthalmitis after Transconjunctival Microincision Vitrectomy Surgery.	Am J Ophthalmol	150	716-725.	2010
Takehiro Nakamura, Shinji Tanaka, Kazuyuki Hirooka, Tetsuhiko Toyoshima, Ph.D.; Nobuyuki Kawai, Takashi Tamiya, Fumio Shiraga	Anti-oxidative effects of D-allose, a rare sugar, on ischemia-reperfusion damage following focal cerebral ischemia in rat.	Neuroscience Letters	487	103-6	2011
Kitaguchi Y, Kusaka S, Yamaguchi T, Mihashi T, Fujikado T.	Detection of photoreceptor disruption by adaptive optics imaging and Fourier-domain optical coherence tomography in eyes with occult macular dystrophy.	Clin Ophthalmol.			in press
Tokuda T, Takeuchi Y, Sagawa Y, Noda T, Sasagawa K, Nishida K, Fujikado T, Ohta J.	Development and in vivo Demonstration of CMOS-Based Multichip Retinal Stimulator With Simultaneous Multisite Stimulation Capability.	IEEE Transactions on Biomedical Circuits and Systems.	4(6)	445-453	2010
Tokuda T, Sagawa Y, Noda T, Sasagawa K, Nishida K, Fujikado T, Ohta.	J.A CMOS-based multichip flexible retinal stimulator for simultaneous multi-site stimulation.	Conf Proc IEEE Eng Med Biol Soc.	1	5883-6	2010

Fujikado T, Morimoto T, Shimojyo H.	Development of anisometropia in patients after surgery for esotropia.	Jpn J Ophthalmol .	54	589-93.	2010
Mihashi T, Okawa Y, Miyoshi T, Kitaguchi Y, Hirohara Y, Fujikado T.	Comparison of retinal reflectance changes elicited by transcorneal electrical retinal stimulation to that by optic chiasma stimulation in cats.	Jpn J Ophthalmol.			in press
Murakami Y, Kusaka S, Hayashi N, Soga K, Fujikado T.	Wavefront analysis and ultrastructural findings in an eye with posterior lentiglobus.	JAAPOS.	14	530-1	2010
Nishida K, Kamei M, Kondo M, Sakaguchi H, Suzuki M, Fujikado T, Tano Y.	Efficacy of suprachoroidal-transretinal stimulation in a rabbit model of retinal degeneration.	Invest Ophthalmol Vis Sci.	51(4)	2263-8	2010
Morimoto T, Miyoshi T, Sawai H, Fujikado T.	Optimal parameters of transcorneal electrical stimulation (TES) to be neuroprotective of axotomized RGCs in adult rats.	Exp Eye Res.	90(2)	285-91	2010
Sakamoto T et al.	Vitrectomy for exudative age-related macular degeneration with vitreous hemorrhage.	Retina	30(6)	856-864	2010
Okubo A, Arimura N, Abematsu N, Sakamoto T	Predictable signs of benign course of polypoidal choroidal vasculopathy: based upon the long-term observation of non-treated eyes	Acta Ophthalmol.	88(4)	107-14.	2010
Shimura M, Nakazawa T, Nishida K, Sakamoto T.	Combination therapy for retinal vein occlusion.	Ophthalmology	117(9)	1858.1-3.	2010
大路正人, 小椋祐一郎, 坂本泰二, 他	眼内長期滞留ガス(SF6, C3F8)ガイドライン	日眼会誌 114	114(2)	110-115	2010
Sonoda Y, Arimura N, Shimura M, Sakamoto T.	Early change of central macular thickness after intravitreous triamcinolone or bevacizumab.	Retina	in press		2011

Shrestha B, Shrestha C, Nitanda T, Kitajima S, Arimura K, Sato M, Sakamoto T, et al	B Cell-Derived Vascular Endothelial Growth Factor A Promotes Lymphangiogenesis and High Endothelial Venule Expansion in Lymph Nodes.	J Immunol.	184(9)	4819-4826	2010
Otsuka H, Arimura N, Sonoda S, Nakamura M, Hashiguchi T, Maruyama I, Nakao S, Hafezi-Moghada m A, Sakamoto T.	Stromal cell derived factor-1 is essential for photoreceptor cell protection in retinal detachment.	Am J Pathol.	177(5)	2268-2277	2010
Kawano H, Uemura A, Sakamoto T.	Incidence of outer foveal defect after macular hole surgery. Am J Ophthalmol.	Am J Ophthalmol.	pub Dec 17	in press	2010
Kadonosono K	Achieving a Wide-angle View During Vitreous Surgery; High-resolution images and wide-angle views of the fundus can contribute to a successful vitrectomy.	Retina Today	Jan/Feb	43-45	2011
門之園一明	糖尿病黄斑浮腫の外科 的治療	日本臨牀	68(増刊 号9)	339-344	2010
Inoue M, Kadonosono K 他	Results of One-Year Follow -Up Examinations for Chronic Central Serous Chorioretinopathy.	Ophthalmological	225(1)	37-40	2011
Inoue M, Kadonosono K 他	Results of 1-Year Follow-Up Examinations After Intravitreal Bevacizumab Administration for Idiopathic Choroidal Neovascularization.	Retina	30(5)	733-738	2010
Yokoi T, Yokoi T, Kobayashi Y, Nishina S, Azuma N..	Risk factors for recurrent fibrovascular proliferation in aggressive posterior retinopathy of prematurity after early vitreous surgery.	Am J. Ophthalmol	150	10-15	2010

Dateki S, Kosaka K, Hasegawa K, Tanaka H, Azuma N, Yokoya S, Muroya K, Adachi M, Tajima T, Motomura K, Kinoshita E, Moriuchi H, Fukami M, Ogata T.	Heterozygous OTX2 mutations are associated with variable pituitary phenotype.	J Clin Endocrinol Metab	95	756-764	2010
Wu J, Kubota J, Hirayama J, Nagai Y, Nishina S, Yokoi T, Asaoka Y, Seo J, Shimizu N, Kajiho H, Watanabe T, Azuma N, Katada T, Nishina H.	p38 mitogen-activated protein kinase controls a switch between cardiomyocyte and neuronal commitment of murine embryonic stem cells by activating MEF2C-dependent BMP2 transcription.	Stem Cells Dev		In press	2010
Ito M, Yokoi T, Sugita S, Shinohara N, Nishina S, Azuma N.	Endogenous Candida chorioretinitis in a healthy infant.	Jpn J Ophthalmol		In press	2010
Fujinami K, Yokoi T, Hiraoka M, Nishina S, Azuma N.	Neovascularization in child following laser pinter-induced macular injury.	Jpn J Ophthalmol		In press	2010
Shoji K, Ito N, Ito Y, Inoue N, Adachi S, Fujimaru T, Nakamura T, Nishina S, Azuma N, Saitoh A.	Is a 6-week course of ganciclovir therapy effective for chorioretinitis in infants with congenital cytomegalovirus infection?	J Pediatr		In press	2010
Kobayashi Y, Yokoi T, Yokoi T, Hiraoka H, Nishina S, Azuma N.	Fluorescein staining of the vitreous during vitrectomy for retinopathy of prematurity.	Retina		In press	2010

総説

発表者氏名	論文タイトル名	発表誌名	巻号	ページ	出版年
齋藤昌晃	糖尿病黄斑症の疾患概念.	糖尿病医療スタッフのプラクティス	27	14-16	2010
森 隆史	眼前眼部の異常、緑内障 -小児科医が外見からみてわかる症状-	小児科臨床	63	935 -941	2010
齋藤昌晃	糖尿病黄斑症の治療-網膜光凝固術、硝子体手術-	糖尿病医療スタッフのプラクティス	27	124-125	2010
齋藤昌晃	糖尿病黄斑症の治療-抗VEGF療法-	糖尿病医療スタッフのプラクティス	27	240-242	2010
齋藤昌晃,飯田知弘	糖尿病網膜症の診断	月刊 糖尿病	2	43 -48	2010
竹田宗泰,飯田知弘,湯沢美都子	眼底病変に対するレーザー光凝固:光凝固がどうしても必要な症例.	眼科手術	23	553-571	2010
齋藤昌晃,飯田知弘	AMDの早期診断.	Pharma Medica	28	37-44	2010
石龍鉄樹	[FAF]眼底自発蛍光 (FAF) の定量的評価法について教えてください.	あたらしい眼科	27	92 -95	2010

Subfoveal Choroidal Thickness after Treatment of Central Serous Chorioretinopathy

Ichiro Maruko, MD,¹ Tomohiro Iida, MD,¹ Yukinori Sugano, MD,¹ Akira Ojima, MD,¹ Masashi Ogasawara, MD,¹ Richard F. Spaide, MD²

Purpose: To evaluate the subfoveal choroidal thickness after treatment of central serous chorioretinopathy (CSC) visualized by enhanced depth imaging spectral-domain optical coherence tomography (EDI OCT) and indocyanine green angiography (ICGA).

Design: Retrospective, comparative series.

Participants: Twenty patients (20 eyes).

Methods: The subfoveal choroidal thickness and height of the serous retinal detachment before and after treatment was measured using EDI OCT. Areas of choroidal vascular hyperpermeability were visualized with ICGA. Eyes with classic CSC were treated with laser photocoagulation (LP), whereas eyes with chronic CSC, which are not amenable to LP, were treated with half-dose verteporfin photodynamic therapy (PDT).

Main Outcome Measures: Change in choroidal thickness and height of the serous retinal detachment after treatment.

Results: There were 12 eyes in the LP group and 8 eyes in the PDT group. The serous subretinal fluid resolved in both groups after treatment. In the LP group, the mean choroidal thickness was $345 \pm 127 \mu\text{m}$ at baseline and $340 \pm 124 \mu\text{m}$ at 4 weeks, a difference that was not significant ($P = 0.2$). The mean choroidal thickness in the PDT group increased significantly from $389 \pm 106 \mu\text{m}$ at baseline to $462 \pm 124 \mu\text{m}$ ($P = 0.008$) by 2 days after treatment, and then reduced rapidly to $360 \pm 100 \mu\text{m}$ ($P = 0.001$) at 1 week and $330 \pm 103 \mu\text{m}$ ($P < 0.001$) after 4 weeks as compared with baseline. Indocyanine green angiography showed decreased hyperpermeability in the PDT group after treatment.

Conclusions: The subretinal fluid resolved in both disease groups; however, the choroidal thickness and hyperpermeability seen during ICGA was reduced after PDT. These findings suggest that PDT reduces the choroidal vascular hyperpermeability seen in CSC and may work by a different mechanism than LP.

Financial Disclosure(s): The author(s) have no proprietary or commercial interest in any materials discussed in this article. *Ophthalmology* 2010;117:1792–1799 © 2010 by the American Academy of Ophthalmology.

Central serous chorioretinopathy (CSC) is characterized by an idiopathic serous retinal detachment in the posterior pole associated with 1 or more leaks from the level of the retinal pigment epithelium (RPE).¹ Gass² proposed that choriocapillary hyperpermeability was the cause of CSC, and later studies found multifocal areas of choroidal vascular hyperpermeability in CSC patients during indocyanine green angiography (ICGA).^{1,3–7} Some patients with CSC have a recent onset of disease with 1 or only a few specific points of leakage from the RPE; these cases are commonly termed *classic CSC*. Other patients with chronic disease have broad areas of granular hyperfluorescence during fluorescein angiography associated with many indistinct areas of leakage. These patients have chronic CSC, which also has been called *diffuse retinal pigment epitheliopathy*.^{1,8}

Although some cases of CSC may resolve spontaneously, treatment may be required in eyes with persistent leakage. Laser photocoagulation (LP) typically is used in classic CSC, but is ineffective in chronic CSC.^{1,9,10} Photodynamic therapy (PDT) with verteporfin causes resolution of leakage and consequently of the subretinal fluid in both

classic and chronic forms of CSC.^{11–14} A possible mechanism of action of PDT in CSC involves damage to the choriocapillaris leading to decreased choroidal vascular hyperpermeability and consequently a reduction in leakage from the level of the RPE.

Optical coherence tomography (OCT) uses short coherence length interferometry to image tissue *in vivo*, particularly the posterior pole of the eye. Conventional OCT has a limited ability to image the choroid because of scattering by pigment within the RPE and by pigment and blood in the choroid and because of a depth-dependent roll-off in sensitivity of spectral-domain OCT instruments in general.¹⁵ A method to improve imaging of the choroid was developed, enhanced depth imaging (EDI) OCT,¹⁵ and by using this technique, the choroid in eyes with CSC was found to be much thicker than normal.¹⁶ The current study evaluated the potential changes in choroidal thickness after treatment of both classic CSC using LP and chronic CSC using half-dose verteporfin PDT. These findings may help to elucidate the pathophysiologic features of CSC as well as its response to treatment.

Table 1. The Clinical Changes of the Mean Choroidal Thickness and the Mean Height of Serous Retinal Detachment during the Follow-up Periods in the Laser Photocoagulation and the Photodynamic Therapy Groups

Case No.	Age (yrs)	Gender	Best-Corrected Visual Acuity (Logarithm of the Minimum Angle of Resolution)		Choroidal Thickness (μm)				Height of Serous Retinal Detachment (μm)			
			Baseline	Final	Baseline	Day 2	Week 1	Week 4	Baseline	Day 2	Week 1	Week 4
Laser photocoagulation												
1	46	F	0.9 (0.05)	1.0 (0.0)	213		205	210	313		221	41
2	51	M	1.2 (-0.08)	1.2 (-0.08)	605		614	585	229		345	124
3	38	M	0.9 (0.05)	0.9 (0.05)	423		436	396	134		103	26
4	65	M	1.2 (-0.08)	1.2 (-0.08)	154		153	149	185		139	45
5	56	M	0.8 (0.10)	0.9 (0.05)	398		414	417	103		118	0
6	56	F	0.15 (0.82)	0.2 (0.70)	200		228	201	72		0	0
7	65	M	0.6 (0.22)	0.9 (0.05)	278		289	278	194		122	22
8	59	M	0.8 (0.10)	0.9 (0.05)	383		389	395	106		111	67
9	59	F	1.2 (-0.08)	1.0 (0.0)	306		306	300	228		228	139
10	54	M	0.9 (0.05)	1.2 (-0.08)	490		495	483	111		51	40
11	48	M	1.2 (-0.08)	1.0 (0.0)	295		289	289	117		128	0
12	64	M	0.7 (0.15)	0.8 (0.10)	396		373	378	306		278	61
Mean	55		0.79 (0.10)	0.87 (0.06)	345		349	340	175		153	47
\pm SD					127		128	124	79		95	45
Photodynamic therapy												
13	58	M	0.8 (0.10)	0.7 (0.15)	390	413	385	366	368	500	369	0
14	59	M	0.15 (0.82)	0.2 (0.70)	378	451	331	289	160	345	101	0
15	56	M	0.4 (0.40)	0.5 (0.30)	641	653	592	550	91	119	94	0
16	57	M	0.3 (0.52)	0.4 (0.40)	386	487	362	375	165	387	209	0
17	70	M	0.9 (0.05)	1.2 (-0.08)	326	—	312	312	245	—	323	104
18	46	M	0.1 (1.00)	0.15 (0.82)	356	395	356	306	85	70	0	0
19	68	M	1.5 (-0.18)	1.5 (-0.18)	356	578	294	211	205	428	208	70
20	65	F	0.6 (0.22)	0.7 (0.15)	278	261	250	233	272	211	161	0
Mean	60		0.43 (0.37)	0.52 (0.27)	389	462	360	330	199	294	183	22
\pm SD					106	124	100	103	92	157	118	40

F = female; M = male; SD = standard deviation.

In the laser photocoagulation group, the choroidal thickness at the fovea before, 1 week after laser photocoagulation (week 1), and 4 weeks after laser photocoagulation (week 4). In the photodynamic therapy group, the choroidal thickness at the fovea before and 2 days after photodynamic therapy (day 2), 1 week after photodynamic therapy (week 1), and 4 weeks after photodynamic therapy (week 4). Choroidal thickness measured using the enhanced depth imaging spectral-domain optical coherence tomography technique. Mean best-corrected visual acuity calculated by logarithm of the minimum angle of resolution scale.

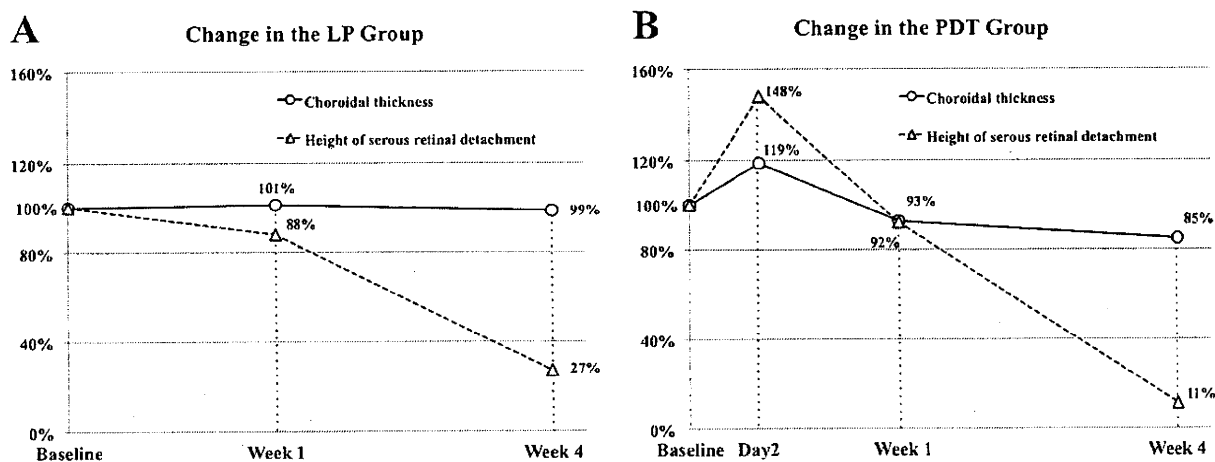


Figure 1. A, Graph showing the percentage change of the choroidal thickness and the height of serous retinal detachment after laser photocoagulation (LP) compared with baseline. Open circles with the connecting solid line indicate the change of the choroidal thickness, and open triangles with the connecting dashed line indicate the height of serous retinal detachment. The height of serous retinal detachment decreased at weeks 1 and 4, whereas the choroidal thickness remained the same. B, Graph showing the percentage change of the choroidal thickness and the height of serous retinal detachment after photodynamic therapy (PDT) compared with baseline. The patients in the PDT group were treated by half-dose verteporfin PDT. Open circles with the connecting solid line indicate the change of the choroidal thickness, and open triangles with the connecting dashed line indicate the height of serous retinal detachment. Both of them increased at day 2 and decreased at weeks 1 and 4. Baseline; before photodynamic therapy, day 2; 2 days after photodynamic therapy, week 1; 1 week after photodynamic therapy, week 4; 4 weeks after photodynamic therapy.

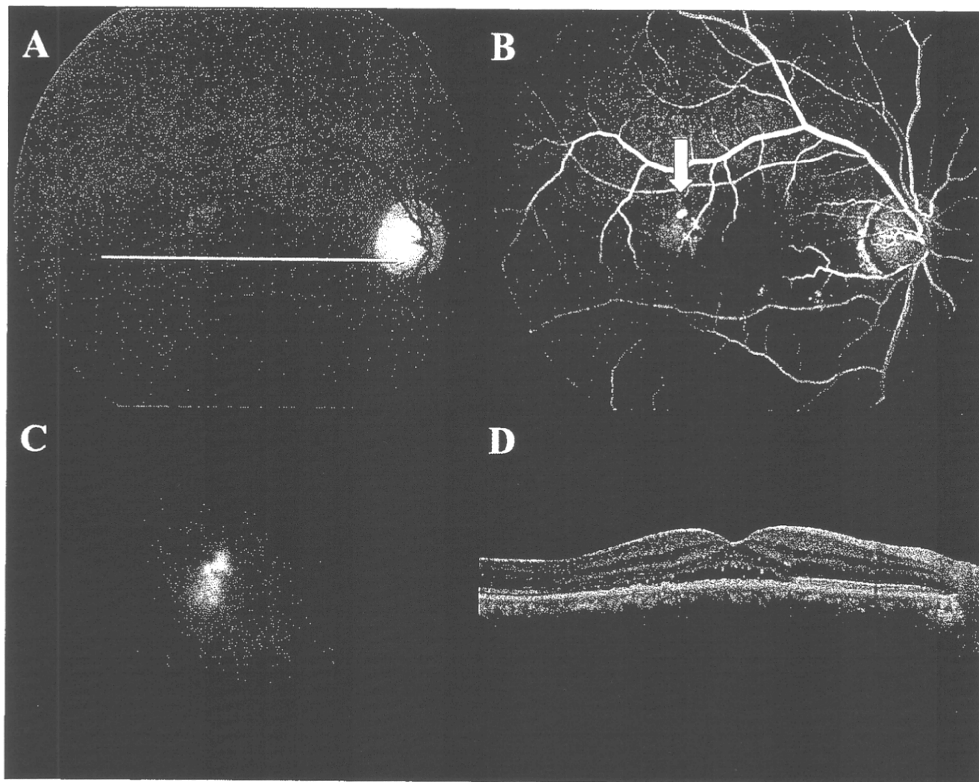


Figure 2. Case 5: a 56-year-old man noted blurred vision in the right eye. The best-corrected visual acuity at baseline was 0.80 (0.10 logarithm of the minimum angle of resolution) in the right eye. There was no history of corticosteroid treatment. **A**, Fundus photograph of the right eye showing a serous retinal detachment at the fovea. **B**, Fluorescein angiogram of the right eye showing a focal leak in the temporal macula (arrow). **C**, Indocyanine green angiogram from the mid phase showing a hyperfluorescent area temporally from the macula that subtended the site of focal leakage seen during fluorescein angiography. **D**, Optical coherence tomography image showing the serous retinal detachment at the macular area.

Patients and Methods

This study followed the tenets of the Declaration of Helsinki. The Institutional Review Board at Fukushima Medical University School of Medicine approved (1) observation using OCT for eyes

with macular and retinal disorder, (2) PDT for the CSC, (3) the observational study for age-related macular degeneration and its similar disorders (including CSC) at the treatment and follow-up, and (4) the retrospective comparative analysis performed in this study.

The clinical examination for diagnosis of CSC included measurement of best-corrected visual acuity (BCVA), slit-lamp biomicroscopy with a contact lens or noncontact lens, indirect ophthalmoscopy, digital fluorescein angiography, and ICGA (TRC-50IX/IMAGENet H1024 system; Topcon, Tokyo, Japan). The BCVA measurement with a Japanese standard decimal visual chart and the logarithm of the minimum angle of resolution (logMAR) scale were used for analysis. All eyes were examined with the Heidelberg Spectralis OCT (Heidelberg Engineering, Heidelberg, Germany). The following were inclusion criteria: (1) patients with BCVA of 0.10 (1.00 logMAR) or better, (2) patients with a serous retinal detachment involving the fovea on OCT; (3) patients with

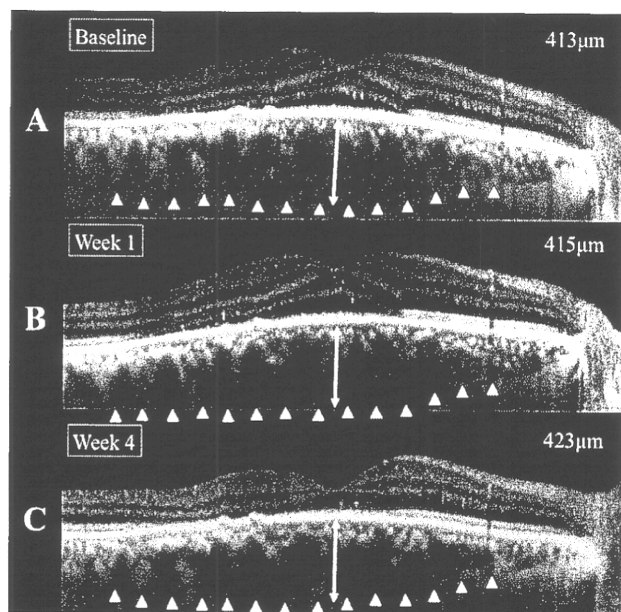


Figure 3. Enhanced depth imaging spectral-domain optical coherence tomography images from the same case as Figure 2. Laser photocoagulation was performed successfully by the following: the set for a spot size of 200 μm , power of 100 mW, and application time of 0.20 seconds. The choroidal thickness of the horizontal images at baseline was (A) 413 μm , (B) 415 μm at week 1, and (C) 423 μm at week 4. The serous retinal detachment resolved by week 4. The best-corrected visual acuity at week 4 was 0.9 (0.05 logarithm of the minimum angle of resolution). Baseline; before laser photocoagulation, week 1; 1 week after laser photocoagulation, week 4; 4 weeks after laser photocoagulation.

CSC according to the diagnostic criteria: CSC was diagnosed if patients had subretinal fluid involving the macula associated with the idiopathic leaks from the RPE during fluorescein angiography. Indocyanine green angiography was used to confirm the presence of choroidal vascular hyperpermeability, to determine the size of the hyperpermeability to guide the PDT if indicated, and to rule out the presence of polypoidal choroidal vasculopathy. Classic CSC was diagnosed if the patients had isolated points of leakage. Chronic CSC was diagnosed if the patients had widespread areas of leakage visualized as diffuse or poorly defined regions of leakage originating from broad areas of RPE damage.

Patients with classic CSC with the apparent focal leakage were treated with LP (LP group). Patients with chronic CSC without the apparent focal fluorescein leakage and with the persistent serous retinal detachment of more than 6 months' duration were treated with half-dose verteporfin PDT (PDT group). All patients had subjective visual loss, and they had the occupational needs or desired treatment after being informed of the risks and benefits. The duration of the serous retinal detachment was inferred from the patient's recall of the onset of visual symptoms.

Laser photocoagulation in the LP group was performed using a DPSS yellow laser (561 nm; Nidek, Gamagori, Japan) with a spot size of 200 μm , at a power of 70 to 100 mW, with an application time of 0.20 seconds. The end point of the LP was the production of a slight graying of the RPE. The PDT protocol for chronic CSC

was performed by using the half-dose (3 mg/m^2) as compared with the normal dose (6 mg/m^2) of verteporfin (Visudine; Novartis, Switzerland) for treating CSC.¹³ The verteporfin was infused over 10 minutes followed by delivery of an activating light dose of 50 J/cm^2 from a 689-nm laser system (Carl Zeiss, Dublin, CA) over an 83-second exposure time. The laser spot size for the PDT was the diameter of the region of indocyanine green hyperpermeability plus 1 mm.

The change in subfoveal choroidal thickness was observed by the EDI OCT technique,¹⁵ in which the Heidelberg Spectralis OCT instrument is pushed in close enough to the eye to obtain an inverted image. Each section was obtained using eye tracking, and 100 scans were averaged to improve the signal-to-noise ratio. The images were reinverted for display purposes. Additional hardware or software is not necessary with the Heidelberg Spectralis OCT for the EDI OCT technique. Other devices of OCT (e.g., the 3D-OCT (Topcon Inc, Tokyo, Japan) and RTVue (Optovue Inc, Fremont, CA) have a software setting that enables the instruments to perform the equivalent of EDI OCT without having to invert the image. The choroidal thickness and the height of the retinal detachment were measured using the attached measuring software in the Heidelberg Spectralis OCT. The subfoveal choroidal thickness was measured from the outer surface of the line formed by the RPE to the inner surface of the observed sclera. The choroidal thickness was measured from a vertical and a horizontal section under the

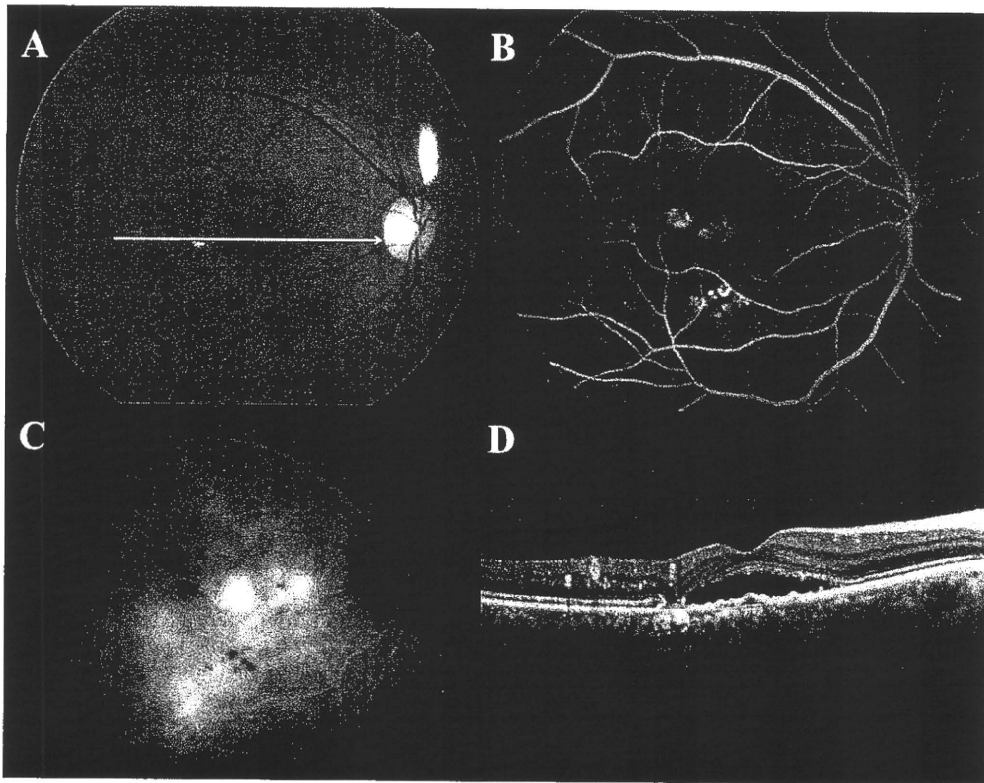


Figure 4. Case 14: a 59-year-old man reported decreased vision in his right eye resulting from the persistent subretinal fluid. He reported an episode of decreased visual acuity in the right eye 5 years previously, and he had a history of laser photocoagulation for the persistent central serous chorioretinopathy in that eye. The best-corrected visual acuity at baseline was 0.15 (0.82 logarithm of the minimum angle of resolution) in the right eye. There was no history of corticosteroid treatment. **A**, Fundus photograph of the right eye showing a serous retinal detachment at the center of the macular area and retinal pigment epithelial scar resulting from laser photocoagulation at the temporal area to the fovea. **B**, Fluorescein angiogram of the right eye showing the diffuse leakage in the central and inferior macular area. **C**, Indocyanine green angiogram in the mid phase showing hyperfluorescence secondary to choroidal vascular hyperpermeability in the posterior pole, including the macular area. **D**, Spectral-domain optical coherence tomography image showing the serous retinal detachment at the macular area, subretinal deposits at the posterior surface of the neurosensory retina, and retinal pigment epithelium irregularity.

center of the fovea from OCT data, and these were averaged. For the LP group, the subfoveal choroidal thickness was measured before LP (baseline), 1 week after LP (week 1), and 4 weeks after LP (week 4). For the PDT group, the subfoveal choroidal thickness was measured before PDT (baseline), 2 days after PDT (day 2), at week 1, and at week 4. The OCT examination was performed at all visits. In Japan, the patients who have undergone a first PDT treatment should stay in the hospital for 2 nights to avoid sun exposure. The height of retinal detachment at the fovea, measured concurrently, was defined as the distance between the outer surface of the neurosensory retina and the inner surface of the RPE. The reported measurements from OCT images represented the average of measurements made by the coauthors (IM, YS, AO), who were masked to treatment status. The visual acuities are stated as decimal equivalents and also as the logMAR equivalents. The results of the measurement of the choroidal thickness and the height of retinal detachment were analyzed using the Student *t* test.

Results

The study included 20 eyes of 20 patients. The mean age of the patients was 57.0 ± 8.2 years, and 16 patients were male. There were 12 eyes of 12 patients with classic CSC and 8 eyes of 8 patients with chronic CSC. The mean baseline decimal visual acuity was 0.79 (0.10 logMAR) for eyes with classic CSC and 0.43 (0.37 logMAR) for those with chronic CSC. The mean number of LP spots was 5.6 ± 2.3 and the mean treatment spot size for the PDT group was $6288 \pm 872 \mu\text{m}$. The patients treated with both LP and PDT required only 1 treatment session, and no treatment complications were observed.

The mean subfoveal choroidal thickness and the mean height of serous retinal detachment at baseline and changes with follow-up for both groups are summarized in Table 1 and Figure 1. Figures 2 and 3 are shown as the representative case in the LP group, and Figures 4, 5, and 6 are shown as the representative case in the PDT group. All data was collected except for day 2 of case 17 in the PDT group. In the LP group, the mean choroidal thickness was $345 \pm 127 \mu\text{m}$ at baseline, $349 \pm 124 \mu\text{m}$ at week 1 ($P = 0.3$, as compared with baseline), and $340 \pm 124 \mu\text{m}$ at week 4 ($P = 0.2$, as compared with baseline). The mean choroidal thickness in the PDT group increased significantly from $389 \pm 106 \mu\text{m}$ at baseline to $462 \pm 124 \mu\text{m}$ at day 2 ($P = 0.008$) and then decreased to $360 \pm 100 \mu\text{m}$ at week 1 ($P = 0.001$, as compared with baseline) and $330 \pm 103 \mu\text{m}$ at week 4 ($P < 0.001$, as compared with baseline). Nine cases in the LP group and 2 cases in the PDT group still had serous retinal detachment at week 4; however, the subretinal fluid disappeared in all cases within 2 months after treatment. The EDI OCT images at day 2 showed the hyperreflective material in the subretinal space possibly because of PDT-induced exudation from the choroid (Fig 5B). There was no similar exudation at week 1 and week 4 in EDI OCT images (Fig 5C, D). The morphologic resolution of retinal detachment tended to occur subsequent to the decrement of choroidal thickness in the PDT group. All cases of the PDT group had decreased choroidal vascular hyperpermeability during ICGA after treatment, which were confirmed by masked evaluation (Fig 6). Only one case (case 11) in the LP group underwent repeat ICGA, which showed no change in choroidal vascular hyperpermeability after LP.

The mean BCVA levels in the LP group at baseline, week 1, and week 4 were 0.79 (0.10 logMAR), 0.82 (0.09 logMAR), and 0.87 (0.06 logMAR), respectively. The mean BCVA levels in the PDT group at baseline, week 1, and week 4 were 0.43 (0.37 logMAR), 0.45 (0.34 logMAR), and 0.52 (0.27 logMAR), respectively. The mean thickness ($80 \pm 28 \mu\text{m}$) of neurosensory retina in eyes with chronic CSC was significantly thinner ($112 \pm 18 \mu\text{m}$)

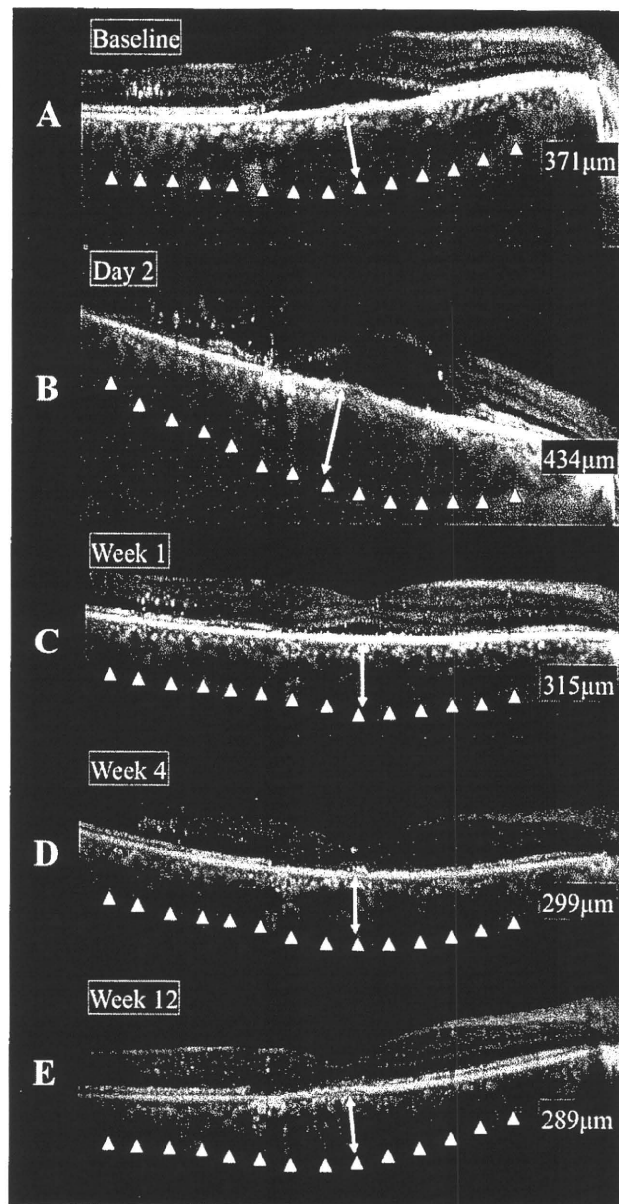


Figure 5. Enhanced depth imaging spectral-domain optical coherence tomography images from the same case as Figure 4. Half-dose verteporfin photodynamic therapy was performed successfully with the spot size of $6800 \mu\text{m}$ covering the greatest linear diameter of the hyperfluorescence in the indocyanine green angiogram with an added 1 mm. The choroidal thickness in the horizontal images at baseline was (A) $371 \mu\text{m}$, and (B) increased to $434 \mu\text{m}$ at day 2, (C) reduced to $315 \mu\text{m}$ at week 1, (D) $299 \mu\text{m}$ at week 4, and (E) $289 \mu\text{m}$ at week 12. Optical coherence tomography images obtained on day 2 (B) show the hyperreflective materials at the subretinal space. The serous retinal detachment disappeared at week 4. The best-corrected visual acuity was 0.2 (0.70 logarithm of the minimum angle of resolution) at week 4. Baseline; before photodynamic therapy, day 2; 2 days after photodynamic therapy, week 1; 1 week after photodynamic therapy, week 4; 4 weeks after photodynamic therapy; week 12; 12 weeks after photodynamic therapy.

than that of the classic CSC group at the baseline ($P < 0.001$). These differences remained during the follow-up periods ($116 \pm 25 \mu\text{m}$ in the LP group at week 4 and $84 \pm 27 \mu\text{m}$ in the PDT group; $P < 0.001$). There were no differences in the retinal thickness

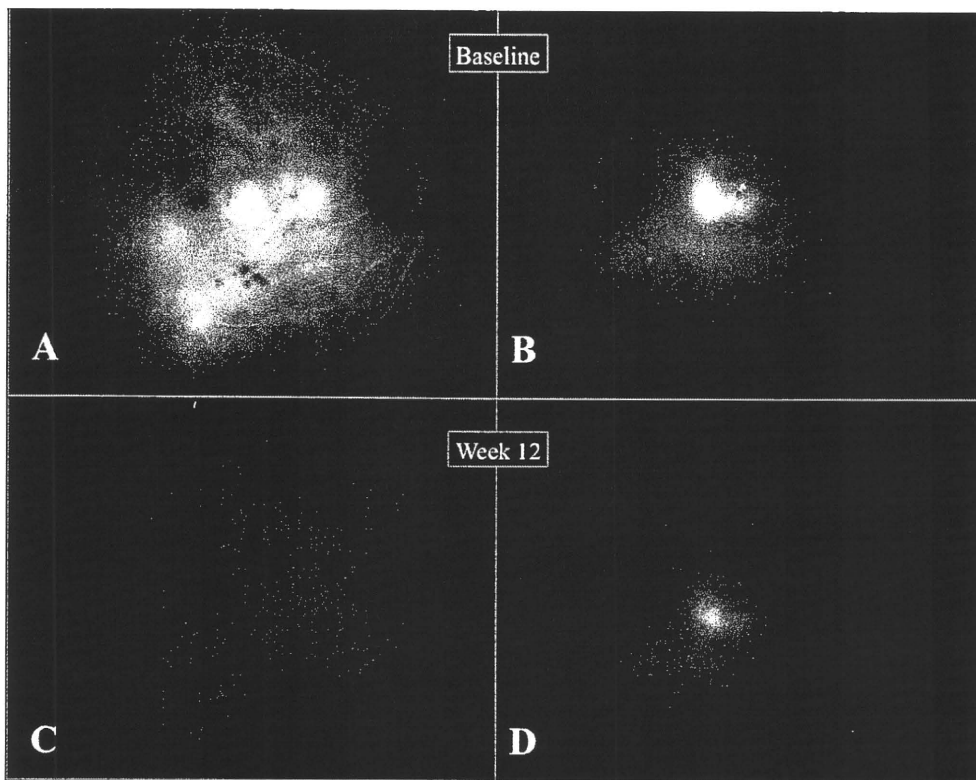


Figure 6. Indocyanine green angiograms obtained from both eyes at baseline and week 12 in the same case as Figure 4. A, B, Both eyes at baseline show the hyperfluorescence from choroidal vascular hyperpermeability at the macular area. C, D, Although the right eye at week 12 did not show hyperfluorescence, the left eye at week 12 showed the persistent hyperfluorescence at the macular area. Baseline; before photodynamic therapy; week 12; 12 weeks after photodynamic therapy.

measured at baseline as compared with week 4 ($P = 0.6$ in the LP group and $P = 0.7$ in the PDT group, respectively).

Discussion

Although there have been many theories concerning the pathogenesis of CSC, Gass² proposed that CSC was the result of choroidal vascular hyperpermeability. His hypothesis seemed to be confirmed by later studies that found evidence of hyperpermeability from the choriocapillaris during ICGA.^{1,3-7} If there is sufficient hydrostatic pressure from choroidal vascular hyperpermeability to cause leaks from the level of the RPE and serous retinal detachment, one would expect that the choroid would be thickened as well.¹⁶ In the present study, eyes with CSC were found to have thickened choroids. Focal LP of leaks did not result in any change in choroidal thickness, whereas PDT led to choroidal thinning and decreased hyperpermeability seen during ICGA, suggesting differing mechanisms of action for these 2 forms of treatment.

Indocyanine green angiography shows a variety of defects in CSC patients, including variable filling of regions within the choroid, choroidal venous dilation, and choroidal vascular hyperpermeability, principally arising from the choriocapillaris.^{1,3-7} Central serous chorioretinopathy commonly is split into classic and chronic cases, but the under-

lying ICGA abnormality unifying both is choroidal vascular hyperpermeability. Indocyanine green angiographic abnormalities were found to persist after resolution of active fluorescein leakage from the level of the RPE and to be bilateral in almost all patients, although there may be signs of CSC in only 1 eye. Similarly, the choroid was found to be thickened in CSC patients as compared with controls, even in fellow eyes without active disease or in affected eyes after cessation of visible leakage.¹⁶ Photodynamic therapy using verteporfin as a treatment for choroidal neovascularization was found to cause choriocapillaris damage and vascular remodeling in the underlying choroid.^{11-14,17-21} This PDT side effect was applied to CSC in the hopes that the damage to the choroid could be used to the benefit of the patient.¹¹⁻¹⁴ Decreasing choroidal vascular hyperpermeability may decrease the exudation related to CSC.

Eyes treated with LP in the present series had a cessation of leakage without a change in choroidal thickness. In 1 case, the ICGA results after LP showed that the hyperpermeability remained the same. Past studies found that the area of hyperpermeability was larger than any focal laser treatment spots and that the choroidal vascular hyperpermeability persisted even after successful LP.^{5,6} Because neither the hyperpermeability seen during ICGA nor the choroidal thickness changes, it is not likely that a widespread alteration in choroidal function was obtained by LP. As such, LP may affect the local environment around the leak.

Immediately after PDT, eyes with CSC showed signs of increased exudation. A transient increase in exudation has been seen in eyes with choroidal neovascularization treated with PDT.²¹⁻²⁶ Eventually, the eyes with CSC showed decreased hyperpermeability during ICGA and decreased choroidal thickness. This suggests that a more widespread alteration in choroidal function induced by PDT may explain, in part, the physiologic effects induced by PDT in CSC eyes. In addition, it also may explain the relatively low rates of recurrence of CSC after PDT¹¹⁻¹⁴: the induced changes within the choroid caused by PDT may normalize the choroidal permeability to the extent that abnormally increased hydrostatic pressure is less likely to occur.

Optical coherence tomography can visualize structures within the eye as dictated by the wavelength range of the light source and the imaging methods used. Although the deeper penetration OCT using a 1- μ m wavelength has been studied recently, OCT instruments are not commercially available.²⁷⁻³⁰ Some authors have reported the choroidal thickness of the various diseases using the EDI OCT technique, such as age-related macular degeneration with pigment epithelial detachment,³¹ CSC,¹⁶ age-related choroidal atrophy,³² normal eyes,³³ and highly myopic eyes.³⁴ This imaging technique can provide images with less apparent noise than published images using the 1- μ m light source.²⁷⁻³⁰

This retrospective study had several limitations, including a small sample size and short-term follow-up. Additional study is needed to investigate the relationship among the extent and severity of hyperpermeability seen during ICGA and the amount of choroidal thickening. Such a study would require a much larger number of patients than was examined in the present study because of known interactions between choroidal thickness and age and also refractive error. The patients in the present study were relatively old, and younger patients need to be evaluated. Because PDT with verteporfin potentially may cause choriocapillaris damage, choroidal ischemia,¹⁷⁻²¹ and retinal toxicity,³⁵ potential for visually significant side effects may be reduced by avoiding direct treatment of the fovea. Further investigations also could examine fovea-sparing PDT techniques to lessen risk of visually significant complications for patients who do not have subfoveal leaks. It may be possible to reduce choroidal vascular hyperpermeability enough to benefit the patient without having to treat the subfoveal choroid. In the present study, EDI OCT was helpful in monitoring the proposed site for the pathophysiologic changes in CSC and the choroid and provided information not available by other means.

References

1. Klais CM, Ober MD, Ciardella AP, Yannuzzi LA. Central serous chorioretinopathy. In Ryan SJ, ed-in-chief, Hinton DR, Schachat AP, Wilkinson CP, eds. *Retina*. 4th ed. vol. 2. Philadelphia: Elsevier Mosby; 2006;1135-61.
2. Gass JD. Pathogenesis of disciform detachment of the neuroepithelium. II. Idiopathic central serous choroidopathy. *Am J Ophthalmol* 1967;63:587-615.
3. Scheider A, Nasemann JE, Lund OE. Fluorescein and indocyanine green angiographies of central serous choroidopathy by scanning laser ophthalmoscopy. *Am J Ophthalmol* 1993;115:50-6.
4. Guyer DR, Yannuzzi LA, Slakter JS, et al. Digital indocyanine-green videoangiography of occult choroidal neovascularization. *Ophthalmology* 1994;101:1727-35.
5. Piccolino FC, Borgia L. Central serous chorioretinopathy and indocyanine green angiography. *Retina* 1994;14:231-42.
6. Iida T, Kishi S, Hagimura N, Shimizu K. Persistent and bilateral choroidal vascular abnormalities in central serous chorioretinopathy. *Retina* 1999;19:508-12.
7. Spaide RF, Goldbaum M, Wong DW, et al. Serous detachment of the retina. *Retina* 2003;23:820-46.
8. Spaide RF, Hall L, Haas A, et al. Indocyanine green videoangiography of older patients with central serous chorioretinopathy. *Retina* 1996;16:203-13.
9. Ficker L, Vafidis G, While A, Leaver P. Long-term follow-up of a prospective trial of argon laser photocoagulation in the treatment of central serous retinopathy. *Br J Ophthalmol* 1988;72:829-34.
10. Yap EY, Robertson DM. The long-term outcome of central serous chorioretinopathy. *Arch Ophthalmol* 1996;114:689-92.
11. Yannuzzi LA, Slakter JS, Gross NE, et al. Indocyanine green angiography-guided photodynamic therapy for treatment of chronic central serous chorioretinopathy: a pilot study. *Retina* 2003;23:288-98.
12. Cardillo Piccolino F, Eandi CM, Ventre L, et al. Photodynamic therapy for chronic central serous chorioretinopathy. *Retina* 2003;23:752-63.
13. Chan WM, Lai TY, Lai RY, et al. Safety enhanced photodynamic therapy for chronic central serous chorioretinopathy: one-year results of a prospective study. *Retina* 2008;28:85-93.
14. Chan WM, Lai TY, Lai RY, et al. Half-dose verteporfin photodynamic therapy for acute central serous chorioretinopathy: one-year results of a randomized controlled trial. *Ophthalmology* 2008;115:1756-65.
15. Spaide RF, Koizumi H, Pozzoni MC. Enhanced depth imaging spectral-domain optical coherence tomography. *Am J Ophthalmol* 2008;146:496-500.
16. Imamura Y, Fujiwara F, Margolis R, Spaide RF. Enhanced depth imaging optical coherence tomography of the choroid in central serous chorioretinopathy. *Retina* 2009;29:1469-73.
17. Schmidt-Erfurth U, Hasan T, Gragoudas E, et al. Vascular targeting in photodynamic occlusion of subretinal vessels. *Ophthalmology* 1994;101:1953-61.
18. Kramer M, Miller JW, Michaud N, et al. Liposomal benzoporphyrin derivative verteporfin photodynamic therapy: selective treatment of choroidal neovascularization in monkeys. *Ophthalmology* 1996;103:427-38.
19. Schmidt-Erfurth U, Laqua H, Schlötzer-Schrehard U, et al. Histopathological changes following photodynamic therapy in human eyes. *Arch Ophthalmol* 2002;120:835-44.
20. Schlötzer-Schrehardt U, Viestenz A, Naumann GO, et al. Dose-related structural effects of photodynamic therapy on choroidal and retinal structures of human eyes. *Graefes Arch Clin Exp Ophthalmol* 2002;240:748-57.
21. Isola V, Pece A, Parodi MB. Choroidal ischemia after photodynamic therapy with verteporfin for choroidal neovascularization. *Am J Ophthalmol* 2006;142:680-3.
22. Schmidt-Erfurth U, Michels S, Barbazetto I, Laqua H. Photodynamic effects on choroidal neovascularization and physiological choroid. *Invest Ophthalmol Vis Sci* 2002;43:830-41.

23. Rogers AH, Martidis A, Greenberg PB, Puliafito CA. Optical coherence tomography findings following photodynamic therapy of choroidal neovascularization. *Am J Ophthalmol* 2002; 134:566–76.
24. Costa RA, Farah ME, Cardillo JA, et al. Immediate indocyanine green angiography and optical coherence tomography evaluation after photodynamic therapy for subfoveal choroidal neovascularization. *Retina* 2003;23:159–65.
25. Schmidt-Erfurth U, Schlötzer-Schrehard U, Cursiefen C, et al. Influence of photodynamic therapy on expression of vascular endothelial growth factor (VEGF), VEGF receptor 3, and pigment epithelium-derived factor. *Invest Ophthalmol Vis Sci* 2003;44:4473–80.
26. Koizumi H, Iida T, Nagayama D, et al. Indocyanine green angiography in eyes with substantially increased subretinal fluid 1 week after photodynamic therapy. *Retin Cases Brief Rep* 2008;2:12–4.
27. Povazay B, Hofer B, Torti C, et al. Impact of enhanced resolution, speed and penetration on three-dimensional retinal optical coherence tomography. *Opt Express* [serial online] 2009;17:4134–50. Available at: <http://www.opticsinfobase.org/abstract.cfm?URI=oe-17-5-4134>. Accessed December 8, 2009.
28. Yasuno Y, Miura M, Kawana K, et al. Visualization of sub-retinal pigment epithelium morphologies of exudative macular diseases by high-penetration optical coherence tomography. *Invest Ophthalmol Vis Sci* 2009;50:405–13.
29. de Bruin DM, Burnes DL, Loewenstein J, et al. In-vivo three-dimensional imaging of neovascular age-related macular degeneration using optical frequency domain imaging at 1050 nm. *Invest Ophthalmol Vis Sci* 2008;49:4545–52.
30. Huber R, Adler DC, Srinivasan VJ, Fujimoto JG. Fourier domain mode locking at 1050 nm for ultra-high-speed optical coherence tomography of the human retina at 236,000 axial scans per second. *Opt Lett* 2007;32:2049–51.
31. Spaide RF. Enhanced depth imaging optical coherence tomography of retinal pigment epithelial detachment in age-related macular degeneration. *Am J Ophthalmol* 2009;147:644–52.
32. Spaide RF. Age-related choroidal atrophy. *Am J Ophthalmol* 2009;147:801–10.
33. Margolis R, Spaide RF. A pilot study of enhanced depth imaging optical coherence tomography of the choroid in normal eyes. *Am J Ophthalmol* 2009;147:811–5.
34. Fujiwara T, Imamura Y, Margolis R, et al. Enhanced depth imaging optical coherence tomography of the choroid in highly myopic eyes. *Am J Ophthalmol* 2009;148:445–50.
35. Paskowitz DM, Donohue-Rolfe KM, Yang H, et al. Neurotrophic factors minimize the retinal toxicity of verteporfin photodynamic therapy. *Invest Ophthalmol Vis Sci* 2007;48:430–7.

Footnotes and Financial Disclosures

Originally received: August 31, 2009.

Final revision: December 31, 2009.

Accepted: January 8, 2010.

Available online: May 15, 2010.

Manuscript no. 2009-1189.

¹ Department of Ophthalmology, Fukushima Medical University School of Medicine, Fukushima, Japan.

² Vitreous, Retina, Macula Consultants of New York, New York, New York.

Financial Disclosure(s):

The author(s) have no proprietary or commercial interest in any materials discussed in this article.

Supported in part by the Macula Foundation, New York, New York.

Correspondence:

Ichiro Maruko, MD, Department of Ophthalmology, Fukushima Medical University School of Medicine, 1 Hikarigaoka, Fukushima, Japan. E-mail: imaruko@fmu.ac.jp.

Combined cases of polypoidal choroidal vasculopathy and typical age-related macular degeneration

Ichiro Maruko · Tomohiro Iida · Masaaki Saito ·
Dai Nagayama

Received: 23 August 2009 / Revised: 8 December 2009 / Accepted: 10 December 2009 / Published online: 14 January 2010
© Springer-Verlag 2009

Abstract

Background When we classified neovascular exudative age-related macular degeneration (AMD) into three types of polypoidal choroidal vasculopathy (PCV), typical AMD, and retinal angiomatous proliferation (RAP) in our previous study, we reported 5.5% had the combined cases, such as one eye had PCV and the other eye had typical AMD. We examined the clinical characteristics of these combined cases in the current study.

Methods All cases underwent fluorescein and indocyanine green angiography (FA and ICGA) at the initial examination. All PCV cases were diagnosed definitively based on characteristic aneurysmal lesions seen on ICGA. Follow-up examinations also were conducted to determine whether polypoidal lesions had developed in the eyes with typical AMD.

Results Among 349 patients with neovascular AMD, 20 (5.7%) had one eye with PCV and the other eye with typical AMD. The average age was 73 years. The mean best-corrected visual acuity levels at the initial examination in eyes with PCV and typical AMD were 0.20 and 0.43, respectively ($p=0.09$). All subgroups of classic and occult CNV were observed in the eyes with typical AMD on FA. During the follow-up period (average, 21.7 months), PCV developed in ten eyes with typical AMD at the initial examination.

Conclusions Although some cases might include different stages of progression or probable cases of PCV, the combined cases in which one eye has PCV and the other eye has typical AMD suggest that those clinical entities are not independent and possibly overlap.

Keywords Polypoidal choroidal vasculopathy · Age-related macular degeneration

Introduction

Neovascular exudative age-related macular degeneration (AMD) is a leading cause of legal blindness in elderly patients in developed countries. In Japan, fewer patients have neovascular AMD compared to Western countries [8, 9, 14, 17, 20]. However, the prevalence of AMD in Japan is increasing rapidly [15], and the demographic features differ from those in other countries.

We classified neovascular AMD in Japanese patients into three types and reported that among 289 patients, 158 (54.7%) were diagnosed with polypoidal choroidal vasculopathy (PCV), 102 (35.3%) with typical AMD, and 13 (4.5%) with retinal angiomatous proliferation (RAP) [13]. We concluded that neovascular AMD in Japanese patients has demographic features that differ from those in Caucasian patients. Each type is characterized by differences in clinical behavior, examination findings, and pathologic deductions. Accurate diagnoses of these types are important for appropriate patient management [2, 19]. However, we also reported that 16 patients (5.5%) had a combination of types, i.e., one eye had PCV and the other eye had typical AMD. These combined cases might indicate that these pathologies are not independent of each other. Because the proportion of PCV in neovascular AMD in Japan is more than 50%, cases with both PCV and typical AMD might be observed frequently.

In the current study, we examined the clinical characteristics of cases in which one eye had PCV and the other eye had typical AMD.

I. Maruko (✉) · T. Iida · M. Saito · D. Nagayama
Department of Ophthalmology,
Fukushima Medical University School of Medicine,
1 Hikarigaoka,
Fukushima 960-1247, Japan
e-mail: imaruko@fmu.ac.jp

Patients and methods

The study followed the tenets of the Declaration of Helsinki. We retrospectively reviewed the medical records of the patients and there were no confidentiality issues. The institutional review board at Fukushima Medical University School of Medicine approved this retrospective analysis. All subjects provided written informed consent after the nature and possible consequences of the study were explained.

The patients with neovascular AMD in whom one eye had PCV and the other eye had typical AMD were evaluated retrospectively based on age, gender, and best-corrected visual acuity (BCVA) in each eye. The BCVA was measured with a Japanese standard decimal VA chart, and the mean BCVA was calculated using the logarithm of the minimum angle of resolution (logMAR) scale. The clinical examination included indirect ophthalmoscopy, slit-lamp biomicroscopy with a contact lens, or noncontact lens (e.g., 60 diopters), and color and red-free fundus photography. All participants were examined by digital fluorescein angiography (FA) and indocyanine green angiography (ICGA) at the initial examination. We used a digital imaging system with an infrared camera and standard fundus camera (TRC-50 IX/IMAGENet H1024 system, Topcon, Tokyo, Japan) and a confocal laser scanning system (HRA-2, Heidelberg Engineering, Dossenheim, Germany). All angiograms were evaluated by three retina specialists (I.M., T.I., M.S.) masked to the clinical findings. We measured the lesion area in eyes with PCV and typical AMD on the FA images using IMAGENet 2000 software (Topcon). The lesion area was defined as the area of leakage caused by neovascularization and features obscuring the boundaries, including blocked fluorescence due to blood, thick exudate, hypertrophic retinal pigment epithelium (RPE), and associated pigment epithelial detachment (PED) on FA. The lesion area was measured in disc areas (DA), with one DA calculated as 2.54 mm^2 based on a standard disc diameter of 1.8 mm [1, 18]. All cases were observed by optical coherence tomography (OCT) to confirm RPE elevation and retinal morphologic changes. The following definitions were used to describe the related clinical and angiographic abnormalities evaluated in the current study.

The diagnostic criteria for PCV in the current study were proposed based on ICGA findings, which visualized the characteristic aneurysmal lesions. The Japanese Study Group of Polypoidal Choroidal Vasculopathy [7] defined the following criteria: protruded orange-red elevated lesions (excluding PED, choroidal hemangioma, and subretinal blood) observed by fundus examination and characteristic aneurysmal lesions seen on ICGA. However, only definitive cases of PCV on ICGA were included in the current study for unequivocal diagnosis. All patients with PCV

were diagnosed as having neovascular AMD on FA, and then it was identified as PCV on ICGA.

The typical AMD lesion area was comprised of classic choroidal neovascularization (CNV) on FA and defined as follows: predominantly classic CNV, neovascular lesions in which the classic CNV component was greater than 50% of the total lesion area; minimally classic CNV, lesions in which the classic CNV components were less than 50% of the total lesion area; and occult CNV with no classic CNV component [2, 18]. Patients with other macular diseases such as high myopia, angioid streaks, and central serous chorioretinopathy were excluded.

All participants were examined and evaluated clinically by digital FA, ICGA, and OCT during the follow-up examinations. If polypoidal lesions developed in the eyes with typical AMD, we specified the location at which a polypoidal lesion developed during the follow-up period.

The results of a comparison of BCVA and the lesion area between the eyes with PCV and the fellow eye with typical AMD were analyzed using the Student's *t*-test. $p < 0.05$ was considered significant.

Results

Among 349 patients with neovascular AMD examined between 2003 and 2005 at Fukushima Medical University Hospital, Fukushima, Japan, 20 patients (5.7%) in whom PCV was present in one eye and typical AMD in the fellow eye at the initial examination were included (16 men, four women; average age, 73 years). All patients were newly diagnosed with bilateral neovascular AMD. Although the combined cases should be defined as those in which each eye had a different type of neovascular AMD (i.e., PCV, typical AMD, or RAP), there were no cases with PCV and RAP or with typical AMD and RAP. Sixteen of the 20 patients had been included in our previous report [7]. Imaging procedures were performed successfully for all patients.

Table 1 shows the characteristics of the combined cases of PCV and typical AMD in the current study. The mean BCVA levels at the initial examination in eyes with PCV and typical AMD were 0.20 (0.71 logMAR) and 0.43 (0.37 logMAR) ($p = 0.09$), respectively. The eyes with typical AMD were classified as one eye with predominantly classic CNV, five eyes with minimally classic CNV, and 14 eyes with occult with no classic CNV on FA. All subgroups classified according to classic CNV component on FA were observed in the eyes with typical AMD. The mean lesion area (DA) in eyes with PCV was larger than in eyes with typical AMD (10.8 ± 9.2 and 5.9 ± 3.9 , respectively; $p = 0.03$).

The 20 patients in the current study also underwent follow-up examinations after the initial examination (average follow-up period, 21.7 months; range, 2–48 months). In 20

Table 1 Clinical characteristics of combined cases in which one eye has PCV and the other eye has typical AMD

Patient no.	Sex	Age	Eyes with PCV			Eyes with Typical AMD					F/U (mo)
			Eye	BCVA at baseline	Lesion area (DA)	Eye	BCVA at baseline	Lesion area (DA)	Subgroup ^a on FA	develop PCV [†]	
1	M	76	OD	0.07	25.7	OS	0.3	5.8	ON	Yes	48
2	M	68	OD	0.8	10.6	OS	0.1	9.6	ON	Yes	6
3	M	62	OS	0.5	6.6	OD	0.5	3.0	ON	Yes	30
4	M	72	OD	0.5	11.2	OS	1.5	10.8	ON	Yes	6
5	M	75	OD	0.2	5.9	OS	0.7	2.5	ON	Yes	18
6	M	70	OD	0.02	7.9	OS	0.15	15.9	MC	Yes	30
7	M	82	OS	0.09	5.2	OD	0.04	6.1	MC	Yes	18
8	F	67	OS	0.06	11.8	OD	0.1	6.4	MC	Yes	2
9	M	79	OS	1.2	1.0	OD	0.3	8.1	MC	Yes	36
10	M	83	OD	0.1	3.7	OS	1.5	1.3	MC	Yes	30
Mean (1–10)		74		0.19	9.0±6.8		0.24	7.0±4.4			21.6
11	M	67	OS	0.03	29.4	OD	0.2	7.9	ON	No	18
12	M	75	OD	0.1	9.0	OS	0.4	4.4	ON	No	36
13	M	75	OS	1.2	2.2	OD	0.2	2.6	ON	No	30
14	M	75	OS	0.5	2.8	OD	0.9	1.5	ON	No	30
15	F	81	OS	0.1	27.2	OD	0.7	3.4	ON	No	24
16	F	53	OS	1.5	6.0	OD	1.2	3.2	ON	No	18
17	M	82	OS	0.05	19.7	OD	1.2	11.5	ON	No	6
18	M	82	OS	0.04	23.6	OD	0.7	3.4	ON	No	18
19	M	71	OD	0.3	3.9	OS	1.0	2.5	ON	No	6
20	F	66	OS	1.2	2.0	OD	1.0	7.2	PC	No	24
Mean (11–20)		73		0.18	12.6±11.1		0.60	4.8±3.1			20.7
Mean all		73		0.20	10.8±9.2		0.43	5.9±3.9			21.7

PCV = polypoidal choroidal vasculopathy; OS = left eye; OS = right eye;

AMD = age-related macular degeneration;

BCVA = best-corrected visual acuity. Mean BCVA was calculated using the logarithm of the minimum angle of resolution (logMAR) scale

Lesion area (DA) = the lesion size (DA) of eyes with PCV and typical AMD was measured from fluorescein and Indocyanine green angiography

DA = disc area

One DA = 2.54 mm² based on a standard disc diameter (DD) of 1.8 mm

FA = fluorescein angiography

MC = Minimally classic CNV

ON = Occult with no classic CNV

PC = Predominantly classic CNV

CNV = choroidal neovascularization

F/U (mo) = duration of follow-up period (months)

^a The area of the lesion of typical AMD was composed of classic choroidal neovascularization (CNV) on fluorescein angiography and evaluated as follows:

predominantly classic CNV: a neovascular lesion in which the classic CNV component was greater than 50% of the total lesion size;

minimally classic CNV: lesions in which the classic CNV components were less than 50% of the total lesion size;

occult with no classic CNV: lesions in which there was no classic CNV component.

[†]develop PCV = development of PCV; The PCV cases appear the polypoidal lesion in the eyes with typical AMD during the follow-up period.

eyes with typical AMD diagnosed at the initial examination, PCV developed angiographically and clinically in ten eyes during the follow-up period (Table 1). Eight of 20 eyes with typical AMD diagnosed at the initial examination underwent

photodynamic therapy (PDT) or laser photocoagulation during the follow-up period. Among the eyes with typical AMD, PCV was observed in four of eight treated eyes and six of 12 untreated eyes in the eyes at the initial examination.

There was no significant difference due to therapy in development of PCV among the eyes with typical AMD at the initial examination. A polypoidal lesion on ICGA developed from the edge of the original CNV at the initial examination in seven eyes and emerged from the area within the original CNV at the initial examination in three eyes.

Case reports

Case 1 was that of a 67-year-old man (patient 11) who reported visual loss in the left eye a few years previously and acute visual loss in the right eye. The BCVA at the initial examination was 0.2 (0.70 logMAR) in the right eye

Fig. 1 Case 1 (patient 11). A 67-year-old man is representative of the combined cases of PCV and AMD in which the right eye has occult with no classic CNV and left eye has PCV. **a, b** A red-free fundus photograph showing RPE degeneration with a large PED in the right eye and an extensive exudative lesion with hard exudates and subretinal hemorrhage in the left eye. **c, d** FA shows occult CNV that includes the fovea with a large PED at the inferior fovea in the right eye and occult CNV with large fibrovascular PED in the left eye. Early phase (**e, f**) and late-phase (**g, h**) ICGA images showing hyperfluorescence corresponding to the PED in the right eye and a polypoidal lesion (*arrows*) at the superior temporal fovea in the left eye. There is no evidence of PCV in the right eye during early and late-phase ICGA

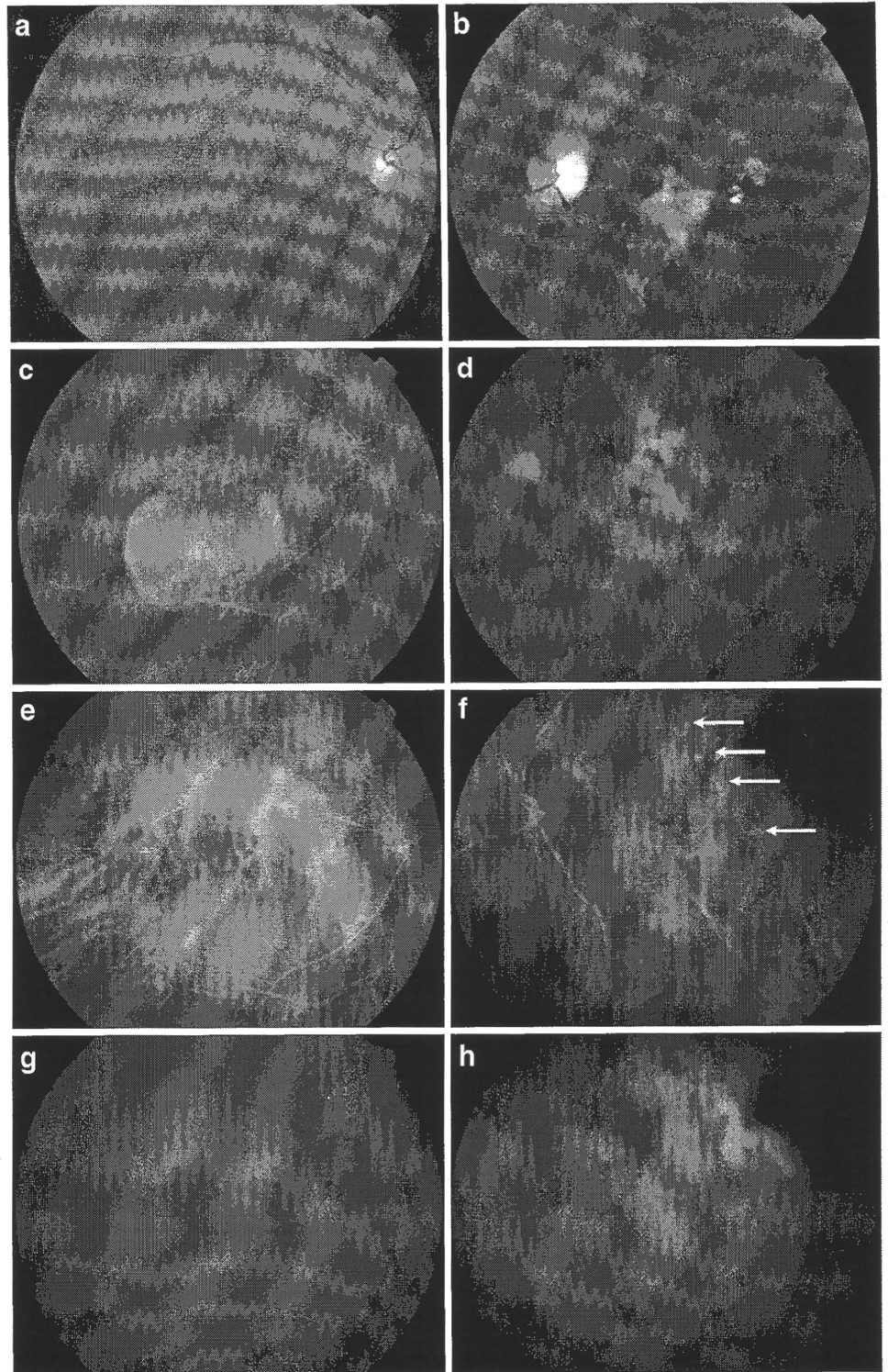
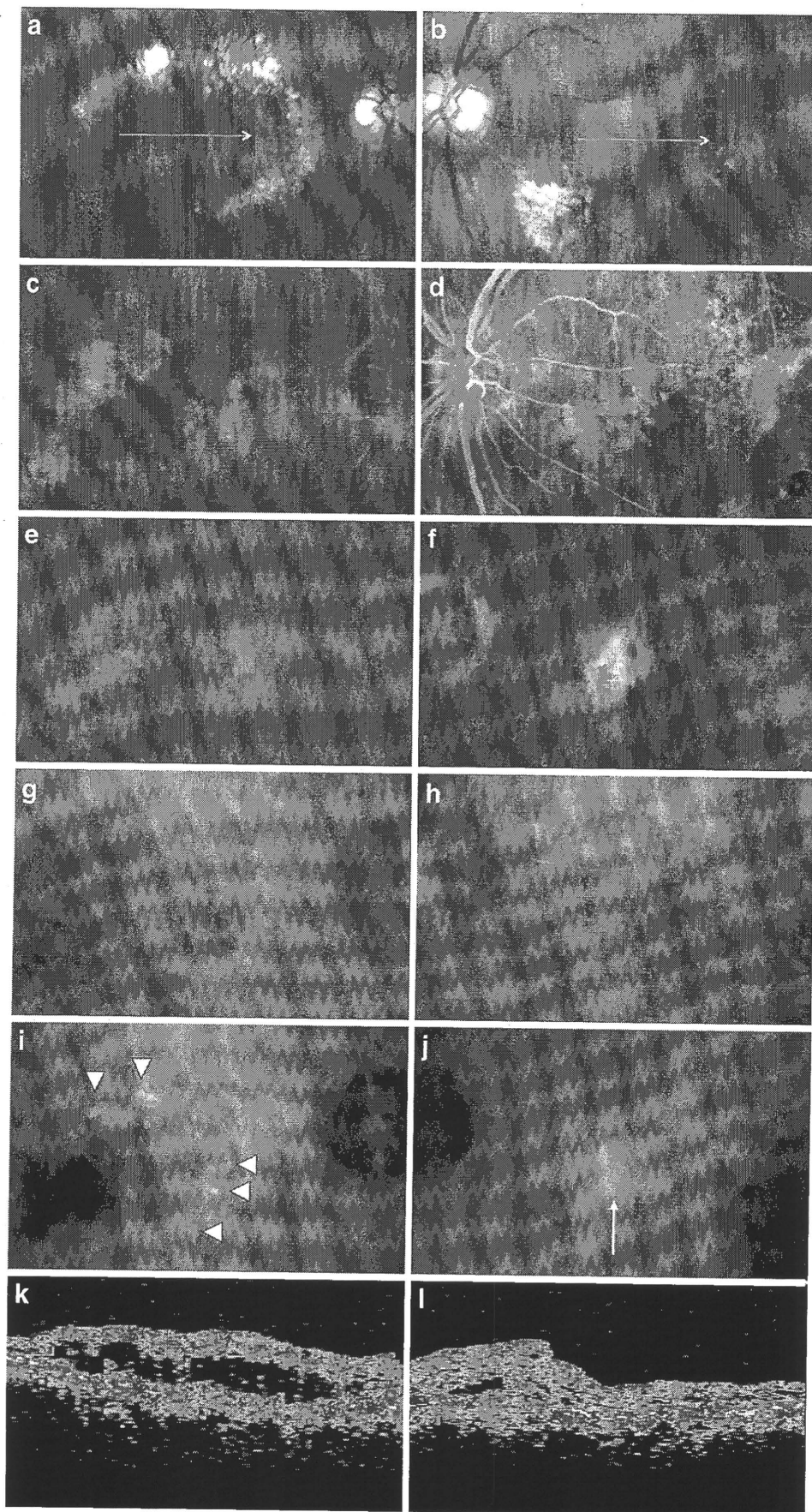


Fig. 2 Case 2 (patient 6). A 70-year-old man is representative of a combined case in which the right eye has PCV and the left eye has minimally classic CNV at the initial examination. **a, b** A red-free fundus photograph showing a gray-green lesion in the macular area surrounded by circinate exudates in the right eye and an extensive exudative lesion with a subretinal hemorrhage in the left eye. Early phase (**c, d**) and late-phase (**e, f**) FA images show minimally classic CNV nasal to the fovea bilaterally. Early phase (**g, h**) and late-phase (**i, j**) ICGA images show polypoidal lesions (*arrowhead*) at the outside edge of the area corresponding to the occult CNV on FA in the right eye and hyperfluorescence (*arrow*) nasal to the fovea in the left eye, which is the same area of classic CNV component on FA. There is no evidence of PCV in the left eye at the initial examination. OCT shows a serous retinal detachment in the right eye (**k**) and the hyperreflective tissue without RPE elevation at the gray-green lesion in the left eye (**l**). OCT images correspond to *horizontal white line* of (a) and (b)



and 0.03 (1.52 logMAR) in the left eye. There was RPE degeneration with a large PED in the right eye and an extensive exudative lesion with hard exudates and subretinal hemorrhages in the left eye. FA showed occult CNV that included the fovea with a large PED at the inferior fovea in the right eye and occult CNV with a large fibrovascular PED in the left eye. ICGA showed a polypoidal lesion at the superior temporal area of the fovea in the left eye. The lesion areas (DA) in eyes with typical AMD (right eye) and PCV (left eye) were 7.9 and 29.4, respectively. Although it was possible that PCV could develop in the future, there was no evidence of PCV in the right eye during the follow-up period (18 months). In this combined case of PCV and AMD, the right eye had occult CNV and the left eye had PCV (Fig. 1).

Case 2 was that of a 70-year-old man (patient 6) who had visual loss in the right eye a few years previously and sudden visual loss in the left eye. The BCVA at the initial examination was 0.15 (0.82 logMAR) in the right eye and 0.02 (1.70 logMAR) in the left eye. There was an elevated orange-red lesion in the macular area surrounded by circinate exudates in the right eye and an extensive exudative lesion that was partially gray-green with a subretinal hemorrhage in the left eye. FA showed minimally classic CNV; classic CNV was nasal to the fovea surrounded by occult CNV bilaterally. ICGA showed polypoidal lesions at the marginal edge of the area corresponding to the occult CNV on FA in the right eye.

OCT showed a serous retinal detachment in the right eye and hyperreflective tissue without elevated RPE, indicating type 2 CNV above the RPE at the gray-green lesion in the left eye. There was no evidence of PCV in the left eye at the initial examination. The lesion areas (DA) in the right eye with PCV and the left eye with typical AMD were 15.9 and 7.9, respectively. In this combined case of PCV and AMD, the right eye had PCV and left eye had the minimally classic CNV of typical AMD at the initial examination. Although there was no leakage from the classic CNV in the left eye on FA after two applications of PDT, a polypoidal lesion was seen after 2.5 years on ICGA temporal to the fovea and separate from the original classic CNV. OCT temporal to the fovea in the left eye showed an elevated dome-shaped RPE corresponding to a polypoidal lesion on ICGA. PCV developed bilaterally during the 30-month follow-up period (Figs. 2 and 3).

Discussion

The current study showed that combined cases of PCV and typical AMD can develop in patients with neovascular AMD, in which one eye has PCV and the other eye has typical AMD. We identified these combined cases in 5.7% of the patients with neovascular AMD. Fifty percent of cases with typical AMD at the initial examination had a polypoidal lesion on ICGA during the follow-up period despite PDT or

Fig. 3 Case 2. PCV in the left eye 2.5 years later in the same patient as in Fig. 2. **a** A red-free fundus photograph showing a gray-green lesion in the macular area without exudative lesion and subretinal hemorrhage. **b** FA shows no classic CNV. Early phase (c) and late-phase (d) ICGA images showing a polypoidal lesion (arrowheads) temporal to the fovea. Arrows in (b), (c), and (d) indicate the area corresponding to the classic CNV component on FA in the left eye in Fig. 2. **e** An OCT image temporal to the fovea in the left eye shows a dome-shaped RPE elevation (arrowhead) corresponding to a polypoidal lesion on ICGA. The OCT image corresponds to the horizontal white line in (a)

