

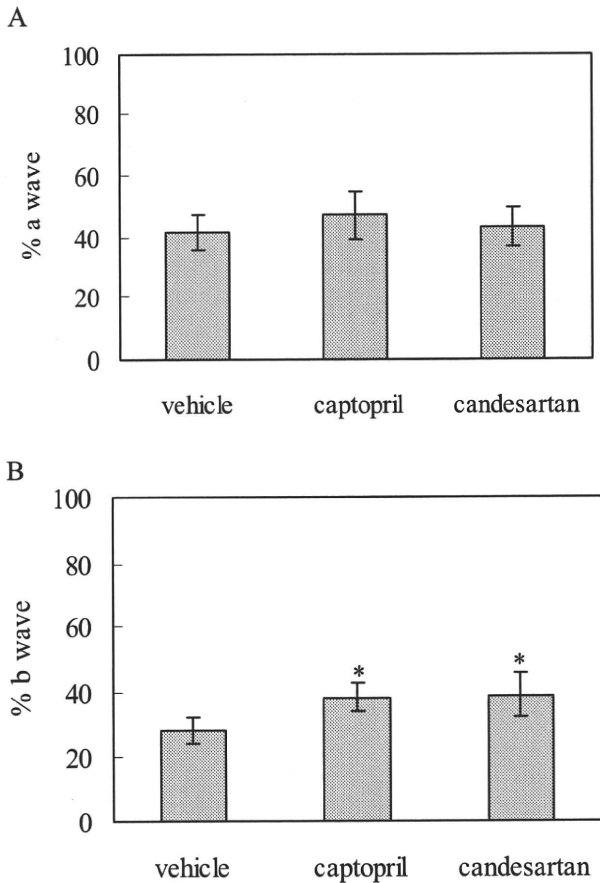FIGURE 7. On postoperative day 7, (A) a-wave amplitude percentages were 41.6% ± 6.0% in the vehicle group, 47.2% ± 8.0% in the captopril group, and 43.4% ± 6.5% in the candesartan group. (B) b-Wave amplitude percentages were 28.3% ± 4.3%, 38.2% ± 4.3%, and 39.0% ± 6.4%, respectively. Data express the mean ± SD. **P* < 0.05 versus vehicle (Dunnnett's multiple comparison test).

NMDA subtype of glutamate receptors are the influx of calcium into cells and the generation of free radicals.⁴⁰ Excessive accumulation of intracellular free Ca²⁺ ([Ca²⁺]_i) can have a wide range of detrimental effects, including inhibition of mitochondrial function, reduction of cellular ATP levels, enhancement of ROS production, and activation of cellular proteases and nitric oxide (NO) synthase.⁴⁰ In combination, these effects can result in neuronal death. In the present study, we showed that suppression of ischemia-induced ROS production can block the AT1-R, which leads to protection of the neurons from delayed neuronal death. However, it is still unclear whether blocking the AT1-R has any effects on the extracellular glutamate levels or [Ca²⁺]_i. Further studies are needed to address why the effect on the RGC and ERG preservation was mild despite the high ROS inhibition observed in this study.

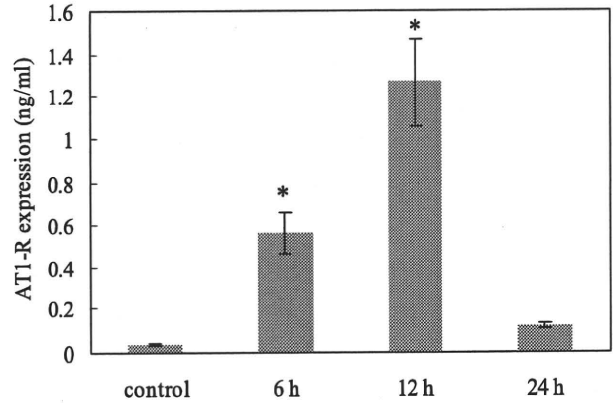


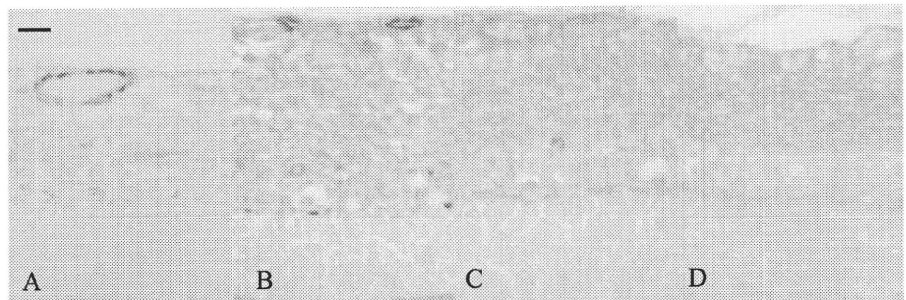
FIGURE 9. AT1-R expression of normal rat retina and rat retina at 6, 12, and 24 hours after ischemia. Data express the mean ± SD. **P* < 0.05 versus vehicle (Dunnnett's multiple comparison test).

ACE inhibitors inhibit the formation of Ang II from Ang I, which reduces the action of Ang II at both AT1-R and AT2-R. ACE inhibitors also play another role in the KKS: they prevent the inactivation of bradykinin. Therefore, though administration of an ACE inhibitor decreases Ang II, it also increases bradykinin in the retina. Conversely, AT1-R antagonists act more selectively by blocking the action of Ang II on the AT1-R. The decreased AT1-R-mediated activities of Ang II are the underlying mechanism of the antihypertensive effects of these drugs.

Bradykinin is well known as a plasma kinin that induces inflammation by way of the B2-R.²³ B2-R is distributed in rat retinas in situ and in vitro, and bradykinin has a protective effect against neurotoxicity induced by glutamate through B2-R in cultured retinal neurons.^{41,42} However, bradykinin did not have a neuroprotective effect in the present study, possibly because of the different experimental methods used (in vivo vs. in vitro). Several investigators have reported that the B2-R antagonists provide a tissue-protective effect against ischemic injury.^{43,44} In the present study, however, the B2-R antagonist icatibant did not exhibit any protective effect against retinal ischemic damage. Although the major KKS components, which include kininogen, kallikrein, kininase II (ACE), and B2-R, have been shown to be present in the choroid and the retina,^{45,46} KKS was not implicated in the ischemic insult to the retina in the present study.

A considerable amount of ROS is produced in ischemia, especially during perfusion. The amounts produced are related to the oxygen supply and metabolism; when these are exacerbated, neuronal cell damage occurs.^{29,47} Ang II activates the NADPH-dependent oxidase complex, which serves as a major

FIGURE 8. Immunohistochemical staining of AT1-R expression in the retina. Retinal sections from normal animals (A) or at 6 hours (B), 12 hours (C), or 24 hours (D) after ischemia. Positive staining for AT1-R on the inner retinal vessels. AT1-R was present in the ganglion cell layer and INL of the ischemic retina. Scale bar, 10 μm.



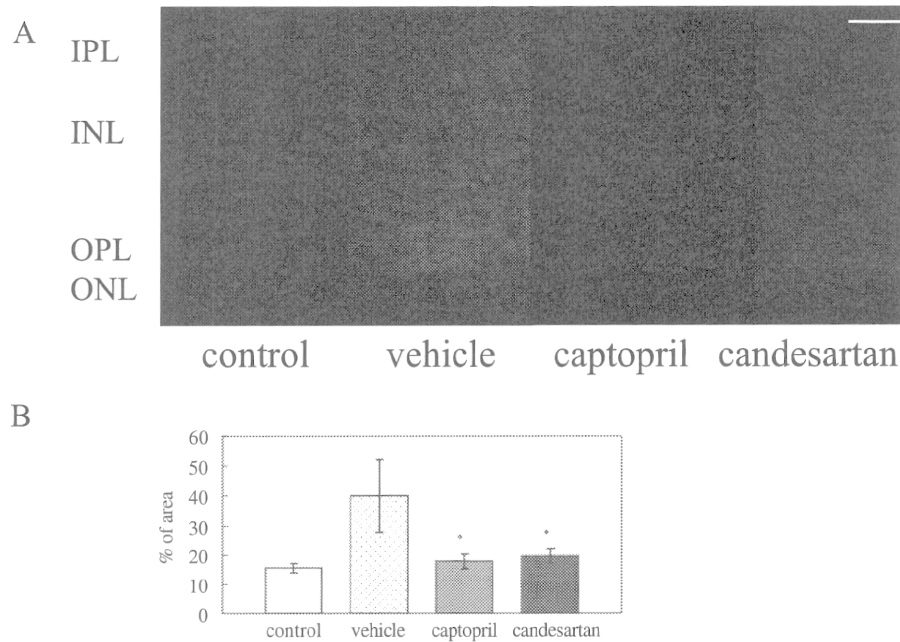


FIGURE 10. Effect of captopril or candesartan pretreatment on the release of ROS. (A) ROS, detected by DHE, was upregulated in retinal neuronal cells in the retina after ischemia (vehicle compared with control). However, pretreatment with 10 mg/kg captopril or 1 mg/kg candesartan decreased the level of ROS. Scale bar, 5 μ m. (B) Measured area of red (%). Data express the mean \pm SD. * $P < 0.05$ versus vehicle (Dunnett's multiple comparison test.)

source of superoxide in addition to upregulation in several pathologic conditions associated with oxidative stress.^{12,13} Given that oxidative stress induces apoptosis in neurons,⁴⁸ hydrostatic pressure-induced oxidative stress could very well be the mechanism responsible for the similar pressure-induced apoptosis seen in RGC-5 cells⁴⁹ and animal models.^{50,51} In acute pancreatitis, administration of an AT1-R antagonist in conjunction with losartan can suppress the production of ROS by NADPH oxidase.⁵² In addition, ACE inhibition or administration of an AT1-R antagonist can reduce oxidative stress and protect dopamine neurons in the 6-hydroxydopamine and MPTP in vivo models of parkinsonism.⁵³⁻⁵⁵ In the present study, there was an increase in the AT1-R level in the inner retina after the ischemia-reperfusion injury. Therefore, it is conceivable that inhibition of AT1-R could contribute considerably to the observed beneficial effects of captopril or candesartan on the neurologic outcome of ischemia-reperfusion injury. Kurihara et al.⁵⁶ recently reported that the AT1-R signal caused the production of Ang II in a positive feedback manner in the retina and ultimately promoted inflammation.

We evaluated functional retinal damage after ischemia-reperfusion injury by measuring the ERG a- and b-wave ampli-

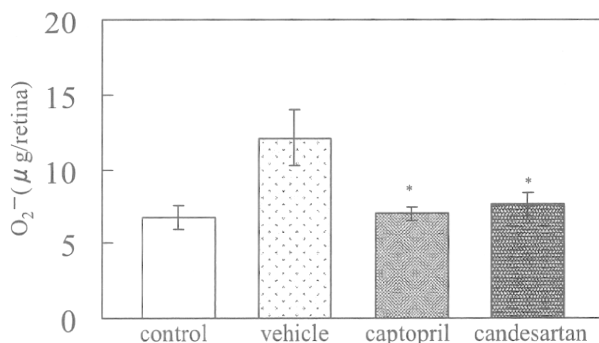


FIGURE 11. Effect of captopril or candesartan pretreatment on the detection of O₂⁻. Data express the mean \pm SD. * $P < 0.05$ versus vehicle (Dunnett's multiple comparison test).

tudes. Although it was impossible to determine the morphologic change in the outer retina with a microscope, Büchi⁵⁷ showed that cell death in the ONL of rat after ischemia could be observed by electron microscopy. This change in the ONL may be responsible for reducing the a-wave amplitude. The histologic change to the retina after pressure-induced ischemia was curiously irregular in distribution, making it difficult to correlate histologic and electrophysiologic recovery.⁵⁸ Given that selected regions of the retina (within 0.5–1 mm of the optic disc) were examined histologically, we presume that there is not a good correlation between the ERG b-wave and the histologic results.

In conclusion, the present study demonstrated that local AT1-R expression is markedly elevated after ischemia-reperfusion injury. Our results provide convincing evidence to suggest that blocking the AT1-R exerts therapeutic effects in cases of retinal ischemic insult.

References

- de Gasparo M, Catt KJ, Inagami T, Wright JW, Unger T. International Union of Pharmacology XXIII: the angiotensin II receptors. *Pharmacol Rev.* 2000;52:415–472.
- de Gasparo M, Husain A, Alexander W, et al. Proposed update of angiotensin receptor nomenclature. *Hypertension.* 1995;25:924–927.
- Murphy TJ, Alexander RW, Griendling KK, Runge MS, Bernstein KE. Isolation of cDNA encoding the vascular type-1 angiotensin II receptor. *Nature.* 1991;351:233–236.
- Sasaki K, Yamano Y, Bardhan S, et al. Cloning and expression of a complementary DNA encoding a bovine adrenal angiotensin II type-1 receptor. *Nature.* 1991;351:230–233.
- Stier CT Jr, Adler LA, Levine S, Chander PN. Stroke prevention by losartan in stroke-prone spontaneously hypertensive rats. *J Hypertens Suppl.* 1993;11:S37–S42.
- Linz W, Jessen T, Becker RH, Scholkens BA, Wiemer G. Long-term ACE inhibition doubles lifespan of hypertensive rats. *Circulation.* 1977;96:3164–3172.
- Nishimura Y, Ito T, Saavedra JM. Angiotensin II AT1 blockade normalizes cerebrovascular autoregulation and reduces cerebral ischemia in spontaneously hypertensive rats. *Stroke.* 2000;31:2478–2486.

8. Ito T, Yamakawa H, Bregonzio C, Terron JA, Falcon-Neri A, Saavedra JM. Protection against ischemia and improvement of cerebral blood flow in genetically hypertensive rats by chronic pretreatment with an angiotensin II AT1 antagonist. *Stroke*. 2002;33:2297-2303.
9. Nagai N, Oike Y, Izumi-Nagai K, et al. Suppression of choroidal neovascularization by inhibiting angiotensin-converting enzyme: minimal role of bradykinin. *Invest Ophthalmol Vis Sci*. 2007;48:2321-2326.
10. Nagai N, Izumi-Nagai K, Oike Y, et al. Suppression of diabetes-induced retinal inflammation by blocking the angiotensin II type 1 receptor or its downstream nuclear factor- κ B pathway. *Invest Ophthalmol Vis Sci*. 2007;48:4342-4350.
11. Nagai N, Oike Y, Noda K, et al. Suppression of ocular inflammation in endotoxin-induced uveitis by blocking the angiotensin II type 1 receptor. *Invest Ophthalmol Vis Sci*. 2005;46:2925-2931.
12. Griendling KK, Sorescu D, Ushino-Fukai M. NADPH oxidase: role in cardiovascular biology and disease. *Circ Res*. 2000;86:494-501.
13. Zalba G, San Jose G, Moreno MU, et al. Oxidative stress in arterial hypertension: role of NADPH oxidase. *Hypertension*. 2001;38:1395-1399.
14. Liu H, Kitazato KT, Uno M, et al. Protective mechanisms of the angiotensin II type 1 receptor blocker candesartan against cerebral ischemia: in-vivo and in-vitro studies. *J Hypertens*. 2008;26:1435-1445.
15. Gallinat S, Yu M, Dorst A, Unger T, Herdegen T. Sciatic nerve transection evokes lasting up-regulation of angiotensin AT2 and AT1 receptor mRNA in adult rat dorsal root ganglia and sciatic nerves. *Brain Res Mol Brain Res*. 1998;57:111-122.
16. Zhu YZ, Chimon GN, Zhu YC, et al. Expression of angiotensin II AT2 receptor in the acute phase of stroke in rats. *Neuroreport*. 2000;11:1191-1194.
17. Matsubara H. Pathophysiological role of angiotensin II type 2 receptor in cardiovascular and renal diseases. *Circ Res*. 1998;83:1182-1191.
18. Saavedra JM. Brain angiotensin II: new developments, unanswered questions and therapeutic opportunities. *Cell Mol Neurobiol*. 2005;25:485-512.
19. Li J, Culman J, Hörtnagl H, et al. Angiotensin AT2 receptor protects against cerebral ischemia-induced neuronal injury. *FASEB J*. 2005;19:617-619.
20. Schulman IH, Raji L. The angiotensin II type 2 receptor: what is its clinical significance? *Curr Hypertens Rep*. 2008;10:188-193.
21. Schachter M. Kallikreins (kininogenases)—a group of serine proteases with bioregulatory actions. *Pharmacol Rev*. 1979;31:1-17.
22. Bhoola KD, Figueroa CD, Worthy K. Bioregulation of kinins: kallikreins, kininogens, and kininases. *Pharmacol Rev*. 1992;44:1-80.
23. Moreau ME, Garbacki N, Molinaro G, Brown NJ, Marceau F, Adam A. The kallikrein-kinin system: current and future pharmacological targets. *J Pharmacol Sci*. 2005;99:6-38.
24. Regoli D, Rhaleb NE, Drapeau G, Dion S. Kinin receptor subtypes. *J Cardiovasc Pharmacol*. 1990;15:S30-S38.
25. Taylor L, Ricupero D, Jean JC, Jackson BA, Navarro J, Polgar P. Functional expression of the bradykinin-B2 receptor cDNA in Chinese hamster lung CCL39 fibroblasts. *Biochem Biophys Res Commun*. 1992;188:786-793.
26. Farmer SG, Burch RM. Biochemical and molecular pharmacology of kinin receptors. *Annu Rev Pharmacol Toxicol*. 1992;32:511-536.
27. Tsujikawa A, Ogura Y, Hiroshiba N, Miyamoto K, Kiryu J, Honda Y. Tacrolimus (FK506) attenuates leukocyte accumulation after transient retinal ischemia. *Stroke*. 1998;29:1431-1437; discussion 1437-1438.
28. Tsujikawa A, Ogura Y, Hiroshiba N, et al. Retinal ischemia-reperfusion injury attenuated by blocking of adhesion molecules of vascular endothelium. *Invest Ophthalmol Vis Sci*. 1999;40:1183-1190.
29. Hirooka K, Miyamoto O, Jinming P, et al. Neuroprotective effects of D-allose against retinal ischemia-reperfusion injury. *Invest Ophthalmol Vis Sci*. 2006;47:1653-1657.
30. Iwama D, Miyamoto K, Miyahara S, et al. Neuroprotective effect of cilostazol against retinal ischemic damage via inhibition of leukocyte-endothelial cell interactions. *J Thromb Haemost*. 2007;5:818-825.
31. Sakamoto K, Kawakami T, Shimada M, et al. Histological protection by cilnidipine, a dual L/N-type Ca(2+) channel blocker, against neurotoxicity induced by ischemia-reperfusion in rat retina. *Exp Eye Res*. 2009;88:974-982.
32. Choi DW. Ionic dependence of glutamate neurotoxicity. *J Neurosci*. 1987;7:369-379.
33. Choi DW. Calcium-mediated neurotoxicity: relationship to specific channel types and role in ischemic damage. *Trends Neurosci*. 1988;11:465-469.
34. Bresnick GH. Excitotoxins: a possible new mechanism for the pathogenesis of ischemic retinal damage. *Arch Ophthalmol*. 1989;107:339-341.
35. Louzada-Júnior P, Dias JJ, Santos WF, Lachat JJ, Bradford HF, Coutinho-Netto J. Glutamate release in experimental ischaemia of the retina: an approach using microdialysis. *J Neurochem*. 1992;59:358-363.
36. Faberowski N, Stefansson E, Davidson RC. Local hypothermia protects the retina from ischemia: a quantitative study in the rat. *Invest Ophthalmol Vis Sci*. 1989;30:2309-2313.
37. Imai H, Hashimoto M, Nakabayashi Y. Spectrophotometric determination of superoxide ion on the nitrobluetetrazolium method. *Buseki Kagaku*. 1994;43:51-56.
38. Adachi K, Kashii S, Masai H, et al. Mechanism of the pathogenesis of glutamate neurotoxicity in retinal ischemia. *Graefes Arch Clin Exp Ophthalmol*. 1998;236:766-774.
39. Lucas DR, Newhouse JP. The toxic effect of sodium L-glutamate on the inner layers of the retina. *AMA Arch Ophthalmol*. 1957;58:193-201.
40. Osborne NN, Ugarte M, Chao M, et al. Neuroprotection in relation to ischemia and relevance of glaucoma. *Surv Ophthalmol*. 1999;43:S102-S128.
41. Yasuyoshi H, Kashii S, Zhang S, et al. Protective effect of bradykinin against glutamate neurotoxicity in cultured rat retinal neurons. *Invest Ophthalmol Vis Sci*. 2000;41:2273-2278.
42. Yamauchi T, Kashii S, Yasuyoshi H, Zhang S, Honda Y, Akaike A. Mitochondrial ATP-sensitive potassium channel: a novel site for neuroprotection. *Invest Ophthalmol Vis Sci*. 2003;44:2750-2756.
43. Kumari R, Maulik M, Manchanda SC, Maulik SK. Protective effect of bradykinin antagonist Hoe-140 during in vivo myocardial ischemic-reperfusion injury in the cat. *Regul Pept*. 2003;115:211-218.
44. Souza DG, Lomez ES, Pinho V, et al. Role of bradykinin B₂ and B₁ receptors in the local, remote, and systemic inflammatory responses that follow intestinal ischemia and reperfusion injury. *J Immunol*. 2004;172:2542-2548.
45. Igic R. Kallikrein and kininases in ocular tissue. *Exp Eye Res*. 1985;41:117-120.
46. Ma JX, Song Q, Hatcher HC, Crouch RK, Chao L, Chao J. Expression and cellular localization of the kallikrein-kinin system in human ocular tissues. *Exp Eye Res*. 1996;63:19-26.
47. Aronowski J, Strong R, Grotta JC. Reperfusion injury: demonstration of brain damage produced by reperfusion after transient focal ischemia in rats. *J Cereb Blood Flow Metab*. 1997;17:1048-1056.
48. Mattson MP. Apoptosis in neurodegenerative disorders. *Nat Rev Mol Cell Biol*. 2000;1:120-129.
49. Agar A, Li S, Agarwal N, Coroneo MT, Hill MA. Retinal ganglion cell line apoptosis induced by hydrostatic pressure. *Brain Res*. 2006;1086:191-200.
50. Garcia-Valenzuela E, Shareef S, Walsh J, Sharma SC. Programmed cell death of retinal ganglion cells during experimental glaucoma. *Exp Eye Res*. 1995;61:33-44.
51. McKinnon SJ, Lehman DM, Kerrigan-Baumrind LA, et al. Caspase activation and amyloid precursor protein cleavage in rat ocular hypertension. *Invest Ophthalmol Vis Sci*. 2002;43:1077-1087.
52. Tsang SW, Ip SP, Leung PS. Prophylactic and therapeutic treatment with AT1 and AT2 receptor antagonists and their effects on changes in the severity of pancreatitis. *Int J Biochem Cell Biol*. 2004;36:330-339.

53. Lopez-Real A, Rey P, Soto-Otero R, Mendez-Alvarez E, Labandeira-Garcia JL. Angiotensin-converting enzyme inhibition reduces oxidative stress and protects dopaminergic neurons in a 6-hydroxydopamine rat model of parkinsonism. *J Neurosci Res.* 2005;81:865-873.
54. Muñoz A, Rey P, Guerra MJ, Mendez-Alvarez E, Soto-Otero R, Labandeira-Garcia JL. Reduction of dopaminergic degeneration and oxidative stress by inhibition of angiotensin converting enzyme in a MPTP model of parkinsonism. *Neuropharmacology.* 2006;51:112-120.
55. Rey P, Lopez-Real A, Sanchez-Iglesias S, Muñoz A, Soto-Otero R, Labandeira-Garcia JL. Angiotensin type-1-receptor antagonists reduce 6-hydroxydopamine toxicity for dopaminergic neurons. *Neurobiol Aging.* 2007;28:555-567.
56. Kurihara T, Ozawa Y, Shinoda K, et al. Neuroprotective effects of angiotensin II type 1 receptor (AT1R) blocker, telmisartan, via modulating AT1R and AT2R signaling in retinal inflammation. *Invest Ophthalmol Vis Sci.* 2006;47:5545-52.
57. Büchi ER. Cell death in rat retina after pressure-induced ischemia-reperfusion insult: electron microscopic study II: outer nuclear layer. *Jpn J Ophthalmol.* 1992;36:62-68.
58. Marmor MF, Dalal R. Irregular retinal and RPE damage after pressure-induced ischemia in the rabbit. *Invest Ophthalmol Vis Sci.* 1993;34:2570-2575.

RESEARCH LETTERS

Reduction in Dose of Intravitreal Bevacizumab Before Vitrectomy for Proliferative Diabetic Retinopathy

Bevacizumab (Avastin) is a full-length recombinant humanized monoclonal antibody directed against vascular endothelial growth factor (VEGF). It has been approved by the US Food and Drug Administration for the treatment of metastatic colorectal cancer.

Intravitreal (IV) injection of bevacizumab, 1.25 mg/0.05 mL, has been studied in patients with age-related macular degeneration, macular edema associated with retinal vein occlusion, and diabetic macular edema. Recently, bevacizumab administered prior to vitrectomy for proliferative diabetic retinopathy (PDR) was reported to reduce intraoperative bleeding.¹ Sawada et al² showed that IV bevacizumab blocked all free VEGF in the aqueous humor.

However, IV bevacizumab may cause systemic adverse effects such as thromboembolic diseases or increases in systolic blood pressure.³ Moreover, the rapid progression of traction retinal detachment after IV injection of bevacizumab was reported.⁴ Therefore, we need to consider an appropriate dose of bevacizumab to be injected intravitreally. The purpose of this study is to elucidate whether a reduced dose (0.25 mg) of IV bevacizumab has an effect equally strong as the widely

administered dose (1.25 mg) when IV bevacizumab is used as a surgical adjunct to treat PDR.

Methods. Thirty-eight eyes of 36 diabetic patients with PDR were studied. This study of the off-label use of bevacizumab and the collection of aqueous humor before and after IV injection were approved by the institutional review board of Kagawa University Faculty of Medicine.

All patients had vitreous hemorrhage or traction foveal detachment due to PDR. All patients underwent vitrectomy after IV injection of bevacizumab. Either 1.25 mg/0.05 mL or 0.25 mg/0.01 mL of bevacizumab was injected into the vitreous as a preoperative adjunct. Twenty-four consecutive eyes were treated with IV injection of 1.25 mg of bevacizumab between October 1, 2006, and February 29, 2008, and 14 consecutive eyes were treated with IV injection of 0.25 mg of bevacizumab between March 1, 2008, and September 30, 2009. Vitrectomy was performed 1 to 5 days after the injection. An aqueous humor sample was obtained just before IV injection of bevacizumab and just before vitrectomy. The concentration of free VEGF in the aqueous humor was measured with an enzyme-linked immunosorbent assay for human VEGF (Quankine VEGF enzyme-linked immunosorbent assay kit; R&D Systems, Minneapolis, Minnesota). Results were analyzed using SPSS version 12.1 statistical software (SPSS Inc, Chicago, Illinois).

Results. No statistically significant differences were found between the dose groups in baseline characteristics such as patient age, duration of diabetes, and presence of vit-

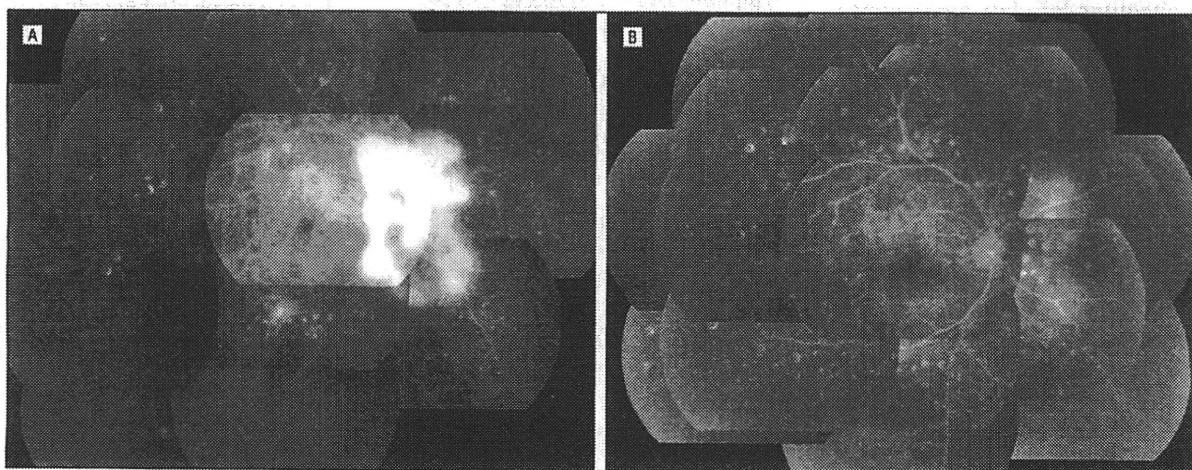


Figure. Fluorescein angiograms before the intravitreal injection of 0.25 mg of bevacizumab (A) and 24 hours after the intravitreal injection of bevacizumab (B) in a 56-year-old diabetic patient with traction foveal detachment. A, Fluorescein leakage from active neovascularization was seen. B, Fluorescein leakage substantially decreased after the intravitreal injection of bevacizumab.

reous hemorrhage or traction foveal detachment. There were no statistically significant differences between both groups in the frequency of intraoperative hemostasis (high infusion pressure or diathermy) (1.25-mg group, 13%; 0.25-mg group, 7%) and the incidence of postoperative vitreous hemorrhage (1.25-mg group, 13%; 0.25-mg group, 14%). No local complications or systemic adverse effects were observed in all eyes.

The mean (SD) free VEGF concentration in the aqueous humor before IV injection of bevacizumab was 349.0 (255.8) pg/mL in the 0.25-mg dose group and 359.5 (231.7) pg/mL in the 1.25-mg dose group. There were no significant differences between the groups. The VEGF levels in the aqueous humor 2 to 5 days after IV injection of bevacizumab were less than the limit of detection (31.0 pg/mL) in all eyes of both groups. Fluorescein angiography was performed before and 24 hours after the 0.25-mg IV injection of bevacizumab in 3 cases. Twenty-four hours after IV injection of bevacizumab, fluorescein angiography showed dramatic regression of retinal neovascularization with marked resolution of the leakage from active neovascularization seen before the injection (**Figure**).

Comment. The free VEGF concentration in the aqueous humor is different from that in the vitreous. However, the VEGF level in the aqueous humor has been reported to be significantly correlated with the VEGF level in the vitreous and is correlated with the severity of diabetic retinopathy and the activity of PDR.⁵ Both 1.25-mg and 0.25-mg IV injections of bevacizumab blocked all free VEGF in the aqueous humor. Nevertheless, 1.25 mg has been widely administered as the standard dose of IV bevacizumab. This study suggests that a lower dose (0.25 mg) of IV bevacizumab may be effective as a preoperative adjunct before vitrectomy in the treatment of PDR.

Hidetaka Yamaji, MD
Fumio Shiraga, MD,
Chieko Shiragami, MD
Hiroyuki Nomoto, MD
Tomoyoshi Fujita, MD
Kouki Fukuda, MD

Author Affiliations: Department of Ophthalmology, Kagawa University Faculty of Medicine, Kagawa, Japan.
Correspondence: Dr Yamaji, Department of Ophthalmology, Kagawa University Faculty of Medicine, 1750-1 Ikenobe, Miki-cho, Kita-gun, Kagawa 761-0793, Japan (proceed@kms.ac.jp).

Financial Disclosure: None reported.

1. Chen E, Park CH. Use of intravitreal bevacizumab as a preoperative adjunct for tractional retinal detachment repair in severe proliferative diabetic retinopathy. *Retina*. 2006;26(6):699-700.
2. Sawada O, Kawamura H, Kakinoki M, Sawada T, Ohji M. Vascular endothelial growth factor in aqueous humor before and after intravitreal injection of bevacizumab in eyes with diabetic retinopathy. *Arch Ophthalmol*. 2007;125(10):1363-1366.
3. Shima C, Sakaguchi H, Gomi F, et al. Complications in patients after intravitreal injection of bevacizumab. *Acta Ophthalmol*. 2008;86(4):372-376.
4. Oshima Y, Shima C, Wakabayashi T, et al. Microincision vitrectomy surgery and intravitreal bevacizumab as a surgical adjunct to treat diabetic traction retinal detachment. *Ophthalmology*. 2009;116(5):927-938.
5. Funatsu H, Yamashita H, Noma H, et al. Aqueous humor levels of cytokines are related to vitreous levels and progression of diabetic retinopathy in diabetic patients. *Graefes Arch Clin Exp Ophthalmol*. 2005;243(1):3-8.

Ultra-High-Resolution Optical Coherence Tomographic Findings in Commotio Retinae

C ommotio retinae is a self-limited opacification of the retina secondary to direct blunt ocular trauma. Histologic studies of monkeys and humans relate this clinical observation to damaged photoreceptor outer segments and receptor cell bodies.¹⁻³ Reports using time-domain optical coherence tomography (OCT) and spectral-domain OCT support the involvement of the photoreceptor layer, but these techniques lack the resolution necessary to confirm results of histologic analysis.⁴⁻⁶ Prototype high-speed ultra-high-resolution OCT (hs-UHR-OCT) images demonstrate these anatomical changes in a patient with acute commotio retinae.

Report of a Case. A 46-year-old man visited the emergency department with pain and blurry vision in the right eye after blunt ocular trauma. Uncorrected visual acuities were 20/30 OD and 20/25 OS. External examination showed periorbital ecchymosis and laceration. Pupil examination results were normal with relative afferent pupillary defect. Intraocular pressures were 14 mm Hg OD and 13 mm Hg OS. Slitlamp examination revealed a subconjunctival hemorrhage in the right eye. Orbital computed tomography demonstrated fracture of the right inferior and medial orbital walls. Dilated examination of the right eye showed a central, annular area of opacification of the retina surrounding the fovea consistent with commotio retinae (**Figure 1**). Retinal imaging was performed using spectral-domain OCT (Cirrus HD-OCT, software version 3.0; Carl Zeiss Meditec, Dublin, California) and prototype hs-UHR-OCT.

Comment. The spectral-domain OCT image suggests hyperreflectivity at the level of the photoreceptors (**Figure 2A**). However, the hs-UHR-OCT image better demonstrates increased backscattering at the level of the

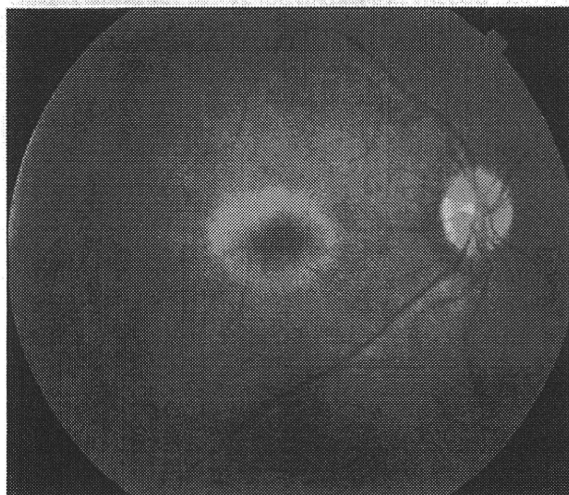


Figure 1. Color fundus photograph of the right eye showing annular opacification surrounding the macula of commotio retinae after blunt trauma. Corresponding spectral-domain and ultra-high-resolution optical coherence tomography images are shown in Figure 2A and C.

Plasma levels of vascular endothelial growth factor and pigment epithelium-derived factor before and after intravitreal injection of bevacizumab

K Matsuyama,¹ N Ogata,¹ M Matsuoka,¹ M Wada,¹ K Takahashi,² T Nishimura¹

¹Department of Ophthalmology, Kansai Medical University, Moriguchi, Osaka, Japan

²Department of Ophthalmology, Kansai Medical University, Hirakata, Osaka, Japan

Correspondence to

Associate Professor Nahoko Ogata, Department of Ophthalmology, Kansai Medical University, Fumizono-cho 10-15, Moriguchi, Osaka 570-8507, Japan; ogata@takii.kmu.ac.jp

Accepted 29 November 2009
Published Online First
10 June 2010

ABSTRACT

Aims To determine the level of vascular endothelial growth factor (VEGF) and pigment epithelium-derived factor (PEDF) in the plasma of patients with proliferative diabetic retinopathy before and after an intravitreal injection of bevacizumab.

Methods Eleven patients with type 2 diabetes and control of 30 non-diabetic patients were studied. The 11 eyes of 11 patients received an injection of bevacizumab (1.25 mg). Samples of blood were collected just before the injection, and after 1 day, 7 days and 1 month. The concentrations of VEGF and PEDF in the plasma were measured by ELISA.

Results The VEGF concentration before the injection was 114.0 pg/ml. It was significantly reduced to 9.7 pg/ml after 1 day, to 11.7 pg/ml after 7 days and to 25.9 pg/ml even after 1 month ($p < 0.001$, $p < 0.001$, $p < 0.001$, respectively). The PEDF concentration before the injection was 7.2 $\mu\text{g/ml}$. It was significantly reduced to 5.8 $\mu\text{g/ml}$ after 1 day, to 5.8 $\mu\text{g/ml}$ after 7 days and to 6.3 $\mu\text{g/ml}$ after 1 month ($p < 0.001$, $p < 0.001$, $p > 0.05$, respectively).

Conclusions The decreased levels of blood VEGF after an intravitreal injection of bevacizumab indicate that bevacizumab enters the general circulation and may also affect the PEDF levels. Thus, we should carefully examine patients for systemic changes and the fellow eye after an intravitreal injection of bevacizumab.

Vascular endothelial growth factor (VEGF) has been implicated in the development of human eye diseases characterised by neovascularisations, and the level of VEGF in the vitreous is highly correlated with the growth of new blood vessels in eyes with diabetic retinopathy.^{1, 2} Pigment epithelium-derived factor (PEDF), on the other hand, is known to be the most potent natural inhibitor of ocular angiogenesis.^{3, 4}

A blockage of VEGF has been associated with an inhibition of iris neovascularisation and suppression of the formation of new retinal vessels in primates.⁵ These findings provided the rationale for anti-VEGF therapy in retinal vascular diseases associated with angiogenesis.

Bevacizumab (Avastin, Genentech, Inc., San Francisco, California, USA) is a recombinant human monoclonal IgG₁ antibody that inhibits human VEGF. It has been approved by the US Food and Drug Administration for intravenous use for metastatic colorectal cancer. Several case series have been recently published on the off-label use of intravitreal bevacizumab in VEGF-mediated diseases.^{6–8}

With the expanding application of bevacizumab worldwide, it seems prudent to determine the VEGF levels in different tissues after intravitreal injections of bevacizumab to optimise the dosing regimens. Intravitreal bevacizumab has been shown to be associated with a substantial decrease in the aqueous VEGF levels in patients with diabetic retinopathy.^{9, 10} Chan *et al*¹¹ also reported on the aqueous VEGF and PEDF levels after intravitreal bevacizumab injection in patients with choroidal neovascularisation. However, to the best of our knowledge, data have not been published on the blood levels of VEGF after an intravitreal bevacizumab injection in a human case series.

Thus, the purpose of this study was to determine the blood levels of VEGF after a single intravitreal injection of bevacizumab and also to determine the levels of PEDF in patients with diabetic retinopathy.

MATERIALS AND METHODS

Subjects

The procedures used in this study conformed to tenets of the Declaration of Helsinki and were performed after receiving approval from the institutional review committee of the Kansai Medical University. An informed consent was obtained from all patients. Patients with proliferative diabetic retinopathy were included if they had neovascular glaucoma, rubeosis of the iris and/or angle structures including the trabecular meshwork, and had aggressive proliferative diabetic retinopathy. Eyes that had undergone vitrectomy were excluded.

Eleven patients with type 2 diabetes mellitus (nine men and two women) and control of 30 non-diabetic patients (15 men and 15 women) were studied. All 11 eyes of the 11 patients received an intravitreal injection of bevacizumab (1.25 mg). The clinical characteristics of the patients are shown in table 1. Eight eyes underwent vitrectomy 1 day after the injection of bevacizumab and three eyes received panretinal photocoagulation after the injection of bevacizumab.

Injection technique

The intravitreal injection of bevacizumab was performed as described.^{9–11} Briefly, under sterile conditions in the operating room, 1.25 mg (0.05 ml) of bevacizumab (Avastin 100 mg/4 ml) was injected into the vitreous by a sharp 30-gauge needle that was inserted into the eye 4.0 mm posterior from the limbus. The needle was carefully removed, and a sterile cotton applicator was used to prevent reflux. The postoperative medications

Table 1 Data of patients with diabetes mellitus

Case	Sex	Age (years)	HbA1c (%)	Rubeosis of angle	Rubeosis of the iris	Retinopathy (comments)
1	M	72	7.8	+	-	PRP+
2	M	56	7.9	+	-	PRP+,VH
3	F	42	10.4	+	+	PRP+
4	M	57	12.8	+	+	PRP-
5	M	50	7.9	+	+	PRP+
6	M	75	6.6	+	+	PRP+
7	M	73	6.9	-	-	PRP+,VH
8	M	53	8.0	+	-	PRP+
9	M	70	6.8	+	+	PRP+
10	F	55	6.6	+	-	PRP+
11	M	41	8.1	+	-	PRP+

F, female; HbA1c, haemoglobin A_{1c}; M, male; PRP, panretinal photocoagulation; VH, vitreous haemorrhage.

included topical antibiotics four times per day for at least 7 days, and antiglaucoma medications as needed.

Collecting blood samples

Samples of blood were collected just before the injection, and at 1 day, 7 days and 1 month after the injection of bevacizumab. The blood samples were collected in tubes containing EDTA and were immediately placed on ice. Platelet-poor plasma was prepared by centrifugation (3000 rpm, 20 min) and stored at -80°C before use.

VEGF and PEDF assay

Before the assay, the samples were thawed on ice. The concentration of VEGF in the plasma was measured with an ELISA Kit (Quantkine VEGF ELISA Kit, R&D Systems Inc., Minneapolis, Minnesota, USA) as previously reported^{9 11-14} according to the manufacturer's instructions. This assay uses a quantitative sandwich enzyme immunoassay technique. The PEDF level in the plasma was measured with an ELISA Kit (Chemikine PEDF Sandwich ELISA Kit, Chemicon International, Temecula, California, USA). The samples were diluted in assay diluent, then immediately applied to the assay plates and measured according to the manufacturer's instructions. The concentrations of VEGF and PEDF were determined by measuring the absorbance at 450 nm with a microplate reader (Titertek, Multiscan, Flow Laboratories Inc., Helsinki, Finland), and the values were compared with those obtained with standard dilutions (VEGF: range 0-2000 pg/ml, PEDF: range 0-1.25 ng/ml). The background absorbance was subtracted from all values.

Statistical analyses

The results are expressed as means (SEM), and the significance of any differences was determined by repeated-measures analysis of variance by ranks with Tukey's multiple comparison test. A p value <0.05 was accepted as significant.

RESULTS

The mean VEGF concentration in the plasma of controls was 92.0 (13.5) (mean (SEM), range 0-172.8) pg/ml. The mean VEGF concentration of diabetic patients in the plasma before the intravitreal injection of bevacizumab was 114.0 (25.3) (range 41.4-351.1) pg/ml. It was significantly decreased after 1 day to 9.7 (3.7) (range 0-42.6) pg/ml (p<0.001) and after 7 days to 11.7 (2.4) (range 0.5-27.5) pg/ml (p<0.001). Even after 1 month, the VEGF level was significantly decreased to 25.9 (7.9) (range 0-91.4) pg/ml (p<0.001) and was still lower than that of the initial levels (figure 1, table 2).

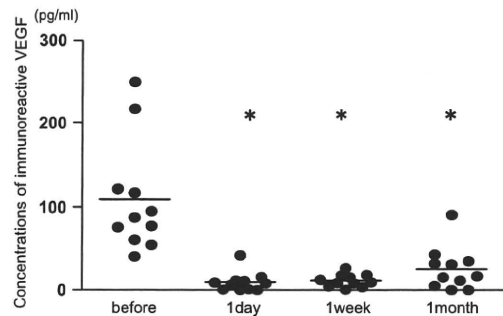


Figure 1 Plasma levels of VEGF before and after an intravitreal injection of bevacizumab. The mean VEGF concentration in the plasma before the intravitreal injection of bevacizumab was 114.0 pg/ml. It was significantly decreased after 1 day to 9.7 pg/ml (p<0.001) and after 7 days to 11.7 pg/ml (p<0.001). Even after 1 month, the VEGF level was significantly decreased to 25.9 pg/ml (p<0.001) and was still lower than that of the initial level. * = p<0.001.

The mean PEDF concentration in the plasma of controls was 3.9 (0.3) (range 0.9-7.6) µg/ml (p<0.001). The mean PEDF concentration in the plasma of diabetic patients before the intravitreal injection of bevacizumab was 7.2 (0.3) (range 4.9-9.3) µg/ml (p<0.001). It was significantly decreased to 5.8 (0.4) (range 4.0-8.4) µg/ml (p<0.001) after 1 day and to 5.8 (0.5) (range 3.5-8.5) µg/ml (p<0.01) after 7 days. After 1 month, the PEDF level was 6.3 (0.6) (range 3.2-9.4) µg/ml (p>0.05). It was still lower than that of initial level, but the difference was not significant (figure 2, table 3).

DISCUSSION

Bevacizumab is a human monoclonal antibody that binds to all isoforms of VEGF. Although experimental data on primates suggested that the full-length antibody might not penetrate the internal limiting membrane of the retina,¹⁵ recent studies have shown that the full-length antibody did penetrate into the rabbit¹⁶ and monkey retina¹⁷ within 24 h.

A significant improvement of the visual acuity and a resolution of neovascular vessels have been reported after an intravitreal injection of bevacizumab in eyes with increased intravitreal levels of VEGF—for example, neovascular glaucoma, diabetic retinopathy, age-related macular degeneration, macular oedema in associated with diabetic retinopathy and retinal vein occlusion.⁶⁻¹¹

With the increasing use of bevacizumab for VEGF-mediated retinal diseases, it is important to know the VEGF levels in various tissues and its clearance after an intravitreal injection. After an intravitreal injection of bevacizumab, the VEGF levels in the aqueous have been shown to decrease in patients with diabetic retinopathy^{9 10} and choroidal neovascularisation.¹¹

Table 2 Concentrations of immunoreactive VEGF in plasmas

	n	Mean	SEM	Median	25th Percentile	75th Percentile	p Value*
Control	30	92.0	13.5	77.8	35.9	148.8	
DM before	11	114.0	25.3	95.3	70.9	125.3	
After 1 day	11	9.7	3.7	8.1	1.0	11.3	<0.001
After 1 week	11	11.7	2.4	9.8	6.5	16.9	<0.001
After 1 month	11	25.9	7.9	17.4	8.4	34.3	<0.001

Concentrations of VEGF are in pictograms of immunoreactive VEGF per millilitre of sample. *Two-sided exact repeated-measures analysis of variance by ranks with Tukey's multiple comparison test. A p value was comparison of after versus before an injection in the group of diabetes mellitus. DM, group of diabetes mellitus.

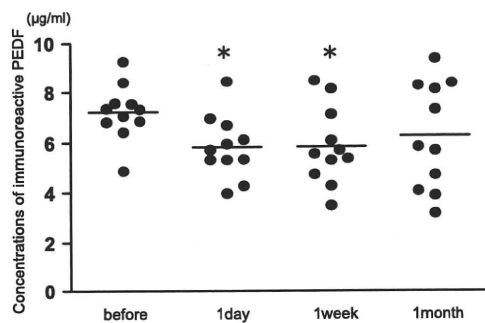


Figure 2 Plasma levels of PEDF before and after intravitreal injection of bevacizumab. The mean PEDF concentration in the plasma before the intravitreal injection of bevacizumab was 7.2 µg/ml. It was significantly decreased after 1 day to 5.8 µg/ml ($p < 0.001$) and after 7 days to 5.8 µg/ml ($p < 0.001$). After 1 month, the PEDF level was 6.3 µg/ml ($p > 0.05$). It was still lower than that of the initial level, but it was not significantly different. *= $p < 0.001$.

In humans, intravitreal bevacizumab (1.25 mg) is estimated to have a half-life of 6.7 days in the vitreous, and vitreous levels of free VEGF were negatively correlated with the bevacizumab concentration.¹⁸ Krohne *et al*¹⁹ reported that the aqueous half-life of 1.5 mg intravitreally injected bevacizumab was 9.82 days.

Although the VEGF levels and clearance of bevacizumab after an intravitreal injection have been reported for human eyes,^{9–11 18–20} to the best of our knowledge, published data are not available on the VEGF concentrations in blood before and after intravitreal bevacizumab in a human case series. In this study, we found a significant decrease of VEGF in the plasma after the intravitreal injection of bevacizumab at 1 day, 7 days and even at 1 month in patients with diabetic retinopathy. These results strongly indicate that intravitreally injected bevacizumab passes into the general blood circulation where it acts to decrease the level of VEGF.

Sawada *et al*¹³ reported that after an intravitreal injection of bevacizumab in one eye, the VEGF concentrations in the aqueous humour of the contralateral eye were not decreased. Thus, they suggested that the effect would be minimal or none on the contralateral eye. However, there is a report that the elimination of bevacizumab from the aqueous humour and serum were parallel with half-time values of 4.88 and 6.86 days after the intravitreal injection of bevacizumab in rabbits.²¹ Bakri *et al*²¹ reported that very small amounts of bevacizumab were detected in the fellow uninjected eye. In addition, Avery *et al*⁸ reported that some patients with bilateral proliferative diabetic retinopathy had regression of neovascularisation in both eyes when bevacizumab was injected intravitreally in only one eye. Their report also support our results that intravitreally injected bevacizumab can pass into the general blood circulation and result in a decrease in the levels of VEGF in the blood.

Table 3 Concentrations of immunoreactive PEDF in plasmas

	n	Mean	SEM	Median	25th Percentile	75th Percentile	p Value*
Control	30	3.9	0.3	3.9	3.1	4.7	
DM before	11	7.2	0.3	7.3	6.8	7.6	
After 1 day	11	5.8	0.4	5.7	5.3	6.4	<0.001
After 1 week	11	5.8	0.5	5.6	5.0	6.6	<0.001
After 1 month	11	6.3	0.6	5.8	4.4	8.2	>0.05

Concentrations of PEDF are in micrograms of immunoreactive PEDF per millilitre of sample. *Two-sided exact repeated-measures analysis of variance by ranks with Tukey's multiple comparison test. A p value was comparison of after versus before an injection in the group of diabetes mellitus.

Heiduschka *et al*¹⁷ and Julien *et al*²² reported that after an intravitreal injection of bevacizumab in the primate eye, bevacizumab quickly penetrated into the retina, choroid, retinal veins and optic nerve. Immunoreactivity for bevacizumab was most prominent on day 1 after the injection.²² In addition, ¹²⁵I-labelled bevacizumab was detected in the blood 1 day after the intravitreal injection and remained relatively stable until day 7.¹⁷ Bevacizumab penetrated quickly into the iris, anterior chamber angle and ciliary body after an intravitreal injection in the primate eye and accumulates particularly in the blood vessel walls.^{17 22} Our results showed that the blood level of VEGF was markedly reduced as early as 1 day after the intravitreal injection of bevacizumab.

Taken together, these findings indicate that intravitreally injected bevacizumab does penetrate into the retina, choroid, intraocular blood vessels and aqueous and quickly enters the general blood circulation. Bevacizumab then lowers the level of VEGF in the blood.

In addition to the VEGF levels, we measured the PEDF levels in the plasma after the intravitreal injection of bevacizumab. PEDF in plasma of controls (3.9 µg/ml) was lower than that of diabetic patients before intravitreal injections of bevacizumab (7.2 µg/ml). These data are coincident with previous reports that presented the plasma PEDF level in diabetic patients was significantly higher than that in controls, and the level was especially high in patients with proliferative diabetic retinopathy.^{23 24} We found that the PEDF levels were significantly reduced at 1 day and 1 week after the injection of bevacizumab. On the other hand, Chan *et al*¹¹ reported that an intravitreal injection of bevacizumab increased the PEDF levels in the aqueous of patients with choroidal neovascularisation secondary to age-related macular degeneration or pathologic myopia. Our results on the PEDF levels disagree with their findings. The difference may be because of differences in the patients and samples. They measured samples of aqueous humour in patients with choroidal neovascularisation, whereas we measured the samples of blood in patients with diabetic retinopathy.

Administration of PEDF has been shown to effectively inhibit retinal neovascularisation.⁴ PEDF can counteract the VEGF-induced vascular permeability²⁵ and suppress the VEGF-induced leukostasis.²⁶ These findings indicated that PEDF acts as an inhibitor of VEGF function. Ohno-Matsui *et al*²⁷ reported that VEGF up-regulates the PEDF expression by VEGFR-1 in human retinal pigment epithelial cells. Zhang *et al*²⁸ reported that PEDF inhibits the expression of VEGF at the transcriptional level, and in contrast to the findings of Ohno-Matsui *et al*,²⁷ VEGF significantly downregulated PEDF expression in retinal capillary endothelial cells, suggesting a VEGF receptor-mediated process. The exact mechanism for the interaction between VEGF and PEDF expression is still unknown. The mechanism of the decrease in PEDF concentration in the blood after bevacizumab injection is uncertain, but it would reflect the VEGF levels.

It has recently been reported that bevacizumab is not toxic to retinal ganglion cells after repeated intravitreal injections.²⁹ Therefore, repeated intravitreal injections of bevacizumab might be safe for the retina. We do not know how much of the intravitreally injected bevacizumab passes through the eye to the general circulation. However, only a small amount of bevacizumab—for example, 1.25 mg/0.05 ml of a single injection, was enough to significantly reduce the VEGF levels in the blood and its effects lasted for at least 1 month. Thus, we suppose that with repeated injections of bevacizumab, its effect may last longer and the revascularisation will be delayed after cardiac infarct and arteriosclerosis obliterans as a result. Further studies

with larger samples and longer follow-up will be necessary to determine the general effects.

In conclusion, although general complications have been reported to be rare after an intravitreal injection of bevacizumab, we should carefully examine patients for systemic changes especially those with multiple injections of bevacizumab.

Acknowledgements This study was supported in part by a Grant-in Aid for Scientific Research from the Ministry of Education in Japan.

Competing interests None.

Patient consent Obtained.

Ethics approval This study was conducted with the approval of the institutional review committee of the Kansai Medical University.

Provenance and peer review Not commissioned; externally peer reviewed.

REFERENCES

1. **Adamis P**, Miller W, Bernal T, et al. Increased vascular endothelial growth factor levels in the vitreous of eyes with proliferative diabetic retinopathy. *Am J Ophthalmol* 1994;**118**:445–50.
2. **Aiello P**, Avery L, Arrigg G, et al. Vascular endothelial growth factor in ocular fluid of patients with diabetic retinopathy and other retinal disorders. *N Engl J Med* 1994;**331**:1480–7.
3. **Dawson DW**, Volpert OV, Gillis P, et al. Pigment epithelium-derived factor: a potent inhibitor of angiogenesis. *Science* 1999;**285**:245–8.
4. **Stellmach V**, Crawford SE, Zhou W, et al. Prevention of ischemia-induced retinopathy by the natural ocular antiangiogenic agent pigment epithelium-derived factor. *Proc Natl Acad Sci U S A* 2001;**98**:2593–7.
5. **Aiello P**, Pierce A, Foley D, et al. Suppression of retinal neovascularization in vivo by inhibition of vascular endothelial growth factor (VEGF) using soluble VEGF-receptor chimeric proteins. *Proc Natl Acad Sci U S A* 1995;**92**:10457–61.
6. **Avery L**, Pieramici J, Rabena D, et al. Intravitreal bevacizumab (Avastin®) for neovascular age-related macular degeneration. *Ophthalmology* 2006;**113**:363–72.
7. **Rosenfeld J**, Fung E, Puliafito A. Optical coherence tomography findings after an intravitreal injection of bevacizumab (Avastin) for macular edema from central retinal vein occlusion. *Ophthalmic Surg Lasers Imaging* 2005;**36**:336–9.
8. **Avery L**, Pearlman J, Pieramici J, et al. Intravitreal bevacizumab (Avastin) in the treatment of proliferative diabetic retinopathy. *Ophthalmology* 2006;**113**:1695–705.
9. **Sawada O**, Kawamura H, Kakinoki M, et al. Vascular endothelial growth factor in aqueous humor before and after intravitreal injection of bevacizumab in eyes with diabetic retinopathy. *Arch Ophthalmol* 2007;**125**:1363–6.
10. **Matsuyama K**, Ogata N, Jo N, et al. Levels of vascular endothelial growth factor and pigment epithelium derived factor in eyes before and after Intravitreal Injection of bevacizumab. *Jpn J Ophthalmol* 2009;**53**:243–8.
11. **Chan WM**, Lai TY, Chan KP, et al. Changes in aqueous vascular endothelial-derived factor levels following intravitreal bevacizumab injections for choroidal

- neovascularization secondary to age-related macular degeneration or pathologic myopia. *Retina* 2008;**28**:1308–13.
12. **Arimura N**, Otsuka H, Yamakiri K, et al. Vitreous mediators after intravitreal bevacizumab or triamcinolone acetonide in eyes with proliferative diabetic retinopathy. *Ophthalmology* 2009;**116**:921–6.
13. **Sawada O**, Kawamura H, Kakinoki M, et al. Vascular endothelial growth factor in fellow eyes of eyes injected with intravitreal bevacizumab. *Graefes Arch Clin Exp Ophthalmol* 2008;**246**:1379–81.
14. **Nonobe NI**, Kachi S, Kondo M, et al. Concentration of vascular endothelial growth factor in aqueous humor of eyes with advanced retinopathy of prematurity before and after intravitreal injection of bevacizumab. *Retina* 2009;**29**:579–85.
15. **Mordenti J**, Thomsen K, Licko V, et al. Intraocular pharmacokinetics and safety of a humanized monoclonal antibody in rabbits after intravitreal administration of a solution or a PLGA microsphere formulation. *Toxicol Sci* 1999;**52**:101–6.
16. **Shahar J**, Avery L, Heilweil G, et al. Electrophysiologic and retinal penetration studies following intravitreal injection of bevacizumab. *Retina* 2006;**26**:262–9.
17. **Heiduschka P**, Fietz H, Hofmeister S, et al. Penetration of bevacizumab through the retina after intravitreal injection in the monkey. *Invest Ophthalmol Vis Sci* 2007;**48**:2814–23.
18. **Zhu Q**, Ziemssen F, Henke-Fahle S, et al. Vitreous levels of bevacizumab and vascular endothelial growth factor-A in patients with choroidal neovascularization. *Ophthalmology* 2008;**115**:1750–5.
19. **Krohne TU**, Eter N, Holz FG, et al. Intraocular pharmacokinetics of bevacizumab after a single intravitreal injection in human. *Am J Ophthalmol* 2008;**146**:508–12.
20. **Beer PM**, Wong SJ, Hammad AM, et al. Vitreous levels of unbound bevacizumab and unbound vascular endothelial growth factor in two patients. *Retina* 2006;**26**:871–6.
21. **Bakri SJ**, Snyder MR, Reid JM, et al. Pharmacokinetics of intravitreal bevacizumab (Avastin). *Ophthalmology* 2007;**114**:855–9.
22. **Julien S**, Heiduschka P, Hofmeister S, et al. Immunohistochemical localisation of intravitreally injected bevacizumab at the posterior pole of the primate eye: implication for the treatment of retinal vein occlusion. *Br J Ophthalmol* 2008;**92**:1424–8.
23. **Ogata N**, Matsuoka M, Matsuyama K, et al. Plasma concentration of pigment epithelium-derived factor in patients with diabetic retinopathy. *J Clin Endocrinol Metab* 2007;**92**:1176–9.
24. **Matsuyama K**, Ogata N, Matsuoka M, et al. Relationship between pigment epithelium-derived factor (PEDF) and renal function in patients with diabetic retinopathy. *Mol Vis* 2008;**14**:992–6.
25. **Liu H**, Ren G, Cooper L, et al. Identification of the antivasopermeability effect of pigment epithelium-derived factor and its active site. *Proc Natl Acad Sci U S A* 2004;**101**:6605–10.
26. **Matsuoka M**, Ogata N, Minamino K, et al. Leukostasis and pigment epithelium-derived factor in rat models of diabetic retinopathy. *Mol Vis* 2007;**29**:1058–65.
27. **Ohno-Matsui K**, Yoshida T, Uetama T, et al. Vascular endothelial growth factor upregulates pigment epithelium-derived factor expression via VEGFR-1 in human retinal pigment epithelial cells. *Biochem Biophys Res Commun* 2003;**303**:962–7.
28. **Zhang X**, Wang J, Gao G, et al. Pigment epithelium-derived factor downregulates vascular endothelial growth factor (VEGF) expression and inhibits VEGF-VEGF receptor 2 binding in diabetic retinopathy. *J Mol Endocrinol* 2006;**37**:1–12.
29. **Cheng CK**, Peng PH, Tien LT, et al. Bevacizumab is not toxic to retinal ganglion cells after repeated intravitreal injection. *Retina* 2009;**29**:306–12.

Two-Year Visual Results for Older Asian Women Treated With Photodynamic Therapy or Bevacizumab for Myopic Choroidal Neovascularization

YASUSHI IKUNO, YOSHIMI NAGAI, SATOSHI MATSUDA, AKIKO ARISAWA, KENICHIRO SHO, TAKASHI OSHITA, KANJI TAKAHASHI, YASUTAKA UCHIHORI, AND FUMI GOMI

• **PURPOSE:** To compare the long-term visual and anatomic outcome of treatment with photodynamic therapy (PDT) or intravitreal bevacizumab (IVB; Avastin; Genentech Inc, South San Francisco, California, USA) for choroidal neovascularization attributable to pathologic myopia (mCNV).

• **DESIGN:** An open-label, interventional case series.

• **METHODS:** SETTING: Multi-institutional. PATIENTS: Thirty-one eyes of Japanese women who received either PDT or IVB for mCNV. Inclusion criteria were age 50 years or older, greatest linear dimension (GLD) 1200 to 3000 μm , and baseline best-corrected visual acuity (BCVA) 20/200 to 20/40. INTERVENTION PROCEDURES: Patients received either PDT or IVB (1 mg/40 μL) throughout the study, with re-treatment when necessary. MAIN OUTCOME MEASURES: BCVA and visual gain/loss at 3, 6, 12, 18, and 24 months after the initial treatment.

• **RESULTS:** Age, BCVA, location of CNV, refractive error, and symptom duration at baseline did not differ significantly between groups. BCVA was significantly improved at 3 to 12 months ($P < .05$); however, the significance was lost at 18 and 24 months in the IVB group. The PDT group showed no significant improvement within the first year, and vision slowly worsened after 12 months, becoming significantly worse at 18 and 24 months compared to baseline ($P < .01$). BCVA was significantly higher in the IVB group at 6 months ($P < .05$), and 12 months or further ($P < .01$). Visual gain was significantly greater in the IVB group at 6, 12, 18, and 24 months ($P < .05$ for 6, 18, and 24 months and $P < .01$ for 12 months).

• **CONCLUSIONS:** These findings indicate that the effects of PDT and IVB have a different time course, and that IVB provides a significantly better BCVA than PDT for mCNV over the long-term. (*Am J Ophthalmol* 2010;149:140–146. © 2010 by Elsevier Inc. All rights reserved.)

Accepted for publication Aug 6, 2009.

From the Department of Ophthalmology, Osaka University Medical School, Osaka, Japan (Y.I., F.G.); Department of Ophthalmology, Kansai Medical University, Hirakata, Japan (Y.N., A.A., K.S., K.T.); Department of Ophthalmology, Osaka Dental University, Osaka, Japan (Y.N.); and Department of Ophthalmology, Osaka General Medical Center, Osaka, Japan (S.M., T.O., Y.U.).

Inquiries to Yasushi Ikuno, Department of Ophthalmology E7, Osaka University Medical School, 2-2 Yamadaoka, Suita 565-0871, Japan; e-mail: ikuno@ophthal.med.osaka-u.ac.jp

HIGH MYOPIA, GENERALLY DEFINED AS A REFRACTIVE error (RE) of -6 diopters (D) or greater, is very common in Europe, in Asia, and in some ethnic groups in the United States.^{1–4} Myopia is a major cause of visual impairment in many countries.^{5–8} Choroidal neovascularization (CNV) is a major myopia-related vision-threatening disease attributable to progressive and irreversible central chorioretinal atrophy. A recent prospective study revealed that more than 90% of patients with myopia-related CNV (mCNV) have vision worse than 20/200 5 to 10 years after disease onset,⁹ indicating the importance of developing effective treatment options for mCNV.

Photocoagulation with thermal burn was first introduced as a treatment for mCNV, especially for extrafoveal cases.¹⁰ The coagulated scar usually expands over time, and the resulting progressive central scotoma is a major concern.¹¹ Thereafter, photodynamic therapy (PDT) using verteporfin was introduced. A prospective, randomized clinical trial, the VIP Study, reported that the visual outcome following PDT treatment was significantly better than that of placebo group at both 3 months and 1 year.¹² The significant benefit was lost after 2 years, suggesting that PDT has only a short-term benefit.¹³

Vascular endothelial growth factor (VEGF) has a critical role in CNV development, because VEGF transgenic mice expressing photoreceptors that are driven by a rhodopsin promoter develop CNV.¹⁴ This finding led us to hypothesize that anti-VEGF treatment would be useful to shrink CNV and subsequently improve vision. Bevacizumab (Avastin; Genentech Inc, South San Francisco, California, USA) is a monoclonal mouse antibody for human VEGF that is currently used for various retinal diseases, such as diabetic retinopathy, idiopathic CNV, age-related macular degeneration, and retinal vaso-occlusive diseases.^{15–18} Intravitreal bevacizumab (IVB), first introduced in 2007, for mCNV,^{19,20} has become a major treatment option for the disease. There are several reports of the 1-year results of treatment with IVB.^{21–23} All of these reports, however, are case series studies that lack controls, making it difficult to evaluate the potential therapeutic effect of IVB as a treatment for mCNV.

Here, we report the long-term (2-year) results of a retrospective interventional multicenter study evaluating

the treatment outcomes between patients who received IVB or PDT.

PATIENTS AND METHODS

• **PATIENT SELECTION:** Thirty-one eyes of 31 consecutive female patients who received PDT or IVB for newly developed mCNV in the Department of Ophthalmology of Osaka University Hospital (Suita, Japan), Kansai Medical University (Hirakata Japan), Osaka Dental University (Osaka, Japan), or Osaka General Medical Center (Osaka, Japan) were included in the study. Patient records were retrospectively reviewed for information such as age, gender, symptom duration, refractive error, axial length, treatment choice, history, pre- and posttreatment best-corrected visual acuity (BCVA), and results of color fundus photography, fluorescein angiography (FA), and all other necessary information. Patient eligibility criteria were as follows: 1) active subfoveal or juxtafoveal CNV associated with pathologic myopia, defined as a RE of -6 D or greater and an axial length of 26.5 mm or longer, and treated with either PDT or IVB; 2) no history of previous treatment for mCNV, such as photocoagulation, PDT, or IVB; 3) no triamcinolone acetonide sub-Tenon treatment²⁴ within the previous 6 months; 4) baseline BCVA between 20/200 and 20/40; 5) baseline greatest linear dimension (GLD) between 1200 and 3000 μm ; and 6) women at least 50 years of age. Exclusion criteria included: 1) history of vitrectomy or intraocular surgery other than cataract surgery; 2) presence of macular hole, retinal detachment, foveoschisis; 3) severe cataract obscuring the fundus; 4) symptom duration of more than 24 months; and 5) significant glaucoma detected by visual field loss.

• **TREATMENT CHOICE:** Treatment was selected following discussion with the patients. All relevant explanations regarding the benefits, risks, and complications were described, and agreement of patients and doctors, as well as informed consent, was obtained at this time. Retinal specialists performed all the diagnostic and interventional procedures. Because IVB is off-label, the approval of the Institutional Review Board was obtained from each of the hospitals. In Japan, PDT became available in May 2004 and IVB became available in October 2005. The initial treatment period was between May 2004 and October 2006 for the PDT group, and between October 2005 and October 2006 for the IVB group in the present study. Therefore, only PDT was available from May 2004 to September 2005, and both PDT and IVB were available after October 2005.

• **TREATMENT PROCEDURES:** Standard PDT was applied according to the VIP Study with a verteporfin (Visudyne; Novartis AG, Basel, Switzerland) infusion.¹² Spot size was set at $+1000$ μm greater than the GLD.

IVB was performed as previously described.²¹ For the IVB injection, 1 mg of bevacizumab (Avastin) was injected via the pars plana using aseptic techniques. Antibiotic eye drops were applied for 1 week after the bevacizumab injection.

• **TREATMENT SCHEDULE, FOLLOW-UP, AND RETREATMENT:** *Photodynamic Therapy.* After the initial PDT, patients were examined every month for the first 3 months, and thereafter FA was performed to confirm the CNV regression. When the CNV persisted, the PDT was repeated, but the interval between each treatment was at least 3 months. Once the CNV was no longer active, patients were examined every 1 to 3 months. BCVA was measured and OCT examination was performed at every visit. FA was performed if recurrent mCNV was suspected based on the appearance of subretinal or intraretinal fluid, new hemorrhage, or significant visual loss (2 lines or more). If persistent or recurrent dye leakage was observed in FA, patients were re-treated.

Intravitreal Bevacizumab. The IVB regimen was described previously²¹ and was similar to the PDT regimen. After the initial IVB, the patients were examined every month for the first 3 months. If persistent subretinal fluid was observed in OCT images, IVB was repeated until it resolved. Thereafter, FA was performed to confirm the CNV regression 3 months after the initial IVB. When the CNV persisted, the IVB treatment was repeated. Once the CNV was no longer active, patients were examined every 1 to 3 months. BCVA was measured and OCT examination was performed at every visit. FA was performed if recurrent mCNV was suspected based on the appearance of subretinal or intraretinal fluid, new hemorrhage, or significant visual loss (2 lines or more). If persistent or recurrent dye leakage was observed, patients were retreated with IVB. None of the patients switched treatment modalities during the study.

• **EXAMINATIONS:** BCVA and intraocular pressure was measured, and optical coherence tomography (OCT; Stratus OCT or Cirrus HD-OCT; Carl Zeiss Meditec, La Jolla, California, USA) was performed at every visit by a technician masked to the patient's treatment. The presence/absence of subretinal or intraretinal fluid was evaluated by horizontal B scan. GLD was measured with Imagenet System software (Topcon, Tokyo, Japan) from the digitized baseline FA images. Changes in the FA dye pattern of leakage from the CNV were graded as 1 of 3 types: vanished, diminished, and unchanged/increased. FA was graded by 3 of the authors (Y.I., Y.N., and S.M.). Myopic chorioretinal atrophy was graded as previously described by Avila and associates²⁵ and evaluated by 3 of the authors (Y.I., Y.N., and S.M.), similar to FA.

• **ENDPOINTS:** The efficacy of IVB and PDT was evaluated based on BCVA at 1, 3, 6, 12, 18, and 24 months after the initial treatment, as well as BCVA gain at each time point as the primary outcome. The treatment number, changes in FA findings after treatment, and rate of serious adverse events were also compared as secondary outcome measures.

• **STATISTICAL ANALYSIS:** BCVA was converted to the logarithm of minimal angle of resolution (logMAR) scale. Statistical evaluation was performed using JMP software version 7.0 (SAS Inc, Cary, North Carolina, USA). A stepwise regression analysis was performed to investigate the factors predictive of BCVA as well as visual improvement after IVB at 24 months. Visual outcome is affected by baseline visual acuity (VA). Therefore, the difference in visual outcome between the 2 groups was also compared using an analysis of covariance (ANCOVA) after adjusting for the baseline BCVA. A *P* value of less than .05 was considered significant.

RESULTS

• **PATIENT CHARACTERISTICS:** Thirty-one eyes (18 right eyes, 13 left eyes) of 31 female patients were eligible for the study. Twenty eyes were treated with PDT (PDT group), and 11 were treated with IVB (IVB group). Mean \pm standard deviation (SD) age was 67.0 ± 7.0 years, ranging from 53 to 79 years. Mean symptom duration was 5.7 ± 4.8 months, ranging from 1 to 20 months. Twenty were phakic, 11 were pseudophakic, and there were no aphakic eyes. The mean \pm SD spherical equivalent RE was -9.8 ± 5.0 D, ranging from -1.5 to -17.5 D, including pseudophakic eyes. Mean \pm SD GLD was 2054 ± 456 μm , ranging from 1327 to 2984 μm . The degree of myopic atrophy according to Avila's classification was as follows: M1 in 4 eyes, M2 in 13 eyes, M3 in 4 eyes, M4 in 8 eyes, and M5 in 2 eyes.

• **BASELINE COMPARISON:** Baseline characteristics of patients in both groups are shown in Table 1. There were no significant differences in age, symptom duration, RE, lens status, CNV size, myopic chorioretinal atrophy grading, CNV location, or pretreatment BCVA between the 2 groups.

• **VISUAL OUTCOME: Baseline Comparison.** The mean logMAR values of both groups at each time point are shown in Table 2. BCVA was significantly better ($P < .05$) in the IVB group than in the PDT group after 6 to 24 months. In the IVB group, BCVA was significantly better than baseline at 1, 3, 6, and 12 months after treatment ($P < .05$ by paired *t* test), but not at 18 months ($P = .29$) or 24 months ($P = .38$). In the PDT group, there was no visual improvement at 1 and 3 months ($P = .65$ and $P = .61$, respectively). Thereafter, the BCVA began to slowly

decrease. The mean logMAR value was not different from baseline at 6 and 12 months ($P = .41$ and $P = .09$, respectively). BCVA continued to decrease throughout the second year, and at 18 and 24 months was significantly worse than at baseline ($P < .01$ for both).

Comparison Between Groups. The logMAR change from baseline in both groups is shown in Figure 1. Mean logMAR improved by 0.13 at 1 month after IVB treatment, and this improvement was maintained until the final follow-up at 24 months. BCVA tended to improve for 3 months after PDT treatment, but then began to decrease after 3 months, and this trend continued until the end of the follow-up period. The mean logMAR gain/loss was similar between groups at 1 ($P = .08$) and 3 ($P = .29$) months after treatment; the gain was significantly greater in the IVB group at 6 ($P < .05$), 12 ($P < .01$), 18 ($P < .05$), and 24 months ($P < .05$).

After 24 months, in the IVB group 4 eyes (36%) significantly improved (≥ 3 lines) from the baseline, 2 (18%) worsened (≥ 3 lines), and 5 (45%) were unchanged. In the PDT group, 4 eyes (20%) worsened and 16 (80%) were unchanged.

Parallel Plot Analysis. Figure 2 is a parallel plot that shows the trend in visual changes over the follow-up period for all the patients. BCVA in the PDT group seemed to cluster around 0, whereas BCVA in the IVB group seemed to vary more over time.

Stepwise Analysis. To identify the factors that most critically affected the final visual outcome, we performed a stepwise linear regression analysis. The factors with the greatest influence on VA at 24 months were treatment choice ($P < .01$), followed by myopic chorioretinal atrophy ($P = .07$). For the final visual improvement at 24 months, pretreatment GLD had the greatest effect ($P < .01$), then treatment choice ($P < .05$) and myopic atrophy grading ($P = .05$). Thus, treatment choice was a critical factor for both final BCVA and final visual changes, together with myopic chorioretinal atrophy.

• **ANALYSIS OF COVARIANCE:** ANCOVA revealed that the 24-month mean logMAR of the IVB group was significantly better than that of the PDT group ($P < .01$) by 0.35 logMAR units when adjusted for pretreatment logMAR level.

• **ANGIOGRAPHIC RESULTS AND RETREATMENTS:** Post-treatment FA revealed that in the PDT group the fluorescein leakage from the CNV vanished in 13 eyes (65%), diminished in 6 (30%), and increased in 1 (5%). In the IVB group, fluorescein leakage vanished in 3 eyes (27%), diminished in 8 (73%), and was unchanged/increased in 0 eyes. This finding was of borderline significance ($P = .05$)

TABLE 1. Baseline Characteristics of 31 Eyes Treated with Intravitreal Bevacizumab or Photodynamic Therapy for Myopic Choroidal Neovascularization

Factors	IVB Group (n = 11)	PDT group (n = 20)	P value
Age (years), mean ± SD	67.8 ± 6.2	66.6 ± 7.5	.63 ^a
Symptom duration (months), mean ± SD	5.5 ± 4.3	5.9 ± 5.2	.81 ^a
Refractive error (D), mean ± SD	-7.8 ± 4.5	-10.9 ± 5.0	.10 ^a
Lens status (n)			
Phakic	6	14	
Pseudophakic	5	6	.32 ^c
CNV size (GLD, μm), mean ± SD	1875 ± 446	2153 ± 442	.10 ^a
Myopic atrophy score (0 to 5), mean ± SD	2.9 ± 1.1	2.3 ± 1.1	.10 ^a
CNV location (sub/juxta/extra)			
Subfoveal	8	18	
Juxtafoveal	3	2	.32 ^b
Pretreatment logMAR value, mean ± SD	0.68 ± 0.29	0.74 ± 0.20	.32 ^a

CNV = choroidal neovascularization; D = diopters; GLD = greatest linear dimension; IVB = intravitreal bevacizumab; logMAR = logarithm of minimal angle resolution; PDT = photodynamic therapy; SD = standard deviation.

^aBy Student *t* test.

^bBy Fisher exact test.

^cBy χ^2 test.

TABLE 2. Mean Logarithm of Minimal Angle Resolution Value of Patients Treated with Either Intravitreal Bevacizumab or Photodynamic Therapy at Various Time Points for up to 2 Years

Time Point	Mean logMAR Value		P value
	IVB Group (n = 11)	PDT Group (N = 20)	
Baseline	0.68 ± 0.29	0.74 ± 0.20	.49
1 month	0.56 ± 0.31	0.76 ± 0.25	.054
3 months	0.54 ± 0.34	0.70 ± 0.34	.19
6 months	0.50 ± 0.34	0.79 ± 0.31	.02 ^a
12 months	0.49 ± 0.29	0.90 ± 0.36	<.01 ^a
18 months	0.56 ± 0.35	0.89 ± 0.24	<.01 ^a
24 months	0.56 ± 0.34	0.92 ± 0.24	<.01 ^a

IVB = intravitreal bevacizumab; logMAR = logarithm of minimal angle of resolution; PDT = photodynamic therapy.

^aSignificant by Student *t* test (two-tailed).

by χ^2 test. The mean ± SD number of PDT treatments was 2.3 ± 1.2 times and that of IVB was 2.9 ± 2.4 times throughout the follow-up. Although the number of required IVB treatments tended to be larger, the difference was not significant ($P = .31$).

• **ADVERSE EVENTS:** A transient visual disturbance was reported in 1 eye in the PDT group, but recovered within a week. None of the patients developed serious adverse events, such as infectious endophthalmitis, subretinal hemorrhage under the fovea, retinal detachment, cardiovascular accident, or death. One eye (5%) developed a subretinal hemorrhage that spared the fovea 2 weeks after

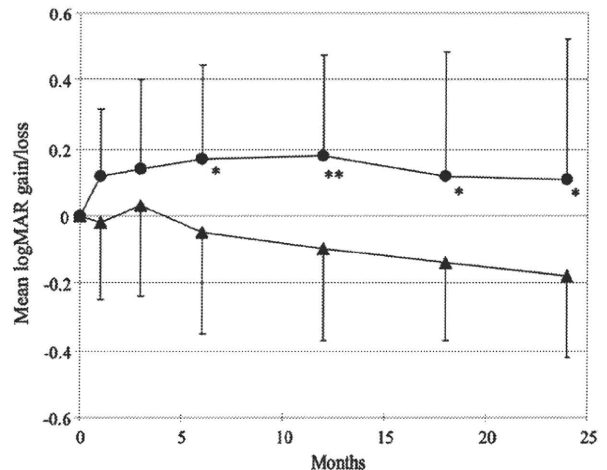


FIGURE 1. Mean logarithm of minimal angle resolution (logMAR) change from baseline at 1, 3, 6, 12, 18, and 24 months after initial treatment for myopic choroidal neovascularization (mCNV) with either intravitreal bevacizumab (IVB; circle) or photodynamic therapy (PDT; triangle). Single asterisk ($P < .05$), and double asterisks ($P < .01$) indicate significant differences between the 2 groups by Student *t* test.

PDT. There was no significant difference between groups in terms of adverse events.

DISCUSSION

INTRAVITREAL BEVACIZUMAB HAS BECOME A MAJOR treatment option for mCNV. A PubMed search using the

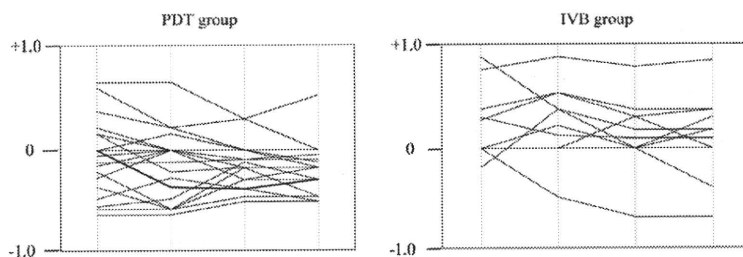


FIGURE 2. Parallel plot analysis representing the time course of the logarithm of minimal angle resolution (log-MAR) gain/loss at 6, 12, 18, and 24 months after initial intravitreal bevacizumab (IVB) or photodynamic therapy (PDT) for myopic choroidal neovascularization (mCNV). Note that the PDT group scores tended to cluster around 0 after treatment, whereas the IVB group scores were more varied.

terms “myopia” and “bevacizumab” produced 20 hits, most of which were case reports or case series lacking control groups, and there has been no strong evidence of a visual benefit from IVB for mCNV. This is the first report comparing IVB and PDT after a 2-year follow-up, and the findings indicate that IVB was superior to PDT.

The efficacy of PDT for mCNV remains controversial, especially over the long-term. The VIP Study, a prospective randomized clinical trial of PDT for mCNV, reported a significant beneficial effect of PDT on mCNV within 1 year. The benefit was no longer significant after 2 years, suggesting that patients must be followed up for at least 2 years to confirm the long-term benefit. In the VIP Study, 77 eyes received PDT, and final visual improvement of at least 3 lines was observed in 12% and significant worsening was observed in 26% after 2 years. Similarly, other reports documented significant visual improvement in 19% and 27% of eyes, and visual worsening in 25% and 36% approximately 2 years after PDT.^{26,27} Our data for the PDT group differed from these studies, showing significant improvement in none of the eyes and worsening in 20%, which may be attributable to differences in the inclusion criteria, as discussed in the next paragraph.

The natural course of mCNV is highly dependent on age at onset.²⁸ Final VA is also dependent on age at initial PDT treatment.^{29–31} For example, Axer-Siegel³⁰ reported a significant final visual improvement in 33% of younger patients (<60 years) and in only 6% of older subjects (≥60 years); similarly, significant visual worsening was recognized in 8% of younger subjects and in 50% of older subjects. Also, Montero and associates²⁹ divided subjects that received PDT for mCNV into 2 groups, a younger group (<55 years) and an older group (≥55 years), and reported a significantly different visual outcome between the 2 groups. These reports suggest that age is a critical factor for prognosis in mCNV, and the critical age seems to be around 50 to 60 years. We excluded patients younger than 50 years and those with a CNV smaller than 1200 μm of GLD, because younger patients generally have a good prognosis and small CNV tend to recover naturally.

Our patient inclusion criteria are somewhat different from those in the other reports. In the VIP studies, the

inclusion criteria did not have a minimum CNV size or age limitation. As a result, in the VIP Study the median GLD was 1900 μm, ranging from 480 to 4120 μm, whereas in the present study mean GLD was 2067 μm, ranging from 1327 to 2984 μm. In the VIP Study, 45% of the patients were younger than 50 years of age. Mean age of our patients was 64.8 years, whereas the median age of those in the VIP Study was 51 years. Ergun and associates²⁶ reported the 2-year results of PDT for mCNV in patients with a mean age of 59.7 years. Thus, the other reports tended to include younger subjects, and this may be one reason why our treatment group has slightly worse results compared to other studies with a 2-year follow-up.

The mean number of PDT treatments in the present study was 2.0 times for a 2-year follow-up. This is very similar to Lam and associates²⁷ (1.7 times for 2 years), who treated a similar Asian population of patients. The VIP Study performed 5.1 treatments and Ergun 3.2 treatments throughout the 2-year follow-up period.^{13,26} Several other reports followed patients for only 1 year. As has been suggested, however, the required number of treatments may vary between the first and second year. Also, the effect of PDT may differ according to race because of pigmentation differences. Therefore, the results are not totally comparable.

Because there are no published studies regarding the 2-year results of IVB, it is difficult to compare our results with previous reports. Three reports of 1-year results, including ours, were recently published.^{21–23} We reported the visual outcome of 63 eyes in patients with a mean age of 58 years, and visual improvement of at least 3 lines was obtained in 40% of the patients 1 year after treatment with a mean logMAR gain of 0.23. In the present study, mean logMAR gain at 12 months was 0.19 logMAR units, which is similar to our previous report.²¹ The inclusion/exclusion criteria, however, were not identical because in our previous reports we did not limit CNV size or age, and therefore care must be taken in interpreting and comparing the data. Others^{22,23} reported 20 eyes and 22 eyes with a mean age of 53 and 49 years, respectively. Visual improvement was obtained in 60% (3 lines or better) and 70% (2 lines or better), respectively, 1 year after treatment. The fact that

these studies included younger subjects, however, must be taken into account.

Interestingly, the vision effects in the IVB group and PDT group had different time courses. VA increased immediately after IVB, and this level was essentially maintained until the end of the follow-up period. BCVA was slightly decreased at 18 and 24 months compared to 12 months, and it was no longer significantly different from the baseline. The decrease after the 1-year time point was not as prominent, however, in this group. In contrast, VA began to decrease after the 6-month follow-up in the PDT group, and this decrease continued until the end of the follow-up period. Actually, the final BCVA was significantly worse than that at baseline in the PDT group. Consequently, the difference in BCVA of both groups was not significant until the 12-month time point, but the difference increased with time.

The mean logMAR value was significantly better in the IVB group at 12, 18, and 24 months with a value of 0.36 logMAR units at the final examination, and the logMAR gain was significantly greater at 6, 12, 18, and 24 months. This trend is similar to the time course of the vision effects in the VIP Study. In the VIP Study, PDT improved vision significantly compared to the placebo control, but the effect was lost at 24 months.^{12,13} The profile of the time course of the vision effects also differed somewhat between groups. Visual changes tended to cluster around 0 in the

PDT group, but tended to be more varied in the IVB group. We therefore regard PDT treatment as more of a stabilizing treatment than IVB in that there was less variance in posttreatment BCVA. The reason for this different profile, however, requires further investigation.

The reason for the worsening vision in the PDT group at a later time point was not identified in the present study. In myopic eyes, secondary expanding atrophy is a major concern for the long-term visual outcome following any treatment, which may be one reason for the late visual loss in the PDT group. In other words, secondary atrophic changes may overwhelm the effect of the treatment. This hypothesis is supported by the finding by Krebs and associates³² that an increase in reading acuity at 12 months after PDT for mCNV is partially lost within 36 months.


Intravitreal bevacizumab provided a significantly better visual outcome than PDT for mCNV. This finding, however, suggests that IVB has beneficial effects compared to PDT, but does not necessarily improve the natural course of the disease, because the control was the PDT-treated group. Thus, the efficacy of IVB remains unknown and this is a limitation of this study. Another limitation of this study is that it was not an equally randomized, prospective study. Therefore, there might be some selection bias that affects the potential difference between visual outcome in both groups. The data must be interpreted carefully when comparing the treatment effects.

THE AUTHORS INDICATE NO FINANCIAL SUPPORT OR FINANCIAL CONFLICT OF INTEREST. INVOLVED IN DESIGN AND conduct of study (Y.I., Y.N.); collection of data (S.M., T.O., A.A., K.S.); management (Y.U., K.T., F.G.), analysis (Y.I.), and interpretation of data (Y.I., Y.N., S.M., F.G.); and preparation (Y.I.), review (Y.I., T.N., S.M.), or approval of manuscript (Y.I.). Because photodynamic therapy is not approved in Japan, approval from the Institutional Review Board of each institute (Osaka University Medical School, Kansai Medical University Hospital, and Osaka General Medical Center) was obtained for this research. The data collection conformed to Japanese law. The study was conducted in accordance with the provisions of the Declaration of Helsinki.

REFERENCES

1. Sawada A, Tomidokoro A, Araie M, Iwase A, Yamamoto T; Tajimi Study Group. Refractive errors in an elderly Japanese population: the Tajimi Study. *Ophthalmology* 2008;115:363–370.
2. Cheng CY, Hsu WM, Liu JH, et al. Refractive errors in an elderly Chinese population in Taiwan: the Shihpai Eye Study. *Invest Ophthalmol Vis Sci* 2003;44:4630–4638.
3. Tarczy-Hornoch K, Ying-Lai M, Varma R; Los Angeles Latino Eye Study Group. Myopic refractive error in adult Latinos: the Los Angeles Latino Eye Study. *Invest Ophthalmol Vis Sci* 2006;47:1845–1852.
4. Katz J, Tielsch JM, Sommer A. Prevalence and risk factors for refractive errors in an adult inner city population. *Invest Ophthalmol Vis Sci* 1997;38:334–340.
5. Xu L, Wang Y, Li Y, et al. Causes of blindness and visual impairment in urban and rural areas in Beijing: the Beijing Eye Study. *Ophthalmology* 2006;1134–1141.
6. Iwase A, Araie M, Tomidokoro A, Yamamoto T, Shimizu H, Kitazawa Y; Tajimi Study Group. Prevalence and causes of low vision and blindness in a Japanese adult population: the Tajimi Study. *Ophthalmology* 2006;113:1354–1362.
7. Klaver CC, Wolfs RC, Vingerling JR, et al. Age-specific prevalence and causes of blindness and visual impairment in an older population: the Rotterdam Study. *Arch Ophthalmol* 1998;116:653–658.
8. Cotter SA, Varma R, Ying-Lai M, Azen SP, Klein R; Los Angeles Latino Eye Study Group. Causes of low vision and blindness in adult Latinos: the Los Angeles Latino Eye Study. *Ophthalmology* 2006;113:1574–1582.
9. Yoshida T, Ohno-Matsui K, Yasuzumi K, et al. Myopic choroidal neovascularization: a 10-year follow-up. *Ophthalmology* 2003;110:1297–1305.
10. Pece A, Brancato R, Avanza P, et al. Laser photocoagulation of choroidal neovascularization in pathologic myopia: long-term results. *Int Ophthalmol* 1995;18:339–344.
11. Brancato R, Pece A, Avanza P, Radrizzani E. Photocoagulation scar expansion after laser therapy for choroidal neovascularization in degenerative myopia. *Retina* 1990;10:239–243.
12. Verteporfin in Photodynamic Therapy Study Group. Photodynamic therapy of subfoveal choroidal neovascularization in pathologic myopia with verteporfin. 1-year results

- of a randomized clinical trial—VIP Report No. 1. *Ophthalmology* 2001;108:841–852.
13. VIP Study Group. Verteporfin therapy of subfoveal choroidal neovascularization in pathologic myopia: 2-year results of a randomized clinical trial—VIP Report No. 3. *Ophthalmology* 2003;110:667–673.
 14. Okamoto N, Tobe T, Hackett SF, et al. Transgenic mice with increased expression of vascular endothelial growth factor in the retina: a new model of intraretinal and subretinal neovascularization. *Am J Pathol* 1997;151:281–291.
 15. Mason JO III, Nixon PA, White MF. Intravitreal injection of bevacizumab (Avastin) as adjunctive treatment of proliferative diabetic retinopathy. *Am J Ophthalmol* 2006;142:685–688.
 16. Avery RL, Pieramici DJ, Rabena MD, et al. Intravitreal bevacizumab (Avastin) for neovascular age-related macular degeneration. *Ophthalmology* 2006;113:363–372.
 17. Gomi F, Nishida K, Oshima Y, et al. Intravitreal bevacizumab for idiopathic choroidal neovascularization after previous injection with posterior subtenon triamcinolone. *Am J Ophthalmol* 2007;143:507–510.
 18. Rosenfeld PJ, Fung AE, Puliafito CA. Optical coherence tomography findings after an intravitreal injection of bevacizumab (Avastin) for macular edema from central retinal vein occlusion. *Ophthalmic Surg Lasers Imaging* 2005;36:336–339.
 19. Sakaguchi H, Ikuno Y, Gomi F, et al. Intravitreal injection of bevacizumab for choroidal neovascularisation associated with pathological myopia. *Br J Ophthalmol* 2007;91:161–165.
 20. Yamamoto I, Rogers AH, Reichel E, et al. Intravitreal bevacizumab (Avastin) as treatment for subfoveal choroidal neovascularisation secondary to pathological myopia. *Br J Ophthalmol* 2007;91:157–160.
 21. Ikuno Y, Sayanagi K, Soga K, et al. Intravitreal bevacizumab for choroidal neovascularization attributable to pathological myopia: one-year results. *Am J Ophthalmol* 2009;147:94–100.
 22. Gharbiya M, Allievi F, Mazzeo L, Gabrieli CB. Intravitreal bevacizumab treatment for choroidal neovascularization in pathologic myopia: 12-month results. *Am J Ophthalmol* 2009;147:84–93.
 23. Chan WM, Lai TY, Liu DT, Lam DS. Intravitreal bevacizumab (Avastin) for myopic choroidal neovascularization: 1-year results of a prospective pilot study. *Br J Ophthalmol* 2009;93:150–154.
 24. Kojima A, Ohno-Matsui K, Futagami S, et al. Trans-Tenon's retrobulbar triamcinolone infusion for myopic choroidal neovascularization. *Acta Ophthalmol Scand* 2006;84:749–754.
 25. Avila MP, Weiter JJ, Jalkh AE, et al. Natural history of choroidal neovascularization in degenerative myopia. *Ophthalmology* 1984;91:1573–1581.
 26. Ergun E, Heinzl H, Stur M. Prognostic factors influencing visual outcome of photodynamic therapy for subfoveal choroidal neovascularization in pathologic myopia. *Am J Ophthalmol* 2004;138:434–438.
 27. Lam DS, Chan WM, Liu DT, et al. Photodynamic therapy with verteporfin for subfoveal choroidal neovascularisation of pathologic myopia in Chinese eyes: a prospective series of 1 and 2 year follow-up. *Br J Ophthalmol* 2004;88:1315–1319.
 28. Kojima A, Ohno-Matsui K, Teramukai S, et al. Estimation of visual outcome without treatment in patients with subfoveal choroidal neovascularization in pathologic myopia. *Graefes Arch Clin Exp Ophthalmol* 2006;244:1474–1479.
 29. Montero JA, Ruiz-Moreno JM. Verteporfin photodynamic therapy in highly myopic subfoveal choroidal neovascularisation. *Br J Ophthalmol* 2003;87:173–176.
 30. Axer-Siegel R, Ehrlich R, Weinberger D, et al. Photodynamic therapy of subfoveal choroidal neovascularization in high myopia in a clinical setting: visual outcome in relation to age at treatment. *Am J Ophthalmol* 2004;138:602–607.
 31. Ruiz-Moreno JM, Amat P, Montero JA, Lugo F. Photodynamic therapy to treat choroidal neovascularisation in highly myopic patients: 4 years' outcome. *Br J Ophthalmol* 2008;92:792–794.
 32. Krebs I, Binder S, Stolba U, et al. Choroidal neovascularization in pathologic myopia: three-year results after photodynamic therapy. *Am J Ophthalmol* 2005;140:416–425.



Biosketch

Yasushi Ikuno, MD, graduated from Osaka University Medical School, Japan, in 1990. He completed his residency and retinal fellowship program in Osaka University Hospital from 1990 to 1996. He became an assistant professor of Department of Ophthalmology, Osaka University Medical School in 1997 and has been working for more than 10 years. Currently he is an Associate Professor, and his main research interest is myopia-specific macular diseases and retinal/choroidal imaging.

