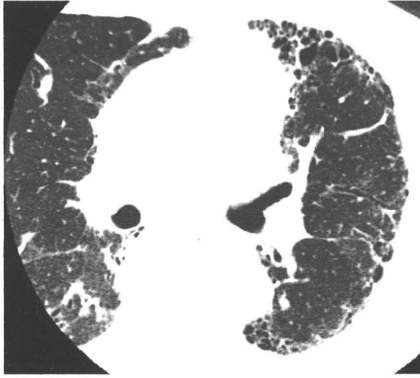


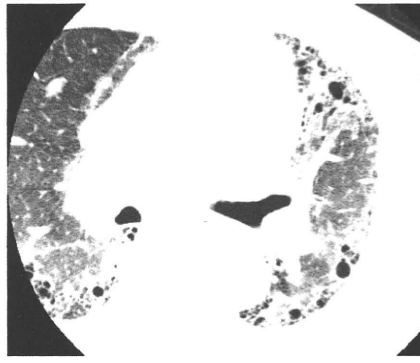
男性

増悪前CT画像



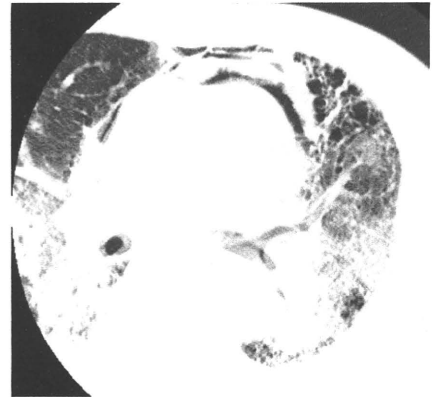
2009/03/18

増悪時CT画像



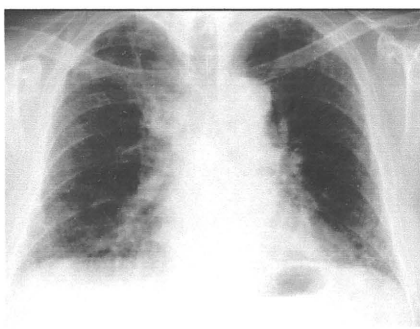
2009/05/11

増悪後CT画像



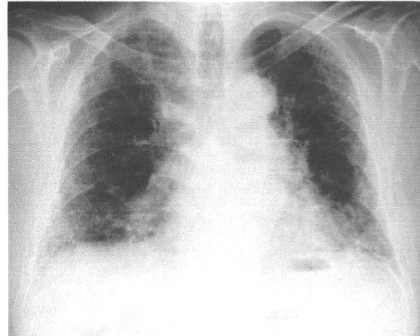
2009/06/12

増悪前XP



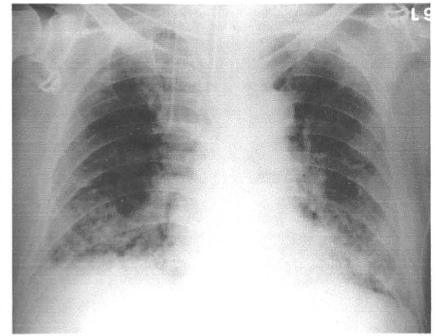
2009/03/18

増悪時XP



2009/05/11

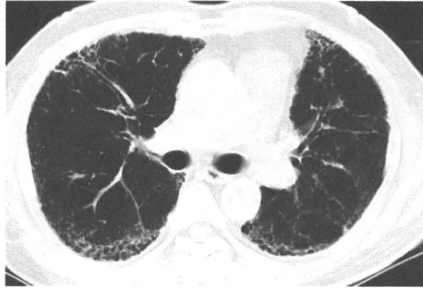
増悪後XP



2009/06/12

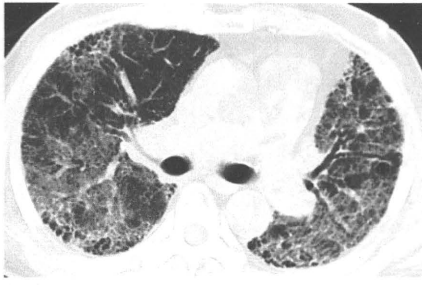男性

増悪前CT画像



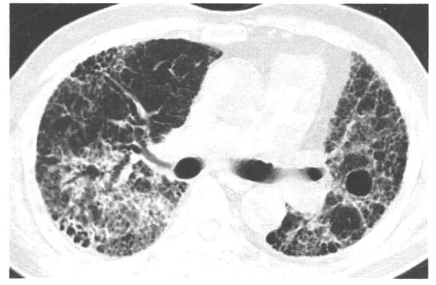2009/02/25

増悪時CT画像



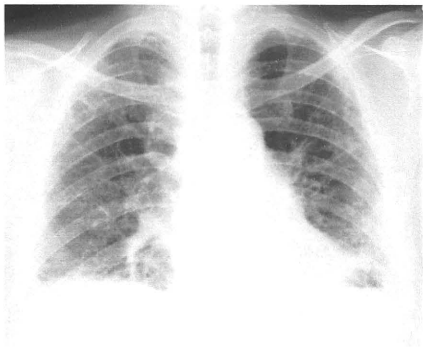
2009/06/13

増悪後CT画像



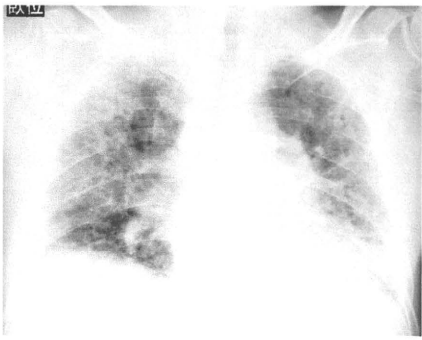
2009/06/23

増悪前XP



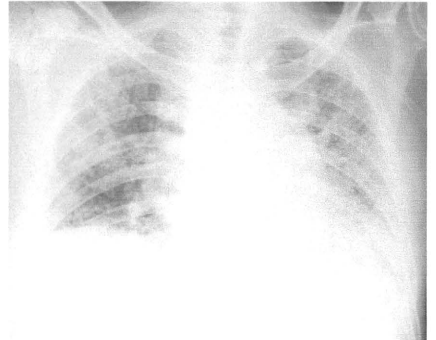
2009/02/25

増悪時XP



2009/06/13

増悪後XP



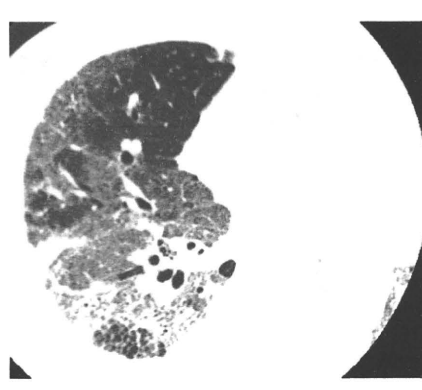
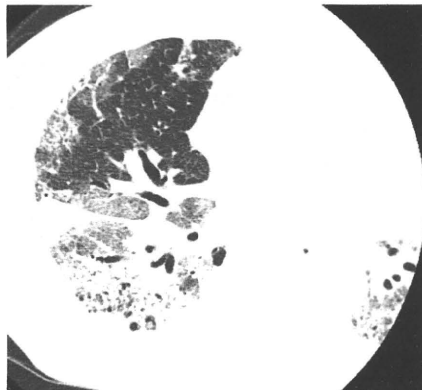
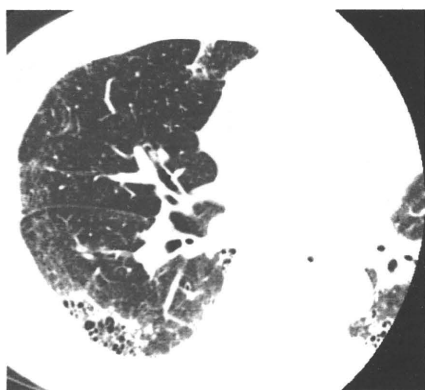
2009/06/24

男性

増悪前CT画像

増悪時CT画像

増悪後CT画像



2009/07/09

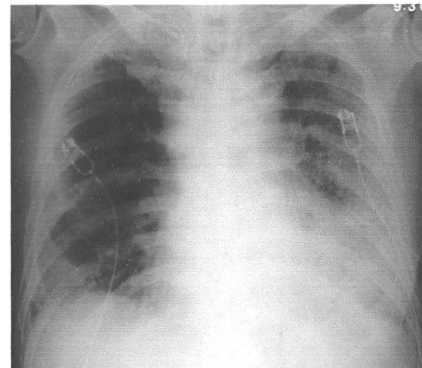
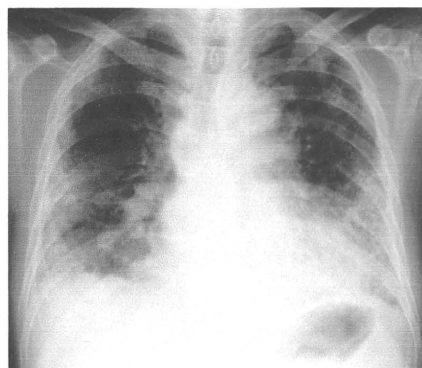
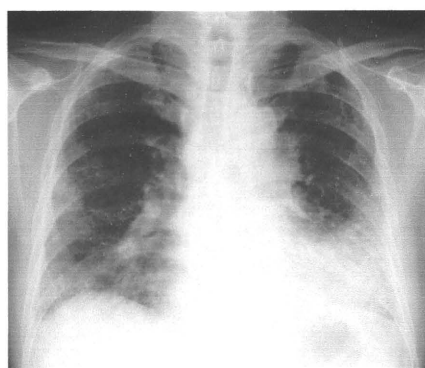
2009/08/03

2009/08/10

増悪前XP

増悪時XP

増悪後XP



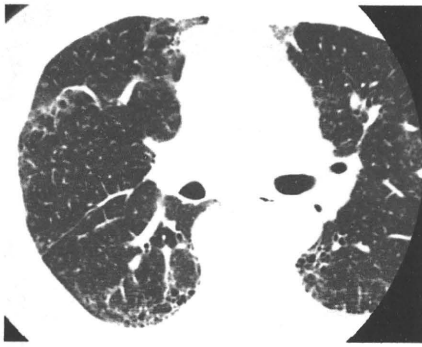
2009/07/09

2009/08/03

2009/08/10

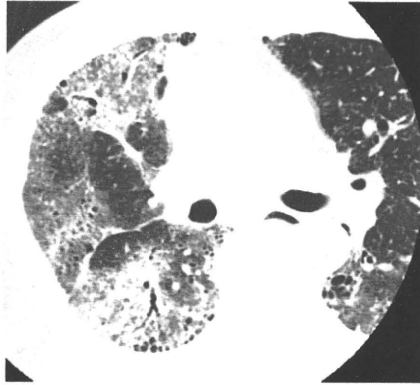
男性

増悪前CT画像



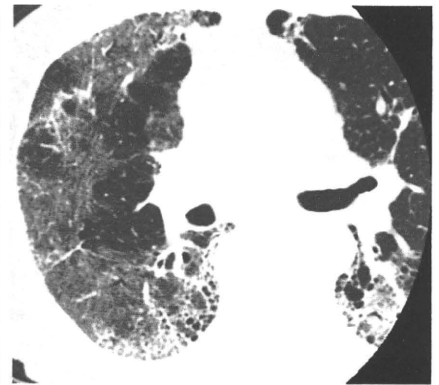
2009/07/14

増悪時CT画像



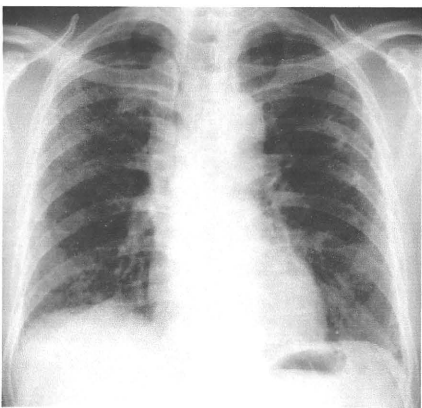
2009/08/11

増悪後CT画像



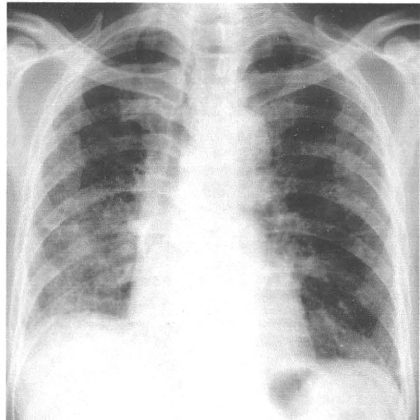
2009/09/11

増悪前XP



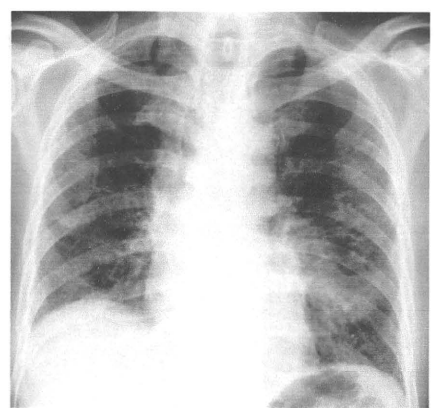
2009/07/28

増悪時XP



2009/08/11

増悪後XP



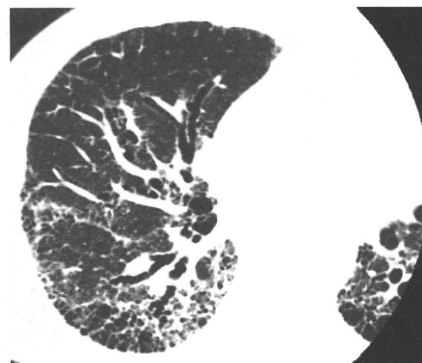
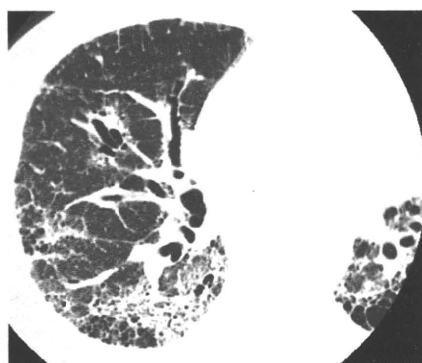
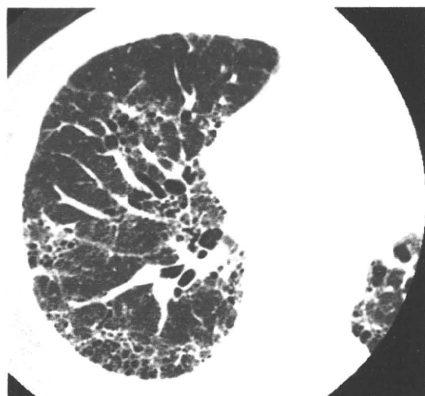
2009/09/11

男性

増悪前CT画像

増悪時CT画像

増悪後CT画像



2009/08/05

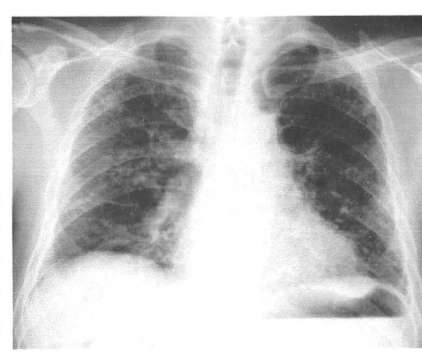
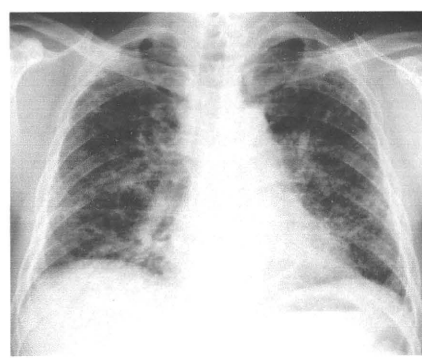
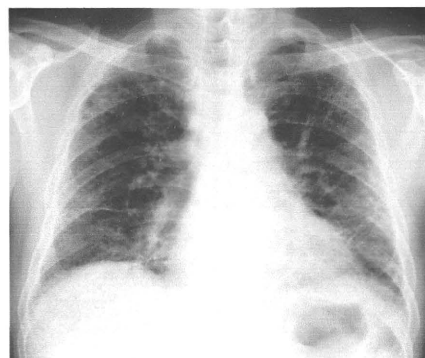
2009/08/19

2009/09/09

増悪前XP

増悪時XP

増悪後XP



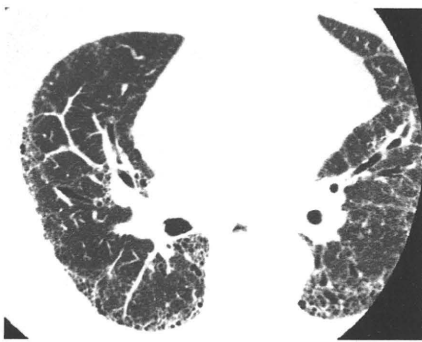
2009/08/05

2009/08/19

2009/09/10

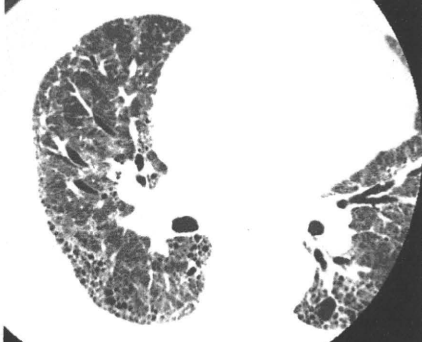
男性

増悪前CT画像



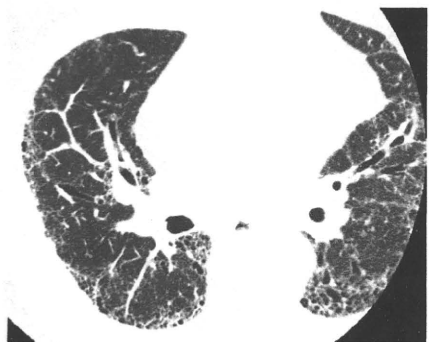2009/06/19

増悪時CT画像



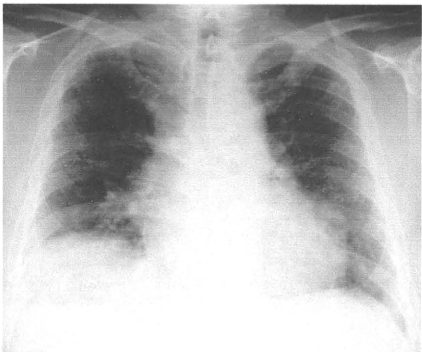
2009/09/15

増悪後CT画像



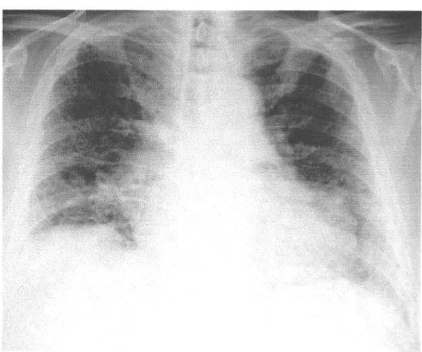
2009/10/13

増悪前XP



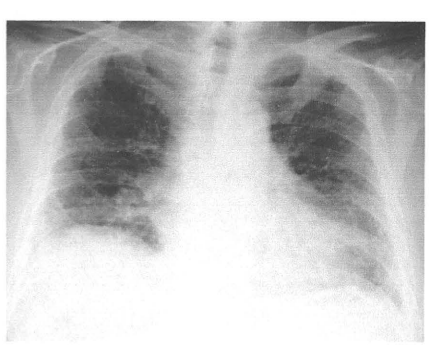
2009/06/19

増悪時XP



2009/09/15

増悪後XP



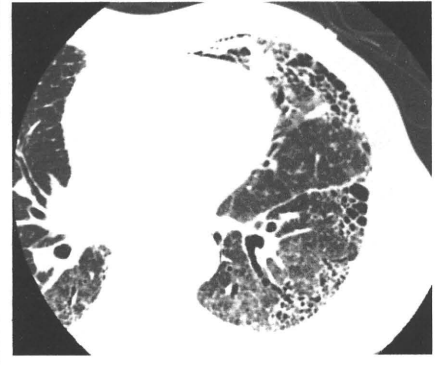
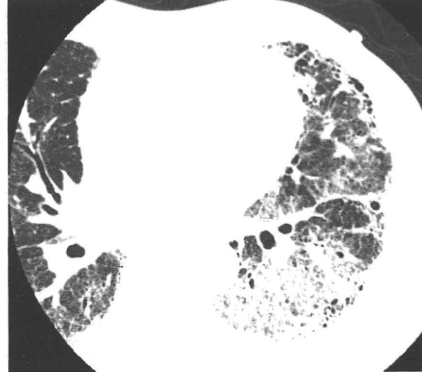
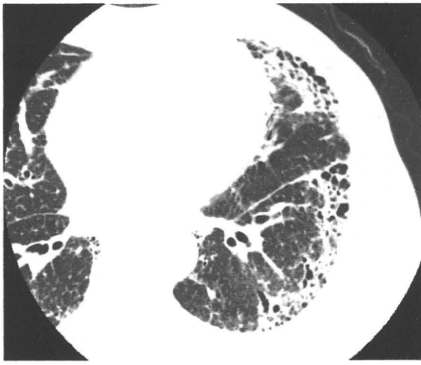
2009/10/13

男性

増悪前CT画像

増悪時CT画像

増悪後CT画像



2009/09/09

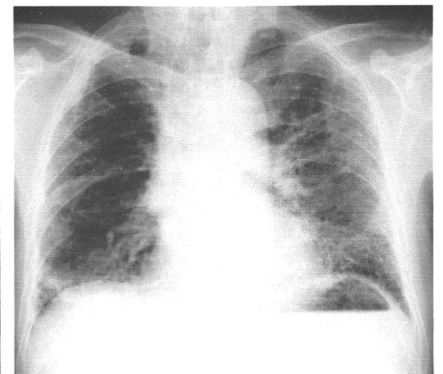
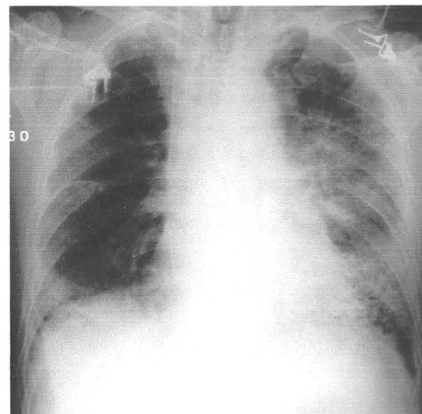
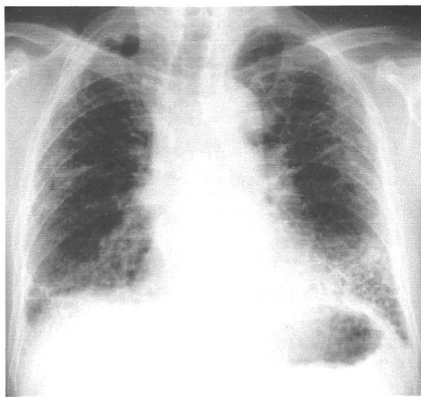
2009/12/03

2010/01/06

増悪前XP

増悪時XP

増悪後XP



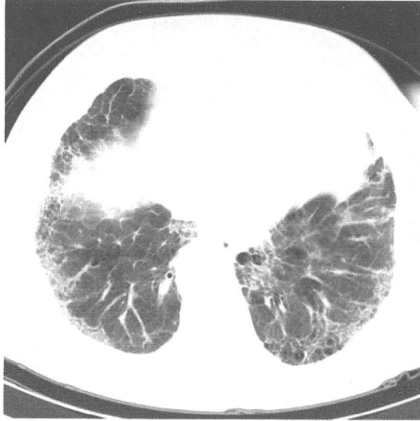2009/10/07

2009/12/03

2010/01/07

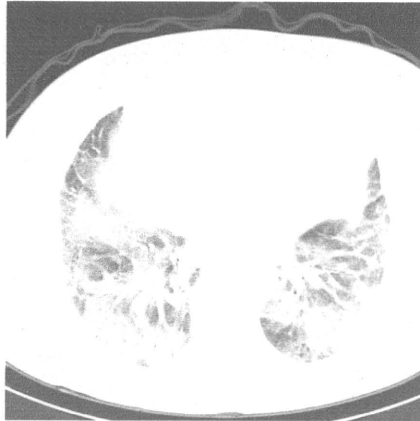
女性

増悪前CT画像



2008/10/29

増悪時CT画像

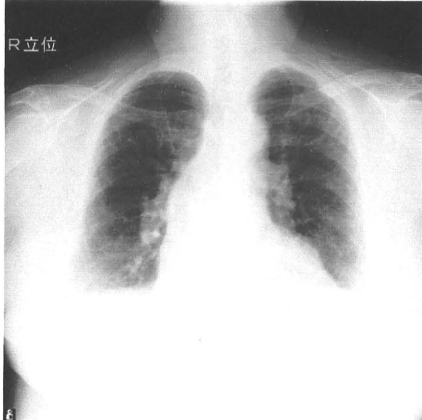


2009/12/05

増悪後CT画像

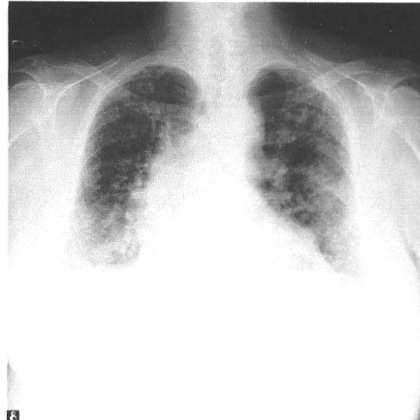
存在せず

増悪前XP



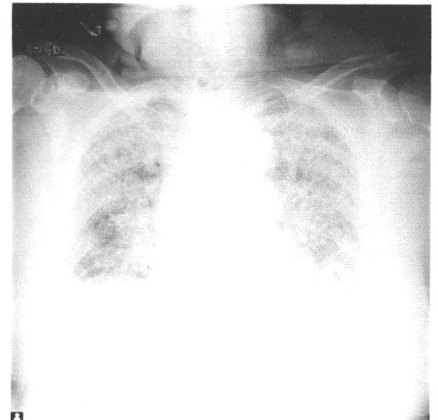
2009/07/29

増悪時XP



2009/12/05

増悪後XP

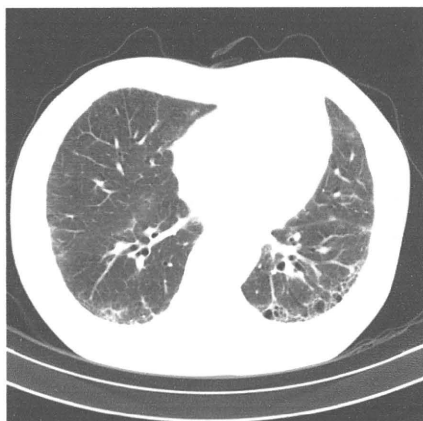

2010/01/02



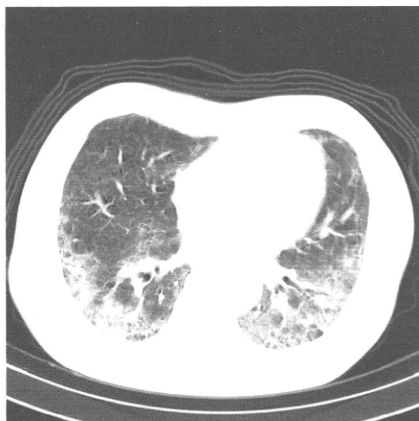男性

増悪前CT画像



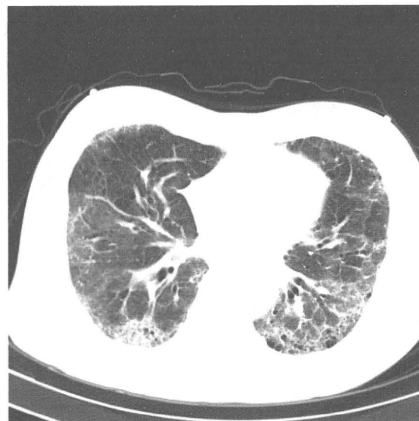2009/08/10

増悪時CT画像



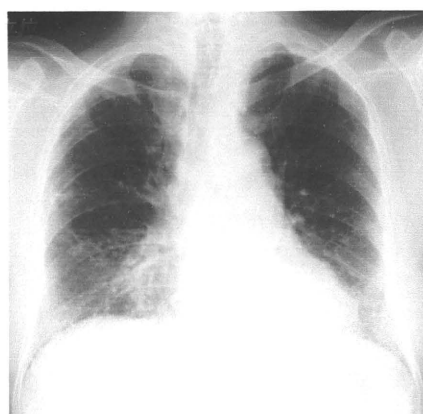
2009/12/07

増悪後CT画像



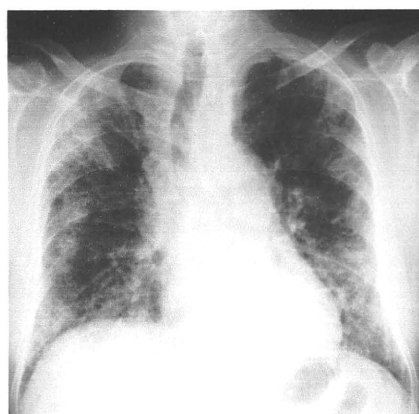
2010/01/19

増悪前XP

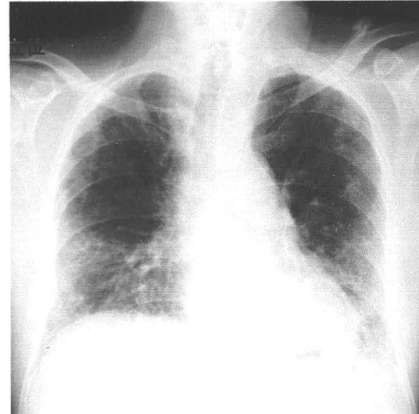


2009/08/10

増悪時XP



増悪後XP



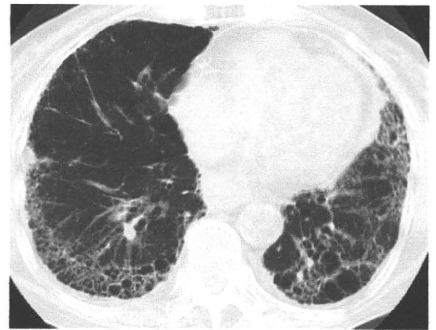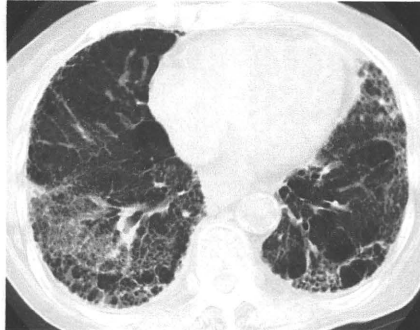
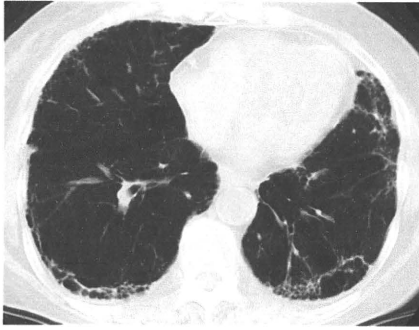
2010/01/22

女性

増悪前CT画像

増悪時CT画像

増悪後CT画像



2008/12/03

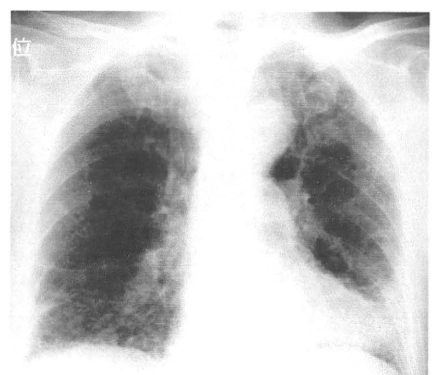
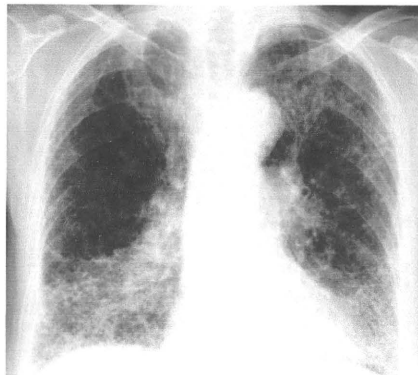
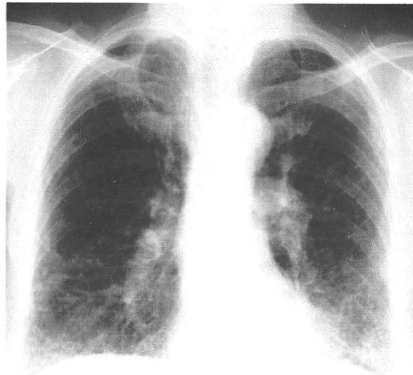
2009/12/02

2010/01/20

増悪前XP

増悪時XP

増悪後XP



2008/12/24

2009/12/02

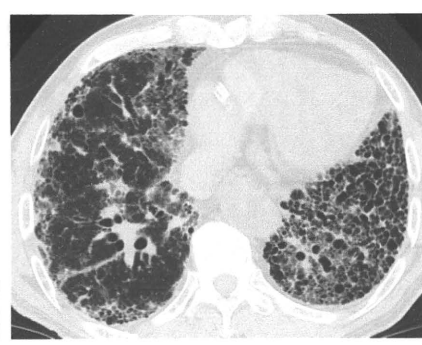
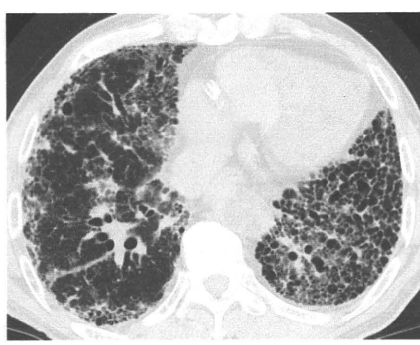
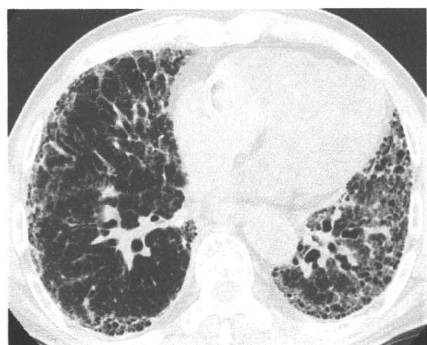2010/01/18

男性

増悪前CT画像

増悪時CT画像

増悪後CT画像



2009/06/12

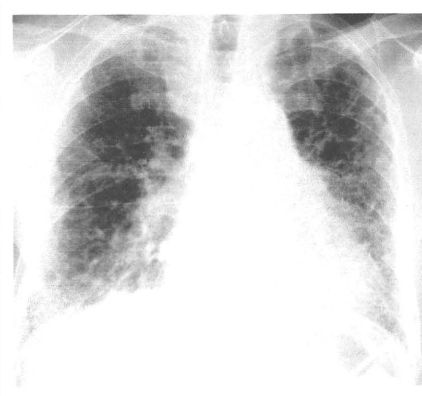
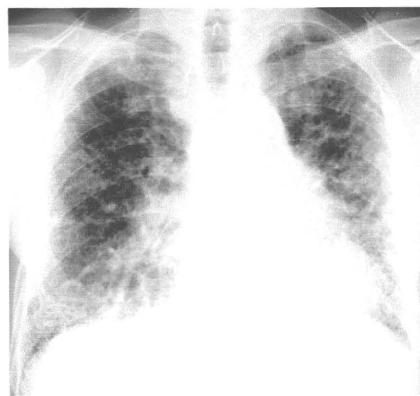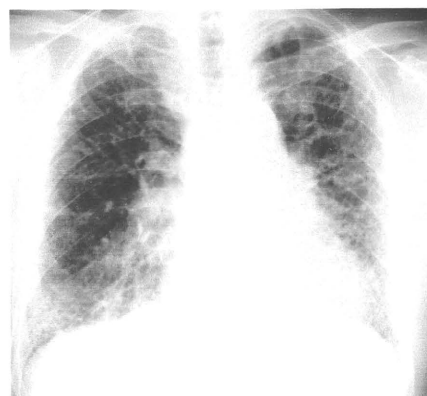
2010/01/04

2010/01/18

増悪前XP

増悪時XP

増悪後XP



2009/06/11

2010/01/04

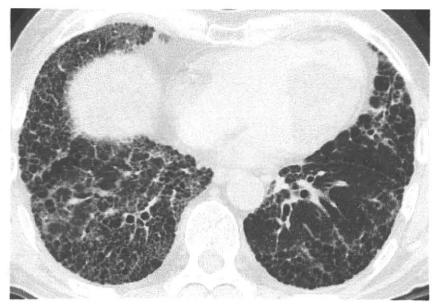
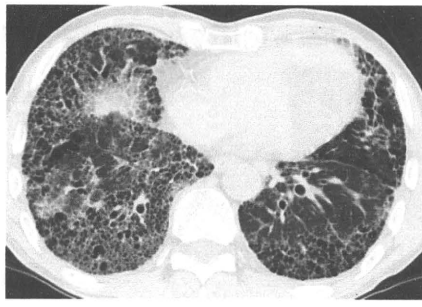
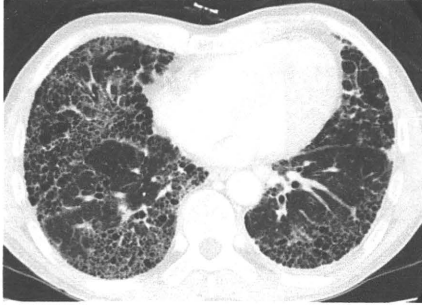
2010/01/18

男性

増悪前CT画像

増悪時CT画像

増悪後CT画像



2009/10/06

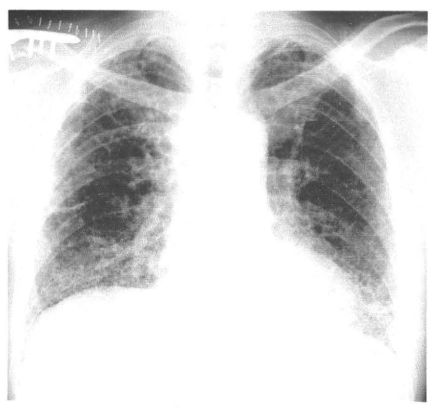
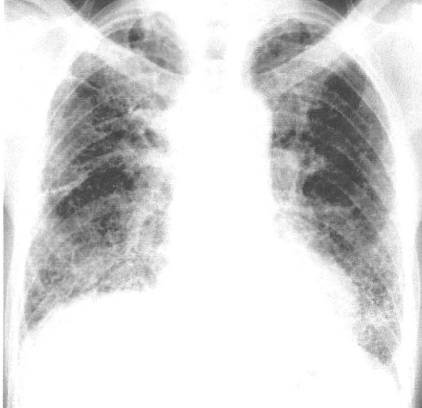
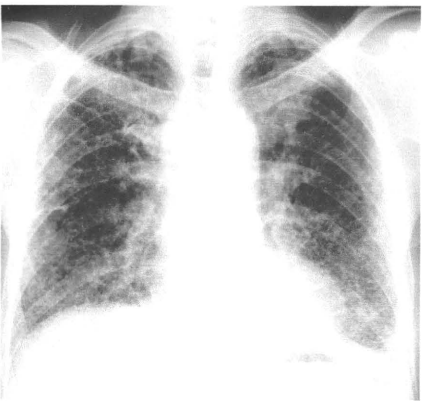
2010/01/04

2010/04/12

増悪前XP

増悪時XP

増悪後XP



2009/10/05

2010/01/04

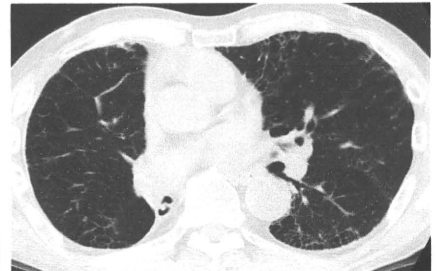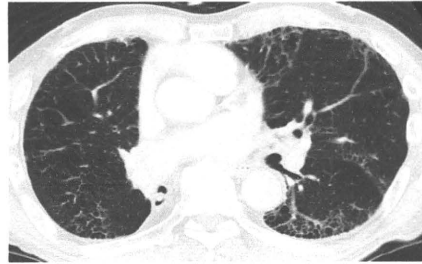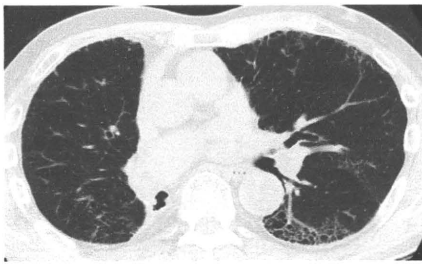
2010/04/12

男性

増悪前CT画像

増悪時CT画像

増悪後CT画像



2009/07/07

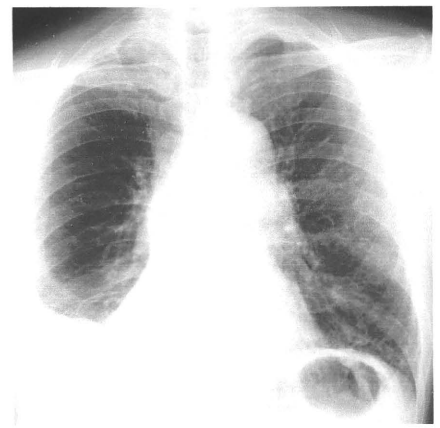
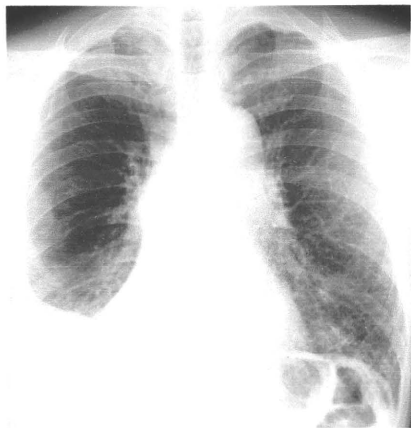
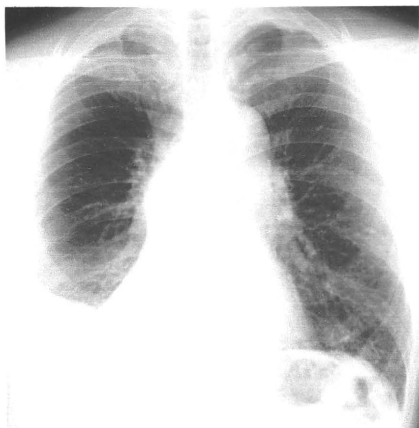
2009/12/25

2010/03/26

増悪前XP

増悪時XP

増悪後XP



2009/04/28

2009/12/24

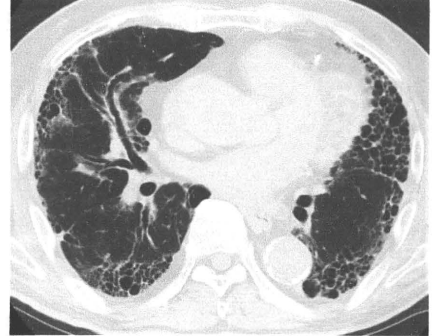
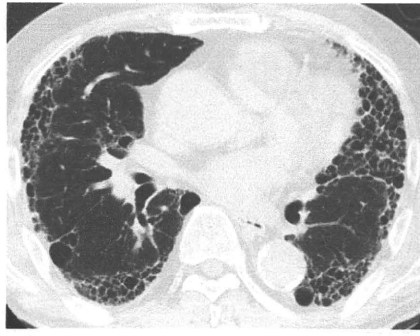
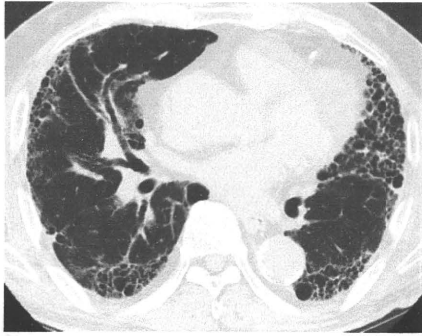
2010/03/26

男性

増悪前CT画像

増悪時CT画像

増悪後CT画像



2009/10/30

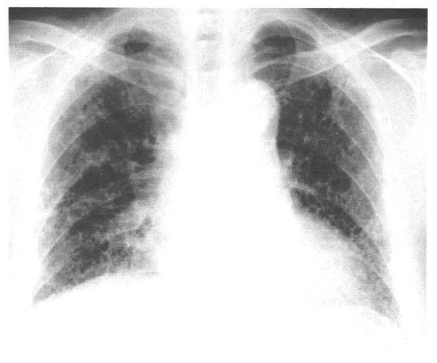
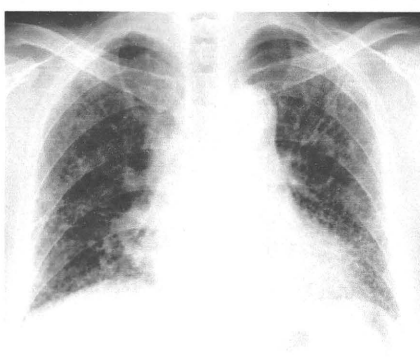
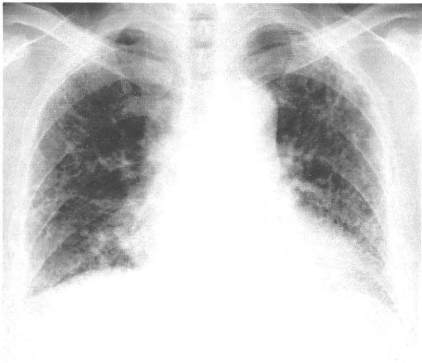
2009/12/25

2010/01/14

増悪前XP

増悪時XP

増悪後XP



2009/10/26

2009/12/25

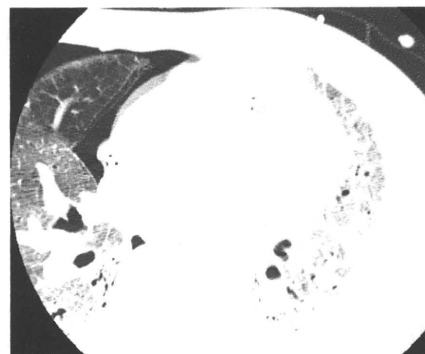
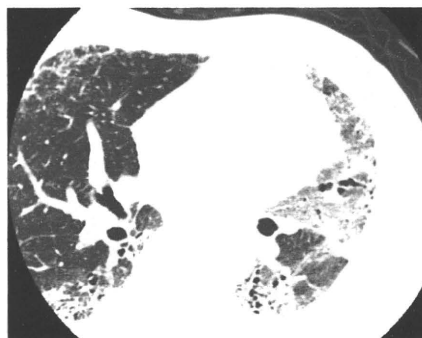
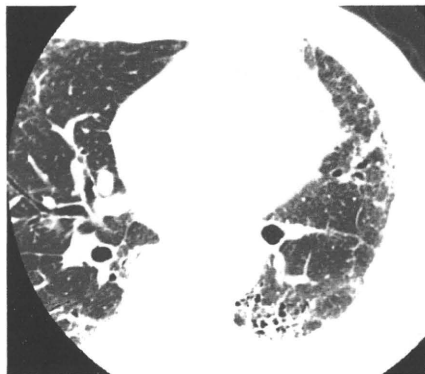
2010/01/14

男性

増悪前CT画像

増悪時CT画像

増悪後CT画像



2009/12/01

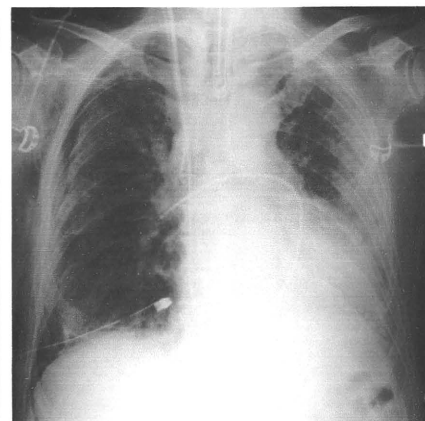
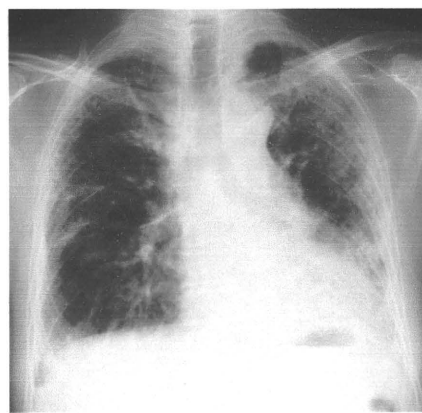
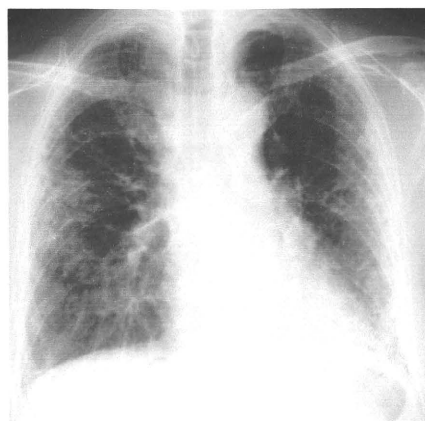
2010/01/19

2010/01/26

増悪前XP

増悪時XP

増悪後XP



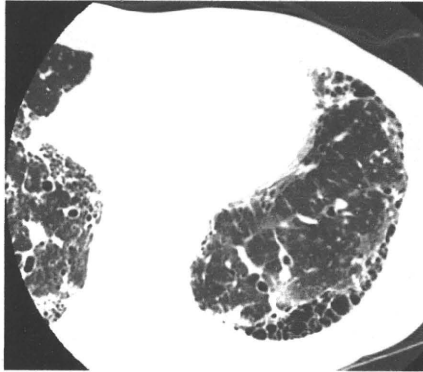
2009/12/01

2010/01/19

2010/01/26

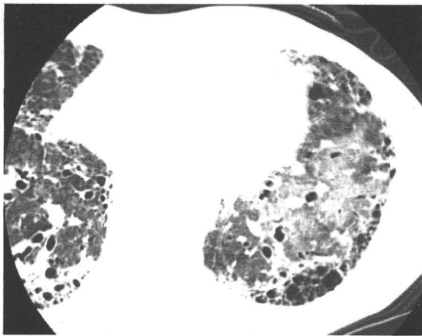
男性

増悪前CT画像



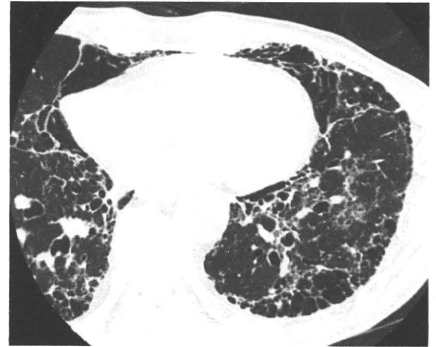2009/12/15

増悪時CT画像



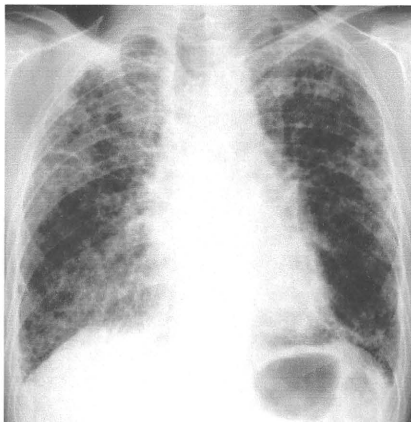
2010/02/08

増悪後CT画像



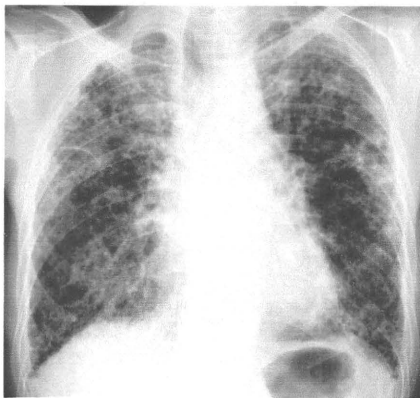
2010/03/01

増悪前XP



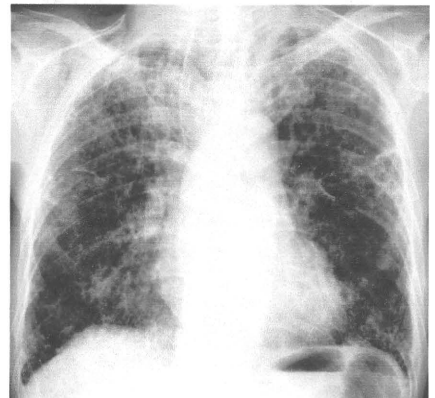
2010/01/12

増悪時XP



2010/02/08

増悪後XP



2010/03/01

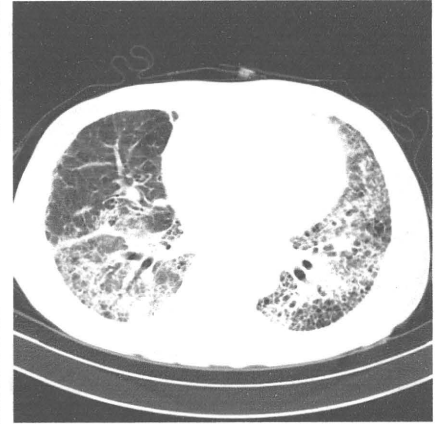
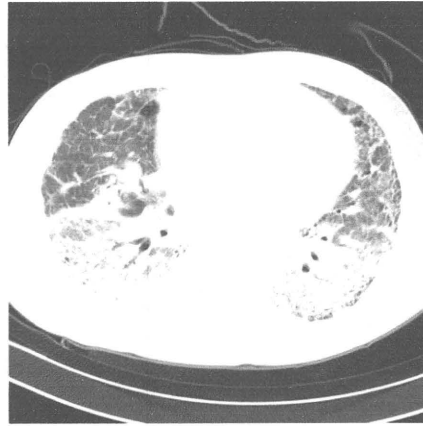


男性

増悪前CT画像

増悪時CT画像

増悪後CT画像



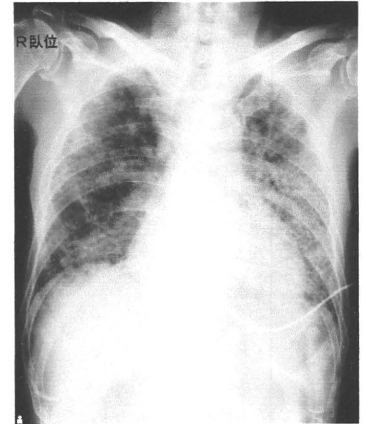
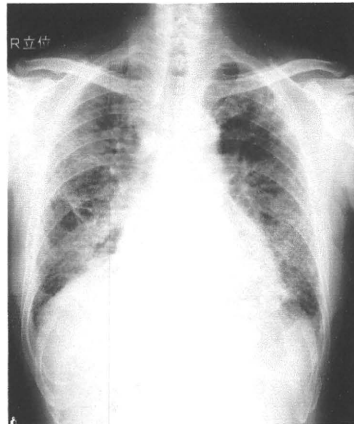
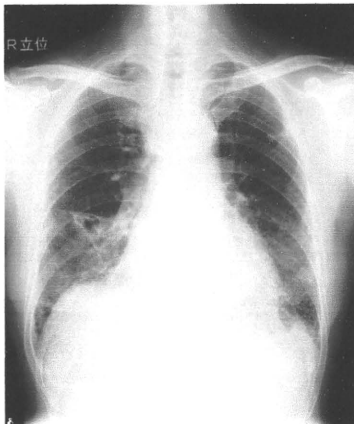
2010/02/03

2010/03/08

増悪前XP

増悪時XP

増悪後XP



2009/12/03

2010/02/03

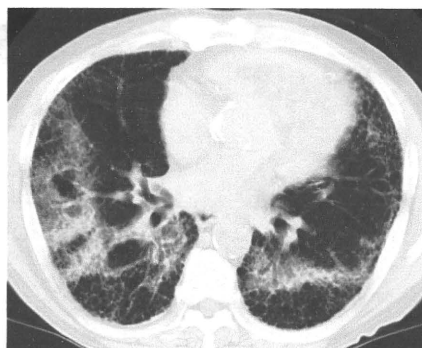
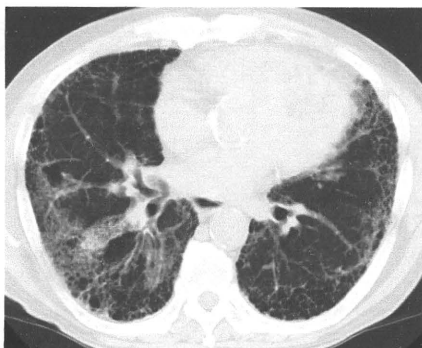
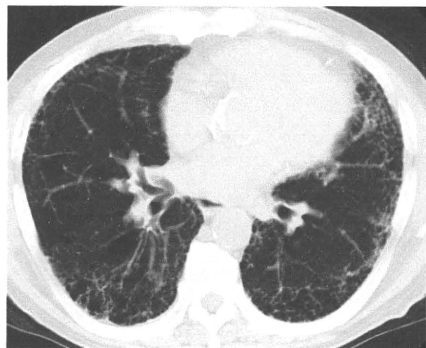
2010/03/08

男性

増悪前CT画像

増悪時CT画像

増悪後CT画像



2009/11/12

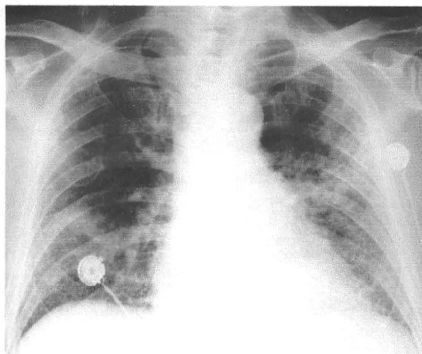
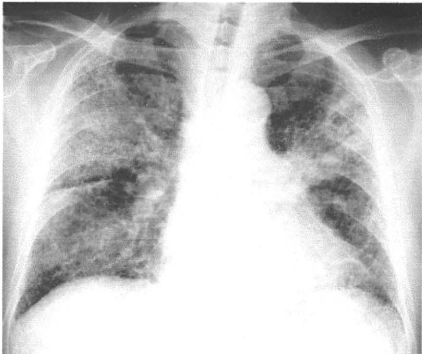
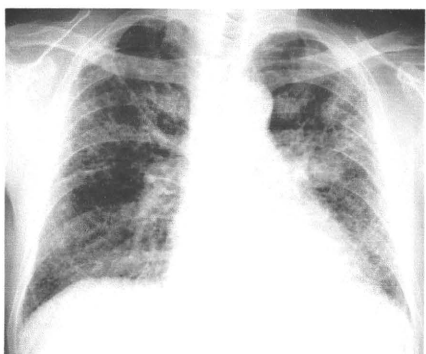
2009/11/15

2009/11/26

増悪前XP

増悪時XP

増悪後XP



2009/11/12

2009/11/15

2009/11/26

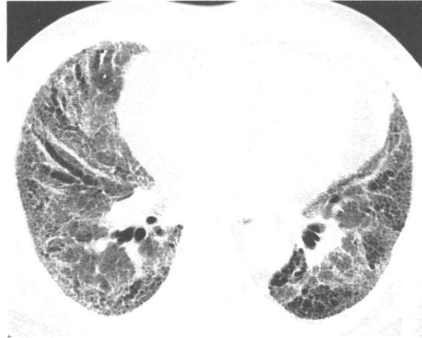
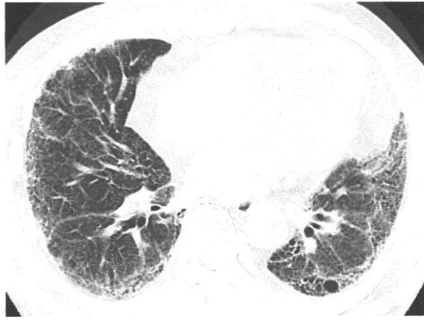
261

男性

増悪前CT画像

増悪時CT画像

増悪後CT画像



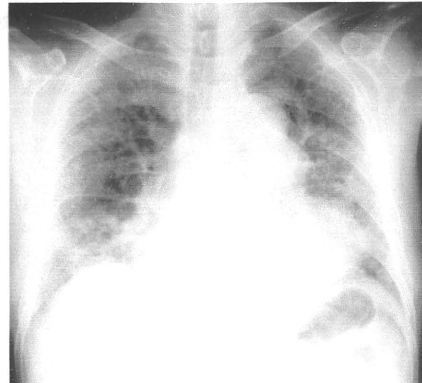
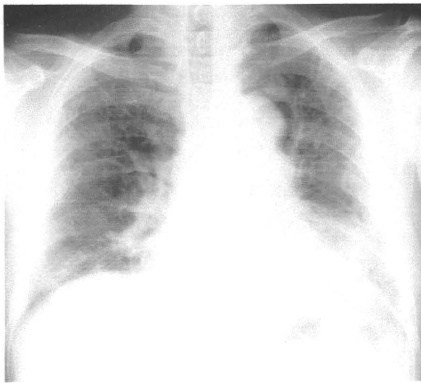
2009/06/18

2010/02/22

増悪前XP

増悪時XP

増悪後XP

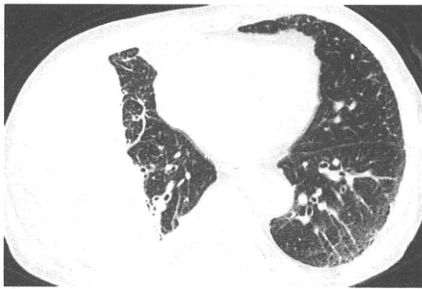


2009/06/18

2010/02/22

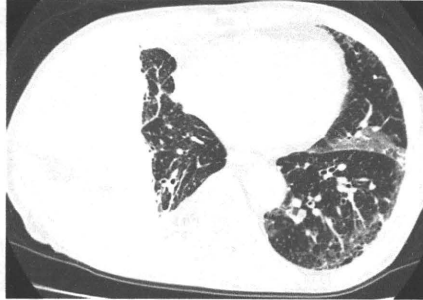
男性

増悪前CT画像



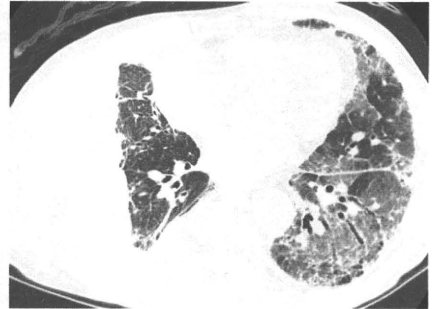2010/01/22

増悪時CT画像



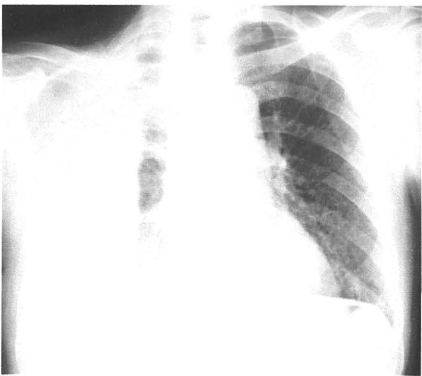2010/02/16

増悪後CT画像



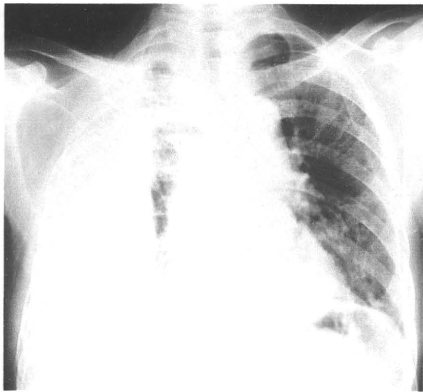
2010/03/18

増悪前XP



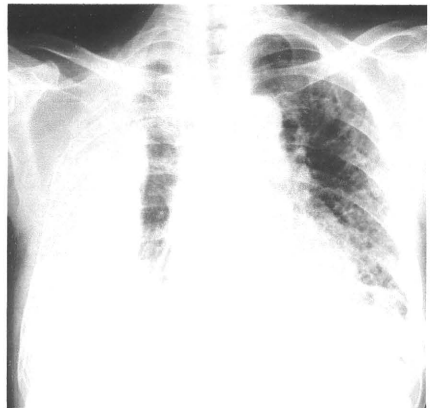
2010/01/26

増悪時XP



2010/02/17

増悪後XP



2010/03/18